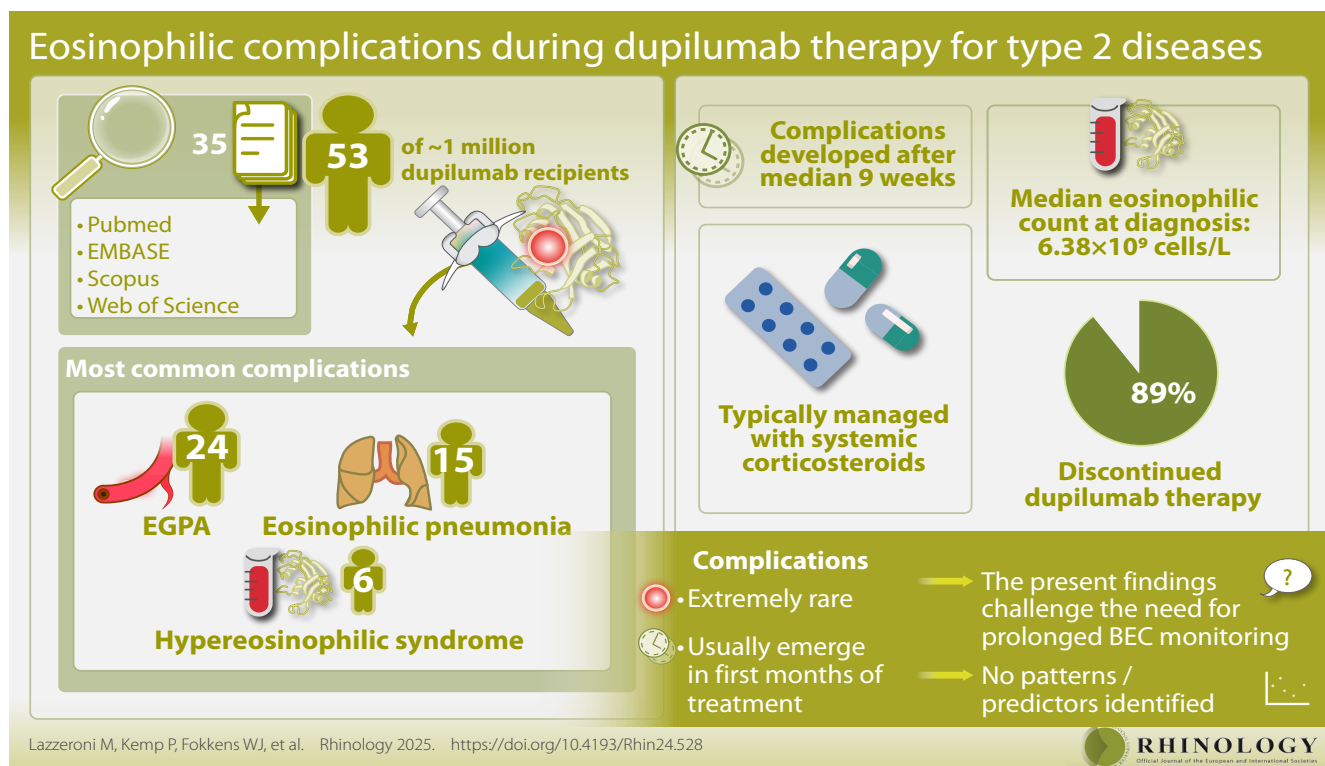


# Eosinophilic complications during dupilumab therapy for type 2 diseases: a systematic review

Matteo Lazzeroni<sup>\*,1,2</sup>, Pieter Kemp<sup>\*,1</sup>, Wytske J. Fokkens<sup>1</sup>, Sietze Reitsma<sup>1</sup>

Rhinology 63: 4, 0 - 0, 2025

<https://doi.org/10.4193/Rhin24.528>



## Abstract

**Background:** Dupilumab shows promising results in the management of several type 2 disorders. However, it often leads to transient, early increases in blood eosinophil count (BEC). This has led to awareness of possibly associated eosinophilic complications, such as eosinophilic granulomatosis with polyangiitis (EGPA) and hypereosinophilic syndrome (HES). Aim of the current work was to collect all eosinophilic complications reported in literature.

**Methodology:** PubMed, Embase, Scopus, and Web of Science were systematically searched for papers reporting on eosinophilic complications of dupilumab therapy for type 2 disorders.

**Results:** While around one million patients are treated with dupilumab globally, we identified a total of 35 reports on 53 patients. The most common complications were EGPA: 24 patients, eosinophilic pneumonia: 15, and HES: 6. Complications developed after a median of 9 (range: 0-71) weeks and the median eosinophilic count at the moment of diagnosis was  $6.38 \times 10^9$  cells/L (IQR 3.13-9.08). Most complications were treated with systemic corticosteroids. Of all patients, 89% discontinued dupilumab therapy and no deceased patients were reported.

**Conclusions:** Reported eosinophilic complications during dupilumab therapy are extremely rare and mostly develop during the first months of treatment, challenging the need for (prolonged) BEC monitoring during dupilumab therapy. No patient patterns or predictors were identified.

**Key words:** complication, dupilumab, eosinophilia, hypereosinophilic syndrome, EGPA

## Introduction

Type 2 inflammation is a response that the immune system physiologically employs to target parasites, venoms and toxins<sup>(1)</sup>. Under specific conditions, such as impaired epithelial integrity, an aberrant and perpetuated type 2 inflammatory response can arise. This leads to the development of the so-called type 2 chronic inflammatory diseases<sup>(2)</sup>, the most common of which are asthma, chronic rhinosinusitis with nasal polyps (CRSwNP), allergic rhinitis, atopic dermatitis (AD), and eosinophilic oesophagitis (EoE). Patients with such a condition are at risk of developing severe and uncontrolled symptoms characterized by poor response to conventional therapies<sup>(3,4)</sup>. Over the last years the increasing understanding of the molecular pathways of type 2 inflammation has led the way for the development of tailored therapies, designed to target specific etiopathological pathways (biological therapy)<sup>(1)</sup>.

Dupilumab is a humanized monoclonal antibody directed against the IL-4 receptor alpha subunit, which targets type 2 inflammation by blocking IL-4 and IL-13 signalling<sup>(5)</sup>. It has shown excellent results in the management of CRSwNP<sup>(6)</sup>, asthma<sup>(7)</sup>, atopic dermatitis<sup>(8)</sup> and eosinophilic esophagitis<sup>(9)</sup>. For severe uncontrolled CRSwNP specifically, it has the potential to reduce the need for surgery and oral corticosteroids and is much more effective in restoring the sense of smell than the foregoing therapies<sup>(10-14)</sup>. Reported treatment emergent adverse events from dupilumab are mostly mild and well-tolerable, both in phase III trials and real-life studies<sup>(15-24)</sup>. Injection site erythema, conjunctivitis (mostly in AD) and arthralgia are among the most reported. Furthermore, transient hyper eosinophilia (blood eosinophil count (BEC)  $> 1.5 \times 10^9$  cells/L) is relatively common during the first months of dupilumab treatment<sup>(25,26)</sup>.

The reporting of sporadic eosinophilic-related complications during dupilumab therapy has gained increasing attention from the scientific community<sup>(27)</sup>, due to the severe, life-threatening potential of these manifestations, such as hypereosinophilic syndrome (HES), eosinophilic granulomatosis with polyangiitis (EGPA) or other clinical manifestations of eosinophil-induced organ damage<sup>(28)</sup>. This has led to the development of strict clinical protocols for the monitoring of BEC during dupilumab therapy<sup>(25)</sup>.

The present study was set out to provide a comprehensive review of all reported eosinophilic complications that developed during dupilumab treatment for the most frequent indications (asthma, CRSwNP, atopic dermatitis and eosinophilic esophagitis). To the best of our knowledge, this is the first systematic review on the topic and our goal is to evaluate the necessity and duration of close BEC monitoring during dupilumab treatment.

## Materials and methods

The reporting of this study is in accordance with the PRISMA 2020 statement<sup>(29)</sup> and followed the recommendations of the

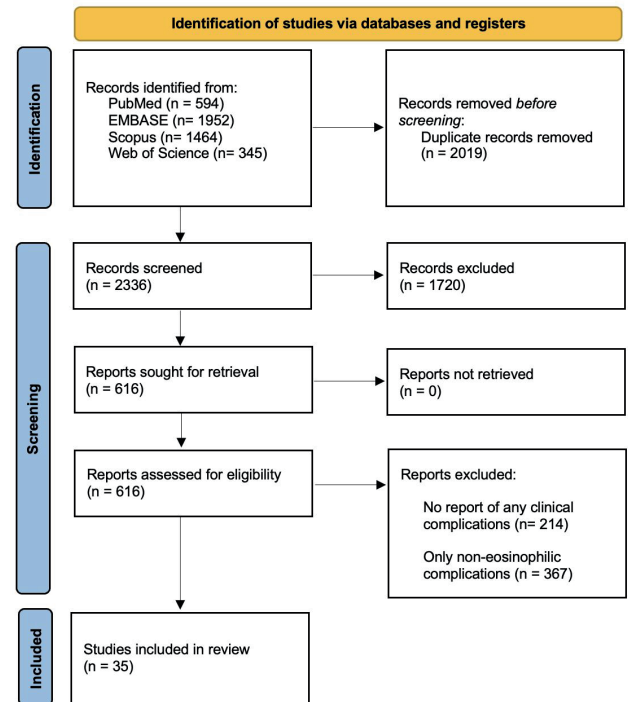


Figure 1. Prisma Flowchart of the study selection process.

Cochrane Handbook for Systematic Reviews of Interventions<sup>(30)</sup>.

### Eligibility criteria

We included studies that met the following eligibility criteria: 1) reports on patients receiving dupilumab treatment for Asthma, CRSwNP, Atopic Dermatitis or Eosinophilic Esophagitis, 2) presenting with eosinophilic complications.

### Search strategy and data extraction

We systematically searched PubMed, EMBASE, Scopus and Web of Science in May 2024 using "Dupilumab AND (eosinophilia OR eosinophils OR hypereosinophilia OR "hypereosinophilic syndrome")" as search strategy. Two authors (ML and PK) independently screened titles and abstracts; potential articles were read in full text. Disagreements were resolved through discussion, with the involvement of a third author (SR) acting as an arbiter if necessary. Every study that discussed the use of dupilumab for any of the included indications was read in full text. This approach was intended to ensure that no relevant study was missed, particularly the ones that did not mention eosinophilic complications in their title and abstract. Conference abstracts presenting patients with eosinophilic complications of dupilumab were also included in an effort towards making this systematic review as comprehensive as possible. Lastly, we consulted EudraVigilance, the electronic system for managing and analysing information on suspected adverse reactions to medicines in the European Economic Area, in an effort to contrast reporting bias or under-reporting in medical literature.

Table 1. Patients characteristics.

Study	Country	Design	No. of patients	Age (years)	Sex	Indication	Comorbidities	Complication	OCS therapy history	Time of onset (weeks) <sup>†</sup>	BEC <sup>‡</sup>	Treatment of complication	Discontinuation of dupilumab	Outcome <sup>§</sup>
Abulhamail et al. (2022) <sup>(34)</sup>	USA	Case report	1	77	F	Asthma, CRSwNP	Antibody deficiency	HES	/	12	30.83	Corticosteroids, Mepolizumab	Yes	Improvement
Adunse et al. (2021) <sup>(35)</sup>	USA	Case report	1	55	F	Der-matitis, bullous pemphigoid	Asthma	Eosinophilic pneumonia	/	10	17.00	Methylprednisone, followed by Prednisolone	Yes	Improvement
Albrecht et al. (2023) <sup>(62)</sup>	Germany	Cohort study	1	/	/	CRSwNP	Asthma	HES/EGPA	/	2	7.55	ICU admission, steroids, long term Methotrexate, Mepolizumab	Yes	Improvement
Bacharier et al. (2021) <sup>(51)</sup>	/	RCT	1	/	F	Asthma	/	HES	/	10	5.34	/	Yes	Resolution
Boscke et al. (2023) <sup>(22)</sup>	Germany	Cohort study	1	/	F	CRSwNP	Asthma, N-ERD	HES	/	12	2.77	Corticosteroids, then switch to Methotrexate and Mepolizumab	Yes	/
Briegel et al. (2021) <sup>(56)</sup>	Germany	Case series	1	50	M	Asthma, CRSwNP	Allergic rhino-conjunctivitis	Eosinophilic pneumonia	None	2	3.95	Prednisolone, Benralizumab	Yes	Improvement
Castro et al. (2018) <sup>(15)</sup>	/	RCT	4	50 56	M M	Asthma Asthma	CRSwNP /	HES Eosinophilic pneumonia	/ /	2 16	10.28 2.71	Hydrocortisone butyrate Levofloxacin, Piperacillin/ Tazobactam Prednisolone	Yes Yes	/ Resolution
				28	F	Asthma	/	Myositis, radi-culopathy	/	24	8.65	NSAID	No	Resolution
				52	F	Asthma	/	Eosinophilic pneumonia	/	18	4.92	Prednisolone	Yes	Resolution
De Corso et al. (2023) <sup>(19)</sup>	Italy	Cohort study	2	/	/	CRSwNP	/	Eosinophilic pneumonia	/	/	/	/	Yes	/
Descamps et al. (2021) <sup>(50)</sup>	France	Case report	1	61	F	Asthma	CRSwNP	Eosinophilic vasculitis	Yes (High dose OCS)	32	11.50	Benralizumab	No	Resolution
Eger et al. (2021) <sup>(57)</sup>	Netherlands	Case series	2	59 63	F F	Asthma Asthma	/	Eosinophilic pneumonia, CAD Stroke, EGPA	Yes (Prednisolone 20 mg/d) Yes (initially prednisolone 30 mg/d, then tapered to 22.5 mg/d)	/ 16	5.08 3.94	Prednisolone, Anticoagulants Prednisolone, Benralizumab	Yes Yes	Improvement Improvement
Gharibeh et al. (2022) <sup>(36)</sup>	USA	Case report	1	66	F	Asthma	/	Eosinophilic pneumonia	/	4	11.23	Prednisolone	Yes	Improvement
Iwamuro et al. (2020) <sup>(37)</sup>	Japan	Case report	1	77	M	Asthma	Atrophic rhinitis, hypertension, duodenal ulcers, hyperuricemia	Eosinophilic gastritis	None	12	/	Prednisolone	/	Resolution



Table 1 continued. Patients characteristics.

Study	Country	Design	No. of patients	Age (years)	Sex	Indication	Comorbidities	Complication	OCS therapy history	Time of onset (weeks) <sup>†</sup>	BEC <sup>‡</sup>	Treatment of complication	Discontinuation of dupilumab	Outcome <sup>§</sup>
Suzaki et al. (2023) <sup>(46)</sup>	Japan	Case report	1	63	F	Asthma, CRSwNP	Eosinophilic otitis media	EGPA	/	4	/	Prednisolone, Azathioprine, Cyclophosphamide, Mepolizumab	Yes	/
Tanaka et al. (2022) <sup>(47)</sup>	Japan	Case report	1	/	M	Asthma, CRSwNP	/	EGPA	None	5	17.40	Methylprednisolone	/	Resolution
Tohda et al. (2023) <sup>(52)</sup>	/	RCT	1	/	/	Asthma	/	EGPA	/	/	/	/	Yes	/
Von Deimling et al. (2023) <sup>(61)</sup>	Germany	Case series	2	25	F	Asthma, CRSwNP	/	EGPA	/	2	7.55	Prednisolone, Methotrexate	Yes	Resolution
			57	57	F	Asthma, CRSwNP	/	EGPA	/	8	3.20	Prednisolone, Rituximab	Yes	Resolution
Wenzel et al. (2016) <sup>(53)</sup>	/	RCT	1	/	/	Asthma	/	HES	/	7	/	Methylprednisolone	Yes	/
Yamazaki et al. (2022) <sup>(48)</sup>	Japan	Case report	1	77	F	Asthma	CRSwNP	EGPA	/	24	5.97	Prednisolone	Yes	/
Zhou et al. (2023) <sup>(49)</sup>	China	Case report	1	71	M	Atopic dermatitis	COPD	Eosinophilic pneumonia	/	1	1.60	Methylprednisolone followed by Prednisolone	No	Resolution
Wechsler et al. (2022) <sup>(54)</sup>	/	RCT	5	56	F	Asthma	Allergic rhinitis	EGPA	Yes, (Short cycles of OCS)	11	7.68	Rituximab, Azathioprine, Prednisolone	/	/
			30	30	F	Asthma	"Sinusitis" and allergic rhinitis	EGPA	/	71	/	/	/	/
			49	49	F	Asthma	CRSwNP	EGPA	Yes (Methylpredni-solone, short cycles)	6	7.30	Fluocortolone	Yes	Improvement
			38	38	F	Asthma	CRSwNP	EGPA	Yes (short cycles of OCS)	45	/	Prednisolone	Yes	/
			44	44	F	Asthma	/	EGPA	Yes (Predni-solone 5-20 mg/d)	25	8.55	/	/	Improvement
Bachert et al. (2019) <sup>(55)</sup>	/	RCT	2	/	/	CRSwNP	/	EGPA	/	/	/	/	/	/
Caminati et al. (2024) <sup>(65)</sup>	/	Case series	3	/	/	Asthma	/	EGPA	/	/	/	/	/	/

<sup>†</sup> time of onset of eosinophilic complication after dupilumab initiation (weeks). <sup>‡</sup> at onset of complication ( $\times 10^9$  cells/L). <sup>§</sup> We reported outcomes as "resolution" in case of total remission of the clinical condition, "improvement" in case of any persistence of clinical symptoms related to the eosinophilic complication. No. = number, BEC = Blood Eosinophil Count, OCS = oral corticosteroids, CRSwNP = Chronic Rhinosinusitis with Nasal Polyps, CRSsNP = Chronic Rhinosinusitis without Nasal Polyps, HES = hyper-eosinophilic syndrome, ICU = Intensive Care Unit, RCT = Randomized controlled trial, N-ERD = (NSAID)-exacerbated respiratory disease, EGPA = Eosinophilic granulomatosis with polyangiitis, CAD = Coronary Artery Disease

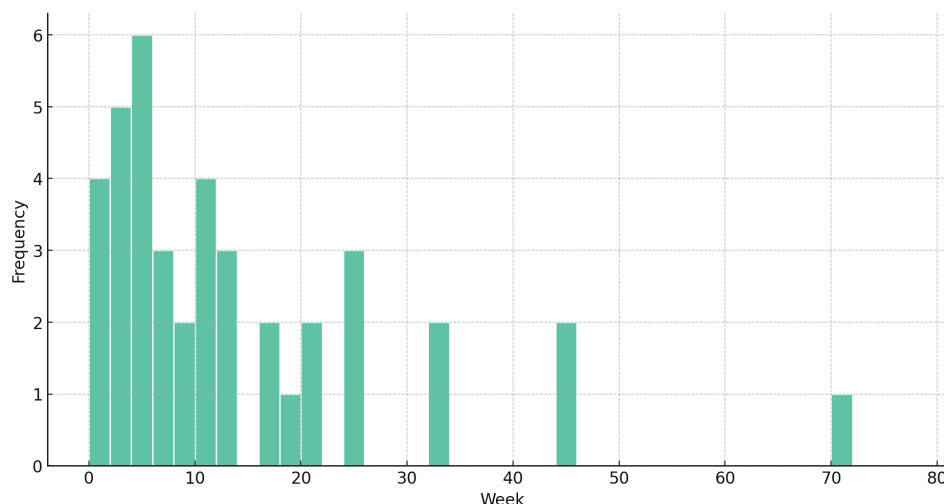


Figure 2. Histogram showing the time of onset (in weeks) of eosinophilic complications after dupilumab initiation.

The following information was retrieved from the included studies: name of the first author, year of publication, country, study design, patients' demographic characteristics (age, sex, comorbidities and medication history of oral corticosteroid use directly prior to start of dupilumab therapy), indication for dupilumab, type of eosinophilic complication, week of onset of eosinophilic complication after dupilumab initiation, BEC level at onset of the complication, treatment, clinical outcome, discontinuation of dupilumab.

### Statistical analysis

Due to the highly heterogeneous study designs and populations no statistical analysis was employed to provide quantitative synthesis. Data was summarized descriptively and presented as valid percentages or medians with interquartile range (IQR), unless otherwise specified. When applicable, visual representation of the results by appropriate graphs was provided using R (version 4.2.1; 2022-06-23).

### Quality assessment

The Cochrane Collaboration's tool RoB-2<sup>(31)</sup> was used to assess the risk of bias for RCTs by two independent reviewers, while the Risk Of Bias In Non-randomized Studies - of Interventions tool (ROBINS-I)<sup>(32)</sup> was used for observational studies. The Joanna Briggs Institute (JBI) critical appraisal checklist for case reports<sup>(33)</sup> was employed for case reports. Disagreements were settled through discussion, with a third author (SR) acting as an arbiter if necessary.

### Results

The search strategy yielded 4355 results. After the removal of duplicate records, 2336 remained. After screening on title and abstract, 616 articles were read in full text for eligibility. A total of 35 studies<sup>(15,19,22,34-65)</sup> met all inclusion criteria. We included 17

case reports<sup>(34-50)</sup>, 6 RCTs<sup>(15,51-55)</sup>, 7 case series<sup>(56-61,65)</sup> and 5 observational cohort studies<sup>(19,22,62-64)</sup>. The PRISMA flow diagram with the performed selection process is shown in Figure 1.

### Demographics

Patients' characteristics are presented in Table 1. In total, 53 patients were included. Their median age was 56 years (IQR 49-63). Of these patients, 73% were females and 27% were male. Dupilumab was prescribed for asthma in 27 patients, for both uncontrolled asthma and CRSwNP in 12, only CRSwNP in 10 and for atopic dermatitis in 4. No studies on eosinophilic esophagitis fulfilled the inclusion criteria for the present systematic review due to the lack of eosinophilic complications. Medication history of oral corticosteroid (OCS) use was available only for 22 of the 53 patients: among them 5 had not been taking OCS, and 9 had received short cycles of OCS treatment for asthma or CRSwNP exacerbations. Prior use of different biologics targeting type 2 inflammation, such as mepolizumab, omalizumab and benralizumab was reported only for 6 patients<sup>(50,57,58,61)</sup>.

### Eosinophilic complications

EGPA appeared in 24 patients, eosinophilic pneumonia in 15 and hyper eosinophilic syndrome in 6. We also found isolated reports of eosinophilic myopericarditis, eosinophilic pleuritis, myositis, eosinophilic vasculitis (non-EGPA), atrial fibrillation, stroke and anaphylaxis. The eosinophilic complications developed after a median of 9 (IQR 4-19) weeks following the first administration of dupilumab (Figure 2). The median eosinophilic count at the moment of diagnosis was  $6.38 \times 10^9$  cells/L (IQR 3.13-9.06). In 11 of the 24 EGPA patients, prior OCS use was reported; 6 used continuous or intensive OCS before dupilumab. Within 6 months of dupilumab treatment 85% of complications were identified; on a rare occasion, one patient was reported to develop EGPA after 71 weeks. This latter patient was a 30-year-

Study	Risk of bias domains					Overall
	D1	D2	D3	D4	D5	
Bacharier et al. (2021)	+	+	+	+	+	+
Bachert et al. (2019)	+	+	+	+	+	+
Castro et al. (2018)	+	+	+	+	+	+
Tohda et al. (2023)	-	+	+	-	+	-
Wechsler et al. (2022)	+	-	+	-	+	-
Wenzel et al. (2016)	+	+	+	+	+	+

Domains:  
D1: Bias arising from the randomization process.  
D2: Bias due to deviations from intended intervention.  
D3: Bias due to missing outcome data.  
D4: Bias in measurement of the outcome.  
D5: Bias in selection of the reported result.

Judgement  
- Some concerns  
+ Low

Figure 3. Results of the risk of bias assessment for randomized studies through the RoB2 tool.

old female with asthma as her main indication for dupilumab therapy. She was also reported to have ‘sinusitis and allergic rhinitis’, experienced multiple episodes of elevated BEC during dupilumab treatment and was diagnosed with EGPA after 71 weeks of treatment. Unfortunately, no further details were reported, such as BEC at baseline or at the discovery of EGPA, or history of any prior OCS use.

### Treatment and outcomes

Dupilumab therapy was discontinued in 89% of the patients and systemic glucocorticosteroids were started in 93% of cases. Specifically, oral prednisolone was prescribed in 60% of the patients, intravenous methylprednisolone in 18% and intravenous/subcutaneous hydrocortisone in 5%. Furthermore, 13% of the patients switched to mepolizumab and 13% to benralizumab. Among the studies reporting on patient outcomes, the eosinophilic complications did not lead to any death. Clinical remission was achieved in 62% of the cases, while 38% showed clinical improvement at least for the reported follow-up of these cases. Detailed information on treatments and outcomes is presented in Table 1.

### EudraVigilance consultation

Our search of the EudraVigilance database found 144 reported cases of EGPA, 119 cases of eosinophilic pneumonia and 20 cases of hyper eosinophilic syndrome. Of these patients 48% were female, 52% male. The vast majority (72%) of the cases was aged between 18-64 years. The complications resolved or are resolving without sequelae in 82% of the cases and resulted only in 2% of the cases in a fatal outcome.

### Quality assessment

As shown in Figure 3, four out of six included RCTs were deemed at “low” risk of bias, while two were rated as “some concerns”. Re-

garding observational studies the overall results are presented in Figure 4: two studies were deemed at “low” risk of bias, three at “moderate” and seven “critical”. The risk of bias assessment of case reports is presented in Supplementary Table 1.

### Discussion

This comprehensive systematic review on eosinophilic complications during dupilumab treatment highlights the rarity of these manifestations. In the entire literature, only 53 patients from a total of 35 studies were found to have developed eosinophilic complications, whereas at this moment (September 2024) roughly one million patients are receiving dupilumab therapy for its approved indications globally (Sanofi, personal communication).

The increased availability of type 2-targeted monoclonal antibodies has revolutionized the management of type 2 disorders such as asthma, CRSwNP, atopic dermatitis and eosinophilic esophagitis <sup>(1,2)</sup>. In case of dupilumab, transient BEC elevations are commonly reported. Although the exact mechanism underlying this effect is still not fully understood, it is thought that the inhibition of IL-4 downregulates the expression of vascular cell adhesion molecule 1 (VCAM1) in endothelial cells, and the inhibition of IL-13 suppresses the production of eotaxins, thus blocking eosinophilic migration from the bloodstream to peripheral organs <sup>(26)</sup>. The encounter of unusually high BEC has alarmed clinicians for potential manifestations of eosinophilic-mediated organ damage, leading to strict clinical protocols with frequent BEC monitoring. As we now show, the incidence of such complications during dupilumab therapy is extremely low. In atopic dermatitis, eosinophilic complications of dupilumab use are very rare. We currently do not have a sound explanation for this difference across the type2 diseases

Notably, the vast majority of the reported eosinophilic complications occurred in patients for which dupilumab was prescri-

Study	Risk of bias domains							Overall
	D1	D2	D3	D4	D5	D6	D7	
Albrecht et al. (2023)	⊖	⊕	⊕	⊕	⊕	⊕	⊕	⊖
Böscke et al. (2023)	⊕	⊕	⊕	⊕	⊖	⊕	⊕	⊖
Briegel et al. (2021)	⊖	⊖	⊕	⊖	⊕	⊖	⊕	⊖
De Corso et al. (2023)	⊕	⊕	⊕	⊕	⊕	⊕	⊕	⊕
Eger et al. (2021)	⊖	⊖	⊕	⊖	⊕	⊖	⊕	⊖
Fargeas et al. (2024)	⊖	⊖	⊕	⊖	⊕	⊖	⊕	⊖
Kurihara et al. (2022)	⊖	⊖	⊕	⊕	⊕	⊖	⊕	⊖
Kushima et al. (2023)	⊖	⊕	⊕	⊕	⊕	⊕	⊕	⊖
Lommatzsch et al. (2021)	⊖	⊖	⊕	⊕	⊕	⊕	⊕	⊖
Numata et al. (2022)	⊕	⊕	⊕	⊕	⊕	⊕	⊕	⊕
Von Delming et al. (2023)	⊖	⊖	⊕	⊕	⊕	⊕	⊕	⊖
Caminati et al. (2024)	⊖	⊖	⊕	⊖	⊕	⊖	⊕	⊖

Domains:  
D1: Bias due to confounding.  
D2: Bias due to selection of participants.  
D3: Bias in classification of interventions.  
D4: Bias due to deviations from intended interventions.  
D5: Bias due to missing data.  
D6: Bias in measurement of outcomes.  
D7: Bias in selection of the reported result.

Judgement  
⊖ Critical  
⊖ Serious  
⊖ Moderate  
⊕ Low

Figure 4. ROBINS-I tool evaluation of the risk of bias for observational studies.

bed for asthma or CRSwNP, and not in any case for eosinophilic esophagitis. This may be since dupilumab was only approved by regulatory organizations for this latter condition in 2022<sup>(66)</sup> and large-scale data regarding its safety in this context is lacking, especially in real life settings.

The most common eosinophilic complication under dupilumab therapy was found to be EGPA. However, it is still unclear if dupilumab treatment can directly lead to the development of the disease or if its role is only to unmask an already existing EGPA<sup>(67)</sup>, by allowing patients on chronic glucocorticosteroid therapy for type 2 diseases to taper their treatment<sup>(58)</sup>. In this regard, EGPA manifestations have also been described following the introduction of other anti-type 2 monoclonal antibodies, such as omalizumab<sup>(68,69)</sup> and benralizumab<sup>(70)</sup>. More recently, the potential safety and efficacy of an off-label application of dupilumab for refractory EGPA-related asthma and CRSwNP has been explored<sup>(71)</sup>. As shown in Figure 2, four of the included eosinophilic complications have occurred in the first two weeks after the administration of the first dose of dupilumab. Especially in these early onset cases it is important to consider the role of other contributing factors such as masked eosinophilic systemic conditions.

In regard to our findings, the relatively high number of patients with systemic corticosteroid-dependence before dupilumab initiation in those with reported EGPA seems to suggest this disease was already present at baseline. However, medication history of oral corticosteroid use was reported only for 44% of the patients included in the present review and should be considered by future studies on eosinophilic complications related

to dupilumab.

Most of the complications that we found developed within the first 24 weeks of treatment (Figure 2): this coincides with the timeframe in which transient eosinophilic peaks are observed during dupilumab therapy<sup>(3,27)</sup>. A meta-analysis by Zhou et al.<sup>(27)</sup> has shown alternated increases and decreases of BECs between weeks 8 and 24 after treatment initiation. Furthermore, a post hoc analysis of randomised controlled trials (RCTs) by Wechsler et al.<sup>(3)</sup> indicated that from week 24 BECs start to decline generally below baseline and are not associated to severe adverse events. Indeed, in our review eosinophilic levels were markedly elevated in most cases, being 2 (6%) times only (39,60) under the threshold of  $1.5 \times 10^9$  cells/L typically used to define hypereosinophilia<sup>(72)</sup>. All reported eosinophilic complications but one were identified within the first year of treatment. This suggests that strict BEC monitoring after the first 52 weeks is not necessary (and one could argue whether monitoring is relevant at all in the light of the very low number of reported complications). This study underscores the rarity of eosinophilic complications during dupilumab therapy for any type 2 indication. Our results corroborate the safety profiles of dupilumab, suggesting that the transient elevations of eosinophilic levels observed during the first months of treatment are seldom associated with clinical complications.

The present study has some limitations. General conclusions drawn from our results should be interpreted with caution due to the limited number of included patients and the risk of underreported eosinophilic complications in current literature. Indeed, publication bias and underreporting of adverse events pose a challenge to the quality of systematic reviews<sup>(73)</sup> and to address this issue we have also searched for eosinophilic complications of dupilumab in the database of the European Medicines Agency, EudraVigilance. The numbers of reported suspected adverse events that we found were somewhat higher than those present in medical literature, but still extremely small compared to the overall number of patients that are being treated by dupilumab. The same consideration applies to the recently published results of Gershnel Milk et al. who provide an overview of eosinophilic complications of dupilumab, among other anti-type 2 inflammation biologics, according to the Food and Drug Administration Adverse Event Reporting System Public Dashboard<sup>(74)</sup>. Even if fatal outcomes were not reported in current literature, the real-life data of eosinophilic complications in the EudraVigilance database comprised two patient deaths. However, these are impossible to contextualize since no specific patient information is provided in these cases.

## Conclusion

In the attempt to make the present review as comprehensive as possible different types of studies were included, with a hetero-



geneous quality of evidence that needs to be considered when interpreting our results. Furthermore, due to the high variability in study design, populations, and interventions undertaken after the onset of eosinophilic complications of dupilumab, we did not perform a meta-analysis in accordance with the recommendations outlined in the Cochrane Handbook for Systematic Reviews of Interventions<sup>(30)</sup>. Despite these limitations, the occurrence of eosinophilic complications during treatment with dupilumab is extremely rare, challenging the need for (prolonged) BEC monitoring in these patients.

## Acknowledgements

None.

## Authors' contributions

ML: data curation, formal analysis, investigation, methodology,

writing - original draft; PK: data curation; formal analysis, investigation, methodology, writing - review & editing; WF: supervision, validation, methodology, writing - review & editing; SR: conceptualization, project administration, validation, supervision, writing - review & editing.

## Funding

None

## Conflicts of interest

ML and PK have no conflict of interest to declare. WF is an advisory board member of Sanofi, GSK, and Dianotic. SR has acted as a consultant and/or advisory board member for Sanofi, GSK, and Novartis. The department of Otorhinolaryngology and Head/Neck Surgery of the Amsterdam UMC has received research funding from Sanofi, GSK, and Novartis.

## References

- Kolkhir P, Akdis CA, Akdis M, et al. Type 2 chronic inflammatory diseases: targets, therapies and unmet needs. *Nat Rev Drug Discov.* 2023;22(9):743-767.
- Akdis CA. Does the epithelial barrier hypothesis explain the increase in allergy, autoimmunity and other chronic conditions? *Nat Rev Immunol.* 2021;21(11):739-751.
- Wechsler ME, Klion AD, Paggiaro P, et al. Effect of dupilumab on blood eosinophil counts in patients with asthma, chronic rhinosinusitis with nasal polyps, atopic dermatitis, or eosinophilic esophagitis. *J Allergy Clin Immunol Pract.* 2022;10(10):2695-2709.
- Senna G, Micheletto C, Piacentini G, et al. Multidisciplinary management of type 2 inflammatory diseases. *Multidiscip Respir Med.* 2022;17(1):813.
- Harb H, Chatila TA. Mechanisms of Dupilumab. *Clin Exp Allergy.* 2020;50(1):5-14.
- Wu Q, Zhang Y, Kong W, et al. Which is the best biologic for nasal polyps: dupilumab, omalizumab, or mepolizumab? a network meta-analysis. *Int Arch Allergy Immunol.* 2022;183(3):279-288.
- Nopsopon T, Lassiter G, Chen ML, et al. Comparative efficacy of tezepelumab to mepolizumab, benralizumab, and dupilumab in eosinophilic asthma: a Bayesian network meta-analysis. *J Allergy Clin Immunol.* 2023;151(3):747-755.
- Chu AWL, Wong MM, Rayner DG, et al. Systemic treatments for atopic dermatitis (eczema): systematic review and network meta-analysis of randomized trials. *J Allergy Clin Immunol.* 2023;152(6):1470-1492.
- Aziz M, Haghbin H, Gangwani M, et al. Efficacy of dupilumab in eosinophilic esophagitis: a systematic review and meta-analysis of randomized controlled trials. *Am J Ther.* 2024;31(1):e43-e45.
- Desrosiers M, Mannent LP, Amin N, et al. Dupilumab reduces systemic corticosteroid use and sinonasal surgery rate in CRSwNP. *Rhinology.* 2021;59(3):301-311.
- Lee SE, Amin N, Mannent LP, et al. The relationship of sinus opacification, olfaction and dupilumab efficacy in patients with CRSwNP. *Rhinology.* 2023;61(6):531-540.
- Mauthe T, Meerwein CM, Ryser FS, et al. Screening olfaction under dupilumab in chronic rhinosinusitis with nasal polyps. *Rhinology.* 2024;62(4):496-505.
- Otten JJ, van der Lans RJJ, Benoist LB, et al. Steroid responsiveness predicts olfactory function recovery in dupilumab treated CRSwNP. *Rhinology.* 2024;62(4):403-409.
- Haxel BR, Fischer L, Pade J, Reden J, Hummel T. Nasal polyp load determines the recovery of olfaction after surgery for chronic rhinosinusitis. *Rhinology.* 2022;60(2):102-108.
- Castro M, Corren J, Pavord ID, et al. Dupilumab efficacy and safety in moderate-to-severe uncontrolled asthma. *N Engl J Med.* 2018;378(26):2486-2496.
- Blauvelt A, de Bruin-Weller M, Gooderham M, et al. Long-term management of moderate-to-severe atopic dermatitis with dupilumab and concomitant topical corticosteroids (LIBERTY AD CHRONOS): a 1-year, randomised, double-blinded, placebo-controlled, phase 3 trial. *Lancet.* 2017;389(10086):2287-2303.
- Dellon ES, Rothenberg ME, Collins MH, et al. Dupilumab in adults and adolescents with eosinophilic esophagitis. *N Engl J Med.* 2022;387(25):2317-2330.
- van der Lans RJJ, Otten JJ, Adriaansen GFJPM, et al. Two-year results of tapered dupilumab for CRSwNP demonstrates enduring efficacy established in the first 6 months. *Allergy.* 2023;78(10):2684-2697.
- De Corso E, Pasquini E, Trimarchi M, et al. Dupilumab in the treatment of severe uncontrolled chronic rhinosinusitis with nasal polyps (CRSwNP): a multicentric observational Phase IV real-life study (DUPIREAL). *Allergy.* 2023;78(10):2669-2683.
- Huber P, Förster-Ruhrmann U, Olze H, et al. Real-world data show sustained therapeutic effects of dupilumab in chronic rhinosinusitis with nasal polyps (CRSwNP) over 3 years. *Allergy.* 2024;79(11):3108-3117.
- Kiricsi A, Bella Z, Kraxner H, et al. Real-life effectiveness of dupilumab in chronic rhinosinusitis with nasal polyps. Results from eight Hungarian centres with 12-month follow-up. *Rhinology.* 2024;62(4):410-420.
- Boscke R, Heidemann M, Bruchhage KL. Dupilumab for chronic rhinosinusitis with nasal polyps: real-life retrospective 12-month effectiveness data. *Rhinology.* 2023;61(3):203-213.
- Haxel BR, Hummel T, Fruth K, et al. Real-world-effectiveness of biological treatment for severe chronic rhinosinusitis with nasal polyps. *Rhinology.* 2022;60(6):435-443.
- Cutroneo PM, Arzenton E, Furci F, et al. Safety of biological therapies for severe asthma: an analysis of suspected adverse reactions reported in the who pharmacovigilance database. *BioDrugs.* 2024;38(3):425-448.
- Kemp P, van der Lans RJJ, Otten JJ, et al. Hypereosinophilia during dupilumab treatment in patients with chronic rhinosinusitis with nasal polyps. *Rhinology.* 2024;62(2):202-207.
- Ryser FS, Yalamanoglu A, Valaperti A, et al. Dupilumab-induced eosinophilia in patients with diffuse type 2 chronic rhinosinusitis. *Allergy.* 2023;78(10):2712-2723.
- Zhou B, Liang S, Shang S, Xiang L, Li L. The changes of eosinophil counts in patients after treatment of Dupilumab: a systematic review and meta-analysis. *Allergy.* 2022;77(12):3690-3694.
- Caminati M, Micheletto C, Norelli F, et al.

- Safety of dupilumab in T2 airways conditions: focus on eosinophilia across trials and real-life evidence. *Expert Opin Biol Ther.* 2024;24(1-2):15-23.
29. Page MJ, Moher D, Bossuyt PM, et al. PRISMA 2020 explanation and elaboration: updated guidance and exemplars for reporting systematic reviews. *BMJ.* 2021;372:n160.
  30. Higgins JPT, Thomas J, Chandler J, Cumpston M, Li T, Page MJ, Welch VA (editors). *Cochrane handbook for systematic reviews of interventions version 6.4 (updated August 2023).* Cochrane, 2023. [www.training.cochrane.org/handbook](http://www.training.cochrane.org/handbook).
  31. Sterne JAC, Savović J, Page MJ, et al. RoB 2: a revised tool for assessing risk of bias in randomised trials. *BMJ.* 2019;366:l4898.
  32. Sterne JA, Hernán MA, Reeves BC, et al. ROBINS-I: a tool for assessing risk of bias in non-randomised studies of interventions. *BMJ.* 2016;355:i4919.
  33. Moola S, Munn Z, Tufanaru C, et al. Chapter 7: Systematic reviews of etiology and risk. In: *Aromataris E, Munn Z (Editors). JBI Manual for Evidence Synthesis.* JBI, 2020. <https://synthesismanual.jbi.global>.
  34. Abulhamail A, Kelbel T, Lin J, Funderburk L. Dupilumab induced hypereosinophilic syndrome (HES). *Ann Allergy Asthma Immunol.* 2022;129:5.
  35. Adunse JU, Yoon Y, Taleb M, et al. A case of Dupilumab-induced Eosinophilic pneumonia. *Am Thoracic Society*, 2021. A2126-A2126. 10.1164/ajrccm-conference.2021.203.1\_MeetingAbstracts.A2126.
  36. Gharaibeh K, Alsaid H, Robinett K, et al. Dupilumab-induced severe hypereosinophilia complicated with Eosinophilic pneumonia. *Chest* 162.4 (2022): A1276-A1277.
  37. Iwamura M, Murakami T, Tanaka T, et al. Eosinophilic gastritis in a patient previously treated with dupilumab. *Case Rep Gastrointest Med.* 2020;6:381670.
  38. Kai M, Vion PA, Boussouar S, Cacoub P, Saadoun D, Le Joncour A. Eosinophilic granulomatosis polyangiitis (EGPA) complicated with periaortitis, precipitating role of dupilumab? a case report: a review of the literature. *RMD Open.* 2023;9(3):e003300.
  39. Kamimura S, Ishitani K, Azuma T, Kitamura Y. A case of eosinophilic granulomatosis with polyangiitis that developed after the initial administration of dupilumab. *Pract Otorhinolaryngol.* 2023;116:11 (1097-1102).
  40. Kanata K, Shirai T, Ichijo K, Uehara M. Eosinophilic pneumonia developed after dupilumab administration in a patient with atopic dermatitis. *Respirol Case Rep.* 2023;11(8):e01192.
  41. Li J. A case of hypereosinophilic myocarditis following dupilumab. *Allergy Asthma Proc.* 2023;44:3(213)
  42. Menzella F, Montanari G, Patricelli G, et al. A case of chronic eosinophilic pneumonia in a patient treated with dupilumab. *Ther Clin Risk Manag.* 2019;15:869-875.
  43. Persaud P, Karmali R, Sankar P, Majid M. Dupilumab-associated eosinophilic granulomatosis with polyangiitis. *Cureus.* 2022;14(8):e27670.
  44. Poelhekken M, Rosenberg FM, Oldhoff JM, et al. Dupilumab in a child with severe atopic dermatitis and severe asthma—a rare case with severe limbic and exercise-induced anaphylaxis. *Int J Dermatol.* 2022;61(10):e400-e401.
  45. Sudo T, Tsuda T, Hayama M, et al. Co-treatment with steroid and dupilumab for eosinophilic chronic rhinosinusitis after eosinophilic pneumonitis caused by dupilumab. *Ear Nose Throat J.* 2022. 104(1\_suppl):395-415.
  46. Suzuki I, Tanaka A, Yanai R, et al. Eosinophilic granulomatosis with polyangiitis developed after dupilumab administration in patients with eosinophilic chronic rhinosinusitis and asthma: a case report. *BMC Pulm Med.* 2023;23(1):130.
  47. Tanaka S, Tsuji T, Shiotsu S, Yuba T, Hiraoka N. Exacerbation of eosinophilic granulomatosis with polyangiitis after administering dupilumab for severe asthma and eosinophilic rhinosinusitis with nasal polyposis. *Cureus.* 2022;14(5):e25218.
  48. Yamazaki K, Nomizo T, Hatanaka K, Hayama N, Oguma T, Asano K. Eosinophilic granulomatosis with polyangiitis after treatment with dupilumab. *J Allergy Clin Immunol Glob.* 2022;1(3):180-182.
  49. Zhou X, Yang G, Zeng X, et al. Dupilumab and the potential risk of eosinophilic pneumonia: case report, literature review, and FAERS database analysis. *Front Immunol.* 2024;14:1277734.
  50. Descamps V, Deschamps L, El Khalifa J, et al. Eosinophilic vasculitis associated with persistent dupilumab-induced hypereosinophilia in severe asthma. *Respir Med Res.* 2021;79:100821.
  51. Bacharier LB, Maspero JF, Katelaris CH, et al. Dupilumab in Children with Uncontrolled Moderate-to-Severe Asthma. *N Engl J Med.* 2021;385(24):2230-2240.
  52. Tohda Y, Nakamura Y, Fujisawa T, et al. Efficacy of dupilumab in patients with uncontrolled, moderate-to-severe asthma recruited from Japanese centers in the phase 3 LIBERTY ASTHMA TRAVERSE study. *Allergol Int.* 2023;72(1):89-99.
  53. Wenzel S, Castro M, Corren J, et al. Dupilumab efficacy and safety in adults with uncontrolled persistent asthma despite use of medium-to-high-dose inhaled corticosteroids plus a long-acting  $\beta_2$  agonist: a randomised double-blind placebo-controlled pivotal phase 2b dose-ranging trial. *Lancet.* 2016;388(10039):31-44.
  54. Wechsler ME, Ford LB, Maspero JF, et al. Long-term safety and efficacy of dupilumab in patients with moderate-to-severe asthma (TRAVERSE): an open-label extension study. *Lancet Respir Med.* 2022;10(1):11-25.
  55. Bachert C, Han JK, Desrosiers M, et al. Efficacy and safety of dupilumab in patients with severe chronic rhinosinusitis with nasal polyps (LIBERTY NP SINUS-24 and LIBERTY NP SINUS-52): results from two multicentre, randomised, double-blind, placebo-controlled, parallel-group phase 3 trials. *Lancet.* 2019;394(10209):1638-1650.
  56. Briegel I, Felicio-Briegel A, Mertsch P, Kneidinger N, Haubner F, Milger K. Hypereosinophilia with systemic manifestations under dupilumab and possibility of dual benralizumab and dupilumab therapy in patients with asthma and CRSwNP. *J Allergy Clin Immunol Pract.* 2021;9(12):4477-4479.
  57. Eger K, Pet L, Weersink EJM, Bel EH. Complications of switching from anti-IL-5 or anti-IL-5R to dupilumab in corticosteroid-dependent severe asthma. *J Allergy Clin Immunol Pract.* 2021;9(7):2913-2915.
  58. Fargeas M, Devouassoux G, Gerfaud-Valentin M. Onset of eosinophilic granulomatosis with polyangiitis (EGPA) after anti-IL-2 biotherapy initiation in severe asthma patients: Report of 3 cases. *Respir Med Res.* 2024;85:101070.
  59. Kurihara M, Masaki K, Matsuyama E, et al. How can dupilumab cause eosinophilic pneumonia? *Biomolecules.* 2022;12(12):1743.
  60. Lommatzsch M, Stoll P, Winkler J, et al. Eosinophilic pleural effusion and stroke with cutaneous vasculitis: two cases of dupilumab-induced hypereosinophilia. *Allergy.* 2021;76(9):2920-2923.
  61. von Deimling M, Koehler TC, Frye BC, Maerker-Hermann E, Venhoff N. Two cases with new onset of ANCA-positive eosinophilic granulomatosis with polyangiitis under treatment with dupilumab: coincidence or causality? *Ann Rheum Dis.* 2023;82(4):580-582.
  62. Albrecht T, Sailer MM, Capitani F, van Schaik C, Löwenheim H, Becker S. Real-world evidence for the effectiveness and safety of dupilumab in patients with CRSwNP after 1 year of therapy. *World Allergy Organ J.* 2023;16(5):100780.
  63. Kushima Y, Shimizu Y, Hoshi H, et al. Changes in peripheral blood eosinophil counts and risk of eosinophilic granulomatosis with polyangiitis onset after initiation of dupilumab administration in adult patients with asthma. *J Clin Med.* 2023;12(17):5721.
  64. Numata T, Araya J, Miyagawa H, et al. Real-world effectiveness of dupilumab for patients with severe asthma: a retrospective study. *J Asthma Allergy.* 2022;15:395-405.
  65. Caminati M, Fassio A, Alberici F, et al. Eosinophilic granulomatosis with polyangiitis onset in severe asthma patients on monoclonal antibodies targeting type 2 inflammation: report from the European EGPA study group. *Allergy.* 2024;79(2):516-519.
  66. Falk GW, Pesek R. Pharmacologic management of eosinophilic esophagitis. *Immunol Allergy Clin North Am.* 2024;44(2):245-264.
  67. Olaguibel JM, Sastre J, Rodríguez JM, Del Pozo V. Eosinophilia induced by blocking the IL-4/IL-13 pathway: potential mechanisms and clinical outcomes. *J Invest Allergol Clin Immunol.* 2022;32(3):165-180.

68. Wechsler ME, Wong DA, Miller MK, Lawrence-Miyasaki L. Churg-strauss syndrome in patients treated with omalizumab. *Chest*. 2009;136(2):507-518.
69. Cazzola M, Mura M, Segreti A, Mattei MA, Rogliani P. Eosinophilic pneumonia in an asthmatic patient treated with omalizumab therapy: forme-fruste of Churg-Strauss syndrome? *Allergy*. 2009;64(9):1389-1390.
70. Hočevár A, Kopač P, Rotar Ž, Novljan MP, Škrbat S. Eosinophilic granulomatosis with polyangiitis evolution during severe eosinophilic asthma treatment with benralizumab. *J Allergy Clin Immunol Pract*. 2020;8(7):2448-2449.
71. Molina B, Padoan R, Urban ML, et al. Dupilumab for relapsing or refractory sinonasal and/or asthma manifestations in eosinophilic granulomatosis with polyangiitis: a European retrospective study. *Ann Rheum Dis*. 2023;82(12):1587-1593.
72. Nguyen L, Saha A, Kuykendall A, Zhang L. Clinical and therapeutic intervention of hypereosinophilia in the era of molecular diagnosis. *Cancers (Basel)*. 2024;16(7):1383.
73. Hazell L, Shakir SA. Under-reporting of adverse drug reactions: a systematic review. *Drug Saf*. 2006;29(5):385-396.
74. Gershnel Milk D, Lam KK, Han JK. Postmarketing analysis of eosinophilic adverse reactions in the use of biologic therapies for Type 2 inflammatory conditions. *Am J Rhinol Allergy*. 2025;39(1):38-48.

Matteo Lazzeroni, MD  
Department of Otorhinolaryngology  
Head and Neck Surgery  
Amsterdam UMC  
University of Amsterdam  
Amsterdam  
The Netherlands

E-mail:  
m.lazzeroni@amsterdamumc.nl

Matteo Lazzeroni<sup>\*,1,2</sup>, Pieter Kemp<sup>\*,1</sup>, Wytse J. Fokkens<sup>1</sup>, Sietze Reitsma<sup>1</sup>

<sup>1</sup> Amsterdam Rhinology Team, Department of Otorhinolaryngology and Head and Neck Surgery, Amsterdam UMC, University of Amsterdam, Amsterdam, The Netherlands

<sup>2</sup> Department of Biomedical, Surgical and Dental Sciences, University of Milan, Milan, Italy

\* equally share first authorship

**Rhinology** 63: 4, 0 - 0, 2025  
<https://doi.org/10.4193/Rhin24.528>

**Received for publication:**  
December 7, 2023

**Accepted:** March 20, 2025

**Associate Editor:**  
Michael Soyka

**This manuscript contains online supplementary material**

**Rhinology Vol 63, No 4, August 2025**

## SUPPLEMENTARY MATERIAL

Table S1. JBI checklist for case reports.

	Were patient's demographic characteristics clearly described?	Was the patient's history clearly described and presented as a timeline?	Was the current clinical condition of the patient on presentation clearly described?	Were diagnostic tests or assessment methods and the results clearly described?	Was the intervention(s) or treatment procedure(s) clearly described?	Was the post-intervention clinical condition clearly described?	Were adverse events (harms) or unanticipated events identified and described?	Does the case report provide takeaway lessons?
Abulhamail et al. (2022)	Yes	No	Yes	No	No	Yes	No	No
Adunse et al. (2021)	Yes	No	Yes	Yes	No	No	No	No
Descamps et al. (2021)	Yes	Yes	Yes	Yes	Yes	Yes	No	Yes
Gharaibeh et al. (2022)	Yes	No	Yes	Yes	No	No	No	Yes
Iwamuro et al. (2020)	Yes	Yes	Yes	Yes	No	No	No	Yes
Kai et al. (2023)	Yes	Yes	Yes	Yes	Yes	Yes	No	Yes
Kamimura et al. (2023)	No	No	Yes	Yes	No	No	No	No
Kanata et al. (2023)	Yes	No	Yes	Yes	Yes	Yes	No	Yes
Li et al. (2021)	Yes	No	No	Yes	No	No	No	No
Menzella et al. (2019)	Yes	Yes	Yes	Yes	Yes	Yes	No	Yes
Persaud et al. (2022)	Yes	Yes	Yes	Yes	No	No	No	Yes
Poelheken et al. (2022)	Yes	No	Yes	No	No	Yes	No	Yes
Sudo et al. (2022)	Yes	No	Yes	No	Yes	Yes	No	Yes
Suzaki et al. (2023)	Yes	No	Yes	Yes	Yes	Yes	No	Yes
Tanaka et al. (2022)	Yes	No	Yes	Yes	Yes	Yes	No	Yes
Yamazaki et al. (2022)	Yes	Yes	Yes	Yes	Yes	Yes	No	Yes
Zhou et al. (2023)	Yes	Yes	Yes	Yes	No	Yes	No	Yes