

The Lamella Ostium Extent Mucosa (LOEM) system: a new classification for endoscopic sinus surgery*

Serafin Sanchez-Gomez¹, Ramon Moreno-Luna¹, Daniel Martin-Jimenez^{1,2}, Juan Maza-Solano¹, Alfonso del Cuvillo³, Jose M. Villacampa-Auba⁴, Jaime Gonzalez-Garcia¹, Rafael Fernandez-Liesa⁵, Isam Alobid⁶, Manuel Bernal-Sprekelsen⁶

Rhinology 63: 1, 125 - 128, 2025

<https://doi.org/10.4193/Rhin24.370>

***Received for publication:**

August 22, 2024

Accepted: October 7, 2024

¹ Rhinology Unit, Department of Otolaryngology, Head and Neck Surgery, Virgen Macarena University Hospital, Seville, Spain

² Department of Otolaryngology, Head and Neck Surgery, Alava University Hospital, Alava, Spain

³ Rhinology and Asthma Unit, Department of Otolaryngology, Jerez University Hospital, Jerez, Spain

⁴ ENT and Cervicofacial Surgery Department, Fundacion Jimenez Diaz University Hospital, Madrid, Spain

⁵ Rhinology and Anterior Skull Base Unit, ENT Department, Hospital Universitario Miguel Servet, Zaragoza, Spain

⁶ Rhinology and Skull Base Unit, Department of Otorhinolaryngology, Hospital Clinic, Barcelona, Spain

Associate Editor:

Michael Soyka

Dear Editor:

In the last decades, various types of endoscopic sinus surgery (ESS) have emerged as treatments for chronic rhinosinusitis (CRS), particularly with the development of personalized, endotype-driven approaches targeting mucosal inflammation and remodeling ⁽¹⁾. Despite these advancements, the literature reports heterogeneous and often divergent outcomes, leaving the actual benefit of more extensive surgical approaches in CRS control a matter of ongoing debate ^(2,3). This discrepancy stems from inconsistent definitions of surgical techniques, leading to variations in osseous and mucosal resections depending on patient phenotype, disease severity and surgeon preference ⁽⁴⁾. To address this inconsistency, the Japanese Rhinology Society introduced a classification based on procedure extent, but it lacks details on anatomical structures and mucosal treatment ⁽⁵⁾. Similarly, the ACCESS system measures ESS extent with postoperative CT-scans but overlooks mucosal interventions ⁽⁶⁾.

In response, we propose a new classification for ESS: the Lamella Ostium Extent Mucosa (LOEM) system. This classification offers a standardized method for coding the extent of ESS performed and comprehensively describes the procedures on the bony structures and mucosa of the sinonasal cavity. No additional post-surgical tests are required, as it is applied directly by the surgeon. In cases of revision ESS, CT-scans, preoperative endoscopic findings and the previous surgical reports can provide complementary information. The development process for this system has followed a rigorous process involving only expert rhinologist and skull base surgeons. All rhinologists had over 15 years of experience performing ESS for CRS patients (>80 cases/year). A preliminary validation in two rounds and at two points in time, using several surgical video cases, was conducted by these experts to resolve discrepancies and consolidate the

thorough and accurate description of this classification.

The LOEM system categorizes surgical procedures into types based on two criteria: anatomy and functionality. The anatomical criterion considers the anteroposterior longitudinal extent involving the lamella (L), the enlargement of ostia/opening (O) and the removal of the sinus wall (E). The functionality criterion (M) is based on the intended outcome of the procedure: preserve sinus aeration and mucociliary function (limited/extended functional surgeries), completely target the mucosa (reboot surgery) ⁽⁷⁾, or perform regenerative surgery (mucoplasty) ^(8,9). To operationalize this, LOEM uses a lettering system to differentiate specific topographic levels of surgical intervention, based on widely-accepted anatomical nomenclature. A subscript code identifies the specific anatomical structures associated with each topographic level (Supplementary Table S1). A categorization of multiple ESS procedures into four distinct groups is shown in Table 1, facilitating a streamlined comparison of surgical approaches across diverse studies and centers. Figures 1 and Supplementary Figures S1–2 depict the technical procedures described in LOEM on each of the anatomical structures. Additionally, a web-based app has been developed to facilitate the description of the surgery using the LOEM system, which will be made publicly available to support further research and validation of the LOEM system (link: <https://loem.netlify.app/>). Although the LOEM system is limited in that it doesn't account for conservative modalities, such as balloon sinuplasty or sequelae (i.e., synechiae, mucocoeles or osteitis) in CRS treatment, it allows a wide range of surgical techniques described so far to be integrated under a unified and compact definition (Supplementary Table S2). Moreover, the pilot study's limitations include a small sample size, geographical restriction, potential interpretation differences and a need for large-scale validation with

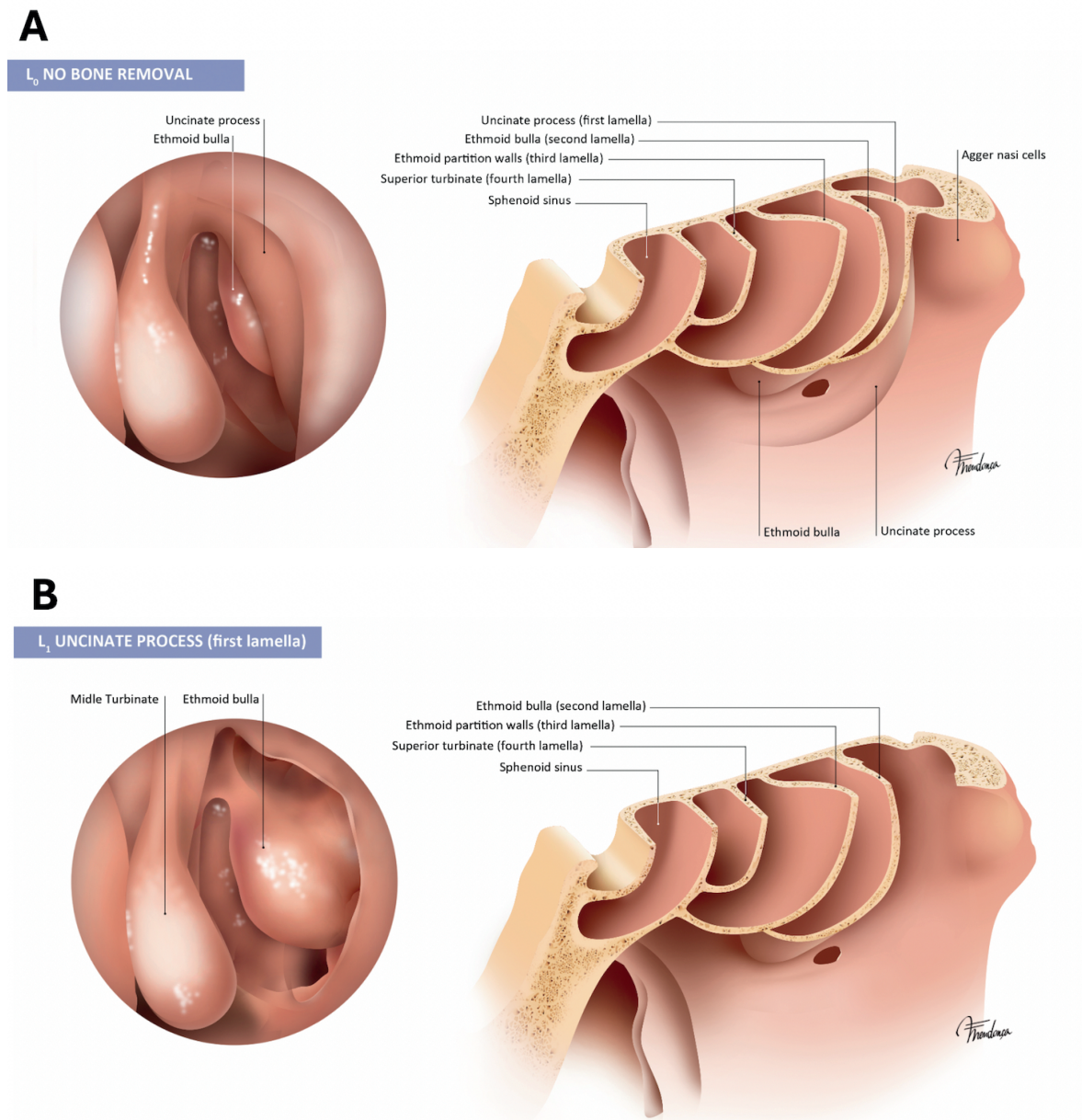


Figure 1. Longitudinal extent of surgery based on the number of removed lamellae. A. L₀: No intervention is performed on the anterior and posterior ethmoid structures. This may occur when no intentional intervention on bones is required (e.g., simple polypectomy). B. L₁: First lamella. This includes the removal of the uncinete process and the Agger nasi cell, along with other anterior ethmoidal cells that are superior to the Agger nasi, if present.

both experienced and novice rhinologists to improve the global applicability and robustness. Nonetheless, this new classification could be connected to diagnostic cases and surgical interventions allowing for a proof-of-concept in the field of Rhinology. Furthermore, the LOEM classification results provide a means of representing surgical knowledge in CRS in a compact and synthetic way, which benefits not only daily clinical practice but also research. This could facilitate communication among surgeons, pave the way towards the collection of more comprehensive datasets and improving artificial intelligence model

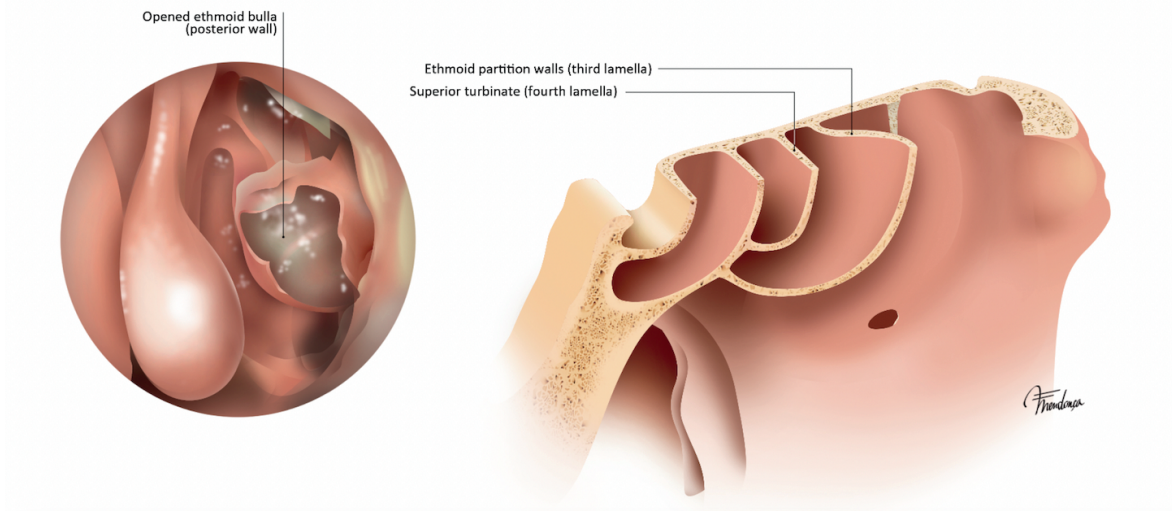
trainings. Further studies will be needed to better understand and validate the accuracy and usefulness of the LOEM system to describe CRS surgical approaches.

Acknowledgements

We would like to thank Leonardo Gil-Rodríguez (leonardogilrodriguez@gmail.com) for developing the interactive web-based app for the LOEM classification system made available in this work. We would also like to show our gratitude to the artist Fernando Mendoca (vilhena.mendonca@gmail.com) who made the

C

L₂ ETHMOIDAL BULLA (second lamella)



D

L₃ ETHMOID PARTITION WALLS (third lamella)

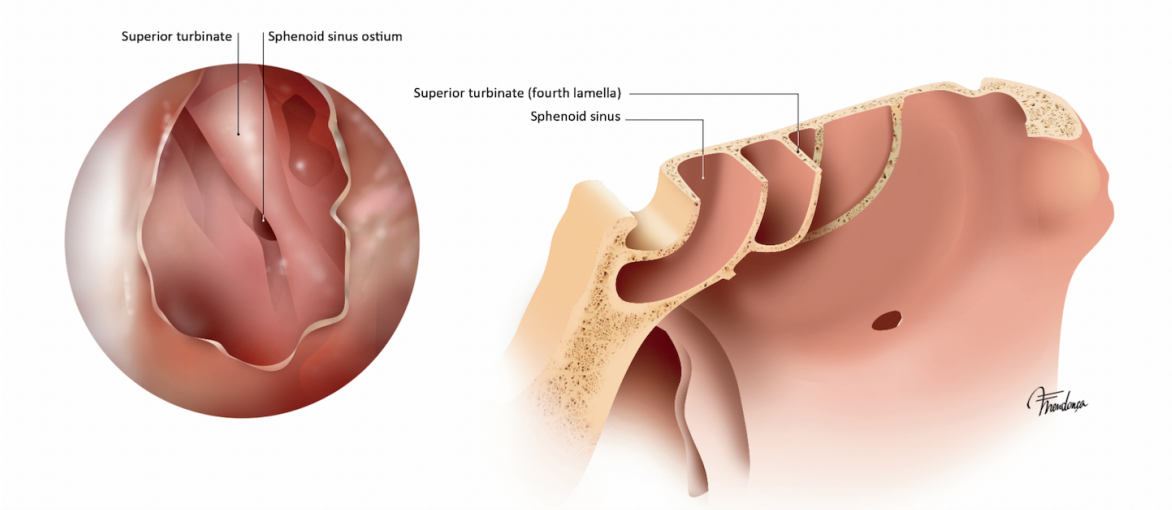


Figure 1. Longitudinal extent of surgery based on the number of removed lamellae. C. L₂: Second lamella. This includes the removal of the ethmoid bulla, in addition to any suprabullar and retrobullar cells and recesses present. D. L₃: Third lamella. This includes the opening of the vertical plate of the basal lamella of the middle turbinate and the removal of any bony septa of the posterior ethmoidal cells.

anatomical images provided in this manuscript. We would also recognize David G. Plant for his editorial assistance (dgplant11@gmail.com). Finally, we would also like to thank M. A. Callejón-Leblic (mcallejon@us.es) for her comprehensive review and help in the edition of this manuscript.

Authorship contribution

Conception: SSG, RML, JMS, AC, IA, MBS. Design: SSG, RML, DMJ, JMS. Supervision: SSG, IA, MBS. Resource: SSG, RML, DMJ, JMS, JGG. Materials: SSG, RML, JMVA, RFL. Data collection and/or

processing: SSG, RML, DMJ. Analysis and/or interpretation: SSG, DMJ. Literature search: SSG, RML, DMJ. Writing: SSG, RML, DMJ. Critical reviews: SSG, RML, DMJ, AC, IA, MBS.

Conflict of interest

The authors declare no conflict of interest.

Funding

No funding was received for this study.

Table 1. Categorization of ESS surgeries following LOEM classification.

Type of surgery	Surgical scope	Requirements	Surgical details			Mucosal removal
			Lamella removal	Bone removal Ostium enlargement	Extension approach	
Type 1	Functional limited	At least 1 lamella or 1 ostium + no resection or functional mucosal	L ₀ , L ₁ , L ₂ , L ₃	O ₀ , O _m , O _f , O _s	E ₀	M ₀ , M _f
Type 2	Functional extended	At least 2 lamellae + at least 2 ostia or 1 extended + functional mucosal	L ₀ , L ₁ , L ₂ , L ₃ , L _{xa}	O ₀ , O _m , O _f , O _s , O _{xa}	E ₀ , E _m , E _f , E _s , E _t , E _{xa}	M _f
Type 3	Radical extended	3 lamellae + 3 ostia + at least 2 extended + radical mucosal	L ₀ , L ₁ , L ₂ , L ₃ , L _{xa}	O ₀ , O _m , O _f , O _s , O _{xa}	E ₀ , E _m , E _f , E _s , E _t , E _{xa}	M _r
Type 4	Radical regenerative	3 lamellae + 3 ostia + at least 2 extended + regenerative mucosal	L ₀ , L ₁ , L ₂ , L ₃ , L _{xa}	O ₀ , O _m , O _f , O _s , O _{xa}	E ₀ , E _m , E _f , E _s , E _t , E _{xa}	M _m

Lamella: L₀: No bone removal; L₁: Uncinate process; L₂: Ethmoidal bulla; L₃: Ethmoid partition walls; L_{xa}: Lamella absent. Ostium: O₀: No ostium enlargement; O_m: Maxillary ostium enlargement; O_f: Frontal ostium enlargement (Draf I, Draf IIa); O_s: Sphenoidal ostium enlargement; O_{xa}: Ostium previously enlarged. Extension: E₀: No extended approach; E_m: Maxillary medial wall opening; E_f: Frontal sinus floor opening (Draf IIb, Draf III); E_s: Sphenoid anterior wall opening; E_t: Turbinate resection; E_{xa}: Sinus wall absent. Mucosa: M₀: No mucosal removal; M_f: Functional. Only diseased mucosa removal. Preservation of mucociliary function and sinus aeration; M_r: Reboot approach. Complete mucosal removal; M_m: Mucoplasty + reboot approach (regenerative surgery). In cases of revision surgeries (R-ESS), the absence of previously performed structures or procedures will be reported under the subscript 'a' (i.e., L_{xa}, O_{xa}, E_{xa}). Previous approaches on the lamella (L), ostium (O) and extension (E) will be considered part of the current surgical process, allowing grading types 2, 3 or 4 solely by the approach taken on the mucosa (M).

References

- Huang Y, Zhang N, Xu Z, Zhang L, Bachert C. The development of the mucosal concept in chronic rhinosinusitis and its clinical implications. *J Allergy Clin Immunol Pract*. 2022;10(3):707–715.
- Martin-Jimenez D, Moreno-Luna R, Cuvillo A, Gonzalez-Garcia J, Maza-Solano J, Sanchez-Gomez S. Endoscopic extended sinus surgery for patients with severe chronic rhinosinusitis with nasal polyps, the choice of mucoplasty: a systematic review. *Curr Allergy Asthma Rep*. 2023;23(12):733–746.
- Blauwblomme M, Gevaert P, Van Zele T. Chronic rhinosinusitis: matching the extent of surgery with pathology or does the extent of surgery matter? *Curr Otorhinolaryngol Rep*. 2023;11(3):273–285.
- Ramkumar SP, Marks L, Lal D, Marino MJ. Outcomes of limited versus extensive surgery for chronic rhinosinusitis: a systematic review and meta-analysis. *Int Forum Allergy Rhinol*. 2023;13(11):2096–2100.
- Kanai K, Okano M, Haruna T, et al. Evaluation of a new and simple classification for endoscopic sinus surgery. *Allergy Rhinol (Providence)*. 2017;8(3):118–125.
- Reitsma S, Adriaansen GFJPM, Cornet ME, Van Haastert RM, Raftopoulos MH, Fokkens WJ. The Amsterdam Classification of Completeness of Endoscopic Sinus Surgery (ACCESS): a new CT-based scoring system grading the extent of surgery. *Rhinology*. 2020; 58(6):538–543.
- Alsharif S, Jonstam K, van Zele T, Gevaert P, Holtappels G, Bachert C. Endoscopic Sinus Surgery for Type-2 CRS wNP: An Endotype-Based Retrospective Study. *Laryngoscope*. 2019;129(6):1286–1292.
- Moreno-Luna R, Gonzalez-Garcia J, Maza-Solano JM, et al. Free nasal floor mucosal grafting after endoscopic total ethmoidectomy for severe nasal polyposis: a pilot study. *Rhinology*. 2019;57(3):219–224.
- Moreno-Luna R, Martin-Jimenez DI, Callejon-Leblic MA, et al. Usefulness of bilateral mucoplasty plus reboot surgery in severe type-2 chronic rhinosinusitis with nasal polyps. *Rhinology*. 2022;60(5):368–376.

Ramon Moreno-Luna, MD, PhD
Rhinology Unit
Department of Otolaryngology
Virgen Macarena University Hospital
Dr Fedriani Av. 3
E-41071 Seville
Spain

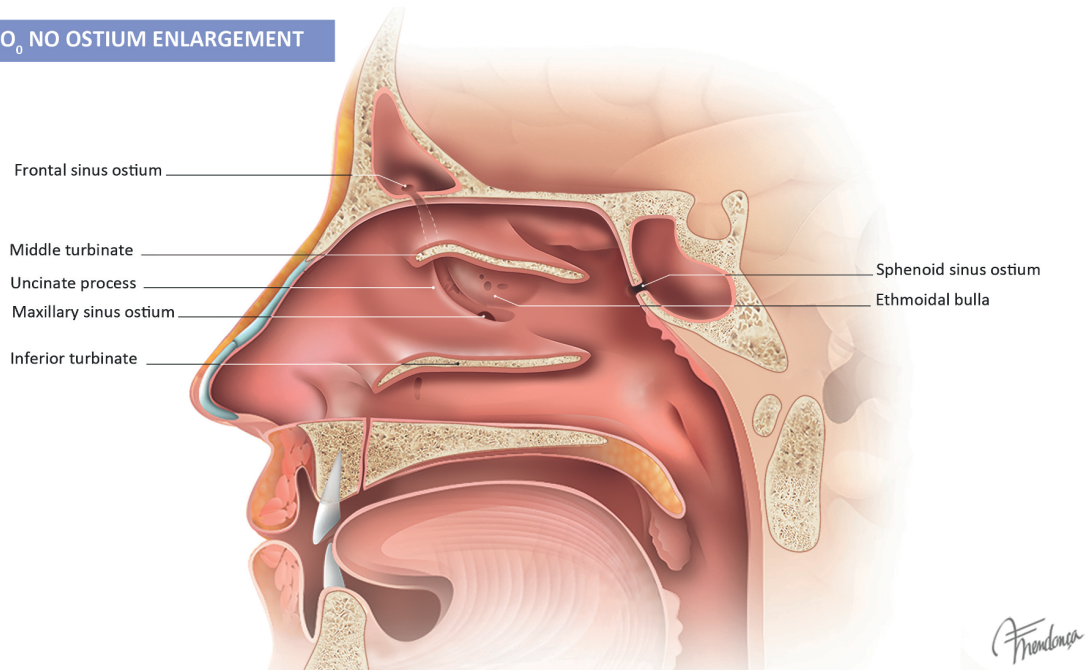
Tel: +34 661818838
E-mail: ramoluorl@gmail.com

This manuscript contains online supplementary material

SUPPLEMENTARY MATERIAL

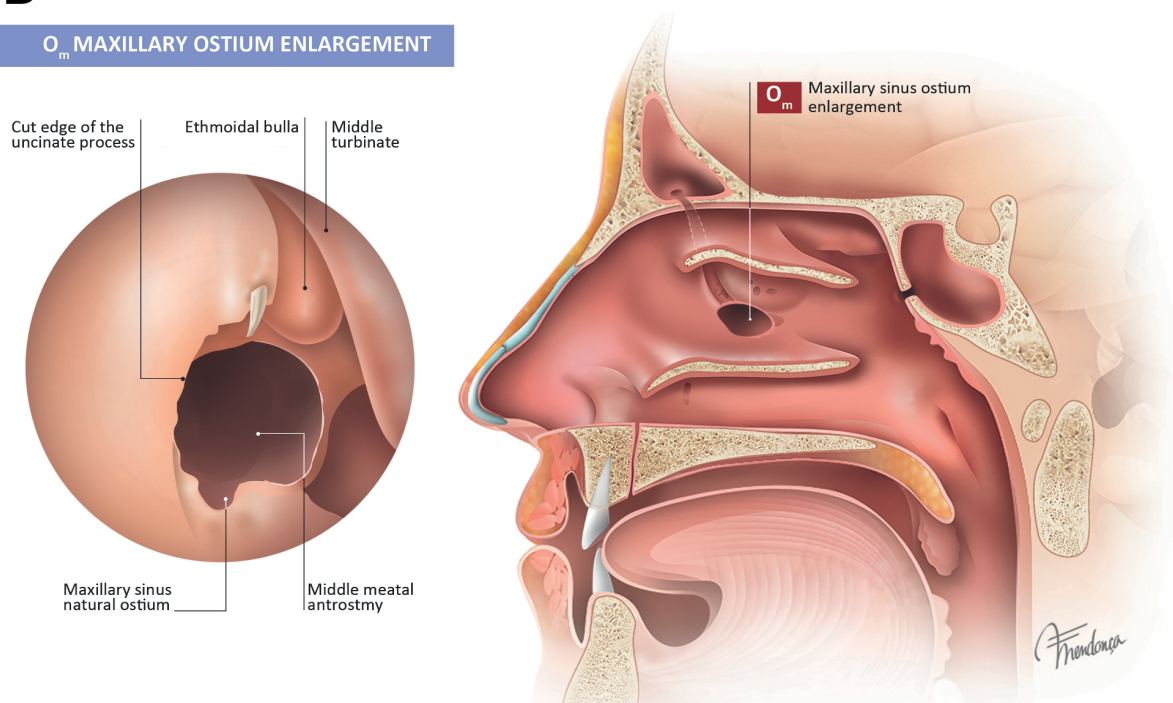
A

O₀ NO OSTIUM ENLARGEMENT



B

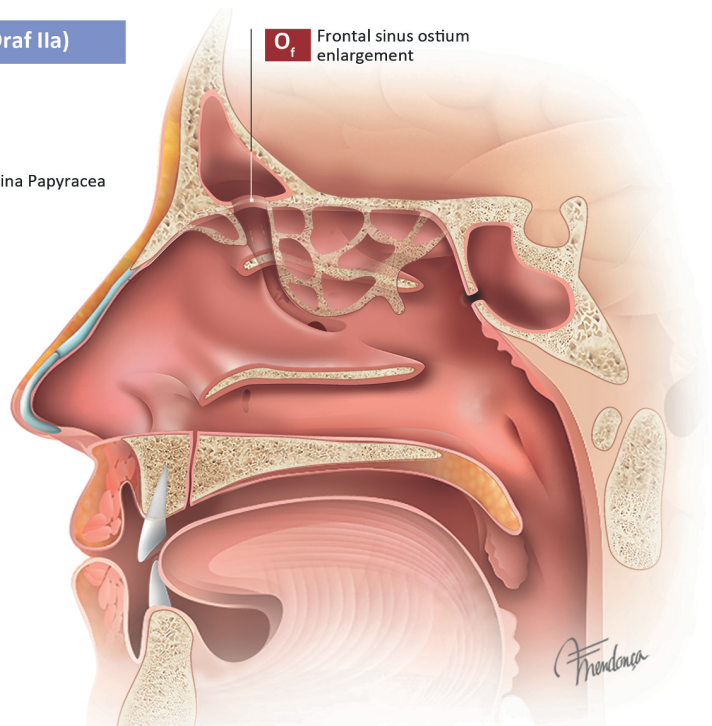
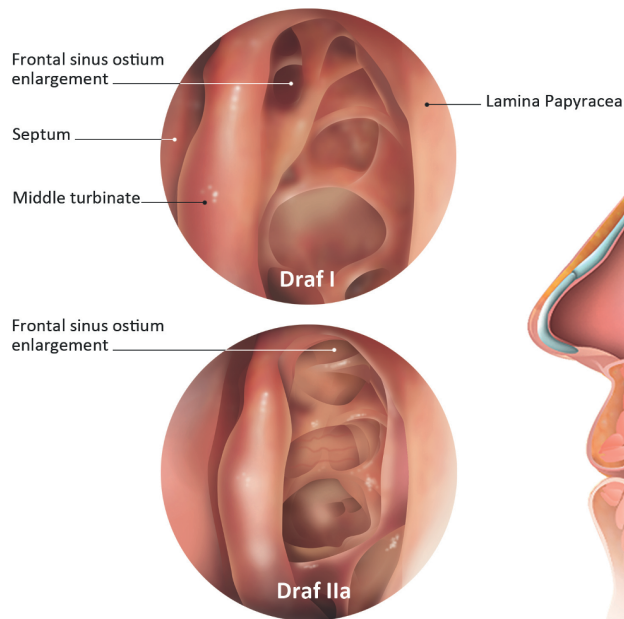
O_m MAXILLARY OSTIUM ENLARGEMENT



Supplementary Figure S1. The second bony criterion of the LOEM system introduces the enlargement of natural sinus ostia or opening. A. O₀: No intervention is performed on any of the sinus ostia. This category includes cases that have a permeable ostium, or cases in which the ostium/opening was intentionally left untouched. B. O_m: Enlargement of the maxillary sinus ostium.

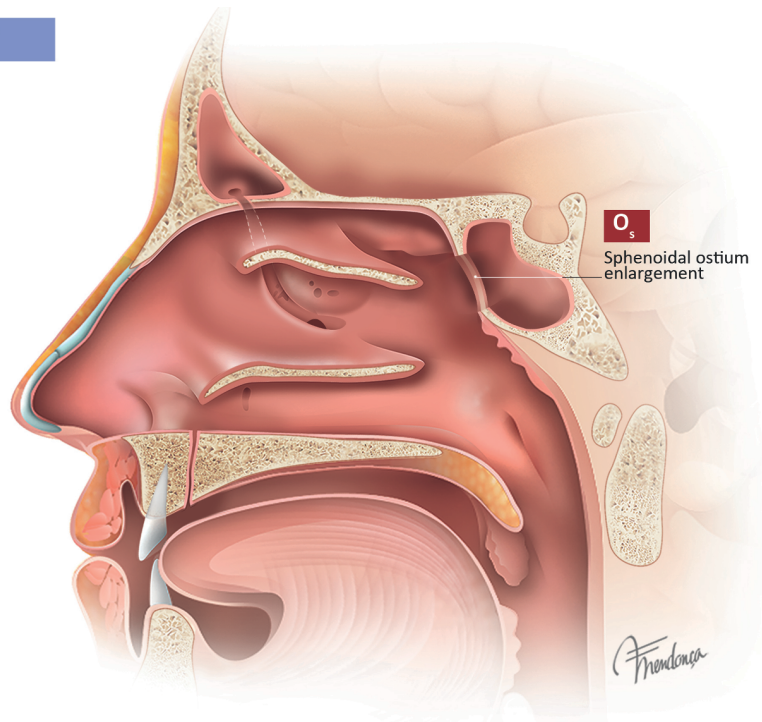
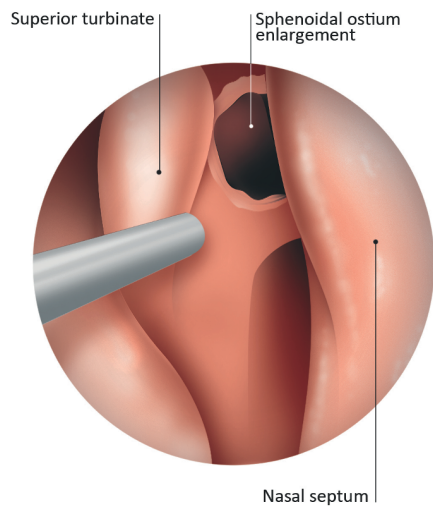
C

O_f FRONTAL OSTIUM ENLARGEMENT (Draf I, Draf IIa)



D

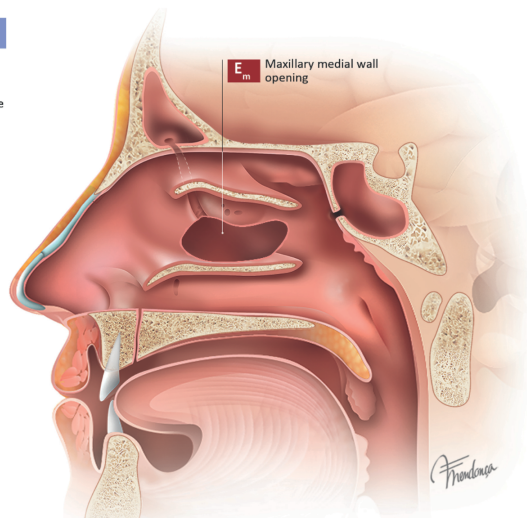
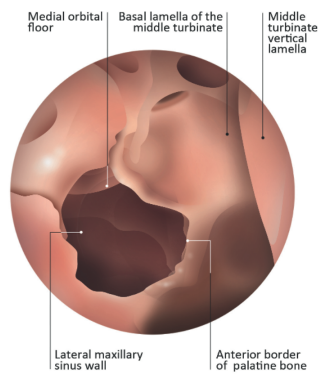
O_s SPHENOIDAL OSTIUM ENLARGEMENT



Supplementary Figure S1. The second bony criterion of the LOEM system introduces the enlargement of natural sinus ostia or opening. C. O_f: Draf I and IIa frontal sinus surgery types or grades 0-4 of EFSS classification. D. O_s: Enlargement techniques performed on the sphenoid sinus ostium, regardless of the specific surgical approach used.

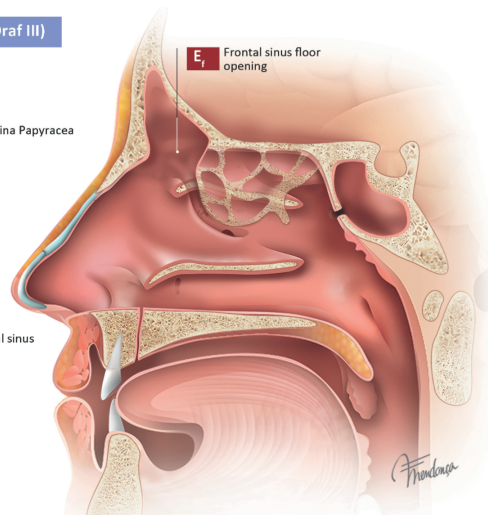
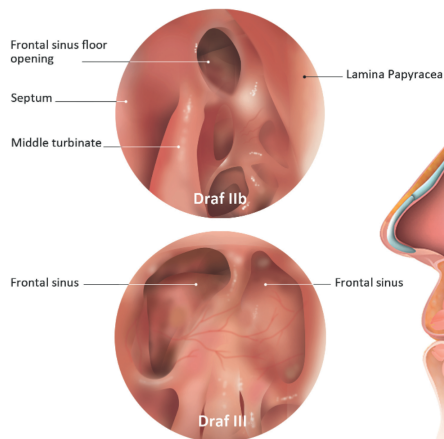
A

E_m MAXILLARY MEDIAL WALL OPENING



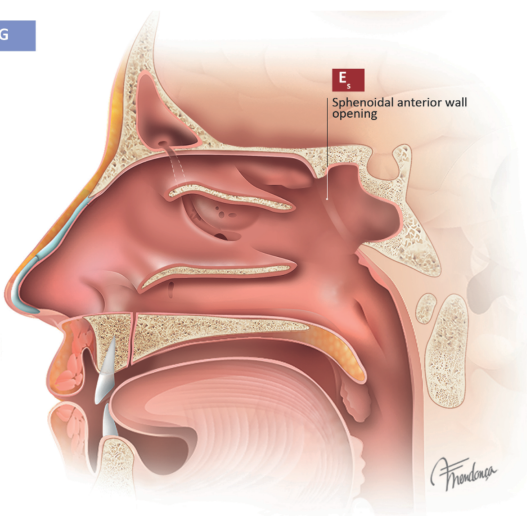
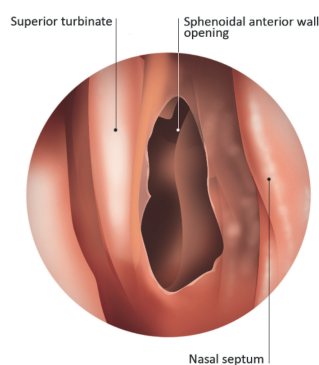
B

E_f FRONTAL SINUS FLOOR OPENING (Draf IIb, Draf III)



C

E_s SPHENOIDAL ANTERIOR WALL OPENING



Supplementary Figure S2. Enlargement of opening of walls beyond ostial/opening. A. E_m: Widening of the medial wall of the maxillary sinus beyond middle meatal antrostomy, including partial or total resection of the fontanelle. B. E_f: significant opening of the frontal sinus floor through Draf IIb or Draf III or grades 5-6 of EFSS classification. C. E_s: Enlargement of the anterior wall of the sphenoid sinus, including bone removal around the ostium.

Supplementary Table S1. Construction of the LOEM classification system

Bone removal	Lamella removal	L ₀	No bone removal	No intervention is performed on the anterior and posterior ethmoid structures. This may occur when no intentional intervention on bones is required (e.g., simple polypectomy).
		L ₁	Uncinate process	The first lamella involves the removal of the uncinate process and the agger nasi cell, along with other anterior ethmoidal cells that are superior to the agger nasi if present.
		L ₂	Ethmoidal bulla	The second lamella refers to the removal of the ethmoid bulla, as well as any suprabullar and retrobullar cells and recesses that may be present.
		L ₃	Ethmoid partition walls	The third lamella includes the opening of the vertical plate of the basal lamella of the middle turbinate (MT) and the removal of any bony septa of the posterior ethmoidal cells.
		L _{xa}	Lamella absent	The subscript 'a' is added to denote the absence of a lamella removed during previous surgeries: L _{xa} , where 'x' can take the values '1', '2', and '3', representing the missing lamella. For example, the notation L _{1a,2a,3'} indicates a patient who has undergone prior ESS in which the first and second lamellae were removed, and for whom the third lamella will be removed in the current surgery.
	Ostium enlargement	O ₀	No ostium enlargement	No intervention is performed on any of the sinus ostia. This category includes cases that have a permeable ostium, or cases in which the ostium/opening was intentionally left untouched.
		O _m	Maxillary ostium enlargement	Enlargement of the maxillary sinus ostium.
		O _f	Frontal ostium enlargement (Draf I, Draf IIa)	Draf I and IIa frontal sinus surgery or Grades 0 to 4 of the Classification of the Extent of Endoscopic Frontal Sinus Surgery (EFSS) ^(1,2) .
		O _s	Sphenoidal ostium enlargement	Enlargement techniques performed on the sphenoid sinus ostium, regardless of the specific surgical approach used (modified sinusotomy, not extending upward to the skull base).
		O _{xa}	Ostium previously enlarged	The subscript 'a' is added to indicate a previously enlarged ostium / opening. The 'x' in the subscript should be replaced by the enlarged ostium.
	Extension approach	E ₀	No extended approach	No extended intervention is performed on the walls of any sinus.
		E _m	Maxillary medial wall opening	Widening of the medial wall of the maxillary sinus beyond middle meatal antrostomy, including partial or total resection of the fontanelle (transnasal endoscopic partial maxillectomy type 1 ⁽⁴⁾).
		E _f	Frontal sinus floor opening (Draf IIb, Draf III)	Significant opening of the frontal sinus floor through Draf IIb or Draf III or grades 5 – 6 of EFSS classification ^(1,2) .
		E _s	Sphenoid anterior wall opening	Enlargement of the anterior wall of the sphenoid sinus, including bone removal around the ostium (type II and III sinusotomies ⁽³⁾).
		E _t	Turbinate resection	Partial removal, trimming or ablation of the MT.
		E _{xa}	Sinus wall absent	The subscript 'a' is added to indicate a previously removed sinus wall. The 'x' in the subscript should be replaced by the enlarged sinus wall.
Mucosal removal		M ₀	No mucosal removal	Cases with no mucosal removal, except for the enlargement of the sinus ostia/openings.
		M _f	Functional. Only diseased mucosa removal. Preservation of mucociliary function and sinus aeration	The main objective is to preserve mucociliary function and ventilation of the paranasal sinuses, regardless of the performance on the bone. It also aims to facilitate the installation of topical treatments. This category encompasses the original criterion of functional ESS aimed at removing only macroscopically irreversibly diseased mucosa.
		M _r	Reboot approach. Complete mucosal removal	The objective is to replace all sinus mucosa with healthy local mucosa, regardless of the intervention on the bone. This procedure is considered a reboot approach following a complete mucosal removal.
		M _m	Mucoplasty + reboot approach (regenerative surgery)	The objective is to create neomucosa from freely grafted healthy mucosa covering a significant part of the excised mucosal area in addition to radical ESS. This type of surgery is classified as mucoplasty regenerative surgery.

Supplementary Table S2. Main types of ESS approaches published to date thorough description of their characteristics and the codification using LOEM system.

	Functional Endoscopic Endonasal Surgery (FEES). Messerklinger, 1978; Kennedy, 1985; Stammberger, 1990 ^(5,6)	Nasalization (radical ethmoidectomy). Jankowski et al., 1997, 2006 ^(7,8)	Full-house Functional Endoscopic Sinus Surgery (FHFESS). Shen et al., 2011 ⁽⁹⁾	Reboot surgery. Alsharif et al., 2019 ⁽¹⁰⁾	Regenerative surgery (reboot surgery plus mucoplasty). Moreno-Luna et al., 2019 ⁽¹¹⁾
Rationale	Conservative approach targeting osteomeatal complex disease (OMC)	Complete removal of the vestigial non-olfactory ethmoid mucosa based on the evo-devo theory	To treat affected sinuses (CT images), regardless of symptoms, complete removal of ethmoidal lamellae prevents obstruction and supports postoperative diagnostics and treatment	To remove all sinus mucosa, microbiota, and immune dysfunction, and promote healthy re-epithelialization from preserved nasal mucosa, starting with the inferior and MTs and septum	To encourage healthy epithelial regrowth and reduce polyp risk after mucosa removal, tissue from a non-polypoid donor site is used to aid re-epithelialization
Objective	To clear diseased ethmoid clefts, restore sinus ventilation and drainage, while minimizing tissue damage	Marsupialization of the ethmoid, maxillary, sphenoid, and frontal sinuses into the nasal cavities	FHFESS is a term used to describe uncinectomy, maxillary antrostomy, total ethmoidectomy, wide sphenoidotomy, and a Draf IIa frontal sinusotomy	To completely remove all mucosa from all sinuses (ethmoid, maxillary, sphenoid, frontal), while leaving the periosteum where possible	To promote the regeneration of tissue and facilitate re-growth of epithelial cells, regenerative surgery can be performed using a graft
Mucosa	Disease is targeted for removal in key areas of the anterior ethmoid and middle meatus. Preservation of as much mucosa as possible	Complete removal of the ethmoid mucosa, preserving mucosa in the large sinuses and around the frontal ostia. Mucosal release ensures precise navigation	Targeted removal of disease from key areas of the ethmoid and middle meatus	Complete removal	Complete removal using a mucosa release technique
Uncinectomy	Performed systematically	Performed systematically	Performed systematically	Performed systematically	Performed systematically
Ethmoidal bulla	Once the cell walls are fractured, they are removed	Once the cell walls are fractured, they are removed	Once the cell walls are fractured, they are removed	Once the cell walls are fractured, they are removed	Circumferential dissection and complete removal
Middle turbinate (MT)	Preservation is preferred	Systematically removed. Spared whenever possible but to preserve exclusively the mucosa covering its medial side within the olfactory cleft, after updating nasalization	Consider the possibility of medializing the MT or securing it to the septum through the induction of synechiae	Preserved as much as possible as a landmark, except for the areas that are damaged by the disease or the anterior portions that require removal during the Draf III procedure	Preservation preferred
Vertical plate of the basal lamella of the MT	The basal lamella is perforated to enter the posterior ethmoid cells whenever needed	The basal lamella is opened to enter the posterior ethmoid cells and the opening is enlarged	The basal lamella is perforated to enter the posterior ethmoid cells and the opening is enlarged	The basal lamella is perforated to enter the posterior ethmoid cells and the opening is enlarged	The basal lamella is perforated to enter the posterior ethmoid cells and the opening is enlarged
Ethmoid bony lamellae	On demand	Removed systematically	Removed systematically	Removed systematically	Removed systematically
Middle meatal antrostomy	On demand	Large opening of the maxillary ostia, leaving mucosa intact.	As large as possible	Wide antrostomy	Limited enlargement
Maxillary sinus mucosa	Localized irreversible disease is removed to the periosteum. Frequently, apparently irreversible mucosal disease resolves	Conservation of maxillary sinus membrane and ostium whenever possible in nasalization updated.	On demand	Complete clearance	Complete clearance

	Functional Endoscopic Endonasal Surgery (FEES). Messerklinger, 1978; Kennedy, 1985; Stammberger, 1990 ^(5,6)	Nasalization (radical ethmoidectomy). Jankowski et al., 1997, 2006 ^(7,8)	Full-house Functional Endoscopic Sinus Surgery (FHFESS). Shen et al., 2011 ⁽⁹⁾	Reboot surgery. Alsharif et al., 2019 ⁽¹⁰⁾	Regenerative surgery (reboot surgery plus mucoplasty). Moreno-Luna et al., 2019 ⁽¹¹⁾
Ethmoid sinus mucosa	On demand	Completely removed systematically	Removed systematically to the periosteum.	Complete clearance, including the lamina orbitalis, skull base, and the lateral aspects of the MT	Complete clearance, including the lamina orbitalis, skull base, and the lateral aspects of the MT
Sphenoidotomy	On demand	Spared when possible	Wide	Wide	Wide
Sphenoid sinus mucosa	Preserved	Ostial conservation depending on the contents found	Preserved unless grossly abnormal	Should try to remove the diseased mucosa from the floor and medial parts of the sphenoid	Should try to remove the diseased mucosa from the floor and medial parts of the sphenoid
Frontal sinus opening	Clearing the frontal recess typically heals the sinus without requiring additional ostium enlargement	The circumferential mucosa of the ostium is to be conserved	Draf IIa, Draf III when indicated	Bilateral Draf IIa or III procedure with wide exposure of the posterior wall of the frontal sinus	Draf III
Frontal sinus mucosa	Preserved	Preserved	Frontal pathway clearance	Complete removal to the periosteum	Removed as possible
Adjunct procedures			Canine fossa trephination and frontal minitrephination whenever necessary		Mucoplasty from nasal floor
LOEM description	Conventional: $L_{1,2}O_mM_f$ Extended: $L_{1,2,3}O_{m,f,s}M_f$	$L_{1,2,3}O_0E_0M_r$	$L_{1,2,3}O_{m,f,s}E_{m,f,s}M_f$	$L_{1,2,3}O_{m,f,s}E_{m,f,s}M_r$	$L_{1,2,3}O_{m,f,s}E_{m,f,s}M_m$

References

- Draf W. Endonasal micro-endoscopic frontal sinus surgery: the Fulda concept. *Oper Tech Otolaryngol-Head Neck Surg.* 1991;2(4):234–240.
- Wormald PJ, Hoseman W, Callejas C, Weber RK, Kennedy DW, Citardi MJ, et al. The International Frontal Sinus Anatomy Classification (IFAC) and Classification of the Extent of Endoscopic Frontal Sinus Surgery (EFSS). *Int Forum Allergy Rhinol.* 2016;6(7):677–696.
- Balakrishnan K, Briner HR, Jones N, et al. Sphenoidectomy ± Sphenoidal Sinusotomy (I, II, III). *Manual of endoscopic sinus and skull base surgery.* 2nd ed. Stuttgart: Thieme Verlag; 2014.
- Turri-Zanoni M, Battaglia P, Karligiotis A, et al. Transnasal endoscopic partial maxillectomy: Operative nuances and proposal for a comprehensive classification system based on 1378 cases. *Head Neck.* 2017;39(4):754–766.
- Kennedy DW. Functional endoscopic sinus surgery: technique. *Arch Otolaryngol.* 1985;111(10):643–649.
- Stammberger H, Posawetz W. Functional endoscopic sinus surgery. Concept, indications and results of the Messerklinger technique. *Eur Arch Otorhinolaryngol.* 1990;247(2):63–76.
- Jankowski R, Pigret D, Decroocq F. Comparison of functional results after ethmoidectomy and nasalization for diffuse and severe nasal polyposis. *Acta Otolaryngol.* 1997;117(4):601–608.
- Jankowski R, Pigret D, Decroocq F, Blum A, Gillet P. Comparison of radical (nasalisation) and functional ethmoidectomy in patients with severe sinonasal polyposis. A retrospective study. *Rev Laryngol Otol Rhinol (Bord).* 2006;127(3):131–140.
- Shen PH, Weitzel EK, Lai JT, Wormald PJ, Lin CH. Retrospective study of full-house functional endoscopic sinus surgery for revision endoscopic sinus surgery. *Int Forum Allergy Rhinol.* 2011;1(6):498–503.
- Alsharif S, Jonstam K, van Zele T, Gevaert P, Holtappels G, Bachert C. Endxry for Type-2 CRSwNP: an endotype-based retrospective study. *Laryngoscope.* 2019;129(6):1286–92.
- Moreno-Luna R, Gonzalez-Garcia J, Maza-Solano JM, et al. Free nasal floor mucosal grafting after endoscopic total ethmoidectomy for severe nasal polyposis: a pilot study. *Rhinology.* 2019;57(3):219–224.