

Usefulness of bilateral mucoplasty plus reboot surgery in severe type-2 chronic rhinosinusitis with nasal polyps*

Ramón Moreno-Luna^{1,†}, Daniel I. Martín-Jiménez^{1,†}, M. Amparo Callejón-Leblic¹, Jaime González-García¹, Juan M. Maza-Solano¹, Cristina Porras-González², Alfonso Del Cuvillo-Bernal³, Serafín Sánchez-Gómez¹ *Rhinology* 60: 0,000 - 000, 2022
https://doi.org/10.4193/Rhin22.131

¹ Rhinology Unit, Department of Otolaryngology, Hospital Universitario Virgen de la Macarena, Seville, Spain

² Molecular Biology and Biomedicine department. Hospital Universitario Virgen de la Macarena, Seville, Spain

³ Rhinology and Asthma Unit, ENT Department, Hospital de Jerez, Jerez de la Frontera, Cádiz, Spain

*Received for publication:

March 20, 2022

Accepted: June 5, 2022

†These authors contributed equally

Background: Although extended endoscopic sinus surgery (ESS) constitutes an alternative approach in patients with Chronic Rhinosinusitis with Nasal Polyps (CRSwNP), the surgical techniques proposed so far do not allow for an optimal control of the disease. This study introduces bilateral mucoplasty as a complementary technique to extended ESS such as reboot surgery, analyzing its benefits in healing and quality of life (QoL).

Methods: Patients diagnosed with severe Type-2 CRSwNP were selected for a prospective cohort study in two surgery groups: reboot surgery plus bilateral mucoplasty versus reboot surgery only. In the first group, an autologous endonasal mucosal graft from the nostril floor was placed bilaterally onto the ethmoidal roof. Endoscopic, radiological and QoL outcomes were compared before and one year after surgery between the two groups using Modified Lund Kennedy (LKM), Meltzer and Lund Mackay (LM) scores, and the Sino-Nasal Outcome Test 22 (SNOT-22).

Results: 64 patients with homogeneous baseline characteristics were included: 17 patients underwent a reboot surgery plus a bilateral mucoplasty and 47 a reboot surgery only. LKM, Meltzer and SNOT-22 scores showed significant differences before and after surgery in both groups, with higher improvement in the mucoplasty group. A greater mean improvement of 20.5 ± 6.4 points in SNOT-22 change was associated with bilateral mucoplasty.

Conclusion: Bilateral mucoplasty plus reboot surgery constitutes a useful surgical resource in Type-2 CRSwNP patients, showing improved endoscopic, radiological and QoL outcomes one year after surgery. Further studies are needed to determine their long-term benefits.

Key words: nasal polyps, chronic rhinosinusitis, nasal surgical procedures, type 2 inflammation, ethmoid sinus

Introduction

Chronic rhinosinusitis with nasal polyps (CRSwNP) is an inflammatory condition whose most prevalent symptoms include nasal obstruction, nasal and postnasal discharge, abnormal sense of smell, and facial pain ⁽¹⁾. With as much as 4% of the population estimated to being affected, CRSwNP significantly impacts on quality of life and overall health ⁽²⁾. In those patients who fail to be clinically controlled with adequate medical therapy, endoscopic sinus surgery (ESS) has been shown to provide a beneficial alternative treatment ^(3,4).

Many authors have emphasised the importance of the inflammatory endotype when proposing a particular surgical extension in patients with CRSwNP ⁽⁵⁻⁹⁾. Type 2 is the most relevant inflammatory endotype and is characterised by eosinophilic inflammation with high levels of immunoglobulin E (IgE), eosinophilic cationic protein (ECP) and interleukins 4, 5 and 13 ^(1,8). This endotype is often related to co-morbidities such as asthma and NSAID-exacerbated respiratory disease (N-ERD) as well as to clinical and analytical markers of CRSwNP severity and relapse. In such circumstances, extensive ESS approaches are associated

with more favourable surgical and improved quality of life (QoL) outcomes, in addition to lower relapse rates⁽⁵⁻⁷⁾.

Recently, our group has described endonasal mucoplasty as a complementary surgical technique, which associated with an extended ESS such as a reboot surgery⁽⁵⁾, provides additional benefits in local healing and QoL in patients with CRSwNP^(10,11). The objective of this study is to assess the usefulness of using bilateral mucoplasties in patients with severe CRSwNP and a type 2 inflammatory endotype.

Materials and methods

Design and participants

From January 2018 to January 2021, patients with CRSwNP were selected for a prospective cohort study in the rhinology unit of a tertiary-care level hospital in Seville (Spain). Two cohort groups were studied: i) patients having undergone a reboot surgery plus a bilateral mucoplasty and ii) patients who only underwent a reboot surgery. Data was collected prospectively in the first group, whereas in the second group, data was taken from the patients' medical records. The inclusion criteria in both groups were male and female patients older than 18 with a polyp size greater than or equal to 4 (at least 2 in each nostril) on the Meltzer scale⁽¹²⁾, with severe self-reported symptoms (≥ 50) in the Sinonasal Outcomes Test-22 (SNOT-22)⁽¹³⁾, who fulfilled at least one criterion of type 2 inflammation as reported by the EPOS 2020⁽¹⁾. Excluded from the study were: women who were either pregnant or breast-feeding; patients with eosinophilic granulomatosis with polyangiitis (EGPA) or severe systemic diseases (excluding bronchial asthma or non-steroidal anti-inflammatory drugs (N-ERD)), neoplasms, or pathologies related to the abuse of vasoconstrictor agents (e.g. oxymetazoline); and CRS patients with unilateral nasal inflammatory disease, bilateral inflammatory disease but without nasal polyps, or those in treatment with monoclonal antibodies during the last twelve months. All patients met the required criteria to undergo surgery for CRSwNP as described by Rudmik et al.⁽³⁾.

The study was approved by the Ethics Committee of the Virgen Macarena University Hospital (COD_0058-N-18) (Seville, Spain). All patients were informed of the surgical procedures and signed a written informed consent.

Surgical technique

All patients underwent a reboot surgery⁽⁵⁾, consisting of a complete resection of the anterior and posterior ethmoidal cells as well as a sphenoidotomy, including an endoscopic control of the frontal sinuses, with a minimum of a type IIA approach. Subsequently, the residual septa were completely removed, leading to a wide exposure of the anterior skull base, the posterior frontal sinus table, and the lamina papyracea. This resulted in a total demucosalization of paranasal sinuses. In the bilateral mucoplasty cohort group, a bilateral autologous endonasal

graft, as described by Moreno-Luna et al., was carried out in its extended version⁽¹⁴⁾. This regenerative technique is performed bilaterally and consists of placing an autologous graft of mucosa from the nostril floor onto the ethmoidal roof, using the anterior ethmoidal artery as an anterior limit, extending it back towards the sphenoidal planum and laterally over the lamina papyracea. Although both the middle and superior turbinates were partially resected, the olfactory nasal mucosa was preserved in all patients.

Data and outcome measures

The data collected included a medical history of asthma, N-ERD, and allergy sensitization. Pre-surgery blood tests including total immunoglobulin E levels and eosinophils in peripheral blood were also collected. Endoscopic variables were evaluated by two consultants from the same rhinology unit using the modified Lund Kennedy (LKM) scoring system from 0 to 2, where higher scores represent worse bilateral disease severity (polyps, oedema, and discharge) and the Meltzer scoring scale (grade 0: no polyps; grade 1: small polyps in the middle meatus/oedema; grade 2: blocked middle meatus; grade 3: polyps that extend beyond the middle meatus, without complete obstruction; grade 4: massive nasal polyposis)^(12,15). Baseline polyps scores were recorded during the pre-operative visit and later confirmed in theatre before intervention. To avoid misclassification bias, post-operative scores were also collected and confirmed by the two same consultants. Radiological impairment (unenhanced CT scan of paranasal sinuses) was measured by the Lund Mackay (LM) scoring scale, ranging from 0 (complete lucency of all sinuses) to 2 (complete opacity of all sinuses)⁽¹⁶⁾. Finally, QoL was assessed using the SNOT-22 questionnaire with outcome scores reporting the severity of symptoms in the range of 0 – 110⁽¹⁷⁾. The study compared the pre-surgery endoscopic, radiological and QoL outcome scores with those taken one year after surgery between the two groups. Item 21 of SNOT-22 (decreased sense of smell) was also considered in order to analyse olfaction outcomes.

Statistical analysis

Descriptive statistics for patient demographics and baseline characteristics were analysed for the two surgery cohort groups. The normality of variables was assessed using the Kolmogorov-Smirnov and Shapiro-Wilk tests. Differences in outcome measures between groups were analysed by unpaired T-student and Mann-Whitney U tests, depending on distribution. Differences among the preoperative and postoperative variables were analysed using paired T-student or Wilcoxon signed-rank tests. Pearson's chi-square (χ^2) test was used to analyse differences in the prevalence of categorical variables between groups. Bivariate and multivariate linear stepwise regression models (backward and forward) were calculated following the Bayesian

Table 1. Distribution of demographic, medical, endoscopic, radiological, and blood tests in both groups before intervention. Numerical variables are displayed as mean \pm SD when normally distributed, otherwise median (IQR). Qualitative variables are expressed in percentages.

	Reboot surgery + Bilateral mucoplasty (n = 17)	Reboot surgery (n = 47)	p-value
Gender			0.105*
Women	10 (58.8%)	17 (36.2%)	
Men	7 (41.2%)	30 (63.8%)	
x age \pm SE	50.5 \pm 11.4	49.3 \pm 14.5	0.745 [†]
Asthmatics	14 (82.4%)	29 (61.7%)	0.120*
Previous ESS	11 (64.7%)	21 (44.7%)	0.157*
NERD	8 (47.1%)	11 (23.4%)	0.067*
Smoking			0.112*
No	9 (52.9%)	36 (76.6%)	
Ex – smoker	6 (35.3%)	6 (12.8%)	
Smoker	2 (11.8%)	5 (10.6%)	
Meltzer scale ($\mu_x \pm$ SE)	5.9 \pm 1.5	5.8 \pm 1.3	0.801 [†]
LKM scale (add of both nostrils) (Me [IQR])	10 (8 – 10)	9 (8 – 10)	0.704 [‡]
Lund – Mackay scale (Me [IQR])	21 (16 – 23)	19 (14 – 22)	0.123 [‡]
Eosinophils in peripheral blood > 300/mcL	10 (58.8%)	32 (69.6%)	0.420
Total IgE			0.982*
> 150 UI/mL	8 (47.1%)	21 (44.7%)	
< 150 UI/mL	5 (29.4%)	14 (29.8%)	
Not determined	4 (23.5%)	12 (25.5%)	
Proven allergic sensitisation			0.881*
Yes	8 (47.1%)	22 (46.8%)	
No	6 (35.3%)	15 (31.9%)	
Not provided	3 (17.6%)	10 (21.3%)	
≥ 1 cycles of corticosteroids in the pre – surgery year	7 (41.2%)	30 (63.8%)	0.105*
Baseline SNOT – 22 ($\mu_x \pm$ SE)	86.7 \pm 15.7	74.6 \pm 15.4	0.008 [†]

* p-value as determined by chi-square test. [†] p-value as determined by the T-student test for independent data; μ_x = arithmetic average, SE = Standard deviation. [‡] p-value as determined by the U de Mann-Whitney test; Me = median, IQR = interquartile range.

information criterion (BIC) to assess potential confounding effect estimates (e.g., sex, age, asthma, N-ERD, previous ESS, baseline SNOT-22 score, etc.). The main exposure variable of interest was the surgical group (bilateral mucoplasty plus reboot surgery versus reboot surgery only), whereas the main outcome of interest was SNOT-22 relative change (SNOT-22 [pre-operative] – SNOT-22 [post-operative]). Final model results were reported using unadjusted and adjusted effect estimates (β), standard error (SE), 95% confidence intervals, and corresponding p-values. Coefficient of multiple determination values (R^2) was used to assess model fitting. Variance inflation factors (VIFs) were used to quantify multicollinearity in model covariates. A p-value = 0.05 was considered significant in our analysis. Data analysis was performed using the IBM SPSS 28 statistical package and the Statistics and Machine Learning Toolbox in Matlab (v. R2021a, The MathWorks Inc, Natick, MA, USA).

Results

A total of 64 patients were included in the study, 26.6% (n = 17) of whom underwent a reboot surgery plus a bilateral endonasal mucoplasty. The second surgery group included 47 patients who only underwent a reboot surgery and fulfilled the proposed criteria. No significant differences were found when comparing both pre-intervention groups, except for baseline SNOT-22 scores with a mean difference of 12.1 points between groups (Table 1).

Both endoscopic and radiological outcome measures showed significant differences before and after surgery in the two groups (Table 2) for a follow-up period of 12 months. Specifically, a significant improvement was seen in Meltzer scores, with more favourable results in the mucoplasty group (p = 0.028) (Table 3). Similar outcomes were observed for modified Lund Kennedy scores (p < 0.001) (Table 3). Although the improvement in Lund-Mackay scores was also greater in the mucoplasty group, the difference was not significant (p = 0.375) (Table 3).

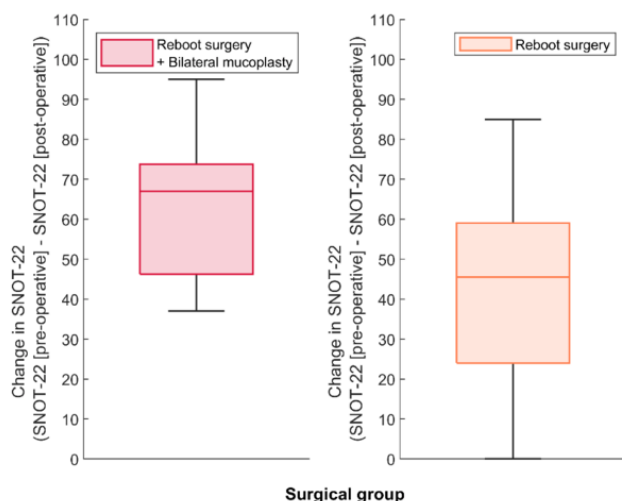


Figure 1. Boxplot distribution of SNOT-22 score changes between the two surgical groups. Significant differences in SNOT-22 changes between groups were detected using unpaired T-student test ($p = 0.003$).

Postoperative care was the same for both groups: the removal of the non-absorbable nasal packing 48 hours after surgery, gentle nasal lavage with seawater or physiological saline three times a day, and the continued use of silicone sheets to protect the septum mucosa and avoid synechia for at least three weeks after surgery. Nasal corticosteroids were prescribed with no patient

requiring oral corticosteroids. The rate of re-surgery within the mucoplasty group was 0% (Table 3). During the follow-up period, it was not necessary to perform a Draf III in any of the patients, nor was an empty nose syndrome observed. In the case of QoL, a significant decrease in SNOT-22 was observed in both surgical groups: from 86.7 ± 15.7 to 24 ± 16.5 ($p < 0.001$) in the reboot surgery plus bilateral mucoplasty group and from 74.6 ± 15.4 to 31.4 ± 26.8 ($p < 0.001$) in the reboot surgery group. Moreover, significant differences between groups in relative SNOT-22 change were also observed, with a greater improvement in the group of patients operated by reboot surgery plus bilateral mucoplasty ($p = 0.003$) (Figure 1). The analysis of olfaction in item 21 showed a significant improvement in each of the two surgical groups: a mean change score of 1.9 ± 1.7 in the reboot surgery plus bilateral mucoplasty group ($p < 0.001$), and of 2.3 ± 2.0 in patients undergoing reboot surgery only ($p < 0.001$); although significant differences between groups were not detected ($p = 0.235$).

The bivariate linear regression model found that subjects undergoing a reboot surgery plus a bilateral mucoplasty experienced on average a 20.5 ± 6.4 greater improvement in the SNOT-22 (Table 4) compared with subjects who only underwent a reboot surgery ($p = 0.002$). A multivariate linear model was derived by performing stepwise backward-forward regression with asthma, NERD, previous ESS as well as sex and age being considered as independent predictors. The model with the lowest BIC, see Table 4 and the equation below, was selected as the best model. In

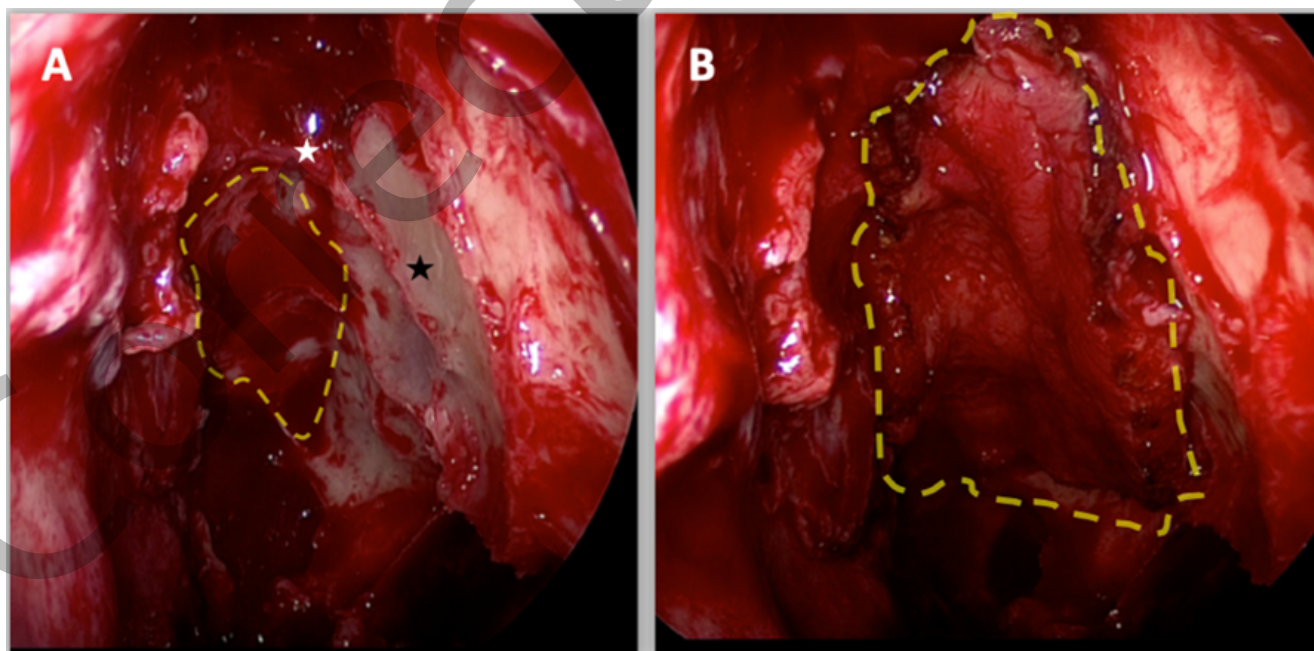


Figure 2. Intraoperative appearance of a mucoplasty. A: intraoperative appearance of a reboot surgery in a left nostril (white star: left anterior ethmoidal artery; dashed line: ethmoidal roof; black star: lamina papyracea). B: intraoperative shape of an endonasal autologous graft (mucoplasty) (dashed line).

Table 2. Comparison of pre-operative and post-operative endoscopic and radiological outcomes in each group.

	Reboot surgery + Bilateral mucoplasty (n = 17)			Reboot surgery (n = 47)		
	Pre-surgery	Post-surgery	p-value	Pre-surgery	Post-surgery	p-value
Meltzer scale ($\mu_x \pm SE$) (Me [IQR])	5.9 \pm 1.5	0 (0 – 0)	<0.001*	5.8 \pm 1.3	0 (0 – 2)	<0.001*
LKM scale (Me [IQR])	10 (8 – 10)	2 (0 – 3.5)	<0.001*	9 (8 – 10)	4 (2 – 8)	<0.001*
Lund–Mackay scale Me [IQR] ($\mu_x \pm SE$)	21 (16 – 23)	9.6 \pm 4	<0.001*	19 (14 – 22)	11.4 \pm 5.3	<0.001*

*p-value as determined by the Wilcoxon signed rank test; Me = median, IQR = interquartile range.

Table 3. Comparison of post-operative endoscopic and radiological outcomes between groups.

	Reboot surgery + Bilateral mucoplasty (n = 17)	Reboot surgery (n = 47)	p-value
Meltzer scale (Me [IQR])	0 (0 – 0)	0 (0 – 2)	0.028 *
LKM scale (Me [IQR])	2 (0 – 3.5)	4 (2 – 8)	<0.001*
Lund–Mackay scale ($\mu_x \pm SE$)	9.6 \pm 4	11.4 \pm 5.3	0.375 [†]
Re – intervention	0 (0%)	4 (8.5%)	0.214 [‡]

* p-value as determined by the U de Mann-Whitney test; Me = median, IQR = interquartile range. [†] p-value as determined by the T–student test for independent data; μ_x = arithmetic average, SE = Standard deviation. [‡] p-value as determined by chi-square test.

Table 4. Linear regression effect estimates for bilateral mucoplasty.

	Unadjusted β ($\mu_x \pm SE$)	Adjusted β ($\mu_x \pm SE$)	95% confidence interval	p value	R ²	Adjusted R ²
Change in SNOT – 22	20.5 \pm 6.4 ^{*1}	-	(7.58 to 33.36)	0.0024	0.146	0.132
	-	22.6 \pm 6.3 ^{*2}	(10.04 to 35.13)	0.00065	0.222	0.195

VIFs were calculated to evaluate multicollinearity in multivariate models. VIFs were <2.00.

*¹ Model equation: Change in SNOT-22 = 43.13 + 20.5 x ((1 if bilateral mucoplasty plus reboot surgery) or (0 if reboot surgery)).

*² Adjusted for significant independent predictor (p < 0.05): previous ESS.

Model equation: Change in SNOT-22 = 48.7 + 22.6 x ((1 if bilateral mucoplasty plus reboot surgery) or (0 if reboot surgery)) - 12.8 x ((1 if previous ESS) or (0 if no previous ESS)).

this model, a bilateral mucoplasty led, on average, to a 22.6 \pm 6.3 greater change in SNOT-22 (p < 0.001). A previous history of ESS reduced the improvement in SNOT-22 by 12.8 \pm 5.4 (p = 0.021). A bilateral extended mucoplasty was feasible in all patients and no intraoperative complications were recorded. Figure 2 illustrates the appearance of a nostril during surgery. None of the patients showed complications at either moment in time. The mucosal graft donor area of the fossa did not show associated morbidity and healed successfully in all selected cases. Figure 3 illustrates the appearance of endonasal healing in both nostrils, one year after surgery, in four patients. There were no major complications (cerebrospinal fluid leaks, haemorrhage, orbital

complications, etc.) in the follow-up period after surgery.

Discussion

Even though extended ESS have been proposed as an alternative approach in those CRSwNP patients that fail to see adequate results from conventional treatments, the different surgery techniques proposed thus far do not yet allow for optimal management of the disease. The clinical characterization of patients is becoming a crucial factor for surgery management, with more aggressive techniques being advised in patients showing type 2 inflammation endotype^(1,5-7). The presence of comorbidities, such as late-onset asthma, N-ERD, or a history of re-inter-

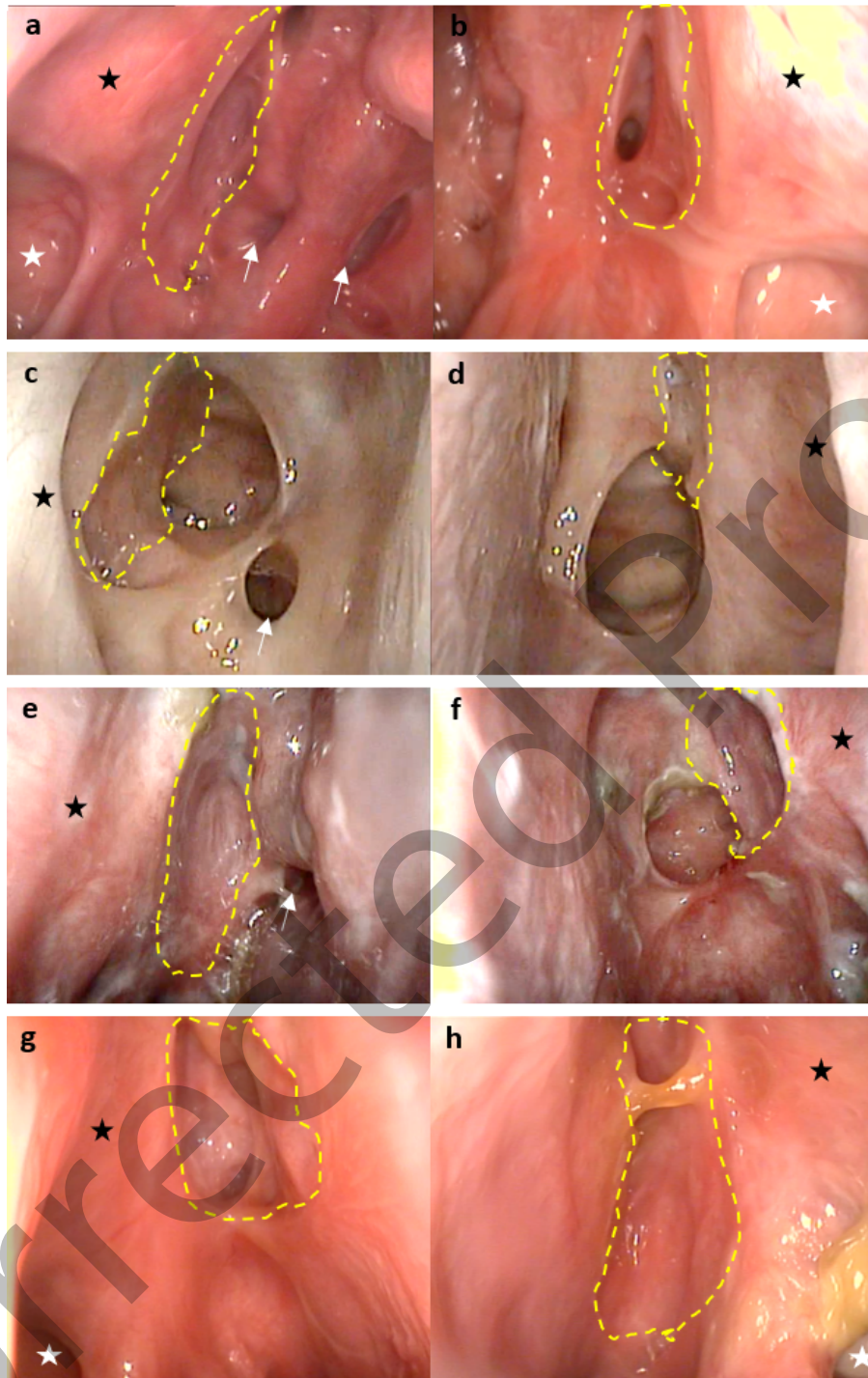


Figure 3. Left-hand column: right nostril; right-hand column: left nostril. A: Patient one (with a posterior septal perforation). B: Patient two. C: Patient three. D: Patient four. Dashed line: mucoplasty; white star: maxillary sinus; black star: lamina papyracea; white arrow: sphenoidal rostrum.

ventions are considered markers of high burden type 2 inflammation^(6,7), often accounting for the failure of the described medical and surgical treatments^(6,7,18). This is the first prospective study aimed at demonstrating the usefulness of a reconstructive surgical technique (bilateral mucoplasty) complementary to a reboot surgery in the treatment of patients with CRSwNP and a type 2 inflammatory endotype.

Based on the technique proposed by Alsharif et al.⁽⁵⁾, a complete resection of the ethmoidal septa plus a frontal sinusotomy (type IIA or more), with a systematic resection of both the healthy and pathologic mucosa, was performed in all patients in the study. Our results showed a considerable improvement in endoscopic outcomes in both groups (Table 2), thus proving the effectiveness of reboot surgery in patients with markers of high burden

type 2 inflammation^(5,6). In contrast with other works where the mucosa was only partially resected^(19,20), we hypothesize that this endoscopic improvement may be due to a complete demucosalization, which would corroborate the results of other works where a complete removal of the sinus mucosa was also performed^(5,6,18). In addition, the reboot surgery technique was complemented with a bilateral extended autologous mucosal graft from the nasal floor in the mucoplasty cohort group, which showed more favourable healing results than those exhibited by patients who only underwent a reboot surgery. Specifically, less postoperative local oedema and a decrease in the recurrence of nasal polyps were seen, as measured by Meltzer and modified Lund Kennedy endoscopic scores (Table 3). Consequently, we hypothesize that such an improvement may be explained by the use of bilateral mucosal grafts with larger surface areas, furthering previous results by our group where this technique was performed unilaterally and limited to smaller graft dimensions^(10,11). It is probable that the use of larger bilateral mucosal grafts offered greater surface coverage in areas of the nostril with a higher tendency to polypoid recurrence^(5,20).

Compared with other extended surgeries^(4,19-23), reboot surgeries have reported a considerable reduction in the nasal growth recurrence rate from 45% to less than 10% in patients with type 2 inflammation two years after surgery⁽⁶⁾. In this study, with a mean follow-up of twelve months in the bilateral mucoplasty cohort, a reintervention rate of 0% was reported, which considerably decreases the tendency for polyp relapse in the medium term. Bilateral mucoplasty may have provided the receptor area (ethmoidal roof and papyracea lamina) with more favourable local inflammatory characteristics, even in patients with high burden type 2 inflammation. In this sense, the study of the mucosa properties at both cellular and molecular level, as well as the underlying mechanism within the inflammatory cascade, opens the way to new emerging therapeutic approaches in the management of patients with CRSwNP.

In terms of radiological outcomes, the results found in this study are comparable to other works in which similar extension techniques were applied^(5,20), showing a decrease in the postoperative Lund Mackay score, but without significant differences being seen between groups (Tables 2 and 3). This lack of significance may be explained by the inherent limitations of this score, which does not differentiate paranasal sinuses that are nearly fully opacified from those that are minimally opacified⁽²⁴⁾.

In addition to endoscopic and radiological outcomes, QoL plays a major role in the management of patients with CRSwNP⁽¹⁾.

The results in this study showed that patients from both surgical groups experienced a significant mean improvement in QoL one year post surgery, with considerably lower mean SNOT-22 values of 24 ± 16.5 and 31.4 ± 26.8 in each group, which are in the same range as previous values reported for reboot surgery⁽⁵⁾. This corresponds to SNOT-22 relative changes (preoperative – postope-

orative) of 67 ± 27.5 and 45.5 ± 35 in each group, which are considerably greater than the minimal clinically important difference of 12 points reported previously⁽²⁵⁾. Previous metanalysis found a mean SNOT-22 change of 24.4 (95% CI: 22.0–26.8) after ESS in published data. However, the magnitude of change considerably diverges between studies, being influenced by factors such as length of follow-up, asthma prevalence, existence of polyps and baseline SNOT-22 scores⁽²⁶⁾. In addition, surgical approach and extent have also been shown to be a factor influencing SNOT-22 outcomes^(27,28). Interestingly, in our study, the mean improvement in SNOT-22 change was significantly greater in the group subjected to bilateral mucoplasty (Figure 1). Indeed, according to bivariate linear regression models, a significantly greater mean improvement of 20.5 units in SNOT-22 was calculated for patients that underwent bilateral mucoplasty compared with those that only underwent a reboot surgery. To confirm whether such a differential gain was biased by higher baseline SNOT-22 scores in subjects undergoing bilateral mucoplasty, multivariate linear regression models were performed, and collinearity was assessed through VIFs. It is noteworthy that the mean improvement was not only preserved but in fact increased to 22.6 points after controlling for age, gender, asthma, NERD, and baseline SNOT-22 score by using stepwise multivariate linear regression modelling. The only covariate that had a significant (negative) effect on SNOT-22 change was a previous history of ESS, which reduced the total improvement to 12.8 points (Table 4). This finding supports the negative impact reported for reinterventions in CRSwNP patients' quality of life^(1,26) and raises the hypothesis of associating bilateral mucoplasties to reboot surgeries as the preferred surgical treatment in patients with a type 2 inflammatory endotype.

A significant improvement of item 21 was seen in both surgical groups, with no significant differences between the two approaches. In the literature, even though enhanced olfaction outcomes have been reported in almost all subjective and objective measures after ESS⁽²⁹⁾, olfaction has also been shown to be the cardinal symptom that improves less when compared with conventional medical treatment⁽³⁰⁾. More comprehensive studies that include validated olfaction tests are still needed⁽³¹⁾, which should allow us to better quantify how surgical approach and extent impact olfaction in CRSwNP patients.

Limitations

This study is limited by the small sample of patients included and the non-randomized design followed, which may have generated inhomogeneous differences between groups, possibly leading to an overestimation of true effect estimates. It must be noticed that the study period coincided with that of the COVID-19 pandemic, which led to a decrease in the performance of elective surgeries, considerably affecting the number of CRSwNP patients surgically intervened in the last two years.

To avoid baseline differences between groups, patients were carefully selected during the same period and by the same surgeons to ensure that they shared similar characteristics. Furthermore, the analysis of relative SNOT-22 changes and the use of multivariate linear regression models to adjust for any measurable confounding disease effect or baseline inhomogeneity strengthens the hypothesis that the observed differences between groups are unbiased.

Additionally, the follow-up time was limited to 12 months, which is insufficient to evaluate the polypoid relapse tendency and QoL outcomes in the long term (at least three years). More clinical studies with larger sample groups and longer follow-up periods would be needed to corroborate these findings. Finally, it is difficult to systematically achieve endotype characterisation in clinical daily practice. In the future, the identification and rapid detection of validated biomarkers from CRS patients could help better delineate the therapeutic profiles and the indication of bilateral endonasal mucoplasty in patients with type 2 inflammatory endotype. Furthermore, further knowledge of the cellular and molecular properties of the nasal mucosa would help us elucidate the true benefits associated to bilateral mucoplasties in CRSwNP patients.

Conclusions

The use of bilateral endonasal mucoplasty associated with extended reboot surgery provides improved endoscopic outcomes in CRSwNP patients with type 2 endotype, showing decreased oedema and nasal growth recurrence, in addition

to a significant improvement in QoL one year after surgery. These outcomes are possibly due to a combination between the benefit derived from the surgical extension of the reboot surgery and the healing and inflammatory properties of the bilateral mucoplasty. We propose this technique as a useful surgical resource, although more clinical studies with larger sample sizes and longer follow-up periods need to be conducted to comprehensively analyse their long-term benefits.

Acknowledgements

We are grateful to all participants who voluntarily enrolled in this project. We thank David G. Plant for editing the manuscript and editorial assistance.

Authorship contribution

Conception: MLR, GGJ, SGS. Design: MJD, MLR, SGS, CBA, CLA. Supervision: MLR, MJD, SGS, PGC. Resource: MSJM, MLR, GGJ, PGC, SGS. Materials: MLR, GGJ, MSJM. Data collection and/or processing: MLR, GGJ, SGS, MSJM, PGC, CLA. Analysis and/or interpretation: MJD, MLR, CLA, SGS. Literature search: MJD, MLR, SGS. Writing: MLR, MJD, CLA. Critical reviews: CLA, MLR, SGS, CBA.

Conflict of interest

The authors report no conflict of interest.

Funding

The authors have not received any funding.

References

1. Fokkens WJ, Lund VJ, Hopkins C, Hellings PW, Kern R, Reitsma S, et al. European Position Paper on Rhinosinusitis and Nasal Polyps 2020. *Rhinology*. 2020;58(Suppl S29):1-464.
2. Fokkens WJ, Lund VJ, Mullol J, Bachert C, Alobid I, Baroody F, et al. EPOS 2012: European position paper on rhinosinusitis and nasal polyps 2012. A summary for otorhinolaryngologists. *Rhinology*. 2012;50(1):1-12.
3. Rudmik L, Soler ZM, Hopkins C, Schlosser RJ, Peters A, White AA, et al. Defining appropriateness criteria for endoscopic sinus surgery during management of uncomplicated adult chronic rhinosinusitis: a RAND/UCLA appropriateness study. *Rhinology*. 2016;54(2):117-28.
4. Chen FH, Deng J, Hong HY, Xu R, Guo JB, Hou WJ, et al. Extensive versus functional endoscopic sinus surgery for chronic rhinosinusitis with nasal polyps and asthma: A 1-year study. *Am J Rhinol Allergy*. 2016;30(2):143-8.
5. Alsharif S, Jonstam K, van Zele T, Gevaert P, Holtappels G, Bachert C. Endoscopic Sinus Surgery for Type-2 CRS wNP: An Endotype-Based Retrospective Study. *Laryngoscope*. 2019;129(6):1286-92.
6. Bachert C, Marple B, Hosemann W, Cavaliere C, Wen W, Zhang N. Endotypes of Chronic Rhinosinusitis with Nasal Polyps: Pathology and Possible Therapeutic Implications. *J Allergy Clin Immunol Pract*. 2020;8(5):1514-9.
7. Cardell LO, Stjärne P, Jonstam K, Bachert C. Endotypes of chronic rhinosinusitis: Impact on management. *J Allergy Clin Immunol*. 2020;145(3):752-6.
8. Tomassen P, Vandeplas G, Van Zele T, Cardell LO, Arebro J, Olze H, et al. Inflammatory endotypes of chronic rhinosinusitis based on cluster analysis of biomarkers. *J Allergy Clin Immunol*. 2016;137(5):1449-1456.e4.
9. Bachert C, Zhang N, Hellings PW, Bousquet J. Endotype-driven care pathways in patients with chronic rhinosinusitis. *J Allergy Clin Immunol*. 2018;141(5):1543-51.
10. Moreno-Luna R, González-García J, Maza-Solano JM, et al. Free nasal floor mucosal grafting after endoscopic total ethmoidectomy for severe nasal polyposis: a pilot study. *Rhinology*. 2019;57(3):219-24.
11. Moreno-Luna R, González-García J, Palacios-García J, Maza-Solano JM, Del Cuervo Bernal A, Sánchez-Gómez S. Usefulness of endonasal mucoplasty in the surgical treatment of chronic rhinosinusitis with nasal polyps. Prospective study. *Acta Otorrinolaringol Esp*. 2021;72(4):256-61.
12. Meltzer EO, Hamilos DL, Hadley JA, Lanza DC, Marple BF, Nicklas RA, et al. Rhinosinusitis: developing guidance for clinical trials. *J Allergy Clin Immunol*. 2006;118(5 Suppl):S17-61.
13. Toma S, Hopkins C. Stratification of SNOT-22 scores into mild, moderate or severe and relationship with other subjective instruments. *Rhinology*. 2016;54(2):129-33.
14. González-García J, Moreno-Luna R, Palacios-García J, Del Cuervo Bernal A, Maza-Solano JM, Santos Pérez J, et al. Radioanatomical study of the extended free nasal floor mucosal graft and its clinical applications. *Laryngoscope Invest Otolaryngol*. 2020;5(6):1011-8.
15. Lund VJ, Kennedy DW. Quantification for staging sinusitis. The Staging and Therapy Group. *Ann Otol Rhinol Laryngol Suppl*. 1995;167:17-21.
16. Hopkins C, Browne JP, Slack R, Lund V, Brown P. The Lund-Mackay staging system for chronic rhinosinusitis: how is it used and

- what does it predict? Otolaryngol-Head Neck Surg. 2007;137(4):555-61.
17. Kennedy JL, Hubbard MA, Huyett P, Patrie JT, Borish L, Payne SC. Sino-nasal outcome test (SNOT-22): a predictor of postsurgical improvement in patients with chronic sinusitis. *Ann Allergy Asthma Immunol.* 2013;111(4):246-251.e2.
 18. Jonstam K, Alsharif S, Bogaert S, Suchonos N, Holtappels G, Park JH, et al. Extent of inflammation in severe nasal polyposis and effect of sinus surgery on inflammation. *Allergy.* 2021;76(3):933-6.
 19. Jankowski R, Pigret D, Decroocq F, Blum A, Gillet P. Comparison of radical (nasalisation) and functional ethmoidectomy in patients with severe sinonasal polyposis. A retrospective study. *Rev Laryngol Otol Rhinol.* 2006;127(3):131-40.
 20. Shen PH, Weitzel EK, Lai JT, Wormald PJ, Lin CH. Retrospective study of full-house functional endoscopic sinus surgery for revision endoscopic sinus surgery. *Int Forum Allergy Rhinol.* 2011;1(6):498-503.
 21. Masterson L, Tanweer F, Bueser T, Leong P. Extensive endoscopic sinus surgery: does this reduce the revision rate for nasal polyposis? *Eur Arch Oto Rhino Laryngol.* 2010;267(10):1557-61.
 22. Videler WJM, van Drunen CM, van der Meulen FW, Fokkens WJ. Radical surgery: effect on quality of life and pain in chronic rhinosinusitis. *Otolaryngol Head Neck Surg.* 2007;136(2):261-7.
 23. DeConde AS, Suh JD, Mace JC, Alt JA, Smith TL. Outcomes of complete vs targeted approaches to endoscopic sinus surgery. *Int Forum Allergy Rhinol.* 2015;5(8):691-700.
 24. Ayoub N, Walgama E, Thamboo A, Chitsuthipakorn W, Patel ZM, Nayak JV, et al. Correlation between extent of sinus surgery, radiographic disease, and postoperative outcomes. *Rhinology.* 2020;58(1):36-44.
 25. Phillips KM, Houssein FA, Speth MM, Sedaghat AR. Utility of Visual Analog Scale of Subdomain Scores of the 22-Item Sinonasal Outcome Test in Chronic Rhinosinusitis. *Otolaryngol-Head Neck Surg.* 2022;1945998211068748.
 26. Soler ZM, Jones R, Le P, Rudmik L, Mattos JL, Nguyen SA, et al. Sino-Nasal outcome test-22 outcomes after sinus surgery: A systematic review and meta-analysis. *Laryngoscope.* 2018;128(3):581-92.
 27. Hopkins C, Rudmik L, Lund VJ. The predictive value of the preoperative Sinonasal Outcome Test-22 score in patients undergoing endoscopic sinus surgery for chronic rhinosinusitis. *Laryngoscope.* 2015;125(8):1779-84.
 28. Alanin MC, Hopkins C. Effect of Functional Endoscopic Sinus Surgery on Outcomes in Chronic Rhinosinusitis. *Curr Allergy Asthma Rep.* 2020;20(7):27.
 29. Kohli P, Naik AN, Farhood Z, Ong AA, Nguyen SA, Soler ZM, et al. Olfactory Outcomes after Endoscopic Sinus Surgery for Chronic Rhinosinusitis: A Meta-analysis. *Otolaryngol Head Neck Surg.* 2016;155(6):936-48.
 30. DeConde AS, Mace JC, Alt JA, Schlosser RJ, Smith TL, Soler ZM. Comparative effectiveness of medical and surgical therapy on olfaction in chronic rhinosinusitis: a prospective, multi-institutional study. *Int Forum Allergy Rhinol.* 2014;4(9):725-33.
 31. Patel ZM, Holbrook EH, Turner JH, Adappa ND, Albers MW, Altundag A, et al. International consensus statement on allergy and rhinology: Olfaction. *Int Forum Allergy Rhinol.* 2022;12(4):327-680.

Ramón Moreno-Luna, MD, PhD
Advisory Board of European Rhinology Society
 Rhinology Unit, Department of Otolaryngology
 Hospital Universitario Virgen de la Macarena
 Avda. Doctor Fedriani 3
 E-41071 Seville
 Spain

E-mail: ramoluorl@gmail.com