

## THE FACIAL PROFILE AND COSMETIC SURGERY

Graeme M. Clark, F.R.C.S., F.R.A.C.S., Melbourne, Australia

Rhinoplastic technique is now well developed and skill in its use can be acquired with practice. Judgement is required, however, to alter the nasal profile to suit the facial profile as a whole. Surgical correction of forehead and chin lines is more difficult, and for this reason, the nasal profile should not accentuate any excessive deviations from the normal in these structures. Certain features of the facial profile are more prominent in one particular sex and it is felt that these characteristics should not be accentuated when operating on the nose of a patient of the opposite sex. The purpose of this paper is to outline the variations in profile that are more frequently associated with a particular sex, and to draw attention to certain principles of aesthetics and perception that can assist in deciding what alterations should be made to the facial profile as a whole. The application of these principles to two patients is discussed.

### Sexual and Racial Variations of the Facial Profile:

The development of the supra-orbital region is important in determining the sex of European and Aboriginal Crania (Larnach and Freedman 3) and this can be seen by referring to Table 1 (Larnach and Macintosh 4). Prominence in this region may be due to the glabella, superciliary ridge and zygomatic trigone (Figs. 1 and 2) which are three independently variable structures. Their convexity may be accentuated by the concavities of the nasion, supra-glabellar fossa and ophrionic groove (Figs. 1 and 2).

Recession of the forehead has also been considered a male characteristic, but this is probably an illusion due to prominence of the supra-orbital region. Frontal curvature indices do not show any significant differences between male and female Aborigines and there is little variation between Aborigines and Europeans (Woo 5).

Table 1. Prominence of Superciliary Ridges in the Australian Aboriginal.  
(after Larnach and Macintosh)

	Total Series	Percentage	
		Females	Males
Small	48.8	90.4	15.4
Medium	25.6	7.7	40.0
Large	25.6	1.9	44.6

Ear, Nose and Throat Section, The Royal Victorian Eye and Ear Hospital, and Alfred Hospital, Melbourne, Australia.

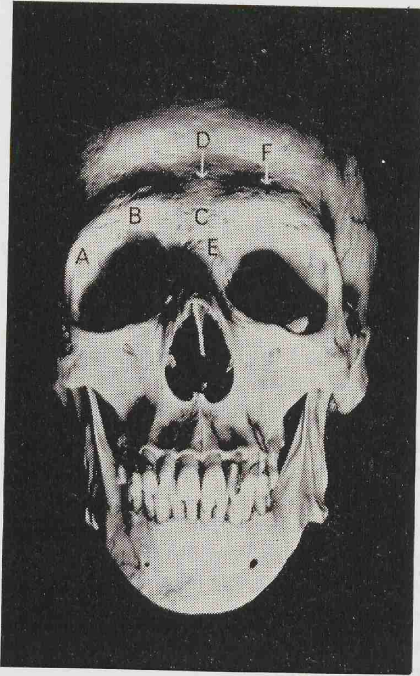


Figure 1. A frontal view of a male European skull.

- A. zygomatic trigone
- B. superciliary ridge
- C. glabella
- D. supra-glabella fossa
- E. nasion
- F. ophrionic groove

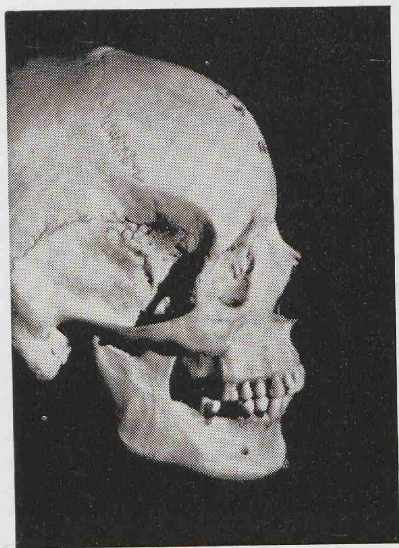There are, however, a number of differences between Aboriginal and European skulls, which include the shape of the lower nasal margins, width of the naso-frontal articulation, prominence of the supra-orbital region and size of the hard palate. On the other hand sex differences in Aboriginal skulls are fundamentally the same as sex differences in European skulls.

As prominence of the supra-orbital region is more characteristic of males, it is suggested that this feature should not be unduly accentuated when operating on the nasal dorsum of a female patient. This can occur if the concavity of the nasion and nasal dorsum are increased, creating the illusion of a more prominent supra-orbital region.

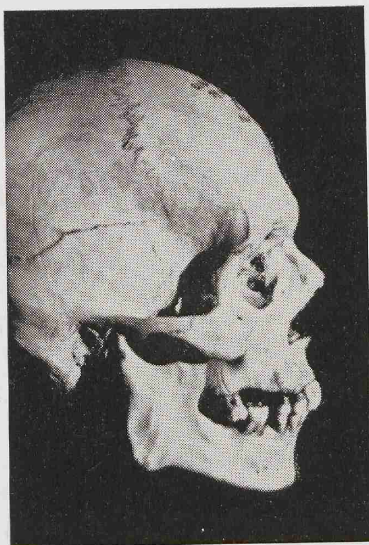
#### **Perception and Illusion and the Facial Profile:**

Optical illusion is one aspect of perception that is seen in everyday life (Guilford 2) and is used by the rhinoplastic surgeon to minimize unattractive features that cannot be corrected surgically. Examples of various types of optical illusion that are relevant to rhinoplastic surgery can be seen in Fig. 3. An important illusory effect is simultaneous contrast, whereby the size of an object is related to other neighbouring objects (Fig. 3 A). This principle explains why excessive deepening of the nasion is not desirable in a female patient who has a prominent supra-orbital region. Secondly, vertical distances appear larger than horizontal one (Fig. 3 B). This is one reason why a patient with a long, vertically-directed nose can have it made look shorter by tilting it upwards so that the dorsal profile line is more horizontal. Thirdly, the illusion that broken or interrupted spaces seem larger than continuous or unbroken ones (Fig. 3 C) may explain why a nose with an irregular profile

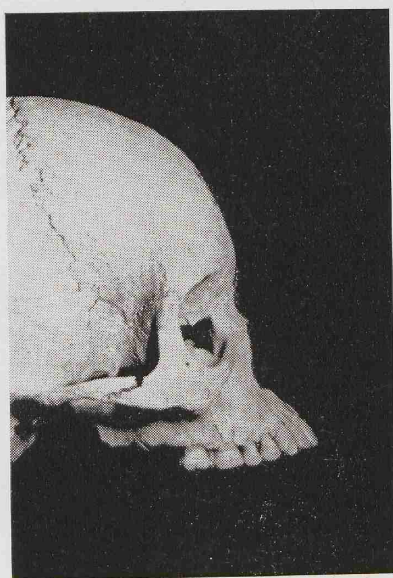




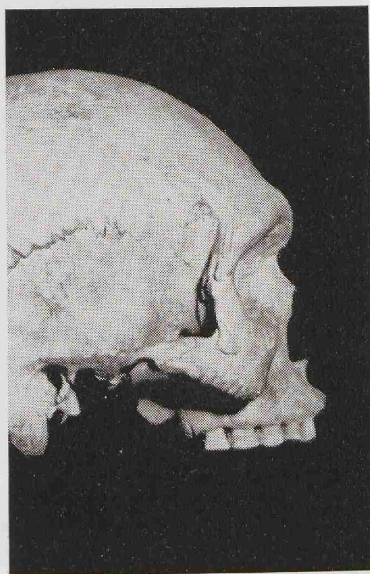
A



B



C



D

Figure 2. Lateral views of European and Aboriginal skulls.

- |                    |                      |
|--------------------|----------------------|
| A. female European | C. female Aboriginal |
| B. male European   | D. male Aboriginal   |


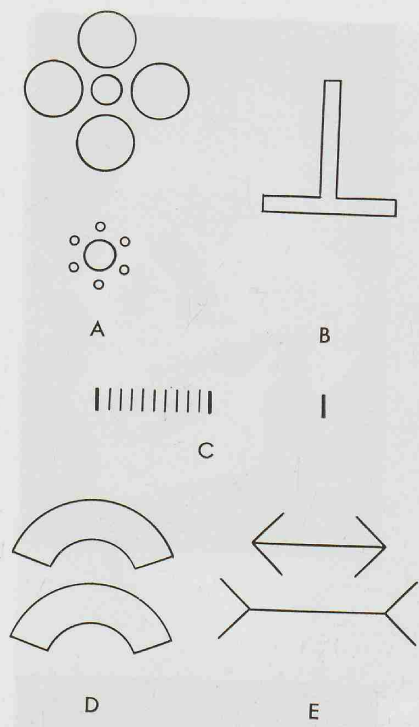


Figure 4. Composite facial profile tracings.

Figure 3. Optical illusions relevant to cosmetic surgery.

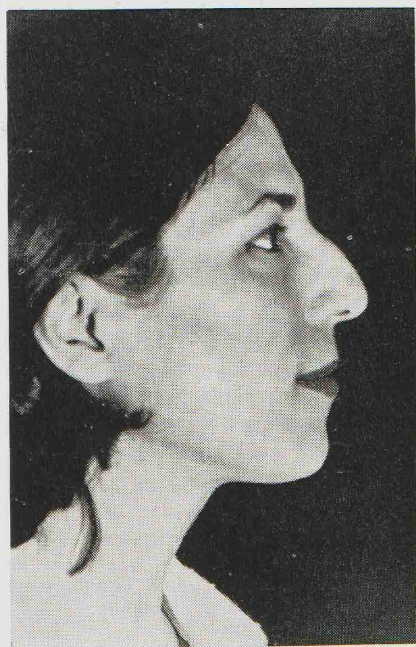line tends to look longer than one with a straight profile. Fourthly, the whole object may be judged according to some emphatic property of a significant part (Fig. 3 D). The sectors seen in Fig. 3 D are equal but the lower one looks larger because there is a contrast in size between neighbouring sides. This principle could help explain why an upper lip appears shorter where there is a drooping nasal tip. Finally, a line cannot be divorced from its ends, and this explains why the lower line in Fig. 3 E looks longer. This principle has application to patients with a long nose and shallow nasion. The nose will appear shorter if this region is deepened and divorced from the forehead line. The application of some of these principles can be seen by referring to Fig. 4. These facial profiles are a result of various combinations of normal, prominent and receding chins with convex and concave nasal profiles, in a person with a receding forehead and prominent supra-orbital region. In order to assist comparison of the profiles, each typical feature has been reproduced exactly in the different tracings. These silhouettes have been studied independently by seven untrained observers and the consensus of opinion is that the prominence in the supra-orbital region is greater in those profiles with a convex dorsal nasal line (Fig. 4 A, B, C). It is suggested that this is an illusion due to an apparent concavity in the region of the nasion. Further observations were that a prominent nose exaggerated a receding forehead and chin and vice versa.



### Case Discussion:

The significance of sex variations in the facial profile, and the principles of illusion are discussed in two patients. The patient in Fig. 5 had a profile line with a convex nasal dorsum and prominent glabella. The amount of hump to be removed was determined by altering the dorsal nasal line on a color print and wax face mask. (A silhouette is not satisfactory for this purpose because the distance between the inner canthus of the eye and nasion cannot be measured. The concavity in the region of the nasion should be considered in relation to this distance). These alterations showed that when the concavity of the nasion and the nasal dorsum increased beyond a certain point, the masculine feature of a prominent glabella was emphasised and the patient's appearance was not enhanced. Excessive bone removal at the nasion is not desirable in a woman with a prominent glabella, or when septal support has been lost (Clark 1). Consequently, in this patient the desired alteration in the nasal profile was a compromise between concavity in the region of the nasion and prominence of the glabella. This increased prominence of the glabella with a deep nasion is due to the illusion of simultaneous contrast.

On the other hand, the patient seen in Fig. 6 had a saddle nose due to loss of septal support. In her case the proportions of the chin and forehead were satisfactory and she had no prominence of the glabella and supra-orbital region. For this reason, it was considered better to deepen the concavity in



A

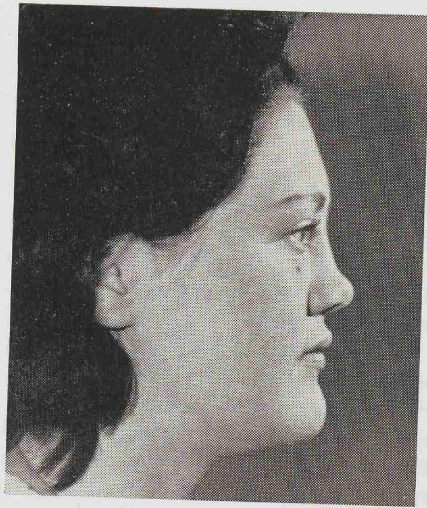

B

Figure 5. Lateral photographs of patient 1.

A. Pre-operative

B. Post-operative



A



B

Figure 6. Lateral photographs of patient 2.  
A. Pre-operative B. Post-operative

the region of the nasion and make the dorsum more concave rather than build up the nose.

### SUMMARY

Studies on Aboriginal and European skulls show that prominence of the glabella and superciliary ridges is a masculine feature. It is suggested that operations on the nasal dorsum should not accentuate this feature in women. Principles of optical illusion and their application to alterations in the facial profile have been discussed. In particular, the concavity in the region of the nasion should not be increased excessively in a woman with a prominent glabella. This is because an optical illusion of simultaneous contrast is created whereby the prominence of the supra-orbital region is enhanced.

### ACKNOWLEDGEMENTS

I would like to thank Professor N. W. G. Macintosh and Mr. S. L. Larnach for providing access to the skulls in the Shellshear Museum of Comparative Anatomy and Physical Anthropology at the University of Sydney. My thanks to Mr. E. Foster for photographic assistance.

### REFERENCES

1. Clark, G. M.: The Role of the Nasal Septum in One-Stage Rhinoplasty. *Arch. Otolaryng.* 85 : 418-423, 1967.
2. Guildford, J. P.: *General Psychology*. B. Van Nostrand Co. Inc. Princeton, 1956. (2nd Ed.)
3. Larnach, S. L. and Freedman, L.: Sex Determination of Aboriginal Crania from Coastal New South Wales, Australia. *Records of the Australian Museum*. 26 : 295-308, 1964.
4. Larnach, S. L. and Macintosh, N. W. G.: *The Craniology of the Aborigines of Coastal New South Wales*. The Oceania Monographs No. 13. The University of Sydney, Sydney, 1966.
5. Woo, J. K.: Racial and Sexual Differences in Frontal Curvature and its Relation to Metopism. *Am. J. Anthropol.* 7 : 215-226, 1949.