

Nasolacrimal duct obstruction caused by an oncocyoma*

Remco de Bree¹, Robert A. Scheeren¹, Allain Kummer² and Rammohan M. Tiwari¹

¹ Department of Otolaryngology / Head and Neck Surgery, VU Medical Center, De Boelelaan 1117, 1081 HV Amsterdam, The Netherlands

² Department of Pathology, VU Medical Center, De Boelelaan 1117, 1081 HV Amsterdam, The Netherlands

SUMMARY

We report the case of a woman with epiphora and purulent rhinorrhea for which she initially underwent a dacryocystorhinostomy. The unilateral rhinorrhea was persistent and one year later an oncocyoma of the lacrimal sac with extension to the nasolacrimal duct was diagnosed. Surgical excision of the tumour via a medial maxillectomy was accomplished. Long-term follow-up for 10 years was without evidence of recurrence. To our knowledge only 22 oncocytomas of the lacrimal sac but none involving the duct have so far been reported. In patients with acquired nasolacrimal duct obstruction a lacrimal sac or nasolacrimal duct tumour though rare is a possibility and should be kept in mind. The majority of these tumours are malignant and oncocytomas may undergo malignant transformation.

Key words: oncocyoma, lacrimal sac, nasolacrimal duct

INTRODUCTION

Acquired nasolacrimal duct obstruction usually is caused by chronic inflammation and fibrosis of the lacrimal sac. These patients have complaints of epiphora and are usually treated by dacryocystorhinostomy. Rarely, nasolacrimal duct obstruction is caused by a lacrimal sac tumour. These tumours include benign as well as malignant tumours: adenocarcinomas, adenoid cystic carcinomas, squamous cell carcinomas, lymphomas, pleomorphic adenomas and oncocytomas (Pe'er et al., 1996). The incidence of lacrimal sac tumours in patients with nasolacrimal duct obstruction is low (Tucker et al., 1997). However, this diagnosis alters the treatment dramatically. Lacrimal sac tumours usually are malignant and should be treated with wide surgical excision.

CASE REPORT

A 58-year-old female was referred to our hospital for complaints of purulent rhinorrhea on the right side since some years. One year before she had undergone a right dacryocystorhinostomy elsewhere, because of a 2-year history of right epiphora. Thereafter, her complaints of epiphora disappeared, but the rhinorrhea persisted. There were no complaints of nasal obstruction, loss of smell or headache. There was no medical history of allergy or chronic sinusitis.

Clinical examination revealed on anterior rhinoscopy purulent secretion in the right inferior meatus. On nasal endoscopy a

tumour at the exit of the nasolacrimal duct was visualized. A CT-scan showed the extension of the tumour filling the entire length of the right nasolacrimal duct from the orbit to the nasal cavity (Figure 1). Histopathological examination of a biopsy taken from the tumour from the inferior meatus showed large cells with abundant eosinophilic granular cytoplasm and round nuclei (Figure 2). The cytoplasmic granules stained positive with phosphotungstic acid-haematoxylin. Electron microscopy showed an abundance of mitochondria (Figure 3). The diagnosis of oncocyoma of the lacrimal sac with extension in the nasolacrimal duct was made.

Patient underwent a medial maxillectomy and excision of the tumour. By removing the medial wall of the maxillary sinus and a medial part of the orbit the entire nasolacrimal duct and lacrimal sac could be excised. Histopathological examination of the surgical specimen showed bone and columnar epithelium with fields of large cells with abundant eosinophilic granular cytoplasm and nuclei with polymorphism and anisokaryosis and moderate chronic inflammatory infiltration. The excision margins were free of tumour. Postoperative course was uneventful. During follow-up some polypoidal mucosa and granulative tissue were removed from the nasal cavity. Histopathological examination showed no signs of recurrence. Ten years later she has no complaints and no evidence of recurrence has been detected.

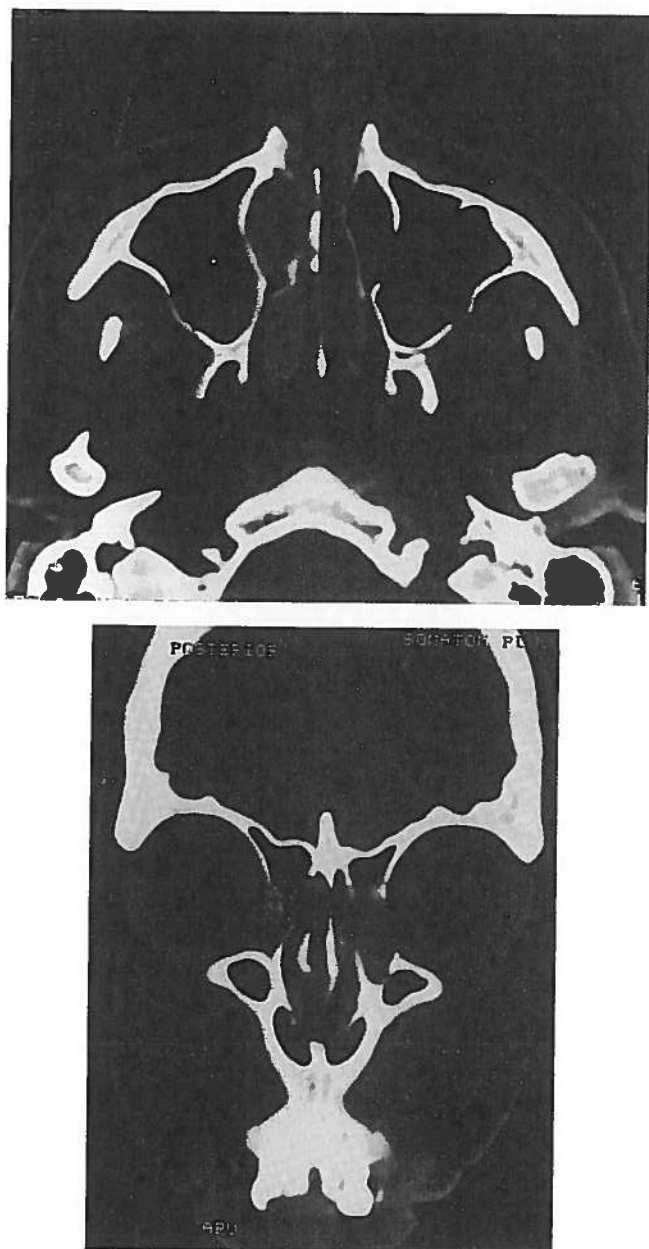


Figure 1. Axial (A) and coronal (B) CT-scan showing the tumour in the lacrimal sac and nasolacrimal duct extending in the nasal cavity.

DISCUSSION

Oncocytomas are rare benign tumours and account for 3.5% of all lacrimal sac neoplasms (Stefanyszyn et al., 1994). To our knowledge only 22 patients with an oncocytoma of the lacrimal sac have been reported to date (Chow et al., 1996; Pe'er et al., 1996; Chen et al., 1998). As far as we know no oncocytoma of the nasolacrimal duct has been reported. In our patient the tumour probably originated from the lacrimal sac and extended to the nasolacrimal duct.

Oncocytomas are composed of large epithelial cells with abundant eosinophilic granular cytoplasm that is shown on electronmicroscopically to be rich in mitochondria, and a round to oval paracentral nucleus (Pe'er et al., 1996). The nature and

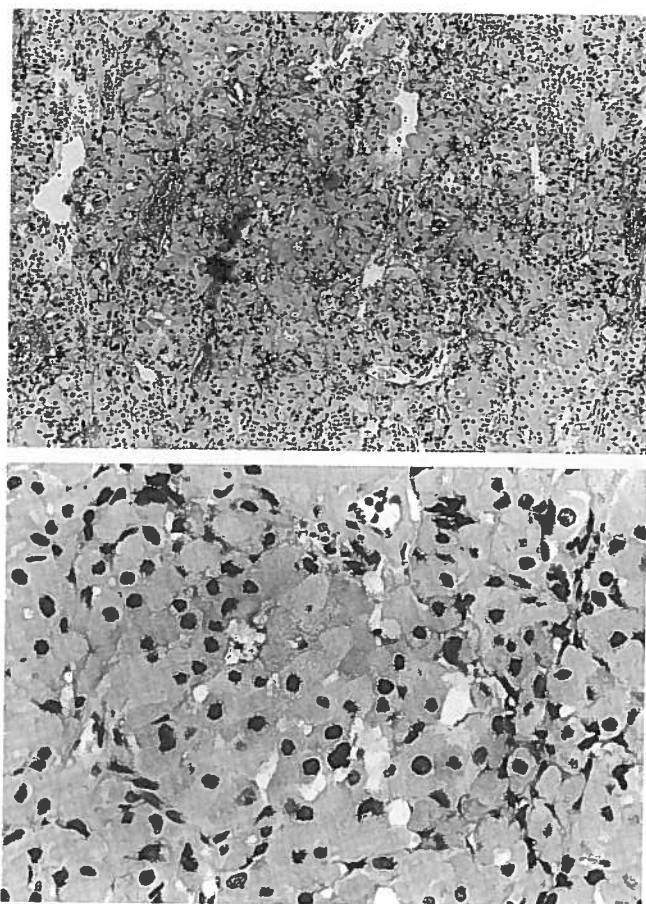


Figure 2A and B. Histopathological examination of the tumour showing large epithelial cells with abundant granular eosinophilic cytoplasm with centrally located nuclei consistent with the diagnosis oncocytoma (hematoxylin-eosin staining; original magnifications x 10 and 40).

function of oncocytes is unknown. Oncocytes are believed to represent metaplastic epithelial cells. This transformation may be due to age-induced exhaustion or excessive physiologic stress, like chronic inflammation (Chow et al., 1996).

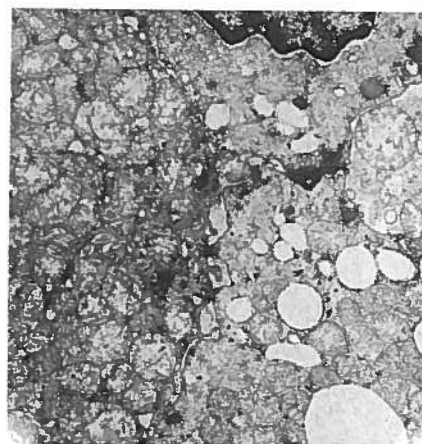


Figure 3. Electron microscopy showing abundance of pleomorphic mitochondria (original magnification x 8,000).

Therefore, in our patient it was difficult to determine if the oncocytoma is due to chronic inflammation or the purulent rhinorrhea was due to the lacrimal sac tumour.

Surgical excision is the treatment of choice, especially because malignant transformation may occur (Tucker et al., 1997; Perlman et al., 1995). Only three malignant oncocytomas of the lacrimal sac have been so far described in the literature (Tomic et al., 1995). In the majority of patients with a malignant lacrimal sac tumour the diagnosis is only made in an advanced stage of the disease. Patients with malignant tumours of the lacrimal sac have an overall mortality of 37.5% (Ni et al., 1982). If the nasolacrimal duct is involved, a lateral rhinotomy is recommended (Pe'er et al., 1996). However, a medial maxillectomy including part of the floor and medial orbital wall offers wider excision.

In patients with acquired nasolacrimal duct obstruction the possibility of an underlying lacrimal sac or nasolacrimal duct tumour, like an oncocytoma, should be kept in mind. These patients require careful long-term follow-up to detect tumour in an early stage and with the recognition that recurrence or malignant transformation is possible, especially if complaints persist after dacryocystorhinostomy.

REFERENCES

1. Chow DR, Brownstein S, Codere F (1996) Oncocytoma of the lacrimal sac associated with chronic dacryocystitis. *Can J Ophthalmol* 31: 249-251.
2. Ni C, Dámico DJ, Fan CQ, Kuo PK (1982) Tumors of the lacrimal sac: a clinicopathological analysis of 82 cases. *Int Ophthalmol Clin* 22: 121-140.
3. Pe'er J, Hidayat AA, Ilsar M, Landau L, Stefanyszyn MA (1996) Glandular tumors of the lacrimal sac. *Ophthalmology* 103: 1601-1605.
4. Perlman JI, Specht CS, McLean IW, Wolfe SA (1995) Oncocytic adenocarcinoma of the lacrimal sac: report of a case with paranasal sinus and orbital extension. *Ophthalmic Surg* 26: 377-379.
5. Stefanyszyn MA, Hidayat AA, Pe'er JJ, Flanagan JC (1994) Lacrimal sac tumors. *Ophthalmic Plast Reconstr Surg* 10: 169-184.
6. Tomic S, Warner TF, Brandenburg JH (1995) Malignant oncocytoma of the lacrimal sac: ultrastructure and immunocytochemistry. *Ear Nose Throat J* 74: 717-720.
7. Tucker N, Chow D, Stockl F, Codere F, Burnier M (1997) Clinically suspected primary acquired nasolacrimal duct obstruction. *Ophthalmology* 104: 1882-1886.

Remco de Bree
Department of Otolaryngology /
Head and Neck Surgery
VU Medical Center
P.O. Box 7057
1007 MB Amsterdam
The Netherlands

Tel: +31-20-444-3690
Fax: +31-20-444-3688
E-mail: r.bree@vumc.nl