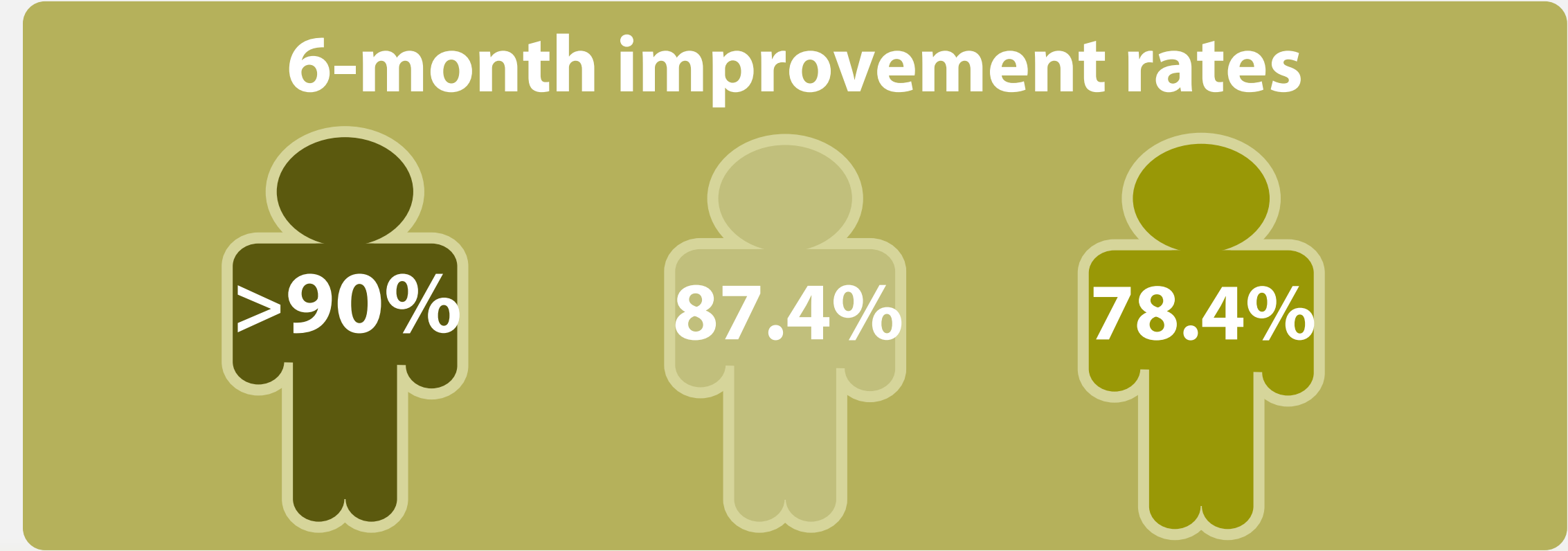
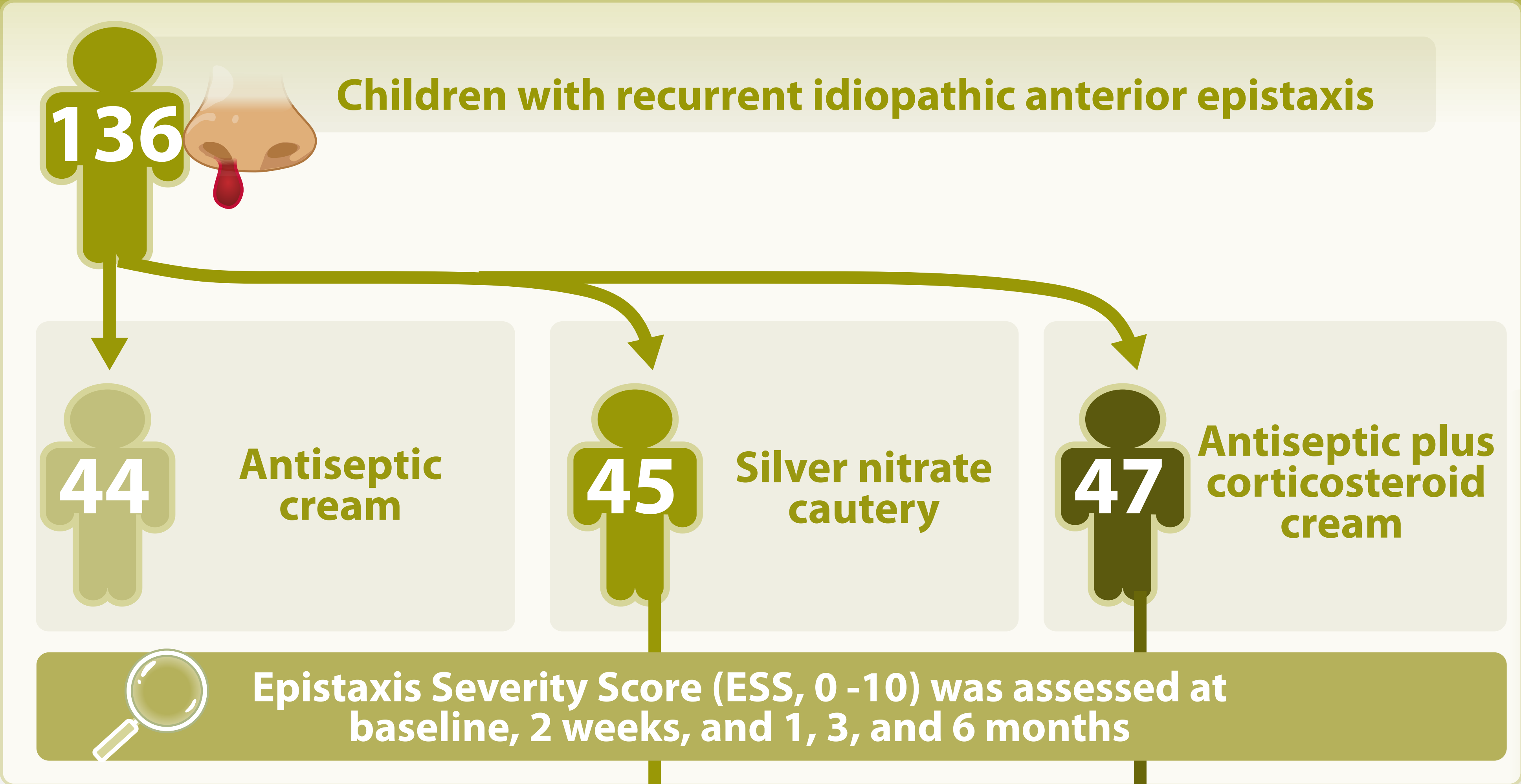


Comparative study between different methods for treatment of recurrent anterior idiopathic epistaxis in children

a prospective randomized clinical study

Recurrent anterior idiopathic epistaxis is common in children, yet optimal management remains debated



Fastest early improvement (2 weeks)

Greatest sustained reduction (1 to 6 months)

Cautery achieves rapid short-term control, but antiseptic plus corticosteroid cream provides the most durable improvement following a short, two-week course