

# Algorithm for navigated ESS\*

Tomislav Baudoin<sup>1</sup>, Marko Velimir Grgić<sup>1</sup>, Dijana Zadravec<sup>2</sup>, Goran Geber<sup>1</sup>, Dejan Tomljenović<sup>1</sup>, Livije Kalogjera<sup>1</sup>

**Rhinology 51:** 143-153, 2013

DOI:10.4193/Rhino12.212

<sup>1</sup> Department of Otorhinolaryngology & Head and Neck Surgery, Sisters of Mercy University Medical Center, Zagreb University School of Medicine, Zagreb, Croatia

<sup>2</sup> Clinical Department of Diagnostic and Interventional Radiology, Sisters of Mercy University Medical Center, Zagreb University School of Dental Medicine, Zagreb, Croatia

**\*Received for publication:**

December 30, 2012

**Accepted:** April 25, 2013

## Summary

ENT navigation has given new opportunities in performing Endoscopic Sinus Surgery (ESS) and improving surgical outcome of the patients' treatment. ESS assisted by a navigation system could be called Navigated Endoscopic Sinus Surgery (NESS). As it is generally accepted that the NESS should be performed only in cases of complex anatomy and pathology, it has not yet been established as a state-of-the-art procedure and thus not used on a daily basis.

This paper presents an algorithm for use of a navigation system for basic ESS in the treatment of chronic rhinosinusitis (CRS). The algorithm includes five units that should be highlighted using a navigation system. They are as follows: 1) nasal vestibule unit, 2) OMC unit, 3) anterior ethmoid unit, 4) posterior ethmoid unit, and 5) sphenoid unit. Each unit has a shape of a triangular pyramid and consists of at least four reference points or landmarks. As many landmarks as possible should be marked when determining one of the five units. Navigated orientation in each unit should always precede any surgical intervention. The algorithm should improve the learning curve of trainees and enable surgeons to use the navigation system routinely and systematically.

**Key words:** algorithm, endoscopic sinus surgery, navigation, NESS, chronic rhinosinusitis

## Introduction

Endoscopic sinus surgery (ESS), conceived by Messerklinger in the early eighties, was the first surgical technique developed that addressed the underlying pathophysiology to treat chronic rhinosinusitis (CRS) <sup>(1,2)</sup>. The most common indication for ESS still remains chronic rhinosinusitis (CRS) following long-term unsuccessful medical treatment <sup>(3)</sup>.

Improved imaging and improved finer, sharper and smaller hand instrumentation and powered instrumentation, support the continuous development of this surgical technique and enable rhinosurgeons nowadays to manage almost any sinus pathology endoscopically.

Navigation, even in well-equipped institutions, has not yet been adopted on a daily basis. However, due to increased demand for safety and reduction of complication rates, limited time for trainees to learn and perform ESS during regular training (due to work time regulation) and availability of user friendly equip-

ment, it is expected that navigation systems could soon be used routinely in everyday surgery, in almost any case and by any surgeon doing the ESS.

To primarily improve training in ESS, orientation and comprehensive use of imaging data, we have developed an algorithm for use of a navigation system in basic ESS.

## Algorithm

The algorithm is adjusted to the Messerklinger technique of FESS. It includes five units, which should be identified using the navigation system. All units have the shape of a triangular pyramid. These are the: 1) nasal vestibule unit, 2) OMC unit, 3) anterior ethmoid unit, 4) posterior ethmoid unit and 5) sphenoid unit (Table 1).

Each unit consists of at least four reference points or landmarks. These points are called basic landmarks. Using the triangulation principle for this algorithm, three of the points form a triangle,

Table 1. All five units with basic and additional points - landmarks.

1 NASAL VESTIBULE UNIT	2 OMC UNIT	3 ANTERIOR ETHMOID UNIT	4 POSTERIOR ETHMOID UNIT	5 SPHENOID UNIT
<b>Basic landmarks</b>	<b>Basic landmarks</b>	<b>Basic landmarks</b>	<b>Basic landmarks</b>	<b>Basic landmarks</b>
1. junction between columella and ala	1. middle turbinate attachment to the lateral nasal wall	1. skull base wall	1. skull base wall	1. roof of the nose
2. inferior attachment of the ala	2. inferior attachment of the uncinate process	2. orbital wall	2. orbital wall	2. junction of superior edge of the choana and lateral nasal wall
3. inferior attachment of the columella	3. anterior tip of the middle turbinate	3. middle turbinate	3. superior turbinate	3. junction of superior edge of the choana and nasal septum
4. anterior tip of the inferior turbinate	4. ethmoidal bulla	4. ground lamella	4. fovea posterior	4. anterior wall of the sphenoid
		<b>Additional landmarks</b>	<b>Additional landmarks</b>	<b>Additional landmarks</b>
		5. maxillary sinus ostium	5. posterior ethmoidal artery	5. natural ostium of the sphenoid
		6. frontal recess	6. Onodi cell	6. sphenopalatine artery
		7. anterior ethmoidal artery		7. clivus

Any pathology is an additional point-landmark in every unit.

and the fourth one is located inside the unit. Points are always marked in the same manner by drawing a triangle and connecting points in which the first point is positioned superiorly, the second laterally, the third medially and the fourth is inside the triangle (Figures 1, 2).

In the third unit - anterior ethmoid unit - and in the fifth unit - sphenoid unit - natural ostia is added as an additional point. Some important anatomical structures could be marked additionally as optional points, such as the anterior ethmoid artery or posterior ethmoid artery.

During ESS, after the patient has been registered for navigation, and before performing the surgery, as many landmarks as possible should be identified and marked on the navigation system. (Any pathology, for instance a polyp, should be marked as an additional point – landmark).

Surgery should be performed step by step, unit by unit. In this way, navigation always precedes surgery in all units except unit 1 (nasal vestibule) where surgery is almost never performed. Each trainee performs surgery under supervision of the instructor.

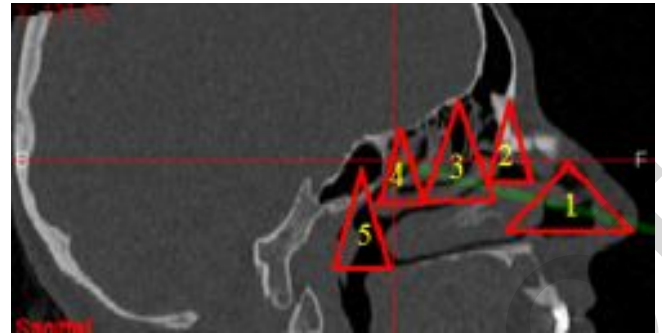


Figure 1. Navigation units: 1. nasal vestibule unit, 2. OMC unit, 3. anterior ethmoid unit, 4. posterior ethmoid unit and 5. sphenoid unit.

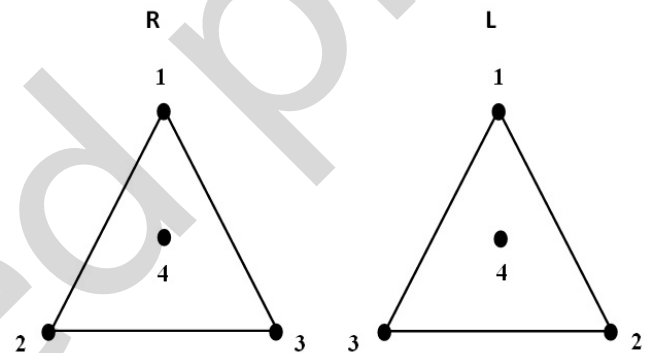


Figure 2. Order of marking points-landmarks in every unit on the right and left side.

The instructor controls the accuracy of marked landmarks by watching the trainee at work during the entire operation. The trainee is not allowed to start the procedure without confirmation of properly marked landmarks in any navigational unit, given by the supervisor.

The next step for our group in developing this algorithm is to create a computer program with landmarks defined according to the algorithm, and to simplify its use. Nowadays, trainee's work is monitored by the supervisor, but soon it will be monitored by both the supervisor and the computer.

**Unit 1: Nasal vestibule unit**

The nasal vestibule unit is the first unit that must be marked during the NESS procedure. It is the entrance to the nose and beginning of the NESS procedure. In this unit, there is no problem with landmark orientation because the anatomy of this unit is mostly external. By marking this unit, the surgeon checks if the accuracy of the navigation system is satisfactory and prepares for the following units.

The nasal vestibule unit consists of four landmarks. The first

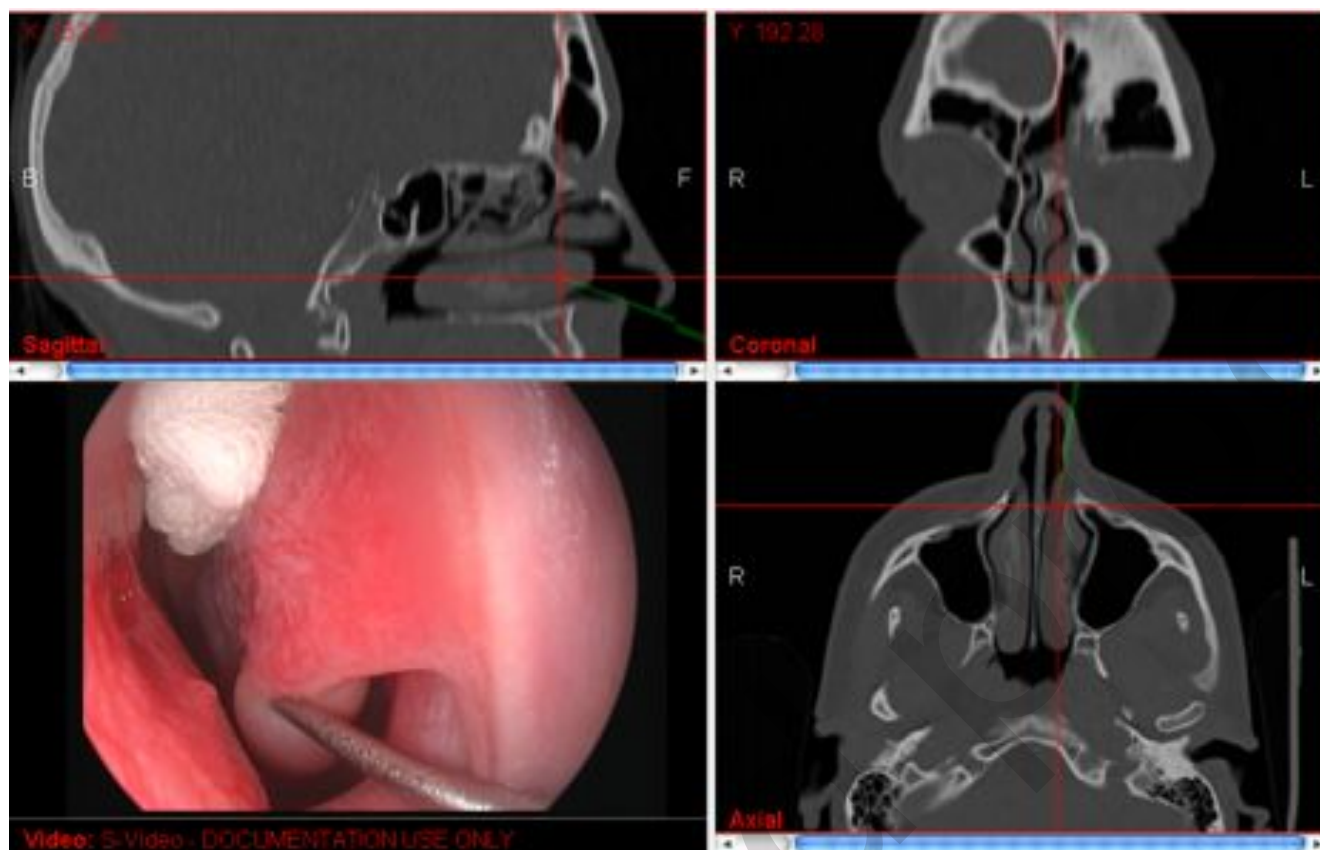


Figure 3. Unit 1 - Nasal vestibule unit (left): Point 4 - Inferior turbinate landmark.

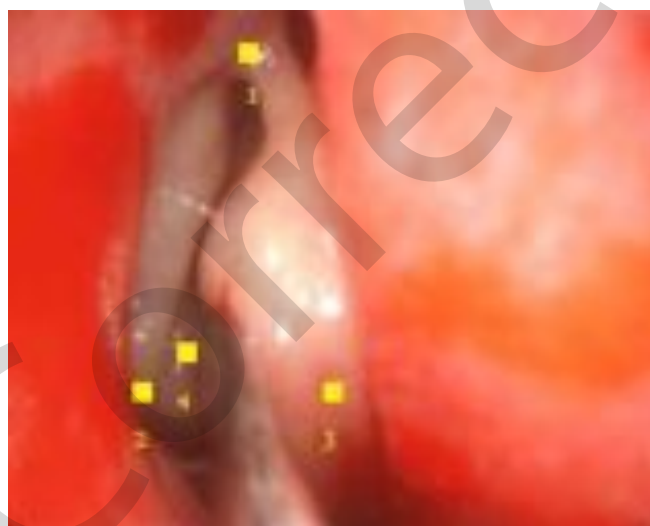

Figure 4. Basic points - landmarks in the Unit 2: OMC unit (right). 1 midturbinate attachment, 2 uncinete process, 3 midturbinate tip, 4 ethmoidal bulla.

point is at the highest point of the nares. This is the point where the lateral rim of the nares connects with the medial rim of the nares. The second point is located at the bottom of the ala of the nose. The third point is opposite to the second point, on the medial bottom of the nares, on the very base of the columella. These three points form a triangle. The fourth point is inside the triangle and is located on the anterior tip of the inferior turbinate (Figure 3).

#### Unit 2: OMC unit

The second unit represents the anatomical space where surgery begins. The ostiomeatal complex is the entrance to the ethmoid. The external points of this unit form a triangle. The first landmark is the superior point of the triangle, located on the highest point of the middle turbinate insertion. The second landmark is on the lowest part of the uncinete process insertion. The third landmark is medially to the anterior tip of the middle turbinate. The fourth landmark is the most prominent part of the anterior wall of the ethmoidal bulla (Figures 4 and 5).

#### Unit 3: Anterior ethmoid unit

As we go deeper inside the ethmoid, orientation is more difficult because the anatomy is more demanding and a collision with critical anatomical structures becomes possible. In this unit, critical anatomical structures such as the anterior skull base and or-

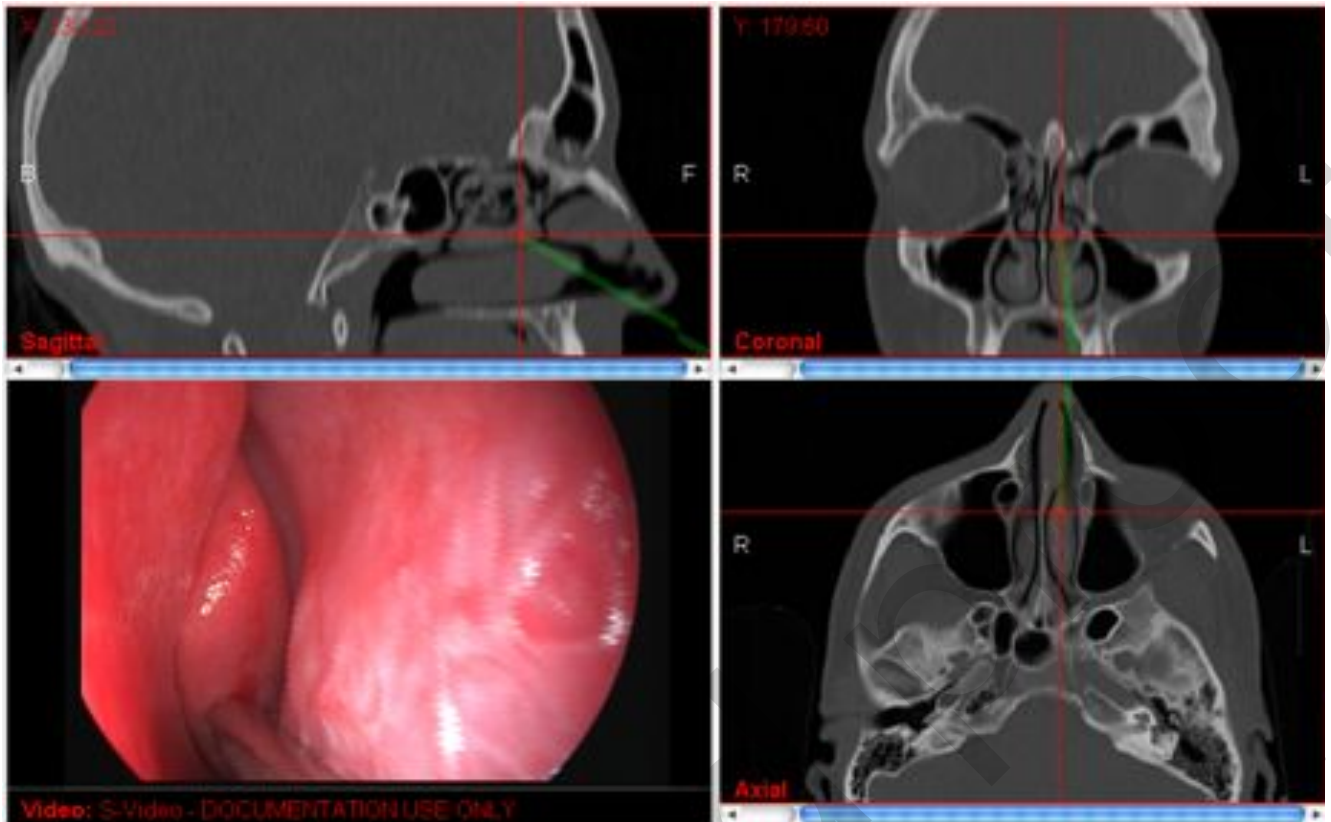


Figure 5. Unit 2 - OMC unit (left): Point 3 – midturbinates landmark.

bital wall should be marked. This triangular pyramid consists of three anterior landmarks. The first is the skull base point on the top of the pyramid. The second point is located on the lamina papyracea and is called the orbital landmark. The third is located medially at the lateral part of the middle turbinate. The fourth is inside this triangle located on the ground lamella. This landmark leads to the fourth unit, the posterior ethmoid unit.

Besides these basic landmarks, we should mark additional landmarks such as the natural maxillary ostium, frontal recess and anterior ethmoidal artery. In this unit, as some of the anatomical landmarks such as uncinat process and ethmoidal bulla can be removed during surgery, some additional points should be marked, e. g. the natural ostium of the maxillary and frontal sinuses and the anterior ethmoidal artery landmark.

As seven landmarks can be marked in this pyramid, this is the unit with the greatest number of marked points (Figure 6).

#### Unit 4: Posterior ethmoid unit

We enter the fourth unit, the posterior ethmoid unit, after removing the ground lamella. The first landmark is on the skull base, behind the ground lamella. The second is laterally, the lamina papyracea landmark. The third point is again medially, the superior turbinate landmark. The fourth point is inside this unit and is located on the deepest part of posterior ethmoidal cells, the

fovea sphenoidal landmark. Additional points are the Onodi cell landmark and posterior ethmoidal artery landmark (Figure 7).

#### Unit 5: Sphenoid unit

The sphenoid is the last unit that should be checked using the NESS algorithm as in basic ESS, this is the furthest point where surgery is performed. The first landmark is on the roof of the nose. The second landmark is the lateral junction of the vertical and horizontal border of the choana. The third landmark is medially, the junction of the septum and horizontal margin of the choana. The fourth point is the landmark of the anterior wall of the sphenoid. Additional landmarks are the natural sphenoid ostium, sphenopalatine artery and clivus (Figure 8).

#### Discussion

ESS is the most common surgical method performed in rhinology. CRS has remained the first indication for ESS. As CRS is an extremely prevalent rhinologic disorder, it is obvious that ESS is so common a procedure. The most common type of ESS, used to treat the majority of patients with CRS, is called basic ESS. Although the technique has been developed in many aspects, in terms of approach, invasiveness and instrumentation, the Messerklinger technique of ESS, as a surgery of five lamellas, still

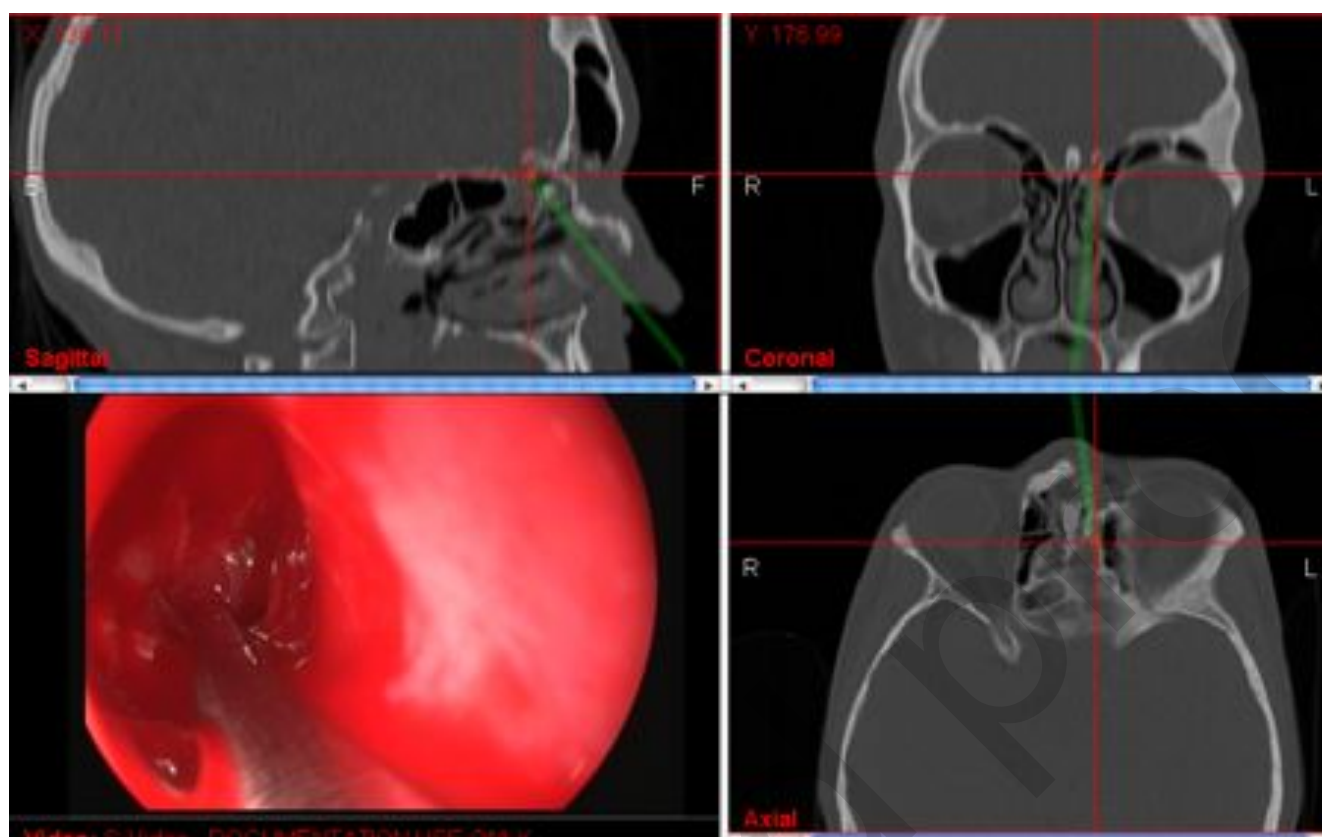


Figure 6. Unit 3 – Anterior ethmoid unit (left): Point 1 – skull base landmark.

remains the gold standard <sup>(1,2)</sup>.

In the beginning, there were many opponents to this technique. Many surgeons in the dawn of ESS rejected to recognize its importance, claiming that surgery should be radical even in the treatment of CRS <sup>(4)</sup>. In those days, this reaction was understandable and normal. Interestingly, despite the clear evidence in favour of endoscopic sinus surgery and a great number of skilled endoscopic sinus surgeons worldwide, some surgeons still prefer a radical surgical approach, claiming for instance for a Caldwell-Luc approach to treat antrochoanal polyps <sup>(5,6)</sup>. Since ethmoidectomy, as a cornerstone of the ESS concept, was historically considered „the easiest operation with which to kill a patient“, the safety issues have been considered since the very early days <sup>(7)</sup>.

The complication rate of ESS is very low. Major complications range from 0 to 1.5% and minor complications from 1.1% to 20.8% in surgical treatment of CRS with nasal polyps <sup>(8)</sup>. Nevertheless, major complications such as intracranial penetration, carotid lesion and eye injury still occur. Surgeons may find themselves lost, especially when faced with a distorted anatomy, severe disease, excessive bleeding or scars left over from previous surgery. Because of that, ESS is one of the greatest sources of litigation an otolaryngologist is faced with today <sup>(9,10)</sup>.

It has led to improvement in knowledge of the surgical anatomy

and recognition of dangerous anatomical areas, based on surgical experience and development of imaging techniques dedicated to better orientation for rhinosurgeons performing ESS. Improved imaging, like multi-slice CT with a 3D reconstruction has become broadly available. Fortunately for the trainees and inexperienced rhinosurgeons, it is a replacement for surgeon's experience from the past, when a 3D reconstruction, needed to improve safety, was done by surgeon himself, integrating coronal and axial images into spatial perception of sinus cavities needed for surgery <sup>(11,12)</sup>.

One of the most important improvements in contemporary ESS is the use of a navigation system. This type of ESS might be called Navigated Endoscopic Sinus Surgery (NESS). A navigation system enables surgeons to operate in a 3-dimensional fashion. The accuracy within 2 mm is generally acceptable. It allows enough precision and confident orientation within anatomical structures of the nose and paranasal sinuses <sup>(13)</sup>. So far, we have performed over hundred operations following this algorithm using a KARL STORZ optical navigation unit NPU. All used navigated instruments, produced by the KARL STORZ Company, are steam sterilizable and fully reusable leading to no additional costs when performing the navigated surgery.

By using a navigated probe in the so-called pointer-based

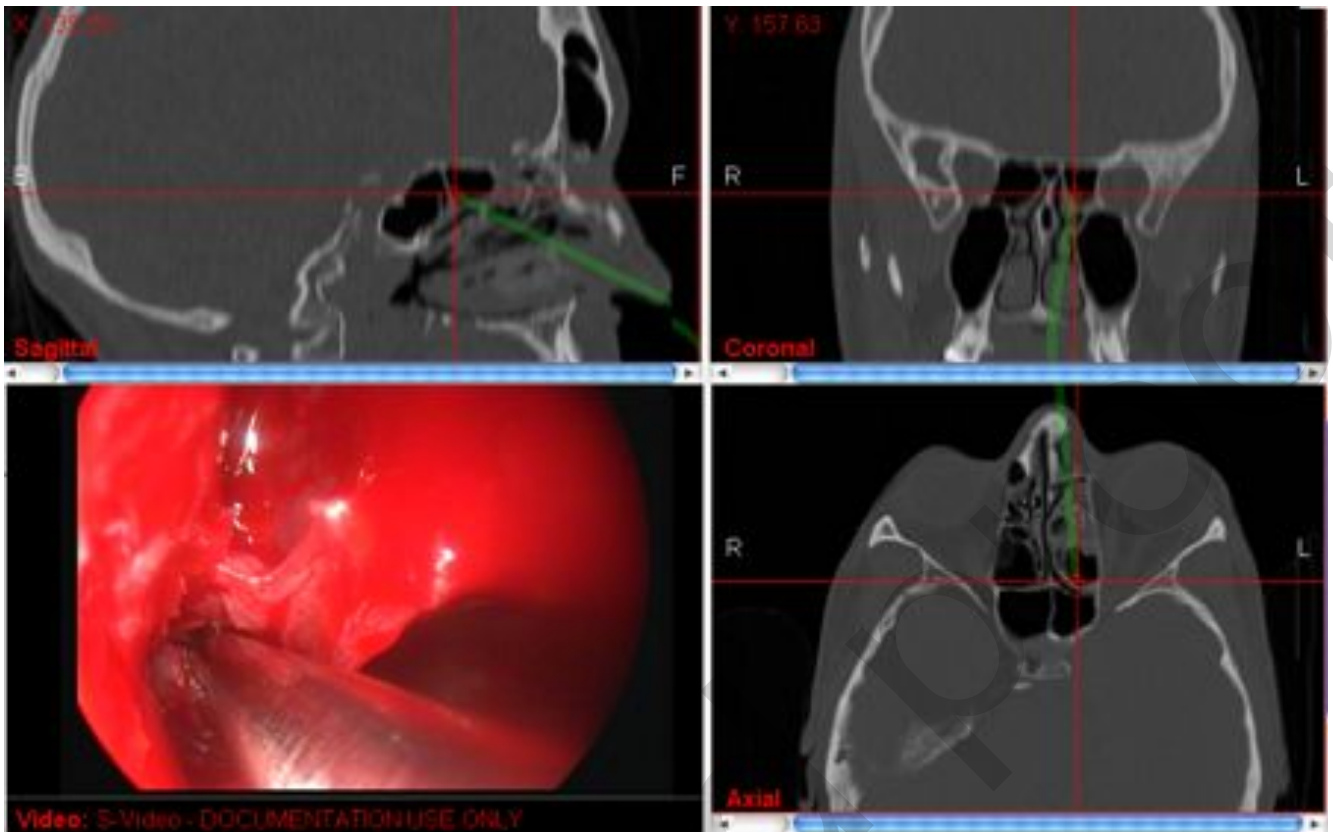


Figure 7. Unit 4 - Posterior ethmoid unit (left): Point 4 – fovea posterior landmark.

NESS, surgeons can orientate inside the operating field localizing anatomical and pathological structures. They can identify landmarks inside the paranasal sinus cavities and mark both anatomical and pathological structures. Step ahead of this kind of NESS is nowadays a possibility that any instrument can be used as a navigated pointer and the surgeon can track position of the navigated instruments during the entire surgery. Even a navigation-tracked shaver is applicable in modern NESS. In this way, surgeons avoid limitation of pointer-based NESS and improve attentiveness in any given situation, as well as in their cognitive workload<sup>(13,14)</sup>.

CT scans have been considered essential for the orientation in ESS. Unexpected anatomical variations have frequently influenced outcomes of ESS if CT scans were not seriously considered and reviewed prior to surgery. CT scans in two planes have often been compared with a roadmap for ESS. Modern navigation systems for ESS are comparable to the relationship between historical CT scanning in two plains, and MSCT with a 3D reconstruction. Nowadays, roadmaps are being replaced by satellite navigation systems, and parking by the highway to read the roadmap is a thing of the past.

Recent developments in navigation techniques and surgical equipment, which reduced technical errors and improved comprehensive use of imaging data during surgery, have tremendously improved safety of the endoscopic surgery, especially in difficult cases. This new technology facilitates surgery through

many advantages: a better visual display, augmentation of critical anatomical structures, better definition and visualization of landmarks, and safety check during surgery. Navigation systems can help surgeons to change their surgical strategy and facilitate decision-making during surgery<sup>(14,15)</sup>.

We may hypothesize that reduction of invasiveness and risk of major complications, due to a better orientation in narrow spaces, would lead to a higher safety and better outcomes. However, there is a lack of strong evidence in the literature for such statement.

Nevertheless, according to published data, the rate of complications is reduced to minimum, especially major complications such as cerebrospinal leak or blindness. Bleeding is more common than major complications, but intraoperative blood loss is significantly lower than in FESS performed without assistance of a navigation system<sup>(16,17)</sup>.

The use of a navigation system leads to reduced intraoperative time consumption, improvement of postoperative results and lowered workload of the surgeons<sup>(12)</sup>. Consequently, it could also reduce costs of the surgery.

There are some statements contrary to this, which can be found in the older literature. It could be explained by technological underdeveloped navigation systems at times when such studies were performed<sup>(18)</sup>.

The use of a navigation system helps surgeons to improve their training and education, but it does not replace the proper trai-

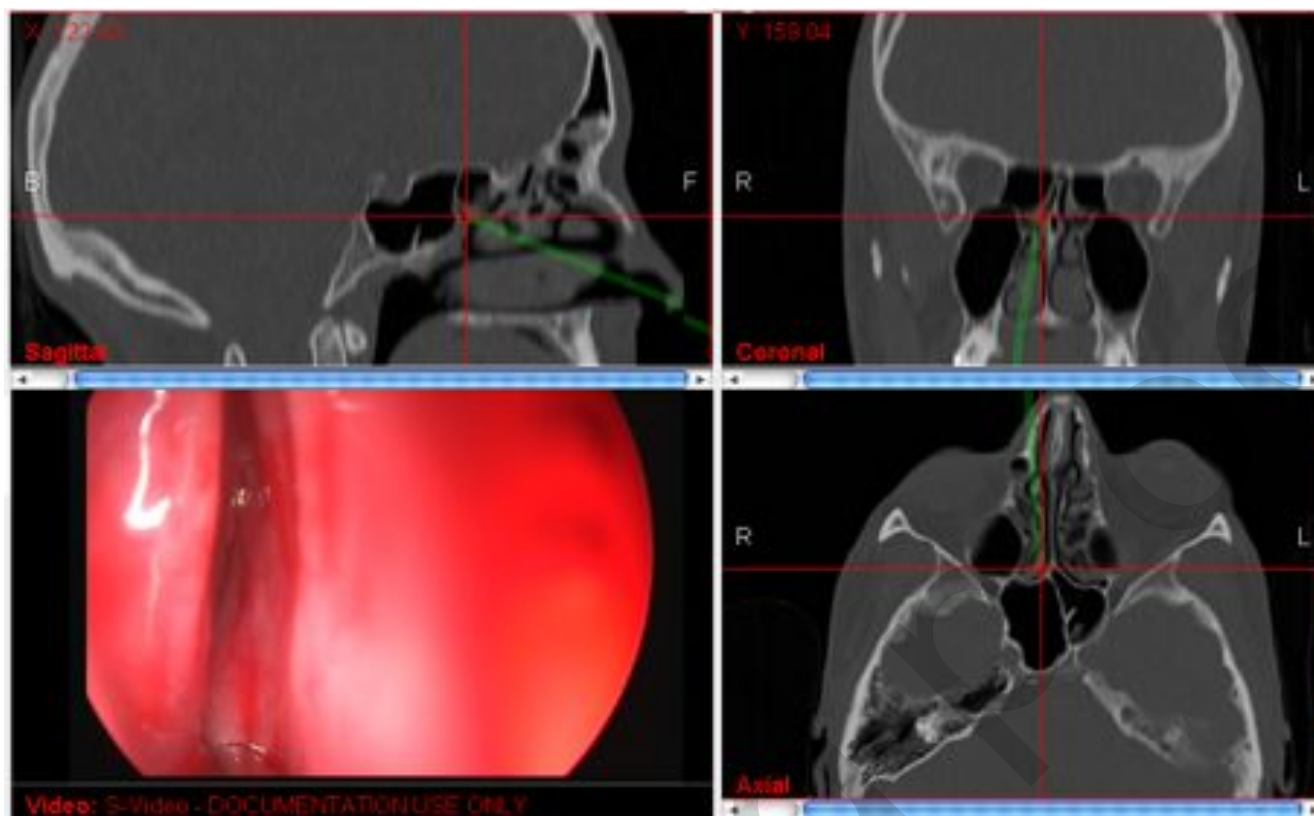


Figure 8. Unit 5 - Sphenoid unit (right): Point 4 – anterior sphenoidal wall.

ning. It is not a substitute for thorough anatomical knowledge, surgical skill and experience, but should rather be supportive of it<sup>(13)</sup>.

The navigation system is extremely helpful in cases with altered surgical anatomy, e.g. in revision surgery and cases of extensive inflammatory diseases such as massive polyposis, and in cases with tumours in the region of the nose and paranasal sinuses<sup>(17)</sup>. This statement leads to preoperative selection of indications for the use of navigation system. According to this statement about 20% of cases should be treated using this tool, and 80% of typical rhinological surgical material should not. The navigation system should be used only in the most complicated cases<sup>(19,20)</sup>. According to the general statement, navigation endoscopic surgery is of the highest value for more complex rhinological procedures. What we deem is that the navigation system should be used routinely in everyday surgery regardless of the indication. It is a tool of value in any case, even the easiest one, and for all surgeons performing ESS, even the most experienced. It should be used on a daily basis not just for selected severe pathology and not solely in special medical facilities.

There is evidence that intraoperative surgical navigation for ESS is useful in all surgical procedures: the simplest primary endoscopic surgery, revision surgery, osteoplastic frontal sinusotomy, transsphenoidal hypophysectomy, endoscopic cerebrospinal fluid leak repair, endoscopic pterygomaxillary fossa biopsy and surgery of neoplasms intruding endocranially or intraorbitally

<sup>(21)</sup>.

There are very few randomized controlled trials evaluating ESS, and none of them is placebo-controlled. There are no randomized controlled trials comparing efficacy, safety and time consumption between the cases using a navigation system vs. standard ESS. So, the level of evidence has been low so far. It is one of unmet needs to evaluate the efficacy of surgery in the treatment of chronic rhinosinusitis.

Until now, no algorithm has been published so far for the use of navigation in ESS.

The algorithm, here proposed, was primarily developed for teaching purposes, and it may seem more complicated than standard registration and calibration and use of the probe when a surgeon feels uncertain with his orientation. However, in our experience, operative time has not been increased, compared to random use of the probe. Safety of surgery is not primarily jeopardized by extension of pathology, but rather by an unfavorable anatomy and operating conditions. Our method needs to be validated in a multicentric study, in terms of time consumption, rate of errors caused by disorientation in a short-term, and improvement of a safety for lower complication rate on the long run.

The aim of the algorithm for basic ESS with the assistance of a navigation system is to facilitate surgeons to use a navigation system systematically in everyday practice, in all patients who

are candidates for ESS. Actually, this algorithm is conceived in the first place for treating patients with CRS performing basic ESS.

Many details of the algorithm have been changed in the meantime to make it more user friendly, more efficient and comprehensive. Now, this is a simple algorithm, easy to follow and apply by any surgeon. Our opinion is that the highest value of the algorithm is for trainees who are starting to learn how to perform NESS. This is contrary to the statement that image guidance should only be used by experienced endoscopists<sup>(18,19)</sup>.

In this way trainees would become familiar with the navigation system from the very onset of doing the sinus surgery. They would use it on a daily basis in any case. Later on, they will be able to perform faster and safer basic surgery and demanding surgical procedures such as advanced ESS and skull base ESS. Due to this, they will have no prejudice that the navigation system is just a tool for advanced surgery. The use of this algorithm will help them learn ESS in a faster way than by learning it without the navigation system. They will perform systematic navigation-assisted surgery, i.e. systematic navigated orientation, as well as systematic performing surgery. In this way, this algorithm will help surgeons grasp all advantages of NESS, such as decreased rate of complications, better surgical outcomes, reduced intraoperative time consumption and cutting costs. Besides, we should consider future perspective of NESS. Very soon there will be no endoscopic video tower without integrated navigation system. The prices of the equipment have been decreasing gradually, and will soon be affordable to a larger po-

pulation of surgeons. Further integration of navigated surgical instrumentation, the ability to update images intraoperatively and advancement in the real-time imaging and robotics are likely to continue at a rapid rate<sup>(22)</sup>. This algorithm could be of value to use ENT navigation routinely and systematically. In this way NESS could become the gold standard of ESS irrespective of indications.

### Authorship contribution

Clinical Department of Diagnostic and Interventional Radiology, Sisters of Mercy University Medical Center, Zagreb University School of Dental Medicine, Zagreb, Croatia.

TB - creator of the idea of the algorithm, performed NESS procedures, wrote the first version of the manuscript.

MVG - contributed to the design of the algorithm, performed NESS procedures testing algorithm.

DZ - radiologist who prepared MSCT scans for navigation and analyzed scans, contributed to the design of the algorithm.

GG - contributed to the design of the algorithm, performed NESS procedures testing algorithm.

DT - performed NESS procedures testing algorithm.

LK - senior author; contributed by advices to improve the algorithm and the manuscript.

### Conflict of interest

Tomislav Baudoin is head physician of the Training Center for Navigated Endoscopic Sinus Surgery, founded in the Dept. of ENT-HNS, Sisters of Mercy University Medical Center, Zagreb, in collaboration with Karl Storz Company.

### References

1. Stammberger H, Posawetz W. Functional endoscopic sinus surgery. Concept, indications and results of the Messerklinger technique, *Eur Arch Otorhinolaryngol.* 1990; 247: 63-76.
2. Kennedy DW, Zinreich SJ, Rosenbaum AE, et al. Functional endoscopic sinus surgery: Theory and diagnostic evaluation. *Arch Otolaryngol.* 1985; 111: 576-582.
3. Fokkens WJ, Lund VJ, Mullol J, et al. EPOS 2012: European position paper on rhinosinusitis and nasal polyps 2012. A summary for otorhinolaryngologists. *Rhinology* 50: 1-12, 2012.
4. Mabry RL. The case for the Caldwell-Luc procedure. *Am J Rhinol.* 1994; 8: 311-315.
5. Ibrahim SH. Evaluation of Caldwell-Luc approach for treatment of antrochoanal polyp. *Tikrit Med J.* 2010; 16: 92-97.
6. Barzilai G, Greenberg E, Uri N. Indications for the Caldwell-Luc approach in the endoscopic era. *J. Otolaryngol Head Neck Surg.* 2005; 219-220.
7. Mosher HP. The surgical anatomy of the ethmoidal labyrinth. *Ann Otolaryngol.* 1929; 38: 869-901.
8. Dalziel K, Stein K, Round A, et al. Endoscopic sinus surgery for the excision of nasal polyps: A systematic review of safety and effectiveness. *Am J Rhinol.* 2006; 20: 506-519.
9. Lund VJ, Wright A, Yiotakis J. Complications and medicolegal aspects of endoscopic sinus surgery. *J R Soc Med.* 1997; 90: 422-428.
10. Chu S-T. Endoscopic sinus surgery under navigation system - Analysis report of 79 cases. *J Chin Med Assoc.* 2006; 69: 529-533.
11. Isaacs S, Fakhri S, Luong A, Citardi MJ. Intraoperative imaging for otorhinolaryngology - head and neck surgery. *Otolaryngol Clin North Am.* 2009; 42: 765-779, viii.
12. Strauss G, Limpert E, Strauss M, et al. Evaluation of a daily used navigation system for FESS. *Laryngorhinootologie.* 2009; 88: 776-781.
13. Fried MP, Parikh SR, Sadoughi B. Image-guidance for endoscopic sinus surgery. *Laryngoscope.* 2008; 118: 1287-1292.
14. Strauss G, Hofer M, Fischer M et al. First clinical application of a navigation-controlled shaver in paranasal sinus surgery. *Surg Technol Int.* 2008; 17: 19-25.
15. Koulechov K, Strauss G, Dietz A, Strauss M, Hofer M, Lueth TC. FESS control: realization and evaluation of navigated control for functional endoscopic sinus surgery. *Computer Aided Surg.* 2006; 11: 147-159.
16. Strauss G, Koulechov K, Roettger S, et al. Evaluation of a navigation system for ENT with surgical efficiency criteria. *Laryngoscope.* 2006; 116: 564-572.
17. Olson G, Citardi MJ. Image-guided functional endoscopic sinus surgery. *Otolaryngol Head Neck Surg.* 2000; 123: 188-194.
18. Eliashar R, Sichel J-Y, Gross M et al. Image guided navigation system - a new technology for complex endoscopic endonasal surgery. *Postgrad Med J.* 2003; 79: 686-690.
19. Smith TL, Stewart MG, Orlandi RR, Setzen M, Lanza DC. Indications for image-guided sinus surgery: the current evidence. *Am J Rhinol.* 2007; 21(1): 80-83.
20. Smith TL, Batra PS, Seiden AM, Hannley M.



Evidence supporting endoscopic sinus surgery in the management of adult chronic rhinosinusitis: a systematic review. *Am J Rhinol.* 2005; 19: 537-543.

21. Citardi MJ, Batra PS. Intraoperative surgical navigation for endoscopic sinus surgery: rationale and indications. *Curr Opin Otolaryngol Head Neck Surg.* 2007; 15: 23-27.
22. Palmer JN, Kennedy DW. Historical perspective on image-guided sinus surgery. *Otolaryngol Clin North Am.* 2005; 38: 419-428.

Tomislav Boudoin, M.D., Ph.D.  
Department of Otorhinolaryngology  
& Head and Neck Surgery  
Sisters of Mercy University Medical  
Center  
Vinogradska c. 29  
HR-10000 Zagreb  
Croatia

Tel. +385-1-378 7155

Fax: +385-1-376 8293

E-mail: [tomislav.boudoin@gmail.com](mailto:tomislav.boudoin@gmail.com)