

Temporal bone pneumatization and its relationship to paranasal sinus development in cystic fibrosis*

Clarice M. Seifert¹, Richard J. Harvey², Joe W. Mathews¹, Ted A. Meyer¹, Chadwick Ahn¹, Brad A. Woodworth³, Rodney J. Schlosser¹

¹ Department of Otolaryngology - Head and Neck Surgery, Medical University of South Carolina, Charleston, South Carolina, USA

² Department of Otolaryngology - Skull Base Surgery, St Vincent's Hospital, Darlinghurst, Sydney, Australia

³ Department of Otolaryngology - Head and Neck Surgery, University of Alabama Birmingham, Alabama, USA

SUMMARY

Background: There is significant debate on the influence of inflammatory mucosal disease on paranasal sinus pneumatization (PSP) and temporal bone pneumatization (TBP) in cystic fibrosis patients (CF). It is often assumed that mucosal disease of the paranasal sinuses will negatively influence development and pneumatization of the paranasal sinuses and temporal bone system.

Methods: A case-control study of TBP and PSP in CF, chronic rhinosinusitis (CRS) and healthy control patients from a tertiary rhinology clinic. TBP and PSP were assessed by computed tomography (CT) using a previously validated scale. Genotype data for patients with CF was determined.

Results: In total, 186 temporal bones and paranasal sinuses from 93 adult patients were assessed through evaluation of CT scans. The patients had a mean age of 43.4 ± 14.9 yrs. The interobserver correlation for TB scoring was 0.86. TBP did not differ between CF, CRS and controls ($\chi^2 = 6.93$, $p = 0.38$). PSP was less in the CF group ($\chi^2 = 34.2$, $p < 0.001$) than the CRS and control groups. CRS and controls did not differ in PSP. 51.6% of CF patients were homozygous for $\Delta F508$ and 16.1% were heterozygous. The $\Delta F508$ status correlated with poorer SP ($\chi^2 = 34.2$, $p < 0.001$), but greater TBP ($\chi^2 = 14.9$, $p = 0.002$).

Conclusions: PSP is impaired in CF and $\Delta F508$ homozygosity is related to poor PSP. TBP is well preserved in the CF population and $\Delta F508$ homozygosity correlates with greater TBP, with the underlying mechanisms being unclear. Genotype might play a role in skull base pneumatization.

Key words: pneumatization, temporal bone, mastoid, paranasal sinus, genotype, chronic otitis, cystic fibrosis

INTRODUCTION

Cystic fibrosis (CF) is an autosomal recessive disease⁽¹⁾ affecting more than 30,000 individuals in the United States and most commonly affecting the Caucasian population (1 in 3200 live births)⁽²⁾. It is caused by defects in the gene found on chromosome 7 that encodes the cystic fibrosis transmembrane conductance regulator (CFTR) protein, a protein responsible for transport of chloride and other electrolytes across the cell membranes of epithelial cells. Defects in this protein results in the production of abnormally thick mucus by exocrine glands, with complications affecting many organs including the lungs, bile ducts, pancreas, paranasal sinuses, intestines, and male reproductive tracts^(2,3).

More than 1500 mutations have been associated with CF to date⁽⁴⁾. The most common mutation, $\Delta F508$, accounts for approximately 66% of the CFTR mutations⁽⁴⁾. This mutation results from the deletion of three base pairs encoding for a phenylalanine at the 508 position in the protein, with resultant misfolding of the protein. The improper folding of the proteins results in defective trafficking: the protein is not transported to the membrane and is subsequently degraded⁽⁵⁾.

Paranasal sinus disease in CF patients is well described, likely resulting from a combination of impaired mucociliary clearance, increased viscosity of the mucus with stasis, promotion

of goblet cell hyperplasia secondary to chronic inflammation with a decrease in ciliated cells, and local bacterial superinfections⁽⁶⁻⁸⁾. It has also been widely noted that paranasal sinus pneumatization (PSP) is also decreased in patients with CF in comparison to patients with other forms of chronic rhinosinusitis (CRS) and the general population⁽⁸⁾. Additionally, in a recent study by Woodworth et al., the association between CF, CRS, and hypoplastic paranasal sinuses was further explored, highlighting the relationship with $\Delta F508$ status and hypoplastic paranasal sinuses. They concluded that homozygotes for the $\Delta F508$ mutation had underdeveloped or abnormal paranasal sinuses in comparison to those patients with other CFTR mutations⁽⁸⁾. It is still unknown whether this result is an acquired characteristic secondary to an increased frequency of sinus infections and mucosal inflammation, or an intrinsic phenotypic expression of the $\Delta F508$ mutation on bone development.

Considering the increased prevalence of paranasal sinus disease, decreased mucociliary clearance in CF and known risk factors for middle ear disease, it would be reasonable to assume that patients with CF would also exhibit an increased incidence of middle ear disease and decreased temporal bone pneumatization (TBP). In fact, the opposite has been found to be true, with an incidence of otitis media in patients with CF no greater than the general population^(1,9-11). Additionally, unlike the underdeveloped paranasal sinuses seen in patients with CF, we have observed well-developed lateral skull base pneumatization (Figure 1). Todd et al. showed that the temporal bones of CF patients have larger than average pneumatiza-

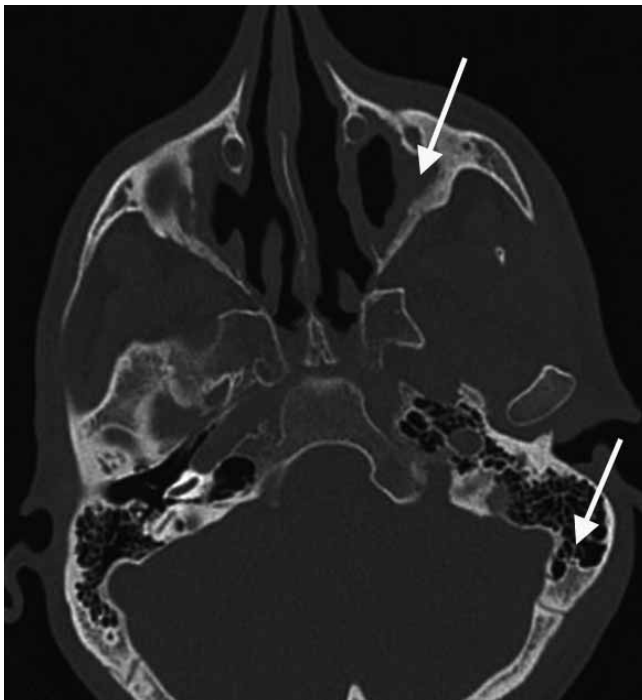


Figure 1. Axial CT scan with hypoplastic maxillary sinuses and extensive temporal bone pneumatization posterior to the sigmoid sinus in a patient with hypoplastic maxillary sinus.

Table 1. Demographics of cystic fibrosis patients, chronic rhinosinusitis patients, and control patients.

	Cystic Fibrosis	Chronic Rhinosinusitis	Control	Total
Total number	31	31	31	93
Mean Age	33.97±7.74	48.24±16.6	47.19±14.58	43.43±14.9
Minimum age	22.92	15.43	17.29	15.43

tion⁽¹²⁾. The reason for these findings, however, has yet to be determined. Arguments, given by Todd et al., suggest that chronic otitis media inhibits the growth of the mastoid air cells and that higher rates of antibiotic use in CF diminishes the potential effect of otitis media in CF. CF might also genetically predispose to greater aeration of the mastoid air cells or enhanced eustachian tube function thus resulting in larger than expected TBP⁽¹²⁾. More recent reports have found that mastoid air cells are actually involved in gas exchange and pressure maintenance of the middle ear, serving as a protective mechanism against otitis media⁽¹³⁻¹⁵⁾.

The objectives of the present study were to compare paranasal sinus pneumatization and temporal bone pneumatization in cystic fibrosis, chronic rhinosinusitis and healthy controls to explore the patterns of pneumatization in each population. In addition, the goal was to further investigate the role of genotype in the development of skull base pneumatization.

METHODS

Population

This study was a retrospective analysis of CT scans of 186 temporal bones and paranasal sinuses from patients with cystic fibrosis, CRS, and patients without CRS or CF (control group) treated at a tertiary rhinologic clinic from 1998 to 2006. Ninety-three adult patients with a mean age of 43.4 ± 14.9 years were included in the study, with 31 patients in each of the study groups (Table 1). Each patient represented two sinus systems ($n = 62$ for total sinuses in each group). Control patients were seen for non-sinus related complaints, primarily non-sinogenic headache. The study had approval from Institutional Research Board of the Medical University of South Carolina.

Outcomes assessment

Genetic testing was previously performed on the CF patient population to determine $\Delta F508$ status⁽⁸⁾. In the CF population, we evaluated PSP using a scale described by Woodworth et al. using CT scans and previously validated criteria⁽⁸⁾. Using these criteria, we analyzed the frontal, maxillary, and sphenoid sinuses in all three populations.

The frontal sinus was defined as aplastic with an absence of frontal bone pneumatization and hypoplastic with 1) an oval shaped sinus with the lateral margin medial to a vertical line

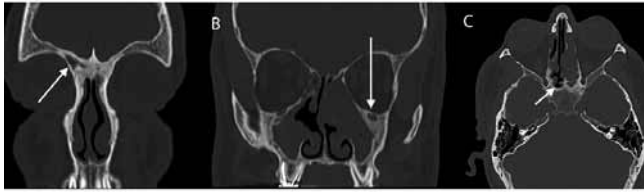

Figure 2. A: Coronal CT scan hypoplastic frontal sinuses. There is a complete absence of the left frontal sinus and the right frontal sinus is hypoplastic with the lateral margin medial to a vertical line drawn through the middle of the orbit (arrow). B: Coronal CT scan with hypoplastic maxillary sinuses. The maxillary sinuses meet four of the five necessary criteria, including an oval-shaped sinus, no pneumatization below the level of the nasal floor, the medial wall of the sinus lateral to a vertical line drawn tangentially to the medial orbital border, and the lateral extension of the medial to a vertical line drawn through the middle of the orbit at the level of the infundibulum (arrow). C: Axial CT scan with hypoplastic sphenoid sinuses with pneumatization limited anterior to the vertical plane of the tuberculum sellae (arrow). Note also the extensive temporal bone pneumatization despite poorly developed sphenoid sinuses.

drawn through the middle of the orbit, 2) with smooth superior margins, and 3) without intra-sinus septa (8) (Figure 2a).

The maxillary sinus was categorized as hypoplastic if four of the following five criteria were met: 1) an oval-shaped sinus, 2) an oval-shaped and enlarged orbit, 3) no pneumatization of the sinus below the level of the nasal floor, 4) the medial wall of the sinus was lateral to a vertical line drawn tangentially to the medial orbital border, and 5) the lateral extension of the sinus was medial to a vertical line drawn through the middle of the orbit at the level of the infundibulum⁽⁸⁾ (Figure 2b).

The sphenoid sinus was defined as hypoplastic if the following criteria were met: oval shaped sinus, pneumatization limited anterior to the vertical plane of the tuberculum sellae, and an absence of intra-sinus septa⁽⁸⁾ (Figure 2c).

Many methods analyzing TBP had previously been described, several of which required three-dimensional digital reconstructions for volumetric assessment^(12,16-18). The simplest criteria not requiring digital reconstruction with reliable reproducibility were previously described in a validated grading scale by Han et al.⁽¹⁷⁾.

The evaluation of pneumatization was performed using the sigmoid sinus as a reference structure at the level where the malleoincudal complex appeared as an ice-cream cone shape. Three parallel lines crossing the sigmoid sinus at the most anterior portion of the sigmoid sinus, the most lateral aspect of the sinus, and the most posterior point of the sinus were drawn at 45° in the anterolateral direction. TBP was classified as a [1] if air cells were not present or present only anterior to the anterior line, a [2] if air cells extended beyond the anterior line but not beyond the line through the lateral aspect of the sigmoid sinus, a [3] if the air cells extended beyond the line

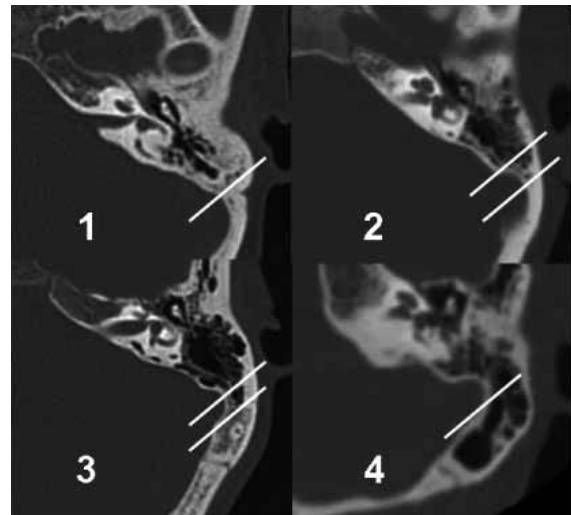


Figure 3. Axial CT scans demonstrating temporal bone pneumatization classification. At the level where the malleoincudal complex appeared as an ice-cream cone shape, three parallel lines were drawn crossing the sigmoid sinus at the most anterior portion of the sigmoid sinus, the most lateral aspect of the sinus, and the most posterior point of the sinus were drawn at 45° in the anterolateral direction. TBP was classified as a (1) if air cells were not present or present only anterior to the anterior line, a (2) if air cells extended beyond the anterior line but not beyond the line through the lateral aspect of the sigmoid sinus, a (3) if the air cells extended beyond the line through the most lateral aspect of the sigmoid sinus but not the most posterior line, and a (4) if the air cells extended beyond the most posterior line.

through the most lateral aspect of the sigmoid sinus but not the most posterior line, and a [4] if the air cells extended beyond the most posterior line⁽¹⁷⁾ (Figure 3).

Extent of mucosal disease was not included, as the Lund-McKay staging system does not reliably account for aplastic or hypoplastic sinuses such as those commonly seen in patients with cystic fibrosis. Although staging systems exist for the radiological changes in cystic fibrosis, they are not comparable to those used in CRS. Additionally, opacification of the sinuses is nearly a universal finding in CF patients⁽⁶⁾.

Assessors

A fellowship trained rhinologist and two additional assessors independently graded the CT scans. The assessors were blinded to genetic status of the patients, but not to their clinical situation.

Statistical analysis

The data were treated as ordinal outcomes. Cross tables were analyzed using a chi-squared analysis. Kruskal-Wallis one-way analysis of variance (ANOVA) yielded similar results but the grading scales are small and ordinal rather than numerical and thus Chi square statistical analysis is included only. Although left and right sinuses were recorded for each patient, repeated measures analysis was not used, as there was the same number

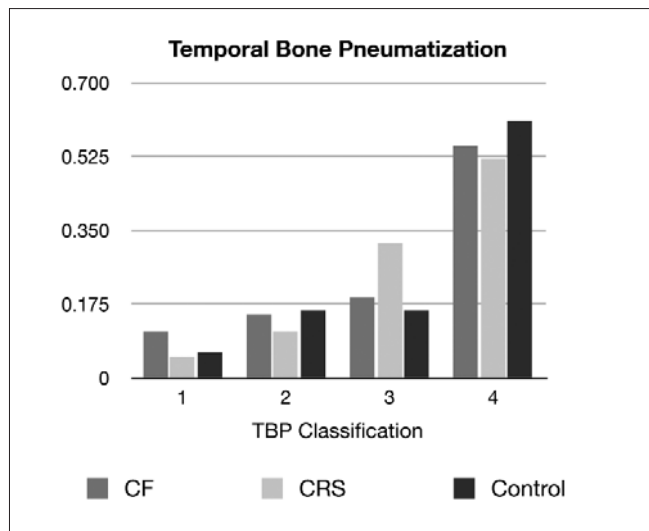


Figure 4. Graph of Temporal Bone Pneumatization in CF, CRS, and Control Groups. TBP did not differ between CF, CRS, and control groups ($\chi^2 = 6.93$, $p = 0.38$). Expressed as proportion of each group.

Table 2. Paranasal Sinus Pneumatization in CF, CRS, and Control Groups, shown as a percentage of each sinus per group (n = 62). 31 patients were in each group with 62 sinuses assessed in each group.

		CF	Group CRS	Control
Frontal	Aplasia	53%	5%	6%
	Hypoplasia	26%	15%	23%
	Normal	21%	81%	71%
Sphenoid	Hypoplasia	73%	5%	0%
	Normal	23%	95%	100%
Maxillary	Hypoplasia	45%	6%	5%
	Normal	55%	94%	95%

of patients in each group. Statistical significance was defined as $p \leq 0.05$. Statistical calculations were performed using the Statistical Package for the Social Sciences software (SPSS; Version 15.0; SPSS Inc., Chicago, IL, USA).

RESULTS

One hundred and eighty six temporal bones and paranasal sinuses from 93 adult patients were assessed (31 CF, 31 CRS, and 31 control patients) (Table 1). The interobserver correlation for TB scoring was 0.86. TBP did not differ between CF, CRS, and control groups ($\chi^2 = 6.93$, $p = 0.38$) (Figure 4). PSP was significantly less in the CF group ($\chi^2 = 34.2$, $p < 0.001$) than the other two groups (Table 2). Interestingly, CRS patients and the control group were not found to differ in PSP. Genetic studies found that 51.6% of CF patients were homozygous for $\Delta F508$ and 16.1% were heterozygous, and that $\Delta F508$ homozygosity was associated with poorer frontal sinus pneumatization ($\chi^2 = 33$, $p < 0.001$), maxillary sinus pneumatization ($\chi^2 = 34.7$, $p < 0.001$), and sphenoid sinus pneumatization ($\chi^2 = 24.9$, $p < 0.001$) (Table 3), but greater TBP ($\chi^2 = 14.9$, $p = 0.002$) (Figure 5).

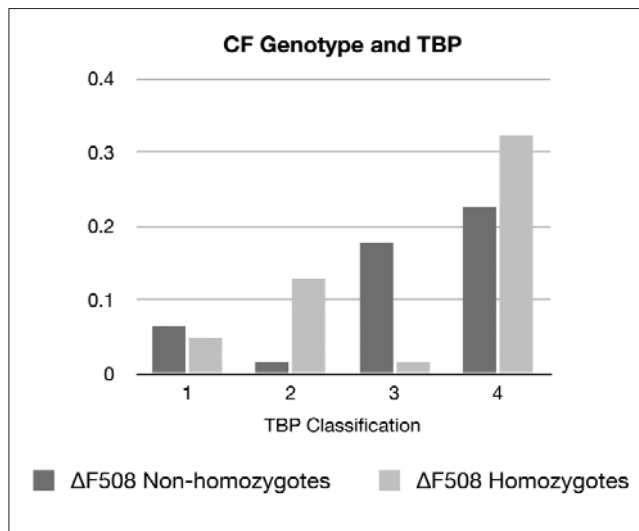


Figure 5. Graph of Temporal Bone Pneumatization in $\Delta F508$ Non-homozygotes vs. $\Delta F508$ Homozygotes. $\Delta F508$ homozygosity was associated with greater TBP ($\chi^2 = 14.9$, $p = 0.002$). Expressed as proportion of each genotype group.

Table 3. Paranasal Sinus Pneumatization in $\Delta F508$ Non-homozygotes (n = 30) vs. $\Delta F508$ Homozygotes (n = 32) of each group.

		CF $\Delta F508$ Non-homozygotes	Group CRS $\Delta F508$ Homozygotes
Frontal	Aplasia	17%	88%
	Hypoplasia	40%	12%
	Normal	43%	0%
Sphenoid	Hypoplasia	43%	100%
	Normal	57%	0%
Maxillary	Hypoplasia	7%	81%
	Normal	93%	19%

DISCUSSION

The most common mutation in CF is the $\Delta F508$. Homozygous $\Delta F508$ mutations with both similar and more severe clinical phenotype have been described^(19,20). Regarding patients with CF, however, it was shown by Woodworth et al. that homozygous $\Delta F508$ mutations lead to a decrease in PSP, suggesting that some mechanism other than mucosal inflammation, such as a genetic predisposition, is responsible for decreased PSP⁽⁸⁾. Those patients with CF were found to have a decrease in PSP, while those non CF patients with CRS had average PSP when compared to the control group. Homozygous $\Delta F508$ patients had significantly poorer PSP than other CF patients, suggesting that $\Delta F508$ homozygosity might be a predisposing factor for poor PSP or possibly more severe mucosal disease during paranasal sinus development.

As previously noted by Todd, there is a surprising increase in TBP associated with CF⁽¹²⁾. Otitis media and middle ear complaints are not more common in the CF population. Contrary to common belief by the non-otolaryngologic medical community, we were not able to determine a significant underdevelopment of the temporal bone air cell system in CF compared to

CRS and control groups. We were able, however, to identify an association between $\Delta F508$ homozygosity and an increase in TBP, suggesting a possible genetic influence in the extent of TBP. This observation contradicts the belief that severe inflammatory mucosal disease of the paranasal system during development of the temporal and mastoid air cell system will affect pneumatization. The influence of genetics on TBP might result from a direct effect on the function of the mastoid air cell mucosa, with changes in gas exchange and pressure from the presence of the CFTR abnormality.

There are distinct differences between the structure and function of the mucosal linings of paranasal sinuses and the mastoid air cells. The paranasal sinuses are lined with ciliated respiratory epithelium and goblet cells, requiring a delicately balanced mucous layer that allows the cilia to clear bacteria from the sinuses. The mastoid air cells, on the other hand, are lined with a single layer cuboidal respiratory epithelium with sparse ciliated and goblet cells and a thin fluid layer superposed. This single layer of cells is highly vascular, functioning as a gas exchange unit, much like the alveoli in the lungs. This gas exchange has been shown to play a critical role in temperature and pressure regulation within the inner and middle ear⁽¹³⁾. It is possible that a disruption of the mucosal lining of the mastoid air cells secondary to the defective CFTR results in a compensatory expansion of pneumatization, potentially from alterations in gas exchange and subsequent pressure changes.

The influence of surgery early in life is not assessed in this study. No CF patients had ESS prior to the first growth spurt but some had ESS prior to the second growth spurt. While anecdotal reports are made of hypoplastic changes after sinus surgery^(21,22), retrospective and prospective cohorts have not demonstrated significant changes to facial or sinus development⁽²³⁻²⁵⁾. Many of our CF patients have had prior sinus surgery and the influence of this may influence overall sinus development but there is limited data to support this.

Additionally, structural changes to the skull base can be observed in those patients with polypoid mucosa that occurs early in childhood. Remodeling of the septum, middle turbinate and orbital wall are common findings. Many of these changes lead to medial maxillary wall bulging with remodeling and 'pseudomucocele' formation are likely to underestimate any assessment of sinus hypodevelopment⁽²⁶⁾. Changes to the nasal airway and decreased paranasal sinus ventilation might also lead to greater pressure buffering in the temporal bones. There is also a possibility that a bias occurred in the sample of either the CF patients or the control group. Paranasal sinus and temporal bone pneumatization have been shown to be age and gender dependent⁽²⁷⁾. The CF group is a younger population (33.97 ± 7.74 yrs) but this was a relatively older group of CF patients in this study with $>2SD$ or 95% of the population older than 18 years. The influence of age related sinus development may influence the outcome but to a limited degree. Todd et al., however, studied a much younger cohort, where

TBP may have been ongoing, and still found a similar relationship between CF and TBP⁽¹²⁾. They had speculated that genetic typing may demonstrate an association but did not have the genetic markers easily available to them 20 years ago. The dramatic increase in TBP in homozygous $\Delta F508$ strongly suggests that $\Delta F508$ homozygosity predisposes patients to have increased TBP.

CONCLUSION

PSP is significantly impaired in CF and $\Delta F508$ homozygosity is related to poor development. Conversely, TBP is well preserved in the CF population and suggested that $\Delta F508$ homozygosity might even code for enhanced TBP through an unknown mechanism. The results challenge that clinical dictum that paranasal sinus disease during development leads to impaired temporal bone development. Future in vitro studies to examine the role of CFTR in both the paranasal sinus mucosa and the mastoid air cells may help to further elucidate the mechanisms involved in their pneumatization.

CONFLICT OF INTEREST STATEMENT

No external funding was received. Dr. Harvey has served on an advisory board for Schering Plough and has received grant support from NeilMed. Dr. Schlosser receives grant support from the Flight Attendant Medical Research Institute, NeilMed, and Xoran. Dr. Schlosser is a consultant for BrainLAB, Medtronic Xomed, Gyru, and Schering Plough and serves on the speaker's bureau for GlaxoSmithKline.

Dr. Mathews, Dr. Meyer, Dr. Ahn, Dr. Woodworth and Dr. Seifert have no financial interests to declare.

IRB STATEMENT

The study was approved by the institutional review boards of the Medical University of South Carolina and St Vincent's Hospital.

REFERENCES

1. Bak-Pedersen K, Larsen PK. Inflammatory middle ear diseases in patients with cystic fibrosis. *Acta Otolaryngol Suppl.* 1979; 360: 138-140.
2. Boyle MP. Adult Cystic Fibrosis. *JAMA.* 2007; 298: 1787-1793.
3. Gershman AJ, Mehta AC, Infeld M, Budev MM. Cystic fibrosis in adults: an overview for the internist. *Cleve Clin J Med.* 2006; 73: 1065-1074.
4. Cystic Fibrosis Genetic Analysis Consortium.
5. Cheung JC, Deber CM. Misfolding of the Cystic Fibrosis Transmembrane Conductance Regulator and Disease. *Biochemistry.* 2008; 47: 1465-1473.
6. Gysin C. Sinonasal disease in cystic fibrosis: Clinical characteristics, diagnosis, and management. *Ped Pulmonol.* 2000; 30: 481-489.
7. Matsui H, Grubb BR, Tarran R, et al. Evidence for periciliary liquid layer depletion, not abnormal ion composition, in the pathogenesis of cystic fibrosis airways disease. *Cell.* 1998; 95: 1005-1015.
8. Woodworth BA, Ahn C, Flume PA, Schlosser RJ. The delta F508 mutation in cystic fibrosis and impact on sinus development. *Am J Rhinol.* 2007; 21: 122-127.
9. Jorissen M, De Boeck K, Feenstra L. Middle ear disease in cystic fibrosis. *Int J Pediatr Otorhinolaryngol.* 1998; 43: 123-128.

10. Ozçelik T, Ozgirgin N, Ozçelik U, Göçmen A, Gürcan B, Kiper N. Ear, nose and throat findings in cystic fibrosis patients. *Turk J Pediatr.* 1997; 39: 51-54.
11. Yildirim N, Sone M, Mutlu C, Schachern PA, Paparella MM, Le CT. Histopathologic features of the temporal bone in patients with cystic fibrosis. *Arch Otolaryngol Head Neck Surg.* 2000; 126: 75-78.
12. Todd NW, Martin WS. Temporal bone pneumatization in cystic fibrosis patients. *Laryngoscope.* 1988; 98: 1046-1049.
13. Magnuson B. Functions of the mastoid cell system: auto-regulation of temperature and gas pressure. *J Laryngol Otol.* 2003; 117: 99-103.
14. Sade J, Fuchs C. Secretory otitis media in adults: II. The role of mastoid pneumatization as a prognostic factor. *Ann Otol Rhinol Laryngol.* 1997; 106: 37-40.
15. Sade J, Fuchs C. Secretory otitis media in adults: I. The role of mastoid pneumatization as a risk factor. *Ann Otol Rhinol Laryngol.* 1996; 105: 643-647.
16. Görür K, Özcan C, Talas DÜ. The computed tomographical and tympanometrical evaluation of mastoid pneumatization and attic blockage in patients with chronic otitis media with effusion. *Int J Pediatr Otorhinolaryngol.* 2006; 70: 481-485.
17. Han SJ, Song MH, Kim J, Lee WS, Lee HK. Classification of temporal bone pneumatization based on sigmoid sinus using computed tomography. *Clin Radiol.* 2007; 62: 1110-1118.
18. Isono M, Murata K, Azuma H, Ishikawa M, Ito A. Computerized assessment of the mastoid air cell system. *Auris Nasus Larynx.* 1999; 26: 139-145.
19. Borgo G, Gasparini P, Bonizzato A, Cabrini G, Mastella G, Pignatti PF. Cystic fibrosis: the delta F508 mutation does not lead to an exceptionally severe phenotype. A cohort study. *Eur J Pediatr.* 1993; 152: 1006-1011.
20. Jorissen MB, De Boeck K, Cuppens H. Genotype-phenotype correlations for the paranasal sinuses in cystic fibrosis. *Am J Respir Crit Care Med.* 1999; 159: 1412-1416.
21. Kosko JR, Hall BE, Tunkel DE. Acquired maxillary sinus hypoplasia: a consequence of endoscopic sinus surgery? *Laryngoscope.* 1996; 106: 1210-1213.
22. Levine SB, Mitra S. Maxillary sinus involution after endoscopic sinus surgery in a child: a case report. *Am J Rhinol.* 2000; 14: 7-11.
23. Senior B, Wirtschafter A, Mai C, Becker C, Belenky W. Quantitative impact of pediatric sinus surgery on facial growth. *Laryngoscope.* 2000; 110: 1866-1870.
24. Bothwell MR, Piccirillo JF, Lusk RP, Ridenour BD. Long-term outcome of facial growth after functional endoscopic sinus surgery. *Otolaryngol Head Neck Surg.* 2002; 126: 628-634.
25. Van Peteghem A, Clement PAR. Influence of extensive functional endoscopic sinus surgery (FESS) on facial growth in children with cystic fibrosis. Comparison of 10 cephalometric parameters of the midface for three study groups. *Int J Pediatr Otorhinolaryngol.* 2006; 70: 1407-1413.
26. Brihaye P, Jorissen M, Clement PA. Chronic rhinosinusitis in cystic fibrosis (mucoviscidosis). *Acta Otorhinolaryngol Belg.* 1997; 51: 323-327.
27. Spaeth J, Krügelstein U, Schlöndorff G. The paranasal sinuses in CT-imaging: Development from birth to age 25. *Int J Pediatr Otorhinolaryngol.* 1997; 39: 25-40.

Richard J. Harvey, MD
 Department of Otolaryngology / Skull Base Surgery
 St Vincent's Hospital
 Victoria St, Darlinghurst
 Sydney NSW 2010
 Australia

Tel: +61-2-9360 4811 (office)
 Fax: +61-2-9360 9919
 E-mail: richard@richardharvey.com.au