

Endoscopic management of frontal sinus mucoceles with anterior table erosion*

Bradford A. Woodworth^{1,3}, Richard J. Harvey^{2,4}, Jeffrey G. Neal²,
James N. Palmer¹, Rodney J. Schlosser²

¹ Department of Otorhinolaryngology-Head and Neck Surgery, University of Pennsylvania, Philadelphia, Pennsylvania, USA

² Department of Otolaryngology-Head and Neck Surgery, Medical University of South Carolina, Charleston, South Carolina, USA

³ Division of Otolaryngology - Head and Neck Surgery, Department of Surgery, University of Alabama at Birmingham, Birmingham, AL, USA

⁴ Department of Otorhinolaryngology - Head and Neck Surgery, St. Vincent's Hospital, Sydney, NSW, Australia

SUMMARY

Objective: To describe the endoscopic management of frontal sinus mucoceles with anterior table erosion. Previous hardware exposure and subsequent contour defects were also assessed.

Design: Retrospective case series.

Methods: Thirty-seven patients (mean 48 yrs, range 20-78) with frontal sinus mucoceles and anterior table erosion, endoscopically managed in a tertiary care setting, were reviewed. The demographic data, defect size, surgical technique, presence of exposed hardware, outcomes, and clinical follow-up were collected for outcome assessment

Results: The average follow-up was 32.6 months (range, 6 – 73). The overall long-term success rate with our initial endoscopic approach was 92% (34/37). The average size of anterior table defects was 181 mm² (4 – 1155). Twelve patients had prior osteoplastic flaps (OPF) with obliteration and 57% (21/37) had previous endoscopic sinus surgeries. Ten patients with prior OPF operations had hardware exposed within the sinus from previous surgeries. Two patients eventually required an OPF with fat obliteration. Most defects were either unnoticeable or cosmetically acceptable to the patients. Only one patient required a contouring plate six months after the procedure. Ninety percent of patients were successfully managed with exposed hardware left in situ.

Conclusions: Endoscopic marsupialization of frontal sinus mucoceles with anterior table erosion has a high success rate with a good cosmetic outcome, often without routine reconstruction. Revision cases and those with exposed hardware did not prevent successful management.

Key words: frontal sinus, mucocele, endoscopic sinus surgery, frontal sinusotomy, Draf, reconstruction

INTRODUCTION

Paranasal sinus mucoceles occur most frequently in the frontal sinus where they often present with frontal headache and proptosis⁽¹⁾. Diplopia may also be present if the globe is displaced downward and outward⁽²⁾. Frontal mucoceles on computed tomography (CT) scan usually appear as an expansile, airless sinus filled with homogeneous material. Different degrees of thinning and erosion of surrounding bone occurs. CT imaging is important in determining the extent of these lesions, the degree of bony erosion and for surgical planning. Once anterior table erosion occurs, the mucocele will expand into the soft tissue of the forehead and may present with a significant cosmetic deformity. There is an added layer of complexity when hardware from previous trauma, open frontal sinus surgery, or neurosurgical procedures are present⁽³⁾.

Erosion and expansion of the mucocele will often follow the path of least resistance along prior osteotomies, fractures, or through contouring plates. Exposed hardware within the sinus lumen, especially in the presence of infection, has traditionally been managed with removal and/or soft tissue covering.

There are a variety of surgical options available to treat frontal sinus mucoceles. The osteoplastic flap with frontal sinus obliteration with fat has been the historical gold standard operation, particularly in cases involving anterior or posterior table erosion, fistulas, osteomyelitis, or intracranial infection⁽⁴⁾. Frontal sinus mucoceles are known to reoccur in these complicated cases and therefore this radical procedure has been advocated for their management. The open surgical approach allows direct access for the placement of a contouring plate on an anterior table erosion to help minimize cos-

metic deformity. However, frontal sinus obliteration can still fail in 5-10% of cases^(4,6). Obliterative procedures are also associated with paresthesias, recurrent pain of the frontal area, and facial scars⁽⁴⁾. Imaging and follow up is often complicated if an obliterative procedure has been performed^(4,7).

With the introduction of nasal endoscopes, endosurgical instruments, and image-guided surgical navigation, there is a trend toward endoscopic management of frontal sinus mucoceles^(2,3,8-17). Endoscopic marsupialization drains the frontal sinus into the nose and enables direct endoscopic visualization during clinical follow-up. Furthermore, the ability to accurately image the sinus by CT scan is also preserved. While draining frontal sinus mucoceles with anterior table erosion via an endoscopic approach may potentially avoid external incisions and undue morbidity, subsequent cosmetic deformity, in the absence of reconstruction, has not been well documented.

This study reviews the outcomes of patients with frontal sinus mucoceles and anterior table erosion who underwent transnasal endoscopic drainage. The potential for long-term salvage of revision cases, the ability to leave hardware in situ and the cosmetic outcome in the absence of primary reconstruction is also assessed.

MATERIALS AND METHODS

Study Design

A retrospective case series of patients with frontal sinus mucoceles and anterior table erosion treated by the senior authors at the University of Pennsylvania and Medical University of South Carolina from 2001 to 2006 were assessed. All cases were performed at either at the Hospital of the University of Pennsylvania or the Medical University of South Carolina. The electronic medical record was reviewed in order to obtain the following data: age, gender, number of previous surgeries, etiology and site of erosion, size of defect, peri and

post-operative morbidity, surgical technique, presence of exposed hardware, outcomes, and clinical follow up. Institutional IRB approval was granted prior to the initiation of the study.

Operative technique

Triplanar CT assessment of frontal recess anatomy was undertaken to ensure an understanding of the maximal dimensions of the subsequent frontal sinusotomy. Magnetic Resonance Imaging (MRI) was often used in cases of prior sinus obliteration (Figure 1). The majority of the cases were revision procedures or had altered anatomy. Image guidance surgery (IGS) was used in all of these cases. All air cells encroaching on the frontal sinus outflow tract, such as agger nasi cells antero-laterally or suprabullar cells posteriorly, were removed in their entirety to increase the chance of long-term frontal patency. All endoscopic frontal recess dissections were performed with 45 or 70 degree 4 mm nasal endoscopes for visualization. If there was little neosteogenesis present, the frontal recess was dissected with frontal sinus hand instruments. We paid careful attention to preserving the mucosa surrounding the outflow tract to help increase long term patency. In cases with abundant neosteogenesis, a 70-degree diamond burr was also utilized during the dissection. An intraoperative decision was made to extend the operation to a Draf IIB or Draf III procedure⁽¹⁸⁾ when the drill was used. If the patient had a prior osteoplastic flap with obliteration, a Draf III⁽¹⁸⁾ was performed to unobliterate the frontal sinuses (Figure 2). Post-operative care occurred in clinic at 1, 2, and 4 weeks postoperatively, with subsequent debridements dependent on the appearance of the opening. A soft silastic stent was often used and removed at the first postoperative visit.

No patient received a primary reconstruction of the anterior table defect. Surveillance for cosmetic deformity following drainage of the mucocele was undertaken. If a noticeable

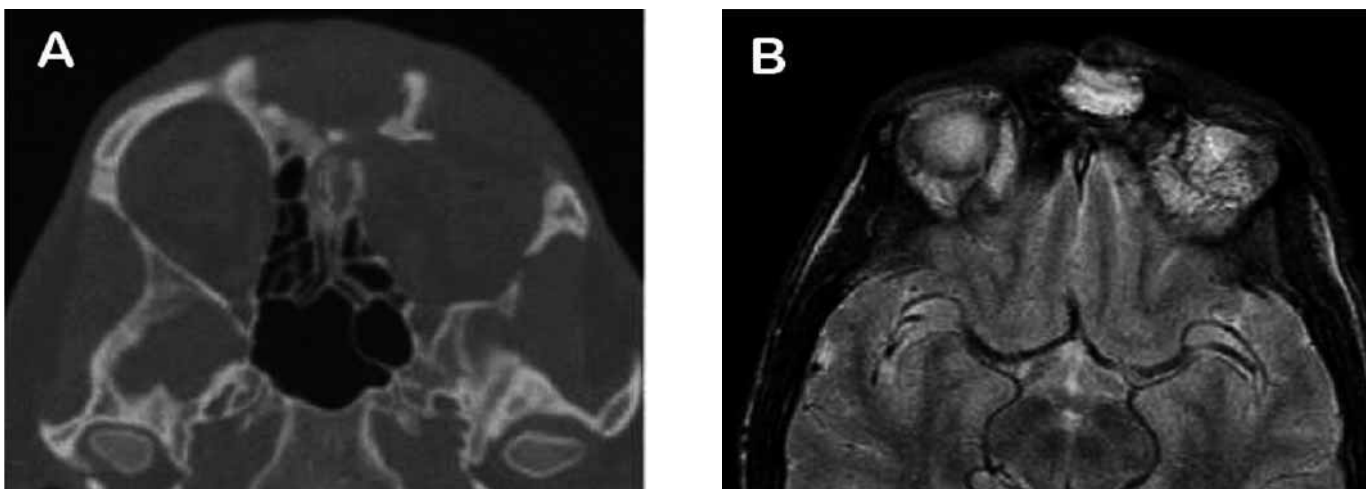


Figure 1. This figure demonstrates how CT and MR imaging are complementary for the evaluation of frontal sinus mucoceles. Although anterior table erosion is evident on the CT scan (A) it is unclear what component of the soft tissue is mucocele and what is fat from the prior obliteration. The axial MRI T2 weighted image (B) clearly demonstrates the confines of the mucocele.

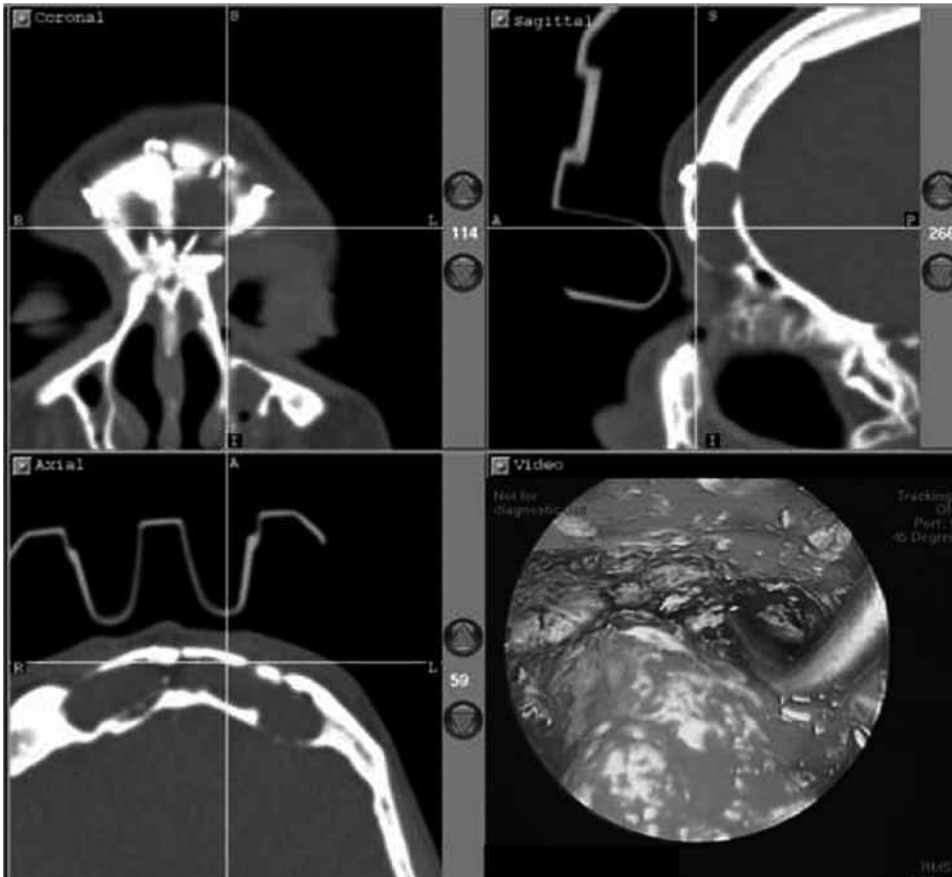


Figure 2A. Triplanar CT imaging and 70-degree endoscopic view of the blocked frontal recess in a patient with a frontal sinus mucocele.

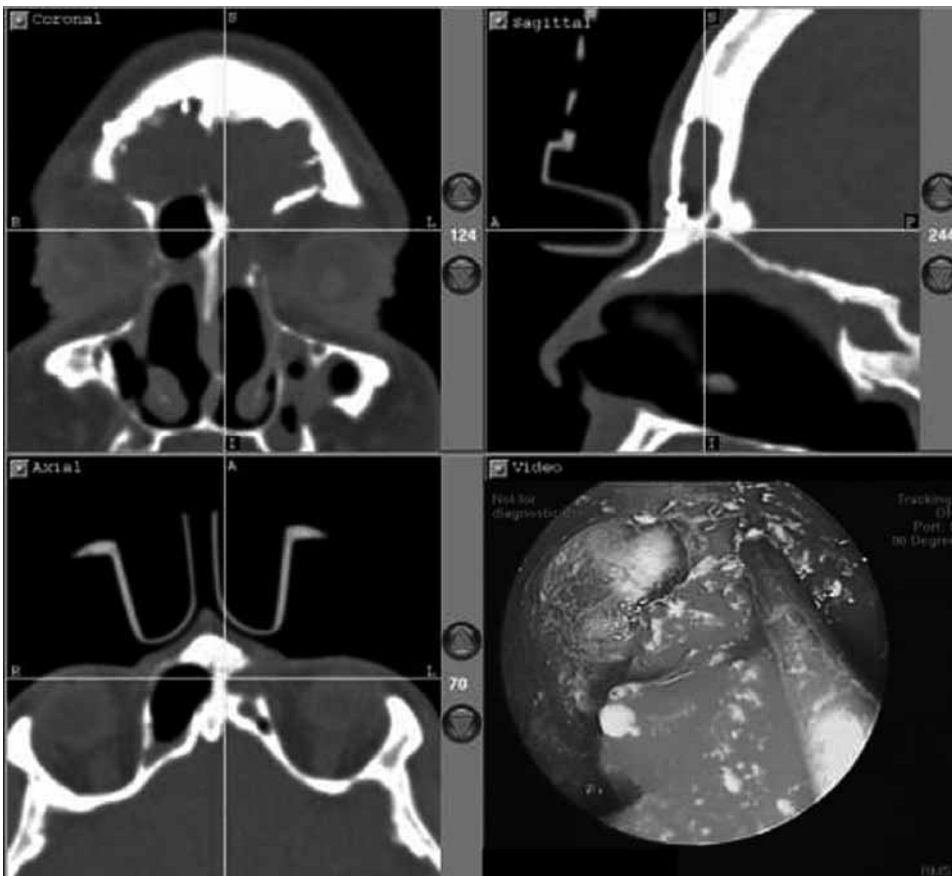


Figure 2B. A Draf III unobliteration procedure was performed in this patient. The anterior table erosion is evident on triplanar imaging and endoscopic view.

Table 1. Patients with frontal sinus mucoceles with anterior table erosion.

Pt	Sex	Age	Prior Surgeries	Treatment	Hardware	F/U	Defect (mm)
1	F	20	Endo x 3, OPF with FSO	Draf III	Yes	53	20 x 10
2	M	68	OPF with FSO	Draf III	Yes	35	10 x 10
3	F	56	Endo x 2	Draf IIA	No	35	2 x 2
4	F	72	OPF with FSO x 2	Draf III, OPF with FSO (Fat)	No	57	2 x 2
5	F	45	Neurosurgery craniotomy	Draf III x 2, OPF with FSO (Fat)	Yes	53	3 x 3
6	M	43	None	Draf III with OPF without FSO	No	53	3 x 3
7	F	78	Endo x 2	Draf IIA	No	53	10 x 10
8	M	63	Endo x 1, OPF with FSO	Draf III	Yes	59	20 x 10
9	M	46	Endo x 1, OPF with FSO	Draf IIA with trephine, Draf III	Yes	73	20 x 10
10	M	36	Endo x 1	Draf IIA	No	62	3 x 3
11	M	42	Trephine	Draf IIA	No	65	10 x 10
12	F	68	Endo x 1	Draf IIA	No	62	10 x 15
13	F	20	Craniofacial surgeries x 10, Endo x 1 with trephine	Draf IIA with trephine	No	48	10 x 17
14	M	35	Endo x 1, OPF with FSO x 2	Draf III	Yes	43	17 x 19
15	M	53	None	Draf IIA	No	38	2 x 5
16	M	44	OPF with FSO (Fat)	Draf III	Yes	34	11 x 6
17	M	48	Draf III	Draf III	Yes	37	7 x 5
18	M	30	OPF with FSO (Hydroxyapatite)	Draf III with trephine	No	29	18 x 11
19	F	42	Endo x 6, OPF with FSO x 2 (Fat)	Draf III	No	6	20 x 20
20	F	50	Trephine	Draf III	No	6	20 x 30
21	F	40	Endo x1, Trephine	Draf IIA	No	7	4 x 5
22	F	50	Endo x 1, Trephine	Draf IIB	No	8	4 x 4
23	M	77	None	Draf IIA	No	8	5 x 7
24	F	53	Endo x 2, Trephine	Draf III	No	7	5 x 5
25	M	42	Endo x 4	Draf IIA	No	22	25 x 12
26	M	38	Endo x 6, OPF with FSO x 1 (Fat)	Draf III	Yes	41	7 x 10
27	M	66	Endo x 3	Draf IIA	No	33	17 x 12
28	M	68	Endo x 2	Draf IIA	No	28	4 x 7
29	M	24	None	Draf IIA	No	23	2 x 2
30	M	38	Endo x 3	Draf IIA	No	24	15 x 19
31	M	58	OPF with FSO x 2 (fat)	Draf III	No	19	13 x 5, 11 x 5
32	M	44	Endo	Draf IIA	No	9	20 x 24
33	M	41	None	Draf IIA	No	9	10 x 10
34	M	38	Endo x 3	Draf IIA	No	23	25 x 12
35	M	38	None	Draf IIA	No	7	15 x 24
36	M	71	GSW	Draf III	No	7	21 x 23
37	M	39	OPF with FSO (silicone implant)	Draf III	Yes	30	33 x 35

Key: M, male; F, female; OPF, Osteoplastic flap; FSO, Frontal sinus obliteration; Endo, endoscopic sinus surgery; GSW, gunshot wound to the forehead; F/U, follow-up.

depression in their forehead developed, they were given the option of a coronal flap or Lynch incision approach for placement of an anterior table reconstruction mesh/plate once the frontal outflow tract was well healed.

RESULTS

Thirty-seven patients with frontal sinus mucoceles with anterior table erosion were treated using endoscopic techniques (Table 1). There were 25 males and 13 females with an average age of 48 years old (age range, 20-78 yrs). The average follow-up after surgical treatment was 32.6 months (range, 6 - 73). All patients were diagnosed with frontal sinus mucoceles with anterior table erosion by high-resolution computed tomogra-

phy (CT). Thirty-one patients (84%) had undergone previous sinus operations (range, 1-10). Twelve patients had prior osteoplastic flaps with obliteration and 21/37 had undergone previous endoscopic sinus surgeries. The frontal sinus had been obliterated in 10 patients with abdominal fat, one with hydroxyapatite, and one patient with a silicone implant (normally used for breast augmentation). Fortunately, the patient with hydroxyapatite had developed a mucocele that was inferior in location and was able to be drained with an endoscopic approach in combination with a trephine. The silicone implant was removed endoscopically via a Draf III procedure. Ten patients with prior osteoplastic flap operations had hardware exposed within the sinus from previous surgeries.

Access to the mucoceles into the nasal cavity was successful in all patients on the first attempt. Frontal trephinations with excision of pre-existing sinocutaneous fistula tracts were performed in 3 patients. One patient with a mucocele secondary to inverted papilloma that obstructed the frontal outflow tract had an endoscopic approach from below and an osteoplastic flap from above with preservation of the frontal sinus outflow tract. At the mean follow-up of 36 months, the overall long-term success rate with our initial endoscopic approach was 92% (34/37). Three patients developed stenosis of the frontal drainage pathway. One patient was successfully opened with a revision endoscopic procedure, while two other patients eventually required an osteoplastic flap with fat obliteration.

Average size of all anterior table defects was 181 mm² (4 – 1155). Almost all defects were either unnoticeable or cosmetically acceptable to the patients. One patient had a defect which he felt was cosmetically unacceptable and subsequently had a contouring plate placed 6 months after the procedure.

Hardware was present in 27% (10/37) of patients. Except for the silicone obliteration material that was removed, all other exposed hardware was left in situ. Even in the presence of turbid mucocele contents, exposed hardware was left to integrate into the mucosal lining. One patient (10%), who had re-stenosis and subsequent obliteration, had hardware removed at a later stage. All other hardware was successfully re-integrated into the sinus mucosa.

DISCUSSION

In the treatment of frontal sinus mucoceles, the traditional gold standard of care has been the osteoplastic flap with obliteration⁽¹⁹⁾. In this procedure, all of the mucosa of the frontal sinus is removed and the sinus is packed with a substance such as fat. Other radical open procedures that ablate the sinus by removal of the anterior table (Reidel procedure) or posterior table (cranialization) are less often used. All three of these procedures involve removal of all sinus mucosa using both cutting and diamond burrs and plugging the frontal recess with fat, fascia, or muscle. This effectively seals the sinus from the nasal cavity. The Reidel procedure creates a significant cosmetic deformity from the collapse of the soft tissue of the forehead onto the posterior table. Frontal sinus cranialization exposes the patient to the potential development of an intracranial mucocele⁽²⁰⁾. Although Montgomery et al. reported success rates with the osteoplastic flap with obliteration of > 90%, they noted 5-10% of patients required revision surgery⁽¹¹⁾. Weber et al. detected recurrent mucoceles in almost 10% of patients who had undergone osteoplastic flaps with obliteration in a long-term follow-up study⁽⁶⁾. When the sinus is obliterated, recurrent mucoceles are almost impossible to detect with a CT scan since the sinus is radiographically opaque⁽⁴⁾. Selecting an open procedure as the first line treatment for frontal sinus mucoceles has some significant shortcomings. Minimally

invasive endoscopic techniques for frontal mucoceles have provided another option for these patients.

The morbidity associated with obliterative or ablative procedures underscores the importance of the endoscopic approach in the management of frontal sinus mucoceles. Transnasal drainage of frontal sinus mucoceles has become the procedure of choice due to the decreased morbidity when compared to open approaches⁽¹⁾. Endoscopic marsupialization preserves the mucocele cavity allowing it to drain intranasally and avoids the morbidity of external approaches. Unlike sinus obliteration, the endoscopic technique preserves the frontal sinus allowing it to be accurately imaged by CT⁽⁴⁾. Kennedy et al. successfully drained 16 of 18 complicated frontal mucoceles, many of which had eroded the posterior table, extended into the orbit, or had associated Pott's puffy tumour⁽²⁾. There were no mucocele recurrences after 42 months of follow-up. Har-El reported that 65 of 66 frontal sinus mucoceles were successfully managed endoscopically with recurrence noted in only 1 patient (0.9%)⁽⁸⁾. This one recurrence was subsequently managed with an open procedure and obliteration. In another series, Constantinidis et al. successfully managed 7 patients with frontal sinus mucoceles using endoscopic techniques⁽²¹⁾. In the present series, all mucoceles (n=37) were successfully accessed at the initial endoscopic procedure. One patient required an osteoplastic flap with frontal sinus preservation in addition to the endoscopic marsupialization of the mucocele for complete removal of inverted papilloma that had obstructed the frontal sinus. Two patients eventually required an osteoplastic flap with fat obliteration for stenosis of the frontal outflow tract. Thus, 35 of the 37 patients were saved from the morbidity of an open procedure for the management of their mucoceles. Endoscopic drainage appears to be a viable and effective technique with little morbidity when performed in specialized centers.

Questions still remain as to the best management of frontal sinus mucoceles when there is anterior table erosion present. Historically, these have been treated with frontal sinus obliteration, especially when they have associated inflammatory disease, tumours, or exposed hardware^(5,11). The continued use of the osteoplastic flap in this situation is often founded on concerns over the potential for a cosmetically unacceptable depression in the forehead following endoscopic drainage. In contrast to endoscopic management, a contouring plate can be positioned over the defect via an osteoplastic flap approach. However, the osteotomies performed during osteoplastic flap surgery may themselves cause noticeable contour deformities of the forehead. Mucosa may be adherent to adjacent soft tissue through the erosion, thus making separation very difficult during obliterative surgery. Cauterization is the preferred method to destroy any remaining mucosa in this situation. This is unquestionably an inexact method of removal and may predispose the patient to recurrent mucoceles in the future.

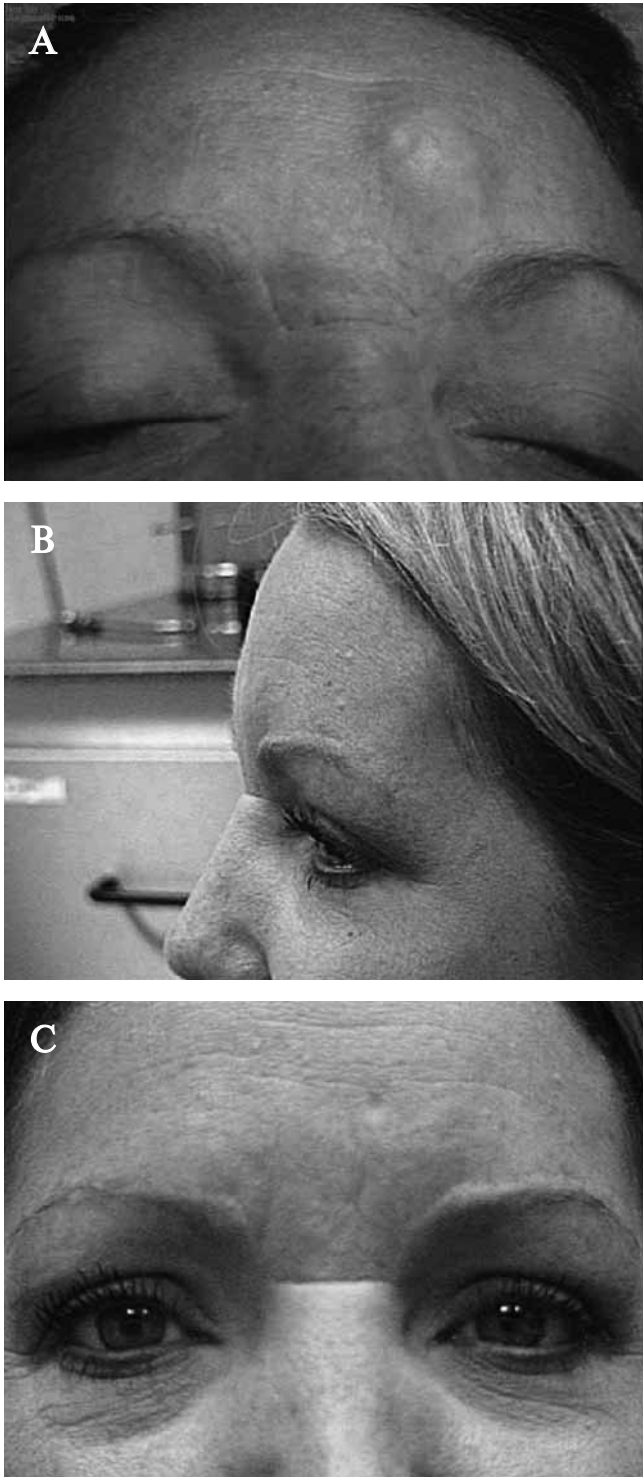


Figure 3. Pictures before and after endoscopic drainage of the frontal sinus mucocele in Figure 2. (A) The mucocele is very noticeable pressing out on the soft tissue of the forehead. (B, C) However, 4 weeks postoperatively, the patient has no visible contour defect of the forehead or supraorbital rim.

This study's outcomes support the current surgical philosophy of endoscopic drainage of frontal sinus mucoceles as the first line treatment when there is anterior table erosion present. The average size defect in this series was 181 mm². None of the patients who were successfully drained endoscopically had a significant cosmetic deformity that required a contouring plate. In this series, offering an endoscopic approach as the first-line treatment decreased the overall morbidity for the patients and did not result in significant cosmetic deformity.

Ninety percent ^(9/10) of the patients in our series with previously exposed hardware were successfully managed endoscopically without having to remove hardware. One patient failed two attempts at endoscopic marsupialization prior to removal of hardware and frontal sinus obliteration with fat. The plates were subsequently replaced 6 months after the complete resolution of the mucocele. Titanium mesh and other hardware have been used extensively in skull base reconstruction. Mesh repair of the orbit often involves integration of the hardware directly into sinus mucosa. Histological evidence of successful mucosal integration has been well documented ⁽²²⁾.

We now approach frontal sinus mucoceles with anterior table erosion in a defined algorithm (Figure 4). Preoperative nasal endoscopy and preoperative imaging with CT ± MRI is always performed. Endoscopic drainage is attempted first. Intra-operative image-guided surgical systems, while not a pre-requisite, are helpful due to altered anatomy and loss of landmarks in many cases. Patients are examined clinically with long-term endoscopic follow-up. When re-stenosis of the frontal outflow tract that cannot be opened with a repeat endoscopic procedure, such as a Draf III, an osteoplastic flap with obliteration is performed. If necessary, a cosmetically unacceptable anterior table defect can be repaired with a contouring plate at that second stage. In cases of successful resolution of the mucocele with a patent frontal sinus outflow tract, patients are given the

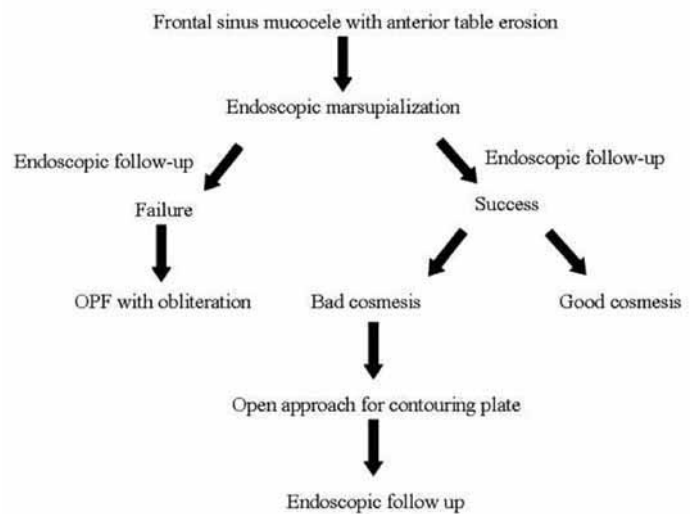


Figure 4. Our algorithm for the management of frontal sinus mucoceles with anterior table erosion.

choice of intervention (placement of a contouring plate) or observation. Of note, 36 of 37 patients in this series felt their defect was either unnoticeable or cosmetically acceptable (Figure 3). Exposed hardware is always left in situ, initially, even in the presence of infection. All patients require long-term clinical surveillance after these procedures.

CONCLUSION

Endoscopic marsupialization of frontal sinus mucoceles with anterior table erosion has a high success rate with a good cosmetic outcome, often without routine reconstruction. Revision cases and those with exposed hardware did not prevent successful management. First line endoscopic management of frontal sinus mucoceles, with anterior table erosion, may eliminate the need for more extensive open surgery.

ACKNOWLEDGEMENTS

We gratefully thank and appreciate our patient depicted in the illustrations for her permission to release her photos.

REFERENCES

1. Bockmuhl U, Kratzsch B, Benda K, Draf W. Surgery for paranasal sinus mucoceles: efficacy of endonasal micro-endoscopic management and long-term results of 185 patients. *Rhinology*. 2006; 44: 62-67.
2. Kennedy DW, Josephson JS, Zinreich SJ, Mattox DE, Goldsmith MM. Endoscopic sinus surgery for mucoceles: a viable alternative. *Laryngoscope*. 1989; 99: 885-895.
3. Javer AR, Sillers MJ, Kuhn FA. The frontal sinus unobliteration procedure. *Otolaryngol Clin North Am*. 2001; 34: 193-210.
4. Chandra RK, Kennedy DW, Palmer JN. Endoscopic management of failed frontal sinus obliteration. *Am J Rhinol*. 2004; 18: 279-284.
5. Goodale RL, Montgomery WW. Experiences with the osteoplastic anterior wall approach to the frontal sinus; case histories and recommendations. *AMA Arch Otolaryngol*. 1958; 68: 271-283.
6. Weber R, Draf W, Keerl R, et al. Osteoplastic frontal sinus surgery with fat obliteration: technique and long-term results using magnetic resonance imaging in 82 operations. *Laryngoscope*. 2000; 110: 1037-1044.
7. Langton-Hewer CD, Wormald PJ. Endoscopic sinus surgery rescue of failed osteoplastic flap with fat obliteration. *Curr Opin Otolaryngol Head Neck Surg*. 2005; 13: 45-49.
8. Har-El G. Endoscopic management of 108 sinus mucoceles. *Laryngoscope*. 2001; 111: 2131-2134.
9. Har-El G, Lucente FE. Endoscopic intranasal frontal sinusotomy. *Laryngoscope*. 1995; 105: 440-443.
10. Meetze K, Palmer JN, Schlosser RJ. Frontal sinus complications after frontal craniotomy. *Laryngoscope*. 2004; 114: 945-948.
11. Montgomery WW. State-of-the-art for osteoplastic frontal sinus operation. *Otolaryngol Clin North Am*. 2001; 34: 167-177.
12. Shirazi MA, Silver AL, Stankiewicz JA. Surgical outcomes following the endoscopic modified Lothrop procedure. *Laryngoscope*. 2007; 117: 765-769.
13. Nakagawa T, Ito J. Endoscopic modified Lothrop procedure for postoperative frontal mucocele. *Acta Otolaryngol Suppl*. 2007; 557: 51-54.
14. Khong JJ, Malhotra R, Selva D, Wormald PJ. Efficacy of endoscopic sinus surgery for paranasal sinus mucocele including modified endoscopic Lothrop procedure for frontal sinus mucocele. *J Laryngol Otol*. 2004; 118: 352-356.
15. Wormald PJ, Ananda A, Nair S. Modified endoscopic lothrop as a salvage for the failed osteoplastic flap with obliteration. *Laryngoscope*. 2003; 113: 1988-1992.
16. Ikeda K, Takahashi C, Oshima T, et al. Endonasal endoscopic marsupialization of paranasal sinus mucoceles. *Am J Rhinol*. 2000; 14: 107-111.
17. Lund VJ. Endoscopic management of paranasal sinus mucoceles. *J Laryngol Otol*. 1998; 112: 36-40.
18. Weber R, Draf W, Kratzsch B, Hosemann W, Schaefer SD. Modern concepts of frontal sinus surgery. *Laryngoscope*. 2001; 111: 137-146.
19. Macbeth R. The osteoplastic operation for chronic infection of the frontal sinus. *J Laryngol Otol*. 1954; 68: 465-477.
20. Donald PJ, Bernstein L. Compound frontal sinus injuries with intracranial penetration. *Laryngoscope*. 1978; 88: 225-232.
21. Constantinidis J, Steinhart H, Schwerdtfeger K, Zenk J, Iro H. Therapy of invasive mucoceles of the frontal sinus. *Rhinology*. 2001; 39: 33-38.
22. Schubert W, Gear AJ, Lee C, et al. Incorporation of titanium mesh in orbital and midface reconstruction. *Plastic Reconstr Surg*. 2002; 110: 1022-1030.

Bradford A. Woodworth, MD
 Division of Otolaryngology
 Department of Surgery
 University of Alabama at Birmingham
 BDB 563
 1530 3rd Ave S
 Birmingham, AL 35294
 USA

Tel: +1-205-934-9765
 Fax: +1-205-934-3993