

Endonasal endoscopic resection of juvenile nasopharyngeal angiofibroma*

Ph. Eloy¹, J.B. Watelet², A.S. Hatert¹, J. de Wispelaere³, B. Bertrand¹

¹ Department of Otorhinolaryngology, Head & Neck Surgery, University Hospital of Mont-Godinne, Université Catholique de Louvain, 5530 - Yvoir, Belgium

² Department of Otorhinolaryngology, Head and Neck Surgery, University Hospital of Ghent, Ghent, Belgium

³ Department of Radiology, University Hospital of Mont-Godinne, Université Catholique de Louvain, Yvoir, Belgium

SUMMARY

Juvenile angiofibroma (JNA) is a rare benign but locally aggressive tumour of the nasopharynx that primarily occurs in adolescent males. We report a series of 6 consecutive cases operated by exclusive endoscopic approach between from March 1996 and June 2003. All were male. The mean age was 17,2 years old (range: 11 – 23 years). The tumour involved the nasopharynx in all the cases (6/6), the sphenoid sinus (3/6) and the medial part of the pterygopalatine fossa (4/6). According to Radkowski's classification (Table 1), one patient was stage Ia, one was stage Ib and four patients were stage IIb.

The mean duration of the surgery was 2 hours. The mean intraoperative blood loss was 575 ml despite a preoperative hyperselective embolization. The mean follow-up after the first operation was 67 months. All patients but one were free of disease. One patient had a recurrence in the nasopharynx and sphenoid sinuses requiring a successful revision procedure 3 years after the primary surgery. Another patient presented with a 5 mm non-symptomatic nodule in the pterygopalatine fossa, regressing on MRI during the 4 years following the surgery. In conclusion, endoscopic resection of JNA is a difficult but effective operation in experienced hands. Based upon the recent international literature, endonasal surgery combined with a preoperative embolization of the arterial supply is indicated for small and middle size JNAs but also for large tumours extended to the pterygopalatine fossa and medial aspect of the infratemporal fossa. Minimal intracranial extension is not an absolute contraindication if there is no clinical or radiological involvement of the cavernous sinus. A tridimensional guiding system can be of some help in large tumours.

Key words: Juvenile nasopharyngeal angiofibroma, endoscopy, endonasal surgery

INTRODUCTION

Juvenile nasopharyngeal angiofibromas (JNAs) are uncommon highly vascular, non-encapsulated tumours that typically occur in adolescent male patients complaining of a painless persistent nasal obstruction and recurrent epistaxis, while other symptoms are dependent upon the direction and extent of tumour spread⁽¹⁻³⁾. They account for 0.05% to 0.5% of all Head and Neck tumours. They are the most common benign tumours of the nasopharynx but they have the potential to cause life-threatening complications secondary to bleeding and intracranial extension⁽⁴⁻⁶⁾.

They are generally known as a neoplasm but recent theories have questioned whether it is a vascular malformation⁽⁷⁻⁹⁾. Shick et al., for example, tries to explain the vascular component of these tumours embryologically due to incomplete regression of the first branchial artery⁽⁹⁾. This vessel connects

temporarily the internal carotid artery and the vessels from the maxillary artery. The persistence of this artery may lead to the development of JNA due to growth stimulation at the time of adolescence.

JNAs originate from the superior margin of the sphenopalatine foramen but the tissue of origin is still unclear⁽¹⁰⁻¹²⁾. More specifically, they are located where the sphenoid process of the palatine bone meets the horizontal ala of the vomer and the root of the pterygoid process of the sphenoid⁽¹³⁾. From this point, progression of the tumour is often slow and characterized by a locally destructive growth, eroding adjacent bone and spreading submucosally through natural foramina and fissures into critical areas. In fact, the tumour grows inferiorly down into the nasopharynx, progresses posteriorly into the sphenoid sinus and disrupts the roots of the pterygoid plates. It can also push forward the posterior wall of the maxillary sinus.

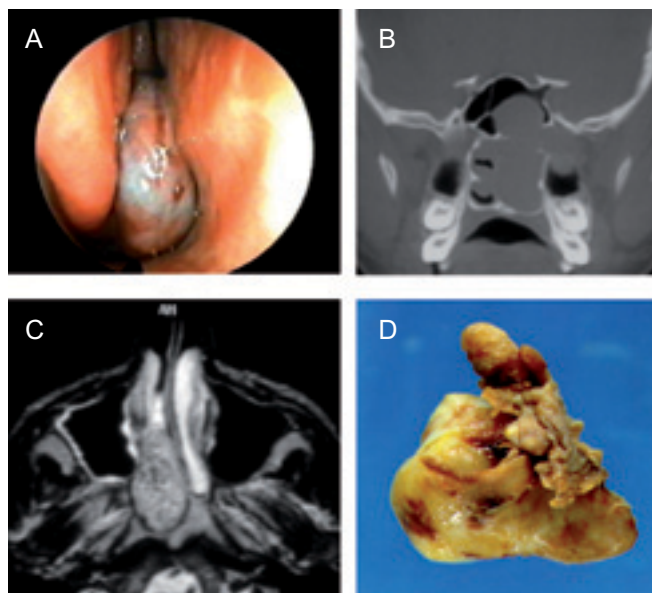


Figure 1. (a) endoscopic view of a typical angiofibroma located at the posterior part of the right nasal fossa. (b) coronal CT scan- extension of the angiofibroma into the left sphenoid sinus and pterygomaxillary fossa (white arrows). (c) typical MR imaging confirming the high vascularization of the tumour. (d) macroscopic view – surgical specimen.

Laterally it can extend into the pterygopalatine and infratemporal fossae and even through the orbital fissures into the orbit and dura of the middle cranial fossa⁽¹⁴⁾. The tumours can also infiltrate cranial nerves, carotid arteries and cavernous sinus. In case of intracranial extension, JNAs remain extradurally.

Diagnosis is based upon the history, physical examination and radiological findings. Biopsy is not recommended because the procedure is often complicated by severe bleeding⁽¹⁵⁾. A pre-operative mapping of all the arterial supplies is mandatory. It needs a selective angiography of both internal and external carotid arteries^(16,17). In case of large tumours the investigation must be performed on both sides⁽¹⁷⁾.

Hyperselective embolization of all the feeding branches depending on the external carotid artery is a major advance in the management of JNAs. This can decrease the vascularity sufficiently to make resection easier without major blood loss and contributes to improve significantly the final results⁽¹⁸⁻²⁰⁾.

Concerning the treatment, although spontaneous regression of these tumours has been reported^(21,22), there is a general agreement that the majority of JNA can be cured by complete excision. Radiotherapy and chemotherapy are confined to very extensive lesions or recurrent tumours involving critical anatomical areas, where the surgical extirpation can carry a significant morbidity^(17,23,24). External approaches (midfacial degloving, lateral rhinotomy, transpalatine, infratemporal approaches) were used traditionally in the past for all stages of JNA. However, during the last 20 years, we have seen a marked shift towards endonasal procedures for resection of small and middle size JNAs^(13,16,17,25-32) but also for large tumours extended to the pterygopalatine fossa and medial

Table 1. Angiofibroma Classifications.

• Classification according to Radkowski	
o	Stage IA - Tumour limited to posterior nares and/or nasopharyngeal vault
o	Stage IB - Tumour involving posterior nares and/or nasopharyngeal vault with involvement of at least 1 paranasal sinus
o	Stage IIA - Minimal lateral extension into pterygomaxillary fossa
o	Stage IIB - Full occupation of pterygomaxillary fossa with or without superior erosion of orbital bones
o	Stage IIC- Extension through the pterygomaxillary fossa into the cheek and temporal fossa
o	Stage IIIA - Erosion of skull base (ie, middle cranial fossa/pterygoid base); minimal intracranial extension
o	Stage IIIB - Extensive intracranial extension with or without extension into cavernous sinus
• Classification according to Fisch	
o	Stage I - Tumours limited to nasal cavity, nasopharynx with no bony destruction
o	Stage II - Tumours invading pterygomaxillary fossa, paranasal sinuses with bony destruction
o	Stage III - Tumours invading infratemporal fossa, orbit and/or parasellar region remaining lateral to cavernous sinus
o	Stage IV - Tumours invading cavernous sinus, optic chiasmal region, and/or pituitary fossa

aspect of the infratemporal fossa. Minimal intracranial extension is not a contraindication if there is no involvement of the cavernous sinus⁽³³⁻³⁷⁾.

The purpose of this paper is to report our experience consisting with a series of 6 consecutive JNAs treated endoscopically in the ENT department of the University Hospital of Mont-Godinne with a mean follow-up of 67 months. We highlight the operative strategy and discuss the advantages and drawbacks of this approach.

MATERIAL AND METHOD

Patients

From March 1996 to June 2003, 6 consecutive patients with extracranial JNA have been operated on with a pure endonasal endoscopic approach in the department of Otorhinolaryngology of the University Hospital of Mont-Godinne. All were male. The mean age was 17,2 years old (range: 11 – 23 years).

Persistent nasal obstruction was the major symptom in all cases. Recurrent nasal bleedings were present in 5 cases. No associated otological, ophthalmological or neurological symptoms were reported.

All patients had a complete preoperative evaluation including a nasal endoscopy, a computerized tomography (CT) scan with contrast, a MRI and a selective angiography of both internal and external carotid systems. The tumour involved the nasopharynx in all cases (6/6), the sphenoid sinus (3/6) and the medial part of the pterygomaxillary fossa (4/6). According to Radkowski's classification (Table 1), one patient was stage Ia, another was stage Ib and four were stage IIB.

Table 2. Clinical findings: patient characteristics, location and extensions of the JNA, preoperative bleeding, follow-up period and final result.

Patient	Age (Years)	Gender	Location of JNA and extensions	Peroperative bleeding	Follow-up (months)	Result
1.	16	Male	Nasopharynx Extension to the right sphenoid sinus and medial part of the pterygopalatine fossa	1000ml	124	Free of disease
2.	11	Male	Nasopharynx	300ml	111	Free of disease
3.	20	Male	Nasopharynx extended to sphenoid sinuses	700ml	75	Recurrence 3 Y later
3.	20	Male	Nasopharynx and extension to sphenoid sinuses	700ml	41	Free of disease
Revision surgery						
4.	20	Male	Nasopharynx and extension to right nasal cavity and pterygopalatine fossa	300ml	69	Free of disease
5.	23	Male	Nasopharynx and pterygomaxillary fossa	500ml	47	Nodule: 6mm Free of symptom
6.	13	Male	Nasopharynx with extension to left pterygopalatine fossa and sphenoid sinus	650ml	37	Free of disease

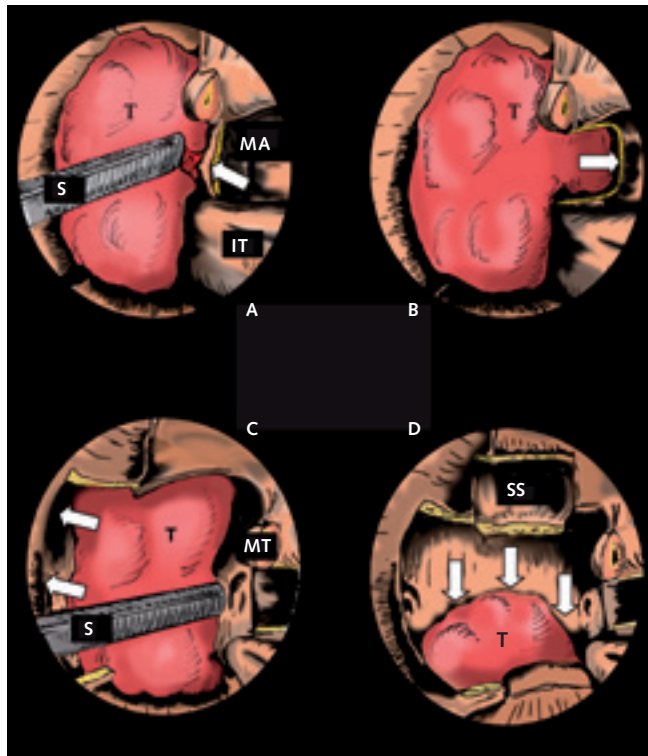


Figure 2. Surgical procedure. (a) endoscopic view – left nasal fossa. Visualization of the tumour at the posterior part of the nasal fossa and the sphenopalatine artery (white arrow). (b) endoscopic view – left nasal fossa. Resection of the posterior maxillary wall when the tumour infiltrates the pterygomaxillary fossa (white arrow: removed posterior wall). (c) resection of the posterior septum to expose widely the tumour and both sides of the nasopharynx (white arrow: removed posterior septum). (d) large opening of the sphenoid sinus and pushing down the tumour into the mouth to deliver it in one piece (white arrow: bascule of the tumour into the mouth).

(T: tumour; MA: middle antrostomy; IT: inferior turbinate; S: suction; MT: posterior part of the middle turbinate - SS: sphenoid sinus).

A preoperative hyperselective embolization of the branches depending on the internal maxillary artery was performed with polyvinyl alcohol particles in all cases 24 hours before surgery. The clinical presentation of the different cases is displayed in Table 2.

Surgical procedure

The surgery was carried out under general anaesthesia. The nasal fossae were topically vasoconstricted with neurosurgical cotton pledgets soaked in 1% xylocaine plus 1/10000 adrenaline and left in place for 15 minutes before surgery. When the tumour extended into the sphenoid sinus we started the surgery with a complete anterior and posterior ethmoidectomy to identify the superior aspect of the JNA; in the other cases we only performed a middle antrostomy. This allowed the identification of the ascending process of the palatine bone. A nasal mucosal flap was elevated posteriorly up to the tail of the middle turbinate to expose the sphenopalatine foramen and to check the effectiveness of the embolization (Figure 2a). If necessary, a metallic clip was secured on the common trunk or on the terminal branches of the sphenopalatine artery. In case of pterygopalatine fossa (PPF) invasion, the vertical plate of the palatine bone and the posterior maxillary wall were removed up to the infraorbital nerve canal (Figure 2b). Using a curved suction and a 45-degree Blakesley forceps, the tumour was detached from the content of the PPF. When the tumour extended beyond the midline of the nasopharynx, a resection of the bony septum was done to improve access and visualization (Figure 2c). Extension into the sphenoid sinus was removed with angulated forceps (Figure 2d) and the floor of the sphenoid sinus was drilled. Nutrient afferent arteries were coagulated with a bipolar diathermy or compressed with cottonoids soaked in a solution of 1‰ adrenaline. Finally, the tumour was reflected inferiorly into the mouth and delivered in one piece. At the posterior wall of the nasopharynx, it was usually more difficult to find the “good” plane for dissection and

Table 3. Literature review – endoscopic resection of JNA.

Authors (reference)	Nb of cases	Staging (Radkowski)	Mean Follow-up (months)	Symptomatic recurrence/asymptomatic residue
Fagnan et al. ⁽²⁸⁾	2	Ib and IIa	12	0/0
Jorissen et al. ⁽²⁶⁾	13	Ib and IIa	30	2/0
Kamel et al. ⁽¹³⁾	1	IIa	24	0/0
Mitskavich ⁽²⁵⁾	1	Ib	24	0/0
Naraghi ⁽³⁸⁾	12	Ia to IIb	15	2/0
Nicolai et al. ⁽¹⁷⁾	15	I to IIc	50	0/1
Newlands. ⁽³¹⁾	3	Ib and IIa	24	0/0
Önerci et al. ⁽³⁶⁾	8	IIc	6	0/0
Önerci et al. ⁽³⁶⁾	4	IIIa	24	0/2
Pryor et al. ⁽²⁹⁾	6	IIb and IIc	24	0/0
Roger et al. ⁽³⁴⁾	20	Ia to IIIa	22	0/2
Schick et al. ⁽¹⁵⁾	5	Ib and IIa	22	0/0
Wormald ⁽³²⁾	7	I to IIc	48	0/0
Hofmann et al. ⁽³³⁾	16	I to IIc	11	3/2
Hofmann et al. ⁽³³⁾	5	IIIa	3	1/1

haemostasis took more time to be effective. Frozen sections biopsies were taken from the resection line for histologic evaluation of the margins. At the end of the procedure, fibrin glue was sprayed into the operative cavity, avoiding postoperative nasal tamponade. To prevent the development of synechia, silastic nasal splints were placed between the septum and the inferior turbinates for 15 days. The patient stayed in the hospital for one or 2 days postoperatively. Postoperative treatment included nasal lavages with saline and nasal ointment (3 times a day).

Follow-up

A CT scan of the surgical field was ordered 6 months after surgery and a MRI every year. A nasal endoscopy was performed in the office at each consultation every 3 months for the first year and one or two times per year for the next 5 years. Patient 3 had no follow-up for 3 years and came back with a symptomatic recurrence in the nasopharynx and sphenoid sinuses.

RESULTS

The duration of the surgery varied from 1 to 3 hours with an average of 2 hours.

No vascular, ophthalmological or neurological complications were reported intra- or postoperatively. In all cases, nasal tamponade was not necessary.

The intraoperative blood loss varied from 300 ml to 1000ml with a mean of 575 ml. No exogenous blood transfusion was necessary. In 2 cases we used a cell saver system for immediate retransfusion of the patient's blood after filtration and washing. All cases achieved immediate remission of symptoms. The mean postoperative follow-up after primary surgery was 67 months (range: 37 – 124 months). Only one patient (patient 3) had a symptomatic tumour recurrence in the nasopharynx and the sphenoid sinuses requiring a revision surgery 3 years after the first procedure. At that time, particular attention was paid

to expose the anterior and inferior walls of both sphenoid sinuses and the choanae widely, and to drill the root of the pterygoid plates and the vidian canal to remove all residual tumour. More than 39 months later, the patient is still free of disease. No residual tumour has been found.

Another patient (patient 5) had a 5 mm nodule, in the pterygopalatine fossa which was non symptomatic and did not show evolution on MRI over a follow-up of 3 years.

DISCUSSION

Surgery of JNAs has always been considered difficult. The tumour is deeply located under the skull base: the access is narrow and the vision is limited. The tumour can be very large and multilobulated, with extensions into important areas such as the infratemporal and pterygopalatine fossae. Some tumour extensions are difficult to remove completely: e.g infiltration of the orbit, cavernous sinus and optic nerve ⁽³³⁻³⁶⁾. The tumour is highly vascular and intraoperative bleeding remained troublesome. The incidence of JNAs tumours is so low that most ENT departments have a limited experience with the management of these tumours ^(32,36).

Surgery of JNAs tumours has been performed traditionally with an external approach. These open procedures provide a generous exposure of the tumour. They allow a large dissection of all the involved structures and facilitate the resection even in case of severe bleeding. But they need an external incision (facial or oral incision), sacrifice of important facial structures such as the turbinates and the internasosinus wall, removal of bone, facial osteotomies and plating of the maxillary framework. Because of these extended tissue damages, they can have some influence on the facial growth ⁽¹⁵⁾.

More recently, we have seen a marked shift towards less invasive surgery. In case of JNAs, endoscopic resection of JNAs confined to the nasal fossa, the nasopharynx and extended to

the sphenoid sinus, the ethmoid sinus and the medial part of the pterygopalatine fossa is supported by excellent results, published in the international literature. Table 3 displays some data published in the literature. Many authors did not have any recurrence^(13,15,16,25,27-32) while others reported some^(26,38). In our series, we had one recurrence out of 6 cases, 3 years after the first surgery. Hofmann⁽³³⁾ reported 16 cases (stage I and II according to Fisch): he had 3 recurrences, 2 cases with residual disease and 11 cases free of disease. Complete excision of large tumours continue to present a considerable surgical challenge but some experienced and well-trained teams extend the indication of endonasal surgery for tumours extended to the pterygopalatine fossa and medial aspect of the infratemporal fossa⁽³³⁻³⁷⁾. Minimal intracranial extension is no more considered a contraindication for endonasal surgery^(17,33-36). The results are excellent, despite residual disease showing no sign of evolution on regular imaging. Roger and colleagues⁽³⁴⁾ had 2 residual diseases out of 10 patients with advanced tumour (1 infratemporal fossa involvement and 9 cases with erosion of the skull base). Nicolai⁽¹⁷⁾ had 1 residual lesion out of 4 tumours invading either the infratemporal fossa or the parasellar region. Önerci⁽³⁷⁾ had 4 patients with limited intracranial penetration with 2 of them having residual disease around the cavernous sinus but there was no progression over a follow-up of 2 years. Hofmann and colleagues⁽³³⁾ reported 1 recurrence, 1 residual disease and 3 cases free of disease, out 5 cases classified IIIa according to the Fisch stadification. Before surgery, one of the prerequisites is to stadify the tumour according to one of the current classifications (Radkowski or Fisch) (Table 1). For this, it is necessary to perform a complete evaluation of the tumour including a nasal endoscopy, a computerized tomography (CT) scan with contrast, a MRI scan and a selective angiography. These investigations should give information about the size of the tumour, its attachments, extensions, blood supply, bony erosions and infiltrations of vital structures such as the optic nerve, carotid artery and cavernous sinus.

Preoperative embolization of the feeding vessels depending on the external carotid artery, mainly the branches of the internal maxillary artery, decreases the vascularity sufficiently to make resection easier without major blood loss⁽¹⁷⁻²⁰⁾. Nevertheless as illustrated by our series and those from Wormald^(32,36), Hofmann⁽³³⁾, and Önerci⁽³⁶⁾ this is not always the case. Some patients could lose more than one liter of blood during the surgery, particularly in case of a large tumour. This can be explained by an incomplete embolization or by the presence of nonembolized branches from the internal carotid system. But, we must keep in mind that major complications such as blindness or brain ischemia can occur⁽³⁹⁾. Hofmann⁽³³⁾ reported 2 cases of non-complicated brain ischemia and Herman⁽⁶⁾, 3 cases of transitory minor complications.

Intratumoral embolization is another way to improve the quality of the embolization^(6,33,40).

During the surgery, some refinements in the technique are necessary.

Injection of vasoconstrictors into the pterygopalatine fossa⁽³²⁾ can be of some help. It is mandatory to cauterize all the points of bleeding at each surgical phase with an endoscopic bipolar cautery or by compression with cottonoids soaked in a 1% solution of adrenalin. The use of suction irrigation instruments such as suction Freer and powered instrumentation are extremely useful⁽³²⁾. The dissection of the tumour must be conducted along the pseudocapsule, allowing a “monobloc resection”^(15,17). In case of large tumour, fragmentation of the tumour can be performed with the laser (diode or KTP)^(17,41,42). The surgical access must be as wide as possible and adapted to individual situations. Resection of the posterior septum gives a generous view on the nasopharynx, particularly for tumours extended beyond the midline. Anterior and posterior ethmoidectomy associated with the removal of the middle turbinate contributes to improve the view on the superior part of the tumour. Removal of the posterior wall of the maxillary sinus is necessary to gain access into the medial part of the pterygomaxillary fossa. To expose the lateral part, the resection should be associated with a medial maxillectomy (complete resection of the intersinonasal wall and the inferior turbinate). In case of infiltration of the sphenoid sinus, it is important to drill the basisphenoid area, the root of the pterygoid plate and the vidian canal to avoid any residual tissue in this region, a frequent source of recurrence. Indeed, Lloyd, Howard and Lund demonstrated by CT and MRI in 1999 that JNAs have an important extension along the pterygoid canal with invasion of the cancellous bone of the pterygoid base and greater wing of the sphenoid in 60% of the patients^(43,44).

The only recurrence we observed may be explained by the absence of drilling of the root of the pterygoid plate during the first surgery but also by another fact. Indeed, it is usually more difficult to find a “good” plane for dissection from the posterior nasopharynx and the haemostasis needs more time to be effective and complete. This has also been mentioned by Hofmann^(32,33). The dissection should therefore be conducted at the level of the prevertebral fascia via a transoral approach; the use of a curved bipolar cautery is recommended^(32,38).

For very large tumours, a two nostrils - four hands technique is recommended^(17,33,36,45) due to the necessity of a resection of the posterior septum. The endoscope and one suction line are inserted in one nostril while the operator uses his instruments on the other side.

A tridimensional image guiding system is particularly useful in case of extended tumours for checking the lateral tumour margins and for identification the vital anatomic structures such as the carotid artery, cavernous sinus, optic nerve and skull base^(1,32,33,36).

The incidence of residual disease in the literature varies from 13% to 50% after an external approach^(43,45,46). After endonasal resection the incidence is less important (Table 3) except in

case of very large tumours ^(17,29,33,34,36,37,46). This can be explained by the fact that endoscopy provides a magnified, multi-angled view of the mass and of its adjacent anatomical structures. All the tumour extensions or residues can be checked with angulated telescopes. Therefore, persistence of JNA may be explained by an incomplete dissection, due to a severe intraoperative bleeding, absence of a good plane for dissection or because the tumour is in contact with vital anatomic structures (optic nerve, carotid artery, cavernous sinus). Residual tumour usually needs a followup by MRI and endoscopy at regular intervals to monitor the pattern of growth. Whenever the mass clearly and regularly increases in size, revision surgery is the preferred option of treatment. When the lesion is located in an area where the surgery is hazardous or may be associated with unwanted complications, gammaknife therapy can be proposed ⁽³³⁾. In the other cases, a “wait and see” attitude is recommended.

CONCLUSION

For experimented sinus surgeons, endoscopic resection of JNAs can be a viable alternative to the traditional, external, transfacial approach. This is a difficult but effective technique with a learning curve that allows removal of small, middle sized and even large JNAs extended to all the retramaxillary space and medial aspect of the infratemporal fossa, even with minimal intracranial extension if there is no infiltration of the cavernous sinus. Endoscopic surgery is associated with minimal morphological disturbance and low morbidity. Very large lesions are more appropriately treated by external approaches.

REFERENCES

1. Scholtz A, Appenroth E, Kammen-Jolly K, Scholtz LU, Thumfard W, Juvenile nasopharyngeal angiofibroma: management and therapy Laryngoscope. 2001; 111: 681-687.
2. Andrews JC, Fisch U, Valavanis A, Aeppli U, Makek MS. The surgical management of extensive nasopharyngeal angiofibromas with the infratemporal approach. Laryngoscope.. 1989; 99: 429-437.
3. Kennedy JD, Haines SJ. Review of skull base surgery approaches with special reference to pediatric patients. J Neuro Otol 1994; 20: 291-312.
4. Waldman SR, Levine HL, Astor F, Wood BG, Weinstein M, Tucker HM. Surgical experience with nasopharyngeal angiofibroma. Arch Otolaryngol. 1981; 107: 677-682.
5. Witt TR, Shah JP, Sternberg SS. Juvenile angiofibroma. A 30-year clinical review. Am J Surg. 1983; 146: 521-525.
6. Herman P, Lot G, Chapot R. Long-term follow-up of juvenile nasopharyngeal angiofibromas: analysis of recurrences. Laryngoscope. 1999; 109: 140-147.
7. Beham A, Beham-Schmid C, Regauer S, Aubock L, Stammberger H. Nasopharyngeal angiofibroma: true neoplasm or vascular malformation? Adv Anat Pathol. 2000; 7: 36- 46.
8. Beham A, Kainz J, Stammberger H, Auböck L, Beham-Schmid C. Immunohistochemical and electron microscopical characterization of stromal cells in nasopharyngeal angiofibromas. Eur Arch Otorhinolaryngol. 1997; 254: 196-199.
9. Schick B, Plinkert PK, Prescher A. Aetiology of angiofibromas: Reflection on their specific vascular component. Laryngorhinootologie. 2002; 81: 280-284.
10. Sessions RB, Bryan RN, Naclerio RM, Alford BR. Radiographic staging of juvenile angiofibroma. Head Neck Surg. 1981; 3: 279-283.

11. Bremer JW, Neel HB, DeSanto LW, Jones GC. Angiofibroma: treatment trends in 150 patients during 40 years. Laryngoscope. 1986; 96: 1321-1329.
12. Harrison DFN. The natural history, pathogenesis and treatment of juvenile angiofibroma. Arch Otolaryngol Head Neck Surg. 1987; 113: 936-942.
13. Kamel RH. Transnasal endoscopic surgery in juvenile nasopharyngeal angiofibroma. J Laryngol Otol. 1996; 110: 962-968.
14. Sennes LU, Butugan O, Sanchez TG, Bento RF, Tsuji DH. Juvenile nasopharyngeal angiofibroma: the routes of invasion. Rhinology. 2003; 41: 235-240.
15. Schick B, el Rahman el Tahan A, Brors D, Kahle G, Draf W. Experiences with endonasal surgery in angiofibroma. Rhinology. 1999; 37: 80-85.
16. Bernal-Sprekelsen M, Vazquez AA, Pueyo J, Carbonell Casaus J. Endoscopic resection of juvenile nasopharyngeal fibromas. HNO. 1998; 46: 172-174.
17. Nicolai P, Berlucchi M, Tomenzoli D, Cappiello J, Trimarchi M, Maroldi R, Battaglia G, Antonelli AR. Endoscopic surgery for juvenile angiofibroma: when and how. Laryngoscope. 2003; 113: 775-782.
18. Moulin G, Chagnaud C, Gras R, Gueguen E, Dessi P, Gaubert JY, Bartoli JM, Zanaret M, Botti G, Cannoni M. Juvenile nasopharyngeal angiofibroma: comparison of blood loss during removal of embolized group versus nonembolized group. Cardiovasc Intervent Radiol. 1995; 18: 158-161.
19. Schroth G, Haldermann AR, Mariani L. Preoperative embolization of paragangliomas and angiofibromas. Arch Otolaryngol Head Neck Surg. 1996; 122: 1320-1325.
20. Li JR, Qian J, Shan XZ, Wang L. Evaluation of the effectiveness of preoperative embolization in surgery for nasopharyngeal angiofibroma. Eur Arch Otorhinolaryngol. 1998; 255: 430-432.
21. Stansbie JM, Phelps PD. Involution of residual juvenile nasopharyngeal angiofibroma. J Laryngol Otol. 1986; 100: 599-603.
22. Weprin LS, Siemers PT. Spontaneous regression of juvenile nasopharyngeal angiofibroma. Arch Otolaryngol Head Neck Surg. 1991; 117: 796-799.
23. Lee JT, Chen P, Safa A, Juillard G, Calcaterra TC. The role of radiation in the treatment of advanced juvenile angiofibroma. Laryngoscope. 2002; 112: 1213-1220.
24. Schick B, Kahle G, Häbeler R, Draf W. Chemotherapie des juvenilen angiofibromas – eine alternative? HNO 1996; 44: 148-152.
25. Mitskavich MT, Carrau RL, Snyderman CH, Weissman JL, Fagan JJ. Intranasal excision of a juvenile angiofibroma. Auris Nasus Larynx. 1998; 25: 39-44.
26. Jorissen M, Eloy P, Rombaux P, Bachert C, Daele J. Endoscopic sinus surgery for juvenile nasopharyngeal angiofibroma. Acta Otorhinolaryngol Belg. 2000; 54: 201-219.
27. Zicot AF, Daele J. Endoscopic surgery for nasal and sinus vascular tumours: about 2 cases of nasopharyngeal angiofibromas and one case of turbinate angioma. Acta Otorhinolaryngol Belg. 1996; 50: 177-182.
28. Fagan JJ, Snyderman CH, Carrau RL, Janecka IP. Nasopharyngeal angiofibromas: selecting a surgical approach. Head Neck. 1997; 19: 391-399.
29. Pryor SG, Moore EJ, Kasperbauer JL. Endoscopic versus traditional approaches for excision of juvenile nasopharyngeal angiofibroma. Laryngoscope. 2005; 43: 282-289.
30. Mann WJ, Jecker P, Amedee RG. Juvenile angiofibromas: changing surgical concept over the last 20 years. Laryngoscope. 2004; 114: 291-293.
31. Newlands SD, Weymuller EA Jr. Endoscopic treatment of juvenile nasopharyngeal angiofibroma. Am J Rhinol. 1999; 13: 213-219.
32. Wormald PJ, Van Hasselt A. Endoscopic removal of juvenile angiofibroma, Otolaryngol Head Neck Surg. 2003; 129: 684-691.
33. Hofmann T, Bernal-Sprekelsen M, Koelke W, Reittner P, Klein E, Stammberger H. Endoscopic resection of juvenile angiofibroma—long term results. Rhinology. 2005; 43: 282-289.
34. Roger G, Tran Ba Huy P, Froelich P. Exclusively endoscopic removal of juvenile nasopharyngeal angiofibroma; trends and lim-

- its. *Arch Otolaryngol Head Neck Surg.* 2002; 128: 928 -935.
35. Pasquini E, Sciarretta V, Franck G. Endoscopic treatment of benign tumours of the nose and paranasal sinuses. *Otolaryngol Head Neck Surg.* 2004; 131: 180-186.
 36. Douglas R, Wormald PJ. Endoscopic surgery for juvenile nasopharyngeal angiofibroma: where are the limits? *Curr Opin Otolaryngol Head Neck Surg.* 2006; 14: 1-5.
 37. Önerci TM, Yucel OT, Ogretmenoglu O. Endoscopic surgery in the treatment of juvenile nasopharyngeal angiofibroma. *Int J Pediatr Otolaryngol.* 2003; 67: 1219-1225.
 38. Naraghi M, Kashfi A. Endoscopic resection of nasopharyngeal angiofibromas by combined transnasal and transoral routes. *Am J Otolaryngol.* 2003; 24: 149-154.
 39. Önerci M, Gumus K, Cil B, Eldem B. A rare complication of embolization in juvenile nasopharyngeal angiofibroma. *Int J Pediatr Otorhinolaryngol.* 2005; 69: 423-428.
 40. Tranbahuy P, Borzik M, Herman P, wassef M, Casasco A. Direct intratumoral embolization of juvenile angiofibroma. *Am J Otolaryngol.* 1994; 15: 429-435.
 41. Nakamura H, Kawasaki M, Higuchi Y, Seki S, Takahashi S. Transnasal endoscopic resection of juvenile nasopharyngeal angiofibroma with KTP laser. *Eur Arch Otorhinolaryngol* 1999; 256: 212-214.
 42. Hazarika P, Nayak DR, Balakrishnan R, Raj G, Pillai S. Endoscopic and KTP laser-assisted surgery for juvenile nasopharyngeal angiofibroma. *Am J Otolaryngol.* 2002; 23: 282-286.
 43. Lloyd G, Howard D, Phelps P, Cheesman A. Juvenile angiofibroma: the lessons of 20 years of modern imaging. *J Laryngol Otol* 1999; 113: 127-134.
 44. Howard DJ, Lloyd G, Lund V. Recurrence and its avoidance in juvenile angiofibroma, *Laryngoscope.* 2001; 111: 1509-1511.
 45. May M, Hoffman DF, Sobol SM. Video endoscopic sinus surgery: a two-handed technique. *Laryngoscope.* 1990; 100: 430-432.
 46. Paris J, Guelfucci B, Moulin G, Zanaret M, Triglia JM. Diagnosis and treatment of juvenile nasopharyngeal angiofibroma, *Eur Arch Otolaryngol.* 2001; 258: 120 -124.
 47. McCombe A, Lund VJ, Howard DJ, Recurrence in juvenile angiofibroma, *Rhinology.* 1990; 28: 97-102.

Professor Philippe Eloy, MD
 Université Catholique de Louvain
 University Hospital of Mont-Godinne
 5530, Yvoir
 Belgium

Fax: +32-81-42-3703
 E-mail: philippe.elay@orlo.ucl.ac.be