

Functional rhinoplasty with batten and spreader grafts for correction of internal nasal valve incompetence*

C. Faris[†], E. Koury[†], P. Kothari, A. Frosh

Department of Otorhinolaryngology, Lister hospital, Stevenage, Hertfordshire, United Kingdom

SUMMARY

Objective: We describe a technique for correction of internal nasal valve incompetence (INVI) using functional rhinoplasty (FRP) with combined cartilaginous batten and spreader grafts and report the functional and cosmetic outcomes.

Design: Prospective series using subjective improvement in nasal airway and quality of life.

Setting: Subregional ENT centre, one operating rhinologist.

Participants: Twenty-three consecutive adults presenting to ENT department at North Hertfordshire NHS Trust with symptomatic INVI.

Main outcomes measures: Pre and post-operative symptom scores for nasal obstruction and its impact on overall quality of life using visual analogue scales (1-100mm). Cosmetic outcome graded using subjective scores. Statistical analysis performed using the Wilcoxon signed rank test.

Results: We found a median subjective improvement on the visual analogue scale of 55 mm for nasal patency ($p < 0.001$) and of 49 mm for quality of life ($p < 0.001$). Twenty-two patients felt that the appearance of their nose had not changed or had significantly improved post-operatively.

Conclusion: Combined use of batten and spreader grafts for the correction of INVI in normal or narrow nasal vaults is effective without compromising cosmesis.

Key words: functional rhinoplasty, graft, cartilage, nasal valve, nasal obstruction

INTRODUCTION

Internal nasal valve incompetence (INVI) is an important cause of nasal obstruction. There is growing evidence that nasal obstruction resulting from INVI is frequently misattributed to septal deviation or turbinate hypertrophy, and therefore may account for a proportion of septoplasty failures [1]. The batten graft [2] and the more commonly used spreader graft [3] have both been described in the literature in isolation for correction of INVI. We report the results of the first series of functional rhinoplasty for symptomatic INVI using combined batten and spreader grafts using autologous septal or auricular cartilage.

METHODS

This prospective study included all consecutive adult patients with symptomatic INVI selected for batten and spreader graft application presenting to the ENT department at the North and East Hertfordshire NHS Trust over a three-year period. It has been the senior author's practice to apply batten grafts in isolation for surgical treatment of INVI. However when there was concomitant deficiency of upper lateral cartilages (ULCS),

patients have been selected for additional spreader grafts. For the patients in this series, the ULCS deficiency has been assessed clinically and included cases where the middle nasal vault was seen to be normal or narrow (pinched in or 'hour-glass' appearance) secondary to deficiencies ULCS (see Figure 4). All procedures were performed by the senior author.

The degree of nasal obstruction (NO) and its impact on overall quality of life (OQOL) with regards to their nasal obstruction before and after surgery was assessed with symptom scores using visual analogue scales (rating 1 to 100mm).

The patients' subjective aesthetic outcome was determined by subjective scoring on a 3 point scale as follows: 1- significantly improved; 2- no significant change; 3- significant deterioration.

The pre-operative questionnaire was completed in the pre-operative assessment clinic. The post-operative questionnaire was completed in the outpatient visits at 3 and 6 months following surgery and by a separate postal survey. All patients completed and returned their questionnaire.

* Received for publication: March 29, 2005; accepted: September 28, 2005

[†] Joint lead authors

Of the 29 patients undergoing surgery for INVI, 25 were selected for combined batten and spreader grafting. Two were lost to follow up, leaving 23 patients in the series (11 male, 12 females; mean follow up 15.3 months, range 6 to 27.1).

Eight of the 23 patients in the series had previous septoplasties, one had a previous cosmetic septorhinoplasty and ten had previous significant nasal trauma. All patients were asked to try nasal strips at night prior to operation. We found the data not to be normally distributed and therefore presented median improvement and used the non-parametric Wilcoxon signed rank test for comparison for pre-post op improvement.

OPERATIVE TECHNIQUE

Graft harvesting

The nose is prepared with standard Moffat’s solution. The quadrilateral cartilage is exposed via a Killian’s incision and by raising mucoperichondrial flaps in the absence of significant septal deviation. Harvesting through an external approach is desirable if there is significant septal deviation to improve cartilage yield and nasal patency. A rectangle of cartilage is excised intact using a standard submucous resection technique. Where insufficient cartilage is available due to previous septoplasty or the presence of poor quality septal cartilage, conchal cartilage is harvested instead. We harvested conchal cartilage by marking the anti-helical fold with washable blue ink and excising the cartilage medial to the fold via a post-auricular technique.

Spreader graft insertion

A standard open rhinoplasty approach is made using an inverted gull wing incision to the collumella. The ULCS and dorsal margin of the nasal septum are exposed. The upper lateral cartilages are divided from the septum while preserving the mucoperichondrium of the nasal cavity that will support the spreader graft. Rectangular grafts are fashioned from the harvested cartilage. The recommended dimensions of the spreader grafts are 3 to 6 mm in length. They are placed so as to extend from the osteocartilaginous junction to a point just caudal to the anterior septal angle. They are secured directly onto the dorsal margin of the nasal septum with 5/0 PDS (Figure 1, Figure 2).

Batten graft insertion

Precise submucosal pockets are dissected just cephalic to the caudal ULCS (the scroll area) from the dorsal edge of the septum to just over the edge of the piriform aperture. The batten grafts are then fashioned to the dimensions of the pocket. The dimensions we have used were 12-20 mm in length and 6-8 mm in width (see Figure 3). Once inserted into the pockets they are secured to the spreaders and septum with 5.0 PDS (Figure 1, Figure 2).

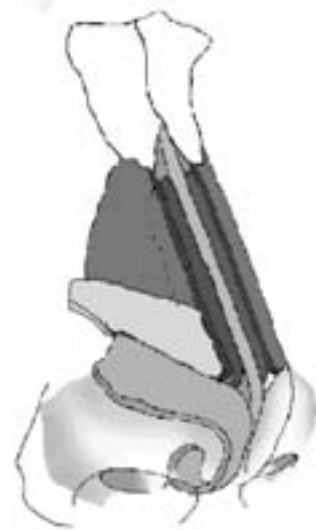

Figure 1. Diagrammatic representation of Batten and Spreader grafts in situ. Note the 5 layers cephaloid (ULC, spreader, septum, spreader, ULC) and 5 layers caudal (batten, spreader, septum, spreader, batten).

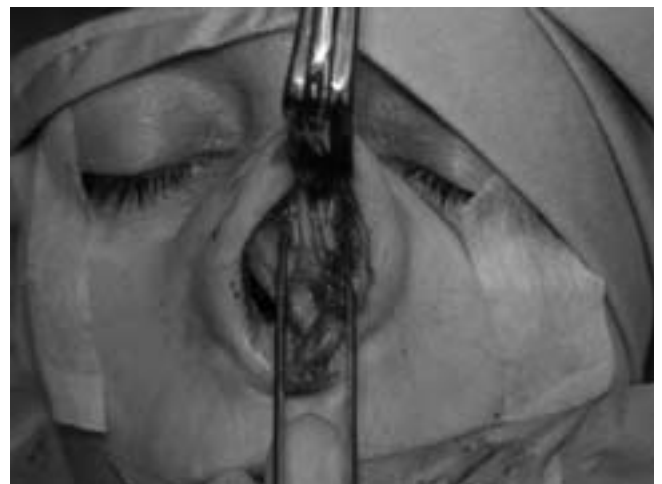


Figure 2. Intra-operative photograph of Batten and Spreader grafts in situ. Note the 5 layers cephaloid (ULC, spreader, septum, spreader, ULC) and 5 layers caudal (batten, spreader, septum, spreader, batten).



Figure 3. Harvested batten grafts from septal cartilage prior to insertion.

Table 1. Pre- and post-operative nasal patency [100mm – nasal obstruction (mm)] and overall quality of life OQOL.

	Pre-op (clinic)	Post-op (survey)	Improvement	p-value (Wilcoxon signed ranks test)
Median Nasal Patency (100 mm) n=23	25	80	55	0.000
Median Overall Quality of Life (100 mm) n=23	28	77	49	0.000

The collumellar incision is closed with interrupted 6.0 proline and 5.0 vicryl rapide used for all mucosal incisions. The skin of the nose is covered with steristrips.

RESULTS

Twenty-one of the 23 subjects responded to the subjective visual appearance question (Table 1). Two cases reported a significant improvement in cosmetic appearance, 1 reported a significant deterioration and eighteen reported no change. The 13 of the 16 patients that found nasal strips to be beneficial all benefited from the surgery.

None of the patients had significant septal deviation at the time of functional rhinoplasty. Eight had undergone a previous septoplasty.

Post-operative complications included 1 graft reabsorption and 1 graft migration, which both required a revision procedure. Both improved with subsequent surgery.



Figure 4. Pre-operative photographs of patient who underwent combined Batten and Spreader graft insertion.

DISCUSSION

INVI an important cause of nasal obstruction and is a neglected and often unrecognised clinical entity which can produce significant symptoms. The nasal valve area is defined anatomically by the caudal margin of the upper lateral cartilage laterally, nasal septum and the floor of the nose [4]. The nasal valve normally contributes up to 50% of the nasal resistance representing the narrowest point in the upper respiratory tract [5].

INVI results from deficiencies of the structural support of the upper lateral cartilage. Loss of this support leads to indrawing of the lateral nasal wall in the nasal valve area during inspiration. This is due to the Bernoulli Principle that states; as the flow through a fixed volume/space increases, the pressure within that space decreases. Therefore as airflow increases through the nasal cavity the pressure decreases producing a pressure differential between itself and atmospheric pressure the trans-mural differential. Where there is loss of lateral nasal wall support small pressure differences are sufficient to cause collapse of the lateral wall and a decrease in nasal valve cross-sectional area. Symptomatic collapse is predisposed by a narrow internal nasal valve angle, as seen in patients with a narrow middle nasal vault.

Predisposing factors include previous rhinoplasty, trauma and age. In our series 12 (44%) had significant previous nasal trauma. Only one patient had undergone a previous rhinoplasty in contrast to North American studies where it is cited as the lead cause of INVI [6]. One young patient with no other recognised risk factors had Ehlers Danlos syndrome. This has not been described as an aetiological factor, but the soft tissue laxity in this condition may contribute to loss of nasal valve support.

As INVI is a dynamic condition and can only be demonstrated by direct visualization of nasal valve area whilst the patient is breathing the diagnosis can be missed. We feel that airflow improvement using the Cottle's manoeuvre and modified



Figure 5. Post-operative photograph of patient who underwent combined Batten and Spreader graft insertion 1 year previously.

Cottle's manoeuvre (supporting the internal nasal valve with an ear curette) to be a reasonable clinical indicator for INVI. Furthermore in our practice the use of nasal strips has been a good positive predictor for successful surgery.

In our group of patients, 8 had undergone previous septal surgery for nasal obstruction (27%). In these cases, INVI was only diagnosed post-operatively when symptoms of nasal obstruction persisted in spite of a corrected nasal septum, highlighting the difficulty of diagnosing INVI. We also feel that FRP should be considered in patients presenting with INVI as a primary procedure as previous septoplasty discounts the use of septal cartilage for graft material.

Patients with INVI and broad middle nasal vault that were treated with batten grafts in isolation in our department. They were not included in this series. These patients we feel tend not to require correction of their nasal valve angle and hence will not benefit from spreader grafts. Furthermore application spreader grafts risks further broadening of the nasal vault and a consequent poor cosmetic outcome is likely. This accounts for a minority of the patients (4 from 29 14%).

The use of spreader grafts [3] in isolation or batten grafts [2] in isolation for the surgical correction of INVI have been described in the literature and are used widely in current practice. Spreader grafts increase the angle of the internal nasal valve by widening of the dorsal root. They do not however adequately prevent indrawing of the lateral nasal wall due to a flail upper lateral cartilage, a problem that was addressed by the development of the batten graft placed in the scroll region [6]. We use the two techniques in combination, as we believe they have a cumulative benefit in the correction of the majority of cases of INVI.

CONCLUSION

The combined use of combined batten and spreader grafts for the correction of INVI in normal or narrow nasal vaults is effective without compromising cosmesis. This subgroup accounts for the majority of our cases of INVI.

We recommend routine assessment of all patients presenting with nasal obstruction for INVI.

REFERENCES

1. Constantian MB, Clardy RB (1996) The relative importance of septal and nasal valvular surgery in correcting airway obstruction in primary and secondary rhinoplasty. *Plast Reconstr Surg* 98: 38-54.
2. Toriumi DM, Josen J, Weinberger M, Tardy ME Jr (1997) Use of alar batten grafts for correction of nasal valve collapse. *Arch Otolaryngol Head Neck Sur* 123: 802-808.
3. Sheen JH (1984) Spreader graft: a method of reconstructing the roof of the middle nasal vault following rhinoplasty. *Plast Reconstr Surg* 73: 230-239.
4. Bridger GP (1970) Physiology of the nasal valve. *Arch Otolaryngol* 92: 543-553.
5. Kern EB (1973) Rhinomanometry. *Otolaryngol Clin North Am* 6: 863-874.
6. Goode RL (1985) Surgery of the incompetent nasal valve. *Laryngoscope* 95: 546-555.

Elias Koury
46 Queens Gate Terrace
South Kensington
London SW7 5PJ
United Kingdom

Tel: +44-20-7584-0710
E-mail: Elias@london.com