

Isolated fibrous dysplasia of the sphenoid sinus*

Fuat Buyuklu¹, Erkan Tarhan¹, Ozcan Cakmak¹, Nuri Ozgirgin¹, Unser Arikan²

¹ Baskent University Faculty of Medicine, Department of Otorhinolaryngology, 06490, Ankara, Turkey

² Baskent University Faculty of Medicine, Department of Pathology, 06490, Ankara, Turkey

SUMMARY

Fibrous dysplasia is an uncommon benign bone disorder of unknown etiology in which normal medullary bone is replaced by fibrotic and osseous tissue. Solitary involvement of the sphenoid sinus is unusual. Here, we present the case of a 28-year-old man complaining of occipital and vertical headache. Imaging modalities demonstrated an expansile lesion filling the entire sphenoid sinus. Biopsy specimen was obtained by endoscopic sphenoidotomy. Diagnosis of fibrous dysplasia was made by imaging results and pathologic examination.

Key words: fibroosseous lesion, fibrous dysplasia, monostotic form, paranasal sinus, isolated sphenoid sinus lesion

INTRODUCTION

Fibrous dysplasia (FD) is a rare bone disease that may affect any part of the skeletal system; however, it shows a tendency for facial and cranial bones most frequently located in the mandible and maxilla [1]. Paranasal sinuses are rarely involved [2]. Otolaryngologists are concerned about FD because of its potential to cause deformity and dysfunction in the facial and cranial bones [1]. FD manifests as a defect in osteoblastic differentiation and maturation originating in the mesenchymal precursor of the bone [1]. The various stages of bone metaplasia are detected histologically and show progressive replacement of cancellous bone by fibrous tissue [2].

McCune and Bruch first described the disease in 1937 and reported that this pathologic condition was a separate clinical entity among the abnormalities of bone formation [1]. Lichtenstein first suggested the term fibrous dysplasia in 1938 [2]. Currently, the precise etiology is not known. Abnormal intracellular regulation of cyclic adenosine monophosphate or protein kinase A has been proposed as a possible etiologic factor in the development of FD by Lee and coworkers [3]. Other researchers have proposed that the pattern and distribution of FD depends on which tissue contains the mutated gene [4].

This locally destructive disease may affect one bone (monostotic) or several bones (polyostotic). The McCune-Albright syndrome is characterized by polyostotic FD with associated endocrinopathy, precocious puberty and cutaneous hyperpigmentation [5]. Ramsey and coworkers have classified the McCune-Albright syndrome as a third type of FD [2]. There is no alteration between these forms; therefore, the monostotic form is not a precursor to the polyostotic form [6]. Regarding ethnicity, 80% of all cases of FD are seen in whites, 2% in blacks, and 1% in Asians [1]. Lesions are generally expected to stabilize at puberty [7]. Malign degeneration is reported 0.5 %

of patients [8]. In this paper, we report a rare case of a patient with FD of the sphenoid sinus.

CASE REPORT

A 28-year-old man presented to our institution with a 5-year history of occipital and vertical headache. He was otherwise healthy and completely asymptomatic except for the headache. Results of physical, otolaryngological, and neurological examinations were unremarkable. Further workup consisted of paranasal computed tomography (CT) for the headache. CT scan demonstrated a sclerotic and expansile lesion filling the entire sphenoid sinus with heterogeneous ossifications that were "ground-glass-like" in appearance, which are characteristic of FD (Figure 1a, b). The imaging modalities revealed very close proximity to the optic canals and cavernous sinuses. Other paranasal sinuses and the skull base were not involved by the lesion.

Magnetic resonance imaging (MRI) revealed a 3.7 x 3.3 cm lesion in the sphenoid sinus that showed low signal intensity on T1 and T2 weighted images (Figure 2). Postcontrast MRI showed heterogeneous contrast enhancement. Owing to the unresectable appearance of the tumor, biopsy was planned via an endoscopic sphenoidotomy. The posterior third of the middle turbinate was resected to better expose the sphenoid recess. The lesion had adhered itself to the anterior wall of the sphenoid sinus. As the lesion was very hard and resembled bone, a biopsy specimen could only be removed by drilling the anterior wall of the sphenoid sinus and adherent lesion to avoid any complication.

Gross examination of the specimen revealed irregular pieces of somewhat-firm pink-and-cream-colored tissue measuring 1 x 1 x 0.6 cm. Following decalcification, histological analysis revealed fibroblastic-looking cells in the stroma of anastomosing bony trabeculae, some of which resembled Chinese letters.

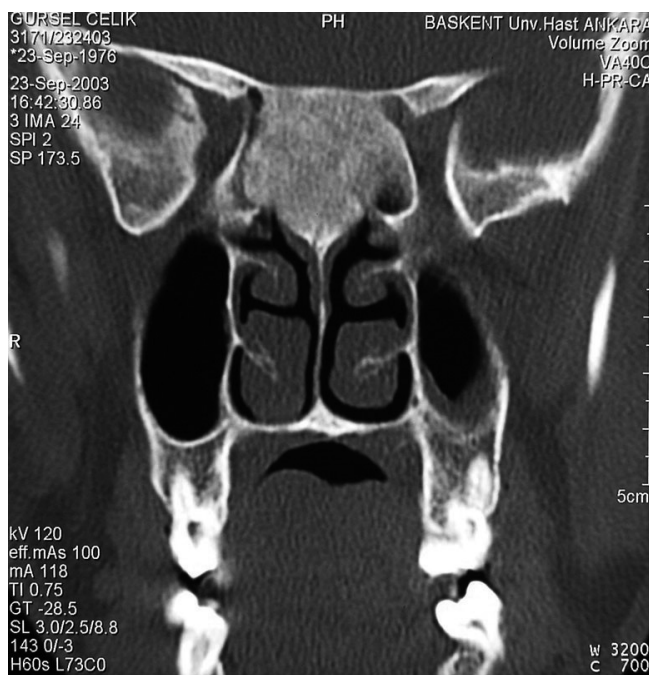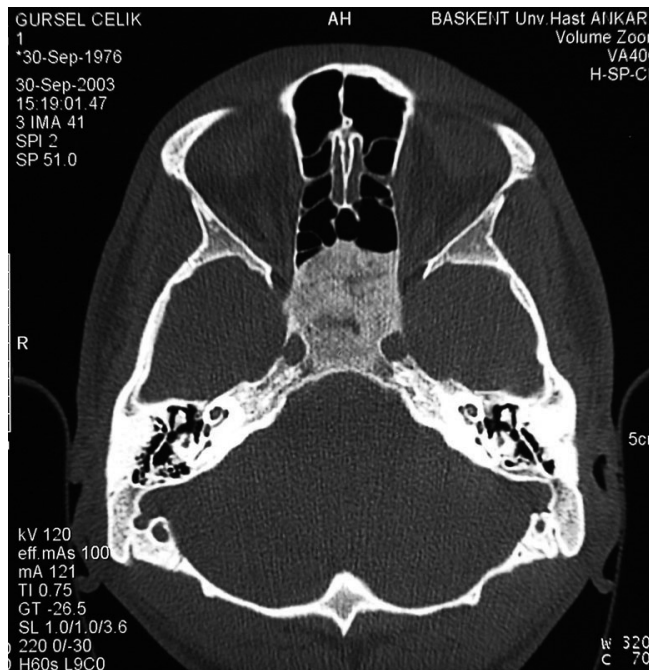


Figure 1a, b. CT scan demonstrating a sclerotic and expansile lesion located in the entire sphenoid sinus with heterogeneous ossifications and "ground-glass-like appearance" Axial(a) and coronal(b) views.

No osteoblastic activity was noted around the bony spicules. There was no sclerotic bone tissue. Overall, these findings were consistent with FD (Figure 3). Conservative strategy with routine follow-up was planned. The patient has been in our clinic every 6 months, and his radiological findings and clinical examinations have remained stable for 12 months.

DISCUSSION

FD is usually diagnosed during the first 2 decades of life and

mostly regresses at puberty, even though in adulthood FD may grow [2, 5]. It is more common in women, with the maxillas most commonly affected. Involvement of the ethmoid and sphenoid sinuses is uncommon [5]. In 1997, Lawson and colleagues reviewed the isolated sphenoid sinus lesions seen at Mount Sinai Medical Center from 1974 to 1996. They found 2 cases of FD in a total of 132 isolated sphenoid sinus lesions [8]. In 1999, Sethi and colleagues also reviewed 21 isolated sphenoid lesions and found only 1 patient with FD [9]. Recently, Cakmak and coworkers reviewed all of the isolated sphenoid sinus lesions seen at the Mayo Clinic between 1935 and 1998. These authors found 5 cases of FD in a total of 182 isolated sphenoid sinus lesions [10]. Several sporadic cases of isolated sphenoid sinus involvement have also been reported [2, 11-14].

FD produces a slow, progressive substitution of bone by irregular proliferative isomorphic fibrous tissue, separated with badly formed and irregularly arranged trabeculae of woven bone [1]. Osteoblastic mesenchymal tissue undergoes irregular development, resulting in a condition with a variable growth rate [5]. The etiology of this disorder remains elusive.

FD has 3 different variants: type 1, monostotic (one bone involvement); type 2, polyostotic (multiple bone involvement); and type 3, the McCune-Albright syndrome. The mildest form is type 1, and it is also the most common, comprising approximately 70% of the cases. It usually involves the ribs and craniofacial bones and is diagnosed in the second and third decades of life. The polyostotic form, accounting for 30% of the cases, is generally seen in childhood. Patients with the polyostotic form are predisposed to more severe, usually unilateral, skeletal and craniofacial involvement [4]. Endocrinopathy is accompanied in 3%-5% of polyostotic FD [1]. The McCune-Albright syndrome, comprising only 3% of the cases, is the most severe form of the disorder and is characterized by bony involvement accompanied by pigmented skin lesions and asexual precocity and hyperthyroidism [4, 7].

The craniofacial region is involved in 25% of the patients with monostotic FD, and in the polyostotic variant this involvement is approximately 40%-60%. Because the most frequent form of FD is the monostotic type, most patients with craniofacial FD have the monostotic variant. The most commonly involved anatomic regions are, in decreasing order, the maxilla, mandible, and the frontal, sphenoid, ethmoid, and temporal bones [1].

The most common presenting symptoms of craniofacial FD are painless swelling and facial deformity. FD may produce an expansile development, and it may involve the nasal fossae, paranasal sinuses, orbits, and temporal bone, causing a variety of functional disorders [7]. When the sphenoid sinus involved, the most common symptoms are headache, diplopia, visual problems, nasal stuffiness, and ptosis [10].

Radiological features are characteristic but nonpathognomonic, so definitive diagnosis requires histopathological confirmation by biopsy. FD is usually seen as an expansile osseous lesion,

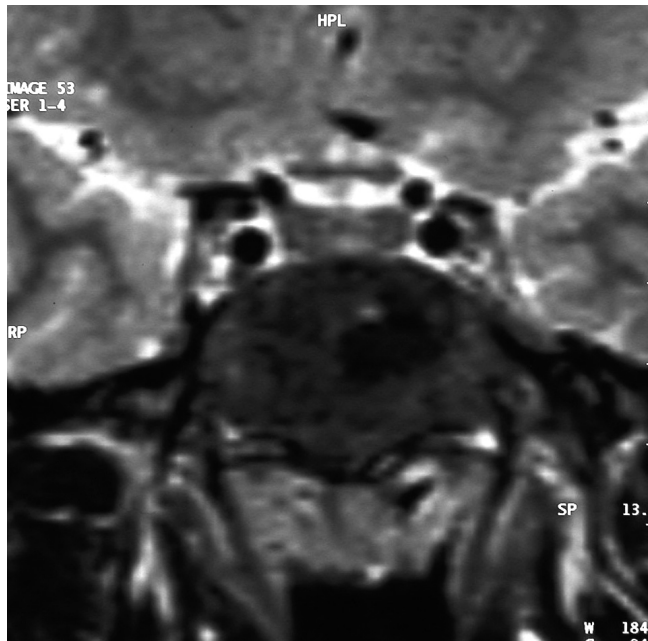


Figure 2. T1-weighted MRI scans of the lesion showing low signal intensity in the sphenoid sinus.

without a well-defined border, and thinned cortical bone. If there is no associated fracture, a periosteal reaction will not be detected. The radiographic manifestation varies, depending on the proportion of fibrous to osseous tissue [7].

Radiographic patterns of FD have been classified as pagetoid, sclerotic, and cystlike [2]. The pagetoid form resembles Paget's disease and is seen in 56% of all cases. It is characterized by alternating zones of radiodense and radiolucent areas, and it generally appears in persons over 30 years of age [7, 11]. The sclerotic pattern is seen in 23% of the patients and is frequently observed in the monostotic type. The lesion is homogeneously dense and is accompanied by bone expansion [7]. The cystlike pattern is seen in 21% of the patients and is characterized by a spherical or oval shape and well-defined radiolucency surrounded by a dense rim, resembling an eggshell [2, 7].

CT is valuable for defining the extent of disease, preparing for surgical planning, and in follow-up for measuring growth rate. A "ground-glass-like" appearance is characteristic of FD. CT findings are pathognomonic and helpful in monitoring the progress of the disease [2, 6]. The range of attenuation coefficients is generally 70 to 130 Hounsfield units (HU), whereas in other diseases, such as osteomyelitis, the tumors have lower attenuation coefficients of 20 to 40 HU [2, 7].

MRI of the FD displays nonspecific signal characteristics, with low signal intensity on T1-weighted images and low-to-high signal intensity on T2-weighted images [2]. The lesion shows moderate-to-intense enhancement with gadolinium. MRI helps to define the fibrous tissue of the lesion and the extent of the pathology.

Paget's disease, ossifying fibroma, aneurysmal bone cysts, giant cell tumor, giant cell reparative granuloma, and brown tumor of hyperparathyroidism must be considered in the differential

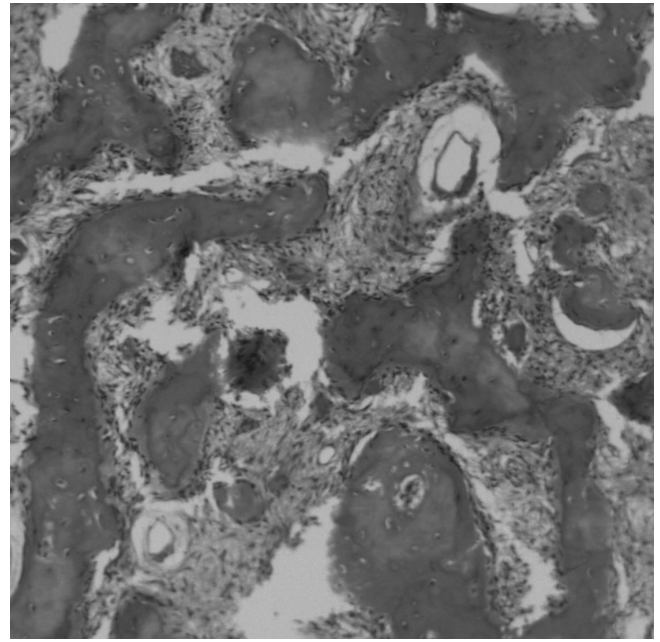


Figure 3. Biopsy specimen showing fibrous dysplasia: irregular spicules and trabeculae of bone with a stromal component containing fibroblastic spindle cells (Hematoxylin-eosin stains x 10).

diagnosis of FD [7].

Expansion of FD may become stable at puberty. Since, FD has a benign nature, especially in asymptomatic patients, conservative management is the first choice in planning treatment. Surgery is recommended for patients with progressive deformities, severe functional disorders, or malignant transformation. Our case was limited to the sphenoid sinus and did not have any symptom other than headache. Therefore, he did not require further treatment, and has shown no progression of the FD for over 12 months follow-up. Sarcomatous alterations have been reported in about 0.5% of cases, mostly in the craniofacial region. Osteosarcoma is the most common secondary tumor in FD. Radiation therapy is contraindicated owing to the high risk of malign transformation [2, 9].

In conclusion, isolated sphenoid sinus FD is rare. Complications may appear because of local extensions. Because the disease is benign in nature, conservative management is the preferred choice of treatment, and surgery should be reserved for functional and aesthetic deformities, as well as in case of threat to vital structures. Owing to the potential risk for malignant change, cautious clinical and radiological evaluation and close follow-up are required.

REFERENCES

1. Cakmak O, Shohet MR, Kern EB (2000) Isolated sphenoid sinus lesions. *Am J Rhinol* 14: 13-19.
2. Commins DJ, Tolley NS, Milford CA (1998) Fibrous dysplasia and ossifying fibroma of the paranasal sinuses. *J Laryngol Otol* 112: 964-968.
3. Espinosa JM, Elizalde A, Aquerreta JD, Alcalde J, Zubieta JL (1998) Fibrous dysplasia of the maxilla. *Ann Otol Rhinol Laryngol* 107: 175-177.

4. Faraci RP, Ketcham AS (1975) Fibrous dysplasia of the sphenoid sinus in an adolescent male. *J Surg Oncol* 7: 461-465.
5. Gillman G, Bryson PC, Rao UN (2004) Radiology Quiz Case 1: Diagnosis. *Arch Otolaryngol Head Neck Surg* 130: 479.
6. Lawson W, Reino AJ (1997) Isolated sphenoid sinus disease: an analysis of 132 cases. *Laryngoscope* 107: 1590-1595.
7. Lustig LR, Holliday MJ, McCarthy EF, Nager GT (2001) Fibrous dysplasia involving the skull base and temporal bone. *Arch Otolaryngol Head Neck Surg* 127: 1239-1248.
8. Mladina R, Manojlovic S, Markov-Glavas D, Heinrich Z (1999) Isolated unilateral fibrous dysplasia of the sphenoid sinus. *Ann Otol Rhinol Laryngol* 108: 1181-1184.
9. Mueller DP, Dolan KD, Yuh WT (1992) Fibrous dysplasia of the sphenoid sinus. *Ann Otol Rhinol Laryngol* 101: 100-101.
10. Ozbek C, Aygenc E, Fidan F, Tuna EU, Ozdem C (2000) Fibrous dysplasia of the temporal bone. *Ann Otol Rhinol Laryngol* 112: 654-656.
11. Papadakis CE, Skoulakis CE, Prokopakis EP, Nikolidakis AA, Bizakis JG, Velegrakis GA, Helidonis ES (2000) Fibrous dysplasia of the temporal bone: report of a case and a review of its characteristics. *Ear NoseThroat J* 79: 52-57.
12. Sethi DS (1999) Isolated sphenoid sinus lesions: diagnosis and management. *Otolaryngol Head Neck Surg* 120: 730-736.
13. Srinivas N, DeLong SR, Amilineni VK (2000) Monostotic fibrous dysplasia of the sphenoid sinus: a serendipitous finding on a bone scan. *Clin Nucl Med* 25: 477-479.

Erkan Tarhan, MD
Baskent University Faculty of Medicine
Department of Otorhinolaryngology
Bahcelievler
06490, Ankara
Turkey

Tel: +90-533-810 2567

Fax: +90-312-215 7597

E-mail: erkant@baskent-ank.edu.tr