

Juvenile angiofibroma of the maxillary sinus*

J. Panesar¹, B. Vadgama², G. Rogers¹, A.D. Ramsay², B.J. Hartley¹

¹ Department of Otolaryngology, Great Ormond Street Hospital for Children, Great Ormond Street, London, WC1N 3JH, United Kingdom

² Department of Histopathology, Camelia Botnar Laboratories, Great Ormond Street Hospital for Children, Great Ormond Street, London, WC1N 3JH, United Kingdom

SUMMARY

Primary extra-nasopharyngeal sites of angiofibromas are extremely unusual. We describe a rare case of extra-nasopharyngeal angiofibroma in a one year old child arising from the left maxilla and indirectly involving the lacrimal system. The initial presentation was of a swelling in the region of the left medial canthus. Only four cases of extra-nasopharyngeal angiofibromas in children below the age of two have been described. We review the literature on what is known about extra-nasopharyngeal angiofibromas.

Key words: angiofibroma, extra-nasopharyngeal, child

INTRODUCTION

Juvenile nasopharyngeal angiofibromas are highly invasive, fibro-vascular tumours that occur almost exclusively in male adolescents. They originate from the region of the sphenopalatine foramen and enlarge to fill the postnasal space. Because of the close proximity to the nasopharynx and the ease with which they invade this site, they are also commonly referred to as nasopharyngeal angiofibromas. Nasopharyngeal angiofibromas may also extend to involve the sphenoid sinus superiorly, the nasal fossa anteriorly and the pterygopalatine fossa laterally. The origin is always specific to the sphenopalatine foramen and pterygoid plates regardless of the extent of local invasion. (Llyod et al., 1992). Angiofibromas that do not originate from the area around the sphenopalatine region are rare and are referred to as extra-nasopharyngeal. (Sarpa and Novelly, 1989) The primary site of these extra-nasopharyngeal angiofibromas is quite varied (Gaffney et al., 1997) and tumours have been found in such diverse sites as the larynx and middle cranial fossa. (Huang et al., 2000) We describe a very rare case of extra-nasopharyngeal angiofibroma arising from the left maxilla. The presentation was unusual as the mass was only apparent after a fall and initially mimicked a primary lesion of the lacrimal system. A variety of pathological processes can give rise to unilateral maxillary swelling in a child and clinically such masses are diagnostically challenging. The differential diagnosis is extremely varied involving a number of congenital and acquired conditions of the maxilla and its contiguous structures (Koch and Myers, 1999) We have also examined the table first compiled by Ali and Jones in 1982 and updated it with more recent extra-nasopharyngeal cases, including ours (Table 1).

CASE PRESENTATION

A one year old boy was referred to the ENT outpatient for assessment of a four week swelling that was present on the left side of his face. The swelling came on after he fell and injured his nose. Shortly after his fall he developed a tender swelling in his left medial canthus with pus coming out of the inferior canaliculus. He became quite unwell and was admitted for intravenous antibiotics. The antibiotics cleared the pus and the inflammation but he was still left with a residual swelling on the left side of his face. He was now snoring and experiencing some difficulty feeding. The parents gave no history of upper respiratory tract infection, epistaxis or nasal congestion. The child was born at term and had had an uneventful birth history. His growth was age appropriate and he was achieving all developmental milestones.

Examination revealed a firm left paranasal protuberance close to the left medial canthus. Anterior rhinoscopy revealed the mass to be extending into the nasal vestibule causing right sided septal deviation. Computed tomography (CT) imaging showed a non-enhancing expansile lesion in the anterior aspect of the maxillary sinus close to the nasolacrimal duct (Figure 1). The consulting ophthalmologists felt that the lesion could be a nasolacrimal cyst. An ultrasound was therefore obtained and suggested a cystic mass. At surgery it was found not to be cystic but solid. Enucleation of the mass was undertaken through the nose. A small bony opening into the maxillary antrum was made and the cyst cavity entered. Gray soft tissue was found in the cyst cavity and sent for histological examination. The cavity was completely cleared and examined endoscopically. The left nasolacrimal duct system was also probed and was felt to be patent. The nasal cavity was packed

Table 1. Previously reported site of origin of extranasalpharyngeal angiofibromas.

Number	Author	Site of origin	Age	Sex	Number	Author	Site of origin	Age	Sex
1	Kleynand Rysse, 1914	Ethmoid sinus	30 years	F	30	Beeden and Alexander, 1971	Oropharynx and hypopharynx	1 year	M
2	Tsuru, 1936	Maxillary sinus	33 years	F					
3	Munson, 1941	Maxillary sinus	15 years	M	31	Iyer et al, 1971	Middle cranial fossa	24 years	M
4	Radcliffe, 1951	Ethmoid sinus	16 years	M	32	Charkabti et al, 1973	Maxillary sinus	17 years	M
5	Alajmo and Fini-Storchi, 1962	Maxillary sinus	58 years	M	33	Rye et al, 1973	Maxillary sinus	17 years	M
6	Alajmo and Fini-Storchi, 1962	Maxillary sinus	6 years	M	34	Stewart and O'Brien, 1973	Molar and retromolar	10 years	M
7	Hora and Weller, 1961	Pteryomaxillary fissure, infratemporal region	21 years	M	35	Ramajaneyulu, 1974	Maxillary sinus	17 years	M
8	Irby, 1961	Cheek and infratemporal fossa	21 years	M	36	Yamagiwa, 1974	Sphenoid sinus	14 years	M
9	Whitlock, 1961	Cheek	16 years	M	37	Isherwood et al, 1975	Pteryomaxillary fissure, infratemporal region	13 years	M
10	Hora and Brown, 1962	Maxillary sinus	13 years	M	38	Krutchkoff, 1977	Maxillary sinus	12 years	M
11	Furstenborg and Boles, 1963	Ethmoid sinus	1 month	M	39	Reddy et al, 1979	Molar and retromolar area	14 years	F
12	Reddy and Farb, 1963	Sphenoid sinus	50 years	M	40	Ali and Jones, 1982	Tonsil	28 years	F
13	Minicone, 1964	Conjunctiva	17 years	M	41	Juul, 1982	Maxillary sinus	27 years	F
14	Morita, 1965	Larynx	29 years	M	42	Obiako et al, 1983	Roof of nasal cavity	12 years	M
15	Ogura et al, 1965	Maxillary sinus	16 years	M	43	Hiraide and Matsubara, 1984	Nasal septum	13 years	M
16	El-Barbary, 1966	Horizontal part of facial nerve	38 years	M	44	Johnson et al, 1987	Parapharyngeal space	25 years	M
17	Baldanzini, 1967	Conjunctiva	33 years	F	45	Sarpa and Novelli, 1989	Nasal septum	9 years	M
18	Chaikovskii, 1967	External nose	14 years	F	46	Kitano et al, 1992	Maxillary sinus	13 years	M
19	Hiranandani et al, 1967	Ethmoid sinus	30 years	F	47	Manjalay et al, 1992	Maxillary sinus	Newborn	M
20	Stricker, 1967	Maxillary sinus	22 years	M	48	Hersh et al, 1995	Nasal vault	69 years	F
21	Szczepanski and Perowski, 1967	Ethmoid sinus	13 years	M	49	Alvi et al, 1996	Inferior turbinate	78 years	F
22	Borisov, 1968	Esophagus	24 years	M	50	Gaffney et al, 1997	Inferior turbinate	9 years	M
23	Marill and Boutovsky, 1968	External ear	28 years	F	51	Peloquin et al, 1997	Middle turbinate	31 years	F
24	Voision et al, 1968	Trachea	57 years	M	52	Schick et al, 1997	Lacrimal sac	15 month	M
25	Canciullo, 1969	Larynx	30 years	F	53	Schick et al, 1997	Paranasal sinus	9 years	M
26	Manigla et al, 1969	Maxillary sinus	15 years	M	54	Schick et al, 1997	Sphenoid sinus	6 years	M
27	Perko et al, 1969	Maxillary sinus	33 years	F	55	Huang et al, 2000	Middle turbinate	14 years	M
28	De Blanc and Chretien, 1970	Bifurcation of common carotid artery	52 years	M	56	Handa et al, 2001	Nasal septum	8 years	M
29	Pathak, 1970	Maxillary sinus	18 years	M	57	Panesar et al, 2003	Maxillary sinus	1 year	M

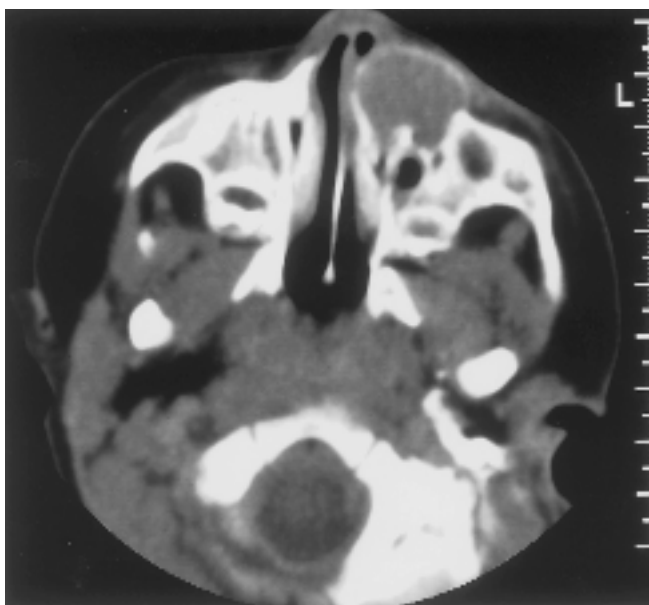


Figure 1. Axial CT scan showing a non-enhancing expansile lesion in anterior aspect of left maxillary sinus.

because of bleeding. Postoperatively the boy had an uneventful recovery and was discharged home with a further ENT outpatient appointment two weeks later. Histological examination of the cyst contents was felt to be non-diagnostic but did show mixed connective tissue elements. There was no evidence of any epithelial lesion or suggestion of malignancy. A possible diagnosis of angiofibroma was raised. Out-patient examination at two weeks continued to reveal a mass at the site of the original lesion. The extension into the nasal cavity was however absent. Six weeks after his drainage procedure the boy had another CT scan. This confirmed that the mass had recurred. A formal midfacial degloving procedure was therefore undertaken and the tumour excised completely. Operative findings showed a nodular antral mass causing partial erosion of the anterior and lateral maxillary wall; there was no extension of the mass posteriorly. Blood loss was minimal and the child had an uneventful recovery.

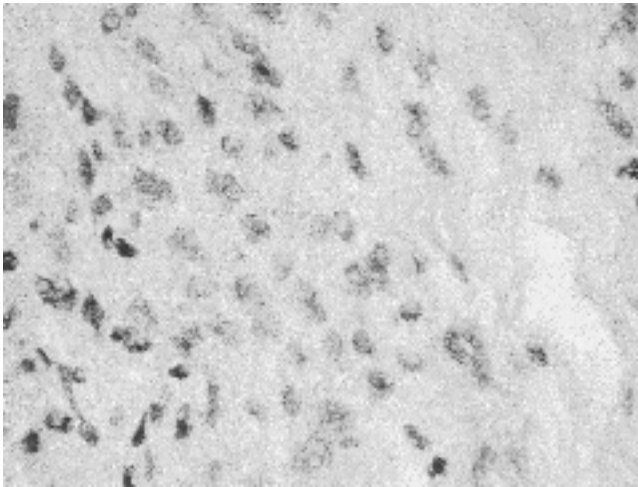


Figure 2. Microscopic examination showing a fibrovascular lesion composed of a moderately cellular proliferation of bland plump spindle cells set within variably loose fibrocollagenous stroma.

Histopathology

The resection specimen submitted for histological assessment consisted of an irregular grey-tan firm mass of tissue measuring 2 x 1 x 0.4 cm with separate tiny fragments of bony tissue. Microscopic examination revealed a fibrovascular lesion composed of a moderately cellular proliferation spindle cells set in loose fibrocollagenous stroma (Figure 2). The cells contained ovoid nuclei, apoptoses and mitotic activity were rare. The stroma was traversed by numerous vessels with a single-layered endothelial lining (Figure 3). Haemosiderin deposition as evidence of previous haemorrhage was present. Tumour invaded the intratrabecular spaces within the fragments of bone. Immunohistochemical staining of the proliferation showed patchy stromal positivity with vimentin only and CD34 highlighted the vasculature. The overall histological features were typical of a juvenile angiofibroma despite the young age of the patient and unusual site of origin.

DISCUSSION

Juvenile nasopharyngeal angiofibromas are benign, unencapsulated, fibro-vascular lesions that account for less than 0.5% of all head and neck tumours. They usually arise from the base of the pterygoid plate, the horizontal ala of the vomer and sphenopalatine foramen. They are most commonly found in young adolescent males and appear to be more common in the Middle East and Indian subcontinent (Gullane et al., 1992). These highly vascular tumours invade the nasopharynx, nose and skull base and commonly present with epistaxis and nasal obstruction. Angiofibromas that do not arise from the vicinity of the sphenopalatine foramen or pterygoid plates are referred to as extra-nasopharyngeal and to date 56 such cases have been described (Huang et al., 2000; Handa et al., 2001). The most common primary extra-nasopharyngeal site for these tumours is the maxillary sinus. Other primary extra-nasopharyngeal sites have included the ethmoid and sphenoid sinuses, nasal

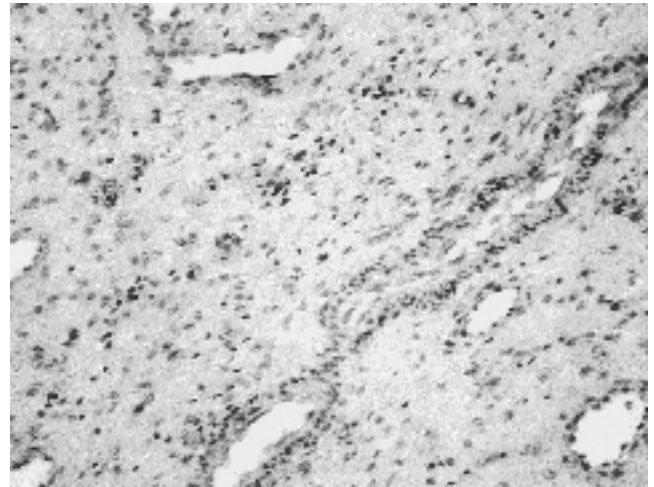


Figure 3. Histopathology of the tumour showing stroma traversed by numerous vessels of varying calibre, all of which have a single-layered endothelial lining.

septum, middle and inferior turbinates, tonsil, parapharyngeal space, ear, trachea, larynx, middle cranial fossa, infratemporal fossa, tonsil, retromolar region and conjunctiva (Ali and Jones, 1998). The mean age of presentation of the tumour in extra-nasopharyngeal sites is 22 years and the male to female ratio is roughly 3:1. In contrast nasopharyngeal angiofibroma presents almost exclusively in adolescent males with a mean age range between 14 to 17 years; female presentation is very rare (Peloquin et al., 1997). It is unclear why this discrepancy in the age of presentation and sex predilection exists between the two different types of angiofibromas.

Congenital cases of angiofibromas and those occurring within the first two years of life are extremely rare (De Vincentiis and Pinelli, 1980). A search of the medical literature has revealed only four such cases, ours being the fifth case (Furstenberg and Boles, 1962; Beeden and Alexander, 1971; Manjalay et al, 1992; Schick et al, 1997). The first case of congenital angiofibroma with histologic proof and other corroborative data was described by Manjalay et al. (1992). A firm maxillary swelling with intraoral extension was noted immediately after birth in a new born baby boy (Furstenberg and Boles, 1962). Beeden and Alexander (1971) described two cases of extra-nasopharyngeal sites involving the ethmoid sinus in a 1 month old, and pharynx in a 1 year old boy, respectively. More recently Schick et al. (1997) describe a case of extra-nasopharyngeal fibroma arising anterior and medial to the lacrimal sac in a 15 month old boy. In their case report the child presented with a swelling close to the medial angle of the left eye. There was no involvement of the lacrimal system although the tumour had displayed the lacrimal sac laterally and had extended into the maxillary and anterior ethmoid sinuses. The location of the tumour in our case was also in the vicinity of the lacrimal system with extension into the maxillary sinus. Our child initially presented with pain and swelling of the lower eyelid, symptoms that were suggestive of acute dacryocystitis. When the

swelling did not completely settle a CT scan was obtained. This suggested a cystic lesion and the mass was thought to be a nasolacrimal cyst. Nasolacrimal cysts typically present with swelling and erythema of the lower eyelid and a palpable mass lateral to the medial canaliculus.

Diagnosis of a nasopharyngeal angiofibroma can be confidently made by CT and MRI. Enlargement of the sphenopalatine foramen with erosion of the pterygoid plates are regarded as pathognomic radiological features and are best seen on CT. T1-weighted MRI will show a typical "salt and pepper" appearance caused by the increased vascularity of the tumour. Extranasopharyngeal angiofibromas are harder to diagnose radiologically because of their atypical location and lack of characteristic features. Excision biopsy precipitates epistaxis and may be non-diagnostic. (Manjalay et al., 1992) Complete excision is therefore undertaken for both therapeutic and diagnostic purposes.

Treatment of extra-nasopharyngeal angiofibromas is surgical and several approaches have been described. The approaches described reflect the diverse locations of the tumour. Huang et al. (2000) and Handa et al. (2001) did a lateral rhinotomy with a partial maxillectomy on tumours that were limited to the nasal vault. Manjalay et al. (1992) used a sub labial incision with carbon dioxide laser to extirpate the tumour in their newborn baby. Schick et al. (1997) advocate an endonasal microendoscopic approach for tumours that are limited to the nasal cavity and paranasal sinuses. The endoscope and KTP laser-assisted surgery has also been used (Hazarika et al., 2002). We used a midfacial degloving approach. This has the advantage of avoiding an external scar and providing very good access to the area of concern. Whatever the approach used, it has to take into account the size and location of the tumour and experience of the surgeon.

Unilateral maxillary swellings present a diagnostic challenge to the clinician as they may arise from a variety of pathological processes. In disease processes involving the maxilla and contiguous structures, common as well as rare pathologies need to be considered. Extra-nasopharyngeal angiofibroma is a rare condition; it however forms part of the differential diagnosis of nasal and paranasal masses.

REFERENCES

1. Ali S, Jones WI (1982) Extranasopharyngeal angiofibroma. *J Laryngol Otol* 96: 559-565.
2. Alvi A, Myssiorek D, Fuchs A (1996) Extranasopharyngeal angiofibroma. *J Otolaryngol* 25: 346-348.
3. Beeden AG, Alexander FW (1971) An unusual pharyngeal tumour. *J Laryngol Otol* 85: 733-735.
4. DeVincentiis G, Pinelli V (1980) Rhinopharyngeal angiofibroma in the pediatric age group. Clinical-statistical contribution. *Int J Ped Otorhinolaryngol* 2: 99-122.
5. Gaffney R, Hui Yau, Vojvodich S, Forte V (1997) Extranasopharyngeal angiofibromas of the inferior turbinate. *Intl J Ped Otorhinolaryngol* 40: 177-180.
6. Gullane PJ, Davidson J, O'Dwyer T et al (1992) Juvenile angiofibromas: A review of the literature and a case series report. *Laryngoscope* 102: 928-933.
7. Handa KK, Kumar A, Singh MK, Chhabra AH (2001) Extranasopharyngeal angiofibromas arising from the nasal septum. *Intl J Ped Otorhinolaryngol* 58: 163-166.
8. Hazarika P, Nayak DR, Balakrishnan R, Raj, G. (2002) Endoscopic and KTP laser-assisted surgery for juvenile nasopharyngeal angiofibromas. *Am J Otolaryngol* 23: 282-286.
9. Huang RY, Damrose EJ, Blackwell KE, Cohen AN, Calceterra TC (2000) Extranasopharyngeal angiofibroma. *Intl J Ped Otorhinolaryngol* 56: 59-64.
10. Koch BL, Myer CM (1999) Presentation and diagnosis of unilateral maxillary swelling in children. *Am J Otol* 20: 106-129.
11. Llyod G, Howard D, Phelps P (1999) Juvenile angiofibroma: The lessons of 20 years of modern imaging. *J Laryngol Otol* 13: 127-134.
12. Peloquin L, Klossek JM, Vasso-Brusa F (1997) A rare case of nasopharyngeal angiofibroma in a pregnant woman. *Otolaryngol Head Neck Surg* 117: S111-S114.
13. Sarpa JR, Novelly NJ (1989) Extranasopharyngeal angiofibroma. *Otolaryngol Head Neck Surg* 101:693-697.
14. Schick B, Kind M, Draf W, Weber R, Lackmann GM (1997) Extranasopharyngeal angiofibroma in a 15 month old child. *Int Pediatr Otorhinolaryngol* 42: 135-140.
15. Schick B, Kind M, Schwarzkopf G, Weber R, Draf W (1997) Early childhood angiofibroma in an unusual site. *HNO* 45: 1022-1088.
16. Schick B, Kind M, Ishikawa N (1998) Extranasopharyngeal angiofibroma in a 15 year old child. *Int Pediatr Otorhinolaryngol* 43: 99-104.
17. Tsunoda A, Kohda N, Ishikawa (1998) Juvenile angiofibroma limited to the sphenoid sinus. *J Otolaryngol* 27: 37-39.

J. Panesar
Mullions
West End Lane
Stoke Poges
Bucks SL2 4ND
United Kingdom

Tel: +44-1753-669093
E-mail: panesarhome@aol.com