

Eosinophilic angiocentric fibrosis as a cause of nasal obstruction*

A.O. Owa¹, S. Boyle², A. P. Gallimore³

¹ ENT Department, Northwick Park Hospital, London, United Kingdom

² Pathology Department, Northwick Park Hospital, London, United Kingdom

³ Farrar-Brown's Laboratory, London, United Kingdom

SUMMARY

We present the tenth case of Eosinophilic Angiocentric Fibrosis (EAF) in the english literature, which presented as nasal obstruction in a patient of Indian descent. The histopathological and clinical features of this underreported condition is discussed as well as other lesions that may show similar features to EAF.

Key words: nasal obstruction, eosinophilic angiocentric fibrosis

INTRODUCTION

Eosinophilic angiocentric fibrosis is a rare benign lesion believed by some to be a mucosal variant of granuloma faciale, which occurs in the skin (Roberts and McCann, 1985). A few cases have been reported in the nose and maxillary sinus with even fewer cases in the subglottic area (Roberts and McCann, 1985; Holmes, 1983; Thompson and Heffner, 2001). The aetiology is not known but some authors believe it might be associated with allergies to an environmental agent (Roberts and McCann, 1985). There is no sex predilection and it tends to occur in young adults unlike granuloma faciale, which tends to occur in older patients. Eosinophilic angiocentric fibrosis (EAF) has only previously been described in Caucasians. We report a case of EAF manifesting as a septal deviation resulting in nasal obstruction in an Asian man.

CASE REPORT

A 41-year-old accountant of Indian extraction was referred to our unit with a 2-year history of increasing nasal obstruction. He complained of no other symptom of note.

The only significant finding on examination was a septal deviation, which was judged to have been interfering with his breathing. A general examination did not reveal any other abnormality. He was subsequently offered a septoplasty.

At operation, a pale coloured fibrous lesion measuring 2.2x 1.3x 0.5 cm was found on the anterior aspect of the left side of the septum. The lesion was very adherent but distinct from the septum. This was completely excised prior to a limited septoplasty and sent for histological examination. This was reported, after a specialist review as eosinophilic angiocentric fibrosis (Figure 1).

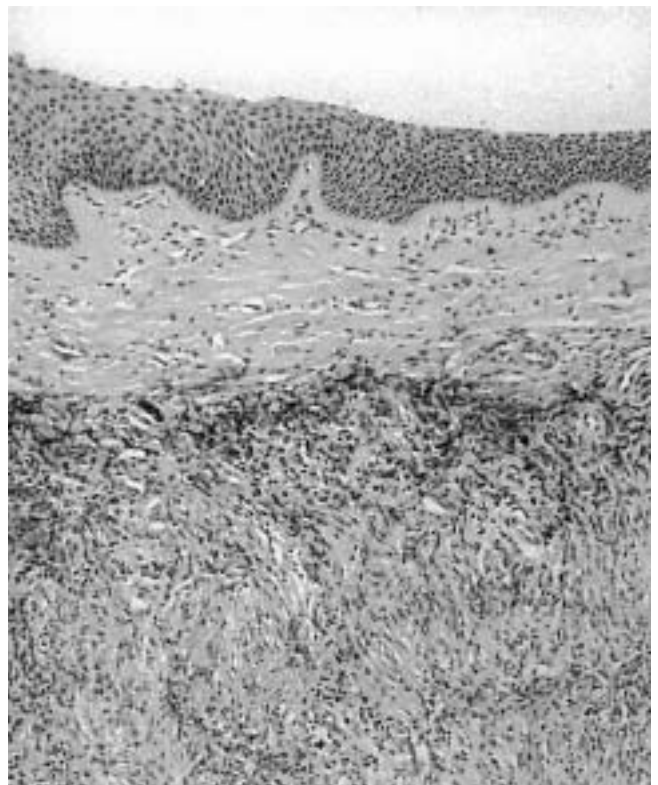


Figure 1. Low power photomicrograph showing the surface epithelium with underlying inflammatory cell infiltrate and fibrosis. The inflammation includes an active venulitis and prominent eosinophils.

The patient made a full recovery, with complete resolution of his symptoms. He is presently on a steroid nasal spray and is under regular review.

DISCUSSION

Few cases of EAF of the nose have been reported in the literature and even fewer cases have been reported in the subglottic area. Roberts and McCabe first coined the term eosinophilic angiocentric fibrosis in 1985, which describes the salient features of the disease. However, the rarity of this lesion may either be due to underreporting or it may be reported as non-specific fibrosis.

EAF shares similar features with granuloma faciale of the skin with which it may be associated (Holmes, 1983; Roberts and McCann, 1985; Burns and Roberts et al., 2001). Two phases of development have been described. An early phase, which shows subepithelial infiltration of small blood vessels by eosinophils and to a lesser extent lymphocytes and plasma cells without fibrinoid necrosis and occurs in a patchy fashion around capillaries and venules of the submucosa. The late phase is characterised by perivascular thick fibrous collagen bundles with an onionskin appearance (Figure 2a and b). Eosinophils remain in the tissue as a common finding.

Only ten cases have been reported in the English literature, mainly in the nose with only two cases being reported in the subglottis.

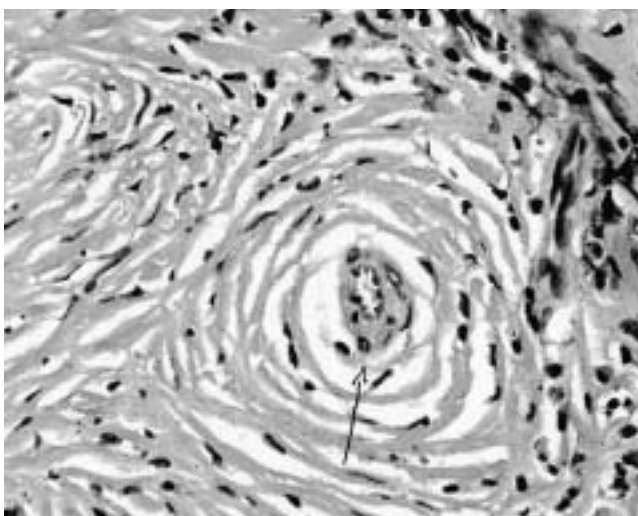
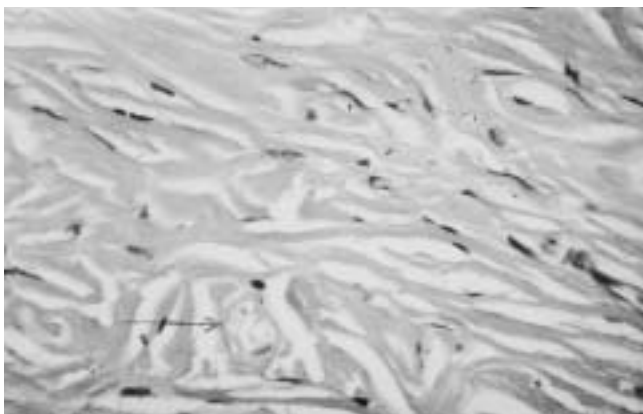


Figure 2a and b. Photomicrograph at high power showing an onion-skin appearance around small vessels due to concentric fibrosis.

The aetiology is unknown, however the clinical presentation in some cases would suggest an allergic origin. It has been found in association with granuloma faciale, indeed some workers (Holmes, 1983; Roberts and McCann, 1985; Burns and Roberts et al., 2001) consider it to be a mucosal variant. Thompson and Heffner describe EAF as a rare submucosal fibrosis, which must be distinguished from other lesions with a similar appearance. They consider sinonasal EAF to be a unique fibroproliferative disorder (Thompson and Heffner, 2001).

EAF must be differentiated from other inflammatory lesions such as Churg-Strauss, Wegener's granuloma and eosinophilic granuloma, which may be distinguished from EAF on clinical and pathological features. The absence of fibrinoid necrosis, true granulomas or giant cell formation would suggest eosinophilic angiocentric fibrosis. Sarcoid may be excluded by the absence of non-caseating granulomas and Sjogren's is typified by glandular involvement and absence of characteristic fibrosis. Specific infections like tuberculosis and leprosy should also be excluded.

Treatment appears to be by surgical excision although there are reports of good results with intralesional steroids (Fageeh et al., 1996; Altermani et al., 1997). Cryotherapy and partial excision are associated with a high recurrence rate.

This patient's presentation was unusual in that it manifested as a septal deviation and the lesion was located on the septum rather than the lateral wall and dorsum of the nose as previously reported by other workers (Altermani et al., 1997). It is also worth noting that the lesion was not identified pre-operatively even though a very experienced surgeon had examined him probably because it appeared to be part of the septum especially as this lesion is also very uncommon which should be a warning to the unwary. We also believe this is the first case reported in a non-Caucasian.

REFERENCES

1. Altermani AM, Pilch BZ, Sakano E, Altermani JM (1997) Eosinophilic angiocentric fibrosis of the nasal cavity. *Modern Pathology* 10: 391-393.
2. Burns BV, Roberts PF, De Carpentier J, Zarod AP (2001) Eosinophilic angiocentric fibrosis affecting the nasal cavity. A mucosal variant of the skin lesion granuloma faciale. *Journal of Laryngology and Otology* 115: 223-226.
3. Fageeh NA, Mai KT, Odell PF (1996) Eosinophilic angiocentric fibrosis of the subglottic region of the larynx and upper trachea. *Journal of Otolaryngology* 25: 276-278.
4. Holmes K (1983) Intranasal granuloma fasciale. *American Journal of Otolaryngology* 4: 184-186.
5. Matai V, Baer S, Barnes S, Boxer M (2000) Eosinophilic angiocentric fibrosis. *Journal of Laryngology and Otology* 114: 563-564.

6. Roberts PF, McCann BG (1985) Eosinophilic angiocentric fibrosis of the upper respiratory tract: a mucosal variant of granuloma fasciale? A report of three cases. *Histopathology* 9: 1217-1225.
7. Roberts PF, McCann BG (1997) Eosinophilic angiocentric fibrosis of the upper respiratory tract: a postscript (letter; comment). *Histopathology* 31: 385-386.
8. Thompson LD, Heffner DK (2001) *American Journal of Clinical Pathology* 115: 243-248.

Anthony Owa
 Specialist Registrar
 Royal National Throat Nose and
 Ear Hospital
 330 Gray's Inn Road
 London WC1X 8EE
 United Kingdom

E-mail: tonyowa@hotmail.com

SOCIETY NEWS

FELLOWSHIPS IN RHINOLOGY

Sponsored by

THE EUROPEAN RHINOLOGIC SOCIETY

Available to four Trainee-Surgeons from Eastern Europe

One place available on each of the following Courses in 2002-2003

International Course on in Functional-Aesthetic Nasal Surgery
 Ulm, Germany, June 20-21 2001
 Course Director: Prof.Dr. G. Rettinger
 Language: English

International Course on FESS (Basic and Advanced Techniques)
 Graz, Austria, July 4-6 2002
 Course Director: Prof.Dr. H. Stammberger
 Language: English

International Course in Functional Corrective Nasal Surgery
 Utrecht, The Netherlands, March 19-22 2002
 Course Director: Dr. A.F. van Olphen
 Language: English

An Endoscopic approach to Rhinosinusitis
 London, United Kingdom, October 9-12 2002
 Course Directors: Prof. V.J. Lund and I.S. Mackay
 Language: English

Sponsorship includes both registration fees and costs of accommodation. Application forms are available from the Secretary of the ERS. Applications should be submitted at least three months before the course starts. Applications and/or queries should be directed to either the President or the Secretary of the European Rhinologic Society.

Prof.Dr. J.M. Fabra Llopiss (President ERS), Department of Otorhinolaryngology, Hospital de la Santa Creu I Santa Pau, San Antonio Ma. Claret 167, E-08025 Barcelona, Spain

Dr. K.J.A.O. Ingels (Secretary ERS), Department of Otorhinolaryngology, University Hospital "St. Radboud", Geert Grooteplein Zuid 18, NL-6525 GA Nijmegen, The Netherlands