

Clinical analysis of submucosal Medpor[®] implantation for empty nose syndrome*

Yuan-Yun Tam¹, Ta-Jen Lee², Chia-Chen Wu², Po-Hung Chang²,
Yi-Wei Chen², Chia-Hsiang Fu², Chi-Che Huang²

Rhinology 52: 35-40, 2014

DOI:10.4193/Rhino13.086

¹ Department of Otolaryngology, Head and Neck Surgery, Keelung Chang Gung Memorial Hospital, Kwei-Shan, Tao-Yuan, Taiwan

***Received for publication:**

June 21, 2013

² Department of Otolaryngology, Head and Neck Surgery, Chang Gung Memorial Hospital and Chang Gung University, Taipei, Taiwan

Accepted: September 2, 2013

Abstract

Background: Empty nose syndrome (ENS) describes symptomatology and radiographic findings after surgeries on turbinates. The treatment of ENS is still debatable.

Purpose: To analyse clinical outcomes of submucosal Medpor[®] implantation for ENS.

Methods: A total of 18 patients underwent submucosal Medpor[®] implantation from 2006 to 2011. We applied SNOT-22 (Sino-Nasal Outcome Test) for statistical survey of the patients' symptoms before and after surgery.

Results: Two patients were lost to follow up after the surgery. Most of the patients developed ENS-related symptoms gradually within 2 years to 16 years after the previous nasal surgery or treatment. The sites of submucosal implantation are mainly septum and nasal floor, unilaterally or bilaterally. There is a significant improvement of SNOT-22 pre-operatively to one year post-operatively.

Conclusions: The symptomatology remains the most important point when dealing with patients with ENS. Submucosal implantation of Medpor[®] is a feasible surgical treatment to ENS. A positive cotton test is suggested for the surgical indication and planning.

Key words: empty nose syndrome, paradoxical nasal obstruction, cotton test, Medpor[®], submucosal implantation

Introduction

Empty nose syndrome (ENS) is an iatrogenic condition, a term which was first coined by Eugene Kern and Monika Sternkvist at the Mayo Clinic in 1994. It describes certain symptomatology and the appearance of radiographic findings after surgeries on turbinates. Though it was discovered initially from imaging studies, mainly computed tomography (CT), at present we diagnose ENS according to a patient's symptoms and there are no objective tests for ENS⁽¹⁾. Paradoxical obstruction is the key symptom of ENS. In addition, patients most commonly complain of dyspnea, nasal and pharyngeal dryness, hyposmia and de-

pression⁽²⁾. The definitive treatment of ENS is still debatable as it is a newly grouped entity of disease existing less than 30 years. Most patients have had unsatisfactory results with conservative medical treatments, such as aggressive nasal irrigation and nasal moisturizers⁽²⁾. Houser has published a study of eight ENS patients who had undergone surgical submucosal implantation of acellular dermis⁽³⁾. Studies of larger case series are quite limited in the related literature. This study presents a retrospective clinical analysis of sixteen patients with ENS who received submucosal implantation of Medpor[®]. We applied statistical analysis on each patient's perioperative symptoms to identify

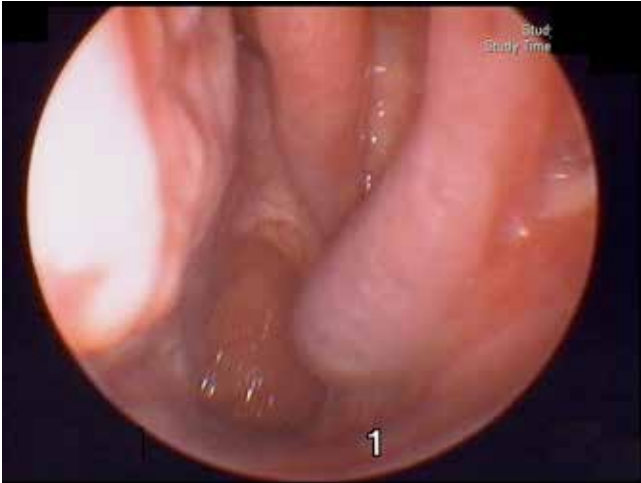


Figure 1. The sinusoscopic finding of a patient with ENS revealed excessively patent left-sided nasal cavity and overly fair view of nasopharynx.

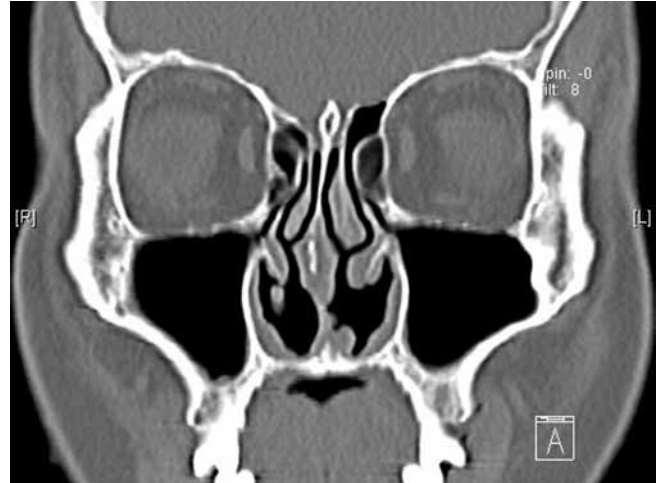


Figure 2. The sinus CT of an ENS patient who received previous inferior turbinectomy showed much widened common nasal cavity and inferior meatus.

the subjective symptoms and the degree of improvement after surgical intervention.

Materials and methods

Study design

The institutional review board of Chang Gung Memorial Hospital had approved this study. We enrolled eighteen patients who were diagnosed as ENS and had undergone submucosal implantation of Medpor® (Porex Surgical Inc.) from 2006 to 2011. The inclusion criteria of ENS were patients with previous surgeries or procedures on turbinates and that their treatment resulted in them having the symptoms of paradoxical nasal obstruction, breathing discomfort and pharyngeal dryness. We applied SNOT-22 (Sino-Nasal Outcome Test) for the statistical survey of the patients' symptoms. The SNOT-22 includes 22 symptoms that were examined in subjects with nasal diseases, which can be a comparative parameter before and after surgery. The symptoms were evaluated within 4 weeks before the submucosal implantation, 3 months and 1 year after the surgery.

Statistical analysis

The analyses were performed using SPSS (version 15.0) software, where p -values < 0.05 were considered to be statistically significant.

Sinuscopy

We performed sinuscopy on all patients to examine their nasal mucosa. We sometimes performed CT of sinuses on patients to exclude other diseases that might cause similar symptoms such as chronic rhinosinusitis and others. Figure 1 highlights the sinusoscopic findings of a patient with ENS that showed excessively patent nasal cavity and a broad view of the nasopharynx.

Figure 2 reveals the CT of the same patient's sinus cavity, where an overly widened common nasal cavity and inferior meatus are noted as the result of an inferior turbinectomy twenty years ago. The allergy test was not routinely done since some patients showed no typical allergy history. Rhinomanometry and acoustic rhinometry were not compulsorily performed because they are beyond the coverage of our national insurance system.

Cotton test

A cotton test without local anesthesia or decongestant was performed pre-operatively for better patient selection⁽³⁾. It is performed by placing a small cotton ball infiltrated with isotonic sodium chloride solution into the widest area of common nasal cavity where previous endonasal surgery or procedures were performed. The patients were requested to breathe with the cotton ball for 30 minutes. If they felt more comfortable with the cotton test, then they were considered as being candidates for surgery. The cotton test is not only a diagnostic tool but also a pre-operative evaluation tool to help decide on a feasible location for the implantation and the amount of implant required.

Surgery

When a patient was diagnosed of ENS and subjectively felt better with the cotton test, we enrolled this patient to our study and performed endonasal submucosal implantation of Medpor®. Under local anesthesia, a horizontal incision was made on the mucosa of the nasal floor over pyriform aperture and then the nasal mucosa was dissected subperiosteally to create a submucosal pocket by using an elevator. This should be done with care to avoid a tear of the mucosa. The patients could be consulted to adjust the optimal amount of implant during surgery. If additional Medpor® was necessary despite the nasal

Table 1. Demographic data of the patients..

No.	Gender	Age	Chief complaint	Site of implant	Prior Surgery	pre-op SNOT-22 score	post-op SNOT-22 score
1	F	53	R't orbital soreness and headache, dryness of nose	R't nasal floor	Septal meatoplasty	72	20
2	M	37	R't supraorbital pain, bil frontal fullness and pain	Bil nasal floor	Revision sinus surgery	50	33
3	M	43	Nasal obstruction, thick post-nasal drip,	Bil nasal floor	Chinese herbal topical treatment	80	26
4	F	41	Dryness and nasal emptiness	Bil nasal floor	Septal meatoplasty	11	11
5	F	53	Nasal obstruction, dryness, headache, post-nasal drip, depressive mood	R't nasal floor / septum	Sinus surgery and septal meatoplasty	30	6
6	M	47	Dryness, headache	Bil nasal floor	Septomeatal plasty and total resection of inferior turbinates	30	20
7	M	46	Dryness, r't cheek pain	R't nasal floor	Caldwel Luc operation and septal meatoplasty	38	7
8	F	58	Dryness, difficult breathing	R't nasal floor / septum	Septomeatal plasty	39	0
9	F	47	Dryness, difficult breathing	Bil nasal floor	Revision sinus surgery and septal meatoplasty	29	18
10	M	63	Nasal obstruction, post-nasal drip, lumping throat	R't nasal floor and septum	Septomeatal plasty	78	69
11	M	68	Dryness, lumping throat	L't nasal floor	Caldwel Luc operation and sinus surgery	10	3
12	M	51	Nasal obstruction, headache, glabellar fullness	R't nasal floor	Chinese herbal topical treatment and septomeatal plasty	23	16
13	M	59	Dry nose, dysphonia, post-nasal drip, cough	Bil nasal floor	Septomeatal plasty	22	6
14	M	31	L't nasal obstruction, sleep disturbance	L't nasal floor	Septomeatal plasty	43	32
15	M	32	Nasal root pain, glabellar pain	R't nasal floor	Nasal traumatic history and septomeatal plasty	21	21
16	F	57	Dry nose, dyspnea, paradoxical nasal obstruction, major depression, rhinogenic headache	Bil nasal floor / septum	Septomeatal plasty	55	28

SNOT-22, 22-item Sino-Nasal Outcome Test; L't, left; R't, right; Bil, bilateral

floor augmentation, then a hemitransfixion incision was made with further dissection to create a septal pocket. The highlight of such surgery is to maintain the integrity of the mucosal flap and prevent the protrusion of the implant.

Medpor® implants

Medpor® is a surgical implant manufactured from porous high-density polyethylene, which has been used for over 20 years as

a suitable framework biomaterial. The sizes of pores range from 100-250 µm, with over 50% being larger than 150 µm. It is a nonreactive material that allows tissue and vascular in-growth because of its interconnecting open pores greater than 100µm⁽⁴⁾. These characteristics are thought to enhance stabilization of the implant and promote resistance to infection⁽⁵⁾. The firm nature of the material allows carving with a sharp instrument without collapsing the pore structure. We used the Medpor®

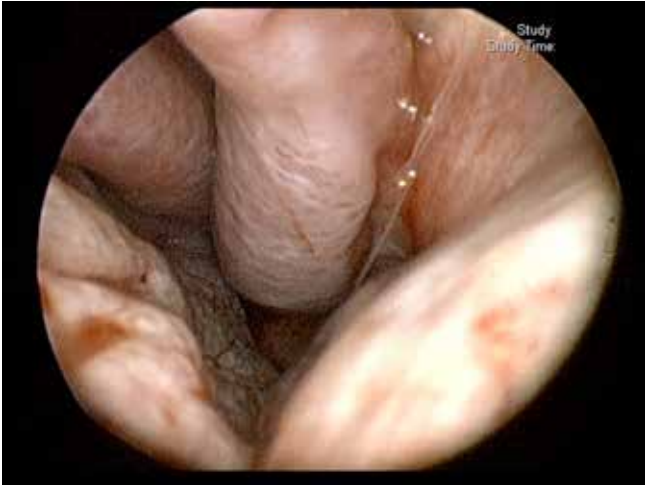

Figure 3. The sinusoscopic finding of a left-sided nasal cavity after submucosal implantation of Medpor® at the nasal floor.

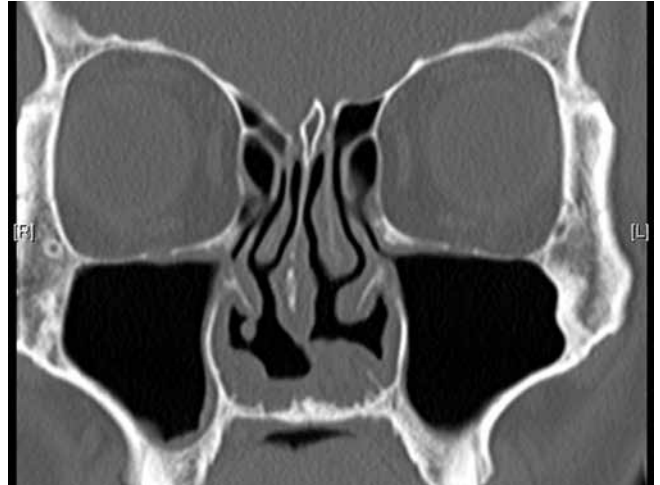

Figure 4. The sinus CT after submucosal implantation of Medpor® showed more appropriate volume of nasal cavity.

Ultra Thin Sheet which is made in sizes of 38 x 50 x 0.85 mm and cut it in to pieces in the size of 8 x 25 mm to 8 x 40 mm according to the length of the patient's nasal floor and the site of implantation. Multiple pieces of Medpor® Ultra Thin Sheet were used to form the ideal contour of submucosal implantation. During follow-up, we also performed sinuscopy on all patients to examine the nasal mucosa and nasal cavity.

Results

We excluded two patients who were lost to follow up after surgery and were not able to complete the required questionnaire. The age of the remaining sixteen patients ranged from 31 to 68 years old at the time of Medpor® implantation being performed. Ten patients were male and six patients were female. The demographic data of these sixteen patients are shown in Table 1. Nearly all patients resulted from previous endonasal surgery including inferior turbinectomy. There was one patient who received unknown Chinese herbal treatment on the nasal mucosa. Most of the patients developed ENS-related symptoms gradually within a number of years after the previous nasal surgery or treatment, ranging from 2 to 16 years. There were two patients who developed their symptoms within months, three patients who developed their symptoms within six months to one year, and only one patient who started having symptoms sixteen years after nasal surgery. We also noted that one patient progressively evolved into atrophic rhinitis. With the intervention of submucosal implantation, their symptoms had also improved. The sites of submucosal implantation are mainly septum and nasal floor, unilaterally or bilaterally. We decided the site of implantation from the results of the cotton test and sinusoscopic findings. The main surgical purpose was to reduce the volume of the excessively empty nasal cavity and increase the surface area of nasal mucosa to reduce the patients' symptoms of paradoxical nasal

obstruction, breathing discomfort and pharyngeal dryness. The nasal floor would be the first site for implant to avoid the possibility of septal perforation. Utilizing this location, it is easier to adjust the amount of implant and provide enhanced stability for the implant. If the nasal floor implantation could not offer adequate reduction of widened nasal cavity, the septum would be another site considered for implantation. Figure 3 notes the sinusoscopic finding after submucosal implantation of Medpor® at the nasal floor. Figure 4 shows the CT of a nasal cavity after submucosal Medpor® implantation in the nasal floor.

The statistical data of pre-op and post-op SNOT-22 are shown in Table 2. The pre-op summation score is 39.25 ± 21.44 . The post-op summation score at 3 months is 19.81 ± 16.17 ($p < 0.05$) at three months and 16.19 ± 13.98 ($p < 0.05$) at one year. If SNOT-22 is studied individually, there are some differences noted between each symptom. There are significant post-operative improvements in most of the symptoms, especially some with a preoperative mean score greater than 2, such as need to blow their nose, post-nasal drip, thick nasal discharge, fatigue, frustration, restless or irritability and sadness. However, there was no significant improvement regarding to altered sense of taste or smell, aural fullness, ear pain, reduced productivity and embarrassment. One patient who had gradually presented as atrophic rhinitis also improved significantly from 22 to 6 according to SNOT-22 score.

Postoperative complications were found in two patients. One patient developed chronic hypertrophic rhinitis four years after implantation, which required regular nasal steroid spray. Another patient was found with a protrusion of the implant six months after surgery and a partial section of the implant was removed under local anesthesia.

Table 2. Pre-op and post-op SNOT-22 score.

	Pre-op	Post-op 3 months	Post-op 1 year
Need to blow nose	2.38	1.00*	0.81*
Sneezing	1.75	0.94*	0.63*
Runny nose	1.25	0.69*	0.63*
Blockage/congestion of nose	2.88	0.88*	0.75*
Sense of taste/smell	0.63	0.75	0.50
Cough	1.06	0.31*	0.31*
Post nasal discharge	3.06	1.56*	1.19*
Thick nasal discharge	2.44	1.31*	1.19*
Ear fullness	1.19	0.50*	0.50
Dizziness	1.75	0.81*	0.63*
Ear pain/pressure	0.63	0.31	0.31
Facial pain/pressure	1.88	0.94*	0.56*
Difficulty falling asleep	2.44	0.94*	0.81*
Lack of a good night's sleep	1.69	0.81*	0.88*
Waking up at night	1.75	1.00*	0.81*
Waking up tired	2.06	1.25*	1.13*
Fatigue during the day	1.38	0.69*	0.50*
Reduced productivity	1.31	0.56*	0.56*
Reduced concentration	1.81	0.94	0.56*
Frustrated/restless/irritable	2.94	1.56*	1.25*
Sad	2.88	1.56*	1.19*
Embarrassed	1.00	0.75*	0.50*
Summation	39.25	19.81*	16.19*

Each item is scored from 0 (no symptoms) to 5 (severe symptoms).

* $p < 0.05$.

Discussion

Most otolaryngologists agree with the importance of maintaining normal anatomy and preserving as much normal mucosa as possible. However, the possibility of excessive reduction of turbinates still remains⁽⁶⁾. In this study, the most frequently encountered ENS patients had undergone a previous inferior turbinectomy. This is reasonable since the inferior turbinates are the most manipulated structure during endonasal surgery. The time interval from surgery to occurrence of ENS varies from each other, ranging from months to years. This might result from the different degrees of previous inferior turbinectomy.

Despite the excessively widened nasal cavity being key figure of ENS, paradoxical nasal obstruction is still the most concerned symptom. The pathophysiology for paradoxical nasal obstruction is unclear, but it might be caused by a decreased sensation of airflow due to tissue loss in the turbinates, which are thought to be the source of nerve growth factor⁽⁷⁾. Pharyngeal dryness results from alternative mouth breathing when patients feel paradoxical nasal obstruction. Due to the above reasons, the patients subjectively feel difficulty in breathing. We did not include the symptoms of hyposmia and depression because the former symptoms might result from previous nasal disease and depressive mood is multifactorial. In the analysis of peri-operative symptoms of patients with ENS, the most concerned symptoms were the need to blow nose, post-nasal dripping, thick nasal discharge, fatigue, frustration, restless or irritability and sadness. Fortunately, the symptoms mentioned above had statistically improved after the submucosal implantation of Medpor®. The mean SNOT-22 score of ENS was 39.25 ± 21.44 . In comparison with the normal population whose average score is 9.3 (95% confidence interval range 7.5–11.1)⁽⁸⁾, it is significantly higher. We used SNOT-22 as our questionnaire as it is well established and frequently used. There are some improvements including altered sense of taste or smell, aural fullness, ear pain, reduced productivity and embarrassment, yet without statistical difference. ENS may be less involved with these symptoms with preoperative low scores. A modified scoring system more specific to ENS should be designed in the future.

In our presented cases, there was one patient who presented with ENS initially after previous nasal surgery, but progressively developed the symptoms of ozena and thick nasal crusting, which is characteristic in atrophic rhinitis⁽⁹⁾. Such a case could be categorized into secondary atrophic rhinitis, which is also referred as iatrogenic atrophic rhinitis⁽¹⁰⁾, resulting from previous nasal surgery. The patient also gained improvement of both symptoms after surgery. With the evaluation of SNOT-22, the symptoms were improved from 22 to 6, also implying that submucosal implantation of Medpor® might be considered as a surgical solution of secondary atrophic rhinitis.

There remained problems determining the ideal volume and the location of the implants. The adjustment of implant amount in patients under local anesthesia can reduce the possibilities of inadequate or over correction. In addition, if the surgeon is not confident on the appropriate amount of implant, it is suggested to insert a smaller amount of implant in the nasal floor at first. Then, another surgery could be used to reinforce the implant several months later in the nasal septum area. We suggest placing the implant first at the nasal floor, then at the nasal septum. We did experience over correction in one of our patients 4 years after surgery. That patient was free of ENS but presented with

hypertrophic rhinitis. This may have been due to the characteristics of implant that allow for tissue and vascular ingrowth and resulted in mucosa hypertrophy several years later ⁽⁴⁾.

There is some selection bias within our prospective self-controlled study. We enrolled the patients who felt less pharyngeal dryness, less nasal obstruction instantly with the cotton test. It made the diagnosis of ENS more accurate and resulted in a relatively fair surgical outcome. This implies that a positive cotton test is an adequate surgical indication for ENS. This explains why most of our patients stated instant improvement after submucosal implantation and the statistical improvement at short-term follow-up of 3 months after surgery. However, long-term follow-up is necessary for possible development of chronic hypertrophic rhinitis and possible protrusion of nonabsorbable implant.

Conclusion

Symptomatology continues to remain the most important diagnostic criteria of patients with ENS. According to our study and the previous report by Chhabra and Houser ⁽¹⁾, ENS can be recog-

nized with symptoms such as paradoxical nasal obstruction, breathing discomfort, nasal and pharyngeal dryness, along with sinusoscopic findings and the cotton test. Moreover, submucosal implantation of Medpor[®] is a feasible surgical solution to ENS. A positive cotton test is suggested for the surgical indication and planning.

Acknowledgement

None

Authorship contribution

YYT: preparation the draft, data collection and editing manuscript

TJL: surgeon and article modification

CCW: data collection

PHC, YWC, CHF: data analysis and interpretation

CCH: correspondence, article modification

Conflict of interest

The authors declare no conflicts of interest.

References

1. Chhabra N, Houser SM. The diagnosis and management of empty nose syndrome. *Otolaryngol Clin North Am.* 2009; 42: 311-330, ix.
2. Rudnik A, Zawadzki T, Wojtacha M, Bazowski P, Gamrot J, Galuszka-Ignasiak B, et al. Endoscopic transnasal transsphenoidal treatment of pathology of the sellar region. *Minim Invasive Neurosurg.* 2005; 48: 101-107.
3. Houser SM. Surgical treatment for empty nose syndrome. *Arch Otolaryngol Head Neck Surg.* 2007; 133:858-863.
4. Klawitter JJ, Bagwell JG, Weinstein AM, Sauer BW. An evaluation of bone growth into porous high density polyethylene. *J Biomed Mater Res.* 1976; 10: 311-323.
5. Lee S, Maronian N, Most SP, Whipple ME, McCulloch TM, Stanley RB et al. Porous high-density polyethylene for orbital reconstruction. *Arch Otolaryngol Head Neck Surg.* 2005; 131: 446-450.
6. Passali D, Lauriello M, Anselmi M, Bellussi L. Treatment of hypertrophy of the inferior turbinate: long-term results in 382 patients randomly assigned to therapy. *Ann Otol Rhinol Laryngol.* 1999; 108: 569-575.
7. Wu X, Myers AC, Goldstone AC, Toggias A, Sanico AM. Localization of nerve growth factor and its receptors in the human nasal mucosa. *J Allergy Clin Immunol.* 2006; 118: 428-433.
8. Gillett S, Hopkins C, Slack R, Browne JP. A pilot study of the SNOT 22 score in adults with no sinonasal disease. *Clin Otolaryngol.* 2009; 34: 467-469.
9. Cottle MH. Nasal atrophy, atrophic rhinitis, ozena: medical and surgical treatment: repair of septal perforations. *J Int Coll Surg.* 1958; 29: 472-484.
10. Payne SC. Empty nose syndrome: what are we really talking about? *Otolaryngol Clin North Am.* 2009; 42: 331-337, ix-x.

Chi-Che Huang
Department of Otolaryngology
Head and Neck Surgery
Chang Gung Memorial Hospital and
Chang Gung University
No.5, Fu Hsing Street
Kwei-Shan
Taoyuan, 333
Taiwan

Tel: +886-3-328-1200 ext.8466

Fax: +886-3-327-1244

E-mail: hcc3110@adm.cgmh.org.tw