

# The role of endonasal surgery in the management of frontoethmoidal osteomas\*

Bernhard Schick, Christof Steigerwald, Abd El Rahman El Tahan, Wolfgang Draf

Department of Ear-, Nose- and Throat Diseases, Head-, Neck- and Facial Plastic Surgery, Communication Disorders, Klinikum Fulda, Germany

## SUMMARY

*Recently endonasal surgery has been considered to be a valuable contribution in the management of paranasal sinus osteoma. A retrospective evaluation study of 34 frontoethmoidal osteomas (23 frontal and 11 ethmoidal osteomas) treated at a tertiary care facility from 1990 to 1999 is presented. Twenty three osteomas (68%) were resected endonasally. Eleven osteomas (32%) were removed using an osteoplastic frontal sinus approach with coronal incision. In 5 cases of huge osteomas originating at the anterior frontal sinus wall, reconstruction of the resected anterior frontal sinus wall was achieved by autologous outer table grafts harvested from the parietal region. Endoscopic and radiological follow-up ranging from 1 to 32 months showed three incomplete endonasal osteoma resections. Complete osteoma removal was achieved via endonasal revision surgery in two of these cases, while the third small residual osteoma remains under observation. There was no case of osteoplastic osteoma removal where incomplete osteoma resection became obvious during follow-up. Ethmoidal osteomas without extrasinusal extension can be resected endonasally. The endonasal approach should be considered also for frontal sinus osteomas if (1) sufficient frontal sinus access can be achieved endonasally, (2) the osteoma is placed medially to a virtual sagittal plane through the lamina papyracea, and (3) the tumour base is at the inferior part of the posterior frontal sinus wall. We favour the osteoplastic frontal sinus approach with coronal incision if an external approach is required to achieve tumour resection with the best aesthetic results.*

*Key words: osteoma, surgery, endonasal approach, osteoplastic procedure, reconstruction*

## INTRODUCTION

Craniofacial osteomas are benign tumours often involving the paranasal sinuses. The frontal sinus is the most frequent location, followed by the ethmoid, maxillary sinus, and sphenoid sinus, respectively (Namdar et al., 1998). Osteomas originate in the sinus wall, but their aetiology is still uncertain. Traditionally, they are named after the invaded sinus rather than the sinus from which they originate (Deflavis et al., 1989).

Age of presentation is most commonly the second to fifth decade, with a male:female ratio of approximately 3:1. Some have suggested an ethnic variation (Rappaport and Attia, 1994). Paranasal osteomas may be discovered incidentally on radiographs or may enlarge, producing symptoms or rare complications (visual impairment, intracranial neurological complications) referable to their location near to the orbit or anterior cranial

base (Samy and Mostafa, 1971; Shady et al., 1994; Smith and Calcaterra, 1989). Differential diagnosis of paranasal osteomas include other fibro-osseous lesions such as fibrous dysplasia, or ossifying fibroma. These different lesions may have a similar radiological appearance, but their borders are usually less well defined than those of osteomas (Margo et al., 1986).

The indications for surgical treatment of frontoethmoidal osteomas were reviewed by Savic and Djerić in 1990. They suggested surgical removal for osteomas extending beyond the boundaries of the frontal sinus, those which continue to enlarge, those which are localised in the region adjacent to the frontonasal recess, those associated with chronic sinusitis, and osteomas of the ethmoid sinus irrespectively of their size. They also propose removal in patients with osteomas who complain of headache when other causes of headaches have been excluded.

\* Received for publication: June 2, 2000; accepted September 9, 2000.

Selection of the appropriate surgical approach in frontoethmoidal osteomas depends in general on location, volume and side of the osteoma, on the anatomical conditions as the anterior-posterior diameter of the frontal recess, and on possible extra-sinusal extensions. In this study we discuss the possibilities and limitations for endonasal osteoma management.

#### MATERIAL AND METHODS

This study presents a retrospective evaluation of 34 patients with frontoethmoidal osteomas treated surgically at the Ear, Nose, and Throat-Department of the Academic Teaching Hospital Fulda from January 1990 to January 1999. The series includes 16 female and 18 male patients with an age ranging from 21 to 70 years (median age: 45 years). Data on the indications for osteoma resection, tumour location and extension, surgical strategies, complications, and follow-up were obtained from the medical records.

Preoperative radiographic diagnostics included axial computed tomography (slice thickness: 2 mm) of the paranasal sinuses with secondary coronal reconstructions to determine side, volume and origin of the osteoma as well as possible endonasal frontal sinus access. For an osteoplastic procedure, an occipito-frontal radiograph of the frontal sinus was required to create a stencil for safe opening of it.

Endonasal surgery was performed as combined micro-endoscopic surgery in supine position under general anaesthesia. Osteomas of the ethmoid were resected using a drill and punches after ethmoidectomy had been performed to the necessary extent. Small osteomas were mobilised after exposure bluntly without the need to use a drill. To reach frontal osteomas via the endonasal approach, a frontal sinus drainage type II or type III according to Draf was performed. Resection of the frontal sinus floor results in a type II drainage. A type III frontal sinus drainage is achieved by removal of the frontal sinus floor on both sides and resection of the superior part of the adjacent nasal septum and the inferior area of the interfrontal septum (Draf et al., 1995). After ethmoidal osteoma resection, a nasal packing was left for 3 days and after a frontal sinus drainage type II or III for 7 days. If necessary, nasal fluorescein endoscopy for evaluation of tight duraplasty was performed after lumbar application of freshly prepared 5% fluorescein solution (0,1 ml/10 kg body weight, but never more than 1 ml).

Osteoplastic frontal sinus approach with coronal incision was the external procedure. After careful hair cleaning with disinfectant shampoo no haircut was found to be necessary for surgery. In case of baldness, the skin incision was performed in the occipital region still baring hair with elevation of the scalp up to the frontal sinus in order to avoid a visible scar. In 4 cases with additional severe chronic sinusitis or expected postsurgical closure of the frontal sinus drainage after osteoma resection, obliteration of the frontal sinus with abdominal fat grafts was indicated. For reconstruction of the anterior frontal sinus wall calvarian bone of the parietal region was harvested and splitted into an inner- and outer-table graft. The inner-table was placed back to cover the donor site, while the outer-table was used for frontal reconstruction.

In addition to clinical and endoscopic follow-up, results of computed tomography in 26 cases and findings of magnetic resonance imaging in 3 cases were available to evaluate surgical success. Bone scintigraphy was carried out 6 to 12 months after frontal reconstruction with outer-table grafts from the parietal region to prove vascularisation of the graft. Follow-up ranged from 1 to 32 months with an average follow-up time of 11 months.

#### RESULTS

From January 1990 to January 1999, 23 frontal and 11 ethmoidal osteomas were resected. Nine of these space-occupying lesions were located in the anterior ethmoid and 2 osteomas found in the posterior ethmoid. The size of the ethmoidal osteomas ranged from 8 to 35 mm (average diameter: 17 mm). Twelve frontal osteomas were found to be based at the inferior posterior frontal sinus wall and didn't extend laterally to a virtual sagittal line through the lamina papyracea. Eleven frontal osteomas were located mainly lateral to a virtual sagittal line through the lamina papyracea or originated from the anterior frontal sinus wall. Radiological signs of chronic inflammatory sinusal disorders were present in 6 patients.

While 14 osteomas had been detected accidentally on radiographs of the head/paranasal sinuses or computed tomographies of the head, computed tomography of the paranasal sinuses proved an osteoma in 5 patients examined because of suspected chronic sinusitis and in 10 patients presenting with chronic headaches. Three patients at the time of presentation already showed a frontal protuberance. In one patient suffering from

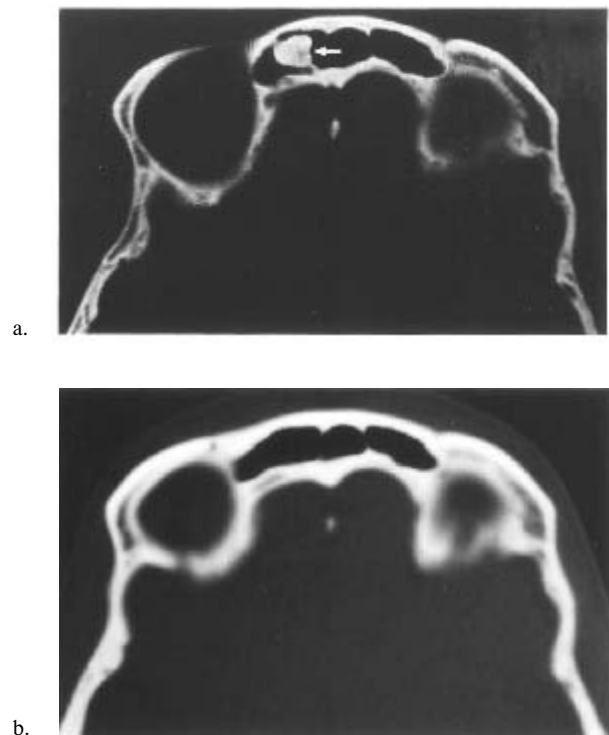


Figure 1 a, b. Computed tomography (a) indicating frontal sinus osteoma in a 25-years-old female patient and follow-up (b) one year after endonasal tumour resection, illustrating complete osteoma removal.

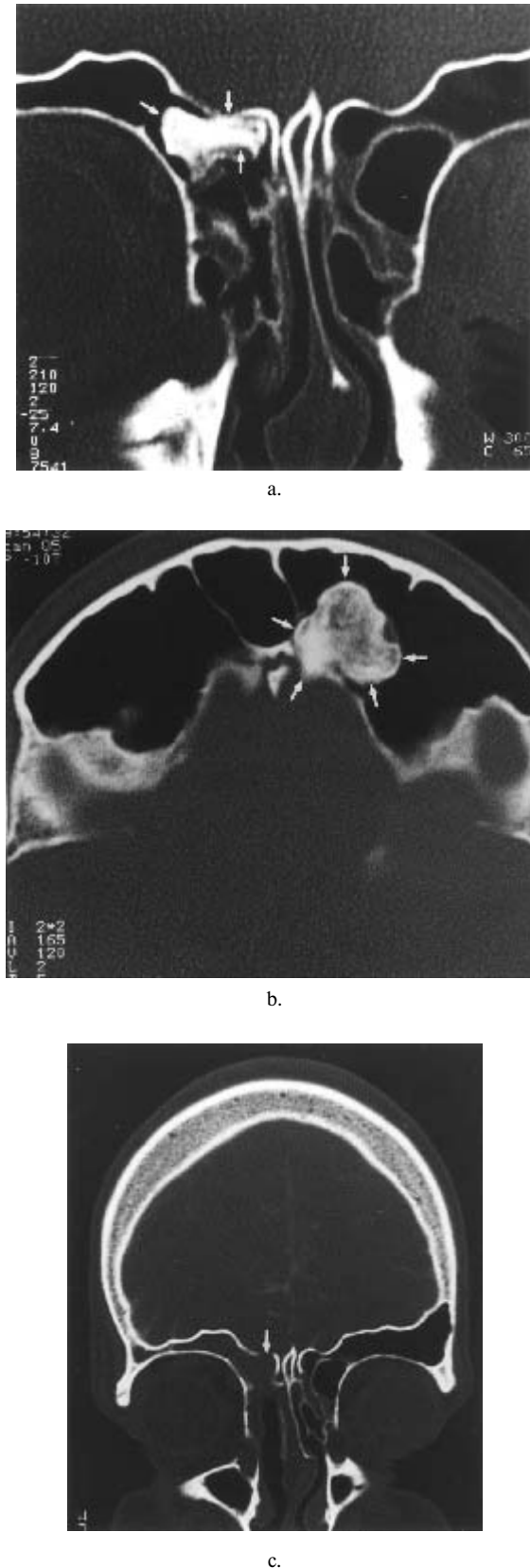


Figure 2 a-c. Frontal sinus osteoma in a 40-years-old male patient originating from the inferior posterior frontal sinus wall (a, arrow) and located medial to a virtual sagittal plane through the lamina papyracea (b). Endonasal osteoma removal was performed. Postsurgical computed tomography (c) indicates complete endonasal tumour resection.

meningitis an osteoma with destruction of the posterior frontal sinus wall was found. Displacement of the eyeball due to an osteoma in one patient already caused a diplopia image. Indications for osteoma therapy in the presented series (Table 1) were 16 times osteomas adjacent to the frontonasal recess, in 4 patients already causing recurrent frontal sinusitis. Six osteomas were removed in management of chronic sinusitis. In 7 patients complaining of headaches, osteoma removal was done after intensive evaluation failed to define any other cause. Osteoma resection with aesthetic correction was performed in three cases of frontal protuberance. Decompression of the eye and closure of a cerebrospinal fluid fistula were accomplished in osteoma management of two patients.

All ethmoidal osteomas and 12 frontal osteomas were resected endonasally (Figures 1 and 2). In 3 cases of endonasally resected osteoma endoscopic and radiological follow-up indicated incomplete tumour resection. Endonasal revision surgery in 2 patients achieved complete tumour removal. In the third patient a remnant of the osteoma has been kept under observation for 2 years. Three circumscript injuries of the periorbit without any sequel occurred in 23 endonasally treated patients. In 3 cases of endonasally resected frontal osteomas dural injuries at the inferior posterior frontal sinus wall occurred. After complete osteoma resection tight duraplasty was achieved endonasally and the tightness tested 6-8 weeks after surgery using fluorescein nasal endoscopy.

An osteoplastic procedure was used to remove 11 frontal osteomas (Figure 3). In 4 patients with the additional finding of chronic sinusitis, an obliteration of the frontal sinus with abdominal fat grafts was carried out. By means of partial resection of the anterior frontal sinus wall in case of osteoma involvement, frontal reconstruction was achieved in 5 patients using outer-table grafts harvested from the parietal region. No side effect from the donor side of the harvested cranial split graft was observed. Radiological follow-up indicated in all cases complete tumour removal. In 4 osteoplastic cases duraplasty was necessary to close a cerebrospinal fluid fistula. Clinical follow-up and fluorescein nasal endoscopy indicated tight dura closure without occurrence of meningitis. One periorbital opening occurred, but didn't cause visual impairment or diplopia.

#### DISCUSSION

Since starting with treatment of inflammatory paranasal disorders the endonasal approach has been extended to many more applications such as surgery of the lacrimal drainage system, orbital diseases, choanal atresia, or closure of cerebrospinal fluid fistulas. Furthermore, the endonasal approach has been found to be suitable to treat tumours of the nose, paranasal sinuses, and anterior skull base (Draf and Berghaus, 1993; Anderhuber et al., 1999; Hosemann, 1996; Schick et al., 1999). Among the various endonasally treated tumours osteomas have been reported (Draf, 1992; Hosemann, 1996; Reib and Hüttenbrink, 1997; Hosemann et al., 2000). But, which are the general items and limitations for endonasal fronto-ethmoidal osteoma resection? Prerequisite for complete endonasal tumour resection is adequate access to all tumour confines. In ethmoidal osteomas

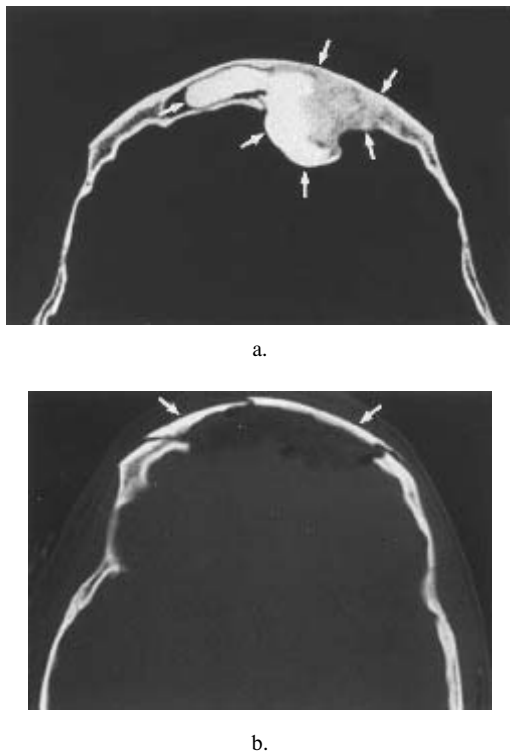


Figure 3 a, b. Huge frontal sinus osteoma affecting major parts of the anterior frontal sinus wall in a 21-years-old female patient (a). After coronal incision the osteoma was removed with the adjacent anterior frontal sinus wall. Reconstruction of the forehead region was accomplished harvesting an outer-table graft of the parietal region. Computed tomography (b) proves excellent aesthetic restoration.

Table 1. Indications for osteoma removal in the presented series of 34 frontoethmoidal osteomas.

Indication	Number
Osteoma adjacent to the frontonasal recess	16
Osteoma removal in management of chronic sinusitis	6
Osteoma finding in case of chronic headache	7
Osteoma causing frontal potuberance	3
Osteoma in case of meningitis	1
Osteoma causing displacement of the eyeball	1

without significant extrasinusal extension the endonasal approach allows complete tumour resection. If the osteoma is huge or broadly attached to the ethmoidal borders, the tumour can be reduced in size with the drill before complete removal is achieved (Reib and Hüttenbrink, 1997). In frontal osteomas the appropriateness of the endonasal approach has to be checked carefully on the base of preoperative computed tomographies. We advise axial scans to get clear answers to the following questions: (1) Can adequate access to the frontal sinus be achieved endonasally? As our concept includes for adequate frontal osteoma exposure a type II or type III frontal sinus drainage, the achievable anterior-posterior diameter of the frontal sinus drainage after removal of the internal nasal spine is of utmost importance to us (Figure 3a). (2) Can all confines of the osteo-

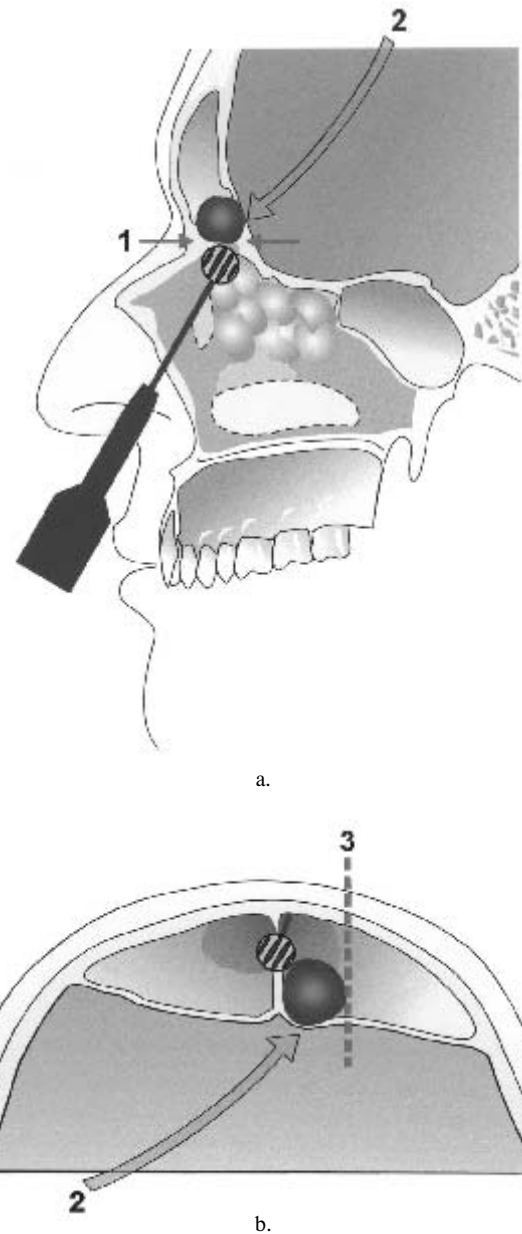


Figure 4 a, b. Endonasal management (a) of frontal sinus osteoma requires adequate frontal sinus access (1) by performing a frontal sinus drainage type II or type III according to Draf (a). The osteoma must be based at the inferior part of the posterior frontal sinus wall (2) and should not extend beyond to a virtual sagittal plane (3) through the lamina papyracea (b).

ma be reached after creating a frontal sinus type II or type III drainage? If an endonasal approach is considered, the attachment site of the osteoma has to be the inferior posterior frontal sinus wall and the osteoma should not extend beyond to a virtual sagittal plane through the lamina papyracea (Figure 3b). If the osteoma is based at the anterior frontal sinus wall or if main parts of the osteoma are located beyond to the level of the lamina papyracea, the attempt of complete endonasal osteoma resection will most likely fail, with requirement for revision surgery. Selecting the endonasal approach for removal of a frontal osteoma the surgeon may be faced during surgery with a cerebrospinal fluid fistula. Therefore, endonasal duraplasty must be possible.

If an external approach is required for frontal osteoma resection, we recommend an osteoplastic frontal sinus operation after coronal incision. This procedure offers the chance for excellent aesthetic results and the advantage of maintaining a frontal sinus drainage surrounded completely by bone. Classic external approaches to the ethmoid or frontal sinus which include partial removal of the bony borders of the frontal recess risk being followed by frontal sinus mucoceles. Furthermore, the osteoplastic frontal sinus operation after coronal incision is less likely to injure the supraorbital nerve. A coronal incision also allows one to harvest outer-table grafts from the parietal region without an additional incision if frontal reconstruction is necessary.

Our current concept for frontoethmoidal osteomas includes to check whether the endonasal approach allows osteoma resection. While ethmoidal osteomas can be resected endonasally in most cases, a frontal osteoma is considered to be accessible endonasally if it is located medial to a virtual sagittal plane through the lamina papyracea and based at the inferior part of the posterior frontal sinus wall. Preoperative computed tomography has to prove an appropriate surgical access to the frontal sinus via a frontal sinus type II or type III drainage. In case a frontal osteoma is not suited to be resected via the less traumatic endonasal approach an osteoplastic frontal sinus operation after coronal incision is the method of choice.

#### REFERENCES

1. Anderhuber W, Stammberger H, Walch Ch, Fock Ch, Regauer S, Luxenberger W, Gotschuli A (1999) Rigid endoscopy in minimally invasive therapy of tumours of the paranasal sinuses and skull base. *Min Invas Ther & Allied Technol* 8: 25-32.
2. DeFlavis L, Nessi R, Scalgia P, Balconi G, Albisetti W, Derichi LE (1989) Ultrasound diagnosis of Osgood-Schlatter and Sinding-Larsen-Johannson diseases of the knee. *Skeletal Radiol* 18: 193.
3. Draf W (1992) Endonasale mikro-endoskopische Pansinusoperation bei chronischer Sinusitis. III. Endonasale mikro-endoskopische Stirnhöhlenchirurgie. Eine Standortbestimmung. *Otolaryngol Nova* 2: 118-125.
4. Draf W, Berghaus A (1993) Tumoren und Pseudotumoren (tumorähnliche Läsionen) der frontalen Schädelbasis, ausgehend von der Nase, den Nasennebenhöhlen und dem Nasenrachenraum (einschliesslich der operativen Zugänge). *Eur Arch Otorhinolaryngol Suppl* 1993/I: 105-203.
5. Draf W, Weber R, Keerl R, Constantinidis J (1995) Aspekte zur Stirnhöhlenchirurgie. Teil 1: Die endonasale Stirnhöhlendrainage bei entzündlichen Erkrankungen der Nasennebenhöhlen. *HNO* 43: 352-357.
6. Margo CE, Wess A, Habal MB (1986) Psammomastoid ossifying fibroma. *Arch Ophthalmol* 104: 1347-1351.
7. Namdar I, Edelstein DR, Huo J, Lazar A, Kimmelman CP, Soletic R (1998) Management of osteomas of the paranasal sinuses. *Am J Rhinol* 12: 393-398.
8. Rappaport JM, Attia EL (1994) Pneumocephalus in frontal sinus osteoma. A case report. *J Otolaryngol* 23: 6.
9. Reib M, Hüttenbrink KB (1997) Zur endoskopischen Entfernung von Osteomen der Nasennebenhöhlen. *HNO* 45: 233-236.
10. Samy LL, Mostafa H (1971) Osteomata of the nose and paranasal sinuses with report of twenty one cases. *J Laryngol Otol* 85: 449-469.
11. Shady JA, Bland LI, Kazee AM, Pilcher WH (1994) Osteoma of the frontoethmoidal sinus with secondary abscess and intracranial mucocele: case report. *Neurosurgery* 34: 920-923.
12. Schick B, El Tahan AER, Brors D, Kahle G, Draf W (1999) Experiences with endonasal surgery in angiofibroma. *Rhinology* 37: 80-85.
13. Smith ME, Calcaterra TC (1989) Frontal sinus osteoma. *Ann Otol Rhinol Laryngol* 98: 896-900.
14. Sovic DL, Djeric DR (1990) Indications for the surgical treatment of osteomas of the frontal and ethmoid sinuses. *Clin Otolaryngol* 15: 397-404.

Dr. med. Bernhard Schick  
Department of Ear-, Nose- and Throat Diseases  
Head- and Neck Surgery  
University Homburg/Saar  
Kirrberger Strasse  
D-66421 Homburg/Saar  
Germany

Phone: +49-6841-16-2984  
Fax.: +49-6841-16-2997  
E-mail: hno@med-rz.uni-saarland.de