

# Nasal septal body and inferior turbinate sizes differ in subjects grouped by sex and age\*

Turhan San<sup>1</sup>, Nuray Bayar Muluk<sup>2</sup>, Suzan Saylisoy<sup>3</sup>, Mustafa Acar<sup>4</sup>, Cemal Cingi<sup>5</sup>

Rhinology 52: 0-0, 2014

DOI:10.4193/Rhino13.138

<sup>1</sup> ENT Department, Göztepe Training and Research Hospital, Istanbul Medeniyet University, Istanbul, Turkey

<sup>2</sup> ENT Department, Medical Faculty, Kırıkkale University, Kırıkkale, Turkey

<sup>3</sup> Department of Radiology, Medical Faculty, Eskisehir Osmangazi University, Eskisehir, Turkey

<sup>4</sup> ENT Department, Yunus Emre State Hospital, Eskisehir, Turkey

<sup>5</sup> ENT Department, Medical Faculty, Eskisehir Osmangazi University, Eskisehir, Turkey

\*Received for publication:

August 25, 2013

Accepted: January 5, 2014

## Abstract

**Objectives:** To compare the size of the nasal septal body (SB) and inferior turbinate (IT) of subjects grouped by sex and age.

**Method:** We measured SB and IT areas (in cm<sup>2</sup>) bilaterally in computed tomography (CT) sections of 150 paranasal sinuses from 72 males and 78 females.

**Results:** The right and left SB areas were smaller in females than in males. In the ≤25-year-old group, the right IT (RIT) was significantly smaller in females than in males. In the 26–35 and 46–45 age groups, the right SB (RSB) was significantly smaller in females than in males.

**Conclusion:** The nasal SB may play a role in nasal physiology similar to a turbinate and help support optimal airflow. The vascular and glandular structures of the SB should be investigated in detail, and minimal invasive procedures should be performed in nasal surgery to avoid damaging essential structures.

**Key words:** nasal septal body size, inferior turbinate size, septoplasty

## Introduction

The nasal septal body (SB) is a widened area of the nasal septum located superior to the inferior turbinate (IT) and anterior to the middle turbinate. It is composed of septal cartilage that is thicker in this area than in the other parts of the nasal septum, and it is suspected to play a role in the maintenance of nasal resistance<sup>(1)</sup>. In addition, it has a thicker mucosal covering than in the other portions of the nasal septum and has an intimate relationship with the internal nasal valve. The nasal SB is a conserved region of the septum located anterior to the middle turbinate approximately 2.5 cm above the nasal floor. The high proportion of venous sinusoids within the swell body suggests the capacity to alter nasal airflow<sup>(2)</sup>. The SB contains vasoactive tissue that may behave in a manner similar to the IT. Situated in the nasal valve region, the SB may undergo changes that alter nasal anatomy and airflow patterns<sup>(3)</sup>.

Wexler et al.<sup>(4)</sup> studied 14 healthy adults who had undergone septoplasty and IT reduction, in which unilateral biopsies were taken from the nasal SB, the adjacent IT, and the inferior septum. Photomicrography with morphometric analysis was used to determine the relative areas of each tissue type. They found that the nasal SB was rich in seromucinous glands (49.9% ± 7.0%) (mean ± standard deviation, SD) compared to that found in the IT (19.9% ± 5.5%;  $p < 0.01$ ). Conversely, the IT mucosa had an increased area of venous sinusoids (28.3 ± 13.9) compared to that in the nasal SB (10.0 ± 6.0;  $p < 0.01$ ). The inferior septal mucosa had glandular and vascular elements that displayed a similar proportion to that found in the nasal SB. Morphometric analysis showed that the SB mucosa had thicker epithelium and more glandular acini and blood sinusoids than the rest of the septal mucosa. Mapping of the SB area showed

that its anterior end was  $2.2 \pm 0.3$  cm behind the caudal edge of the septal cartilage, and its inferior border was  $1.1 \pm 0.2$  cm above the floor of the nose. The mean horizontal diameter of the SB was  $2.0 \pm 0.15$  cm, and the mean vertical diameter was  $1.5 \pm 0.11$  cm. The intimate relationship between the SB and the internal nasal valve and the histological characteristics of its mucosa suggest a potential role in modifying the nasal airflow pattern and resistance, and in changing the humidity and temperature of the inspiratory air stream <sup>(5)</sup>.

In the present study, we investigated the areas of nasal SB and IT in subjects grouped by sex and age. The study was carried out using radiographic data with paranasal sinus computed tomography (PNSCT).

### Materials and methods

This retrospective study was conducted at the Medeniyet University Göztepe Education and Research Hospital. The PNSCT archive of the first author (TS) was used as the retrospective data source.

### Study subjects

This study included PNSCT sections from 150 subjects. Group 1 consisted of PNSCT data from 72 males and Group 2 consisted of PNSCT data from 78 females. The mean age of all study participants was  $43.62 \pm 14.25$  (range, 16–79) years, the mean age in males was  $41.62 \pm 14.55$  (range, 16–79) years, and the mean age in females was  $45.46 \pm 13.80$  (range, 17–79) years.

In addition, the subjects were divided into the following age groups:

1.  $\leq 25$  years (n = 19; 14 male, 5 female)
2. 26–35 years (n = 21; 9 males, 12 females)
3. 36–45 years (n = 43; 19 males, 24 females)
4. 46–55 years (n = 39; 18 males, 21 females)
5. 56–65 years (n = 16; 8 males, 8 females)
6.  $\geq 66$  years (n = 12; 4 males, 8 females)

PNSCT sections were performed to address different clinical issues such as maxillofacial trauma, headache, intermittent nasal obstructions, difficulty in breathing from the nose and problems with smelling. This study excluded PNSCT sections from patients with sinonasal disease, maxillofacial fractures, or evidence of previous surgeries.

### PNSCT evaluation

The PNSCTs were obtained using the Securus: Philips (Best, Holland; voltage of 120 kV, current of 200 mA X-ray, beam width of 3 mm). The measurements were done in coronal sections of the PNSCT by the same radiologist (SS) without knowledge of the age and/or sex of the subjects. Dynamic PNSCT views were used for the measurements.

We investigated the size (area) of the nasal SB and IT in the right and left sides of the PNSCT. The measurements for the nasal SBs were performed as to previously published methods <sup>(2,3)</sup>. Coronal PNSCT slices were used to measure the area of the nasal SB on the right (RSB) and left (LSB) sides. The SB was identified bilaterally as reported previously <sup>(2,3)</sup>. The nasal SB was located superior to the anterior aspect of the IT and anterior to the head of the middle turbinate. The SB was determined to be fusiform in shape and tapered gently at its anterior aspect, with the

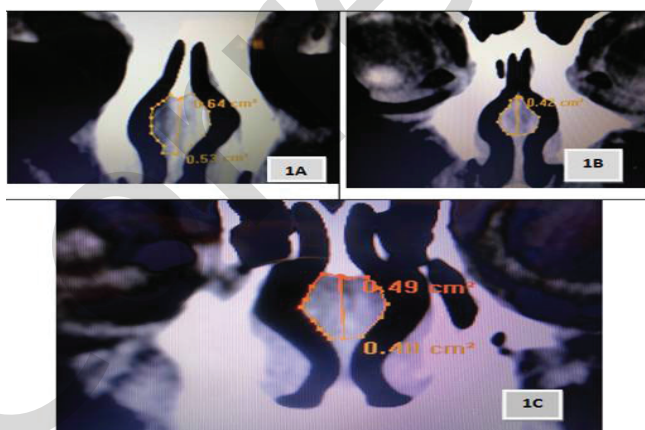


Figure 1. Coronal PNSCT of the septal body showing the average area measurements on the right and left sides\*.

\*PNSCT: paranasal sinus computerized tomography.

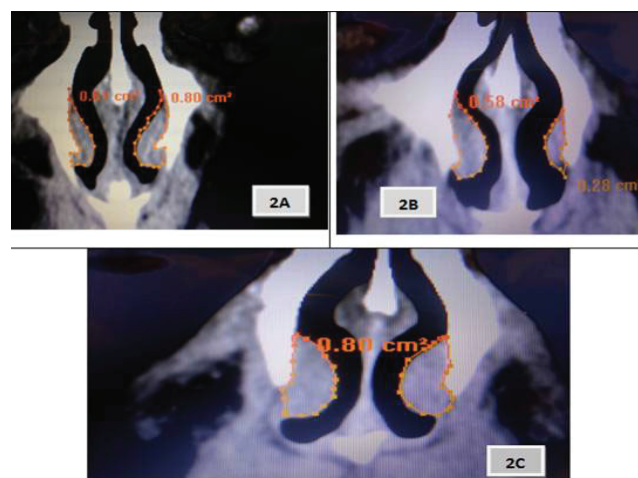


Figure 2. Coronal PNSCT of the inferior turbinate showing the average area measurements on the right and left sides\*.

\*PNSCT: paranasal sinus computerized tomography.

epicenter located near the junction of the septal cartilage and perpendicular plate of the ethmoid (2). The measurements were performed separately on the right and left sides. The measurements are demonstrated in Figure 1. The measurements of IT were performed: coronal PNSCT slices were used for the size (area) measurements of the IT on the right (RIT) and left (LIT) sides separately (Figure 2).

All steps of the study were planned and carried out according to the principles outlined in the Declaration of Helsinki (6).

**Statistical analyses**

The statistical package for SPSS (Version 16.0) was used for statistical evaluation. The independent samples t-test, Mann–Whitney U test, Pearson’s correlation test, and Spearman’s correlation Rho efficient test were used. A p-value < 0.05 was considered significant.

**Results**

Area measurements of the right and left IT and nasal SB in Groups 1 and 2 are shown in Table 1. The differences in RIT, LIT, RSB, and LSB between the males and females were analyzed using the independent samples t-test. No significant difference was detected between the IT areas in the males and females. In contrast, the RSB (0.40 cm<sup>2</sup>) and LSB (0.41 cm<sup>2</sup>) in the females were significantly smaller than those in the males (0.49 cm<sup>2</sup> and 0.47 cm<sup>2</sup>, respectively).

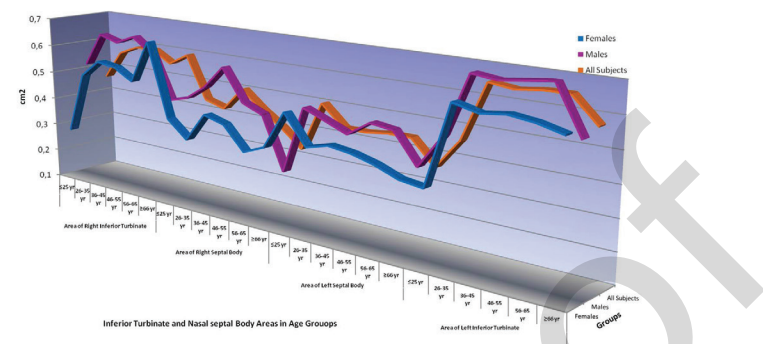


Figure 3. Line graphs of the inferior turbinates and nasal septal bodies.

The right and left IT and nasal SB in subjects grouped by age are shown in Tables 2–3 and Figure 3. The difference in RIT, LIT, RSB, and LSB between males and females was analyzed by the Mann–Whitney U test for each age group. In the ≤25 age group, the RIT was significantly larger in females (0.28 cm<sup>2</sup>) than in males (0.52 cm<sup>2</sup>; p = 0.042). In the 26–35 and 46–45 groups, the RSB was significantly smaller in females (0.34 and 0.44 cm<sup>2</sup>, respectively) than in males (0.51 and 0.59 cm<sup>2</sup>, respectively).

The correlation matrix in all subjects was performed using Pearson’s correlation test and Spearman’s correlation rho efficient test. Age, sex, and areas were used (Table 4). The RSB and LSB were significantly smaller in females than in males.

Table 1. Sizes of the right and left inferior turbinates and nasal septal bodies.

	All subjects (n = 150)				Group 1: Males (n = 72)				Group 2: Females (n = 78)				t	p*
	Mean	SD	Min	Max	Mean	SD	Min	Max	Mean	SD	Min	Max		
Age	43.62	14.25	16.00	79.00	41.62	14.55	16.00	76.00	45.46	13.80	17.00	79.00	-1.657	0.100
Right inferior turbinate size (RIT) (cm <sup>2</sup> )	0.56	0.21	0.04	1.10	0.60	0.22	0.22	10.10	0.54	0.20	0.04	1.08	1.695	0.092
Left inferior turbinate size (LIT) (cm <sup>2</sup> )	0.61	0.22	0.05	1.29	0.64	0.23	0.13	10.29	0.59	0.21	0.05	0.99	1.489	0.139
Right septal body size (RSB) (cm <sup>2</sup> )	0.44	0.17	0.03	0.99	0.49	0.18	0.10	0.94	0.40	0.16	0.03	0.99	3.374	0.001
Left septal body size (LSB) (cm <sup>2</sup> )	0.44	0.17	0.05	0.87	0.47	0.17	0.09	0.87	0.41	0.17	0.05	0.79	2.228	0.027

\*p-value for the results of the independent samples t-test.

Table 2. Area measurements of the right and left inferior turbinates and nasal septal bodies in all subjects.

	All subjects (n = 150)					
	Age Groups (years)	n	Mean	SD	Min	Max
Area of right inferior turbinate (RIT) (cm <sup>2</sup> )	≤25	19	0.46	0.20	0.04	0.84
	26-35	21	0.56	0.24	0.10	1.10
	36-45	43	0.59	0.16	0.30	0.90
	46-55	39	0.59	0.24	0.20	1.08
	56-65	16	0.55	0.21	0.24	0.99
	≥66	12	0.59	0.22	0.20	0.90
Area of left inferior turbinate (LIT) (cm <sup>2</sup> )	≤25	19	0.46	0.15	0.05	0.77
	26-35	21	0.65	0.21	0.27	0.98
	36-45	43	0.64	0.22	0.22	0.98
	46-55	39	0.65	0.27	0.12	10.29
	56-65	16	0.65	0.20	0.29	0.99
	≥66	12	0.57	0.15	0.25	0.77
Area of right septal body (RSB) (cm <sup>2</sup> )	≤25	19	0.44	0.15	0.03	0.66
	26-35	21	0.42	0.15	0.15	0.70
	36-45	43	0.50	0.20	0.15	0.99
	46-55	39	0.44	0.18	0.17	0.88
	56-65	16	0.39	0.14	0.13	0.68
	≥66	12	0.33	0.14	0.10	0.57
Area of left septal body (LSB) (cm <sup>2</sup> )	≤25	19	0.50	0.16	0.06	0.79
	26-35	21	0.43	0.17	0.05	0.73
	36-45	43	0.43	0.17	0.20	0.78
	46-55	39	0.44	0.19	0.09	0.87
	56-65	16	0.44	0.16	0.20	0.83
	≥66	12	0.36	0.16	0.22	0.70

**Discussion**

Nasal SB is a highly glandular structure in the anterior-superior septum, with a moderate proportion of venous sinusoids. It is located at the distal valve segment and is structured for secretory function and vasoactive airflow regulation<sup>(4)</sup>. Costa et al.<sup>(2)</sup> analyzed the radiographic, anatomical, and histological characteristics of the nasal septal swell body. Computer-aided analysis of magnetic resonance images (MRIs) and histological examination of cadaveric nasal septa were performed. In addition, head MRI studies were performed on 54 live adult patients and 10 cadaveric nasal septa. Radiographic dimensions of the swell body and distances to other nasal landmarks were

measured. Nasal septal and swell body histological characteristics of the vascular, connective, and glandular tissues within the swell body and the adjacent septum were compared. The swell body was fusiform-shaped and located anterior to the middle turbinate, with a mean (SD) width of 12.4 (± 1.9) mm, height of 19.6 (± 3.2) mm, and length of 28.4 (± 3.5) mm. The epicenter was 24.8 (± 2.9) mm from the nasal floor, 43.9 (± 4.1) mm from the nasal tip, and 39.0 (± 4.6) mm from the sphenoid face. Histological analyses revealed that, compared to adjacent septal mucosa, the swell body contained significantly more venous sinusoids (37% versus 16%) and fewer glandular elements (28% versus 41%).

Table 3. Area measurements of the right and left inferior turbinates and nasal septal bodies in males and females.

	Age Groups (years)	Group 1: Males (n = 72)					Group 2: Females (n = 78)					z	p*
		n	Mean	SD	Min	Max	n	Mean	SD	Min	Max		
Area of right inferior turbinate (RIT) (cm <sup>2</sup> )	≤25	14	0.52	0.17	0.22	0.84	5	0.28	0.18	0.04	0.56	-2.038	0.042
	26-35	9	0.64	0.29	0.27	1.10	12	0.50	0.19	0.10	0.93	-1.138	0.255
	36-45	19	0.62	0.17	0.35	0.90	24	0.56	0.16	0.30	0.85	-1.052	0.293
	46-55	18	0.65	0.27	0.22	0.99	21	0.55	0.21	0.20	1.08	-1.269	0.205
	56-65	8	0.60	0.21	0.31	0.99	8	0.51	0.21	0.24	0.81	-0.735	0.462
	≥66	4	0.44	0.18	0.24	0.68	8	0.66	0.22	0.20	0.90	-1.537	0.124
Area of left inferior turbinate (LIT) (cm <sup>2</sup> )	≤25	14	0.49	0.11	0.36	0.77	5	0.35	0.20	0.05	0.56	-1.437	0.151
	26-35	9	0.69	0.24	0.36	0.98	12	0.62	0.18	0.27	0.84	-0.925	0.355
	36-45	19	0.68	0.25	0.22	0.98	24	0.60	0.19	0.29	0.98	-1.199	0.231
	46-55	18	0.69	0.30	0.13	1.29	21	0.61	0.24	0.12	0.99	-0.916	0.360
	56-65	8	0.70	0.13	0.55	0.99	8	0.60	0.25	0.29	0.98	-1.576	0.115
	≥66	4	0.55	0.15	0.45	0.77	8	0.58	0.16	0.25	0.77	-0.600	0.549
Area of right septal body (RSB) (cm <sup>2</sup> )	≤25	14	0.46	0.12	0.28	0.66	5	0.40	0.22	0.03	0.62	-0.185	0.853
	26-35	9	0.51	0.15	0.27	0.70	12	0.34	0.12	0.15	0.55	-2.027	0.043
	36-45	19	0.59	0.19	0.21	0.94	24	0.44	0.18	0.15	0.99	-2.655	0.008
	46-55	18	0.48	0.18	0.19	0.88	21	0.42	0.17	0.17	0.80	-0.987	0.324
	56-65	8	0.45	0.13	0.28	0.68	8	0.34	0.14	0.13	0.57	-1.576	0.115
	≥66	4	0.27	0.17	0.10	0.51	8	0.37	0.13	0.19	0.57	-1.529	0.126
Area of left septal body (LSB) (cm <sup>2</sup> )	≤25	14	0.50	0.12	0.28	0.72	5	0.50	0.28	0.06	0.79	-0.463	0.643
	26-35	9	0.47	0.14	0.22	0.73	12	0.40	0.19	0.05	0.71	-0.925	0.355
	36-45	19	0.44	0.17	0.22	0.77	24	0.42	0.17	0.20	0.78	-0.551	0.582
	46-55	18	0.49	0.21	0.09	0.87	21	0.41	0.17	0.21	0.77	-1.311	0.190
	56-65	8	0.48	0.18	0.27	0.83	8	0.39	0.13	0.20	0.64	-0.893	0.372
	≥66	4	0.38	0.15	0.22	0.60	8	0.36	0.18	0.23	0.70	-0.425	0.671

\*p-value for the results of the Mann-Whitney U test. Analysis was performed between Group 1 (males) and Group 2 (females).

In the present study, we examined 150 PNSCT sections (72 males, 78 females). Coronal CT scans were used for the area measurements, which were taken bilaterally. Measurements and statistical analyses were performed for the different age groups. Although there was no significant difference in the IT size between males and females, the SB area was found to differ significantly between the sexes. The RSB (0.40 cm<sup>2</sup>) and LSB (0.41 cm<sup>2</sup>) were significantly smaller in females than in males (0.49 mm<sup>2</sup> and 0.47 mm<sup>2</sup>, respectively).

The differences in the RIT, LIT, RSB, and LSB were analyzed in

males and females according to age. In the ≤25 age group, the RIT was 0.28 cm<sup>2</sup> overall. In the 26–35 and 46–45 groups, the RSB was significantly smaller in females (0.34 and 0.44 cm<sup>2</sup>, respectively) than in males (0.51 and 0.59 cm<sup>2</sup>, respectively).

Correlation tests showed that the RSB and LSB were smaller in females than in males. As these ages (up to the menopause) coincide with active hormonal time and estrogen levels (especially E2) in females, it is possible that this result is related to hormonal cycling in females. Studies have reported a lack of significant expression of oestrogen and progesterone recep-

Table 4. Correlation analysis results.

		Age*	Gender <sup>#</sup>	Area of right inferior turbinate (aRIT) (cm <sup>2</sup> )*	Area of left inferior turbinate (aLIT) (cm <sup>2</sup> )*	Area of right septal body (aRSB) (cm <sup>2</sup> )*	Area of left septal body (aLSB) (cm <sup>2</sup> )*
Age*	r		0.106	0.120	0.140	-0.115	-0.109
	p		0.198	0.144	0.088	0.161	0.185
Gender <sup>#</sup>	r	0.106		-0.124	-0.103	-0.266	-0.191
	p	0.198		0.129	0.211	<b>0.001</b>	<b>0.019</b>

\* p-value for the Pearson correlation test. <sup>#</sup> p-value for the Spearman's correlation rho efficient test

tors in nasal telangiectasias<sup>(7)</sup>. Progesterone receptors were not detected in any of the cases and only two cases showed a weak expression of estrogen receptors with an immunoreactive score of 2/12. Negligible or weak expression levels of estrogen and progesterone in vascular structures have been reported<sup>(7)</sup>. The nasal SB has numerous blood sinusoids and seromucinous glands<sup>(1)</sup>; however, oestrogen and progesterone expression is weak in these vessels in the nose. Interestingly, we found that females have a smaller nasal SB, a region containing a rich vascular network.

Kulungowski et al.<sup>(8)</sup> compared subjects with arteriovenous, lymphatic, and venous malformations to normal controls and found no differences in androgen receptor, estrogen receptor, or progesterone receptor staining ( $p = 0.7$ ). Growth hormone receptor was overexpressed and located principally in vessels with vascular malformations. Growth hormone might contribute to the expansion of vascular malformations. In our study, the completion of the growth process may be one possible explanation for the smaller nasal SB area in 26- to 45-year-old females.

Nasal airflow is regulated predominantly by the nasal turbinates. However, the observation that the SB contains significant vasoerectile tissue suggests that the nasal SB may also influence nasal airflow. The anatomical location of the SB would appear to support this hypothesis: it occupies the space in the anterior nasal chamber anterior to the middle turbinate head and superior to the anterior portion of the IT, approaching the region of the internal nasal valve<sup>(2,9)</sup>. Turbinates have a highly developed vasculature that plays a role in nasal physiology in moistening and warming the air. In septal deviation, the IT is smaller on the deviated side, and the greater ipsilateral SB probably assumes this role due to its advanced vascular structure.

In subjects with septal deviation, the area of the IT on the contralateral side (non-deviated side) is greater than that on the de-

viated side. Therefore, nasal resistance will be equalized in both nasal passages. The nasal SB is more prominent contralateral to a septal deviation. These findings are similar to those seen with IT hypertrophy. The results indicate that SB hypertrophy may play a role in regulating nasal airflow and may contribute to nasal obstruction<sup>(3)</sup>.

Cho et al.<sup>(10)</sup> investigated the relationship between the subjective sensation of nasal obstruction and the corresponding cross-sectional area for nasal airflow in patients with a deviated septum. Anterior anatomical characteristics (the internal nasal valve angle and the cross-sectional areas at the external nasal valve, the head of the IT, and the head of the middle turbinate) and posterior anatomical factors (the cross-sectional areas at the openings of the frontal sinus, maxillary sinus, and end of the nasal septum) were examined. Anterior anatomical factors were related to the visual analog scale (VAS) scores of patients with anterior septal deviation, and posterior anatomical factors were related to the VAS scores of patients with posterior septal deviation. They concluded that the anterior and posterior parts of the nasal cavity are both related to nasal obstruction. In some patients, the posterior part of the nasal cavity was more important than other locations in causing nasal obstruction.

Setlur and Goyal<sup>(3)</sup> retrospectively measured 100 sinus CTs in terms of the degree of septal deviation and the size of the SB. The mean width of the SB was 9.3 mm. In 99 of 100 cases, the SB was significantly larger on the side opposite to the nasal septal deviation ( $p = 0.05$ ). The difference in SB thickness ipsilateral and contralateral to a septal deviation was found to correlate with the degree of septal deviation. The mean difference in SB size was 3.98 mm in cases with severe septal deviation, 1.97 mm in cases with moderate deviation, and 1.21 mm in cases with mild septal deviation. They concluded that the SB is more prominent contralateral to a septal deviation. These findings are similar to those seen with IT hypertrophy. The results indicate that SB



hypertrophy may play a role in regulating nasal airflow and may contribute to nasal obstruction.

SB is affected inadvertently during routine septal surgery. Removing cartilage from the area of the SB in the anterior septum improves the cross-sectional area in the region of the nasal valve; however, it might also interfere with the microenvironment and innervations to the SB, preventing parasympathetic tone from promoting vasodilation<sup>(2,9)</sup>. In septoplasty, rhinoplasty, and septo-rhinoplasty operations, surgeons must take great care to minimize damage to the SBs on both sides of the nose.

### Conclusion

The nasal SB may play a role in nasal physiology similar to that of a turbinate. The SB supports optimal airflow in normal nasal physiology, and also in septal deviation and IT hypertrophy. The vascular and glandular structures of the SB should be investigated further. When nasal surgery is required, minimal invasive procedures should be performed to avoid damaging the essential structures.

### References

1. Septal Body. <https://sites.google.com/site/drtbalusotolaryngology/rhinology/septal-body> (Received online on November, 24th, 2012).
2. Costa DJ, Sanford T, Janney C, Cooper M, Sindwani R. Radiographic and anatomic characterization of the nasal septal swell body. *Arch Otolaryngol Head Neck Surg.* 2010; 136: 1107-1110.
3. Wexler D, Braverman I, Amar M. Histology of the nasal septal swell body (septal turbinate). *Otolaryngol Head Neck Surg.* 2006; 134: 596-600.
4. Elwany S, Salam SA, Soliman A, Medanni A, Talaat E. The septal body revisited. *J Laryngol Otol.* 2009 Mar;123(3):303-8. Epub 2008 Sep 17.
5. Setlur J, Goyal P. Relationship between septal body size and septal deviation. *Am J Rhinol Allergy.* 2011 Nov-Dec;25(6):397-400.
6. 52nd WMA General Assembly. World Medical Association Declaration of Helsinki: ethical principles for medical research involving human subjects. *JAMA* 2000; 284: 3043-3049.
7. Eivazi B, Werner JA, Roessler M, Negm H, Teymoortash A. Lack of significant estrogen and progesterone receptor expression in nasal telangiectasias in hereditary hemorrhagic telangiectasia: an immunohistochemical analysis. *Acta Otolaryngol.* 2012; 132: 86-89.
8. Kulungowski AM, Hassanein AH, Nosé V, et al. Expression of androgen, estrogen, progesterone, and growth hormone receptors in vascular malformations. *Plast Reconstr Surg.* 2012; 129: 919e-924e.
9. Nurse LA, Duncavage JA. Surgery of the inferior and middle turbinates. *Otolaryngol Clin North Am.* 2009; 42: 295-309.
10. Cho GS, Kim JH, Jang YJ. Correlation of nasal obstruction with nasal cross-sectional area measured by computed tomography in patients with nasal septal deviation. *Ann Otol*

*Rhinol Laryngol.* 2012; 121: 239-245.

### Authorship contribution

TS: Design, planning, data collection, comments on results, writing the article

NBM: Design, planning, statistical analysis of the results, comments on results, writing the article, submission of the article

SS: Design, planning, evaluation of PNSCT views, comments on results, writing the article

MA: Design, planning, comments on results, writing the article

CC: Design, planning, comments on results, writing the article

### Acknowledgement:

"Except data collection, preparation of this paper including designing and planning was supported by Continuous Education and Scientific Research Association."

### Conflicts of Interest

The authors declare that there is no conflict of interest.

Dr. Nuray Bayar Muluk  
Birlik Mahallesi, Zirveket 2. Etap  
Sitesi, C-3 blok, No: 62/43  
06610 Çankaya  
ANKARA,  
TURKEY

Tel: +90-312-496 4073,  
+90-532-718 2441  
Fax: +90-312-496 4073  
E-mail: nbayarmuluk@yahoo.com  
nurayb@hotmail.com