

Comparison of polyvinyl alcohol coated nasal packing with non-absorbable nasal packing*

Jeong-Hun Seol¹, Jae-Myung Kim¹, Sung-Shik Kim², Bo Ra Na¹, Hyovin Jung¹,
Jae Hoon Cho¹, Jin Kook Kim¹

Rhinology 51:000-000, 2013

DOI:10.4193/Rhino12.176

***Received for publication:**

October 17, 2012

Accepted: January 18, 2013

¹ Department of Otorhinolaryngology-Head & Neck Surgery, Konkuk University School of Medicine, Seoul, Korea

² Coenko Nose infirmary, Gyeonggi-do, Korea

Summary

Background: A number of different nasal packing materials are available for prevention of nasal bleeding after endoscopic sinus surgery. Polyvinyl alcohol (PVA) coated nasal packing is an expandable packing for use in rhinological surgery. This innovative surface treatment helps to reduce the possibility of adherence to tissue and of blood clotting within the sponge. The present study investigated the effects of PVA coated packing and non-absorbable packing with respect to pain, healing site and postoperative bleeding following endoscopic sinus surgery.

Methodology: Patients between 18–80 years of age undergoing sinus surgery were enrolled. Each patient's ethmoid cavities were randomised to receive PVA coated packing material or the standard non-absorbable sinus packs. The remaining nasal packing material was removed on the 2nd day in the clinic. We determined visual analog scale score, bleeding time and wound healing status. A single rhinologist graded postoperative endoscopic appearance. Length of follow-up was 3 months.

Results: Thirty three patients were recruited. There was a significant difference in the bleeding time between the two groups, but pain and wound healing were not significantly different between the two groups.

Conclusion: PVA-coated nasal packing presents comparable characteristics with traditional nasal packing.

Key words: nasal packing, endoscopic sinus surgery, postoperative management, VAS, Polyvinyl alcohol

Introduction

Nasal packs are widely used in the practice of otorhinolaryngology, especially following nasal surgery and epistaxis. A number of different nasal packing materials are available for preventing nasal bleeding after endoscopic sinus surgery (ESS). The type of the nasal packing material used will depend on the preference and experience of the surgeon, the ease of insertion and removal and, most importantly, the extent of discomfort or pain, especially during removal of the material. Ideally, nasal packs should be easy to insert and remove with minimal discomfort, and they should effectively prevent postoperative bleeding⁽¹⁻³⁾. Packing materials and approaches used to prevent nasal bleed-

ing include petroleum gauze impregnated with 5% lidocaine ointment, encasing the middle meatal spacer (MMS) tampon in Silastic⁽⁴⁾ or traditional MMS made by placing Meroce^(5,6) (Medtronic Xomed, Mississauga, ON, Canada) within a vinyl glove finger^(5,6) and absorbable biomaterials such as Nasopore⁽⁷⁾ (Stryker, Canada, Hamilton, ON, Canada), which is a biodegradable synthetic polyurethane foam produced by a freeze-drying process. New packing materials are continuously being developed with the aims of reducing adhesion, decreasing healing time and preventing shedding or tearing. Visco⁽⁸⁾ nasal packing, which is a sponge tampon coated by polyvinyl alcohol (PVA), is an expandable packing for use in rhinological surgery. This innovative

surface treatment helps to reduce the possibility of adherence to tissue and of blood clotting within the sponge.

In this study, we investigated the effects of two different types of nasal packs with respect to pain, healing time and postoperative bleeding following ESS.

Materials and methods

Patients

A prospective case-control trial was conducted on patients with chronic rhinosinusitis with polyposis who underwent bilateral ESS. Patients who had chronic rhinosinusitis with polyposis refractory to medical treatment requiring bilateral ESS were recruited in a sub-specialized rhinology clinic. Consecutive adult patients with chronic rhinosinusitis were approached for inclusion in the study. To be included in the study, the patients had to be > 18 years of age with bilateral chronic or recurrent rhinosinusitis, and a Lund-Mackay computed tomography (CT) scan score difference ≤ 3 between the left and right sides of the nasal cavity⁽⁷⁾. Patients were excluded if they were ineligible for informed consent, unwilling or unable to comply with the postoperative visits necessary for data collection, displayed unilateral disease, had an underlying bleeding disorder, had a significant difference in disease status between the nasal cavities based on CT scan (Lund-Mackay score difference > 2) or had any history of intolerance to triamcinolone.

Data collection

Baseline Lund-Mackay, Perioperative Sinus Endoscopy (POSE) and Lund-Kennedy scores were collected^(8,9). The objective endoscopic scoring system for sinonasal cavities included assessments of features such as crusting, mucosal edema, polyposis, secretions and scarring (Lund-Kennedy, two points for each category), as well as additional assessments of the middle turbinate, middle meatal antrostomy and secondary sinuses (POSE). The POSE scoring system has been specifically developed for studies, such as the present one; this system provides additional data richness in the ethmoid inflammation category and includes scoring instructions for the baseline assessment⁽⁸⁾.

Intervention

After of the ESS, sinus cavities were randomised to receive standard non-absorbable nasal packing (Merocel®; Medtronic Xomed, Jacksonville, FL, USA) or polyvinyl alcohol-covered non-absorbable nasal packing (Visco® nasal packing, Somyoung Medics, Gyeonggi-do, Korea). Each patient had one sinus cavity packed with non-absorbable sinus packs and the other packed with cross-linked polyvinyl alcohol (PVA) covered standard non-absorbable sinus packs. Thus, patients served as their own control.

Nasal packing and measurement

After the operation, the procedure to select randomised packing material was performed by the nursing staff, based on standardized instructions and was concealed from the surgical staff. The primary investigator left the room and nasal packing by the surgeon was placed in appropriate cavities according to the randomization. The respective packs were removed 48 hours (± 3) after surgery, which is the authors' standard of practice. Allocation of randomization was placed in an envelope and remained sealed until the entire postoperative data were collected. Bleeding duration time was estimated based on the total time for cessation of bleeding from the nasal cavity after removal of packing. The pain intensity involved in the packing removal process for each side was graded by the patients according to a visual analogue scale (VAS), a 10-cm scale where 0 indicates no pain or fullness and 10 indicates the most severe pain and fullness. Postoperative healing assessments of oedema, crusting, secretions and scarring were done at postoperative days 7, 14 and 28, and 3 months using the validated Lund-Kennedy and POSE scores. Patients resumed their nasal saline irrigation and intranasal steroid sprays postoperatively just after packing removal as per the standard protocol in our centre.

Statistical analyses

A number needed to treat calculation was performed using an α -error of 5% and a power of 80% (β -error of 20%). Thirty six patients were required to show statistical and clinical significance, should they exist. Statistical analyses of all data reported in this study were performed using SPSS 16.0 (SPSS, Chicago, IL, USA). The parameters were compared using the Wilcoxon signed rank test. A value of $p < 0.05$ was considered statistically significant.

Ethical considerations

Ethics approval was obtained from the Human Research Ethics Board of the Konkuk University Medical Centre (KUMC). None of the patients approached for recruitment declined to participate.

Results

Demographics

Thirty three patients were enrolled for the present study through the rhinology clinics at KUMC and complete observation. Analyses of the preoperative POSE and Lund-Kennedy and Lund-Mackay scores showed no significant differences between the cavities (Table 1).

A comparative analysis of pain and bleeding time between the two groups after removal of packing

Bleeding time in nasal cavity after removal of the Visco nasal packing was statistically significantly shorter than that of Merocel ($p = 0.025$). However, there was no significant difference in the VAS during packing removal ($p = 0.605$) (Figure 1).

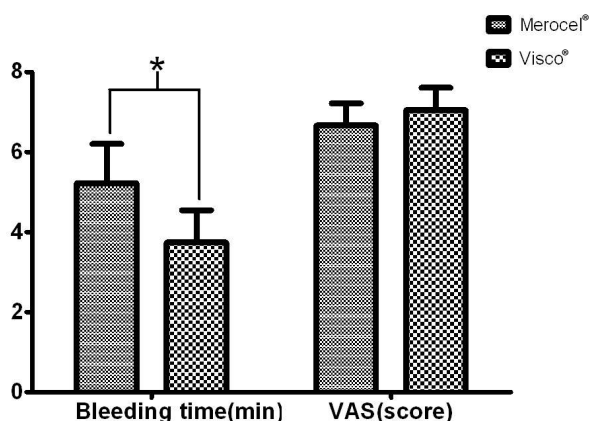


Figure 1. Bleeding time of Visco[®] group was significantly shorter than that of Merocel[®] ($p = 0.025$), but there was no difference in the VAS score ($p = 0.605$).

Postoperative healing assessment

There was no statistically significant difference between the postoperative healing site after 7 days, 2 weeks, 1 month and 3 months in endoscopic examinations (Tables 2 and 3).

Discussion

Packing after routine endonasal surgery is a common practice in medicine. A middle meatal pack promotes haemostasis and behaves as a stent to maintain middle turbinate lateralization and as a spacer to prevent blood or mucus accumulation in the ethmoid cavity postoperatively. Packing may also prevent synechia development and reduce the risk of restenosis⁽¹⁰⁾. This procedure has led to the development of various packing materials, some of which apply pressure and allow breathing or attempt to decrease postoperative adhesions⁽¹¹⁾. However, while a number of non-absorbable packing materials have been used, antibiotics have been required to prevent toxic shock syndrome^(12,13), and most of the patients experienced pain and nasal bleeding during or after removal of the packing.

Visco[®] nasal packing is an expandable PVA packing that facilitates a painless and easy application. This surface treatment helps reduce adhesions, decrease healing time and prevent shedding or tearing. However, there has not been a definitive comparison of the efficiency of this product with other available products.

In the present work, we compared haemostasis, pain and wound healing between popularly used packing material and PVA-coated packing material. Bleeding time after removal of PVA-covered Merocel[®] was significantly shorter than that of Merocel[®] ($p = 0.025$). This result corresponded with a prior comparative study between Telfa, paraffin gauze and Merocel[®]⁽¹⁴⁾.

Presently, there was an unremarkable difference between the

Table 1. Baseline data of Lund-Mckay, POSE and Lund-Kennedy score between the Merocel and Visco groups.

| | Merocel ^{®†} | Visco ^{®†} | p-value [‡] |
|--------------|-----------------------|---------------------|----------------------|
| Lund-Mckay | 3-12 (6.52) | 4-12 (6.58) | 0.840 |
| POSE | 2-14 (6.90) | 1-14 (6.54) | 0.325 |
| Lund-Kennedy | 84 (45) | 1-6 (3.21) | 0.340 |

[†] Range (Average); [‡] Wilcoxon signed rank test

Table 2. Lund-Kennedy scores after packing removal different between the two groups.

| Period (no. of patients) | Merocel ^{®†} | Visco ^{®†} | p-value [*] |
|------------------------------|-----------------------|---------------------|----------------------|
| POD [‡] 7 days (33) | 0-4 (1.48) | 0-4 (1.6) | 0.513 |
| POD 14 days (32) | 0-3 (1.21) | 0-3 (1.21) | 0.325 |
| POD 1 month (30) | 0-4 (1.2) | 0-4 (0.96) | 0.182 |
| POD 3 months (26) | 0-4 (0.84) | 0-4 (0.69) | 0.327 |

[†] Range (Average); [‡] POD = Postoperative date; ^{*} Wilcoxon signed rank test

Table 3. POSE scores after packing removal between the two groups.

| Period (no. of patients) | Merocel ^{®†} | Visco ^{®†} | p-value [*] |
|------------------------------|-----------------------|---------------------|----------------------|
| POD [‡] 7 days (33) | 1-10 (4.09) | 0-8 (4.36) | 0.487 |
| POD 14 days (32) | 0-10 (3.47) | 0-8 (2.96) | 0.187 |
| POD 1 month (30) | 0-10 (2.6) | 0-8 (2.2) | 0.268 |
| POD 3 months (26) | 0-5 (1.46) | 0-5 (1.19) | 0.364 |

[†] Range (Average); [‡] POD = Postoperative date; ^{*} Wilcoxon signed rank test

two groups with respect to pain during removal of packing ($p = 0.605$), which was not consistent with prior findings⁽¹⁴⁾. Biodegradable packing material reportedly causes less pain than conventional material^(15,16). As well, another study reported no significant difference in pain while removal of vinyl-covered Merocel[®] and biodegradable packing material⁽¹⁷⁾.

With respect to postoperative wound healing, presently there was no significant difference between the two groups based on postoperative follow-up outpatient clinic visit. It has been reported that there was no difference between the conventional material and absorbable packing material, while there was extensive adhesion of biodegradable packing material⁽¹⁸⁾.

Ahead of considering cost-effect, some absorbable packing ma-

terials were developed with comparable functions, like prevention of bleeding and adhesion⁽¹⁹⁾. Nevertheless, biocompatibility is a pre-requisite feature with absorbable packing material, and variable results have been reported following comparison of the effects between absorbable and non-absorbable materials^(15,17,20). One study reported no statistically significant differences between biodegradable and non-absorbable materials at any time with respect to any variable⁽²¹⁾. In the present study, Visco[®] was better than Merocel[®] with respect to bleeding time and there were no other significant differences. In this respect, PVA coated material is cost-effective when compared to biodegradable material.

The limitations of our study were the small number of subjects, lack of comparison of PVA-coated material with other materials and underpowered long-term follow-up.

Conclusion

The present study evaluated the utility of a PVA-coated packing material for preventing nasal bleeding after endoscopic sinus

surgery. With respect to bleeding time, removal of PVA-coated packing material resulted in a significantly shorter period of bleeding than the removal of Merocel[®]. There was no significant difference in the pain and wound healing between the two materials.

Acknowledgement

This work was supported by Konkuk University Medical Centre Research Grant 2012.

Authorship contribution

The study was designed by JHS and JHC. The data were collected by JMK and SSK.

The statistical analyses were done by BRN. The manuscript was written by JHS and HJ. The procedure of study was directed by JKK.

Conflict of interest

No conflict of interest exists.

References

1. Weber R, Hochapfel F, Draf W. Packing and stents in endonasal surgery. *Rhinology* 2000; 38: 49-62.
2. Ozcan C, Vayisoglu Y, Kilic S, Gorur K. Comparison of rapid rhino and merocel nasal packs in endonasal septal surgery. *J Otolaryngol Head Neck Surg*. 2008; 37: 826-831.
3. Bresnihan M, Mehigan B, Curran A. An evaluation of Merocel and Series 5000 nasal packs in patients following nasal surgery: a prospective randomised trial. *Clin Otolaryngol*. 2007; 32: 352-355.
4. Kuo MJ, Zeitoun H, Macnamara M, Wagstaff K, Carlin WV, Turner N. The use of topical 5% lignocaine ointment for the relief of pain associated with post-operative nasal packing. *Clin Otolaryngol Allied Sci*. 1995; 20: 357-359.
5. Kuhn FA, Javer AR. Primary endoscopic management of the frontal sinus. *Otolaryngol Clin North Am*. 2001; 34: 59-75.
6. Akbari E, Philpott CM, Ostry AJ, Clark A, Javer AR. A double-blind randomised controlled trial of gloved versus ungloved merocel middle meatal spacers for endoscopic sinus surgery. *Rhinology* 2012; 50: 306-310.
7. Lund VJ, Mackay IS. Staging in rhinosinusitis. *Rhinology*. 1993; 31: 183-184.
8. Wright ED, Agrawal S. Impact of perioperative systemic steroids on surgical outcomes in patients with chronic rhinosinusitis with polyposis: evaluation with the novel Perioperative Sinus Endoscopy (POSE) scoring system. *Laryngoscope*. 2007; 117: 1-28.
9. Lund VJ, Kennedy DW. Staging for rhinosinusitis. *Otolaryngol Head Neck Surg*. 1997; 117: S35-40.
10. Bugten V, Nordgard S, Skogvoll E, Steinsvag S. Effects of nonabsorbable packing in middle meatus after sinus surgery. *Laryngoscope*. 2006; 116: 83-88.
11. Eliashar R, Gross M, Wohlgeleitner J, Sichel JY. Packing in endoscopic sinus surgery: is it really required? *Otolaryngol Head Neck Surg*. 2006; 134: 276-279.
12. Todd J, Fishaut M, Kapral F, Welch T. Toxic-shock syndrome associated with phage-group-I Staphylococci. *Lancet*. 1978; 2: 1116-1118.
13. Younis RT, Lazar RH. Delayed toxic shock syndrome after functional endonasal sinus surgery. *Arch Otolaryngol Head Neck Surg*. 1996; 122: 83-85.
14. Garth RJ, Brightwell AP. A comparison of packing materials used in nasal surgery. *J Laryngol Otol*. 1994; 108: 564-566.
15. Franklin JH, Wright ED. Randomized, controlled, study of absorbable nasal packing on outcomes of surgical treatment of rhinosinusitis with polyposis. *Am J Rhinol*. 2007; 21: 214-217.
16. Kimmelman CP, Edelstein DR, Cheng HJ. Seprigel sinus (hylan B) as a postsurgical dressing for endoscopic sinus surgery. *Otolaryngol Head Neck Surg*. 2001; 125: 603-608.
17. Shoman N, Gheriani H, Flamer D, Javer A. Prospective, double-blind, randomized trial evaluating patient satisfaction, bleeding, and wound healing using biodegradable synthetic polyurethane foam (NasoPore) as a middle meatal spacer in functional endoscopic sinus surgery. *J Otolaryngol Head Neck Surg*. 2009; 38: 112-118.
18. Chandra RK, Kern RC. Advantages and disadvantages of topical packing in endoscopic sinus surgery. *Curr Opin Otolaryngol Head Neck Surg*. 2004; 12: 21-26.
19. Wormald PJ, Boustred RN, Le T, Hawke L, Sacks R. A prospective single-blind randomized controlled study of use of hyaluronic acid nasal packs in patients after endoscopic sinus surgery. *Am J Rhinol*. 2006; 20: 7-10.
20. Chheda N, Katz AE, Gynizio L, Singer AJ. The pain of nasal tampon removal after nasal surgery: a randomized control trial. *Otolaryngol Head Neck Surg*. 2009; 140: 215-217.
21. Miller RS, Steward DL, Tami TA, et al. The clinical effects of hyaluronic acid ester nasal dressing (Merogel) on intranasal wound healing after functional endoscopic sinus surgery. *Otolaryngol Head Neck Surg*. 2003; 128: 862-869.

Professor Jin Kook Kim MD, PhD
Department of Otorhinolaryngology
Head & Neck Surgery
Konkuk University,
School of Medicine
120-1 Neungdongro, Gwangjin-gu,
Seoul, 143-729,
Korea

Tel: +82-2-2030-7662
Fax: +82-2-2030-5299
E-mail: entalk@kuh.ac.kr

Appendix

CONSORT 2010 Flow Diagram

