

Cavernous sinus thrombosis secondary to allergic fungal sinusitis*

Esther J. Cheung, William C. Scurry, Jon E. Isaacson, Johnathan D. McGinn

Division of Otolaryngology, Head & Neck Surgery, Penn State Milton S. Hershey Medical Center, Hershey, PA, USA

SUMMARY

*Cavernous sinus thrombosis (CST) is a rare and serious complication secondary to invasive fungal sinusitis, but rarer still in cases of allergic fungal sinusitis. Current recommendations for cavernous sinus thrombosis are controversial, especially regarding anticoagulation, secondary to the rarity of the diagnosis. Early surgical debridement and intravenous antibiotics are crucial to prevent mortality and decrease morbidity. Because thrombosis is thought to be caused by a bacterial superinfection, which follows a response to *Aspergillus*, antifungals may not be necessary. Despite the controversy, most physicians opt to treat with anticoagulation.*

*Key words: cavernous sinus thrombosis, *Aspergillus fumigatus*, allergic fungal sinusitis, non-invasive fungal sinusitis, fungal sphenoiditis, anticoagulation, heparin, warfarin, anti-fungals, amphotericin*

INTRODUCTION

Cavernous sinus thrombosis (CST) is a rare but serious complication following invasive fungal sinusitis, but rarer still in cases of allergic fungal sinusitis caused by *Aspergillus fumigatus*. Current treatment includes surgical debridement and prompt initiation of intravenous antibiotics, but anticoagulation remains controversial. We present an unusual presentation of cavernous sinus thrombosis secondary to allergic fungal sinusitis of the sphenoid, discuss radiologic findings, and review therapeutic recommendations.

CST can be a consequence of infections involving the paranasal sinuses, face, orbits, oral cavity or middle ear. Patients may present with fever, headache, nausea and vomiting, proptosis, chemosis, ophthalmoplegia, papilledema, diplopia, mental status changes and facial paresthesias. Without treatment, the infection may progress to meningitis, brain abscess or carotid-cavernous sinus fistulas. With the advent of antibiotics and newer imaging techniques, mortality from CST has decreased from 72.8% to less than 20%. Morbidity has gone from 50-75% to 22%⁽¹⁾. In acute infections, the causative organisms are usually gram-positive bacteria such as *Staphylococcus aureus* and *Streptococcus* species. Chronic infections are secondary to gram negative rods and less commonly fungi, especially *Aspergillus fumigatus* and *Mucoraceae* species.

CST is a rare consequence of invasive fungal sinusitis⁽²⁻⁹⁾ and even rarer still in non-invasive or allergic fungal sinusitis. In

the invasive form, patients in an immunocompromised state can allow the organism easy access into mucosal structures, infiltrating orbital and intracranial structures via hematogenous spread. Most cases of invasive fungal sinusitis are secondary to *Aspergillus fumigatus*, the rest being identified as *Mucor* and dematiaceous fungi. Non-invasive disease can be divided into two categories. One type is caused by the formation of mycetomas or aspergillomas ("fungus ball") and most commonly affects a single sinus. Patients usually are asymptomatic. The second type, allergic fungal sinusitis, is thought to be an inflammatory response of IgE mediated type I and immune complex-mediated type III reactions^(10,11). The majority of these patients demonstrate atopy, but all are immunocompetent. Dematiaceous fungi, especially *Bipolaris* and *Curvularia*, are the most common pathogens and *Aspergillus* plays a smaller role⁽¹²⁾. According to Bent and Kuhn, diagnostic criteria of allergic fungal sinusitis include: 1) type I hypersensitivity by history, skin test or serology, 2) nasal polyposis, 3) CT findings of chronic rhinosinusitis, 4) eosinophilic mucin without fungal invasion into sinus tissue, and 5) positive fungal stain of sinus contents removed during surgery, usually with scant fungal hyphae⁽¹³⁾. Some authors have proposed a minimal criteria of chronic rhinosinusitis, eosinophilic mucin and presence of fungal organisms within mucus⁽¹⁴⁾.

Branching fungal hyphae are usually seen within a background of eosinophils and Charcot-Leyden crystals, which are the breakdown products of eosinophils. Intracranial involvement is rarely seen in allergic fungal sinusitis. We reviewed cases of

cavernous sinus thrombosis secondary to non-invasive fungal sinusitis and came across only two mentioned cases in the English language literature since 1966⁽¹⁵⁾.

CASE REPORT

A 49-year-old gentleman with a past medical history of recurrent rhinosinusitis and hypertension presented to the emergency room at our institution after 9 days of left sided headache accompanied by nausea, vomiting and blurry vision. He had been treated by a community otolaryngologist one week prior with oral amoxicillin/clavulanate. He complained of new onset diplopia on lateral gaze but denied recent fevers. He had slightly tender left sided periorbital swelling and proptosis as well as upward and lateral gaze restrictions. Pupillary reflex was mildly sluggish on the left. A contrast-enhanced CT scan of the brain and orbits revealed fluid within the ethmoid air cells on the left more than the right with complete opacification of the left sphenoid sinus. The slight thickening of the soft tissue of the left orbital apex and non-enhancement of the left cavernous sinus along with the dural enhancement adjacent to the left sphenoid sinus was suggestive of a cavernous sinus thrombosis (Figure 1). The internal carotids were normal. An MRI and MRA of the brain and orbits with and without contrast was also obtained revealing dural enhancement adjacent to the left sphenoid sinus and proximal left tentorium as well

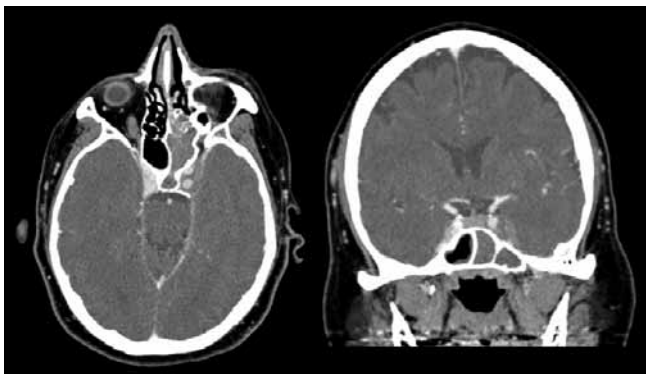


Figure 1. Contrast enhanced CT showing complete opacification of the left sphenoid sinus and non-opacification of the left cavernous sinus, suggesting thrombosis.

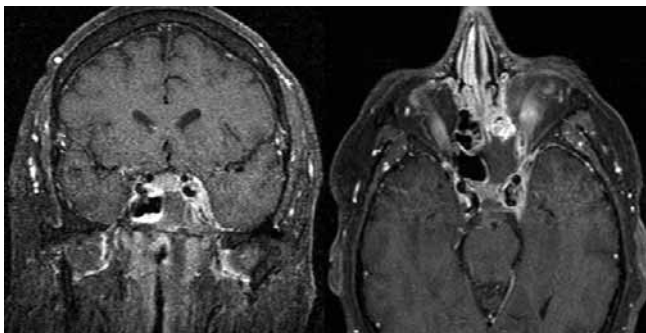


Figure 2. T1 weighted post gadolinium enhanced MRI of the brain showing left sphenoid sinusitis with adjacent dural enhancement. Axial view reveals enhancement of cavernous sinus.

as a slight hypodensity within the left cavernous sinus, consistent with severe sphenoid sinusitis and venous sinus thrombosis (Figure 2). Ophthalmology, infectious diseases and neurology were consulted.

The patient underwent endoscopic anterior and posterior ethmoidectomies, uncinectomy and left sphenoidotomy with image guidance. A septoplasty and partial left middle turbinectomy was also performed. Upon debridement of the anterior face of the sphenoid sinus, a light tan substance with “peanut-butter” consistency was encountered filling the sinus. This was removed and sent to pathology for identification and cultures. After irrigation, the sphenoid was widely opened. Upon recommendation from neurology and infectious diseases, the patient was started on intravenous heparin postoperatively.

Pathology revealed non-invasive necrotic debris with many eosinophils, Charcot Leyden crystals and fungal hyphae, which eventually grew *Aspergillus fumigatus* on culture as well as staphylococcus (Figures 3 and 4). Intravenous vancomycin, voriconazole and ampicillin/sulbactam were started. A follow up CT of the head with angiography two days after surgery did not reveal narrowing or aneurismal dilation of the intracranial vessels, although there was a persistent decrease in contrast opacification adjacent to the sella on the left and narrowing of the bony wall on the lateral aspect of the sphenoid sinus consistent with cavernous sinus thrombosis. The patient improved significantly with complete resolution of his complaints and was discharged on daily warfarin bridged with low molecular weight heparin for a goal INR of 2-3. He also received six weeks of intravenous vancomycin (1 gram every 8 hours) and oral amoxicillin/clavulanate (875 mg twice daily) and 3 months of voriconazole (300 mg twice daily). He complained of occasional vertex headaches at his 3-month follow up but was relatively asymptomatic. A follow up CT of the sinuses revealed minimal mucosal thickening in the sphenoid and ethmoid sinuses. Repeat MRI and MRA at 3 weeks and 3 months showed improving cavernous sinus enhancement with near resolution of sphenoidal opacification and an unremarkable MRA. He remained symptom free at his 6-month follow up with continued improvement by CT and MRI.

DISCUSSION

CST is a rare complication of invasive fungal sinusitis. Intracranial vessel involvement occurs because of the predisposition of the *Aspergillus* to the intimal walls of blood vessels, leading to thrombosis. Numerous fungal hyphae are seen within arterial walls⁽³⁻⁹⁾. In comparison, our case is consistent with non-invasive fungal sinusitis based on a history and CT findings of chronic rhinosinusitis, eosinophilic mucin and fungus without invasion into sinus tissue, and histological findings of scattered hyphae on fungal stains. In the few cases of venous thrombosis that have been secondary to non-invasive fungal sinusitis, it is postulated that cavernous sinus involvement may

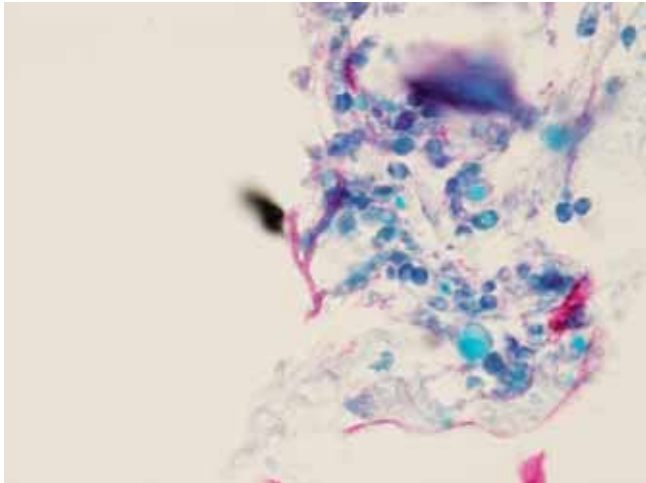


Figure 3. 400X Silver stain of sphenoid contents with a close up of *Aspergillus fumigatus*. Note branched hyphae.

be due to adjacent inflammation or a secondary bacterial superinfection and not the fungal organism itself. In any case, the pre-existing slow blood flow within the valve-less cavernous sinus is a predisposing factor. We performed a search using the OVID database for previous reports of cavernous sinus thrombosis associated with non-invasive fungal sinusitis. Results were restricted by abstracts written or translated in English. The database did not contain abstracts prior to 1966. We found only one report of two cases published recently in 2005 by Deveze et al. in France⁽¹⁵⁾. They reported two cases of CST secondary to non-invasive fungal sinusitis. One patient had a right cavernous sinus thrombosis and bilateral fungal sphenoiditis. The second patient had contralateral venous thrombosis, with left sided sphenoiditis and right-sided thrombosis. These cases supported the idea that non-invasive fungal aspergillosis may cause complications which in turn lead to venous thrombosis.

Treatment of invasive fungal sinusitis consists of anti-fungal drugs and surgical debridement. Anti-fungal treatment for gross disease especially in the immunocompromised host includes high dose Amphotericin B (> 1.5 mg/kg/day), often for a total dose of 2 grams or more and with close observation for nephrotoxicity. Surgical treatment involves frozen sections for diagnosis and margins with complete resection. The patient is closely followed with serial nasal endoscopy. Non-invasive fungal sinusitis usually responds to surgical debridement alone. Some advocate antifungal therapy or nystatin instillation intraoperatively. Rifampin and/or flucytosine have been shown to be more effective in combination with Amphotericin in the treatment of invasive cases, but not significantly so compared with Amphotericin only^(4,16).

Antibiotic therapy for CST is based on the pathogens associated with the disease process. This includes a 3rd generation cephalosporin with broad- spectrum coverage and good blood-

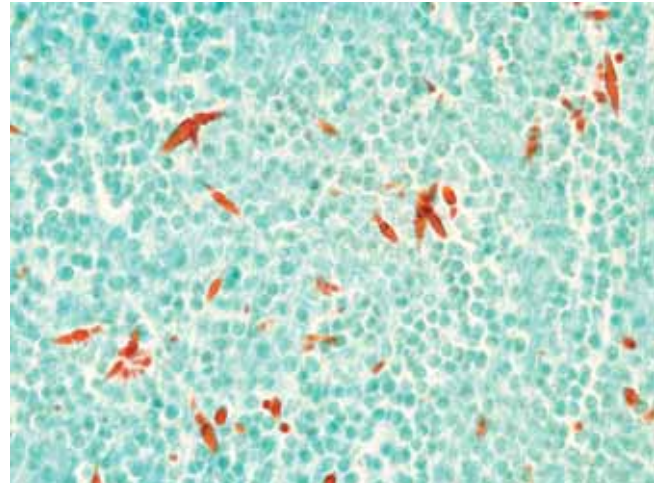


Figure 4. PAS stain of sphenoid sinus with many Charcot Leyden crystals.

brain barrier penetration. Duration of antibiotics for CST has not been standardized, but it is recommended that they should be given for at least two weeks after the patient's symptoms have resolved as bacteria sequestered within the thrombi will not be completely eradicated until the sinuses have recanalized^(17,18). Anticoagulation is still controversial^(19,20). Current recommendations call for initial intravenous heparin and at least 6 months of warfarin. A review of seven cases by Levine et al. of anticoagulation in cavernous sinus thrombosis found no difference in the addition of anticoagulation versus antibiotic treatment alone in regards to mortality⁽¹⁹⁾. Types of antibiotic therapy were not discussed. They did note that anticoagulation significantly reduced morbidity in survivors when combined with early antibiotic use. Unfortunately it is difficult to draw conclusions when the sample size is small, but they concluded that the benefit of anticoagulation in preventing further thrombus propagation and allowing recanalization of the thrombus outweighs the small, but real risk of intracranial hemorrhage. Bhatia and Jones recommended maintaining APTT ratio and INR between 1.5-2.5 and 2.0-3.0 respectively until radiologic evidence of resolution⁽²¹⁾. They felt that long term anticoagulation was not necessary as long as there were no persisting factors for thrombosis. In their management of cavernous sinus thrombosis from non-invasive fungal sinusitis, Deveze et al.⁽¹⁵⁾ recommended treatment of the bacterial superinfection with intravenous antibiotics as well as intravenous heparin and then a subsequent surgical drainage when the patient improves clinically or if the symptoms persist despite antibiotics. No anti-fungal drugs were recommended. They used three grams of intravenous cefotaxime and 400 mg of ofloxacin daily for 8 days followed by 8 days of oral amoxicillin plus clavulanate at three grams a day. Anticoagulation was stopped following complete resolution proven by angiographic CT or MRI.

CONCLUSION

CST is a rare complication following fungal sinusitis secondary

to invasive *Aspergillus* and even rarer still in non-invasive cases. Since there are few documented cases of this complication secondary to non-invasive fungal sinusitis, not much is known regarding medical therapy. Authors advocate surgical debridement in conjunction with medical therapy including anti-bacterials, but not necessarily anti-fungals. CST may be caused by a secondary bacterial infection that leads to an inflammatory reaction and hypercoagulability and not by the organism itself. Patients have been shown to improve with antibiotics only. Our patient improved after surgical debridement and antibiotics combined with anti-fungals. It is also unknown whether anticoagulation therapy for CST in non-invasive fungal sinusitis is warranted, but most physicians opt to treat rather than risk severe complications that may follow thrombosis.

REFERENCES

1. Yarrington CT, Jr. Cavernous sinus thrombosis revisited. *Proc Royal Soc Med.* 1977; 70: 456-459.
2. Fokkens W, Lund V, Mullol J: European Position Paper on Rhinosinusitis and Nasal Polyps. *Rhinol Suppl* 2007, 20: 1-136.
3. Sekhar LN, Dujovny M, Rao GR. Carotid-cavernous sinus thrombosis caused by *Aspergillus fumigatus*. Case report. *J Neuro Surg* 1980; 52: 120-125.
4. Dyken ME, Biller J, Yuh WT, et al. Carotid-cavernous sinus thrombosis caused by *Aspergillus fumigatus*: magnetic resonance imaging with pathologic correlation--a case report. *Angiology.* 1990; 41: 652-657 [erratum appeared in *Angiology.* 1991; 42: 172].
5. Urculo E, Aranzadi M, Ruiz I, et al. *Aspergillus* granuloma of the cavernous sinus: magnetic resonance imaging with pathologic correlation. *Acta Neurochirurgica.* 2005: 341-342.
6. Cannon ML, Antonio BL, McCloskey JJ, et al. Cavernous sinus thrombosis complicating sinusitis. *Ped Crit Care Med.* 2004; 5: 86-88.
7. Chandra S, Goyal M, Mishra NK, et al. Invasive aspergillosis presenting as a cavernous sinus mass in immuno competent individuals; report of 3 cases. *Neuroradiology.* 2000; 42: 108-111.
8. Freudenstein D, Koerbel A, Beschoner R, et al. Successful treatment of *Aspergillus* granuloma involving the cavernous sinus and the middle fossa by using surgery and voriconazole. *J Neurosurg.* 2007; 106: 511.
9. Goel A, Nadkarni T, Desai A. *Aspergilloma* in the Paracavernous Region. *Neurologia Medico-Chirurgica (Tokyo)* 1996; 36: 733-736.
10. McClay J, Marple B. Allergic Fungal Sinusitis. In: e-medicine: <http://www.emedicine.com/Ent/topic510.htm>. LG Close FT, SG Batuello, CL Slack, AD Meyers, editor; 2006.
11. Ebbens F, Georgalas C, Rinia A et al. The fungal debate: where do we stand today? *Rhinology* 2007, 45: 178-189.
12. Manning SC, Holman M. Further Evidence for Allergic Pathophysiology in Allergic Fungal Sinusitis. *Laryngoscope* 1998; 108: 1485-1496.
13. Bent J, Kuhn F. Diagnosis of allergic fungal sinusitis. *Otolaryngol Head Neck Surg.* 1994; 111: 580-588.
14. Ponikau J, Sherris D, Kern E, et al. The Diagnosis and Incidence of Allergic Fungal Sinusitis. *Mayo Clinic Proc.* 1999; 74: 877-884.
15. Deveze A, Facon F, Latil G, et al. Cavernous sinus thrombosis secondary to non-invasive sphenoid aspergillosis. *Rhinology* 2005; 43: 152-155.
16. Denning D, Stevens D. Antifungal and surgical treatment of invasive aspergillosis: review of 2,121 published cases. *Rev Infect Dis.* 1990; 12: 1147-1201.
17. Shaw R. Cavernous sinus thrombophlebitis: a review. *Brit J Surg* 1952: 40-48.
18. Karlin R, Robinson W. Septic cavernous sinus thrombosis. *Ann Emerg Med.* 1984: 449-455.
19. Levine SR, Twyman RE, Gilman S. The role of anticoagulation in cavernous sinus thrombosis. *Neurology.* 1988; 38: 517-522.
20. Visudtibhan A, Visudhiphan P, Chiemchanya S. Cavernous sinus thrombophlebitis in children. *Ped Neurol.* 2001; 24: 123-127.
21. Bhatia K, Jones NS. Septic cavernous sinus thrombosis secondary to sinusitis: are anticoagulants indicated? A review of the literature. *J Laryngol Otol.* 2002; 116: 667-676.

Johnathan McGinn, MD

Division of Otolaryngology - Head & Neck Surgery
Penn State Milton S. Hershey Medical Center
500 University Drive, MC H091
Hershey, PA 17033
USA

Tel: +1-717-531-8945
Fax: +1-717-531-6160
E-mail: jmcmginn@psu.edu

ERRATUM

In the second abstract "*Anticoagulation and epistaxis*" of the meeting report (*Rhinology* 46, 345-347, 2008), the affiliation of Drs. Walker, Rutter, and McGarry was unfortunately wrongly indicated. They are in fact based at North Glasgow Otolaryngology Department, Gartnavel General Hospital, Glasgow, Scotland.