

Endoscopic management of inverted papillomas: long-term results – the St. Paul's Sinus Centre experience

Carl M. Philpott, Alia Dharamsi, Miranda Witheford, Amin R. Javer

St Paul's Sinus Centre, St Paul's Hospital, Vancouver, BC, Canada

SUMMARY

Objectives: To demonstrate that computer-assisted endoscopic management of inverted papillomas yields excellent long-term results in terms of preventing recurrence and minimizing significant morbidity and mortality.

Methods: A retrospective chart review of patients who are being followed up for tumour recurrence or have undergone tumour removal between 2000 and 2008. All cases were undertaken using the GE Instatrak 3500+ navigation system.

Results: Inverted papillomas are the most common tumour managed endoscopically (57% of all sinonasal tumours) with 76 patients seen over the last 8 years. Approximately 50% of these cases had undergone previous surgery in another centre where the tumour was either not recognized or the resection was incomplete. Twentynine percent of these patients had a recurrence but only three required a revision procedure using an open approach; otherwise recurrences were successfully managed endoscopically. Endoscopic recurrence during the first half was 32% (versus 14% for open procedures), dropping to a recurrence rate of 11% in the latter period.

Conclusions: Endoscopic management of inverted papillomas allows good control of the disease and avoids unnecessary morbidity associated with open procedures. Although there is a higher initial recurrence rate, these recurrences can be successfully managed endoscopically, and computer navigation can be a useful adjunct in achieving this.

Key words: paranasal sinus neoplasms, inverted papilloma, endoscopic surgical procedures, image guided surgery

INTRODUCTION

Endoscopic management of sino-nasal disease is a technique that, whilst now an established part of subspecialty rhinologic practice, is still in its relative infancy. Over the past two decades, the role of endoscopes in the diagnosis and management of sino-nasal and anterior skull base neoplasms has expanded dramatically with endoscopic approaches becoming the gold standard for removal^(1,2), with excision control rates comparable to the traditional open methods such as lateral rhinotomy and external frontoethmoidectomy⁽³⁾. Initially the endoscopes were utilized for detection and investigation of pathology as well as surveillance for post-operative tumour recurrence following traditional external procedures⁽⁴⁾. This later expanded to include resection in palliative scenarios, and for patients with benign tumours, most notably fibro-osseous lesions and inverted papilloma, with the latter first being reported by Waitz and Wigand⁽⁵⁾. As familiarity with endoscopic techniques increased, this was followed by resection of primary and recurrent malignant neoplasia⁽⁶⁾. Image guidance for sinus surgery is increasing in use globally^(7,8) although remains predominantly the realm of tertiary rhinology centres. The reliability, accuracy

and feasibility of using image guidance systems has developed alongside the endoscopic revolution⁽⁹⁾ with both infra-red and electromagnetic systems evolving as technology improves. Roth et al. stated 2-3 mm as the achievable standard for accuracy in 1995⁽¹⁰⁾ and currently the accepted error margin for the electromagnetic system in use at St. Paul's Sinus Centre is below 2 mm. This error margin is dependent on the registration process (known as the fiducial registration error (FRE)) and is in line with the average FRE readings from the literature⁽¹¹⁾. Although the issue of accuracy does have its limitations⁽¹²⁾, the availability of a three-dimensional visualisation of a sino-nasal tumour rather than just the two-dimensional endoscopic image can be invaluable, especially when neurovascular structures are adjacent to or involved in the tumour⁽¹³⁾.

The purpose of this study is to demonstrate the effectiveness of a computer-assisted endoscopic approach in achieving good long-term outcomes in the management of inverted papillomas at a tertiary referral centre.

METHODS

Study design

A retrospective review of case notes was performed for patients with inverted papillomas treated under the care of the senior author (ARJ) at St Paul's Sinus Centre between 2000 and 2008. For the purposes of looking specifically at patients with a complete 5-year follow-up, only the patients managed between 2000 and 2004 were considered. The key aspects identified in the notes were the site of the tumour, any recurrence including the timing, any morbidity and mortality and the need for any adjunct or substituted external approach to the endoscopic resection. The results below reflect on the practice of primary endoscopic resection of IPs as a preference with the use of computer navigation software in the operating theatre. At St Paul's Hospital, the system in current use is the GE Instatrak 3500 plus electromagnetic system 14. This system utilises a reference headset, which is worn by the patient during their CT scan and is then reapplied to their head once they are anaesthetised in the operating theatre. Calibration for a straight and 45° suction is performed on the headset transmitter at the beginning of the procedure; a 90° suction can be added and calibrated later if required. All patients have been followed carefully in the outpatient clinic where possible at 6 week intervals for the first year and then at 2-3 month intervals for successive years until 5 years after the last procedure.

Surgical techniques

Endoscopic adjuncts:

With the primary goal of achieving a thorough surgical clearance endoscopically, we utilise several adjuncts involving either technique, instrumentation or both to involve a progressively larger resection as necessary to remove the tumour.

Trans-septal approach: This technique allows for a greater angulation when accessing IPs that arise anteriorly in the maxillary sinus. The maxillary sinus is first approached conventionally by performing a complete uncinectomy and making a wide antrostomy using a 30° endoscope. When it becomes apparent that an endoscopic medial maxillectomy will be required, the resection of the medial wall of the maxilla progresses anteriorly through the nasolacrimal duct. Although it is possible to use greater scope angulations, a greater degree of movement may be achieved by bringing instruments across from the other side of the nose. In this respect, a Killian's incision is made on the opposite side of the nasal septum and the mucoperichondrial flap is elevated for a few millimetres posteriorly to allow a staggered incision into the cartilage. An exit wound is then made through the mucosa on the opposite side staggered again posterior to the cartilaginous incision. Either one or both of the endoscope and any instrument can now be passed through this access pathway to visualise and operate in the anterior maxillary sinus.

Obtuse angled instruments: 90° and 120° endoscopes and debridors are now available and can aid surgical access to the anterior and lateral maxillary sinus. They do, however, require a certain level of skill and dexterity to work at such angles from the plane of the instruments. Using one of these obtuse angled scopes can

even be used in conjunction with the trans-septal approach by bringing an instrument across the septum whilst holding the scope tip closer to the site of intervention.

Open adjuncts:

Caldwell-Luc assisted: In our centre, this technique is the exception rather than the rule. Creating a small anterior window enough to allow an endoscope or drill tip into the maxillary sinus may be necessary where the above techniques are unable to allow or not suitable to facilitate adequate visualisation or surgical access to the anterior sinus wall.

Osteoplastic flap – gull wing incision: This incision enables a superiorly based skin flap to be elevated and expose the frontal sinuses and may be useful where a small window is required to allow an instrument or endoscope to be passed from above whilst working from below. A limited incision may be used to enable a trephine rather than creating a more formal bony window.

Osteoplastic flap – coronal flap: This incision with an inferiorly based skin flap allows wide exposure to the anterior table of the frontal sinuses and with the bony window removed gives unrivalled visualisation and access to both frontal sinuses.

RESULTS

In the last eight years, there have been 76 patients with IPs managed at St Paul's Sinus Centre. The age range for the patients was 12 to 85 years old (mean of 59) with 56 male and 21 female patients. In terms of 5 year follow up, of all tumour cases performed between 2000 and 2004, there were 18 patients with 22 recurrences. The primary site of the IPs was the maxillary sinus in nearly half of the cases, with the remaining sinuses accounting for most of the remainder (Table 1, Figure 1). Open procedures utilised included the osteoplastic flap (n = 6; bicoronal and gull-wing incisions) and Caldwell-Luc assisted (n = 3), as well as the endoscopic adjunct of the trans-septal approach to the anterior maxillary sinus when undertaking an endoscopic medial maxillectomy and these are detailed further below⁽¹⁵⁾.

For the initial period of 2000-4 the recurrence rate following resection of IPs was 18 out of 41 (43%), with 3 patients requiring an open procedure (2 at revision, 1 prior to treatment at St Paul's Hospital). In this early cohort only 4 patients with recurrences were primary resections; the remaining recurrences occurred in patients (n = 14) who had had their initial surgery elsewhere (78%). Other noteworthy findings were that 2 patients had 5 revisions between them, 2 died of other causes before revision and 2 patients did not have revisions due to medical co-morbidity. From

Table 1. Inverted papillomas – primary site by frequency and percentage.

Site of lesion	Number	Percentage	Left	Right
Maxillary	37	49%	18	19
Frontal	14	18%	8	6
Ethmoid	11	14%	7	4
Sphenoid	9	12%	4	5
Septum	4	5%	2	2
Lateral wall	1	1%	1	0
	76	–	40	36

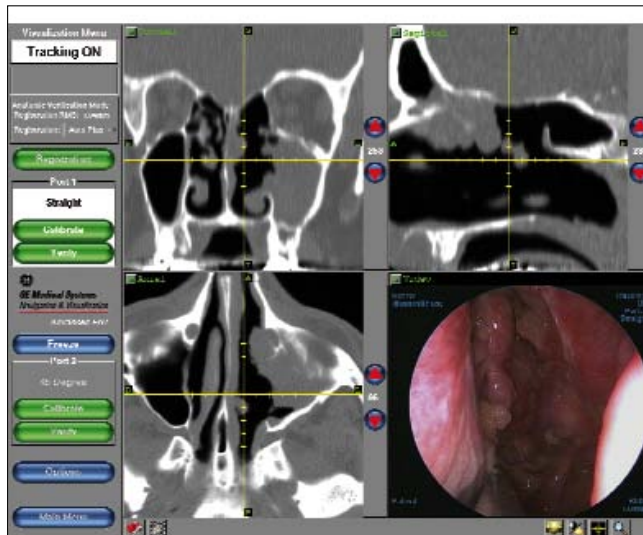


Figure 1. Endoscopic and image guidance software view of multifocal recurrence of an inverted papilloma.

the 23 non-recurrences, 13 patients had their primary surgery elsewhere (56%). The difference in the rate for primary surgery versus revision surgery was not however significant ($p = 0.27$). The morbidity for these IPs is summarised in Table 2.

Follow-up for IPs during the second period (2005-8) showed 5 recurrences to date in 4 patients at 1 month, 5 months, 6 months and in the fourth patient twice at 2 and 13 months. During this period, 4 open approaches were utilised for secondary management and only 12 patients were managed previously at another centre. This means that for this second period the recurrence rate to date is 4 out of 35 (11%). Immediate post-operative morbidity included the following: frontal sinusitis [1], epistaxis [4] of which 1 case was returned to theatre twice, headaches/facial pain [2], paraesthesia [2] and CSF leak [1], which required a revision craniotomy (Table 2). Persistent morbidity in this group included crusting [2], mucocoele formation [2], CRS [1] and RARS [1]. With the two periods combined, the recurrence rate for 2000-8 was 22/76 (29%).

For all cases of IP managed during 2000-2008, when the primary surgery was performed at St Paul's Hospital, the mean time for recurrence was 12 months as compared to 8.5 months when the primary surgery was performed elsewhere ($p < 0.001$; Table 3). Overall the mean time for recurrence was 13.4 months and was

Table 2. Morbidity for IP resections 2000-2004.

Symptom	Frequency
Epistaxis	4 patients; 1 returned to theatre
Infection (sinusitis)	2
Persistent crusting	5
CSF leak & revision craniotomy	1
Pain/headaches	3
Paraesthesia	2
Mucocoele formation	2

Table 3. Timing of recurrence in IPs.

Patient scenario	Mean time to recurrence
Previous surgery elsewhere	8.5 months
Primary surgery at SPH ($p < 0.001$)	12 months
Endoscopic approach (n = 21)	11.1 months
Combined/open approach (n = 1)	17.0 months
All recurrences	13.4 months

Table 4. Recurrence rate according to Krouse Staging.

Krouse Stage	Number of patients	Number of recurrences	Percentage recurrence rate for stage
1	4	3	75%
2	12	1	8%
3	53	13	25%
4	7	5	71%
Total	76	22	

shorter in the endoscopic group (11.1 months) than in the combined/open approach group (17 months). For managing the recurrences, an open approach was used in 3 cases (13%) and the remainder were managed endoscopically (Figure 1).

Krouse Staging

The breakdown of cases by Krouse staging⁽¹⁶⁾ is shown in Figure 2, demonstrating that the majority of cases dealt with were stage 3 or 4 (86%). Table 4 summarises recurrences according to staging; the highest recurrence rate was seen in stage 1, where all the cases were IPs of septal origin. The stage 4 cases had the next highest recurrence rate at 71%.

DISCUSSION

The timing of any recurrence is an important consideration in the follow-up of the patients post-operatively. The community served by St Paul's Hospital covers an enormous geographic area (Western Canada – British Columbia, Yukon, (Alberta, Saskatchewan, Manitoba), which means that patients may have considerable distances to travel for clinic appointments and are therefore at higher risk of missing them. Despite these challenges, the follow-up at our centre has been excellent.

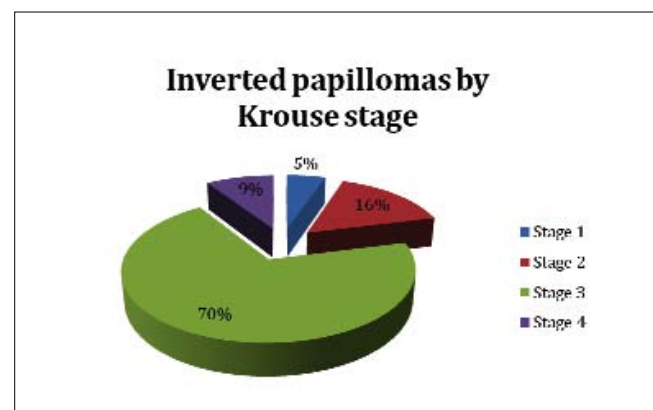


Figure 2. Percentages of cases according to Krouse staging.

In recent years, there has been a greater move towards endoscopic management of IPs but with ongoing concerns about incomplete excision, adjunct open procedures are often performed. Tufano et al. showed that an external endoscopic approach rather than a formal open procedure can yield good results in obtaining clearance of IPs⁽¹⁷⁾. Other centres have shown recurrence rates for endoscopic and open approaches to be equal in terms of recurrence rates⁽¹⁸⁾ (Table 5). Although our total figures do not currently match the recurrence rate for the endoscopic approach in the meta-analysis, our more recent figures are currently on a par with their 12% rate and we have a low rate for the open procedures, albeit with only a handful of cases. Based on the Krouse staging, our figures suggest a higher number of stage 3 and 4 tumours than other centres^(19,20) but with recurrence rates in the stage 3 cases showing very similar percentages⁽²¹⁾. Where other centres have demonstrated similar numbers of stage 3 and 4 tumours, there appears to have been a greater reliance on open procedures^(3,22).

In 2005, Barzilai et al. discussed the rationale for using the Caldwell-Luc approach for maxillary sinus disease and incredibly reported higher numbers of cases for chronic rhinosinusitis than for inverted papillomas, however they did conclude that this approach should be reserved for IPs and fungal disease in the endoscopic era⁽²³⁾. Lund sets out the case for selective use of appropriate techniques depending on the extent of the tumour but clearly shows an excellent example of the success of the endoscopic approach in her case series of 37 cases⁽²⁴⁾. Furthermore, she makes the pertinent point that it is difficult to know the full extent of mucosal involvement until the time of surgery and so

on this basis, patients should be counselled and consented for the possibility of an open adjunct procedure. The figures from our centre demonstrate that the maxillary sinus is the most common primary site for IPs accounting for 49%. These figures are however in disagreement with some authors including Alba et al.⁽²⁵⁾ who suggested the sphenoid sinus is rarely affected.

The technology for image guided surgery is continually improving with the latest generation of machines allowing fusion of CT and MRI images to give both the bony and soft tissue definition combination, which can be very useful in endonasal surgery for sino-nasal tumours⁽¹³⁾. It should always be clear, however, that no technological advances are any substitute for good surgical skills in dealing with these cases. Specifically, meticulous surgical technique, anatomical knowledge and appropriate selection of instrumentation and approaches will help achieve a good outcome^(13,26).

CONCLUSION

Endoscopic management of IPs can achieve good control of the disease and reduce the need for open procedures with their increased morbidity, and the use of computer navigation can be a useful adjunct. The role in the modern era for endoscopic resection of these tumours as the preferred approach is clear⁽²⁷⁾ and although there is a higher initial recurrence rate, these recurrences can be successfully managed endoscopically.

ACKNOWLEDGEMENTS

Dr Allan Clark, University of East Anglia, Norwich – for his statistical advice.

Table 5. Inverted papilloma series in the literature comparing endoscopic alone with combined/open approaches (2000-present).

Author series	Year	Endoscopic cases	Recurrence	Open or open adjunct	Recurrence
Winter et al. ⁽²⁸⁾	2000	67	22.4%	37	16.2%
Lund ⁽²⁴⁾	2000	13	8%	24	21%
Zumegan et al. ⁽²⁹⁾	2000	25	48%	29	24%
Klimek et al. ⁽¹⁸⁾	2000	33	18%	22	18%
Andersen et al. ⁽³⁰⁾	2001	12	7%*	16	*
Krouse ⁽³¹⁾	2001	7	14%	5	0%
Schlosser et al. ⁽³²⁾	2001	20	20%	1	0%
Han et al. ⁽³³⁾	2001	15	13%	12	8%
Thorp et al. ⁽³⁴⁾	2001	2	0%	41	27%
Sadeghi et al. ⁽³⁵⁾	2003	5	0%	6	0%
Kraft et al. ⁽³⁶⁾	2003	26	8%	8	37%
Lawson et al. ⁽³⁷⁾	2003	41	12%	119	15%
Pasquini et al. ^(?)	2004	36	3%	32	19%
Dubin et al. ⁽³⁷⁾	2005	5	40%	1	0%
Minovi et al. ⁽³⁸⁾	2006	61	10%	16	15%
Baradaranfar ⁽³⁹⁾	2006	20	6%*	4	*
Busquets et al. ⁽⁴⁰⁾	2006	28	11%	1	0
Stange et al. ⁽⁴¹⁾	2008	64	17.5%	16	20%
Lee et al. ⁽²²⁾	2009	79	4%	11	21%
Lawson ⁽³⁾	2009	6	15%	17	43%
Philpott et al. ⁽⁴²⁾	2009	69	32%	7	14%
Busquets (MA) ⁽⁴⁰⁾	2006	714	12%	346	20%

* Abstract information in English only – not possible to derive open procedure data

MA = meta-analysis

Table does not include series where endoscopic approaches alone were reported.

REFERENCES

1. Banhiran W, Casiano RR. Endoscopic sinus surgery for benign and malignant nasal and sinus neoplasm. *Curr Opin Otolaryngol Head Neck Surg.* 2005; 13: 50-54.
2. Reh DD, Lane AP. The role of endoscopic sinus surgery in the management of sinonasal inverted papilloma. *Curr Opin Otolaryngol Head Neck Surg.* 2009; 17: 6-10.
3. Lawson W, Patel ZM. The evolution of management for inverted papilloma: an analysis of 200 cases. *Otolaryngol Head Neck Surg.* 2009; 140: 330-335.
4. Blokmanis A. Endoscopic diagnosis, treatment, and follow-up of tumours of the nose and sinuses. *J Otolaryngol.* 1994; 23: 366-369.
5. Waitz G, Wigand ME. Results of endoscopic sinus surgery for the treatment of inverted papillomas. *Laryngoscope.* 1992; 102: 917-922.
6. Stammberger H, Anderhuber W, Walch C, Papaefthymiou G. Possibilities and limitations of endoscopic management of nasal and paranasal sinus malignancies. *Acta Otorhinolaryngol Belg.* 1999; 53: 199-205.
7. Han D, Zhou B, Ge W, Zhang L, Zhang Y. Application of an image-guidance system in endoscopic sinus surgery. *Zhonghua er bi yan hou ke za zhi.* 2001; 36: 126-128.
8. Tschopp KP, Thomaser EG. Outcome of functional endonasal sinus surgery with and without CT- navigation. *Rhinology.* 2008; 46: 116-120.
9. Javer AR, Kuhn FA. Stereotactic computer-assisted navigational sinus surgery: historical perspective and review of the available systems. *J Otolaryngol.* 2001; 30: 60-64.
10. Roth M, Lanza DC, Zinreich J, Yousem D, Scanlan KA, Kennedy DW. Advantages and disadvantages of three-dimensional computed tomography intraoperative localization for functional endoscopic sinus surgery. *Laryngoscope.* 1995; 105: 1279-1286.
11. Schmerber S, Chassat F. Accuracy evaluation of a CAS system: laboratory protocol and results with 6D localizers, and clinical experiences in otorhinolaryngology. *Comput Aided Surg.* 2001; 6: 1-13.
12. Labadie RF, Davis BM, Fitzpatrick JM. Image-guided surgery: what is the accuracy? *Curr Opin Otolaryngol Head Neck Surg.* 2005; 13: 27-31.
13. Sama A, Jones NS. Image-Guided Surgery in Rhinology. *ENT News.* 2009; 17: 57-59.
14. Kherani S, Javer AR, Woodham JD, Stevens HE. Choosing a computer-assisted surgical system for sinus surgery. *J Otolaryngol.* 2003; 32: 190-197.
15. Wormald PJ, Ooi E, van HCA, Nair S. Endoscopic removal of sinonasal inverted papilloma including endoscopic medial maxillectomy. *Laryngoscope.* 2003; 113: 867-873.
16. Krouse JH. Development of a staging system for inverted papilloma. *Laryngoscope.* 2000; 110: 965-968.
17. Tufano RP, Thaler ER, Lanza DC, Goldberg AN, Kennedy DW. Endoscopic management of sinonasal inverted papilloma. *Am J Rhinol.* 1999; 13: 423-426.
18. Klimek T, Atai E, Schubert M, Glanz H. Inverted papilloma of the nasal cavity and paranasal sinuses: clinical data, surgical strategy and recurrence rates. *Acta Oto-Laryngologica.* 2000; 120: 267-272.
19. Minovi A, Kollert M, Draf W, Bockmühl U. Inverted papilloma: feasibility of endonasal surgery and long-term results of 87 cases. *Rhinology.* 2006; 44: 205-210.
20. Lee TJ, Huang SF, Huang CC. Tailored endoscopic surgery for the treatment of sinonasal inverted papilloma. *Head Neck.* 2004; 26: 145-153.
21. Lee TJ, Huang SF, Lee LA, Huang CC. Endoscopic surgery for recurrent inverted papilloma. *The Laryngoscope.* 2004; 114: 106-112.
22. Lee TJ, Huang CC, Chen YW, Chang KP, Fu CH, Chang PH. Medially originated inverted papilloma. *Otolaryngol Head Neck Surg.* 2009; 140: 324-329.
23. Barzilai G, Greenberg E, Uri N. Indications for the Caldwell-Luc approach in the endoscopic era. *Otolaryngol Head Neck Surg.* 2005; 132: 219-220.
24. Lund VJ. Optimum management of inverted papilloma. *J Laryngol Otol.* 2000; 114: 194-197.
25. Alba JR, Armengot M, Díaz A, Pérez A, Rausell N, Basterra J. Inverted papilloma of the sphenoid sinus. *Acta Otorhinolaryngol Belg.* 2002; 56: 399-402.
26. Fokkens WJ. No tracking system replaces good seamanship. *Rhinology.* 2008; 46: 81.
27. Krouse JH. Evolution in the management of inverted papilloma. *Otolaryngol Head Neck Surg.* 2009; 140: 336-337.
28. Winter M, Rauer RA, Göde U, Waitz G, Wigand ME. Inverted papilloma of the nose and paranasal sinuses Long-term outcome of endoscopic endonasal resection. *HNO.* 2000; 48: 568-72.
29. Zumege C, Thomas JP, Michel O. Experience with endonasal endoscopic surgery of inverted papilloma of the nose and paranasal sinuses. *Laryngorhinootologie.* 2000; 79: 221-225.
30. Andersen PJ, Kjeldsen AD, Pedersen AT. Treatment of inverted papilloma with endonasal endoscopic sinus surgery. *Ugeskrift for laeger.* 2002; 164: 4283-4287.
31. Krouse JH. Endoscopic treatment of inverted papilloma: safety and efficacy. *Am J Otolaryngol.* 2001; 22: 87-99.
32. Schlosser RJ, Mason JC, Gross CW. Aggressive endoscopic resection of inverted papilloma: an update. *Otolaryngol Head Neck Surg.* 2001; 125: 49-53.
33. Han JK, Smith TL, Loehrl T, Toohill RJ, Smith MM. An evolution in the management of sinonasal inverting papilloma. *Laryngoscope.* 2001; 111: 1395-1400.
34. Thorp MA, Oyarzabal-Amigo MF, du Plessis JH, Sellars SL. Inverted papilloma: a review of 53 cases. *Laryngoscope.* 2001; 111: 1401-1405.
35. Sadeghi N, Al-Dhahri S, Manoukian JJ. Transnasal endoscopic medial maxillectomy for inverting papilloma. *Laryngoscope.* 2003; 113: 749-753.
36. Kraft M, Simmen D, Kaufmann T, Holzmann D. Long-term results of endonasal sinus surgery in sinonasal papillomas. *Laryngoscope.* 2003; 113: 1541-1547.
37. Dubin MG, Sonnenburg RE, Melroy CT, Ebert CS, Coffey CS, Senior BA. Staged endoscopic and combined open/endoscopic approach in the management of inverted papilloma of the frontal sinus. *Am J Rhinol.* 2005; 19: 442-445.
38. Minovi A, Kollert M, Draf W, Bockmühl U. Inverted papilloma: feasibility of endonasal surgery and long-term results of 87 cases. *Rhinology.* 2006; 44: 205-210.
39. Baradaranfar MH, Dabirmoghaddam P. Endoscopic endonasal surgery for resection of benign sinonasal tumors: experience with 105 patients. *Arch Iran Med.* 2006; 9: 244-249.
40. Busquets JM, Hwang PH. Endoscopic resection of sinonasal inverted papilloma: a meta-analysis. *Otolaryngol Head Neck Surg.* 2006; 134: 476-482.
41. Stange T, Schultz CHJ. Surgical management of inverted papillomas of the nose and paranasal sinuses. *HNO.* 2008; 56: 614-622.
42. Philpott C, Dharamsi A, Javer A. Endoscopic management of sinonasal tumours - the St Paul's Experience. *Rhinology World.* Philadelphia 2009.

Carl Philpott
 St Paul's Sinus Centre, St Paul's Hospital,
 1081 Burrard Street,
 Vancouver,
 British Columbia,
 V6Z 1Y6 Canada

E-mail: carl.philpott@btinternet.com