

Outcomes of intubation and endoscopic DCR in functional nasolacrimal duct obstruction*

Yinon Shapira^{1,2}, Carmelo Macri^{1,2}, Eiman Usmani^{1,2}, Alkis J Psaltis^{3,4},
Weng O Chan^{1,2}, Dinesh Selva^{1,2}

Rhinology 60: 0, 0 - 0, 2022

<https://doi.org/10.4193/Rhin22.047>

¹ Discipline of Ophthalmology and Visual Science, University of Adelaide, Adelaide, SA, Australia

² Department of Ophthalmology, Royal Adelaide Hospital and South Australian Institute of Ophthalmology, Adelaide, SA, Australia

³ Department of Otolaryngology Head and Neck Surgery, University of Adelaide, Adelaide, SA, Australia

⁴ Department of Otolaryngology Head and Neck Surgery, Central Adelaide Health Network, Adelaide, SA, Australia

*Received for publication:

January 29, 2022

Accepted: March 30, 2022

Abstract

Background: To ascertain the success of lacrimal intubation and DCR in alleviating epiphora due to functional nasolacrimal duct obstruction (FNLDO).

Methods: Consecutive adult patients with epiphora attending a tertiary lacrimal clinic from May 2010 to February 2021 were reviewed to identify cases with FNLDO. FNLDO was defined as epiphora with the exclusion of alternate causes of watering on clinical examination, patent lacrimal syringing, normal DCG, and post-sac delay on DSG. Epiphora resolution and improvement rates in FNLDO were compared between lacrimal intubation and endo-DCR.

Results: 23 endo-DCRs (20 patients, 65% females, mean age 68.9 ± 12.2) and 41 intubations (29 patients, 61.2% females, mean age 65.0 ± 14.1) performed in FNLDO were included. Resolution of epiphora was achieved in 15 of the DCR procedures (median follow-up 9 months) compared to 14 of intubations (median follow-up 10 months). Significant epiphora improvement (i.e., either improvement or resolution) was noted in 21 DCRs and 24 intubations. Seven patients undergoing intubation as the primary procedure had endo-DCR performed following the intubation. Among respondents to a phone questionnaire, 53.8% who had endo-DCR (median 69 months) and 50% that had intubation (median 28 months) reported significant improvement in epiphora.

Conclusions: Improvement in epiphora due to FNLDO was approximately 59% in intubations, while the success of endo-DCR was higher (91%). The long-term results of these interventions warrant further investigation.

Key words: functional block, silicone stenting, endoscopic DCR, success, outcomes

Introduction

Epiphora patients with a patent but dysfunctional nasolacrimal duct (NLD) drainage (i.e., 'functional block') are commonly encountered in the lacrimal clinic⁽¹⁾. Nevertheless, the evidence regarding the preferred intervention in this scenario, namely lacrimal intubation or DCR, is limited^(2,3). Furthermore, due to lack of uniformity in diagnosing and defining functional NLD obstruction (FNLDO), most studies reporting success rates of lacrimal intubation⁽³⁻⁵⁾ or DCR⁽⁶⁻¹⁰⁾ do not differentiate between anatomical NLD stenosis (NLDS) and FNLDO in their 'functional block' cohort.

Dacryocystography (DCG) and dacryoscintigraphy (DSG) can be combined to determine the specific cause of NLD impairment,

differentiating anatomical stenosis (NLDS) from non-anatomical FNLDO^(1,2,11,12). The current study reports the results of lacrimal intubation in FNLDO and compares them to those of endoscopic DCR in this group.

Materials and methods

Data was collected retrospectively from consecutive adult patients with epiphora attending the Royal Adelaide Hospital lacrimal clinic from May 2010 to February 2021. The study received Institutional Review Board (IRB) approval and adhered to the tenets of the Declaration of Helsinki.

Based on the clinical assessment, patients with puncto-canalicular obstruction/stenosis, eyelid malposition/paralysis, potential

Table 1. Demographic and Preoperative Baselines of FNLDO patients stratified by treatment group.

	Endoscopic DCR (n=23 for 20 patients)	Lacrimal Intubation (n=41 for 29 patients)	P
Age (mean years)	68.9±12.2	65.0±14.1	0.33
Gender (% female)	65%	62.1%	0.84
Duration of epiphora (median months [range])	24 [2-72]	36 [2-240]	0.24
Epiphora (Munk) severity (mean)	4.33±1.0	4.06±0.90	0.48

FNLDO functional nasolacrimal duct obstruction; DCR dacryocystorhinostomy

causes of reflex tearing, acute dacryocystitis, or previous lacrimal surgery were excluded. Patients with canalicular or nasolacrimal duct obstruction on DCG were excluded. In addition, those with presac delay or normal transit on DSG were excluded.

FNLDO diagnosis was based on patent lacrimal syringing along with a normal DCG and a post-sac delay on DSG. All Imaging studies were performed by trained radiologists and assessed by an experienced oculoplastic surgeon, as previously described⁽¹³⁾. Patients diagnosed with FNLDO were presented with two options: Silicone tube intubation or endoscopic DCR. They were advised that the success rate of intubation may be lower than that of DCR and that intubation is generally a less invasive procedure with a potentially faster recovery. They were told that in the event of failure of intubation to resolve epiphora, DCR could be offered as a secondary procedure. We then proceeded based on the patient's choice.

Procedures

All procedures were carried out or supervised by a tertiary oculoplastic surgeon (D.S.). In patients who elected to undergo DCR, powered endoscopic DCR without intubation was performed under general or local anesthesia with sedation as previously described⁽¹⁴⁾. Briefly, the osteotomy was performed with a punch (Hajek Koffler, Martin, Tuttlingen, Germany) and powered rough-diamond DCR burr (Medtronic-Xomed, Jacksonville, FL, USA). Mucosal apposition and complete bone coverage with anterior and posterior lacrimal flaps were ensured. No stents were used in any of these patients. Postoperative instructions included daily nasal douching with a saline spray for two weeks that commenced the day after surgery. For patients electing to proceed with intubation, Nunchaku® (FCI Ophthalmics, Boston, MA, USA) silicone self-retaining bicanalicular nasolacrimal intubation stent was used. Intubation was conducted under general or local anesthesia with sedation, and tubes were left in place for eight weeks.

Success of intervention

Epiphora resolution was determined based on the final postoperative assessment in the clinic and was scored as follows: 1) complete resolution of epiphora; 2) partial resolution; and 3)

no resolution or worsening of epiphora. The assessment of success was based on the last postoperative follow-up before the secondary procedure if subsequent surgical procedures were undertaken to treat epiphora.

A telephone questionnaire was conducted to evaluate longer-term outcomes. The patients were asked to quantify their symptoms on the following scale: 1) complete resolution of epiphora; 2) significant improvement; 3) slight improvement; 4) no change; and 5) worsening of epiphora. Patients were also asked if they would recommend the treatment they had to others suffering from watery eyes.

Statistical analysis

Data were analyzed by the StatSoft Statistica software, version 10 (StatSoft, OK, USA). Means were compared by Student's t-test. In skewed data, medians were compared by the Mann-Whitney U test. Proportions were compared by the chi-square or Fisher exact test, as appropriate. A two-sided p-value < 0.05 was considered significant.

Results

A total of 64 consecutive symptomatic eyes/lacrimal systems of 49 patients with FNLDO were included (Table 1). Among these, 23 DCRs (20 patients, 65% females) and 41 intubations (29 patients, 62.1% females; p=0.84) were performed as the primary procedure. The mean age in the DCR and intubation groups was 68.9±12.2 years (range 42-90) and 65.0±14.1 years (range 34-86), respectively (p=0.33). There was no significant difference in the median duration of epiphora between the DCR (24 [range 2-72] months) and intubation (36 [range 2-240] months) groups (p=0.24). There was no significant difference in the baseline epiphora (Munk) severity between the DCR (4.33±1.0) and intubation (4.06±0.90) groups (p=0.48).

The postoperative follow-up was a median of 9 (range 2-84) months for the DCR procedures and 10 (range 2-55) months for the intubations (p=0.53). Figure 1 presents the comparison of postoperative outcomes (for endoscopic DCR versus lacrimal intubation) at the last clinical follow-up appointment and at the time of the extended follow-up via phone questionnaire. Resolution of epiphora was achieved in 15 (65.2%) of the DCR

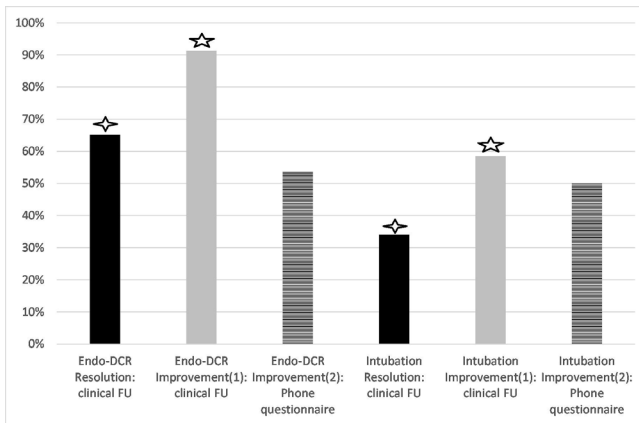


Figure 1. Comparison of postoperative outcomes (for endoscopic DCR versus lacrimal intubation) in functional nasolacrimal duct obstruction patients, at the last clinical follow-up appointment and at the time of an extended follow-up via phone questionnaire. (1) Self-reported resolution or improvement of epiphora (clinical follow-up); (2) Self-reported resolution or significant improvement of epiphora (phone questionnaire). \diamond $p=0.017$, \star $p=0.006$

procedures compared to 14 (34.1%) of intubations ($p=0.017$). The number of cases with an improvement of epiphora (i.e., either improvement or resolution) was 21 (91.3%) of DCRs and 24 (58.5%) of intubations ($p=0.006$). Only one patient (4.3%) undergoing DCR as the primary procedure had a DCR revision with intubation 78 months postoperative due to anatomical failure. Following this, the patient reported resolution of epiphora (and a patent ostium was demonstrated). In comparison, seven patients (17.1%, $p=0.24$) undergoing intubation as the primary procedure had DCR performed at a median of 17 (range 10-55) months following the intubation. Following the secondary DCR, epiphora resolved in four (of the seven) patients and remained unimproved in three despite anatomical patency. All cases were contacted for a phone questionnaire. Out of the 41 patients that did not undergo a subsequent lacrimal procedure, twenty-eight patients (37 eyes; 13 DCRs, and 24 intubations) responded, representing a 59.1% DCR and 70.6% intubation response rate. The median time from the procedure to the phone audit was 69 (range 18-82) months for the DCRs and 28 (range 7-66) months for the intubations ($p=0.003$). Of the DCR procedures, 7 (53.8%) reported significant improvement or resolution, compared to 12 (50.0%) of intubation respondents ($p=0.64$).

Specifically, of the eight DCR respondents that reported resolution of epiphora at their final clinical follow-up, three remained epiphora free at the time of the long-term phone audit, three reported significant improvement, and two reported no improvement. Of the five that reported improvement of epiphora on their final clinical follow-up, only one remained improved at the time of the phone audit. Of the ten intubation respondents that

reported resolution of epiphora at their final clinical follow-up, at the time of the phone audit, three reported that epiphora remains resolved, five reported significant improvement, and two reported no improvement. Of the six that reported improvement of epiphora on their final clinical follow-up, only two remained improved at the time of the phone audit. Out of the eight that had no improvement following the intubation at their final clinical follow-up, two reported significant improvement, one reported slight improvement, while five remained unchanged at the time of the phone audit.

Eight (61.5%) of the DCR and 15 (62.5%) of the intubation respondents attested that they would recommend the procedure to others suffering from watery eyes ($p=1.0$).

Finally, the patients who underwent a subsequent lacrimal procedure (following intubation or DCR) were also contacted. Out of the seven patients that underwent a secondary DCR following their intubation, six responded to the phone audit (median 39 [3-122] months postoperative). Two reported resolution, one reported slight improvement, and three reported worsening. The DCR patient who underwent subsequent revision and tube placement reported worsening epiphora (122 months follow-up).

Discussion

Debate exists amongst clinicians as to the first-line management for FNLDO. Some regard lacrimal intubation as first-line treatment, while others perceive intubation as inferior to DCR in this scenario^(3,15,16). We thus sought to audit our intubation and endoscopic DCR results in cases of FNLDO.

We found that lacrimal intubation in FNLDO improved epiphora in 59% of cases. Furthermore, 17% of all intubated patients wanted further surgical intervention (due to insufficient improvement) and underwent a secondary endoscopic DCR. At the final clinical follow-up, the intubation success rate was lower than that of endo-DCR, as the latter attained almost a 2-fold higher resolution rate (65%) and a significantly higher overall epiphora improvement rate (91%). Therefore, our experience suggests that lacrimal intubation may be less effective than endo-DCR in most cases of FNLDO.

The possibility of selection bias between these two groups should be acknowledged. While several baseline factors were shown to be comparable between the treatment groups (e.g., diagnosis of FNLDO, demographics, severity, and duration of epiphora), other variables could not be controlled for due to the retrospective nature of this study. Most significant is the possibility of surgeon influence when patients chose to undergo either intubation or endo-DCR. Although patients were given a choice, only a randomized trial could eliminate such bias.

One previous study directly compared the results of lacrimal intubation (using Crawford tubes) to DCR in patients with a patent but dysfunctional NLD drainage⁽³⁾. Cho et al.⁽³⁾ defined FNLDO

as patency to syringing but with evidence of post-sac delay on DSG but notably did not perform DCG. Arguably, this diagnostic methodology combines NLD stenosis and non-anatomical functional delay in the "functional block" cohort. In the current study, FNLDO was diagnosed based on the combined findings of syringing, DCG, and DSG. This diagnostic approach likely enables differentiation of FNLDO from NLDS^(2,12). Cho et al.⁽³⁾ report complete resolution of epiphora in 81.3% of endo-DCRs and 68.5% of intubations at six months of follow-up. Unlike our findings, the difference was not statistically significant. Furthermore, the complete resolution rate in both treatment groups was substantially higher than herein reported. These discrepancies may stem from the different definitions of FNLDO in the studies or differences in techniques.

To our knowledge, no published studies evaluated lacrimal intubation in FNLDO proven on combined DCG and DSG findings. There are, however, series that evaluated lacrimal intubation in a homogenous cohort of NLDS cases, verified via detection of partial anatomical blockage on DCG. Angrist et al.⁽¹⁶⁾ reported a 74% success rate in this group, comparable to the proportion reported by Cho et al.⁽³⁾. On the other hand, in a prospective study by Bleyen et al.⁽¹⁷⁾, the success rate of intubation in the NLDS cohort was only 52%. Our findings may suggest that success rates may be lower in a homogenous cohort of FNLDO.

Regarding DCR, previous studies that did not differentiate between partial stenosis and functional block report 50–94% success rates in this combined group of patients^(6–10). Only two studies investigated the effect of DCR on true functional block (i.e., confirmed by DCG and DSG). Peter and Pearson⁽¹⁸⁾ reported that 54% of eyes with normal anatomy on DCG had successful external DCRs. Wormald and Tsirbas⁽¹⁾ demonstrated a success rate of 84% of endo-DCR in FNLDO patients. Our reported (epiphora resolution) success rate of 65% for endo-DCR is within the range of these two studies. Our long-term results based on the phone questionnaire suggest that the success rate dropped to 54% in the subset of patients that responded.

However, the findings of our phone questionnaire should be interpreted with caution. Firstly, the response rate (i.e., 59% of DCRs and 70% of intubations) introduces a possible selection bias in both groups. Secondly, while the last clinical postoperative follow-up time was the same in both treatment groups, the time from treatment to the phone questionnaire was significantly longer in the DCR patients. This temporal bias may preclude comparison of the phone audit results between the groups, as it may erroneously portray a greater decline in DCR success when compared with intubation. These limitations notwithstanding, at a median of 69 months post-DCR and 28 months post lacrimal

intubation, approximately 60% of respondents in both groups attested that they would recommend the intervention to others. Further limitations of this study firstly include its retrospective, non-randomized nature. Second, while anatomical success rates are reported for the endo-DCR outcomes, such objective (anatomical) outcomes are not possible for lacrimal intubation in functional impairment. Therefore, the post-op outcome is clinician rated and may be prone to observation bias. Furthermore, it should be acknowledged that a telephone questionnaire may encourage the respondent to exaggerate outcomes in order to please the interviewer.

Conclusion

This study is the first to ascertain the success rate of lacrimal intubation and endo-DCR in functional NLD obstruction, utilizing clinical assessment and comprehensive lacrimal imaging (DCG and DSG) to ensure a homogenous cohort (excluding anatomical stenosis). The results of this single-center audit suggest that improvement in epiphora may be expected in approximately 59% of intubations, while the success of endo-DCR was significantly higher (91%). Nevertheless, preliminary evidence based on our phone questionnaire may suggest that the improvement following DCR may diminish after several years. The long-term results of these interventions in FNLDO warrant further investigation to draw a definite conclusion.

Acknowledgements

None.

Authorship contribution

YS: analysis and interpretation of data, drafting of manuscript, and critical revision. CM: analysis and interpretation of data, acquisition of data, and critical revision. EU: analysis and interpretation of data, acquisition of data, and critical revision. AJP: conception or design of the work, analysis and interpretation of data, and critical revision. WOC: conception or design of the work, analysis and interpretation of data, and critical revision. DS: conception or design of the work, analysis and interpretation of data, and critical revision.

Conflict of interest

All authors declare there are no competing financial interests in relation to the work described.

Funding

This study did not receive funding.

References

1. Wormald PJ, Tsirbas A. Investigation and endoscopic treatment for functional and anatomical obstruction of the nasolacrimal duct system. *Clin Otolaryngol Allied Sci*. 2004 Aug;29(4):352–356.
2. Chan W, Malhotra R, Kakizaki H, Leibovitch I, Selva D. Perspective: What does the term functional mean in the context of epiphora?

- ra? Clin Exp Ophthalmol. 2012;40(7):749–754.
3. Cho W-K, Paik J-S, Yang S-W. Surgical success rate comparison in functional nasolacrimal duct obstruction: simple lacrimal stent versus endoscopic versus external dacryocystorhinostomy. Eur Arch Otorhinolaryngol. 2013 Feb;270(2):535–540.
4. Kashkouli MB, Kempster RC, Galloway GD, Beigi B. Monocanalicular Versus Bicanalicular Silicone Intubation for Nasolacrimal Duct Stenosis in Adults. Ophthalmic Plast Reconstr Surg. 2005 Mar;21(2):142–147.
5. Moscato EE, Dolmetsch AM, Silkiss RZ, Seiff SR. Silicone Intubation for the Treatment of Epiphora in Adults With Presumed Functional Nasolacrimal Duct Obstruction. Ophthalmic Plast Reconstr Surg. 2012 Jan;28(1):35–39.
6. O'Donnell BA, Clement CI. Assessing patients with epiphora who are patent to syringing: Clinical predictors of response to dacryocystorhinostomy. Ophthal Plast Reconstr Surg. 2007;23(3):173–178.
7. Sahlin S, Rose GE. Lacrimal drainage capacity and symptomatic improvement after dacryocystorhinostomy in adults presenting with patent lacrimal drainage systems. Orbit. 2001 Jan 8;20(3):173–179.
8. Cheung LM, Francis IC, Stapleton F, Wilcsek G. Symptom assessment in patients with functional and primary acquired nasolacrimal duct obstruction before and after successful dacryocystorhinostomy surgery: a prospective study. Br J Ophthalmol. 2007 Dec 1;91(12):1671–1674.
9. Zaidi FH, Symanski S, Olver JM. A clinical trial of endoscopic vs external dacryocystorhinostomy for partial nasolacrimal duct obstruction. Eye (Lond). 2011 Sep;25(9):1219–1224.
10. Delaney YM, Khooshabeh R. External dacryocystorhinostomy for the treatment of acquired partial nasolacrimal obstruction in adults. Br J Ophthalmol. 2002 May;86(5):533–535.
11. Rose JDG, Clayton CB. Scintigraphy and contrast radiography for epiphora. Br J Radiol. 1985;58(696):1183–1186.
12. Hurwitz JJ, Victor WH. The Role of Sophisticated Radiological Testing in the Assessment and Management of Epiphora. Ophthalmology. 1985 Mar;92(3):407–413.
13. Sia PI, Curragh D, Howell S, Selva D. Interobserver agreement on interpretation of conventional dacryocystography and dacryoscintigraphy findings: A retrospective single-centre study. Clin Exp Ophthalmol. 2019; Aug;47(6):713–717.
14. Cannon PS, Chan W, Selva D. Incidence of canalicular closure with endonasal dacryocystorhinostomy without intubation in primary nasolacrimal duct obstruction. Ophthalmology. 2013 Aug;120(8):1688–1692.
15. Conway ST. Evaluation and management of "functional" nasolacrimal blockage: Results of a survey of the american society of ophthalmic plastic and reconstructive surgery. Ophthal Plast Reconstr Surg. 1994;10(3):185–187.
16. Angrist RC, Dortzbach RK. Silicone Intubation for Partial and Total Nasolacrimal Duct Obstruction in Adults. Ophthalmic Plast Reconstr Surg. 1985 Jan;1(1):51–54.
17. Bleyen I, van den Bosch WA, Bockhoits D, Mulder P, Paridaens D. Silicone Intubation with or without Balloon Dacryocystoplasty in Acquired Partial Nasolacrimal Duct Obstruction. Am J Ophthalmol. 2007 Nov;144(5):776–780.e1.
18. Peter NM, Pearson AR. External dacryocystorhinostomy for the treatment of epiphora in patients with patent but non-functioning lacrimal systems. Br J Ophthalmol. 2010 Feb 1;94(2):233–235.

Yinon Shapira
 Department of Ophthalmology
 Royal Adelaide Hospital and South
 Australian Institute of Ophthalmology
 Adelaide
 South Australia
 Australia

E-mail: yinonshapira@gmail.com