



# RHINOLOGY

Official Journal of the European and International Societies

VOLUME 61 | SUPPLEMENT 31 | OCTOBER 2021

ERS 2021  
abstract book

29th congress of the  
European Rhinologic  
Society

Thessaloniki, Greece

*September 26-30, 2021*

2021



# RHINOLOGY

Official Journal of the European and International Rhinologic Societies

## Editor-in-Chief

Prof W.J. Fokkens

## Associate Editors

Prof C. Hopkins

Prof B.N. Landis

Dr. S. Reitsma

Prof. A.R. Sedaghat

## Managing Editor

Dr. W.T.V. Germeraad

## Editorial Assistant and Rhinology Secretary

Mrs. J. Kosman

Mrs. J. Kessler

assistant@rhinology.org

## Webmaster

Prof D. Barač

rhinologywebmaster@gmail.com

## Address

Journal Rhinology, c/o AMC, Mrs. J. Kosman / A2-234, PO Box 22 660,  
1100 DD Amsterdam, the Netherlands.

Tel: +31-20-566 4534

Fax: +31-20-566 9662

E-mail: assistant@rhinology.org

Website: www.rhinologyjournal.com

*Rhinology* (ISSN 0300-0729) is the official Journal of the European and International Rhinologic Societies and appears bimonthly in February, April, June, August, October and December. Cited in Pubmed, Current Contents, Index Medicus, Excerpta Medica and Embase.

Founded in 1963 by H.A.E. van Dishoeck, *Rhinology* is a worldwide non-profit making journal. The journal publishes original papers on basic research as well as clinical studies in the major field of *rhinology*, including physiology, diagnostics, pathology, immunology, medical therapy and surgery of both the nose and paranasal sinuses. Review articles and short communications are also published, but no Case reports. All papers are peer-reviewed. Letters-to-the-editor provide a forum for comments on published papers, and are not subject to editorial revision except for correction of English language.

In-depth studies that are too long to be included into a regular issue can be published as a supplement. Supplements are not subject to peer-review.

## © *Rhinology*, 2023.

All rights reserved. No part of this publication may be reproduced or transmitted in any form or by any means electronic or mechanical, including photocopying, recording or any information storage and retrieval system without prior permission in writing from the Publisher.

Submission of a manuscript for publication implies the transfer of the copyright from the author(s) to the publisher and entails the author's irrevocable and exclusive authorization of the publisher to collect any sums or considerations for copying or reproduction payable by third parties.

# ERS 2021

Sep 26-30, 2021  
Thessaloniki, Greece



28<sup>th</sup> Congress of European Rhinologic Society -  
39<sup>th</sup> Congress of the International Society of  
Inflammation and Allergy of the Nose (ISIAN) &  
21<sup>st</sup> Congress of the International  
Rhinologic Society (IRS)

## ABSTRACTS

[www.ers-isian2021.com](http://www.ers-isian2021.com)



### ERS-ISIAN-IRS

at the Mediterranean waterfront of  
Thessaloniki  
“The nose across the lifespan”

## **Contents**

Oral Presentations by ID	2-403
ePosters by ID	404-639
Author/Co-Author with abstract ID	640-657

## **Oral Presentations**

## Electrogustometry vs. chemogustometry - Quality or Quantity?

**Pavlos Pavlidis**<sup>1</sup>, Athanasios Saratziotis<sup>2</sup>, Gregor Schitteck<sup>3</sup>, Maria Ferfeli<sup>4</sup>, Georgios Kekes<sup>5</sup>, Haralampos Gouveris<sup>6</sup>

<sup>1</sup> ENT Clinic, Papanikolaou Hospital, Thessaloniki, Greece, <sup>2</sup> ENT Clinic, University Hospital of Larissa, Larissa, Greece, <sup>3</sup> Medical University of Graz, Division of General Anaesthesiology, Emergency- and Intensive Care Medicine, Graz, Austria, <sup>4</sup> Applied Informatics, University of Macedonia, Greece, <sup>5</sup> Medical School of Aristotle University of Thessaloniki, Thessaloniki, Greece, <sup>6</sup> ENT Clinic, University Hospital of Mainz, Mainz, Germany

*Smell and taste 2, Building M2 CR2, Sept 27, 14.45*

**Background:** The study aimed at investigating the effects of various stimulus duration patterns on electrogustometric (EGM) thresholds.

**Methodology:** In 212 non-smokers (age range 10-80 years), divided into 8 age groups, EGM-thresholds were recorded bilaterally. We evaluated the effects of stimulus duration (0.5, 1.0, 1.5, and 2.0 s) on EGM detection thresholds. We have also examined any possible correlation between EGM-thresholds and age or sex.

**Results:** EGM thresholds recorded in response to stimuli of 1 and 1.5s duration are not significantly different from each other, although lower than those recorded after 0.5-stimuli. EGM-thresholds after 2s stimuli are the highest of all thresholds tested. These findings are consistent at all 6 recording areas, and all age groups.

**Conclusions:** The relationship between lingual threshold sensitivity to low levels of electric current with stimulus duration ranging from 0.5 to 2 sec is non-monotonic. no difference between sexes in threshold detection was present. The finding that EGM-thresholds increase non-uniformly (and certainly non-linearly) with age.

**Key-words:** stimulus, electrogustometry, threshold, taste strips

### Literature

1. Stillman JA, Morton RP, Goldsmith D (2000) Automated electrogustometry: a new paradigm for the estimation of taste detection thresholds. Clin Otolaryngol Allied Sci25:120-5.
2. Loucks CA, Doty RL (2004) Effects of stimulation duration on electrogustometric thresholds. Physiology & Behavior 81: 1-4.
3. Miller SL, Mirza N, Doty R (2002) Electrogustometric thresholds: Relationship to anterior tongue locus, area of stimulation and number of fungiform papillae. Physiol Behav 75: 753-757.
4. Negoro A, Umemoto M, Fukazawa K, Terada T, Sakagami M(2004) Observation of tongue papillae by video microscopy and contact endoscopy to investigate their correlation with taste function Auris Nasus Larynx 31: 255-259.
5. Pavlidis P, Gouveris H, Kekes G, Maurer J (2014) Electrogustometry thresholds, tongue tip vascularization, and density and morphology of the fungiform papillae in diabetes. B-ENT 10:271-278.
6. Pavlidis P, Cámara RJA, Kekes G, Gouveris H (2018) Bilateral taste disorders in patients with Ramsay Hunt syndrome and Bell palsy. Ann Neurol 83:807-815.
7. Wolf A, Illini O, Uy D, Renner B, Mueller CA (2016) A new extension to the Taste Strips test. Rhinology 2016; 54: 45-50.
8. Coats AC (1974) Effects of age, sex and smoking on electrical taste threshold. Ann Otol Rhinol Laryngol 83: 365-369.
9. Reed DR (2008) Birth of a New Breed of Supertaster. Chemical Senses 33:489-491.
10. Braun T, Mack B, Kramer MFR (2011) Solitary chemosensory cells in the respiratory and vomeronasal epithelium of the human nose: a pilot study. Rhinology 49: 507-512.

201040

## Long term Outcome, and Failure associated Risk Factors for Primary Endoscopic Dacryocystorhinostomy

**Meir Warman**<sup>1,2</sup>, Itai Amos<sup>2</sup>, Doron Halperin<sup>1,2</sup>, Yosef Bavnik<sup>1,2</sup>, Asher Milstein<sup>3,2</sup>, Yohai Shoshani<sup>3,2</sup>, Hana Leiba<sup>3,2</sup>, Oded Cohen<sup>1,2</sup>

<sup>1</sup>Department of Otolaryngology, Head and Neck Surgery, Kaplan Medical Center, Rehovot, Israel, <sup>2</sup> Hebrew University- Hadassah Medical School, Jerusalem, Israel, <sup>3</sup> Department of Ophthalmology, Kaplan Medical Center, Rehovot, Israel

*Lacrimal Surgery 1, Building M1 Room Σ4, Sept 27, 11.45*

**Background:** Despite Endoscopic Dacryocystorhinostomy (eDCR) being a common procedure, data of long term outcomes and failure rate is lacking. This study objective is to assess the long-term success of eDCR and to identify associated risk factors for failure.

**Methods:** A retrospective study including all eDCR surgeries performed during 15 years period. For long term follow-up analysis, patients were included data 5 and 10 years following surgery. Primary outcome was surgical success, defined by both anatomical and functional parameters. Data was collected from the hospital electronic medical records and was completed by phone interviews with the patients. Pre, intra and post-operative variables were collected and stratified by multivariate analysis to find possible risk factors for surgical failure.

**Results:** 321, 161 and 68 patients were included for immediate, 5 and 10 years outcome analysis, respectively. Success rates were 92.5%, 86.3% and 80% respectively. After multivariate analysis, older age ( $p<0.001$ ,  $p=0.001$ ) previous smoking ( $p=0.043$ ,  $p=0.037$ ) and postoperative complains of Epiphora ( $p=0.01$ ) were all statistically significant predictors for the failure of eDCR for 5 and 10 years.

**Conclusions:** eDCR is beneficial for the majority of patients even 10 years following surgery. Surgeons should be aware of the patients at higher risk for failure.

**Key words:** endoscopic dacrocystorhonostomy



## Antrochoanal Polyp has a unique inflammatory expression compare to Allergic Polyp and Nasal Turbinate

**Meir Warman**<sup>1,3</sup>, Alma Kamar Matias<sup>3</sup>, Ady Yosepovich<sup>2,3</sup>, Ayelet Harari<sup>2,3</sup>, Doron Halperin<sup>1,3</sup>, Oded Cohen<sup>1,3</sup>

<sup>1</sup>Department of Otolaryngology, Head and Neck Surgery, Kaplan Medical Center, Rehovot, Israel; <sup>2</sup>Department of Pathology, Kaplan Medical Center, Rehovot, Israel; <sup>3</sup>Hebrew University, Hadassah Medical School, Jerusalem, Israel

*Paediatric rhinology 1, Building M2 Room CR3, Sept 28, 11.45*

**Background:** To describe the histologic features of Antrochoanal polyp (ACP), Allergic polyp (AP) and Hypertrophic turbinate (HT), and compare mast and plasma cell marker expression in each pathology.

**Methods:** A retrospective case control study between the years 2010-2019. Nasal biopsies of ACP, AP and HT were compared. Histologic and immunohistochemical staining of CD117 and CD138 receptors were compared.

**Results:** 99 patients were included, consisting of 40 (40.4%), 39 (39.4%) and 20 (20.2%) patients in the ACP, AP and HT subgroups, respectively. ACPs displayed a significantly higher level of edema and intramural cysts compared to AP and HT (40% vs. 10.3% and 0%, respectively,  $p < 0.001$ ). Squamous metaplasia was demonstrated in ACP (27.5%) and AP (25.6%), but not in HT. AP group demonstrated higher rates of CD117 expression in the epithelium compared to ACP and HT (mean cell count: 10.3 vs. 5.63 and 6.15, respectively,  $p = 0.004$ ), while HT group displayed a significantly higher expression of CD117 and CD138 in the lamina propria compared to ACP and AP (cell count mean: 105.7 vs. 79.5 and 98.9 respectively,  $p = 0.045$ ).

**Conclusions:** Both HT and AP share similar histological features, suggestive of a T helper (Th-2)-mediated response. Conversely, ACP displayed a different inflammatory expression, suggesting a different pathogenesis.

**Key words:** Allergic polyps, Antrochoanal polyp, Inferior Turbinate hypertrophy

### Literature

1. R.K Chandra, M.O Patadia, j. Raviv, (2009). Diagnosis of nasal airway obstruction. Otolaryngologic Clinics of North America, 42(2), 207–225. DOI: 10.1016/j.otc.2009.01.004
2. Esmaili A., Acharya A., (2017). Clinical assessment, diagnosis and management of nasal obstruction. Australian family physician. 46(7), 499-503. PMID: 28697294.
3. Hulse K.E, Stevens W.W, Tan B.K, Schleimer R.P.,(2015). Pathogenesis of nasal polyps. Clinical and experimental allergy, 45(2) 328-246. DOI: 10.1111/cea.12472.
4. Crombruggen K.V., Zhang N., Gevaert P., et al. (2011). Pathogenesis of chronic rhinosinusitis: Inflammation. The journal of allergy and clinical Immunology, 128(4), 728-732. DOI: 10.1016/j.jaci.2011.07.049.
5. Stevenes W.W., Schleimer R.P., Kern R.C., (2016). Chronic rhinosinusitis with nasal polyps. The journal of allergy and clinical Immunology, 4(4), 573-4. DOI: 10.1016/j.jaip.2016.04.012
6. Y.Min, J.W. Chung, J.S Shin, (1995). Histologic Structure of Antrochoanal polyps . Acta Otolaryngol, 115, 543-547. DOI: 10.3109/00016489509139364
7. M. Maldonado, A. Martinez, I. Alobid, et al. (2004). The ACP. Rhinology, 43, 178-182. PMID: 15626248.



8. Flint P.W., Haughey B.H., Lund V., et al. (2014). Cummings otolaryngology, 6th edition. Canada, Elsevier.
9. Berger G., Gass S., Ophir D., (2006). The histopathology of the hypertrophic inferior turbinate. *Otolaryngology, head and neck surgery*, 132: 588-594. DOI: 10.1001/archotol.132.6.588
10. Larsen P.L., Tos M., Moncesen C., (1986). Nasal glands and goblet cells in chronic hypertrophic rhinitis. *American journal of otolaryngology*, 7(1):28-33. DOI: [https://doi.org/10.1016/S0196-0709\(86\)80031-X](https://doi.org/10.1016/S0196-0709(86)80031-X)
11. Chun Y.L., Cheng P.H., Sheen Y.F., (2004). Mucosal changes in rhinitis medicamentosa. *The annals of Otolaryngology, Rhinology and Laryngology*. 113(2), 147- 151. DOI: 10.1177/000348940411300213
12. Wormald, P. J. (2005). Endoscopic sinus surgery - Anatomy, three-dimensional reconstruction, and surgical technique. 333 Seventh Ave, New York, NY 10001: Thieme Medical Publishers.
13. Zele V.T., Claeys S., Gevaert P., et al. (2006). Differentiation of chronic sinus diseases by measurement of inflammatory mediators. *Allergy*, 61:1280-1289. DOI: 10.1111/j.1398-9995.2006.01225.x
14. Romagnani S. (2000). T cell subsets. *Annals of Allergy, Asthma & Immunology*, 85(1), 9-18. DOI: 10.1016/S1081-1206(10)62426-X
15. Hershey G.K.K., Friderich M.F., Esswein L.A., et al. (1997) The Association of Atopy with a Gain-of-Function Mutation in the  $\alpha$  Subunit of the Interleukin-4 Receptor. *New England journal of medicine*; 337:1720-1725. DOI: 10.1056/NEJM199712113372403
16. Boucherat O., Boczkowski J., Jeannotte L., et al. (2013). Cellular and molecular mechanisms of goblet cell metaplasia in the respiratory airways. *Experimental lung research*, 39, 207–216. DOI: 10.3109/01902148.2013.791733
17. Incorvaia. C., Fuiano N., Martignago I., et al., (2017). Local allergic rhinitis: evolution of concepts. *Clinical and translational allergy*, 7:38. DOI: 10.1186/s13601-017-0174-7
18. P. Frosini, G. Picarella, E. de campora, (2009). Antrochoanal polyp: analysis of 200 cases. *Acta otorhinolaryngologica italica*, 29, 21-26. PMID: 19609378
19. Cook P.R., Davis W.E., McDonald R., et al. (1993). Antrochoanal polyposis: a review of 33 cases. *ENT Journal*; 72: 401-10. PMID: 8344181
20. Kamath M.P, Hegde M.C., Sreedharan S., et al. (2002). Antrochoanal polyps and allergy - a comparative study. *Indian Journal of Otolaryngology and Head and Neck Surgery*, 54:7-11. PMID: 23119842
21. Heck W.E., Hallberg O.E., Williams H.L (1950). Antrochoanal polyp. *Archives of Otolaryngology–Head & Neck Surgery*. 52: 538-48. PMID: 14770693
- Latta J.S., Schall R.F. (1934). The histology of the epithelium of the paranasal sinuses under various conditions. *Annals of otology, rhinology and laryngology*, 43(4) 945-972. DOI: <https://doi.org/10.1177/000348943404300401>

201049

## Clinical evaluation of the course of chronic obstructive lung disease and chronic rhinosinusitis

**M.Salokhiddinov**<sup>1</sup>, D. Sultanov<sup>1</sup>

<sup>1</sup>*Department of ENT Disease, Tashkent Medical Academy, Uzbekistan*

*Allergic Rhinitis 1, Building M1 Room 23, Sept 28, 10.15*

**Background:** Approximately 90% of allergic asthmatics suffer from rhinitis, and around 30% of rhinitis patients suffer from chronic obstructive lung disease (COPD).

**Methodology/Principal:** The study included 80 patients (46 men, 34 women) were admitted during exacerbation of COPD at the Department of ENT Disease, Tashkent Medical Academy according to severity: stage I - 15 (18.75%), II - 35 (43.75%), III - 16 (20%), IV - 14 (17.5%). The average age was  $62.0 \pm 5.52$  years. A quantitative bacteriological study and polymerase chain reaction (PCR) were performed

**Results:** The study showed that in 31 (33%) patients, X-ray signs of various forms of sinusitis were detected by radiation diagnostic methods. Of these, group 1 - 25 (31%) patients with symptoms of rhinosinusitis; group 2 represented 34 (43%) patients in which there were no radiological, microbiological and clinical signs of rhinosinusitis. A microbiological study of the material revealed: in the sputum - H. Influenza - 32%, S. pneumoniae - 12%, M. catarrhalis - 4%, Enterobacteriaceae - 9%, H. Parainfluenzae - 6%, P. Aeruginosa - 8%

**Conclusion:** COPD in 55% of cases occurs comorbidly with bacterial rhinosinusitis. Patients of this category need comprehensive monitoring by an otorhinolaryngologist and pulmonologist

**Key words:** rhinosinusitis, polymerase chain reaction, COPD, sclerosis, H. Influenza

### **Literature:**

1. Nutku E, Toda M, Hamid QA. Rhinitis, nasal polyposis and asthma: pathological aspects Wallaërt B, Chanes P, Godard P, editors. The nose and lung diseases. European Respiratory Monograph 20016115–142.
2. Bascom R. The upper respiratory tract, mucus membrane irritation. Environ Health Perspectives. 1991;95:39–44.

201062

## Evaluating drug-induced sleep endoscopy (DISE)-oriented Multilevel OSA Surgery

**Dor Maayan<sup>1</sup>**, Isaac Shochat<sup>1</sup>, Itzhak Braverman<sup>1,2</sup>

<sup>1</sup>Hillel Yaffe Medical Center - Hadera, Israel, <sup>2</sup>Technion School of Medicine – Haifa, Israel

*Snoring and OSA 1, Building M2 Room CR2, Sept 28, 14.45*

**Background:** Obstructive sleep apnea (OSA) is a condition caused by upper airway obstruction. Surgery allows removal of one or more obstructive junctions: the tonsils, base-of-tongue, epiglottis, soft palate, or uvula. Drug-induced sleep endoscopy (DISE) is an established planning tool enabling surgeons' visualization of the surgical site. This study tests the effectiveness of DISE-guided surgery and each of its components.

**Materials & Methods:** Respiratory Disturbance Index (RDI) scores were recorded and in before- and after-surgery polysomnography tests. These were compared utilizing a mixed linear model ANOVA method.

**Results:** 67 operations took place: nine women (13%) and 58 men (87%). Of these patients, 24 met our inclusion criteria, 35.8% ages 35-45, and 23.9% ages 55-65. 38 (58%) required three surgery locations, and an additional 10 (14.9%) required four. Analysis of the pre- and post-operation RDI scores showed statistically significant ( $p=0.001$ ) improvement of the mean RDI score (27.6 and 17.8, respectively). Individual surgery-locations indicated a significant ( $p<0.05$ ) improvement of the RDI score before (36.1) and after surgery (16.5) in tonsillectomy patients.

**Conclusions:** Tonsillectomy was statistically significant in lowering the RDI score when compared to the other surgeries. When appropriate, surgery offers a good treatment of OSA and DISE proves a reliable planning tool.

**Key words:** *DISE, OSA, Tonsillectomy*

### Literature

Borowiecki B, Pollak CP, Weitzman ED, Rakoff S, Imperato J. Fibro-optic study of pharyngeal airway during sleep in patients with hypersomnia obstructive sleep-apnea syndrome. *Laryngoscope*. 1978;88(8 Pt 1):1310–1313

## The Function of Chromatin Remodeling Complex SWI/SNF and VDR in Chronic Rhinosinusitis

**K. Kowalik<sup>1</sup>**, M. Waniewska-Łęczycka<sup>1</sup>, E. Sarnowska<sup>2</sup>, N. Rusetska<sup>2</sup>, M. Popko-Zagor<sup>1</sup>.

<sup>1</sup>Department of Otorhinolaryngology, Faculty of Medicine and Dentistry, Medical University of Warsaw, Poland

<sup>2</sup>Department of Molecular and Translational Oncology, Maria Skłodowska-Curie-Institute Oncology Center, Warsaw, Poland

CRS – pathophysiology 1, Building M1 Room Σ3, Sept 28, 11.45

**Background :** The SWI/SNF chromatin remodeling complex enables glucocorticoid receptor and vitamin D receptor (VDR) to function correctly. The SWI/SNF may play an important role in chronic rhinosinusitis (CRS). The aim of this study was to assess: 1) the expression of the SWI/SNF in sinonasal mucosa; 2) relation of SWI/SNF and VDR expression; 3) correlation with clinical data.

**Methodology:** The study population consisted of 166 patients. The SWI/SNF expression level was analyzed using immunohistochemistry (IHC). Human nasal epithelial cells (HNECs) was stimulated by lipopolysaccharide (LPS), Staphylococcal enterotoxin B (SEB), and vitamin D3 in vitro. The transcript level of the SWI/SNF subunits was measured by qRT-PCR reaction.

**Results:** In the control group, the intensity of the IHC staining for SWI/SNF was significantly higher than in CRS patients ( $p < 0.05$ ). A positive correlation of the SWI/SNF expression was noticed with VDR expression level ( $p < 0.043$ ). The decreased transcript level of the genes encoded for SWI/SNF in HNECs after LPS stimulation and after vitD3 treatment was observed.

**Conclusions:** The SWI/SNF complex may play a role in CRS development through influence on steroid hormone and VDR signaling. Thus, in CRS patients with altered SWI/SNF function and resistance to steroids treatment, the modification in therapy may be mandatory.

**Key words:** chronic rhinosinusitis, nasal polyps, vitamin d, steroids.

### Literature:

1. Bachert, C. and G. Holtappels, *Pathophysiology of chronic rhinosinusitis, pharmaceutical therapy options*. GMS Curr Top Otorhinolaryngol Head Neck Surg, 2015. **14**: p. Doc09.
2. Fokkens, W.J., et al., *EPOS 2012: European position paper on rhinosinusitis and nasal polyps 2012. A summary for otorhinolaryngologists*. Rhinology, 2012. **50**(1): p. 1-12.
3. Ball, S.L., et al., *How reliable are sino-nasal cell lines for studying the pathophysiology of chronic rhinosinusitis?* Ann Otol Rhinol Laryngol, 2015. **124**(6): p. 437-42.
4. Lou, H., C. Wang, and L. Zhang, *Steroid transnasal nebulization in the treatment of chronic rhinosinusitis*. Curr Opin Allergy Clin Immunol, 2016. **16**(1): p. 39-44.
5. King, H.A., K.W. Trotter, and T.K. Archer, *Chromatin remodeling during glucocorticoid receptor regulated transactivation*. Biochim Biophys Acta, 2012. **1819**(7): p. 716-26.
6. Trotter, K.W., H.A. King, and T.K. Archer, *Glucocorticoid Receptor Transcriptional Activation via the BRG1-Dependent Recruitment of TOP2beta and Ku70/86*. Mol Cell Biol, 2015. **35**(16): p. 2799-817.
7. Santen, G.W., M. Kriek, and H. van Attikum, *SWI/SNF complex in disorder: SWItching from malignancies to intellectual disability*. Epigenetics, 2012. **7**(11): p. 1219-24.
8. Sarnowska, E., et al., *The Role of SWI/SNF Chromatin Remodeling Complexes in Hormone Crosstalk*. Trends Plant Sci, 2016.

9. Tomaszewska M, Sarnowska E, Rusetska N, et al. Role of Vitamin D and Its Receptors in the Pathophysiology of Chronic Rhinosinusitis. *J Am Coll Nutr.* 2019;38(2):108-118.
10. Ramirez-Carrozzi, V.R., et al., *Selective and antagonistic functions of SWI/SNF and Mi-2beta nucleosome remodeling complexes during an inflammatory response.* *Genes Dev,* 2006. **20**(3): p. 282-96.
11. Orlandi RR, Kingdom TT, Hwang PH, et al. International Consensus Statement on Allergy and Rhinology: Rhinosinusitis. *International forum of allergy & rhinology.* 2016;6 Suppl 1:S22-209.
12. Jung, I., et al., *SRG3/mBAF155 stabilizes the SWI/SNF-like BAF complex by blocking CHFR mediated ubiquitination and degradation of its major components.* *Biochem Biophys Res Commun,* 2012. **418**(3): p. 512-7.
13. DelBove, J., et al., *Identification of a core member of the SWI/SNF complex, BAF155/SMARCC1, as a human tumor suppressor gene.* *Epigenetics,* 2011. **6**(12): p. 1444-53.
14. Glaros, S., et al., *The reversible epigenetic silencing of BRM: implications for clinical targeted therapy.* *Oncogene,* 2007. **26**(49): p. 7058-66.
15. Wei Z, Yoshihara E, He N, et al. Vitamin D Switches BAF Complexes to Protect beta Cells. *Cell.* 2018;173(5):1135-1149.e1115.
17. Smith, C.L., et al., *Structural analysis of the yeast SWI/SNF chromatin remodeling complex.* *Nat Struct Biol,* 2003. **10**(2): p. 141-5.

**Rusetsky Y.**<sup>1</sup>, Sergeeva N.<sup>2</sup>, Meytel I.<sup>1</sup>, Spiranskaya O.<sup>1</sup>, Malyavina U.<sup>1</sup>

<sup>1</sup>National Medical Research Center for Children's Health Federal state autonomous institution of the Russian Federation Ministry of Health, ENT surgery department, Moscow, Russian Federation, <sup>2</sup>I.M. Sechenov First Moscow State Medical University, ENT department, Moscow, Russian Federation

*Rhinoplasty 2, Building M2 CR2, Sept 27, 11.45*

**BACKGROUND:** Fixation of autografts remains an extremely important issue in rhinoplasty. The traditional technique suturing of graft increase the time of intervention and is difficult. Tissue adhesives are a promising alternative suturing method.

**OBJECTIVE:** In our study we estimated the efficiency and safety of the cyanoacrylic-based biological adhesive in open rhinoplasty.

**DESIGN:** Prospective study.

**MATERIALS AND METHODS:** The study included 42 patients underwent open septoplasty aged between 18 and 45 years. All cases used septal cartilage for dorsal strut grafting and tip grafting.

We used medical glue based ethyl ether 2-cyanoacrylic acid ("Sulfacrylate", Russia). Adhesive contain anti-inflammatory, antimicrobial components to prevent of inflammatory reaction and reduces wound healing time. We have used Sulfacrylate to glue pieces of septal cartilage to secure cartilage grafts in appropriate positions.

We estimated postoperative complications and surgical outcome 12 months postoperatively.

**RESULTS:** There were no intraoperative or postoperative complications. Cartilage grafts appeared to maintain their volume and position. All patients achieving successful aesthetic outcomes and functional result.

**CONCLUSION:**

Rhinoplasty with the use of cyanoacrylic-based biological adhesive with bactericidal and hemostatic properties is noteworthy, promising, efficient and safe for clinical use. Sulfacrylate is an excellent adjunct to rhinoplasty procedures because it successfully eliminates the displacement autografts. Further studies are required for the clarification of long-term results.

**Key words:** rhinoplasty, glue rhinoplasty, rhinosurgery, glue rhinosurgery.

**I. Bujoreanu<sup>1</sup>**, D. Spinos<sup>1</sup>, C. Rennie<sup>1</sup>, H. Saleh<sup>1</sup>

<sup>1</sup>ENT Department, Charing Cross Hospital, London, UK

*Orbital surgery 1, Building M2 CR3, Sept 29, 11.45*

**Background:** Graves ophtalmopathy (GO) is caused by lymphocytic inflammation in autoimmune thyrotoxicosis. As periorbital fat has limited lymphatic drainage and the bony orbit is rigid, the eye and the optic nerve become compressed.

**Methodology/Principal:** Patients requiring emergency orbital decompression between 1<sup>st</sup> January and 31<sup>st</sup> December 2018 were included.

**Results:** Six patients were included (3 males). Ages ranged from 35-65. Most patients were smokers (n=4) and had prior diagnosis of hyperthyroidism (n=4). Disease was commonly bilateral (n=4) and the most common signs were extraocular muscle restriction, proptosis and pain on movement. Compressive optic neuropathy (CON) was present in 4 of 6 patients. CAS scores ranged between 4-6. All patients received IV corticosteroids pre-operatively and 50% received mycophenolate treatment. Only one patient had pre-operative orbital radiotherapy (ORT). Time until surgery varied from 1-75 days (mean 21.5). All patients underwent a 3-wall orbital decompression. Post-operatively 4 of 6 patients had improved visual acuities.

**Conclusions:** GO is present in 20% of patients with Graves' disease. Mild disease is managed with topical eye treatments, but corticosteroids and ORT can be used in persistent or severe cases. CON presents with altered colour vision and reduced visual acuity. Surgical orbital decompression should only be performed as last measure in sight-threatening disease.

**Key words:** Graves Ophlatmopathy, Graves Disease, Thyrotoxicosis, Surgical decompression, Optic nerve emergencies

#### Literature

1. Verity DH, Rose GE. Acute thyroid eye disease (TED): principles of medical and surgical management. *Eye (Lond)*. 2013 Mar;27(3):308–19.
2. Sikder S, Weinberg RS. Thyroid eye disease: pathogenesis and treatment. *Ophthalmologica*. 2010;224(4):199–203.
3. Gold KG, Scofield S, Isaacson SR, Stewart MW, Kazim M. Orbital Radiotherapy Combined With Corticosteroid Treatment for Thyroid Eye Disease-Compressive Optic Neuropathy. *Ophthal Plast Reconstr Surg*. 2018;34(2):172–7.
4. Wong LL, Lee NG, Amarnani D, Choi CJ, Bielenberg DR, Freitag SK, et al. Orbital Angiogenesis and Lymphangiogenesis in Thyroid Eye Disease. *Ophthalmology*. 2016 Sep;123(9):2028–36.
5. Phillips ME, Marzban MM, Kathuria SS. Treatment of Thyroid Eye Disease. *Curr Treat Options Neurol*. 2010 Jan 13;12(1):64–9.
6. Lee HBH, Rodgers IR, Woog JJ. Evaluation and Management of Graves' Orbitopathy. *Otolaryngol Clin North Am*. 2006 Oct;39(5):923–42.
7. WR. N. Ophthalmic Graves' disease: a dual theory of pathogenesis. *Ophthalmol Clin North Am*. 1991;4:73–87.
8. Ben Simon GJ, Katz G, Zloto O, Leiba H, Hadas B, Huna-Baron R. Age differences in clinical manifestation and prognosis of thyroid eye disease. *Graefe's Arch Clin Exp Ophthalmol*. 2015 Dec 7;253(12):2301–8.
9. Perros P, Dayan CM, Dickinson AJ, Ezra D, Estcourt S, Foley P, et al. Management of patients with Graves' orbitopathy: initial assessment, management outside specialised



centres and referral pathways. Clin Med (Northfield Il). 2015 Apr 1;15(2):173–8. 201069

## Endoscopic surgical plastic closure of nasal septum perforation.

**Rusetsky Y.<sup>1</sup>, Mokoyan Zh.<sup>2</sup>, Meytel I.<sup>1</sup>, Spiranskaya O.<sup>1</sup>, Malyavina U.<sup>1</sup>**

<sup>1</sup>National Medical Research Center for Children's Health Federal state autonomous institution of the Russian Federation Ministry of Health, ENT surgery department, Moscow, Russian Federation, <sup>2</sup>I.M. Sechenov First Moscow State Medical University, ENT department, Moscow, Russian Federation

*Septal and turbinate surgery 1, Building M2 CR3, Sept 28, 14.45*

**BACKGROUND:** Being increasingly faced with the problem of pediatric nasal septal perforations, we have found that the surgical management of nasal septal perforations in children is not widely described in the literature. The objective of our study was to demonstrate the results of different surgical techniques, including two original endoscopic techniques, in the septal perforation repair in children.

**MATERIALS AND METHODS:** 24 children, ranging between 6 and 17 years of age, with nasal septal perforations were operated using different endoscopic techniques from February 2015 to May 2019 at the special tertiary referral clinic. Apart from well-known techniques, such as anterior ethmoidal artery flap, intranasal bipediced advancement flap, sublabial flap, free temporal fascia graft, we used two original techniques – inverted edges technique and cross-septal returned flap.

**RESULTS:** The total rate of complete perforation closure was 79% (19 of 24 patients). Regarding the reduction of symptoms, the efficacy of surgery was approaching 100%. The combination of inverted edges technique and anterior ethmoidal artery septal flap demonstrated the best results with no reperforations in all 10 cases. Using cross-septal returned flap, we achieved complete closure of perforation in 5 (83%) of 6 patients. The remaining techniques were performed rare and showed relatively low rates of success. There were 2 cases of complications (oronasal fistula), both developed in patients with sublabial mucosal flap complications.

### **CONCLUSION:**

Use of endoscopic assistance, vascularized mucoperichondrial flaps and bilateral closure demonstrates high effectiveness in septal perforation surgical repair in children.

**Key words:** Nasal septal perforation, Pediatric otorhinolaryngology, Endoscopic rhinosurgery, Repair of septal perforation, Septal perforation in children.

201748

## Granulomatosis with polyangiitis - a rhinologist's perspective.

**Ljiljana Jovancevic**

*University of Novi Sad, Faculty of Medicine, Novi Sad, Serbia*

*Clinical Centre of Vojvodina, ORL and HNS Clinic, Novi Sad, Serbia*

*CRS - diagnosis and investigations 1, Building M1 Room 23, Sept 27, 10.15*

Granulomatosis with polyangiitis (GPA) is an idiopathic chronic inflammatory disease characterised by necrotizing granulomatous lesions and systemic vasculitis, associated with antineutrophil cytoplasmic antibodies (C-ANCA). The pathophysiology is most likely autoimmune. GPA has peak incidence is in the fourth to fifth decades. Both sexes are affected equally, majority of patients are Caucasian.

Two thirds of patients initially present with an ENT related symptoms, of which the majority are rhinological (~40%). The patients usually have these nasal symptoms: crusting (75%), discharge (70%), nasal stuffiness (65%), bleeding (59%), reduced sense of smell (52%) and facial pain (33%). A characteristic supratip collapse occurs in 18-25%. On endoscopic examination the nasal mucosa is usually very friable, granular and covered with old blood and crust.

We present 3 cases of patients with GPA, all with typical GPA rhinologic manifestations, all female, average age at presentation 39 years. Two of them were diagnosed for GPA prior to rhinology consult, and one diagnosed by rhinologist.

ENT physicians, especially rhinologists, have a determining role in recognising the early onset of the disease since the delay in the necessary diagnosis and treatment can lead to a long-term disability or mortality due to the common rapid progression of the disease.

**Rusetsky Y.**<sup>1</sup>, Sergeeva N.<sup>2</sup>, Meytel I.<sup>1</sup>, Arutunyan S.<sup>1</sup>, Spiranskaya O.<sup>1</sup>, Malyavina U.<sup>1</sup>

<sup>1</sup>National Medical Research Center for Children's Health Federal state autonomous institution of the Russian Federation Ministry of Health, ENT surgery department, Moscow, Russian Federation, <sup>2</sup>I.M. Sechenov First Moscow State Medical University, ENT department, Moscow, Russian Federation

*Rhinoplasty 2, Building M2 CR2, Sept 27, 11.45*

**BACKGROUND:** Dorsum-preservation rhinoplasty is becoming more and more popular. This approach based on so cold 'let-down technique'.

This approach can lead to some complications and consequences, including a residual hump and a step on the dorsum.

Therefore, surgeons are trying to find the best option for the described technique.

**OBJECTIVE:** In our study we developed and estimated the efficiency and safety ринопластики с сохранением хрящевой спинки носа.

**DESIGN:** Prospective study.

**MATERIALS AND METHODS:** The study included 19 patients underwent ринопластике aged between 20 and 31 years. In all cases we used soft let-down rhinoplasty technique. During this surgery bony "cap" of hump was removed by piezotom, than we resected cartilaginous and bony strip from upper part of septum. Thus, cartilaginous hump was pushed down.

We estimated postoperative complications and surgical outcome 12 months postoperatively.

**RESULTS:** There were no intraoperative or postoperative complications. All patients achieving successful aesthetic outcomes and functional result.

**CONCLUSION:**

Rhinoplasty with removing bony part of hump by piezotom and cartilaginous let-down is promising, efficient and safe for clinical use. Further studies are required for the clarification of long-term results.

displacement autografts. Further studies are required for the clarification of long-term results.

**Key words:** rhinoplasty, Soft let-down rhinoplasty, rhinosurgery, piezosurgery.

## Altered Viscosity of Nasal Secretions in Postnasal Drip

**Sarina Bucher**<sup>1</sup>, Peter Schmid-Grendelmeier<sup>2</sup>, Michael B. Soyka<sup>1</sup>

<sup>1</sup>Department of Otorhinolaryngology Head and Neck Surgery, University of Zurich and University Hospital Zurich, Zurich, Switzerland, <sup>2</sup>Allergy Unit, Department of Dermatology, University of Zurich and University Hospital Zurich, Zurich, Switzerland

*Rhinology – miscellaneous 4, Building M1 Room Σ1, Sept 27, 14.45*

**Background:** Postnasal Drip (PND) is a common symptom associated with upper respiratory tract disorders. It occurs without other symptoms or combined with chronic rhinosinusitis (CRS). However, the pathophysiology of PND is debated to this day and an objective definition of PND has not been established. Therefore we aimed to elucidate whether the viscosity and volume of nasal secretions as well as the mucociliary clearance and sensitivity of the nasopharynx, or atopy could play a role in the pathophysiology of PND.

**Methods:** A prospective case-control study of 30 patients – 15 PND and 15 healthy subjects – was conducted. The viscosity and volume of nasal secretions, the nasopharyngeal sensitivity, the mucociliary clearance, and allergic sensitisation using a skin prick test (SPT) were assessed in all subjects.

**Results:** Viscosity of nasal secretions in PND patients was significantly increased compared to healthy subjects. Two follow-up measurements in symptom-free intervals showed reversibility of increased viscosity. Analysis of nasopharyngeal sensitivity showed significant reductions in PND patients. Furthermore, mucociliary clearance seems to be prolonged in PND patients. The volume of nasal secretions and the atopy screening showed no significant differences in PND compared to healthy individuals.

**Conclusion:** Increased viscosity seems to play a relevant role in the pathophysiology of PND. Additionally, delayed mucociliary clearance as well as hyposensitivity of the nasopharynx may be further components. Earlier concepts of PND, regarding an increased volume of secretions and atopy, do not seem to hold true since our analyses showed no significant difference between cases and controls.

**Key words:** postnasal drip, secretion, viscosity, mucociliary clearance, sensitivity

## Literature

1. Dobell H. On winter cough, catarrh, bronchitis. (Appendix. Post Nasal Catarrh). 1st ed. London, Kessinger Publishing; 1866:172-174
2. Rimmer J, Hellgren J, Harvey RJ. Simulated postnasal mucus fails to reproduce the symptoms of postnasal drip in rhinitics but only in healthy subjects. *Rhinology*. 2015; 53(2):129–134.
3. Litt M. Basic concepts of mucus rheology. *Bull Physiopathol Respir (Nancy)*. 1973; 9(1):33–46.
4. King M. Viscoelastic properties of airway mucus. *Fed Proc*. 1980; 39(13):3080–3085.
5. Majima Y, Harada T, Shimizu T et al. Effect of biochemical components on rheologic properties of nasal mucus in chronic sinusitis. *Am J Respir Crit Care Med*. 1999; 160(2):421–426.
6. Passàli D, Bellussi L, Lauriello M, Passali D. The rheological characteristics of nasal mucus in patients with rhinitis. *Eur Arch Otorhinolaryngol*. 1995; 252(6):348–352.
7. Saito DM, Innes AL, Pletcher SD. Rheologic properties of sinonasal mucus in patients

- with chronic sinusitis. *Am J Rhinol Allergy*. 2010; 24(1):1–5.
8. Adler K, Dulfano MJ. The rheological factor in mucociliary clearance. *J Lab Clin Med*. 1976;88(1):22–28.
  9. De Oliveira-Maul JP, De Carvalho HB, Goto DM et al. Aging, diabetes, and hypertension are associated with decreased nasal mucociliary clearance. *Chest*. 2013; 143(4):1091–1097.
  10. Goto DM, Torres GM, Seguro AC, Saldiva PHN, Lorenzi-Filho G, Nakagawa NK. Furosemide impairs nasal mucociliary clearance in humans. *Respir Physiol Neurobiol*. 2010; 170(3):246–252.
  11. Golhar S. Nasal mucus clearance. *J Laryngol Otol*. 1986; 100(5):533–538.
  12. Kesimci E, Bercin S, Kutluhan A, Ural A, Yamanturk B, Kanbak O. Volatile anesthetics and mucociliary clearance. *Minerva Anesthesiol*. 2008; 74(4):107–111.
  13. Darsow U, Vieluf D, Ring J. Atopy patch test with different vehicles and allergen concentrations: An approach to standardization. *J Allergy Clin Immunol*. 1995; 95(3):677–684.
  14. Brofeldt S, Mygind N. Viscosity and spinability of nasal secretions induced by different provocation tests. *Am Rev Respir Dis*. 1987; 136(2):353–356.
  15. Lai SK, Wang YY, Wirtz D, Hanes J. Micro- and macrorheology of mucus. *Adv Drug Deliv Rev*. 2009;61(2):86–100.
  16. Ma JT, Tang C, Kang L, Voynow JA, Rubin BK. Cystic fibrosis sputum rheology correlates with both acute and longitudinal changes in lung function. *Chest*. 2018;154(2):370–377.
  17. Rubin BK, Druce H, Ramirez OE, Palmer R. Effect of clarithromycin on nasal mucus properties in healthy subjects and in patients with purulent rhinitis. *Am J Respir Crit Care Med*. 1997;155(6):2018–2023.
  18. Lourenço RV, Klimek MF, Borowski CJ. Deposition and clearance of 2 micron particles in the tracheobronchial tree of normal subjects--smokers and nonsmokers. *J Clin Invest*. 1971; 50(7):1411–1420.
  19. Nakagawa NK, Franchini ML, Driusso P, de Oliveira LR, Saldiva PHN, Lorenzi-Filho G. Mucociliary clearance is impaired in acutely ill patients. *Chest*. 2005; 128(4):2772–2777.
  20. Lim KG, Rank MA, Kita H, Patel A, Moore E. Neuropeptide levels in nasal secretions from patients with and without chronic cough. *Ann Allergy Asthma Immunol*. 2011; 107(4):360–363.
  21. Cathcart RA, Wilson JA. Catarrh - The patient experience. *Rhinology*. 2011; 49(4):387–391
  22. Keh SM, Facer P, Yehia A, Sandhu G, Saleh HA, Anand P. The menthol and cold sensation receptor TRPM8 in normal human nasal mucosa and rhinitis. *Rhinology*. 2011; 49(4):453–457
  23. Van Gerven L, Boeckxstaens G, Hellings PW. Up-date on neuro-immune mechanisms involved in allergic and non-allergic rhinitis. *Rhinology*. 2012; 50:227–235.
  24. O'Hanlon S, Facer P, Simpson KD, Sandhu G, Saleh HA, Anand P. Neuronal markers in allergic rhinitis: Expression and correlation with sensory testing. *Laryngoscope*. 2007; 117(9):1519–1527.

**Aggeliki Tsaprantzi<sup>1</sup>**, Zoi Tatsiou<sup>2</sup>, Georgia Hainoglou<sup>1</sup>

<sup>1</sup>Otolaryngology department of General Hospital of Kavala, Kavala, Greece, <sup>2</sup>Histopathology department of General Hospital of Kavala, Kavala, Greece

*Benign nasal tumours 1, Building M1 Room Σ3, Sept 29, 10.15*

Sinonasal oncocytic papilloma is a rare benign tumor. Risk factors are the cigarette smoke, alcohol, sun radiation and mutation. There are three types of nasal papillomas: oncocytic, inverted, exophytic. Nasal papilloma resection is in evolution. New endoscopic sinus surgery techniques have been developed, with benefits in morbidity.

We present a case of a 60-years-old woman who presented to our department complaining of difficulty breathing. Nasal endoscopy had shown a polypoid lesion at the right nasal cavity wall. Endoscopic biopsy-resection revealed: oncocytic papilloma. At follow up she is free of disease, without any sign of possible local recurrence.

Oncocytic papilloma is arising from the lateral nasal cavity wall or paranasal sinuses. Preoperative computed tomography scans must be obtained to determine the extent of the tumor. Endoscopic sinus surgery, wide field resection is the therapy of choice. Functional Endoscopic Sinus Surgery, Draff I, II, III are promising procedures for effective surgical therapy. Midfacial degloving approach is another treatment strategy. Malignant change to squamous cell carcinoma, occurs in 4-17% of oncocytic papillomas.

In conclusion, oncocytic papilloma has to be resected in free margins, without macroscopic residual disease. Advanced endoscopic techniques have better results of prognosis and patient has a better quality of life.

**Key words:** papilloma, oncocytic, mutation, endoscopic sinus surgery, prognosis.

## Literature

1. Koyama M, Terauchi T, Koizumi M, Tanaka H, Takeuchi K. Sinonasal oncocytic Schneiderian papilloma accompanied by intravascular lymphoma: A case report on FDG-PET/CT imaging. *Medicine (Baltimore)* 95(34):e4646, 2016.
2. Vorasubin N, Vira D, Suh J.D, Bhuta S, Wang M.B. Schneiderian papillomas: Comparative review of exophytic, oncocytic, and inverted types. ***Am J Rhinol Allergy* 27(4): 287–292, 2013.**
3. Batsakis JG, Suarez P. Schneiderian papillomas and carcinomas: A review. *Adv Anat Pathol* 8:53–64, 2001.
4. Cheng T-Y, Ueng S-H, Chen Y-L, et al. Oncocytic Schneiderian papilloma found in a recurrent chronic paranasal sinusitis. *Chang Gung Med J* 29:336–341, 2006.
5. Bawa R, Allen GC, Ramadan HH. Cylindrical cell papilloma of the nasal septum. *Ear Nose Throat J* 74:179–181, 1995.
6. Barnes L, Bedetti C. Oncocytic Schneiderian papilloma: A reappraisal of cylindrical cell papilloma of the sinonasal tract. *Hum Pathol* 15:344–351, 1984
7. Kaufman MR, Brandwein MS, Lawson W. Sinonasal papillomas: Clinicopathologic review of 40 patients with inverted and oncocytic Schneiderian papillomas. *Laryngoscope* 112:1372–1377, 2002.
8. Kapadia SB, Barnes L, Pelzman K, et al. Carcinoma ex oncocytic Schneiderian (cylindrical

cell) papilloma. *Am J Otolaryngol* 14:332–338, 1993.

9. Lund VJ, Stammberger H, Nicolai P, et al. European position paper on endoscopic management of tumours of the nose, paranasal sinuses and skull base. *Rhinol Suppl* 22:1–143, 2010.

10. Wormald PJ, Ooi E, van Hasselt CA, Nair S. Endoscopic removal of sinonasal inverted papilloma including endoscopic medial maxillectomy. *Laryngoscope* 113:867–873, 2003.



201098

## Kinetic oscillation stimulation in non-allergic rhinitis: a per protocol analysis of a randomized controlled trial

**Klementina S. Avdeeva**<sup>1</sup>, Sietze Reitsma, Wytske J. Fokkens<sup>1</sup>

<sup>1</sup>*Department of Otorhinolaryngology, Amsterdam UMC, location Academic Medical Centre, Amsterdam, The Netherlands*

*Non-allergic rhinitis 1, Building M2 CR2, Sept 28, 11.45*

**Background:** Non-allergic rhinitis (NAR) has a high prevalence and lacks sufficient treatment options. Kinetic oscillation stimulation (KOS) of the nasal cavity might improve symptoms in NAR.

**Methods:** We performed a per-protocol analysis of data from a previously published paper on KOS treatment in NAR. The per-protocol analysis set included 124 patients (64 received KOS, 60 – placebo). The primary outcome was the change in total vasomotor rhinitis symptoms and medication score (TVRSMS) after 4 weeks from the treatment. A subgroup analysis was performed based on local vasoconstrictor abuse (LVA).

**Results:** KOS resulted in a significant reduction of TVRSMS after 4 weeks compared to placebo (change from baseline -0.8;  $p < 0.05$ ). Stopping local vasoconstrictor abuse showed a significant reduction in TVRSMS (change from baseline: -1.1) which was additive to the KOS effect (change from baseline in those stopping LVA + KOS: -1.6). A mixed model analysis showed that KOS treatment significantly reduced TVRSMS ( $p = 0.02$ ,  $SE = 0.200$ , 95% CI -0.85, -0.0606), though the effect of LVA did not reach significance.

**Conclusion:** A single KOS treatment appears to reduce TVRSMS compared to placebo after 4 weeks. Stopping local vasoconstrictor abuse has a comparable effect. A well-designed RCT is needed to elucidate the validity of these findings.

**Key words:** kinetic oscillation stimulation, non-allergic rhinitis, vasomotor rhinitis, idiopathic rhinitis, rhinitis medicamentosa

Literature: Ehnhage A, Johnsson PS, Ahlstrom-Emanuelsson C, Andersson M, Knutsson J, Lien J, et al. Treatment of idiopathic rhinitis with kinetic oscillations - a multi-centre randomized controlled study. *Acta Otolaryngol.* 2016;136(8):852-9.

201103

## Patient- recorded benefit from nasal closure in a Danish cohort of patients with Hereditary Haemorrhagic Telangiectasia

**Andersen JH<sup>1</sup>**, Kjeldsen AD<sup>1,2,3</sup>

<sup>1</sup>Department of ORL-Head & Neck Surgery, Odense University Hospital, Denmark; <sup>2</sup>Department of Clinical Research, University of Southern Denmark, <sup>3</sup> Member of HHT-WG VASCERN (European reference network for Vascular disease)

*Epistaxis and HHT 2, Building M1 Room Σ3, Sept 29, 14.45*

**Background:** Nasal closure, also known as the modified Young's procedure, was introduced in Denmark in 2008 as a surgical solution to severe epistaxis in patients with Hereditary Haemorrhagic Telangiectasia.

The objective of this study was to report the overall satisfaction of the procedure from a patient-point-of view as well as the occurrence of complications.

**Methods:**All HHT-patients who underwent nasal closure from 2008-2018 were included in the study. Patients were evaluated for postoperative complications and subjective outcome using Glasgow Benefit Inventory (GBI).

**Results:** Ten patients were included in the study and were observed for a mean of 64 months. None of the patients were completely free of complications, and reversal was requested in a single case. Haemoglobin levels rose with an average of 2.8 g/dl. The average GBI score after surgery was 38,05. Nine of Ten patients would recommend nasal closure to fellow HHT-patients.

**Conclusion:**Nasal closure is highly recommended among patients, but due to the rate of postoperative complications the procedure should be reserved a carefully selected group of HHT-patients.

**Key words:** HHT, Epistaxis, Young's Procedure, Glasgow Benefit Inventory (GBI)

## A radiological study of the keystone area: implications for dorsal hump reduction surgical planning

**David Santos Rodrigues Dias<sup>1</sup>**, Luís Cardoso<sup>2</sup>, Mariline Santos<sup>1</sup>, Cecília Almeida e Sousa<sup>3</sup>, Miguel Gonçalves Ferreira<sup>4</sup>

*Rhinoplasty 1, Building M2 CR1, Sept 29, 14.45*

<sup>1</sup>Centro Hospitalar Universitário do Porto, Instituto de Ciências Biomédicas Abel Salazar – Universidade do Porto – Otolaryngology-Head and Neck Surgery Department. Resident; <sup>2</sup>Centro Hospitalar Universitário do Porto, Instituto de Ciências Biomédicas Abel Salazar – Universidade do Porto - Neuroradiology Department. Resident; <sup>3</sup>Centro Hospitalar Universitário do Porto, Instituto de Ciências Biomédicas Abel Salazar – Universidade do Porto – Otolaryngology-Head and Neck Surgery Department. Director of Department; <sup>4</sup>Centro Hospitalar Universitário do Porto, Instituto de Ciências Biomédicas Abel Salazar – Universidade do Porto, Hospital da Luz – Arrábida. Senior Surgeon.

**Background:** To study the relation between cartilaginous and bony components of the keystone area in seeking and non seeking for rhinoplasty patients.

**Methodology:** Measurements from mid-sagittal slices in nasal computed tomography scans taken in adult Caucasian patients between January 2015 and December 2018 were compared between patients seeking primary rhinoplasty due to a nasal hump and patients not seeking rhinoplasty (control group). Patients with previous nasal surgery or trauma, genetic or congenital facial disorders and high septal deviation were excluded. The length of overlap between nasal bones and septal cartilage was compared between the two groups.

**Results:** The study population included 138 (69 seeking and 69 not seeking rhinoplasty) patients (96 females). The mean age was 32.9 years (range 18 – 55 years). Mean length (mm) of overlap between nasal bone and septal cartilage was similar between both groups ( $11.7 \pm 3.3$  vs  $10.8 \pm 3.3$ ;  $p=0.235$ ). Superficial nasal hump measured  $16.7 (\pm 2.71)$  mm in length, under which a segment of nasal bone of  $8.4 (\pm 2.4)$  mm in length could be found. In only 2 (3%) of patients ethmoid bone existed under the latter.

**Conclusions** Dorsal reduction should focus on detaching the ULCs from the overlying nasal bone and address the cartilaginous vault within the bony vault.

**Key words:** Rhinoplasty; Hump Reduction; Nose Anatomy; Preservation Rhinoplasty: Spare Roof Technique

### Literature

1. Palhazi P, Kosins M. The Osseocartilaginous Vault of the Nose: Anatomy and Surgical Observations. *Aesthetic Surgery Journal*. 2015;35(3): 242–251.
2. Santos M, Coutinho M, Sousa CA, Ferreira MG. Caucasian Mediterranean patients seeking rhinoplasty-Anthropometric measurements and prevalence of major deformities. *Clinical Otolaryngology*. 2019;44(4):581-587.
3. Sadick HR, Gassner H. Nuances in component nasal hump reduction. *Journal of Plastic, Reconstructive & Aesthetic Surgery*. 2018;71:178–184.
4. Park S, Choi J, Park H, Lim Y et al. The Nasal Keystone Region: An Anatomical Study. *JAMA FACIAL PLAST SURGERY*. 2013;15(3):235-237.
5. Oneal RM, Beil RJ. Surgical Anatomy of the Nose. *Clinics in Plastic Surgery*. 2017;37(2):191-211.
6. Kim IS, Lee MY, Lee KI, et al. Analysis of the Development of the Nasal Septum according to Age and Gender Using MRI. *Clinical and Experimental*

- Otorhinolaryngology 2008;1(1):29-34.
7. Simon P, Lam K, Sidle D, Tan B. The Nasal Keystone Region: An Anatomical Study. JAMA FACIAL PLASTIC SURGERY. 2013;15(3):235-237.
8. Kim J, Jung D, Kim H,, Kim C, Kim T. Analysis of the Development of the Nasal Septum and Measurement of the Harvestable Septal Cartilage in Koreans Using Three-Dimensional Facial Bone Computed Tomography Scanning. Archives of Facial Plastic Surgery. 2014;41(163-170).
9. Verwoerd HL, Koppel PGJ, Van Osch GJVM. Rhinosurgery in children: developmental and surgical aspects of the growing nose. GMS Current Topics in Otorhinolaryngology - Head and Neck Surgery. 2010;9.
10. Hwang S, Lim O, Hwang M, Kim M, Lee J. The Clinical Analysis of the Nasal Septal Cartilage by Measurement Using Computed Tomography. Archives of Craniofacial Surgery. 2016;17(3):140-145.
11. Kim In, Chung Y, Lee Y. An Anatomic Study on the Overlap Patterns of Structural Components in the Keystone Area in Noses of Koreans. Clinical and Experimental Otorhinolaryngology 2008;1(3):158-160.
12. Saxena R, Friedman S, Bly R, et al. Comparison of Micro-Computed Tomography and Clinical Computed Tomography Protocols for Visualization of Nasal Cartilage Before Surgical Planning for Rhinoplasty. JAMA Facial Plastic Surgery. 2019.
13. Ferreir MG, Monteiro D, Reis C, Sousa CAA. Spare Roof Technique: A Middle Third New Technique. Facial Plastic Surgery. 2016;32(01):111-116.
14. Santos M, Rego AR, Coutinho M, Sousa CA, Ferreira MG.. Spare roof technique in reduction rhinoplasty: Prospective study of the first one hundred patients. Laryngoscope. 2019;00:1-5.
15. Robotti E, Chauke-Malinga NY, Leone F. A Modified Dorsal Split Preservation Technique for Nasal Humps with Minor Bony Component: A Preliminary Report. Aesthetic Plastic Surgery. 2019;43(5):1257–1268.
16. Lazovic GD, Daniel RK, Janosevic LB et al.. Rhinoplasty: the nasal bones - anatomy and analysis. Aesthet Surg J. 2015;35(3):255-263.

**Mariola Popko**<sup>1</sup>, Egbert H. Huizing<sup>2</sup>, Dirk J. Menger<sup>3</sup>, Suzanne A.M.W. Verlinde-Schellekens<sup>4</sup>, Claire Mackaaij<sup>4</sup>, Ronald L.A.W. Bleys<sup>4</sup>

<sup>1</sup> Department of Otorhinolaryngology, Faculty of Medicine and Dentistry, Medical University of Warsaw, Warsaw, Poland, <sup>2</sup> c/o Department of Anatomy, University Medical Centre Utrecht, Utrecht, The Netherlands, <sup>3</sup> Department of Otorhinolaryngology, University Medical Centre Utrecht, Utrecht, The Netherlands, <sup>4</sup> Department of Anatomy, University Medical Centre Utrecht, Utrecht, The Netherlands

*Rhinoplasty 1, Building M2 CR1, Sept 29, 14.45*

**Background:** Knowledge of tip supporting structures is crucial for successful rhinoplasty surgery. Emphasis is often put on ligamentous structures that are claimed to support the nasal tip. Up to now descriptions of these ligaments have been mainly based on dissection studies while histological evidence has been lacking. Therefore the aim of the present study was to provide precise and comprehensive anatomical and histological descriptions of the tip supporting structures.

**Methodology:** Serial coronal sections of the entire external noses from seven cadavers were studied after staining by Mallory-Cason and Verhoeff-Van Gieson procedures.

**Results:** No histological evidence of ligaments between the cartilaginous and bony parts of the nasal skeleton, and between the skin and the nasal skeleton was found. A continuous perichondrial-periosteal lining surrounding the bony skeleton, triangular, and lobular cartilages was identified within the soft tissue envelope.

**Conclusions:** The main tip supporting and shaping structures are: septal and lobular cartilages, premaxillae and soft tissue envelope with periosteal-perichondrial envelope/membrane.

These findings may have clinical relevance in functional and esthetic rhinoplasties.

**Key words:** tip, perichondrium, periosteum, rhinoplasty, septum

## A unilateral mucoperichondrial/mucoperiosteal flap including inferior turbinate with contralateral underlay xenograft for a large nasal septal perforation repair

**Alfonso Luca Pendolino**<sup>1,2</sup>, Mustafa Jaafar<sup>1</sup>, Samit Unadkat<sup>1</sup>, Henry Zhang<sup>1</sup>, Premjit Randhawa<sup>1</sup>, Peter J. Andrews<sup>1,2</sup>.

<sup>1</sup>Department of ENT, Royal National Ent & Eastman Dental Hospitals, London, United Kingdom, <sup>2</sup>Ear Institute, UCL, London, UK.

*Septal and turbinate surgery 2, Building M2 Study Hall, Sept 29, 14.45*

**Background:** A large septal perforation repair is considered technically difficult when more than 1.5 cms in diameter with successful closure outcomes reported to be low. The challenge is to mobilise a larger mucoperichondrial flap which enables primary closure. We describe a novel technique which incorporates the inferior turbinate mucosa in addition to the lateral nasal wall transposition flap.

**Methodology:** A unilateral septal mucoperichondrium and periosteal flap utilizing inferior septum, nasal floor, lateral nasal wall and inferior turbinate mucosa is mobilized in addition to superior septum enabling primary closure of the perforation. The contralateral septal mucoperichondrium remains un-mobilised. which allows for the underlay of a porcine submucosa mesh with interpositional crushed cartilage.

**Results:** A case study of 11 patients successfully treated with this technique is presented. Perforation dimension ranged from 3-47 mm, with a median size of 15 mm. Complete closure of the perforation was achieved in all but one patient (91%), with a median follow-up of 4 months. All patients experienced a significant improvement in their symptoms.

**Conclusions:** The addition of inferior turbinate mucosa as part of the unilateral lateral nasal wall mucoperichondrium/periosteal flap combined with a contralateral acellular matrix underlay optimizes the repair of larger perforations.

**Key words:** Nasal Septal Perforation, Nasal Septum, Surgical Flaps, Reconstructive Surgical Procedures, Turbinates

### Literature

1. Oberg D, Akerlund A, Johansson L, Bende M. Prevalence of nasal septal perforation: the Skövde population-based study. *Rhinology* 2003;41(2):72-5.
2. Pereira C, Santamaría A, Langdon C, López-Chacón M, Hernández-Rodríguez J, Alobid I. Nasoseptal Perforation: from Etiology to Treatment. *Curr Allergy Asthma Rep* 2018 5;18(1):5.
3. Kühn D, Hospowsky C, Both M, Hey M, Laudien M. Manifestation of granulomatosis with polyangiitis in head and neck. *Clin Exp Rheumatol*. 2018;36 Suppl 111(2):78-84.
4. Felicetti M, Cazzador D, Padoan R, Pendolino AL, Faccioli C, Nardello E, Berti A, Silvestrini M, Paolazzi G, Brunori G, Zanoletti E, Emanuelli E, Martini A, Schiavon F. Ear, nose and throat involvement in granulomatosis with polyangiitis: how it presents and how it determines disease severity and long-term outcomes. *Clin Rheumatol*. 2018;37(4):1075-1083.
5. Leong SC, Webb CJ. Sino-Nasal Outcome Test-22 quality-of-life patterns in patients presenting with nasal septal perforation *Clin Otolaryngol*. 2018;43(2):604-608.
6. Delaney SW, Kridel RWH. Contemporary Trends in the Surgical Management of Nasal Septal Perforations: A Community Survey. *Facial Plast Surg* 2019;35(1):78-84.

7. Kim SW, Rhee CS. Nasal septal perforation repair: predictive factors and systematic review of the literature. *Curr Opin Otolaryngol Head Neck Surg* 2012;20:58-65.
8. Chhabra N, Houser SM. Endonasal repair of septal perforations using a rotational mucosal flap and acellular dermal interposition graft. *Int Forum Allergy Rhinol* 2012;2(5):392-6.
9. Kilty SJ, Brownrigg PJ, Safar A. Nasal septal perforation repair using an inferior turbinate flap. *J Otolaryngol* 2007;36:38e42.
10. Kridel RW, Foda H, Lunde KC. Septal perforation repair with acellular human dermal allograft. *Arch Otolaryngol Head Neck Surg* 1998;124:73e8.
11. André RF, Lohuis PJ, Vuyk HD. Nasal septum perforation repair using differently designed, bilateral intranasal flaps, with nonopposing suture lines. *J Plast Reconstr Aesthet Surg* 2006; 59:829e34.
12. Friedman M, Ibrahim H, Ramakrishnan V. Inferior turbinate flap for repair of nasal septal perforation. *Laryngoscope* 2003;113(8):1425-8.
13. Teymoortash A, Werner JA. Repair of nasal septal perforation using a simple unilateral inferior meatal mucosal flap. *J Plast Reconstr Aesthet Surg* 2009;62(10):1261-4.
14. Raol N, Olson K. A novel technique to repair moderate-sized nasoseptal perforations. *Arch Otolaryngol Head Neck Surg* 2012;138(8):714-6.
15. Greywoode J, Hamilton J, Malhotra PS, Saad AA, Pribitkin EA. Repair of nasal septal perforation with porcine small intestinal submucosa xenograft. *J Otol Rhinol* 2012, 1:2.
16. Dayton S, Chhabra N, Houser S. Endonasal septal perforation repair using posterior and inferiorly based mucosal rotation flaps. *Am J Otolaryngol* 2017;38(2):179-182.
17. Watson D, Barkdull G. Surgical management of the septal perforation. *Otolaryngol Clin North Am* 2009;42(3):483-93.
18. Tastan E, Aydogan F, Aydin E, Can IH, Demirci M, Uzunkulaoglu H, Unlu I. Inferior turbinate composite graft for repair of nasal septal perforation. *Am J Rhinol Allergy* 2012;26(3):237-42.
19. Virkkula P, Mäkitie AA, Vento SI. Surgical outcome and complications of nasal septal perforation repair with temporal fascia and periosteal grafts. *Clin Med Insights Ear Nose Throat* 2015;29;8:7-11.
20. Nomura T, Ushio M, Kondo K, Kikuchi S. Effects of nasal septum perforation repair on nasal airflow: An analysis using computational fluid dynamics on preoperative and postoperative three-dimensional models. *Auris Nasus Larynx* 2018;45(5):1020-1026.



# Evaluation of patient satisfaction from nasal septal surgery applying NOSE questionnaire.

J. Dąbrowska-Bień<sup>1</sup>, **S. F. Górski<sup>1</sup>**, E. Gos<sup>2</sup>, H. Skarżyński<sup>1</sup>, P. H. Skarżyński<sup>1 2 3 4</sup>

<sup>1</sup>Department of Otorhinolaryngosurgery, World Hearing Center, Institute of Physiology and Pathology of Hearing, Kajetany/Warsaw, Poland, <sup>2</sup>Department of Teleaudiology and Screening, World Hearing Center, Institute of Physiology and Pathology of Hearing, Kajetany/Warsaw, Poland, <sup>3</sup>Heart Failure and Cardiac Rehabilitation Department, Medical University of Warsaw, Poland, <sup>4</sup>Institute of Sensory Organs, Warsaw, Poland.

*Septal and turbinate surgery 2, Building M2 Study Hall, Sept 29, 14.45*

**Background:** The primary goal of this study was to compare quality of life and severity of symptoms related to nasal obstruction after septoplasty. The secondary goal is septoplasty effectiveness assessment using the NOSE questionnaire.

**Methodology/Principal:** A single institution prospective observational study. Patients had had septal deviation and symptomatic nasal obstruction for at least 3 months, and medical management had failed. 51 patients completed the NOSE-POL and VAS questionnaires 2 weeks before the septoplasty, 3 months and 7 months after the surgery.

**Results:** There was significant improvement in nasal obstruction 3 months (27.41,  $p < 0.001$ ), and 7 months after septoplasty (20.74,  $p < 0.05$ ) compared to baseline. (60,37). The comparison between 3-month and 7-month score was not statistically significant ( $p > 0.05$ ), indicating stability of nasal obstruction symptoms. VAS-score before septoplasty was (6.33). VAS-score results also statistically confirmed significant improvement in nasal obstruction symptoms 3 months after the septoplasty ( $M = 2.39$ ;  $p < 0.001$ ) as well as 7 months after the surgery ( $M = 3.84$ ;  $p < 0.01$ ).

**Conclusions** In patients with septal deformity, nasal septoplasty results in significant improvement in disease-specific quality of life and high patient satisfaction.

NOSE-POL questionnaire is a useful tool for measuring the outcomes of this procedure.

**Key words:** Nasal Septum/surgery, Nasal Obstruction/surgery, Quality of Life, Prospective Studies, Treatment Outcome

## Literature

1. Akerlund A, Millqvist E, Oberg D, Bende M. Prevalence of upper and lower airway symptoms: the Skövde population-based study. *Acta Otolaryngol.* 2006;126(5):483-488. doi:10.1080/00016480500416835
2. Hastan D, Fokkens WJ, Bachert C, et al. Chronic rhinosinusitis in Europe--an underestimated disease. A GA<sup>2</sup>LEN study. *Allergy.* 2011;66(9):1216-1223. doi:10.1111/j.1398-9995.2011.02646.x
3. Bauchau V, Durham SR. Prevalence and rate of diagnosis of allergic rhinitis in Europe. *Eur Respir J.* 2004;24(5):758-764. doi:10.1183/09031936.04.00013904
4. Smith KD, Edwards PC, Saini TS, Norton NS. The prevalence of concha bullosa and nasal septal deviation and their relationship to maxillary sinusitis by volumetric tomography. *Int J Dent.* 2010;2010. doi:10.1155/2010/404982
5. Siegel NS, Gliklich RE, Taghizadeh F, Chang Y. Outcomes of septoplasty. *Otolaryngol Head Neck Surg.* 2000;122(2):228-232. doi:10.1016/S0194-5998(00)70244-0
6. Jessen M, Ivarsson A, Malm L. Nasal airway resistance and symptoms after functional septoplasty: comparison of findings at 9 months and 9 years. *Clin Otolaryngol Allied Sci.*

1989;14(3):231-234. doi:10.1111/j.1365-2273.1989.tb00366.x

7. Samad I, Stevens HE, Maloney A. The efficacy of nasal septal surgery. *J Otolaryngol.* 1992;21(2):88-91.
8. Dinis PB, Haider H. Septoplasty: long-term evaluation of results. *Am J Otolaryngol.* 2002;23(2):85-90. doi:10.1053/ajot.2002.30987
9. Stewart MG, Smith TL, Weaver EM, et al. Outcomes after nasal septoplasty: results from the Nasal Obstruction Septoplasty Effectiveness (NOSE) study. *Otolaryngol Head Neck Surg.* 2004;130(3):283-290. doi:10.1016/j.otohns.2003.12.004
10. Harrill WC, Pillsbury HC, McGuirt WF, Stewart MG. Radiofrequency turbinate reduction: a NOSE evaluation. *Laryngoscope.* 2007;117(11):1912-1919. doi:10.1097/MLG.0b013e3181271414
11. Uppal S, Mistry H, Nadig S, Back G, Coatesworth A. Evaluation of patient benefit from nasal septal surgery for nasal obstruction. *Auris Nasus Larynx.* 2005;32(2):129-137. doi:10.1016/j.anl.2005.01.006
12. André RF, Vuyk HD, Ahmed A, Graamans K, Nolst Trenité GJ. Correlation between subjective and objective evaluation of the nasal airway. A systematic review of the highest level of evidence. *Clin Otolaryngol.* 2009;34(6):518-525. doi:10.1111/j.1749-4486.2009.02042.x
13. Boyce JM, Eccles R. Assessment of subjective scales for selection of patients for nasal septal surgery. *Clin Otolaryngol.* 2006;31(4):297-302. doi:10.1111/j.1749-4486.2006.01243.x
14. Singh A, Patel N, Kenyon G, Donaldson G. Is there objective evidence that septal surgery improves nasal airflow? *J Laryngol Otol.* 2006;120(11):916-920. doi:10.1017/S0022215106003410
15. Arunachalam PS, Kitcher E, Gray J, Wilson JA. Nasal septal surgery: evaluation of symptomatic and general health outcomes. *Clin Otolaryngol Allied Sci.* 2001;26(5):367-370. doi:10.1046/j.0307-7772.2001.00481.x
16. Stewart MG, Witsell DL, Smith TL, Weaver EM, Yueh B, Hannley MT. Development and validation of the Nasal Obstruction Symptom Evaluation (NOSE) scale. *Otolaryngol Head Neck Surg.* 2004;130(2):157-163. doi:10.1016/j.otohns.2003.09.016
17. Dąbrowska-Bień J, Skarżyński H, Gos E, Gwizdalska I, Lazecka KB, Skarżyński PH. Clinical Evaluation of a Polish Translation and Cross-Cultural Adaptation of the Nasal Obstruction Symptom Evaluation (NOSE) Scale. *Med Sci Monit.* 2018;24:7958-7964. doi:10.12659/MSM.909934
18. Rhee JS, Poetker DM, Smith TL, Bustillo A, Burzynski M, Davis RE. Nasal Valve Surgery Improves Disease-Specific Quality of Life. *The Laryngoscope.* 2005;115(3):437-440. doi:10.1097/01.mlg.0000157831.46250.ad
19. Busner J, Targum SD. The clinical global impressions scale: applying a research tool in clinical practice. *Psychiatry (Edgmont).* 2007;4(7):28-37.
20. Fokkens WJ, Lund VJ, Mullol J, et al. European Position Paper on Rhinosinusitis and Nasal Polyps 2012. *Rhinol Suppl.* 2012;23:3 p preceding table of contents, 1-298.
21. Cohen J. A power primer. *Psychological Bulletin.* 1992;112(1):155-159. doi:10.1037/0033-2909.112.1.155
23. Correlation and regression | The BMJ. <https://www.bmj.com/about-bmj/resources-readers/publications/statistics-square-one/11-correlation-and-regression>. Accessed December 15, 2019.
23. Nilsen AH, Helvik A-S, Thorstensen WM, Bugten V. A comparison of symptoms and quality of life before and after nasal septoplasty and radiofrequency therapy of the inferior turbinate. *BMC Ear Nose Throat Disord.* 2018;18:2. doi:10.1186/s12901-017-0050-z
24. Bugten V, Nilsen AH, Thorstensen WM, Moxness MHS, Amundsen MF, Nordgård S. Quality of life and symptoms before and after nasal septoplasty compared with healthy

individuals. *BMC Ear Nose Throat Disord.* 2016;16:13. doi:10.1186/s12901-016-0031-7

25. Thorstensen WM, Bugten V, Sue-Chu M, Fosslund NPW, Romundstad PR, Steinsvåg SK. Sino-nasal characteristics in asthmatic patients. *Otolaryngol Head Neck Surg.* 2012;147(5):950-957. doi:10.1177/0194599812451408

26. Randolph CC. Allergic rhinitis and asthma in the athlete. *Allergy Asthma Proc.* 2006;27(2):104-109.

201183

## Collapse of bacterial diversity of the sinus microbiome characterizes poor evolution after ESS for CRS

**Axel E. Renteria**<sup>1,2</sup>, Anastasios Maniakas<sup>1,3</sup>, Emmanuel Gonzalez<sup>4,5</sup>, Leandra Endam Mfuna<sup>1</sup>, Marc-Henri Asmar<sup>1</sup>, Martin Desrosiers<sup>1,2</sup>

<sup>1</sup>Centre de Recherche du Centre Hospitalier de l'Université de Montréal (CRCHUM), Montréal, QC, Canada;

<sup>2</sup>Département d'oto-rhino-laryngologie et chirurgie cervico-faciale du centre hospitalier de l'Université de Montréal (CHUM), Montréal, QC, Canada <sup>3</sup>Department of Otorhinolaryngology & head and neck surgery, MD Anderson Center of Texas University, Houston, Texas, USA; <sup>4</sup>Canadian Centre for Computational Genomics, Montreal, QC, Canada; <sup>5</sup>Genome Québec Innovation Center, Montreal, QC, Canada.

*CRS – pathophysiology 2, Building M1 Room S1, Sept 29, 10.15*

Microbiome dysbiosis is a well-documented feature of chronic rhinosinusitis (CRS). Nevertheless, why recurrence of the disease is so frequent after surgery remains unexplained. In this study, we evaluated the microbiome of CRS patients after endoscopic sinus surgery (ESS) to understand microbiome changes associated with treatment failure using in-depth 16S bacterial RNA analysis.

96 adult patients with CRS were recruited at time of ESS and followed prospectively after surgery where they continued the standard medical treatment. Endoscopically-obtained sinus swabs were collected pre- and post-op for 16S bacterial RNA analysis. Patients responding to surgery and those failing it had their microbiome compared at the OTU level to assess bacterial abundance, alpha and beta diversity. Failure to the treatment was assessed with the modified Lund-Kennedy scale.

Compared to patients responding to surgery, those failing it demonstrated a significant decrease in alpha diversity ( $P < 0.0001$ ) and change in beta diversity ( $P < 0.001$ ). A significant multiple log-fold increase in all *Staphylococcus aureus* OTUs was also found ( $FDR < 0.001$ ).

With this report, we better characterize patients refractory to the surgical treatment, which can lead to an improved management early in the course of the disease. Furthermore, restoring diversity may be considered as novel therapeutic goal.

**Key words:** Diversity, Microbiome, OTU, CRS, ESS, *S. aureus*

## Azithromycin reduces *Staphylococcus aureus* in refractory CRS patients: a 16S RNA analysis

**Axel E. Renteria<sup>1,2</sup>**, Anastasios Maniakas<sup>1,3</sup>, Emmanuel Gonzalez<sup>4,5</sup>, Leandra Endam Mfuna<sup>1</sup>, Marc-Henri Asmar<sup>1</sup>, Martin Desrosiers<sup>1,2</sup>

<sup>1</sup>Centre de Recherche du Centre Hospitalier de l'Université de Montréal (CRCHUM), Montréal, QC, Canada;

<sup>2</sup>Département d'oto-rhino-laryngologie et chirurgie cervico-faciale du centre hospitalier de l'Université de Montréal (CHUM), Montréal, QC, Canada <sup>3</sup>Department of Otorhinolaryngology & head and neck surgery, MD Anderson Center of Texas University, Houston, Texas, USA; <sup>4</sup>Canadian Centre for Computational Genomics, Montreal, QC, Canada; <sup>5</sup>Genome Québec Innovation Center, Montreal, QC, Canada.

*CRS – pathophysiology 2, Building M1 Room Σ1, Sept 29, 10.15*

In CRS, the microbiome is believed to be an important component of pathophysiology, thus assessment of modification in microbiome structure following therapeutic intervention may help identify underlying mechanisms of action. We wished to compare microbiome changes associated with low-dose macrolide use in refractory CRS patients.

Prospective, placebo-controlled trial study. 40 adult CRS patients refractory to ESS and budesonide rinses were recruited after surgery. Patients were randomized to either azithromycin 250 mg or placebo thrice weekly for 4 months. Endoscopically-obtained sinus swabs were obtained at beginning and end of treatment. 16S bacterial analysis using the ANCHOR technique was used to assess changes in the microbiome of azithromycin vs placebo treated patients at the OTU level to assess bacterial abundance, alpha and beta diversity.

Patients on placebo demonstrated a significant change in their beta diversity at the OTU level compared to patients on azithromycin ( $P = 0.043$ ). There was also a significant increase in all *S. aureus* subspecies (OTU) of their microbiome ( $P < 0.0001$ ).

Here, we demonstrate the microbiome of refractory CRS may be modulated by the addition of low dose azithromycin. Reduction in *S. aureus* abundance is unexpected and may either reflect improvement of barriers or a possible anti-*S. aureus* antibiotic effect.

**Key words:** Diversity, Microbiome, OTU, CRS, ESS, *S. aureus*, azithromycin

201190

The nasal microbiome in chronic rhinosinusitis and healthy controls: A comparative analysis.

**Axel Wolf, MD<sup>1</sup>**, Christina S. Kumpitsch<sup>2</sup>, Christine Moissl-Eichinger<sup>2,3</sup> and Peter V. Tomazic, MD<sup>1</sup>

<sup>1</sup> Department of Otorhinolaryngology, Medical University of Graz, , Austria, <sup>2</sup> Diagnostic and Research Institute of Hygiene, Microbiology and Environmental Medicine, Medical University of Graz, Austria, <sup>3</sup> BioTechMed, Krenngasse 37, 8010 Graz, Austria

*Abstract Session 13, Building M2 CR1, Sept 27, 14.45*

**Background:** Advances in DNA sequencing have made it possible to undertake in-depth analyses of microbes that are not amenable to culture. Based on recent studies that described an altered microbiome in patients suffering from chronic rhinosinusitis (CRS), we hypothesize that the paranasal microbiome can reflect disease status, stage and indicate mechanistic processes in general. This study aimed to undertake a comparative analysis of the nasal microbiome of patients with CRS with and without nasal polyps (CRSwNP, CRSsNP) and healthy controls.

**Methodology:** This project included 20 CRSwNP patients (16m, 4w, mean age 43yrs., SD 11.6), 20 CRSsNP patients (12m, 8w, mean age 39yrs., SD 13.1) and 10 healthy controls (8m, 2w, mean age 41yrs., SD 14.3). Samples of mucus of the ostiomeatal complex were analysed by high-throughput sequencing of the 16S rRNA gene using the MiSeq platform.

**Results:** Sequence data revealed microbial changes that may mirror disease status and disease progression.

**Conclusion:** Mapping microbial changes in patients with CRSsNP and CRSwNP might improve our understanding of the pathobiology of the disease, and help in the design of novel diagnostic and treatment strategies.

**Key words:** chronic; sinusitis; polyps; microbiome; nose

201206

Office-based polypectomy efficacy and patients' tolerability using an electrically-powered microdebrider in 50 patients.

**J. Viera-Artiles, P<sup>1</sup>.** Corriols, E. López-Simón<sup>1</sup>, D. Lobo, R. Megía<sup>1</sup>

<sup>1</sup>ENT Department, Hospital Universitario Marqués de Valdecilla, Santander, Spain.

*CRS - surgical management 4, Building M1 Σ2, Sept 29, 10.15*

**Background:** In-office polypectomies under local anaesthesia in selected chronic rhinosinusitis (CRS) patients with obstructive nasal polyps has become popularized in North America, in opposition to functional endoscopic sinus surgery. However, the impact and expansion in Europe are very low in comparison. We aim to provide more in-depth evidence about the patient's experience, safety and effectivity of this procedure to help widespread implementation.

**Methodology/Principal:** A prospective study of 50 consecutive CRS patients who underwent in-office "microdebrider-assisted" polypectomy was performed. Patients' tolerability was measured objectively through vital signs monitoring and subjectively with a visual analogue scale (VAS) for pain. The effectivity was assessed using the SNOT-22 questionnaire pre-surgery, 1 and 3 months afterwards. Surgical complications and post-operative events were recorded.

**Results:** The procedure was very well tolerated with a mean VAS for the pain of 2,75 out of 10. The vasovagal presyncope was the most common incident (10%). One complication with severe bradycardia was registered caused by the trigemino-cardiac reflex. The SNOT-22 questionnaires' score showed a 60% reduction in the first month which was maintained later.

**Conclusions:** In-office polypectomy is a well-tolerated and effective for selected CRS patients. Severe complications are rare but might happen. Therefore, it is important to perform this procedure under safe conditions.

**Key words:** Nasal Polyps, Sinusitis, Local Anesthesia.



201211

## Anatomic findings in patients undergoing revision endoscopic sinus surgery and factors predicting the need for revision procedure: a retrospective study

**Victoria Grammatopoulou**<sup>1</sup>, Chang Woo Lee<sup>1</sup>, Vishnu S. Sunkaraneni<sup>1</sup>

<sup>1</sup> ENT Department, Royal Surrey County Hospital, Guildford, UK

*CRS - surgical management 2, Building M2 CR3, Sept 27, 10.15*

**Background:** The main indication for endoscopic sinus surgery (ESS) remains the failure of maximum medical treatment for patients with chronic rhinosinusitis (CRS). The study reports pre- and intra-operative anatomic findings along with the factors predicting the need for revision ESS.

**Methodology/Principal:** We identified 136 cases with CRS who underwent repeat surgery over a 7-year period. All patients were assessed with endoscopic examination of the sinonasal cavities and computed tomography (CT) of the sinuses after failed conservative treatment.

**Results:** Preoperative endoscopic, CT and intraoperative surgical findings included residual anterior ethmoid cells in 85%, incomplete posterior ethmoidectomy in 84%, unopened sphenoid sinus in 75%, retained agger nasi cell in 73.5%, remnant uncinate process in 57%, residual frontal cells in 47%, amputated middle turbinate in 25%, false middle meatal antrostomy in 18%, septal deviation in 17%, inferior antrostomies in 13%, neo-osteogenesis in 12.5%, lateralised middle turbinate in 7%, accessory ostia in 4% cases. A significant number of patients had systemic diseases, including asthma in 32% and non-steroidal anti-inflammatory drug exacerbated respiratory disease (N-ERD) in 10%. Allergic fungal rhinosinusitis (AFRS) was found in 15%, 7% suffered with allergic rhinitis, 4% had bronchiectasis, one patient had Churg-Strauss disease and one patient had cystic fibrosis.

**Conclusions:** There is little consensus about the extent of primary ESS. Failed ESS may be caused by a number of factors, including systemic diseases associated with CRS, but also by anatomic findings related to technical approaches.

**Key words:** Chronic rhinosinusitis, revision ESS, sinus CT scan.

### **Literature:**

1. Gore MR, Ebert CS, Zanation AM, Senior BA. Beyond the "central sinus": radiographic findings in patients undergoing revision functional endoscopic sinus surgery. *Int. Forum Allergy Rhinol.* 2013 Feb;3(2):139-46.
2. Levine CG, Casiano RR. Revision Functional Endoscopic Sinus Surgery. *Otolaryngol Clin North Am.* 2017 Feb;50(1): 143-164.
3. Shen PH, Weitzel EK, Lai JT, Wormald PJ, Lin CH. Retrospective study of full-house functional endoscopic sinus surgery for revision endoscopic sinus surgery. *Int Forum Allergy Rhinol.* 2011 Nov-Dec;1(6):498-503.
4. Wood AJ, Zhou L, Wilkinson S, Douglas RG. Effectiveness of extensive sinus surgery with post-operative medical management for chronic rhinosinusitis. *J Laryngol Otol.* 2017 Jul; 131(S2):S19-S24.
5. Huang BY, Lloyd KM, DelGaudio JM, Jablonowski E, Hudgins PA. Failed Endoscopic Sinus Surgery: Spectrum of CT Findings in the Frontal Recess. *Radiographics.* 2009 Jan-Feb;29(1):177-95.
6. Bassiouni A, Wormald PJ. Role of Frontal Sinus Surgery in Nasal Polyp Recurrence. *Laryngoscope.* 2013 Jan;123(1):36-41.
7. Stein NR, Jafari A, DeConde AS. Revision rates and time to revision following endoscopic

sinus surgery: a large database analysis. *Laryngoscope*.2018 Jan;128(1):31-36.

## Introduction of a personalized 3D test system for Primary Ciliary Dyskinesia – optimizing diagnostics and therapy planning

**Stephan Hackenberg**<sup>1</sup>, Agmal Scherzad<sup>1</sup>, Helge Hebestreit<sup>2</sup>, Nina Lodes<sup>3</sup>, Maria Steinke<sup>3</sup>

<sup>1</sup>Department of Oto-Rhino-Laryngology, Head and Neck Surgery, University Hospital Wuerzburg, Germany;

<sup>2</sup>Pediatric Department, University Hospital Wuerzburg, Germany, <sup>3</sup>Chair of Tissue Engineering and Regenerative Medicine, University Hospital Wuerzburg, Germany

*Paediatric rhinology 2, Building M2 CR3, Sept 28, 11.45*

**Background:** Primary ciliary dyskinesia (PCD) is a rare disease with a heterogeneous genetic pattern and various clinical manifestations based on a broad spectrum of ciliary dysfunction including amotile or hypermotile disorders. Therapeutic approaches must be adjusted to the individual phenotype

**Methodology:** We designed personalized in-vitro models using primary nasal mucosa cells and fibroblasts from biopsies of patients with PCD and healthy controls. Co-culture was conducted under air-liquid interface conditions using a decellularized biological matrix. Models were characterized via REM and immunohistochemistry. Ciliary beat was assessed by high-speed microscopy including particle transport studies. Therapeutic testing was performed using an aerosol exposure chamber.

**Results:** A well-differentiated pseudostratified model of the respiratory epithelium was established including kinocilia and mucus-producing goblet cells. Ciliary beat patterns were well analyzable. The individual ciliary dysfunction (amotile or hypermotile) could successfully be transferred into the model. Diverse response patterns were observed following aerosol exposure to drugs.

**Conclusions:** We could introduce a novel test-system for PCD helping to identify the individual phenotype of the heterogeneous disease combined with the possibility to evaluate the effectiveness of potential therapeutic agents. Hence, our approach is a first step towards personalized medicine in rare diseases of the respiratory tract.

**Key words:** Primary ciliary dyskinesia, rare disease, in vitro, brush biopsy

201267

## Surgery as single-modality treatment for early-stage olfactory neuroblastoma: an institutional experience, systematic review and individual patient data meta-analysis

**Christian M. Meerwein**<sup>1</sup>, Georgios Nikolaou<sup>1</sup>, Gregori Binz<sup>1</sup>, Michael B. Soyka<sup>1β</sup>, David Holzmann<sup>1β</sup>

<sup>1</sup>Department of Otorhinolaryngology, Head & Neck Surgery, University Hospital Zurich, Zurich, Switzerland.

<sup>1β</sup>Both authors contributed equally as last authors.

*Sinonasal malignancy 2, Building M1 Room Σ3, Sept 28, 14.45*

**Background:** We aimed to summarize evidence on purely-surgically treated olfactory neuroblastoma (ONB) patients and to present their outcome measures in an individual patient data (IPD) meta-analysis, including our own institutional case series.

**Methods:** Retrospective institutional case series, systematic review of literature and IPD meta-analysis on purely-surgically treated patients.

**Results:** A total of 10 patients was treated purely surgically at our institution between 1985 and 2019. Their median follow-up time was 83 months (IQR 32-123). At last follow-up, 10/10 patients (100%) were alive and free of disease. The IPD meta-analysis on 128 patients from 32 studies revealed a DFS and OS of 67.7% and 75.4% at 5 years and 57.1% and 71.9% at 10 years, respectively. On univariate analysis, tumor stage Kadish C/D and tumor grading Hyams III//IV significantly affected OS ( $p=0.000$  and  $0.001$  respectively). For low-risk patients with absence of risk factors (Kadish C/D, Hyams III/IV, positive surgical margins), the DFS was 80.6% at 5 years and 67.8% at 10 years respectively. Median follow-up period was 60 months (IQR 20-102).

**Conclusions:** "Surgery-only" is an equal alternative to combined treatment in carefully selected patients with lack of risk factors and better outcome measures then reported before.

**Key words:** olfactory, neuroblastoma, treatment, outcome, surgical, margins

### Literature

Diaz EM, Jr., Johnigan RH, 3rd, Pero C, et al. Olfactory neuroblastoma: the 22-year experience at one comprehensive cancer center. *Head & Neck*. 2005;27(2):138-149.

Dulgierov P, Allal AS, Calcaterra TC. Esthesioneuroblastoma: a meta-analysis and review. *Lancet Oncology*. 2001;2(11):683-690.

Lund VJ, Howard D, Wei W, Spittle M. Olfactory neuroblastoma: past, present, and future? *Laryngoscope*. 2003;113(3):502-507.

Nicolai P, Castelnovo P, Lombardi D, et al. Role of endoscopic surgery in the management of selected malignant epithelial neoplasms of the naso-ethmoidal complex. *Head and Neck-Journal for the Sciences and Specialties of the Head and Neck*. 2007;29(12):1075-1082.

## Diagnostic accuracy of CT and MRI compared to surgical exploration for anterior skull base and medial orbital wall infiltration in advanced sinonasal tumours

**Christian M. Meerwein**<sup>1</sup>, Shila Pazahr<sup>2</sup>, Michael B. Soyka<sup>1</sup>, Martin W. Hüllner<sup>3</sup>, David Holzmann<sup>1</sup>

<sup>1</sup>Department of Otorhinolaryngology, Head & Neck Surgery, University Hospital Zurich, Zurich, Switzerland,

<sup>2</sup>Department of Neuroradiology, University Hospital Zurich, Zurich, Switzerland, <sup>3</sup>Department of Nuclear Medicine, University Hospital Zurich, Zurich, Switzerland.

*Sinonasal malignancy 2, Building M1 Room E3, Sept 28, 14.45*

**Background:** Knowledge of medial orbital wall (MOW) and anterior skull base (ASB) infiltration is of uttermost importance for staging and therapy planning of advanced sinonasal tumours.

**Methods:** We assessed the diagnostic performance of preoperative CT and MRI for MOW and ASB infiltration compared to intraoperative exploration.

**Results:** Both CT and MRI yielded higher diagnostic accuracy for MOW infiltration (Reader 1: 83.6% CT; 89.0% MRI, Reader 2: 91.8% CT, 93.2% MRI) than for ASB infiltration (Reader 1: 82.2% CT, 82.2% MRI, Reader 2: CT 67.7%, MRI 67.7%). Both modalities were equal to the gold standard, except for ASB assessment by Reader 2 with MRI. A postoperative change of T classification is common (Reader 1: 28.8%, Reader 2: 31.5%).

**Conclusions:** CT and MRI are accurate methods for the assessment of MOW infiltration. ASB assessment is challenging and false-positive and false-negative findings are common with both methods, emphasizing the need for intraoperative exploration. Based on our findings we opt for an obligate tumour biopsy and tumor exploration under general anesthesia.

**Key words:** CT, MRI, skull base, tumour, classification

### Literature

5. Lund VJ, Howard DJ, Lloyd GA, Cheesman AD. Magnetic resonance imaging of paranasal sinus tumors for craniofacial resection. *Head Neck*. 1989;11(3):279-283.
6. Lloyd GA, Lund VJ, Phelps PD, Howard DJ. Magnetic resonance imaging in the evaluation of nose and paranasal sinus disease. *Br J Radiol*. 1987;60(718):957-968.
7. perineural, and venous sinus invasion of skull base tumors. *AJNR Am J Neuroradiol*. 1996;17(10):1937-1945.
13. Eisen MD, Yousem DM, Loevner LA, Thaler ER, Bilker WB, Goldberg AN. Preoperative imaging to predict orbital invasion by tumor. *Head Neck*. 2000;22(5):456-462.
14. Moiyadi AV, Pai P, Nair D, Pal P, Shetty P. Dural involvement in skull base tumors-accuracy of preoperative radiological evaluation and intraoperative assessment. *J Craniofac Surg*. 2013;24(2):526-530.
15. Edge SB, Compton CC. The American Joint Committee on Cancer: the 7th edition of the AJCC cancer staging manual and the future of TNM. *Ann Surg Oncol*. 2010;17(6):1471-1474.
16. Simmen D, Schuknecht B. [Computerized tomography of paranasal sinuses--a preoperative check list]. *Laryngorhinootologie*. 1997;76(1):8-13.
17. Schuknecht B, Simmen D. [State of the Art. Diagnostic imaging of paranasal sinus diseases]. *Laryngorhinootologie*. 2002;81(2):126-146.

18. Landis JR, Koch GG. The measurement of observer agreement for categorical data. *Biometrics*. 1977;33(1):159-174.
19. Imola MJ, Schramm VL, Jr. Orbital preservation in surgical management of sinonasal malignancy. *Laryngoscope*. 2002;112(8 Pt 1):1357-1365.
20. Turri-Zanoni M, Lambertoni A, Margherini S, et al. Multidisciplinary treatment algorithm for the management of sinonasal cancers with orbital invasion: A retrospective study. *Head Neck*. 2019;41(8):2777-2788.
21. Nicolai P, Battaglia P, Bignami M, et al. Endoscopic surgery for malignant tumors of the sinonasal tract and adjacent skull base: a 10-year experience. *Am J Rhinol*. 2008;22(3):308-316.
22. Hanna E, DeMonte F, Ibrahim S, Roberts D, Levine N, Kupferman M. Endoscopic resection of sinonasal cancers with and without craniotomy: oncologic results. *Arch Otolaryngol Head Neck Surg*. 2009;135(12):1219-1224.
23. Nicolai P, Castelnovo P, Lombardi D, et al. Role of endoscopic surgery in the management of selected malignant epithelial neoplasms of the naso-ethmoidal complex. *Head Neck*. 2007;29(12):1075-1082.
24. Lisan Q, Kolb F, Temam S, Tao Y, Janot F, Moya-Plana A. Management of orbital invasion in sinonasal malignancies. *Head Neck*. 2016;38(11):1650-1656.
25. Zwagerman NT, Zenonos G, Lieber S, et al. Endoscopic transnasal skull base surgery: pushing the boundaries. *J Neurooncol*. 2016;130(2):319-330.
26. Lund V, Howard DJ, Wei WI. Endoscopic resection of malignant tumors of the nose and sinuses. *Am J Rhinol*. 2007;21(1):89-94.
27. Lepera D, Leone F, Volpi L, et al. Endoscopic endonasal approach for sinonasal and anterior skull base malignancies in the elderly. *Head Neck*. 2018;40(5):917-926.
28. Oker N, Verillaud B, Wassef M, et al. Ethmoidal adenocarcinoma treated by exclusive endoscopic approach: Focus on learning curve and modification of management. *Head Neck*. 2018;40(1):126-136.
29. McIntyre JB, Perez C, Penta M, Tong L, Truelson J, Batra PS. Patterns of dural involvement in sinonasal tumors: prospective correlation of magnetic resonance imaging and histopathologic findings. *Int Forum Allergy Rhinol*. 2012;2(4):336-341.

A randomized open-label study comparing herbal product with *Andrographis paniculata* extract and mometasone furoate nasal spray in therapy of acute postviral rhinosinusitis

**Aleksandar Perić<sup>1</sup>**, Dejan Gaćeša<sup>2</sup>, Aleksandra Barać<sup>3</sup>, Aneta V. Perić<sup>4</sup>

<sup>1</sup>Department of Otorhinolaryngology, Military Medical Academy Faculty of Medicine, Belgrade, Serbia, <sup>2</sup>ENT Hospital "Dr. Žutić", Belgrade, Serbia, <sup>3</sup>University in Belgrade, School of Medicine, Belgrade, Serbia, <sup>4</sup>Institute for Pharmacy, Military Medical Academy Faculty of Medicine, Belgrade, Serbia

*Acute Rhinosinusitis 1, Building M1 Room Σ1, Sept 27, 10.15*

**Background:** The aim of this study was to assess efficacy and safety of herbal preparation Sinulan forte® containing extract of *Andrographis paniculata* in comparison to mometasone furoate nasal spray (MFNS) in therapy of acute postviral rhinosinusitis (APRS).

**Methodology/Principal:** Forty-six APRS patients were included in this randomized study. Group 1 (n = 23) received MFNS 200 µg twice daily and Group 2 (n = 23) received Sinulan forte®, tablets 225 mg per os, twice daily, both for 10 days. We assessed total symptom score (TSS), individual scores for each nasal symptom, quality of life outcome (Sino-nasal outcome test 20, SNOT-20), and endoscopic findings, before and after treatment. We compared the absolute post-treatment scores, as well as relative changes for all parameters after two different therapies.

**Results:** Significantly lower absolute post-treatment scores and better relative improvement were found for TSS, nasal obstruction, rhinorrhea, facial pain/pressure, impaired sense of smell, mucosal oedema and nasal secretion in patients receiving herbal preparation. We found no adverse events in Group 2, while in Group 1 two patient reported mild epistaxis and two dryness in the nose.

**Conclusions:** Herbal product with *Andrographis paniculata* can be a safe and effective treatment for patients with APRS.

**Key words:** Inflammation; Glucocorticoids; Plants, medicinal; Rhinitis; Sinusitis

## Literature

1. Laccourreye O, Werner A, Laccourreye L, Bonfils P. Benefits, pitfalls and risks of phytotherapy in clinical practice in otorhinolaryngology. *Eur Ann Otorhinolaryngol Head Neck Dis* 2017; 134(2): 95-99.
2. Coon JT, Ernst E. *Andrographis paniculata* in the treatment of upper respiratory tract infections: a systematic review of safety and efficacy. *Planta Med* 2004; 70(4): 293-298.
3. Passali D, Cambi J, Passali FM, Bellussi LM. Phytoneering: a new way of therapy for rhinosinusitis. *Acta Otorhinolaryngol Ital* 2015; 35(1): 1-8.
4. Meltzer EO, Teper A, Danzig M. Intranasal corticosteroids in the treatment of acute rhinosinusitis. *Curr Allergy Asthma Rep* 2008; 8(2): 133-138.

201333

## Retrospective analyses of prognostic factors in patients with chronic rhinosinusitis with nasal polyps

**Demir UL.<sup>1</sup>**

<sup>1</sup>University of Uludag Medical School, Department of Otolaryngology, Bursa-TURKEY

*CRS - surgical management 2, Building M2 CR3, Sept 27, 10.15*

**Background:** Chronic Rhinosinusitis with nasal polyps (CRSwNP) is a common upper airway disease which can be recalcitrant despite adequate medical or surgical treatment in some patients. The underlying factors which influence disease recurrence following primary or revision surgery are still unclear. We aimed to evaluate and compare the prognostic factors in patients with CRSwNP after primary or revision endoscopic sinus surgery (ESC).

**Methodology/Principal:** The data of 204 patients who underwent ESC (108 primary and 96 revision) between 2008-2019 in a tertiary university hospital with the diagnosis of CRSwNP were retrospectively analysed. The demographic findings, comorbid diseases, endoscopic and computerized tomography (CT) findings, surgical experience and outcomes are documented.

**Results:** Presence of aspirin sensitivity ( $p=0.038$ ), positive skin prick test ( $p=0.016$ ) and Samter's triad ( $p=0.016$ ) were found to be significant in patients with recurrence who underwent to revision surgery. In addition, the disease was more severe in revision group diagnosed via preoperative endoscopic nasal polyp score ( $p=0.003$ ) and Lund-Mackay CT score ( $p=0.001$ ).

**Conclusions:** To achieve better outcomes and to reduce the revision rates after surgery we should perform a meticulous dissection to prevent any residual diseased cell detected at CT. In addition, a customized treatment protocols can be delineated according to the comorbid diseases.

**Key words:** Chronic Rhinosinusitis, nasal polyp, endoscopic sinus surgery, recurrence, revision.



## Nasal packing in routine nasal surgery: Is there any value? A systematic review

**Dr Sofia Anastasiadou<sup>1</sup>**, Mrs Catherine Rennie<sup>2</sup>, Mr Hesham Saleh<sup>2</sup><sup>1</sup>Core surgical trainee in Birmingham Children's Hospital, Birmingham, UK; <sup>2</sup>Consultant Rhinologist in Imperial Healthcare NHS Trust, London*Rhinology – miscellaneous 1, Building M1 Room Σ2, Sept 28, 14.45*

**Background** In theory, nasal packing after routine nasal surgery aims to limit post-operative epistaxis. However, there is little evidence supporting this and increasing numbers of surgeons are not using any packing material after routine nasal surgery. There is an abundance of trials, which investigate the use of nasal packing, we have therefore performed a systematic review to determine if there is any value in routine post-operative nasal packing.

**Methods** A systematic review was performed to include all English language randomised controlled trials published on the Medline and Embase and Classic+Embase databases. 930 trials were identified and this was reduced to 16 on screening.

**Results** Having identified the appropriate studies, full text screening and data analysis was performed. We found little evidence to support routine nasal packing

**Conclusion** This systematic literature review does not support routine use of nasal packing after nasal surgery. There was no increase in complications in the group without nasal packing and as packing can cause discomfort for patients and many modern packs are expensive we would not advocate their routine use.

**Key words:** nasal packing, septoplasty, septo-rhinoplasty

## Literature

- F. Zhang, J. Chen, X. Lei, X. Chen, and X. Zhang, "The comfort of patients with different nasal packings after endoscopic sinus surgery for chronic rhinosinusitis: A protocol for network meta-analysis," (in eng), *Medicine (Baltimore)*, vol. 98, no. 24, p. e16007, Jun 2019, doi: 10.1097/MD.00000000000016007.
- R. Eliashar, M. Gross, J. Wohlgelernter, and J. Y. Sichel, "Packing in endoscopic sinus surgery: is it really required?," (in eng), *Otolaryngol Head Neck Surg*, vol. 134, no. 2, pp. 276-9, Feb 2006, doi: 10.1016/j.otohns.2005.10.012.
- K. G. Kastl *et al.*, "Patient comfort following FESS and Nasopore® packing, a double blind, prospective, randomized trial," (in eng), *Rhinology*, vol. 52, no. 1, pp. 60-5, 03 2014, doi: 10.4193/Rhin13.020.
- M. G. Shrimme, A. Tabaee, A. K. Hsu, S. Rickert, and L. G. Close, "Synechia formation after endoscopic sinus surgery and middle turbinate medialization with and without FloSeal," (in eng), *Am J Rhinol*, vol. 21, no. 2, pp. 174-9, 2007 Mar-Apr 2007.
- S. D. Kim *et al.*, "Effectiveness of hemostatic gelatin sponge as a packing material after septoplasty: A prospective, randomized, multicenter study," (in eng), *Auris Nasus Larynx*, vol. 45, no. 2, pp. 286-290, Apr 2018, doi: 10.1016/j.anl.2017.05.007.
- I. Z. Iqbal *et al.*, "Intranasal packs and haemostatic agents for the management of adult epistaxis: systematic review," (in eng), *J Laryngol Otol*, vol. 131, no. 12, pp. 1065-1092,

Dec 2017, doi: 10.1017/S0022215117002055.

- K. Badran, T. H. Malik, A. Belloso, and M. S. Timms, "Randomized controlled trial comparing Merocel and RapidRhino packing in the management of anterior epistaxis," (in eng), *Clin Otolaryngol*, vol. 30, no. 4, pp. 333-7, Aug 2005, doi: 10.1111/j.1365-2273.2005.01019.x.
- E. Eski and I. Yilmaz, "Effect of nasal packs in septoplasty," (in eng), *Am J Otolaryngol*, vol. 36, no. 5, pp. 726-7, 2015 Sep-Oct 2015, doi: 10.1016/j.amjoto.2014.12.012.

201462

## Resection of hemangioma in maxillary sinus via prelacrimal approach

**Luan Tran**<sup>1</sup>, Lam Le<sup>2</sup>

<sup>1</sup>Pham Ngoc Thach University of Medicine, 02 Duong Quang Trung street, District 10, Ho Chi Minh City, Vietnam,

<sup>2</sup>Ear Nose Throat Hospital - Ho Chi Minh City, 155 Tran Quoc Thao street, District 3, Ho Chi Minh City, Vietnam

*Benign nasal tumours 2, Building M2 Room Σ4, Sept 28, 10.15*

**Background:** hemangiomas in sinonasal region especially those originating from sinus mucosa are very rare in literature.

**Methodology/Principal:** clinical case series

**Results:** six cases of maxillary sinus hemangioma were resected via prelacrimal approach at Ear Nose Throat Hospital - Ho Chi Minh City. The most common symptoms were epistaxis and nasal obstruction. CT features were well-enhanced heterogeneous mass, with bony remodeling and erosion. Tumors originated from anterior wall of maxillary sinus in most cases. During the surgery, maxillary sinus hemangioma was found as a soft and bleeding tumor. Complete tumor excision was obtained in all cases via prelacrimal approach. Intra-operative bleeding was well controlled, blood loss was 265ml on average. Pathology results were cavernous hemangioma in four cases and lobular capillary hemangioma in two cases. Neither complications nor recurrence were noted.

**Conclusions:** prelacrimal approach is safe and effective for maxillary sinus hemangioma resection.

**Key words:** hemangioma, maxillary sinus, prelacrimal approach

201474

## Surgery in nasal polyp patients: outcome after a minimum observation of 10 years

**Stephan Vlamincx, MD** <sup>1</sup>; Emmanuel Prokopakis, MD, PhD <sup>2</sup>; Hideyuki Kawauchi, MD, PhD <sup>3</sup>; Jean-Christophe van Cutsem <sup>1</sup>; Peter W Hellings, MD, PhD <sup>4</sup>; Mark Jorissen, MD, PhD <sup>4</sup>; Sven Seys, PhD <sup>4</sup>; Frederic Acke, MD, PhD <sup>5</sup>; Claus Bachert, MD, PhD <sup>5</sup>; Thibaut Van Zele, MD, PhD <sup>5</sup>; Philippe Gevaert, MD, PhD <sup>5</sup>

<sup>1</sup>Department of Otorhinolaryngology, CHM Mouscron, Belgium, <sup>2</sup>Department of Otorhinolaryngology, University Hospital, Crete, Greece, <sup>3</sup>Department of Otorhinolaryngology, University Hospital, Shimane, Japan, <sup>4</sup>Department of Otorhinolaryngology, University Hospital, Leuven, Belgium, <sup>5</sup>Department of Otorhinolaryngology, University Hospital, Ghent, Belgium

*CRS - outcome assessment 2, Building M1 Room Σ1, Sept 28, 10.15*

**Key words:** asthma, adult onset asthma, chronic rhinosinusitis, nasal polyps, outcome, endoscopic sinus surgery.

**Disclosure:** None of the authors have any conflict of interest or financial disclosure.

**BACKGROUND:** Chronic rhinosinusitis with nasal polyps (CRSwNP) often requires surgery, but recurrence even after surgery is common. Recurrence rates largely vary in literature and asthma seems to be a comorbid factor. In this study, we aim to estimate disease recurrence during a long-term follow-up, together with the investigation of possible predicting and/or influencing parameters.

**METHODS:** Out of 196 patients operated for CRSwNP between 01/2000 and 01/2006, 133 patients had a follow-up of at least 10 years and could be included. The inflammatory profile at surgery was determined on nasal tissue and sinonasal secretions, and included analysis of eosinophils, eosinophilic-rich mucus (ERM) and fungal hyphae (FH). During follow-up, recurrence, received treatments and comorbidities were collected.

**RESULTS:** Out of the 133 included patients, local eosinophilia was present in 81% and ERM in 60%. Recurrence during follow-up was observed in 62%, and was associated with local eosinophilia and ERM (both  $p < 0.001$ ). Asthma was present in 28% at inclusion, and 17% developed asthma after surgery during follow-up. The presence of asthma, at inclusion as well as developed during follow-up, was significantly associated with recurrence of CRSwNP ( $p = 0.001$  for group comparison).

At final evaluation the mean SNOT-22 score was 31.0 points (SD 21.3, range 0-91). The comparison of SNOT-22 with the clinical evaluation (absence or presence of nasal polyps) showed significance ( $p = 0.001$ , mean 24.9 (SD 18.2) for absence of NP versus mean 40.6 (SD 22.3) for presence of NP.

**CONCLUSIONS:** Recurrence after CRSwNP surgery is common when a long-term follow-up is taken into account. ERM detected in sinonasal secretions at surgery seems to be a predictive factor for recurrence. Asthma is a frequently found comorbid factor in CRSwNP, develops even at higher age despite surgical treatment for CRSwNP, and is also associated with a higher recurrence rate. Sustained medical care after surgery is mandatory.

**Nuno O. Mendes<sup>1</sup>**, J. Antunes<sup>1</sup>, C. Adónis<sup>1</sup>, A. Guimarães<sup>1</sup>, Filipe M. Freire<sup>1</sup>

<sup>1</sup>Otolaryngology Department, Hospital Professor Doutor Fernando Fonseca, Lisbon, Portugal

*Snoring and OSA 1, Building M2 CR2, Sept 28, 14.45*

**Background:** Obstructive Sleep Apnea (OSA) is common in children. Although adenotonsillectomy is the recommended treatment, some patients with severe OSA (Apnea-hypopnea index/AHI >10) remain symptomatic after surgery and may need further workup. This study aims to: 1) analyse preoperative factors and its relation with surgical failure in severe pediatric OSA; 2) determine the levels of airway collapse during DISE (Drug Induced Sleep Endoscopy) in cases of surgical failure (AHI>5 after adenotonsillectomy); 3) evaluate the efficacy of targeted surgery based on DISE findings.

**Methodology/Principal:** Between 2010 and 2019, all children diagnosed with severe OSA in our Hospital underwent adenotonsillectomy and repeated polysomnography. Cases of surgical failure underwent DISE for planning eventual directed surgery.

**Results:** 80 cases of severe pediatric OSA were diagnosed (68,8% males; mean age:4,3 years – SD 2,49; mean AHI:16,3 – SD 7,14). We found a significant association between surgical failure (11,3% of cases; mean AHI:6,9 – SD 0,91) and obesity ( $p=0,002$ ). Epiglottis collapse was present in every DISEs. Adenoids were present in 66%. All cases of surgical failure had directed surgery and surgical cure ( $AHI\leq 5$ ) was obtained in 100% of cases.

**Conclusions:** DISE based surgery seems a safe and effective tool to manage persistent OSA after adenotonsillectomy.

**Key words:** Sleep Apnea, Obstructive; Endoscopy; Epiglottis

**Nuno O. Mendes<sup>1</sup>**, J. Rito, D. Raposo<sup>1</sup>, G. Pedrosa, A. Guimarães<sup>1</sup>, Filipe M. Freire<sup>1</sup>

<sup>1</sup>Otolaryngology Department, Hospital Professor Doutor Fernando Fonseca, Lisbon, Portugal

*Imaging and investigations 1, Building M1 Room Σ4, Sept 29, 11.45*

**Background:** Diagnosis of Sinonasal Inverted Papilloma (SIP) is histological, however, paranasal sinus CT-scan and MRI may show some typical features of this benign tumour. This investigation aims to ascertain if there is any association between the pattern of radiologic findings and the potential for recurrence or malignant transformation of SIP.

**Methodology/Principal:** Cases with histological diagnosis of SIP between 2012 and 2019 were reviewed. Preoperative CT and MRI were analysed and cases of recurrence or malignant transformation identified.

**Results:** 31 cases of SIP were diagnosed (63,3% males; mean age 62,4 years - SD 13,6; mean follow-up 4,3 years – SD 1,1) in our Hospital.

On preoperative CT, focal hyperostosis was the most common sign (83,9%) and it located tumour implantation site in all cases. A Convuluted cerebriform pattern on MRI showed a positive predictive value of 80,6% on identifying SIP. We found a significant association between focal bone resorption on CT and malignant transformation at 2 years ( $p=0,024$ ). No imaging feature was associated with potential for SIP recurrence.

**Conclusions:** While MRI shows good accuracy on distinguishing inverted papilloma from other lesions, hyperostosis on CT predicts its site of implantation. Bone resorption on CT is the only feature that may have prognostic value.

**Key words:** Papilloma, Inverted; Hyperostosis

## To be or not to be Local Allergic Rhinitis?

**Alexios S. Vardouniotis<sup>1</sup>**, Ioannis Papadakis<sup>2</sup>, Konstantinos Ballas<sup>3</sup>, Eleftherios Margaritis<sup>4</sup>, Emmanuel Fountoulakis<sup>4</sup>, Panayiotis Kontopoulos<sup>4</sup>, Marios Stagas<sup>5</sup>, Ilias Lapousis<sup>6</sup>

<sup>1</sup>NHS Treatment Center, Portsmouth, UK, <sup>2</sup>Thorpe Park Clinic, Living Care, Leeds, UK, <sup>3</sup>Communitas ENT clinics, NHS, Croydon, UK, <sup>4</sup>Private Practice, Athens, Greece, <sup>5</sup>Stagas Labs®, Athens, Greece, <sup>6</sup>Interbalkan European Medical Center, Thessaloniki, Greece

*Non-allergic rhinitis 1, Building M2 CR2, Sept 28, 11.45*

**Background:** Local allergic rhinitis (LAR) presents as a diagnostic and therapeutic challenge for clinicians. Even though it affects a significant proportion of non-atopic rhinitis patients and a significant number of articles regarding prevalence, evolution, diagnosis and treatment have been published, the condition remains still largely unrecognized and therefore misdiagnosed and mistreated.

**Principal:** We present and discuss a case of a 9 year old boy, presenting with nasal symptoms and negative results of SPTs (Skin Prick Tests) or serum IgE (sIgE). Nasal Allergen Challenge (NAC) was used to diagnose Local Allergic Rhinitis to house dust mites and the patient was treated with Allergen Immunotherapy (AIT).

Initially, the sublingual protocol was well tolerated. Unfortunately however, after a while he presented with an allergic skin reaction. His rash was uncomplicated; he did not have any other accompanying symptoms besides skin itchiness. Eventually after dose modification the patient is successfully continuing the treatment.

The question raised is how can the symptoms be justified, since LAR is defined as a localized nasal allergic response - specific IgE antibodies are produced locally- with absence of systemic atopy.

**Results:** The symptoms, duration, severity, and complications of LAR are similar to those of AR and can affect adults and children. Thus, a portion of patients diagnosed with NAR or chronic rhinitis of unknown etiology may have LAR. Patients are frequently misdiagnosed with idiopathic NAR, and distinguishing between both entities is difficult without specific diagnostic tests.

**Conclusions:** The relationship between local allergic inflammation and systemic allergic inflammation is unclear. Nevertheless, LAR is an example of precision medicine, where a correct early diagnosis through NAC, enables the establishment of an etiologic treatment in means of (AIT) facilitating the improvement in quality of life in the years to follow and potentially preventing the development of lower airway disease.

**Keywords:** Local allergic rhinitis, allergic rhinitis, nasal IgE, nasal provocation test, allergen immunotherapy

#### Literature:

Hellings, P.W.; Klimek, L.; Cingi, C.; Agache, I.; Akdis, C.; Bachert, C.; Bousquet, J.; Demoly, P.; Gevaert, P.; Hox, V.; et al. Non-allergic rhinitis: Position paper of the European Academy of Allergy and Clinical Immunology. *Allergy* 2017, 72, 1657–1665.

Rondón, C.; Campo, P.; Togias, A.; Fokkens, W.J.; Durham, S.R.; Powe, D.G.; Mullol, J.; Blanca, M. Local allergic rhinitis: Concept, pathophysiology, and management. *J. Allergy Clin. Immunol.* 2012; 129, 1460–1467. DOI:[10.1016/j.jaci.2012.02.032](https://doi.org/10.1016/j.jaci.2012.02.032).

Rondon, C.; Eguiluz-Gracia, I.; Campo, P. Is the evidence of local allergic rhinitis growing? *Curr. Opin. Allergy Clin. Immunol.* 2018; 18, 342–349.

DOI: 10.1097/ACI.0000000000000456.

Campo, P.; Eguiluz-Gracia, I.; Bogas, G.; Salas, M.; Plaza Seron, C.; Perez, N.; Mayorga, C.; Torres, M.J.; Shamji, M.H.; Rondon, C. Local allergic rhinitis: Implications for management. Clin. Exp. Allergy 2019, 49, 6–16. DOI: **10.1111/cea.13192**.



201560

## The Burden of Non-steroidal anti-inflammatory exacerbated respiratory disease from the patient's perspective – a qualitative analysis of posts from the Samter's Society

**MC Alanin<sup>1</sup>**, T Laidlaw<sup>2+3</sup>, The Samter's Society, C Hopkins<sup>1+4</sup>

<sup>1</sup>ENT Department, Guy's Hospital, London, UK, <sup>2</sup>Translational Research in Allergy, Harvard Medical School, USA,

<sup>3</sup>Brigham and Women's Hospital, Boston MA, USA, <sup>4</sup>King's College London, UK

*CRS - diagnosis and investigations 2, Building M1 Room Σ2, Sept 28, 10.15*

**Background:** A subset of patients with chronic rhinosinusitis with nasal polyps and asthma have non-steroidal anti-inflammatory drug exacerbated respiratory disease (N-ERD). Typically, these patients often have more difficult to treat symptoms of both chronic rhinosinusitis and asthma. They also have higher rates of revision after surgery. In this paper we aim to include the patient's perspective of living with N-ERD.

**Methodology:** In this qualitative study, three months of posts from the Samter's Society Support Group on social media were screened and analysed

**Results:** Thematic analysis revealed eight main themes in relation to patient interpretations when living with N-ERD. Main themes included symptom severity, quality of life, biological treatment options, diet, surgery, medical treatment, lack of awareness of N-ERD, conflicts between medical professionals and the importance of the support group

**Conclusions:** This study adds to the growing body of evidence that many patients with N-ERD are living with uncontrolled disease which has significant impact on their quality of life. In addition, it has identified important themes that are relevant to know for doctors treating these patients. Finally, it has highlighted the importance of patient advocacy groups in providing support to patients living with chronic disease

**Key words:** Nasal polyps, paranasal sinus disease, quality of life, respiratory system, smell

## Trigeminal Endonasal Perception – an Outcome Predictor for Septoplasty

Sabrina Bischoff<sup>1\*</sup>; Sophia C. Poletti<sup>1,2,3\*</sup>, Seraina Kunz<sup>1</sup>, Si-Young Kiessling<sup>4</sup>, Dominik Hinder<sup>5</sup>, Anita Dreher<sup>6</sup>, Cezmi A. Akdis<sup>6</sup>, **Michael B. Soyka<sup>1</sup>**

*\* both authors contributed equally*

<sup>1</sup>Department of Otorhinolaryngology Head and Neck Surgery, University of Zurich and University Hospital Zurich, Zurich, Switzerland, <sup>2</sup>Smell & Taste Clinic, Department of Otorhinolaryngology, 'Technische Universität Dresden', Dresden, Germany, <sup>3</sup>Department of Otorhinolaryngology-Head and Neck Surgery, University of Tübingen, Tübingen, Germany, <sup>4</sup>Department of Otorhinolaryngology Head and Neck Surgery, Kantonsspital St.Gallen, St.Gallen, Switzerland, <sup>5</sup>Department of Otorhinolaryngology Head and Neck Surgery, Luzerner Kantonsspital, Luzern, Switzerland, <sup>6</sup>Swiss Institute of Asthma and Allergy Research (SIAF), University of Zurich, Davos Switzerland

*Septal and turbinate surgery 2, Building M2 Study Hall, Sept 29, 14.45*

**Background:** Septal surgery is a commonly performed procedure. However, outcome is not always favorable. So far no good parameters could be identified to predict surgical outcome. Trigeminal function has been linked to the sensation of nasal patency. We speculated that trigeminal sensitivity could predict postoperative success.

**Methodology/Principal:** Patients undergoing septal surgery were tested for their trigeminal function before and 6 weeks after surgery using a lateralization test. At the same time points nasal patency was rated on a visual analogue scale. TRPV1 mRNA expression was measured by PCR.

**Results:** : Thirty patients were included with a median age of 29 years and equal gender distribution. Trigeminal perception and sensation of nasal obstruction showed a significant correlation ( $r=0.40$ ,  $p=0.03$ ): preoperative lateralisation test scores, representing endonasal trigeminal sensitivity, correlated significantly with the mean VAS change scores, which demonstrate subjective improvement. Additionally, high TRPV1 mRNA expression was linked with good postoperative nasal patency.

**Conclusions:** This study not only shows the importance of the trigeminal sensitivity in patients undergoing septoplasty, it also proves to be a fairly good predictor for the subjective outcome. Patients with low trigeminal sensitivity should undergo septoplasty only after thorough counselling.

**Key words:** Nasal Septum, Surgery, Trigeminal Nerve, Treatment Outcome

## Monoclonal antibodies for the treatment of chronic rhinosinusitis with nasal polyposis – therapeutic outcome and predictive biomarkers

Eva Catharina Meier<sup>3</sup>, Peter Schmid-Grendelmeier<sup>4</sup>, Urs Steiner<sup>5</sup>, **Michael Soyka**<sup>1</sup>

<sup>1</sup>Department of Otorhinolaryngology, Head and Neck Surgery, University Hospital and University of Zürich, Zürich, Switzerland, <sup>2</sup>Allergy Unit Department of Dermatology, University Hospital and University of Zürich, Zürich, Switzerland, <sup>3</sup>Department of Clinical Immunology, University Hospital Zurich, Zürich, Switzerland.

*CRS - medical management 1, Building M2 CR2, Sept 27, 10.15*

**Background:** There are few studies about the treatment with monoclonal antibodies (mAB) like omalizumab, mepolizumab, and dupilumab in patients suffering from chronic rhinosinusitis with nasal polyposis (CRSwNP). Studies about the use of benralizumab in CRSwNP are missing.

The reported rate of success in those studies differ and it stays uncertain, if there are any biomarkers to predict a successful therapy.

Our aim was to analyse the therapeutic outcome in a real life setting and to identify predictive biomarkers for treatment-success.

**Method/Principals:** Data of patients with CRSwNP treated with a mAB between November 2014 and January 2020 were analysed retrospectively.

Improvement in polyp-score and clinical symptoms like nasal obstruction, sense of smell, nasal discharge, and facial pain have been analysed.

To identify possible predictive biomarkers, other characteristics like use of nasal or systemic steroids, comorbidities, previous history of sinus surgery, tissue-eosinophilia, blood values (eosinophils, total-IgE, eosinophilic cationic protein, IL-5), and allergic sensitization in serum also have been analysed.

**Results:** 48 treatments in 29 patients (m/f = 15/14) aged 27-70 years were reviewed.

In the omalizumab-group ten (45.4%), in the mepolizumab-group twelve (60%), and in the benralizumab-group two (33.4%) showed a reduction in polyp-size and/or improvement in clinical symptoms.

A correlation between biomarkers and treatment-success couldn't been found.

**Conclusion:** MAB can be an additional treatment-option in difficult-to-treat patients with CRSwNP.

But, due to missing predictive biomarkers, it remains still unknown how to choose the right mAB.

**Key words:** Sinusitis, Antibodies, Monoclonal, Cytokines, Therapeutics

201565

## Inflammatory endotypes of chronic rhinosinusitis with nasal polyps with and without NSAID intolerance: The use of nasal secretions

Urs C. Steiner<sup>1\*</sup>, Sabrina Bischoff<sup>2\*</sup>, Alan Valaperti<sup>1</sup>, Joanna Starzyk<sup>2</sup>, Sarina Bucher<sup>2</sup>, Lucas M Bachmann<sup>3</sup>, **Michael B. Soyka**<sup>2</sup>

<sup>1</sup>Department of Clinical Immunology, University Hospital Zurich, Zürich, Switzerland, <sup>2</sup>Department of Otorhinolaryngology, Head and Neck Surgery, University Hospital and University of Zürich, Zürich, Switzerland, <sup>3</sup>Medignition INC., Zürich, Switzerland

*CRS - diagnosis and investigations 3, Building M1 Room S4, Sept 29, 10.15*

**Background:** Chronic rhinosinusitis with nasal polyps (CRSwNP), in Europe, is a predominantly type 2-dominated inflammatory disease of the upper airways. CRSwNP with comorbid NSAID-exacerbated respiratory disease (NERD) present a more intense inflammation and is difficult to treat. The aim of the study was to compare the cytokine based inflammatory endotype of CRSwNP with and without NSAID intolerance in nasal secretions..

**Methodology/Principal:** Nasal secretions were collected from twenty-six patients suffering from CRSwNP, thirteen with NERD and thirteen without NSAID intolerance. As control, nasal secretion was collected from fifteen healthy donors. The tryptase and ten human cytokines were analyzed by a cytokine multiple array on a Luminex 200 platform..

**Results:** The inflammatory endotype of CRSwNP compared to healthy participants was characterized by significantly increased IL-6 and IL-5. Furthermore, NERD patients presented a significant elevation of tryptase and IL-13. Between CRSwNP with and without NSAID intolerance the increased IL-5 (1.52pg/ml vs 28.17pg/ml; p-value: 0.022) - and IL-13 (0.57pg/ml vs 15.02pg/ml; p-value: 0.023) values in NERD was objectified.

**Conclusions:** We could identify IL-13 as a specific biomarker in nasal secretions of patients with NERD. This implies that targeted anti-IL-13 therapy could be useful specifically in these patients. We therefore suggest non-invasive cytokine measurements to be of high importance in endotyping CRSwNP patients before the use of biologic treatment.

**Key words:** Sinusitis, Fluids and Secretions, Cytokines, Inflammation, Precision Medicine

201684

## Developing a skull base surgery service in a developing country - the Pretoria University , South Africa experience 2015 - 2020

**T.H.C. Quitter<sup>1</sup>**

<sup>1</sup>Department of Otorhinolaryngology and Head and Neck Surgery, Pretoria University, Pretoria, Gauteng, South Africa

*CRS - diagnosis and investigations 1, Building M1 Room Σ4, Sept 27, 14.45*

**Background:** Sharing the experience of developing a skull base surgery service in a developing country

**Methodology/Principal:** Describing the process of developing a comprehensive service for skull base surgery in a developing country in collaboration with the university's department of neurosurgery. This includes unusual solutions that had to be found and challenges specific to the context of South Africa.

**Results:** Information on more than 100 patients treated, divided into categories of inflammatory disease, benign and malignant tumours. Challenges faced in the process. Solutions developed. Initiatives taken to teach the skills acquired to more colleagues as well as retaining young specialists in the service.

**Conclusions:** Developing the skull base service at Pretoria University has been a difficult but satisfying experience. It is difficult to obtain equipment in a resource scarce environment as well as challenging to retain young specialists despite the financial pull of private practice. We have been immensely encouraged by the support that we received from experts in the field within our country as well as in other countries. The byproduct of this process has been the establishment of instructional courses in sinus surgery and base of skull surgery that are aimed at colleagues from South Africa and Sub-Saharan Africa.

**Key words:** Provide up to 5 key words using Mesh terms for indexing purposes

Skull Base, Developing countries, South Africa, Health resources, Neoplasms

201794

## Endovascular emergency treatment of Cavernous Internal Carotid Artery acute injury with Flow Diverter Stent: a single center experience.

Agosti E.<sup>1</sup>, **Sileo G.**<sup>2</sup>, Bandi F.<sup>2</sup>, Arosio A.D.<sup>2</sup>, Turri-Zanoni M.<sup>2</sup>, Pozzi F.<sup>1</sup>, Giorgianni A.<sup>3</sup>, Locatelli D.<sup>1</sup>, Castelnovo P.<sup>1</sup>

<sup>1</sup>Department of Neurosurgery, University of Insubria, Varese, Italy, <sup>2</sup>Department of Otolaryngology, University of Insubria, Varese, Italy, <sup>3</sup>Department of Neuroradiology, ASST Sette-Laghi, Ospedale di Circolo, Varese, Italy

*Epistaxis and HHT 1, Building M1 Room Σ4, Sept 28, 11.45*

**Background:** the management of internal carotid artery (ICA) acute injury is an emergency that requires prompt intervention. Various treatment techniques are described in the literature, differing in ICA occlusion or reconstruction.

**Methodology:** we describe a case series of 5 patients with massive epistaxis consequent cavernous ICA acute injury (3 iatrogenic, 1 post-traumatic and 1 erosive neoplastic). After a first endoscopic endonasal packing operation, the patients performed digital subtraction angiography (DSA) with balloon occlusion test (BTO) which highlighted possible post-occlusive neurological deficits in absence of good hemodynamic compensation. Therefore, a flow diverter stent (FDS) was placed in the site of the lesion during intravenous (iv) infusion of ReoPro in 3 cases and Tirofiban in 2 cases.

**Results:** No patient had periprocedural ischemic-hemorrhagic complications. All patients had a regular clinical evolution, without general complications or focal neurological deficits. In 4 patients, no further bleeding occurred, while in 2 cases epistaxis recurred at 5 and 15 days after the endovascular procedure, with resolution after endoscopic ICA coverage with Hadad flap or muscular free graft.

**Conclusions:** FDS positioning is a valid option in patients affected by cavernous ICA injury with poor hemodynamic compensation at BTO.

**Key words:** carotid artery injury, endovascular procedure, stents, epistaxis

**Pavlos Pavlidis**<sup>1</sup>, Athanasios Saratziotis<sup>2</sup>, Gregor Schitte<sup>3</sup>, Maria Ferfeli<sup>4</sup>, Georgios Kekes<sup>5</sup>, Haralampos Gouveris<sup>6</sup>

<sup>1</sup>ENT Clinic, Papanikolaou Hospital, Thessaloniki, Greece, <sup>2</sup>ENT Clinic, University Hospital of Larissa, Larissa, Greece, <sup>3</sup>Medical University of Graz, Division of General Anaesthesiology, Emergency- and Intensive Care Medicine, Graz, Austria, <sup>4</sup>Applied Informatics, University of Macedonia, Greece, <sup>5</sup>Medical School of Aristotle University of Thessaloniki, Thessaloniki, Greece, <sup>6</sup>ENT Clinic, University Hospital of Mainz, Mainz, Germany

*Smell and taste 2, Building M2 CR2, Sept 27, 14.45*

**Background:** The study aimed at investigating the effects of various stimulus duration patterns on electrogustometric (EGM) thresholds.

**Methodology:** In 212 non-smokers (age range 10-80 years), divided into 8 age groups, EGM-thresholds were recorded bilaterally. We evaluated the effects of stimulus duration (0.5, 1.0, 1.5, and 2.0 s) on EGM detection thresholds. We have also examined any possible correlation between EGM-thresholds and age or sex.

**Results:** EGM thresholds recorded in response to stimuli of 1 and 1.5s duration are not significantly different from each other, although lower than those recorded after 0.5-stimuli. EGM-thresholds after 2s stimuli are the highest of all thresholds tested. These findings are consistent at all 6 recording areas, and all age groups.

**Conclusions:** The relationship between lingual threshold sensitivity to low levels of electric current with stimulus duration ranging from 0.5 to 2 sec is non-monotonic. no difference between sexes in threshold detection was present. The finding that EGM-thresholds increase non-uniformly (and certainly non-linearly) with age.

Key-words: stimulus, electrogustometry, threshold, taste strips

#### Literature

1. Stillman JA, Morton RP, Goldsmith D (2000) Automated electrogustometry: a new paradigm for the estimation of taste detection thresholds. Clin Otolaryngol Allied Sci 25:120-5.
2. Loucks CA, Doty RL (2004) Effects of stimulation duration on electrogustometric thresholds. Physiology & Behavior 81: 1-4.
3. Miller SL, Mirza N, Doty R (2002) Electrogustometric thresholds: Relationship to anterior tongue locus, area of stimulation and number of fungiform papillae. Physiol Behav 75: 753-757.
4. Negoro A, Umemoto M, Fukazawa K, Terada T, Sakagami M (2004) Observation of tongue papillae by video microscopy and contact endoscopy to investigate their correlation with taste function Auris Nasus Larynx 31: 255-259.
5. Pavlidis P, Gouveris H, Kekes G, Maurer J (2014) Electrogustometry thresholds, tongue tip vascularization, and density and morphology of the fungiform papillae in diabetes. B-ENT 10:271-278.
6. Pavlidis P, Cámara RJA, Kekes G, Gouveris H (2018) Bilateral taste disorders in patients with Ramsay Hunt syndrome and Bell palsy. Ann Neurol 83:807-815.
7. Wolf A, Illini O, Uy D, Renner B, Mueller CA (2016) A new extension to the Taste Strips test. Rhinology 2016; 54: 45-50.
8. Coats AC (1974) Effects of age, sex and smoking on electrical taste threshold. Ann Otol Rhinol Laryngol 83: 365-369.
9. Reed DR (2008) Birth of a New Breed of Supertaster. Chemical Senses 33:489-491.
10. Braun T, Mack B, Kramer MFR (2011) Solitary chemosensory cells in the respiratory and vomeronasal epithelium of the human nose: a pilot study. Rhinology 49: 507-512.

# Electrogustometry and contact endoscopic findings in patients with head and neck malignancies after treatment with radiochemotherapy.

**Pavlos Pavlidis<sup>1</sup>**, Athanasios Saratziotis<sup>2</sup>, Maria Ferfeli<sup>3</sup>, Georgios Kekes<sup>4</sup>, Haralampos Gouveris<sup>5</sup>

<sup>1</sup>ENT Clinic, Papanikolaou Hospital, Thessaloniki, Greece, <sup>2</sup>ENT Clinic, University Hospital of Larissa, Larissa, Greece, <sup>3</sup>Applied Informatics, University of Macedonia, Greece, <sup>4</sup>Medical School of Aristotle University of Thessaloniki, Thessaloniki, Greece, <sup>5</sup>ENT Clinic, University Hospital of Mainz, Mainz, Germany

*Smell and taste 2, Building M2 CR2, Sept 27, 14.45*

**Background:** to study any changes in electrogustometric (EGM) thresholds and changes in the morphology of the fungiform papillae (fPap) as well as in shape and density of the vessels of the tip of the tongue in patients treated with Radio-chemotherapy (RCT). We have also studied the possibility of any reversion in possible functions and morphology.

**Methodology/Principal:** Eight patients (n=8) with head and neck malignancies (hypopharynx, larynx, oropharynx, parotid) treated with RCT were prospectively studied. A radiation dose ranging between 50,4 Gy and 72 Gy was delivered to the primary tumor. Chemotherapy was given in 2 cycles. Measurements took place before the beginning of treatment (serving as a reference for each patient) and at the end of each cycle of chemotherapy. Two additional measures have been conducted two and four months after the end of the therapy.

**Results:** Patients treated with combined RCT have pronounced changes in the form and vascularization of the fPap during the treatment. EGM-Thresholds were also significantly increased. The additional measurement after the end of the therapy showed an improvement in the EGM-Thresholds, which was not accompanied by an immediate improvement in the shape and vascularization of fPap.

**Conclusion:** Though taste acuity (EGM-Thresholds) seems to increase gradually after the end of RCT, parameters such as the form and vascularization of fPap do not improve parallel.

**Key-words:** radiochemotherapy, electrogustometry, fungiform papillae, vascularization

## Literature

1. Epstein JB, Emerton S, Kolbinson D, Le N, Philips N, Stevenson-Moore P, Osoba D (1999) Quality of life and oral function following radiotherapy for head and neck cancer. *Head Neck* 21:1-11
2. Pavlidis P, Gouveris H, Anogeianaki A, Koutsonikolas D, Anogianakis G, Kekes G (2013) Age-related changes in electrogustometry thresholds, tongue tip vascularization, density, and form of the fungiform papillae in humans. *Chem Senses* 38:35-43
3. Ruo Redda MG, Allis S (2006) Radiotherapy-induced taste impairment. *Cancer Treat Rev.* 32:541–547
4. Pavlidis P, Gouveris H, Gorgulla H, Hast HJ, Maurer J (2015) Electrogustometry and contact endoscopic findings in patients with head and neck malignancies treated with chemotherapy, radiotherapy or radiochemotherapy *Chem Senses.* 40:165-171



## Functional and morphological changes in nasal mucosa in Wegener Granulomatosis and Sarcoidosis - two case reports

Georgios Katsilis<sup>1</sup>, Ioannis Skoumpas<sup>1</sup>, Kuriaki Xanthopoulou<sup>1</sup>, Angellos Nikolaou<sup>1</sup>, **Pavlos Pavlidis<sup>1</sup>**

<sup>1</sup>ENT-Clinic, Papanikolaou Hospital, Thessaloniki, Greece, <sup>2</sup>Department of Nephrology and Dialysis, General Hospital of Veria, Veria, Greece

*Granulomatous diseases of the nose 1, Building M1 Room Σ2, Sept 28, 11.45*

**Background:** Wegener Granulomatosis and Sarcoidosis represent an inflammatory procedure of blood vessels and may affect multiple organs, thus a part of patients will show some otorhinolaryngologic symptoms as the initial sign of the disease. These symptoms may include epistaxis, sinusitis, nasal disease or hearing loss either.

**Case Report 1:** A 64-year-old female presented with a 3-month history of intermittent epistaxis. Contact Endoscopy showed an irregular vascularization of the nasal mucosa. The vesicles were dilated and the mucosa clearly susceptible. Biopsy of oral mucosa confirmed the diagnosis of Wegener granulomatosis. The Sniffin' Sticks Test indicated the presence of hyposmia.

**Case Report 2:** A 54-year-old female presented with a 2-month history of rhinorrhea, reported anosmia, nasal enlargement, chronic rhinosinusitis, cervical lymphadenopathy, supraglottic nodules and salivary gland enlargement. The patient underwent Contact Endoscopy that showed non-typical vascularization and necrotized areas of nasal mucosa. The Sniffin' Sticks Test indicated the presence of anosmia.

**Conclusions:** Sinonasal manifestations of systemic diseases may occur. The combined use of Contact Endoscopy and olfactory tests could provide useful information concerning the morphological and functional condition of nasal mucosa.

**Keywords:** Granulomatosis, Mucosa, Contact Endoscopy, Smell-Test

### Literature

1. Mortaz E, Adcock M, Barnes PJ. Sarcoidosis: Role of non-tuberculosis mycobacteria and Mycobacterium tuberculosis. International Journal of Mycobacteriology. 2014; 3: 225-29
2. Cardona PJ. Reaktivation or reinfection in adult tuberculosis: Is that the question? International Journal of Mycobacteriology. 2016; 4: 400-07
3. Braun JJ, Gentine A, Pauli G. Sinonasal sarcoidosis: review and report of fifteen cases. The Laryngoscope. 2004. 114:1960-63
4. Gottschlich S, Ambrosch P, Kramkowski D, et al. Head and neck manifestations of Wegener's granulomatosis. Rhinology. 2006; 44: 227-33

201859

## Minimally Invasive Surgery Under Local Anaesthesia for Chronic Rhinosinusitis With Nasal Polyps: Our Experience in Older Adults

M Casale<sup>1</sup>, **A Moffa**<sup>1,2</sup>, A Costantino<sup>2</sup>, L Sabatino<sup>1</sup>, M Cassano<sup>2</sup>, V. Rinaldi<sup>2</sup>, P. Baptista<sup>4</sup>.

<sup>1</sup>Unit of Otolaryngology, Integrated Therapies in Otolaryngology, Campus Bio-Medico University, Rome, Italy. <sup>2</sup>Unit of Otolaryngology, University of Foggia, Foggia, Italy. <sup>4</sup>Unit of Otolaryngology, University Clinic of Navarra, Pamplona, Spain.

*CRS - surgical management 1, Building M2 CR3, Sept 29, 10.15*

**Background:** This paper aims to report our experience with a minimally invasive surgical procedure for the treatment of chronic rhinosinusitis with nasal polyps, performed in a day-surgery setting under local anaesthesia.

**Methodology/Principal** A retrospective study of 30 patients with chronic rhinosinusitis with nasal polyps was conducted. Sino-Nasal Outcome Test 22 and modified Lund-Kennedy scores were collected. Intra- and post-operative pain was evaluated using a 10-point visual analogue scale.

**Results:** The mean Sino-Nasal Outcome Test 22 score decreased from  $41.8 \pm 15.8$  pre-operatively to  $13.3 \pm 9.5$  post-operatively ( $p < 0.001$ ). Accordingly, the mean endoscopic score decreased from  $6.8 \pm 1.8$  to  $0.2 \pm 0.7$  ( $p < 0.001$ ). The mean intra-operative pain score was  $2.9 \pm 3.2$ , and 29 patients (96.7 per cent) reported no pain in the post-operative period (visual analogue scale score = 0).

**Conclusions:** Our study confirms that minimally invasive surgery represents a safe, repeatable procedure that results in remarkable subjective and objective improvement, without intra- and post-operative pain or discomfort.

**Key words:** Anesthesia; Elderly; Nasal Polyps; Sinusitis; Surgery.

201860

## Long-term outcome of endoscopic dacryocystorhinostomy among octogenarians - A case control study

**Idit Tessler**<sup>1,2</sup>, Oded Cohen<sup>1,2</sup>, Itai Amos<sup>2</sup>, Doron Halperin<sup>1,2</sup>, Yosef Bavnik<sup>1,2</sup>, Asher Milstein<sup>3,2</sup>, Yochai Shoshani<sup>3,2</sup>, Hana Leiba<sup>3,2</sup>, Meir Warman<sup>1,2</sup>

<sup>1</sup>Department of Otolaryngology, Head and Neck Surgery, Kaplan Medical Center, Rehovot, Israel, <sup>2</sup>Hebrew University, Hadassah Medical School, Jerusalem, Israel, <sup>3</sup>Department of Ophthalmology, Kaplan Medical Center, Rehovot, Israel

*Lacrimal Surgery 1, Building M1 Room Σ4, Sept 29, 11.45*

**Background:** Despite increasing use of endoscopic dacryocystorhinostomy (eDCR), and the increased risk of nasolacrimal duct obstruction with age, data on eDCR among the growing octogenarian population remains limited. This study aims to evaluate short- and long-term eDCR efficacy and safety in octogenarians.

**Methods:** A retrospective case-control study of patients age  $\geq 80$  with younger controls who underwent eDCR between 2002-2017. Pre-, intra- and postoperative factors were collected and completed through telephone interviews. Surgical success rates, defined anatomically (patent lacrimal flow) and functionally (symptomatic relief), were analyzed and measured at the first visit following surgery (immediate success), and after five-years. Univariant analyses were used to assess safety and possible prognostic factors.

**Results:** The study groups included 52 octogenarians (mean age  $83.4 \pm 3.6$ ) and 269 controls ( $57.8 \pm 18.0$ ). The octogenarian's success rate was 94.2% in the immediate analysis and 78.1% after five-years, similar to the controls (92.2% and 80%, respectively), despite higher comorbidity rate among octogenarians (96% vs. 78.8%,  $p=0.001$ ). Intra- and postoperative complication rates were low in both octogenarians and controls with no significant differences.

**Conclusions:** Among octogenarians, eDCR safety, and immediate and five-years outcomes are comparable with younger patients, suggesting that this surgery should be offered to NLDO patients, regardless of age.

**Key words:** endoscopic, dacryocystorhinostomy, long-term outcome, success rate, elderly



201861

**Integrated Odontogenic Sinusitis Classification: a customized approach for Odontogenic Sinusitis. Multi-level classification for patients suffering from odontogenic sinusitis.**

A Moffa<sup>1,2</sup>, V Rinaldi<sup>1</sup>, MA Lopez<sup>1</sup>, M Cassano<sup>2</sup>, A Costantino<sup>3</sup>, L Sabatino<sup>1</sup>, P Baptista<sup>4</sup>. **M Casale<sup>1</sup>**.

<sup>1</sup>*Integrated Sleep Surgery Team UCBM - Unit of Otolaryngology – Integrated Therapies in Otolaryngology, Campus Bio-Medico University, Rome, Italy;* <sup>2</sup>*Unit of Otolaryngology, University of Foggia, Foggia, Italy;* <sup>3</sup>*Otorhinolaryngology Unit, Humanitas Clinical and Research Center-IRCCS, Rozzano (MI), Italy;* <sup>4</sup>*Unit of Otolaryngology, Clinica Universitaria de Navarra, Pamplona, Spain*

*Rhinology – miscellaneous 4, Building M1 Room Σ1, Sept 27, 14.45*

**Background:** The purpose of this study was to propose a multi-level classification system for patients suffering from Odontogenic Sinusitis (OS).

**Methodology/Principal:** The patients were divided into three groups: Group 1, acute odontogenic sinusitis; Group 2, chronic odontogenic sinusitis; Group 3, foreign body in the maxillary sinus without sinusitis. The three groups were divided into subgroups A and B based on the presence or absence of oro-antral communication. The OS etiology was then defined for each group: sinus lift (I), implantological treatment complications (II) and "classic" dental treatment complications (III). All patients were classified according to the treatment performed: medical therapy, intra-oral surgical approach, FESS or combined.

**Results:** 44 patients were included: 24 patients (Group 1), 18 patients (Group 2), and 2 patients (Group 3). In 24 patients an oro-antral communication was detected. In 23 patients was observed a foreign body in the maxillary sinus. The most common etiology was the "classic" dental treatment complication (III), observed in 29 patients and 36 patients were treated with a surgical approach.

**Conclusions:** Our study showed the need to personalize the clinical approach in the individual patient given the significant heterogeneity of the pathology in terms of the clinical presentation, etiology and therapy necessary for the definitive resolution of the disease.

**Key words:** Odontogenic Sinusitis, Classification, oro-antral communication and maxillary sinus.

201883

## Pilot clinical trial of an asymmetrical balloon in the treatment of epistaxis in adult patients.

Christian Debry<sup>1</sup>, Léa Fath, Laura Nakhleh<sup>1</sup>, Guillaume Trau<sup>1</sup>, Idir Djennaoui<sup>1</sup>, Pierre Mahaudeau<sup>1</sup>, Naif Bawazeer<sup>1</sup>, Pauline Paris<sup>1</sup>, Saït Ciftci<sup>1</sup>

<sup>1</sup>ENT, Head & Neck Surgery Department, Haute-pierre Hospital, Strasbourg University Hospital, Strasbourg, Alsace, France

*Epistaxis and HHT 2, Building M1 Room Σ3, Sept 29, 11.45*

**Background:** To assess safety and efficacy of an asymmetrical balloon in the treatment of epistaxis managed in an emergency setting.

**Methods:** Ten patients were treated with CAVI-T™ for epistaxis. Control visits were performed upon device positioning, at several timepoints during treatment and 7 to 10 days post-removal. Primary endpoints were the bleeding arrest and pain score at introduction and inflation of the balloon, during treatment, upon removal and post removal. Secondary endpoints were the adverse events reported and patient quality of life evaluated with the RhinoQoL questionnaire.

**Results:** Bleeding was stopped upon positioning in 90% (n=9) of the cases. Balloon was efficacious in 100% of the patients (n=9) after 1 and 12h and in 88.9% of the cases (n=8) after 6, 24 and 48h. Pain score was moderate at insertion, inflation and during treatment and described as mild upon and post-removal. Minor bleeding recurrence occurred in two patients during the post-treatment period. The adverse events considered device related were in line with other intranasal devices. The mean RhinoQoL impact scores calculated tend to decrease upon the control visits.

**Conclusions:** This study confirms the safety and efficacy of the CAVI-T™ asymmetrical balloon in the management of epistaxis in an emergency setting.

**Keywords:** epistaxis, nasal packing, balloon catheter, intranasal device

### Literature

1. Nikolaou G, Holzmann D, Soyka MB. Discomfort and costs in epistaxis treatment. *Eur Arch Otorhinolaryngol*.2013;270: 2239-44.
2. Pope LER, Hobbs CGL. Epistaxis: an update on current management. *Postgrad Med J*.2005;81:309-14.
3. Timsit CA, Bouchene K, Olfatpour B, Herman P, Tran Ba Huy P. Epidemiology and clinical findings in 20,563 patients attending the Lariboisière Hospital ENT Adult Emergency Clinic. *Ann Otolaryngol Chir Cervicofac* .2001; 118:215-24.
4. Bal dit Sollier C, Drouet L. Epistaxis et traitements antithrombotiques. *Sang Thromb Vaiss*. 2014;26:109-21.
5. Swords C, Patel A, Smith ME, Williams RJ, Kuhn I, Hopkins C. Surgical and interventional radiological management of adult epistaxis:systematic review. *J Laryngol Otol*. 2017; 131: 1108-30.
6. Kindler RM, Holzmann D, Landis BN, Ditzen B, Soyka MB. The high rate of long-term recurrences and sequelae after epistaxis treatment. *Auris Nasus Larynx*.2016;43:412-7.

7. Vermeeren L, Derks W, Fokkens W, Menger D-J. Complications of balloon packing in epistaxis. *Eur Arch Otorhinolaryngol*.2015;272:3077–81.
8. Van Wyk FC, Massey S, Worley G, Brady S. Do all epistaxis patients with a nasal pack need admission? A retrospective study of 116 patients managed in accident and emergency according to a peer reviewed protocol. *J Laryngol Otol*.2007;121:222-7.
9. Marro M, Mondina M, Stoll D, de Gabory L. French validation of the NOSE and RhinoQOL questionnaires in the management of nasal obstruction. *Otolaryngol Head Neck Surg*.2011;144(6):988-93.
10. Atlas SJ, Gallagher PM, Wu YA *et al*. Development and validation of a new health-related quality of life instrument for patients with sinusitis. *Qual Life Res*.2005;14: 1375-86.
11. Atlas SJ, Metson RB, Singer DE, Wu YA, Gliklich RE. Validity of a new health-related quality of life instrument for patients with chronic sinusitis. *Laryngoscope*. 2005; 115:846-54.
12. Beck R, Sorge M, Schneider A, Dietz A: Current approaches to epistaxis treatment in primary and secondary care. *Dtsch Arztebl Int*.2018;115: 12-22.
13. Schaitkin B, Strauss M, Houck JR. Epistaxis: medical versus surgical therapy: a comparison of efficacy, complications, and economic considerations. *Laryngoscope*. 1987;97: 1392-95.
14. Klotz DA, Winkle MR, Richmon J, Hengerer Arthur S. Surgical Management of Posterior Epistaxis: A Changing Paradigm. *Laryngoscope*. 2002;112(9):1577-82.
15. Zou Y, Deng YQ, Xiao CW, Kong YG, Xu Y, Tao ZZ, Shen SM. Comparison of outcomes between endoscopic surgery and conventional nasal packing for epistaxis in the posterior fornix of the inferior nasal meatus. *Pak J Med Sci*. 2015;31(6): 1361-65.
16. Kahn MA, Sumera A, Attique A, Bhatti A. To compare efficacy and discomfort in posterior nasal packing with Foley's catheters versus Bipp gauze in cases of posterior epistaxis. *Armed Forces Med J* .2015; 65(5):640-43.
17. Bachelet JT, Bourlet J, Gleizal A. Hemostatic absorbable gel matrix for severe post-traumatic epistaxis. *Rev Stomatol Chir Maxillofac Chir Orale*.2013; 114(5), 310-14.
18. Snyderman CH, Goldman SA, Carrau RL *et al*. Endoscopic sphenopalatine artery ligation is an effective method of treatment for posterior epistaxis. *Am J Rhinol*.1999; 13:137-40.
19. Wang L, Vogel DH, Posterior epistaxis: comparison of treatment. *Otolaryngol Head Neck Surg*. 1981;89:1001-06.
20. Sireci F, Speciale R, Sorrentino R, Turri-Zanoni M, Nicolotti M, Canevari FR. Nasal packing in sphenopalatine artery bleeding: therapeutic or harmful? *Eur Arch Otorhinolaryngol*.2017;274:1501-5.

## 4-Phase Rhinomanometry, Acoustic Rhinometry and Peak Nasal Inspiratory Flow: comparison between the methods.

**Enrico Savietto**<sup>1</sup>, Diletta Giulia Giuntoli<sup>1</sup>, Andrea Pettorelli<sup>1</sup>, Daniele Sartori<sup>1</sup>, Bruno Scarpa<sup>2</sup>, Alfonso Luca Pendolino<sup>3</sup>, Piero Nicolai<sup>1</sup>, Giancarlo Ottaviano<sup>1</sup>.

<sup>1</sup>Department of Neurosciences, Otolaryngology Section, University of Padova, Padova, Italy, <sup>2</sup>Department of Statistical Sciences, University of Padova, Padova, Italy, <sup>3</sup>Department of ENT, Royal National Throat, Nose and Ear Hospital, London, United Kingdom

*Rhinology – miscellaneous 1, Building M1 Room Σ2, Sept 28, 14.45*

**Background:** Rhinomanometry(RM), acoustic rhinometry(AR) and peak nasal inspiratory flow(PNIF) are the most known objective methods for the measurement nasal patency. The aim of this study was to compare PNIF, AR and 4-phase rhinomanometry(4-PR) and evaluate their correlation with subjective measures of nasal obstruction [Sino-nasal outcome test 22(SNOT-22) and VAS for nasal obstruction(VAS-NO)].

**Methodology:** 101 consecutive adult patients were enrolled. They completed SNOT-22 and VAS-NO questionnaires. Bilateral and unilateral PNIF was measured, nasal resistances were evaluated with 4-PR, AR was performed considering the minimal cross-sectional area.

**Results:** SNOT-22 and VAS-NO showed a positive correlation( $r=0.54, p<0.001$ ). AR, PNIF and 4PR showed mainly significant correlations between them both unilaterally and bilaterally(PNIFvs 4PR: $r=-0.31, p=0.0016$ ; IPNIFvs I4PR: $r=-0.3, p=0.0025$ ; rPNIFvs r4PR: $r=-0.35, p<0.001$ ; PNIFvs AR: $r=0.18, p=0.077$ ; IPNIFvs IAR: $r=0.26, p=0.0087$ ; rPNIFvs rAR: $r=0.32, p=0.0011$ ; 4PRvs AR: $r=-0.5, p<0.001$ ; I4PRvs IAR: $r=-0.51, p<0.001$ ; r4PRvs rAR: $r=-0.46, p<0.001$ ). SNOT-22 correlated with PNIF( $r=-0.31, p=0.0017$ ), rPNIF( $r=-0.22, p=0.028$ ) and marginally with IPNIF( $r=-0.18, p=0.071$ ). VAS-NO correlated with PNIF( $r=-0.29, p=0.0034$ ), IPNIF( $r=-0.26, p=0.0097$ ) and marginally with rPNIF( $r=-0.16, p=0.11$ ) and 4PR( $r=0.2, p=0.052$ ). Dividing patients with SNOT-22>22 and<22, PNIF resulted slightly lower in the former group( $p=0.078$ ). Dividing patients with VAS-NO>5 and <5, PNIF resulted lower( $p=0.009$ ) and 4PR higher( $p=0.013$ ) in the former group.

**Conclusions:** 4-PR, AR and PNIF roughly correlate with each other but PNIF shows the best correlation with symptom scores and should be widely available in clinical practice.

**Key words:** 4-Phase Rhinomanometry, Acoustic Rhinometry, PNIF, SNOT-22, VAS-NO

### Literature:

- Rimmer, J. et al. European position paper on diagnostic tools in rhinology. *Rhinology* 2019;57(Suppl S28):1-41.
- Yepes-Nuñez, J.J. et al. Assessment of nasal obstruction: correlation between subjective and objective techniques. *Allergol Immunopathol (Madr)* 2013;41:397-401.
- Vogt, K. et al. The new agreement of the international RIGA consensus conference on nasal airway function tests. *Rhinology* 2018;56:133-43.
- Ottaviano, G. & Fokkens, W.J. Measurements of nasal airflow and patency: a critical review with emphasis on the use of peak nasal inspiratory flow in daily practice. *Allergy* 2016 Feb;71:162-74.



201913

## Clinical significance of Immunoglobulin E responses to staphylococcal enterotoxin A in patients with nasal polyposis

**Aleksandra Aleksić**, Mirjana Gnjatić, Zorica Novaković, Nataša Guzina Golac

*ENT Department, University Clinical Centre of the Republic of Srpska, Bosnia and Herzegovina*

*CRS - diagnosis and investigations 2, Building M1 Room Σ2, Sept 28, 10.15*

**Background:** Recent researches have showed that *Staphylococcus aureus* enterotoxins might be associated with inflammatory mucosal changes seen in CRSwNP. The aim of this study was to determine the prevalence of specific IgE to *Staphylococcus aureus* enterotoxin A (SEA-IgE) in the serum from CRSwNP patients and their involvement concomitant presence of asthma.

**Methods:** The study group consisted of 70 patients, 32 with proven CRSwNP and no asthma, 13 with proven CRSwNP and asthma, and 25 healthy control. Detailed clinical history, clinical examination, skin prick test were performed. The levels of total IgE and SEA-IgE were obtained using ImmunoCAP assays.

**Results:** Comparing the patients of CRSwNP with asthma group and CRSwNP without asthma group, the patients with asthma had greater endoscopic score and had more prominent sinus radiological changes than those without asthma. Values of SEA-IgE were significantly higher in group with nasal polyps than in control group. The presence of SEA-IgE antibodies were not associated with the presence of asthma.

**Conclusion:** Serum SEA specific IgE values were significantly higher in patients with CRSwNP than in the control group. This study did not find the significant higher level of serum SEA specific IgE in patients with CRSwNP and asthma.

**Key words:** chronic rhinosinusitis, nasal polyps, *Staphylococcus aureus* exotoxins, asthma.

202016

A retrospective audit comparing epistaxis management in a tertiary unit to the UK National ENT Trainee Research Network (INTEGRATE) Epistaxis audit.

M. Baldry<sup>1</sup>, P. Deekonda<sup>1</sup>, H. Jones<sup>1</sup>

<sup>1</sup>Department of Otolaryngology, University Hospital Southampton, UK.

*Epistaxis and HHT 1, Building M1 Room Σ4, Sept 28, 11.45*

**Background** :Epistaxis is the most common ENT emergency. The 2016 INTEGRATE study audited management of patients admitted with epistaxis in the UK. We compared current practice with this large, prospective study.

**Methodology**:Notes of patients admitted with epistaxis from January-June 2019 were retrospectively reviewed.

**Results** :Male:female ratio (1.41:1 vs 1.27:1), median age (76 vs 73) and comorbidities were similar in our audit and INTEGRATE.

Some management practices differed: (1) Initial assessment was performed more frequently by middle-grade doctors (50.96% vs 9.54%), (2) packing prior to initial ENT review was more common (66.35% vs 46.17%), (3) cautery was performed more frequently (75% vs 32.53%), (4) antithrombotics were more frequently held (70% vs 45%).

Mean length of stay was 1.61 days.

**Conclusions**:We have highlighted some differences in practice. Grade of doctor at initial review may affect management, such as increased chemical/electrocautery rates, but our length of stay was comparable. Prior packing likely reflects the geography of our catchment area. Antithrombotics were held more frequently than recent guidance advises. This audit forms part of a QIP to standardise our epistaxis care and second cycles will be completed.

**Key Words**:Epistaxis, cautery, packing, surgery

202017

A retrospective audit comparing epistaxis management in a tertiary unit to the 2017 British Rhinological Society (BRS) consensus recommendations.

M. Baldry<sup>1</sup>, P. Deekonda<sup>1</sup>, H. Jones<sup>1</sup>

*Department of Otolaryngology, University Hospital Southampton, UK.*

*Epistaxis and HHT 1, Building M1 Room Σ4, Sept 28, 11.45*

**Background :**Epistaxis is a common ENT emergency associated with significant morbidity. We audited our current practice against the 2017 British Rhinological Society (BRS) guidelines.

**Methodology:**Notes of patients admitted with epistaxis over a 6-month period (January-June 2019) were retrospectively reviewed.

**Results :**104 records were analysed. In line with BRS guidelines, cautery was used in the majority of cases (75%), however, the majority utilised silver nitrate instead of electrocautery ( $n=72$ , 92.31% vs  $n=13$ , 16.67%). When packs were inserted prior to review, only 42.03% ( $n=29$ ) were removed within 24 hours. Contrary to guidance, warfarin ( $n=11$ , 78.6%), direct oral anticoagulants (DOACS) ( $n=20$ , 69%) and antiplatelets ( $n=9$ , 53.0%) were held/alterd in the majority of cases.

**Conclusions:**Although largely compliant with the BRS guidance, we have identified several points for improvement in our centre:

We can increase the first-line use of cautery, in particular electrocautery

Removal of packs within 24 hours could be improved, which may allow for reduced length of stay.

Routine cessation of antiplatelets/anticoagulants will be reviewed, depending on patient comorbidities/haemodynamic status.

A prospective, second audit of these areas is scheduled.

**Key words:**Epistaxis, cautery, packing, surgery

202035

## External, endonasal or combined approach in the management of diverse frontal sinus pathology

Hristo K. Zlatanov<sup>1</sup>, Nadya V. Georgieva<sup>1</sup>, Anastasiya K. Korkova<sup>1</sup>

<sup>1</sup>ENT department, Military Medical Academy – Sofia, Bulgaria

*CRS - surgical management 3, Building M2 CR3, Sept 28, 10.15*

**Background:** Treatment of the frontal sinus pathology has proved surgically challenging even for the most experienced surgeon due to variable anatomy, difficult intranasal endoscopic access, close proximity to vital structures and predilection for recurrence, scarring and stenosis.

**Methodology/Principal:** Retrospective analysis of the management of frontal sinus pathology in our department in the past 5 years was conducted. Demographic data, symptoms, indications, different surgical approach, complications, recurrences and outcomes were recorded.

**Results:** Since 2015 we have treated 30 patients with frontal sinus pathologies. Patient age ranged between 18 and 68 years. 21 of them were male and 9 female. 25 of them underwent only endonasal surgery and 5 of them underwent the combined external and endonasal approach. From the patients who underwent combined approach 2 were primary and 3 revision procedures. Follow –up period was 12 months. Complications were observed in 4 patients and recurrence - in 2 of the patients treated with combined access. Postoperatively, symptoms resolved in 24 patients and improved in 6 patient.

**Conclusions:** Endoscopic approach has revolutionized frontal sinus surgery and has become the standard approach to frontal sinus diseases. Combined approach procedures are usually reserved for patients with absent or distorted intranasal landmarks, failed endoscopic approaches, complicated frontal sinusitis and evidence of lateral disease or posterior table erosion.

**Key words:** frontal sinus, combined approach, endonasal surgery

### Literature

1. Fokkens W.J., Lund V.J. , Hopkins C. et al. European Position Paper on Rhinosinusitis and Nasal Polyps 2012 Rhinology. 2012 Suppl. 23: 1-298, 2012
2. Sharma R, Rimmer J, Hopkins C. Surgical interventions for chronic rhinosinusitis with nasal polyps. Cochrane Library Syst Rev. 2014;11:CD006990. doi:10.1002/14651858.CD006990.pub2
3. Gleeson M., Browning G., Burton M., Clarke R. Scott-Brown's Otorhinolaryngo logy, Head and Neck Surgery, 7th Edition, 2008, Vol.2
4. Cummings CW, Flint PW, Haughey BH et al. Cummings Otolaryngology: Head & Neck Surgery, 4th ed., 2005
5. Lalwani AK. Current Diagnosis & Treatment: Otolaryngology Head and Neck Surgery, 2nd edition. 2008



202077

## Retrospective study of patients with lacrimal obstruction that underwent dacryocystorhinostomy

**J. Rito, M<sup>1</sup>.** Melo, N. Mendes<sup>1</sup>, P. Henriques<sup>1</sup>, F. Freire<sup>1</sup>

<sup>1</sup>*Serviço de Otorrinolaringologia, Hospital Professor Doutor Fernando Fonseca, Amadora, Lisboa, Portugal*

*Lacrimal Surgery 1, Building M1 Room Σ4, Sept 27, 11.45*

**Background:** Endoscopic dacryocystorhinostomy (DCR) is a surgical technique indicated in the treatment of symptomatic cases of distal lacrimal obstruction. It consists of opening the tear sac directly into the nasal cavity, representing an effective alternative to external DCR. We analyze the results of endoscopic DCR and evaluate the efficacy in the treatment of obstruction of the nasolacrimal pathway, factors of success and relapse.

**Methodology/Principal:** Retrospective analysis of clinical processes of patients undergoing endoscopic dacryocystorhinostomy between 2012 and 2020. Cases with a follow-up of less than 6 months, absence of dacryocystography or computed tomography of the perineal sinuses were excluded. Statistical analysis using the IBM SPSS Statistics 23.0 software.

**Results:** Fifty-six patients were included, 13 males and 43 females, mean age 63.1 years. All interventions were performed under the same surgical technique. The success of endoscopic DCR was 84.6%. The early extrusion (<3 months) of the silicone tubes was associated with a 100% recurrence. There was a statistically significant association between the permanence time of the tubes and the recurrence ( $p = 0.018$ ). No statistically significant difference was found between the mean age and the existence of complications or relapse.

**Conclusions:** Endoscopic DCR is a safe and proven high-efficiency surgical technique for the treatment of distal obstructions of the nasolacrimal pathway. The use of silicone tubes and their ideal permanence time remains controversial in the literature.

**Key words:** dacryocystorhinostomy, nasolacrimal, endoscopic, treatment, surgery

## Does the insertion type of the uncinate process correlate to the development of Frontal Sinus Mucocoeles?

**Tiago Mendes Chantre**, Mafalda Silva Barroso<sup>1</sup>, Bernardo Carvalho Araújo<sup>1</sup>, João Jacinto<sup>2</sup>, Catarina Marques<sup>3</sup>, Ilídio Gama<sup>1</sup>, Ezequiel Barros<sup>1</sup>

<sup>1</sup>Department of Otorhinolaryngology, Head and Neck Surgery, Centro Hospitalar Universitário de Lisboa Central, Lisbon, Portugal, <sup>2</sup>Department of Neuroradiology, Centro Hospitalar Universitário de Lisboa Central, Lisbon, Portugal, <sup>3</sup>Department of Quantitative Methods for Management and Economics, IBS, Lisbon, Portugal

*Imaging and investigations 1, Building M1 Room S4, Sept 29, 11.45*

**Background:** The frontal sinus drainage pathway is formed by either the ethmoid infundibulum or the middle meatus, which depends on the superior insertion of the uncinate process. According to Landsber & Friedman there are 6 types of superior uncinate process insertion. The aim of this study is to find a correlation between the uncinate process insertion type and the development of frontal sinus mucocoeles.

**Methodology/Principal:** Fifty sinus CT scans were analyzed. Exclusion criteria were previous nasal surgeries, malignancy, polyposis and an insufficient image quality. The superior insertions of the uncinate process were analyzed according to the Landsber & Friedman classification. The results were tabulated and analyzed using SPSS 25.0.

**Results:** The analysis revealed type 1 insertion in 6% of the CT scans, type 2 in 32%, type 3 in 26%, type 4 in 0%, type 5 in 28% and type 6 in 8%. Despite 44% of the CT scans with frontal sinus mucocoele showing a type 2 insertion of the uncinate process, both the Chi-Square test and the Cramer's V test showed no statistical significance ( $p > 0,05$ ). The logistic regression also showed no correlation.

**Conclusions:** The insertion of the uncinate process is unlikely to influence the development of frontal sinuses mucocoeles.

**Key words:** Uncinate Process, Frontal sinus, Mucocoele

## THE POSITION OF OBJECTIVE DIAGNOSIS OF NASAL BREATHING DISORDERS WHEN CHOOSING TREATMENT TACTICS

**Budkovaia Marina, M.D., scientific**<sup>1</sup>, Artemyeva Elena<sup>2</sup>

<sup>1</sup>An employee of the Department of Development and Implementation of High-tech Methods of Treatment of St. Petersburg, Research Institute of Ear, Throat and Speech, Saint Petersburg, Russia. <sup>2</sup>resident at the St. Petersburg Research Institute of Ear, Throat and Speech.

*Rhinology – miscellaneous 4, Building M1 Room Σ1, Sept 27, 14.45*

**Background:** To date, an objective assessment of the nasal breathing function and timely identification of the main causes of nasal obstruction is a necessary condition for choosing the optimal treatment strategy for patients with subjective nasal obstruction and concomitant pathology of the hearing organ.

**Materials and methods:** 109 patients with subjective complaints of difficulty in nasal breathing were examined. The examination included: VAS and NOSE questionnaire, otorhinolaryngological examination, nasal endoscopy, CT of the paranasal sinuses, and computer simulation of air flows in the nasal cavity. The objective assessment of the function of nasal breathing included the rhinomanometry, rhinoresistometry, acoustic rhinometry and long-term rhinometry and the nasal provocation test.

**Results:** 35(39.8%) of the patients previously operated for correction of intranasal structures were found to have objective impairment of nasal breathing, mainly of a mild degree due to oedema of the nasal mucosa. Of these, 4 (11.4%) of the patients had the positive result of the nasal provocation test. Repeated surgical treatment was recommended for 5 (13.7%) of the patients with a pronounced degree of nasal obstruction. In 6 (3.5%) of the patients with unsatisfactory functional results of reconstructive hearing-improving operations, a moderate degree of nasal breathing disturbance was detected from the same side as the operated ear, requiring a correction of intranasal structures.

The remaining 68 (62.4%) patients without previous surgical treatment had a high and moderate degree of nasal obstruction was established almost equally as a result of the structural and functional component. In this regard, this group underwent surgical treatment. Only 7(6.4% of the total number of examined patients) were found to have no aerodynamic disturbances during nasal flow movement.

**Conclusions.** A comprehensive analysis of the nasal breathing function is important when examining patients with complaints of nasal breathing difficulties. Furthermore, it is an important component at the planning stage of conservative or surgical treatment to achieve the most stable functional result.

**Key words:** nasal breathing, obstruction, rhinomanometry, surgical treatment, flow



202116

## Malignant mucosal melanoma arising from the right maxillary sinus: a case report of potentially deadly unilateral conductive hearing loss with literature review

V. Blackabey<sup>1</sup>, O. Kenyon<sup>1</sup>, R. Talwar<sup>1</sup>

<sup>1</sup>Luton and Dunstable University Hospitals, Lewsey road, Luton, LU4 0DZ

*Sinonasal malignancy 1, Building M1 Room Σ3, Sept 27, 14.45*

**Background:** Sinonasal melanoma is a rare tumour with a poor prognosis with high rates of loco-regional recurrence and distant metastasis [1,2,4].

With ongoing advances in medical technology we discuss an unusual presentation of sinonasal melanoma and review current literature regarding management and future developments.

**Methodology/Principal:** Patient presentation, findings and investigations (including imaging and clinical photographs) was used for the case report as well as a literature review of current research.

**Results:** Current literature has shown no significant difference in survival between surgery and combined chemoradiotherapy [1]. This may be due to late presentation and the high risk of reoccurrence/distant metastasis [1]. Optimisation of treatment of distant metastasis and reoccurrence is an important factor in survival [1].

Immunotherapy has been shown to improve survival in those with metastatic mucosal melanoma [3]. However data is limited due to the small sample size and requires further research [4].

**Conclusions:** Surgery with curative intent is the current aim of treatment however leads to severe functional loss [2,4].

Our case highlights the importance of a thorough clinical history and examination. It also describes the use of FESS to obtain histological diagnosis whilst debulking the tumour conferring symptomatic relief.

Non-surgical interventions, particularly, immunotherapy may guide future management.

**Key words:** malignant mucosal melanoma, sinonasal tumour

### Literature

1. Gore, MR and Zanation, AM. Survival in Sinonasal Melanoma: A Meta-Analysis. Journal of Neurological Surgery. Part B, Skull Base 2012; 73(3):157-162.
2. Paleri, V. Roland, N. Head and Neck Cancer: United Kingdom National Multidisciplinary Management Guidelines. Journal of Laryngology and Otology 2016; 130(S2): 1-230.
3. Romano, A. Iaconetta, G. Pansini, A. Mascolo, M. Cieri, M. Abbate, V. Salzano, G. Dell'Aversana Orabona, G. Califano, L. Sinonasal mucosal melanoma extended to Nose Bridge: A one-time reconstruction treatment report. Oral and Maxillofacial surgery cases 2018; 4: 1-5.
4. Gilain, L. Houette, A. Montalban, A. Mom, T. Saroul, N. Mucosal melanoma of the nasal cavity and paranasal sinuses. European Annals of Otorhinolaryngology, Head and Neck diseases 2014; 131: 365-369.
5. Jangard, M. Hansson, J. Ragnarsson-Olding, B. Primary sinonasal malignant melanoma: a nationwide study of the Swedish population, 1960-2000. Rhinology 2013; 51(1): 22-30.

## Review of Anaesthetic Considerations for Paediatric Endoscopic Sinus Surgery

Agarwal M<sup>1</sup>, Rachmanidou A<sup>1</sup>, **Gupta A<sup>1</sup>**, Mohan S<sup>1</sup><sup>1</sup>University Hospital Lewisham, Lewisham High Street, London, United Kingdom SE13 6LH*Paediatric rhinology 3, Building M1 Room Σ1, Sept 29, 11.45*

**Background:** Endoscopic sinus surgery is a common procedure in the adult population, but is less commonly performed in children. Consequently, data investigating the anaesthetic management of paediatric patients undergoing endoscopic sinus surgery are scarce. The aim of this review was to examine anaesthetic practice in our institution for children undergoing endoscopic sinus surgery, and to establish how this differs from adult practice.

**Methodology:** All patients aged 18 years or younger undergoing sinus surgery at our hospital between August 2018 to February 2020 were included. Data were collected retrospectively from patient case records and descriptive analyses were performed.

**Results:** 24 patients were included. The mean age was 14.9 years. 1 child had an inhalational induction of anaesthesia. Maintenance of anaesthesia was by total intravenous anaesthesia in 3 patients, and a mixture of sevoflurane and intravenous opioid infusion in 2 patients. The remaining 19(79%) had volatile maintenance. 6 patients were intubated, 18(75%) were managed with a laryngeal mask. The use of Moffat's solution was documented in 4(16.7%) patients.

**Conclusions:** This review demonstrates how anaesthetic management of children undergoing endoscopic sinus surgery differs from adult practice. Further work is needed to establish the surgical implications of these differences. This data adds to the paucity of relevant literature available.

**Key words:** Paediatric anaesthesia, paediatric sinus surgery, FESS, Moffats

## Literature

1. Tan PY, Poopalalingam R. Anaesthetic Concerns for Functional Endoscopic Sinus Surgery. *Proceedings of Singapore Healthcare*, 2014; 23(3), 246-253
2. Danielsen A, Gravingsbraten R, Olofson J. Anaesthesia in endoscopic sinus surgery. *Eur Arch Otorhinolaryngol*. 2003 Oct; 260(9): 481-6

## Fungal rhinosinusitis-Case reports with emphasis on Invasive versus Non-invasive type, presentation, diagnosis, management and outcome

**DIACONU Elena Teodora<sup>2</sup>**, BEJENARU Paula<sup>2</sup>, ANTONIE Catrinel<sup>2</sup>, ARJOCA Elena<sup>2</sup>, CÎRSTEA Anca<sup>2</sup>, CONDEESCU Mihnea<sup>2</sup>, CURCĂ Claudiu<sup>2</sup>, DIMCEA Alisa<sup>2</sup>, MITRAN Denisa<sup>2</sup>, MUNTEANU Gloria<sup>2</sup>, NEDELICU Ruxandra Ioana<sup>2</sup>, NICOLAESCU Alexandru<sup>2</sup>, NIȚU Liliana<sup>1,2</sup>, OTHMAN Amer<sup>2</sup>, POPESCU Bogdan<sup>1,2</sup>, POPA Teodora<sup>2</sup>, RUJAN Simona Andreea<sup>2</sup>, SIREȚEANU Luiza Maria<sup>2</sup>, TAHER Bianca Petra<sup>2</sup>, BERTEȘTEANU Șerban Vifor Gabriel<sup>1,2</sup> and GRIGORE Raluca<sup>1,2</sup>.

<sup>1</sup>U.M.F. „Carol Davila” Bucharest – General medicine faculty – ENT Department (Romania)

<sup>2</sup>„Colțea” Clinical Hospital Bucharest – ENT Department (Romania)

*CRS - surgical management 2, Building M2 CR3, Sept 27, 10.15*

Fungal rhinosinusitis is a general term used to define a wide range of pathological responses, including invasive, chronic, granulomatous, and allergic disease. The prevalence of fungal sinus disease is thought to have been increasing in recent decades. This may be due to increased awareness, antibiotic overuse and increased use of immunosuppressant medications. Usually it is blamed for causing most cases of chronic rhinosinusitis, but it can also have an acute presentation which, although rare, is important because of its aggressive course and high mortality rates (from 50% up to 80%).

I will present two cases in which fungal rhinosinusitis had its two opposite clinical presentations. One patient who had no symptoms presented to the Clinic after an incidental finding on a radiography done for the teeth. The other patient known with several comorbidities presented with a poor general condition and had a fulminant course of the disease. The cases will emphasise on the important clinical findings, diagnosis algorithm, surgical management and outcome.

The role of Fungi is clearly important to ENT surgeons, a prompt diagnosis and therapeutic approach are very important for a good outcome.

**Key Words:** fungal rhinosinusitis, invasive, non-invasive, fungi.

Literature: Invasive and Non-Invasive Fungal Rhinosinusitis-A Review and Update of the Evidence, **Peter George Deutsch, Joshua Whittaker and Shashi Prasad** ; Otorhinolaryngology. Head Neck Surgery 2018, Current understanding of allergic fungal rhinosinusitis. World J. Tyler M.A., Luong A.U.; Fungal Rhinosinusitis: A Categorization and Definitional Schema Addressing Current Controversies, **Arunaloke Chakrabarti, David W. Denning, Berrylin J. Ferguson, Jens Ponikau, Walter Buzina, Hirohito Kita, Bradley Marple, Naresh Panda, Stephan Vlaminc, Catherine Kauffmann-Lacroix, Ashim Das, Paramjeet Singh, Saad J. Taj-Aldeen, A. Serda Kantarcioglu, Kumud K. Handa, Ashok Gupta, M. Thungabathra, Mandya R. Shivaprakash, Amanjit Bal, Annette Fothergill and Bishan D. Radotra**



**Athanasia Printza**<sup>1</sup>, Marina Boziki<sup>2</sup>, Constantinos Valsamidis<sup>1</sup>, Christos Bakirtzis<sup>2</sup>, Nikolaos Grigoriadis<sup>2</sup>, Jannis Constantinidis<sup>1</sup>

<sup>1</sup>*1<sup>st</sup> Otolaryngology Department, Medical School, Aristotle University of Thessaloniki, AHEPA Hospital, Greece*

<sup>2</sup>*2<sup>nd</sup> Neurology Department, Medical School, Aristotle University of Thessaloniki, AHEPA Hospital, Greece*

*Smell and taste 3, Building M2 CR3, Sept 27, 14.45*

**Background:** We investigated if smell dysfunction in multiple sclerosis (MS) can be used as a disease progression marker.

**Methodology:** Cross-sectional, case-control prospective study of 171 participants, 117 MS patients and 54 controls (age and sex matched), who reported smell, taste, and nasal breathing, and completed questionnaires for nasal obstruction (NOSE), nasal-symptoms-QoL (SNOT-22), and olfaction-associated QoL (QOD). The smell was assessed with the “Sniffin’ sticks” (odour threshold (OT), discrimination (OD), and identification (OI), TDI). We recorded the disease characteristics, cognitive and emotional status. We compared the patients’ smell scores to the controls’, evaluated the nasal-function-related confounding factors, and the nasal-symptoms/olfaction-associated QoL. We examined correlations of the hyposmia to the MS type, Expanded Disability Status Scale correlated negatively (EDSS), disease duration, cognitive and emotional status.

**Results:** The OD, OI, and TDI scores of the patients were significantly lower than the controls’ (OD:  $12.19 \pm 0.23$  vs.  $13.35 \pm 0.31$ ,  $p=0.004$ ; OI:  $14.06 \pm 0.16$  vs.  $14.72 \pm 0.15$ ,  $p=0.002$ ; TDI:  $32.92 \pm 0.47$  vs.  $35.12 \pm 0.57$ ,  $p=0.006$ ). Twenty-two patients (18.8%) were hyposmic. Hyposmia correlated with EDSS and disease duration. The EDSS score correlated negatively with OD and TDI (Pearson’s  $r=-0.299$ ,  $p=0.001$ ;  $r=-0.242$ ,  $p=0.01$ , respectively). The disease duration correlated negatively with OD, OI and TDI ( $r=-0.305$ ,  $p=0.001$ ;  $r=-0.253$ ,  $p=0.008$ ;  $r=-0.3$ ,  $p=0.001$ , respectively).

**Conclusions:** The olfactory function changes in MS in accordance to disease progression.

**Key words:** Smell, olfaction, multiple sclerosis, olfactory identification, nasal symptoms

#### Literature

1. Goektas O, Schmidt F, Böhner G, Erb K, Ludemann L, Dahlslett B, Harms L, Fleiner F. Olfactory bulb volume and olfactory function in patients with multiple sclerosis. *Rhinology*, 2011. 49(2): p. 221-6.
2. Kobal G, Hummel T, Sekinger B, Barz S, Roscher S, Wolf S. “Sniffin’ sticks”: screening of olfactory performance. *Rhinology*, 1996. 34:222–226
3. Oleszkiewicz A, Schriever VA, Croy I, Hähner A, Hummel T. Updated Sniffin' sticks normative data based on an extended sample of 9139 subjects. *Eur Arch Otorhinolaryngol*, 2019(276): p. 719-28.
4. Bsteh G, Hegen H, Ladstätter F, Berek K, Amprosi M, Wurth S, Auer M, Di Pauli F, Deisenhammer F, Reindl M, Berger T, Lutterotti A. Change of olfactory function as a marker of inflammatory activity and disability progression in MS. *Mult Scler Relat Disord*, 2019. 25(2): p. 267-274.

**Adam Kesner<sup>1</sup>**, Zuzana Balatkova<sup>1</sup>, Jan Plzak<sup>1</sup>

Department of Otorhinolaryngology and Head and Neck Surgery, 1st Faculty of Medicine, Charles University, Faculty Hospital Motol, Prague, Czech republic

*Rhinology – miscellaneous 3, Building M1 Room Σ1, Sept 27, 11.45*

**Background:** Endoscopic endonasal surgery has been developing in the last decade, especially in the indication of operations for malignant or benign sinus tumors. Along with the increasing number of FESS surgeries, the number of surgeries for complications such as postoperative synechiae and iatrogenic mucocoele is increasing.

**Methodology:** The group included 24 patients who underwent endoscopic endonasal surgery or combined approach at the Dept. of Otorhinolaryngology and Head and Neck Surgery of the 1st Faculty of Medicine of Charles University and Motol University Hospital for symptomatic sinus mucocoele in 2016-2019. Evaluation of postoperative results is focused on patients who have been shown to have iatrogenic mucocoele.

**Results:** In addition to finding an increasing number of operations for mucocoele of paranasal sinuses in recent years, there is a clear tendency to grow iatrogenic mucocoeles in comparison with mucocoele traumatic or associated with anatomical variations (deviation of the septum, nasal polyposis, chronic rhinosinusitis)

**Conclusions:** The increasing incidence of iatrogenically produced mucocoeles of paranasal sinuses is a call for careful adherence to the principles of functional endonasal surgery.

**Keywords:** iatrogenic mucocoele, paranasal sinuses, synechiae, endoscopic endonasal surgery, chronic rhinosinusitis

**Literature:** 1. Mucocoele development after endoscopic sinus surgery for nasal polyposis: A long-term analysis. **Benkhatar H<sup>1</sup>, Khettab I, Sultanik P, Laccourreye O, Bonfils P., Ear Nose Throat J.** 2018 Sep;97(9):284-294., **Ear Nose Throat J.** 2018 Sep;97(9):284-294.

2. Facial mucocoele and brain complications: diagnostic priorities. **Sigüenza González R<sup>1</sup>, Pérez Fernández S<sup>1</sup>, Jiménez Cuenca I<sup>1</sup>, Castañeda Cruz C<sup>1</sup>, BJR Case Rep.** 2019 Nov 15;5(4):20190006. doi: 10.1259/bjrcr.20190006. eCollection 2019 Dec.

3. Frontoethmoidal mucocoele presenting with ocular manifestations. **Roncone DP<sup>1</sup>. Clin Exp Optom.** 2019 Nov 26. doi: 10.1111/cxo.13006.

202257

A cohort study evaluating Drug Induced Sedation Endoscopy (DISE) as selection tool for choice of treatment in 300 consecutive patients with obstructive sleep apnea

**E.K. Kiær<sup>1</sup>**, C. von Buchwald<sup>1</sup>, P.J. Jennum<sup>2</sup>

<sup>1</sup>Danish Center for Sleep Surgery, Department of Oto-rhino-laryngology Head and Neck Surgery, Copenhagen University Hospital, Copenhagen, The Capital Region, Denmark; <sup>2</sup>Danish Center for Sleep Medicine, Department of Clinical Neurophysiology, Copenhagen University Hospital, Glostrup, The Capital Region, Denmark

*Snoring and OSA 1, Building M2 CR2, Sept 28, 14.45*

**Background:** The golden standard of treatment for obstructive sleep apnea is continuous positive airway pressure (CPAP). Unfortunately, up to 50% of patients do not adhere to this treatment. Surgery as an alternative has been criticized for poor patient selection to potentially harmful procedures. We wanted to investigate if patient selection by Drug Induced Sedation Endoscopy (DISE) with sedation based on the Nurse Administered Propofol Sedation (NAPS) regimen would improve surgical outcome when compared to the traditional method for patient selection before surgery.

**Methodology/Principal:** 300 consecutive patients with OSA referred to the Danish Center for Sleep Surgery for evaluation of possible alternatives to CPAP treatment.

**Results:** In this study we looked at: how many of the referred patients were selected for surgery, which procedures were recommended, which treatments were recommended for the remaining non-surgical patients, and how patients were distributed between groups. We look at surgical outcome based on AHI and patient reports, and how many required CPAP treatment postoperatively.

Data-analysis is ongoing and will be ready for the conference.

**Conclusions:** Preliminary results show implications that DISE is a valid selection tool for sleep surgery. This method of selection should be considered in all surgical sleep centers.

**Key words:** DISE, sleep-endoscopy, obstructive sleep apnea, sleep-surgery

#### Literature

1. Jennum P, Folksen J, Andreasen J. *Diagnostik Og Behandling Af Obstruktiv Søvnåpnø - En Medicinsk Teknologivurdering*. Vol 6.; 2006.
2. Sundaram S, Lim J, Lasserson TJ. Surgery for obstructive sleep apnoea in adults ( Review ). *Cochrane Collab*. 2013;(4):1-76.
3. Kezirian EJ, Weaver EM, Yueh B, et al. Incidence of serious complications after uvulopalatopharyngoplasty. *Laryngoscope*. 2004;114(3):450-453. doi:10.1097/00005537-200403000-00012

202273

## Eosinophilic angiocentric fibrosis: a series of eight cases

**Alanin MC<sup>1</sup>**, Harun N<sup>2</sup>, Collins L<sup>3</sup>, Odell E<sup>3,4</sup>, Hopkins C<sup>1</sup>.

<sup>1</sup> ENT, Guy's and St Thomas' NHS Foundation Trust, UK, London; <sup>2</sup> Faculty Dentistry, Universiti Teknologi MARA, Malaysia; <sup>3</sup> Head and Neck Pathology, Guy's and St Thomas' NHS Foundation Trust, UK, London; <sup>4</sup> King's College London

*Granulomatous diseases of the nose 1, Building M1 Room Σ2, Sept 28, 11.45*

**Background:** Eosinophilic angiocentric fibrosis (EAF) is recognized as a type of IgG4 related disease. It is a rare, locally destructive inflammatory condition of the upper respiratory tract including the nose and sinuses. The systemic involvement is unclear. The aim of the study was to analyze the clinical characteristics of EAF with a focus on ENT involvement and correlate with IgG4 immunohistochemistry.

**Methods:** Eight cases of EAF were retrospectively reviewed including clinical characteristics, diagnostic work up and demographic data and histopathology.

**Results:** We included eight patients (7 female). The mean age was 37 years (range 28-64). Seven patients had disease in the nasal cavity and one in the subglottic space. Clinically, EAF presented with ulceration or necrosis in three cases and swelling in five cases. Three patients were atopic, one had dermatitis and one arthralgia. No patients had lesions in other organ systems. Serum IgG and IgG4 were normal in the tested patients and in four patients was the IgG4/IgG ratio >40%. There was evidence of fibrosis and eosinophilia in all cases on histopathological examination and three demonstrated phlebitis.

**Conclusions:** AEF showed ENT involvement in all cases but no signs of systemic disease. IgG4 ratio is often low in EAF.

**Key words:** AEF, IgG4



## Chronic Rhinosinusitis in COPD: a prevalent but unrecognized comorbidity, which impacts HRQoL - A cross-sectional study

**Elisabeth Arndal**<sup>1</sup>, Anne Lyngholm Sørensen<sup>2</sup>, Therese Sophie Lapperre<sup>3</sup>, Nihaya Said<sup>3</sup>, Charlotte Riis Trampedach<sup>4</sup>, Kasper Aanaes<sup>1</sup>, Mikkel Alanin<sup>1</sup>, Karl Bang Christensen<sup>2</sup>, Vibeke Backer<sup>5</sup>, Christian von Buchwald<sup>1</sup>.

<sup>1</sup> Department of Otorhinolaryngology – Head and Neck Surgery and Audiology, Copenhagen University Hospital, Rigshospitalet, Denmark. <sup>2</sup> Section of Biostatistics, University of Copenhagen, Denmark. <sup>3</sup> Department of Respiratory Medicine, Bispebjerg Hospital, Denmark <sup>4</sup> Department of Radiology, Bispebjerg Hospital, Copenhagen University. <sup>5</sup> Centre for Physical Activity Research (CFAS), Rigshospitalet, Copenhagen University Hospital, Denmark.

*CRS - diagnosis and investigations 1, Building M1 Room E3, Sept 27, 10.15*

**Background:** COPD patients have multiple comorbidities impacting their mortality and quality of life. Unified airway disease is known from asthma, cystic fibrosis and primary ciliary dyskinesia but little is known about chronic rhinosinusitis (CRS) in COPD. **Methodology:** cross-sectional study of CRS in 222 COPD patients. Patients completed CAT, and SNOT22 questionnaires and CRS diagnosed according to EPOS; incl. nasal endoscopy, CT-sinus scan and a HRCT-thorax.

**Results:** 22.5% of COPD patients had CRS according to EPOS criteria and 82% of these were undiagnosed prior to the study. CAT, SNOT22 and SNOT22-nasal symptom sub scores were significantly higher in COPD patients with CRS compared with those without CRS and healthy controls. Multiple logistic regression analysis showed a trend towards, a male COPD patient who actively smoked, took inhaled steroids, had a high CAT and SNOT22\_nasal symptom sub scores was the most likely candidate for having CRS.

**Conclusions:** This is a large study of CRS in COPD and the only study diagnosing CRS according to EPOS; further supporting the unified airways in COPD. The SNOT22\_nasal symptoms subscale should be a standard COPD questionnaire and patients at risk should be referred for otorhinolaryngologic evaluation and treatment.

**Key words:** Unified airways, CRS, COPD, SNOT22, CAT, HRQoL

### Literature:

- 1) <https://www.who.int/respiratory/copd/burden/en/>
- 2) Håkansson K, Bachert C, Konge L, et al. Inflammation in Chronic Rhinosinusitis with Nasal Polyps and Asthma: The United Airways Concept Further Supported. *PLoS One*, 2015;10(7):e0127228. doi: 10.1371/journal.pone.0127228.
- 3) Guilemany JM, Angrill J, Alobid I, et al. United airways again: high prevalence of rhinosinusitis and nasal polyps in bronchiectasis. *Allergy*, 2009;64:790–797.
- 4) Hansen SK, Rau MH, Johansen HK, et al. Evolution and diversification of *Pseudomonas aeruginosa* in the paranasal sinuses of cystic fibrosis children have implications for chronic lung infection. *ISME J*, 2012;6(1):31-45.
- 5) Alanin MC, Aanaes K, Høiby N, et al. Sinus surgery can improve quality of life, lung

infections, and lung function in patients with primary ciliary dyskinesia. *Int Forum Allergy Rhinol*, 2017;7(3):240-247.

- 6) Hastan D, Fokkens WJ, Bachert C, et al. Chronic rhinosinusitis in Europe an underestimated disease. A GA<sup>2</sup>LEN study. *Allergy*, 2011;66(9):1216-23.
- 7) Blackwell DL, Lucas JW, Clarke TC. Summary health statistics for U.S. adults: national health interview survey, 2012. *Vital Health Stat 10*, 2014;(260):1-161.
- 8) Chen Y, Dales R, Lin M. The epidemiology of chronic rhinosinusitis in Canadians. *Laryngoscope*, 2003;113(7):1199-205.
- 9) Shashy RG, Moore EJ, Weaver A. Prevalence of the chronic sinusitis diagnosis in Olmsted County, Minnesota. *Archives of otolaryngology-head & neck surgery*, 2004;130(3):320-3.
- 10) Sahlstrand-Johnson P, Ohlsson B, Von Buchwald C, et al. A multi-centre study on quality of life and absenteeism in patients with CRS referred for endoscopic surgery. *Rhinol*, 2011;49(4):420-8.
- 11) **Fokkens WJ, Lund VJ, Mullol J**, et al. European Position Paper on Rhinosinusitis and Nasal Polyps 2012. *Rhinol Suppl*, 2012;23(3):1-298.
- 12) Roberts NJ, Lloyd-Owen SJ, Rapado F, et al. Relationship between chronic nasal and respiratory symptoms in patients with COPD. *Respiratory Medicine*, 2003;97:909–914.
- 13) Hens G, Vanaudenaerde DM, Bullens DMA, et al. Sinonasal pathology in nonallergic asthma and COPD: united airway disease beyond the scope of allergy. *Allergy*, 2008;63:261–267
- 14) Huerta A, Donaldson GC, Singh R, et al. Upper Respiratory Symptoms Worsen over Time and Relate to Clinical Phenotype in Chronic Obstructive Pulmonary Disease. *Ann Am Thorac Soc*, 2015; 12(7):997–1004.
- 15) Hurst JR, Wilkinson TMA, Donaldson GC, et al. Upper airway symptoms and quality of life in chronic obstructive pulmonary disease (COPD). *Respiratory Medicine*, 2004;98:767–770.
- 16) Håkansson K, von Buchwald C, Thomsen SF, et al. Nonallergic rhinitis and its association with smoking and lower airway disease: A general population study. *Am J Rhinol Allergy*, 2001;25:25-29.
- 17) Chien CY, Tai SY, Wang LF, et al. **Chronic obstructive pulmonary disease predicts chronic rhinosinusitis without nasal polyps: A population-based study.** *Am J Rhinol Allergy*, 2015;29(3):e75-80.
- 18) Yang X, Xu Y, Jin J, et al. Chronic rhinosinusitis is associated with higher prevalence and severity of bronchiectasis in patients with COPD. *COPD*, 2017;12:655–662.

- 19) Kelemence A, Abadoglu O, Gumus C, et al. The Frequency of Chronic Rhinosinusitis/Nasal Polyp in COPD and Its Effect on the Severity of COPD. *COPD*, 2011;8:8–12.
- 20) Hopkins C, Gillett S, Slack R, et al. Psychometric validity of the 22-item Sinonasal Outcome Test. *Clin. Otolaryngol*, 2009;34:447–454.
- 21) Fokkens W, Desrosiers M, Harvey R, et al. **EPOS2020: development strategy and goals for the latest European Position Paper on Rhinosinusitis.** *Rhinology*. 2019;1;57(3):162-168.
- 22) Singh D, Agusti A, Anzueto A, et al. Strategy for the Diagnosis, Management, and Prevention of Chronic Obstructive Lung Disease: the GOLD science committee report 2019. *Eur Respir J*, 2019; 18;53(5). pii: 1900164. doi: 10.1183/13993003.00164-2019.
- 23) Fokkens WJ, Lund VJ, Hopkins C, et al. **European Position Paper on Rhinosinusitis and Nasal Polyps 2020.** *Rhinology*, 2020;58(Suppl S29):1-464.
- 24) Dejaco D, Riedl D, Huber A, et al. The SNOT-22 factorial structure in European patients with chronic rhinosinusitis: new clinical insights. *European Archives of Oto-Rhino-Laryngol*, 2019;276:1355–1365.
- 25) Jones PW, Harding G, Wiklund I, et al. Tests of the responsiveness of the COPD assessment test following acute exacerbation and pulmonary rehabilitation. *CHEST*, 2012;142(1):134-140.
- 26) Fletcher CM. The clinical diagnosis of pulmonary emphysema, an experimental study. *Proc R. Soc Med*, 1952;45:577-584.
- 27) Lange B, Thilsing T, Al-kalemji A, et al. Sino-Nasal Outcome Test 22, valideret for danske patienter. *Dan Med Bul*, 2011;58(2):A4235.
- 28) Lund VJ, Mackay IS. Staging in rhinosinusitis. *Rhinol*, 1993;107:183-4.
- 29) Buuren S. van, Groothuis-Oudshoorn K. Mice: Multivariate Imputation by Chained Equations in R. *Journal of Statistical Software*, 2011;45(3). Doi:10.18637/jss.v045.i03
- 30) **Hoffmans R, Wagemakers A, van Drunen C**, et al. Acute and chronic rhinosinusitis and allergic rhinitis in relation to comorbidity, ethnicity and environment. ***PLoS One***, 2018;13(2):e0192330. doi: 10.1371/journal.pone.0192330.
- 31) **Wang XD, Zheng M, Lou HF**, et al. An increased prevalence of self-reported allergic rhinitis in major Chinese cities from 2005 to 2011. ***Allergy***, 2016;71(8):1170-80.
- 32) **Stankiewicz JA.** Endoscopic and imaging techniques in the diagnosis of chronic rhinosinusitis. ***Curr Allergy Asthma Rep***, 2003;3(6):519-22.
- 33) **Holbrook EH, Brown CL, Lyden ER**, et al. Lack of significant correlation between rhinosinusitis symptoms and specific regions of sinus computer tomography scans. ***Am J Rhinol***, 2005;19(4):382-7.

- 34) Bachert C, Claey's SE, Tomassen P, et al. Rhinosinusitis and asthma: a link for asthma severity. *Curr Allergy Asthma Rep*, 2010;10(3):194-201.
- 35) **Håkansson K, Thomsen SF, Konge L**, et al. A comparative and descriptive study of asthma in chronic rhinosinusitis with nasal polyps. *Am J Rhinol Allergy*, 2014;28(5):383-7.
- 36) Van Zele T, **Claey's S**, Gevaert P, et al. Differentiation of chronic sinus diseases by measurement of inflammatory mediators. *Allergy*, 2006;61(11):1280-9.
- 37) Stanley PJ, **Wilson R, Greenstone MA**, et al. Effect of cigarette smoking on nasal mucociliary clearance and ciliary beat frequency. *Thorax*, 1986;41(7):519-23.
- 38) **Ito JT, Ramos D, Lima FF**, et al. Nasal Mucociliary Clearance in Subjects with COPD after smoking Cessation. *Respir Care*, 2015;60(3):399-405.
- 39) Yaghi A, Zaman A, Cox G, Dolovich MB. **Ciliary beating is depressed in nasal cilia from chronic obstructive pulmonary disease subjects.** *Respir Med*, 2012;106(8):1139-47.
- 40) Dransfield MT, **Wilhelm AM, Flanagan B**, et al. Acquired cystic fibrosis transmembrane conductance regulator dysfunction in the lower airways in COPD. *Chest*, 2013;144(2):498-506.
- 41) **Wu D, Bleier BS, Wei Y**. Current Understanding of the Acute Exacerbation of Chronic Rhinosinusitis. *Front Cell Infect Microbiol*, 2019;4(9):415.
- 42) Mallia P, **Message SD, Keadze T**, et al. An experimental model of rhinovirus induced chronic obstructive pulmonary disease exacerbations: a pilot study. *Respir Res*, 2006;6(7):116.
- 43) Sethi S, Murphy TF. **Infection in the pathogenesis and course of chronic obstructive pulmonary disease.** *N Engl J Med*, 2008;359(22):2355-65.
- 44) Hox V, **Maes T, Huvenne W**, et al. A chest physician's guide to mechanisms of sinonasal disease. *Thorax*, 2015;70(4):353-8.
- 45) Dewan NA, **Rafique S, Kanwar B**, et al. Acute exacerbation of COPD: factors associated with poor treatment outcome. *Chest*, 2000;117(3):662-71.
- 46) Hoggard M, Biswas K, Zoing M, et al. **Evidence of microbiota dysbiosis in chronic rhinosinusitis.** *Int Forum Allergy Rhinol*, 2017;7(3):230-239.
- 47) **Wang Z, Maschera B, Lea S**, et al. Airway host-microbiome interactions in chronic obstructive pulmonary disease. *Respir Res*, 2019;20(1):113-117.

## Olfactory function in the unified airways – odour identification in patients with Chronic Obstructive Pulmonary Disease

**Elisabeth Arndal**<sup>1</sup>, Anne Lyngholm Sørensen<sup>2</sup>, Karl Bang Christensen<sup>2</sup>, Kasper Aanæs MD, Ph.D.<sup>1</sup>, Vibeke Backer<sup>3</sup>, Thomas Hummel<sup>4</sup>, Christian von Buchwald<sup>1</sup>.

<sup>1</sup> Department of Otorhinolaryngology – Head and Neck Surgery and Audiology, Copenhagen University Hospital, Rigshospitalet, Denmark. <sup>2</sup> Section of Biostatistics, University of Copenhagen, Denmark. <sup>3</sup> Centre for Physical Activity Research (CFAS), Rigshospitalet, Copenhagen University Hospital, Denmark. <sup>4</sup> Smell & Taste Clinic, Department of Otorhinolaryngology, Technical University Dresden, Germany.

*Smell and taste 2, Building M2 CR2, Sept 27, 14.45*

**Background:** olfactory dysfunction and chronic obstructive pulmonary disease (COPD) impact health related quality of life, social interactions, morbidity and mortality but very little is known about olfaction in COPD. We tested odour identification in COPD patients.

**Methodology/Principal:** 135 COPD patients age 49-89 years were tested with Sniffin' Sticks Identification (SIT16) test. Patients were stratified according to age, COPD +/- active smoking AND +/- Chronic Rhinosinusitis (CRS) and COPD severity and compared with normative data from healthy controls.

**Results:** No difference in mean SIT16 scores for all COPD patients, regardless of subgroup, compared with healthy controls. A statistically significant higher percentage of anosmia was observed in the 61-80-year old COPD patients. This groups had a lower percentage of hyposmia and corresponding higher percentage of normosmia compared to controls. The same was true in all COPD subgroups except COPD+Smoking+CRS. There was no statistical difference in the distribution of anosmia, hyposmia and normosmia in the 49-60-year-old and >80-year-old age groups.

**Conclusions:** The largest study of odour identification and olfactory function in patients with COPD showing no difference in mean SIT16 scores but a higher prevalence of anosmia compared with healthy controls. This underlines the importance of asking about and testing olfactory function.

**Key words:** Olfaction, Sniffin' Sticks, unified airways, CRS, COPD

### Literature:

1. Hummel T, Whitcroft KL, Andrews P, Altundag A, Cinghi C, Costanzo RM, Damm M, Frasnelli J, Gudziol H, Gupta N, Haehne A, Holbrook E, Hong SC, Hornung D, Hüttenbrink KB, Kamel R, Kobayashi M, Konstantinidis I, Landis BN, Leopold DA, Macchi A, Miwa T, Moesges R, Mullol J, Mueller CA, Ottaviano G, Passali GC, Philpott C, Pinto JM, Ramakrishnan VJ, Rombaux P, Roth Y, Schlosser RA, Shu B, Soler G, Stjärne P, Stuck BA, Vodicka J, Welge-Luessen A. **Position paper on olfactory dysfunction.** Rhinol Suppl. 2017 Mar;54(26):1-30. Review.
2. Murphy C, Schubert CR, Cruickshanks KJ, Klein BE, Klein R, Nondahl DM. Prevalence of olfactory impairment in older adults. **JAMA.** 2002 Nov 13;288(18):2307-12.
3. Neuland C, Bitter T, Marschner H, Gudziol H, Guntinas-Lichius O. Health related and specific olfaction-related quality of life in patients with chronic functional

anosmia or severe hyposmia. **Laryngoscope**. 2011 Apr;121(4):867-72. doi: 10.1002/lary.21387. Epub 2011 Feb 4.

4. **McClintock MK, Bullivant S, Jacob S, Spencer N, Zelano B, Ober C.** Human body scents: conscious perceptions and biological effects. **Chem Senses**. 2005 Jan;30 Suppl 1:i135-7.
5. Wedekind C. A predicted interaction between odour pleasantness and intensity provides evidence for major histocompatibility complex social signalling in women. **Proc Biol Sci**. 2018 May 16;285(1878). pii: 20172714. doi: 10.1098/rspb.2017.2714.
6. Qazi JJ, Wilson JH, Payne SC, Mattos JL. **Association Between Smell, Taste, and Depression in Nationally Representative Sample of Older Adults in the United States.** *Am J Rhinol Allergy*. 2020 Jan 2:1945892419897217. doi: 10.1177/1945892419897217.
7. <https://www.who.int/respiratory/copd/burden/en/>
8. Arndal E, Sorensen AL, Lapperre TS, Said N, Trampedach CR, Aanaes K, Alanin MC, Christensen KB, Backer V, von Buchwald C. A cross-sectional study of Chronic Rhinosinusitis in COPD: a highly prevalent but neglected disease, which negatively impacts HR-QoL. (Submitted).
9. Yang X, Xu Y, Jin J, et al. Chronic rhinosinusitis is associated with higher prevalence and severity of bronchiectasis in patients with COPD. *COPD*. 2017;12:655–662.
10. **Nordén J, Grönberg AM, Bosaeus I, Forslund HB, Hulthén L, Rothenberg E, Karlsson J, Wallengren O, Slinde F.** Nutrition impact symptoms and body composition in patients with COPD. **Eur J Clin Nutr**. 2015 Feb;69(2):256-61.
11. Hurst JR, Wilkinson TM, Donaldson GC, Wedzicha JA. **Upper airway symptoms and quality of life in chronic obstructive pulmonary disease (COPD).** *Respir Med*. 2004 Aug;98(8):767-70.
12. **Brämerson A, Johansson L, Ek L, Nordin S, Bende M.** Prevalence of olfactory dysfunction: the Skövde population-based study. **Laryngoscope**. 2004 Apr;114(4):733-7.
13. Landis BN, Konnerth CG, Hummel T. A study on the frequency of olfactory dysfunction. **Laryngoscope**. 2004 Oct;114(10):1764-9.
14. Landis BN, Hummel T, Hugentobler M, Giger R, Lacroix JS. Ratings of overall olfactory function. **Chem Senses**. 2003 Oct;28(8):691-4.

15. **Hummel T, Sekinger B, Wolf SR, Pauli E, Kobal G.** Sniffin' sticks': olfactory performance assessed by the combined testing of odor identification, odor discrimination and olfactory threshold. **Chem Senses.** 1997 Feb;22(1):39-52.
16. Doty, R.L., Shaman, P., Kimmelman, C.P. and Dann, M.S. (1984) University of Pennsylvania Smell Identification Test: a rapid quantitative olfactory function test for the clinic. *Laryngoscope*, 94, 176–178
17. **Kobayashi M.** The Odor Stick Identification Test for the Japanese (OSIT-J): clinical suitability for patients suffering from olfactory disturbance. **Chem Senses**, 2005;30 Suppl 1:i216-7.
18. **Han P, Zang Y, Akshita J, Hummel T.** Magnetic Resonance Imaging of Human Olfactory Dysfunction. **Brain Topogr**, 2019;32(6):987-997.
19. Knecht **M, Hummel T.** Recording of the human electro-olfactogram. **Physiol Behav**, 2004;83(1):13-9.
20. **Ajmani GS, Suh HH, Wroblewski KE, Pinto JM.** Smoking and olfactory dysfunction: A systematic literature review and meta-analysis. **Laryngoscope.** 2017 Aug;127(8):1753-1761. doi: 10.1002/lary.26558. Epub 2017 May 31.
21. **Whitcroft KL, Hummel T.** Clinical Diagnosis and Current Management Strategies for Olfactory Dysfunction: A Review. **JAMA Otolaryngol Head Neck Surg.** 2019 Jul 18. doi: 10.1001/jamaoto.2019.1728.
22. Dewan NA, Bell CW, Moore J, Anderson B, Kirchain W, O'Donohue WJ Jr. **Smell and taste function in subjects with chronic obstructive pulmonary disease. Effect of long-term oxygen via nasal cannulas.** *Chest.* 1990 Mar;97(3):595-9.
23. **Bitter T, Gudziol H, Burmeister HP, Mentzel HJ, Guntinas-Lichius O, Gaser C.** Anosmia leads to a loss of gray matter in cortical brain areas. **Chem Senses.** 2010 Jun;35(5):407-15. doi: 10.1093/chemse/bjq028. Epub 2010 Mar 15.
24. **Fischer ME, Cruickshanks KJ, Schubert CR, Pinto AA, Carlsson CM, Klein BE, Klein R, Tweed TS.** Age-Related Sensory Impairments and Risk of Cognitive Impairment. **J Am Geriatr Soc.** 2016 Oct;64(10):1981-1987. doi: 10.1111/jgs.14308. Epub 2016 Sep 9.
25. **Rumeau C, Nguyen DT, Jankowski R.** How to assess olfactory performance with the Sniffin' Sticks test®. **Eur Ann Otorhinolaryngol Head Neck Dis.** 2016 Jun;133(3):203-6.
26. Niklassen AS, Ovesen T, Fernandes H, Fjaeldstad AW. **Danish validation of sniffin' sticks olfactory test for threshold, discrimination, and identification.** *Laryngoscope.*

27. **Singh D, Agusti A, Anzueto A**, et al. Strategy for the Diagnosis, Management, and Prevention of Chronic Obstructive Lung Disease: the GOLD science committee report 2019. **Eur Respir J**. 2019; 18;53(5). pii: 1900164. doi: 10.1183/13993003.00164-2019.
28. Hopkins C, Gillett S, Slack R, et al. Psychometric validity of the 22-item Sinonasal Outcome Test. *Clin. Otolaryngol*. 2009;34:447–454.
29. **Jones PW, Harding G, Wiklund I**, et al. Tests of the responsiveness of the COPD assessment test following acute exacerbation and pulmonary rehabilitation **Chest**. 2012;142(1):134-140.
30. Lund VJ, Mackay IS. Staging in rhinosinusitis. *Rhinology*. 1993;107:183-4.
31. Oleszkiewicz A, Schriever VA, Croy I, Hähner A, Hummel T. **Updated Sniffin' Sticks normative data based on an extended sample of 9139 subjects**. *Eur Arch Otorhinolaryngol*. 2019 Mar;276(3):719-728.
32. Buuren S. van, Groothuis-Oudshoorn K. Mice: Multivariate Imputation by Chained Equations in R. *Journal of Statistical Software*, 2011;45(3). Doi:10.18637/jss.v045.i03
33. **Kohli P, Naik AN, Harruff EE, Nguyen SA, Schlosser RJ, Soler ZM**. The prevalence of olfactory dysfunction in chronic rhinosinusitis. **Laryngoscope**. 2017 Feb;127(2):309-320.
34. **Singh AK, Touhara K, Okamoto M**. Electrophysiological correlates of top-down attentional modulation in olfaction. **Sci Rep**. 2019 Mar 20;9(1):4953. doi: 10.1038/s41598-019-41319-6.
35. **Håkansson K, Bachert C, Konge L**, et al. Inflammation in Chronic Rhinosinusitis with Nasal Polyps and Asthma: The United Airways Concept Further Supported. **PLoS One**. 2015;10(7):e0127228. doi: 10.1371/journal.pone.0127228.
36. Sorokowska **A, Albrecht E, Hummel T**. Reading first or smelling first? Effects of presentation order on odor identification. **Atten Percept Psychophys**. 2015 Apr;77(3):731-6. doi: 10.3758/s13414-014-0811-3.
37. **Ottaviano G, Frasson G, Nardello E, Martini A**. Olfaction deterioration in cognitive disorders in the elderly. **Aging Clin Exp Res**. 2016 Feb;28(1):37-45. doi: 10.1007/s40520-015-0380-x. Epub 2015 May 24.
38. **Krismer F, Pinter B, Mueller C, Mahlknecht P, Nocker M, Reiter E, Djamshidian-Tehrani A, Boesch SM, Wenning GK, Scherfler C, Poewe W, Seppi K**. Sniffing the diagnosis: Olfactory testing in neurodegenerative parkinsonism. **Parkinsonism Relat Disord**. 2017 Feb;35:36-41. doi: 10.1016/j.parkreldis.2016.11.010. Epub 2016 Nov 21.



39. Fokkens WJ, Lund VJ, Hopkins C, et al. **European Position Paper on Rhinosinusitis and Nasal Polyps 2020.** *Rhinology*, 2020;58(Suppl S29):1-464.
40. Damm M, Pikart LK, Reimann H, Burkert S, Göktas Ö, Haxel B, Frey S, Charalampakis I, Beule A, Renner B, Hummel T, Hüttenbrink KB. **Olfactory training is helpful in postinfectious olfactory loss: a randomized, controlled, multicenter study.** *Laryngoscope*. 2014 Apr;124(4):826-31.
41. **Hummel T, Kobal G, Gudziol H, Mackay-Sim A.** Normative data for the "Sniffin' Sticks" including tests of odor identification, odor discrimination, and olfactory thresholds: an upgrade based on a group of more than 3,000 subjects. **Eur Arch Otorhinolaryngol.** 2007 Mar;264(3):237-43.
42. **Erskine SE, Philpott CM.** An unmet need: Patients with smell and taste disorders. **Clin Otolaryngol.** 2019 Dec 19. doi: 10.1111/coa.13484.
43. Frasnelli J, **Hummel T.** Olfactory dysfunction and daily life. **Eur Arch Otorhinolaryngol.** 2005 Mar;262(3):231-5.
44. **Haehner A, Tosch C, Wolz M, Klingelhoef L, Fauser M, Storch A, Reichmann H, Hummel T.** Olfactory training in patients with Parkinson's disease. **PLoS One**, 2013;8(4):e61680. doi: 10.1371/journal.pone.0061680.

## Effect of dupilumab versus placebo across various responder definitions for improvement in nasal congestion (NC) and loss of smell (LoS) scores among patients with chronic rhinosinusitis with nasal polyps (CRSwNP)

**Claus Bachert**<sup>1,2</sup>, Martin Desrosiers<sup>3</sup>, Stella Lee<sup>4</sup>, Peter W. Hellings<sup>5</sup>, Wytske Fokkens<sup>6</sup>, Nicolas Duverger<sup>7</sup>, Chunpeng Fan<sup>8</sup>, Benjamin Ortiz<sup>9</sup>, Michel Djandji<sup>11</sup>, Nikhil Amin<sup>9</sup>, Leda P. Mannent<sup>7</sup>, Asif H. Khan<sup>7</sup>, Isabelle Guillemin<sup>10</sup>, Siddhesh Kamat<sup>9</sup>, Chien-Chia Chuang<sup>11</sup>

<sup>1</sup>Ghent University, Ghent, Belgium; <sup>2</sup>Karolinska Institutet, Stockholm, Sweden; <sup>3</sup>Centre de recherche du Centre hospitalier de l'Université de Montreal (CRCHUM), Montreal, QC, Canada; <sup>4</sup>University of Pittsburgh Medical Center, Pittsburgh, PA, USA; <sup>5</sup>University Hospitals Leuven, Leuven, Belgium; <sup>6</sup>Academic Medical Center, Amsterdam, Netherlands; <sup>7</sup>Sanofi, Chilly-Mazarin, France; <sup>8</sup>Sanofi, Bridgewater, NJ, USA; <sup>9</sup>Regeneron Pharmaceuticals, Inc., Tarrytown, NY, USA; <sup>10</sup>Sanofi, Lyon, France; <sup>11</sup>Sanofi, Cambridge, MA, USA

*CRS - outcome assessment 1, Building M1 Room Σ4, Sept 27, 10.15*

**Background:** Currently, there are no CRSwNP consensus guidelines on the definition of clinically meaningful changes in patient-reported NC and LoS scores. To contextualize the impact of dupilumab vs placebo, responder analyses were conducted across a range of within-person change thresholds for improvement in NC and LoS scores.

**Methodology:** In the phase 3 SINUS-24/SINUS-52 (NCT02912468/NCT02898454) studies, patients reported NC and LoS on a scale of 0 (no symptoms) to 3 (severe symptoms). Pooled study data were used to compare proportion of dupilumab versus placebo patients with improvement in NC and LoS scores of  $\geq 0.5$ ,  $\geq 0.75$ , and  $\geq 1$  from baseline to Week 24 (Wk24). Cumulative distribution function (CDF) curves evaluated responders in dupilumab versus placebo across the entire spectrum of responder definitions.

**Results:** Proportion of dupilumab/placebo patients with  $\geq 0.5$ ,  $\geq 0.75$ ,  $\geq 1.0$  improvement in NC score was 77.2%vs39.4%, 72.6%vs32.9%, 65.6%vs24.5%, respectively; all  $P < 0.0001$ . Similarly, proportion of dupilumab/placebo patients with  $\geq 0.5$ ,  $\geq 0.75$ ,  $\geq 1.0$  improvement in LoS score was 70.9%vs22.0%, 68.4%vs18.1%, 64.4%vs15.2%, respectively; all  $P < 0.0001$ . CDF curves supported the previous results, with distinct separation between dupilumab and placebo curves across all responder definitions.

**Conclusions:** A significantly greater proportion of dupilumab patients experience improvement in NC and LoS vs placebo regardless of within-person change threshold used.

**Key words:** Nasal Polyps, Loss of Smell, Nasal Congestion, responder definition

### Acknowledgments and funding sources

Research sponsored by Sanofi and Regeneron Pharmaceuticals, Inc. ClinicalTrials.gov Identifier: NCT02912468 (SINUS-24) and NCT02898454 (SINUS-52). Medical writing/editorial assistance provided by Michael van der Veer, PhD, of Excerpta Medica, funded by Sanofi Genzyme and Regeneron Pharmaceuticals, Inc.

202297

## Our method of joining dura mater of frontal sinus tumors with intracranial invading by electrocautery

Zabolotniy D.<sup>1</sup>, Rylska O., **Kvasha O.**<sup>1</sup>, Savchenko T.<sup>1</sup>, Zarytska I.<sup>1</sup>

<sup>1</sup>State Institution "Institute of otolaryngology named after Prof. O.S. Kolomiychenko of the National Academy of Medical Sciences of Ukraine"; Kyiv, Ukraine.

*Technological advances 1, Building M1 Room Σ4, Sept 29, 14.45*

**Introduction.** When tumors of frontal sinus invade dura mater, for surgeon, it is necessary to completely close the defect of the dura mater to avoid intra- and postoperative complications.

**Materials and methods.** 63 patients who underwent surgical treatment for tumors of frontal sinuses with intracranial invading during the last years were analyzed. Patonmed electric cauterizing technology was used.

**Results.** All patients were divided into 2 groups - in the first group – we use our special developed bipolar instrument and use them to connect surgically dura mater, and in the second group - electrocautery was not used, and the dura mater was connected in traditional surgical methods. After 10 months, 6.25% of patients were diagnosed with nasal liquor in the second group and 1 case of meningitis (3.13%) in the second group. The second group also diagnosed 2 cases of continued growth (6.25%).

**Conclusion.** We observed following advantages of using electrocautery and special bipolar instrument during surgery of tumors of frontal sinus with intracranial invading: significantly decreased the volume of intraoperative blood loss, decreased duration of surgical interventions, decrease traumatism of intervention and decreased frequency of intra- and postoperative complications and it is reliable to joint dura mater.



# Improvement of the aerobic performance in endurance athletes with nasal valve compromise with application of an internal nasal dilator

Konstantinos Valsamidis<sup>1</sup>, Athanasia Printza<sup>1</sup>, Nikolaos Valsamidis<sup>2</sup>, Jannis Constantinidis<sup>1</sup>, Stefanos Triaridis<sup>1</sup>

<sup>1</sup>1st Otolaryngology Department, Medical School, Aristotle University of Thessaloniki, AHEPA Hospital, 54124, Thessaloniki, Greece; <sup>2</sup>School of Physical Education and Sports Science, Aristotle University of Thessaloniki, 57001, Thessaloniki, Greece

*Rhinology – miscellaneous 3, Building M1 Room Σ1, Sept 27, 11.45*

**Background:** We investigated the effects of an internal nasal dilator on nasal airflow and cardio-respiratory capacity in adult endurance athletes, while performing controlled exhaustive physical exercise.

**Methodology:** Prospective observational study. Participants were 38 adult endurance athletes, 23 with and 15 without nasal valve compromise. Nasal patency was objectively evaluated with anterior rhinomanometry, acoustic rhinometry and peak nasal inspiratory flow (PNIF). Maximum oxygen uptake (VO<sub>2</sub>max), maximum pulmonary ventilation, time to exhaustion and total time of nasal respiration were recorded during a submaximal treadmill test. Dyspnea intensity and fatigue perception were evaluated using a labeled visual analog scale. All assessments were performed with and without the application of the internal nasal dilator.

**Results:** All the parameters related to aerobic capacity were significantly reduced in the group of athletes with nasal valve compromise ( $p < 0.05$  for all variables). The internal nasal dilator improved statistically significantly the nasal patency ( $p < 0.001$ ), VO<sub>2</sub>max and aerobic performance and self-rating of dyspnea and fatigue ( $p < 0.05$  for all parameters) only in athletes with nasal obstruction. PNIF correlated significantly with VO<sub>2</sub>max ( $\rho = 0.4$ ,  $p < 0.05$ ).

**Conclusions:** Internal nasal dilation improves nasal patency and aerobic performance during submaximal exercise in adult endurance athletes with nasal obstruction symptoms due to nasal valve compromise.

**Keywords:** internal nasal dilator, athletes, aerobic performance, nasal patency, cardio-respiratory capacity

## Literature

1. Ricardo Reis Dinardi, Claudia Ribeiro de Andrade, Hugo Cesar Martins-Costa, Cassio da Cunha Ibiapina Does the Airmax1 internal nasal dilator increase peak nasal inspiratory flow (PNIF) in adolescent athletes? International Journal of Pediatric Otorhinolaryngology 2016;84: 37–42
2. Catriona M. Adams, Jeremiah J. Peiffer Neither internal nor external nasal dilation improves cycling 20-km time trial performance Journal of Science and Medicine in Sport 2017;20:415–419
3. Matteo Gelardi, Giuseppe Porro, Domenico Accettura, Vitaliano Nicola Quaranta, Nicola Quaranta, Giorgio Ciprandi The role of an internal nasal dilator in athletes Acta Biomed 2019; 90(2): 28-30

4. P.W. Hellings, G.J.N. Tienite', Improvement of nasal breathing and patient satisfaction by the endonasal dilator Airmax1, *Rhinology* 2013;52:31-34.
5. Garyfalia Lekakis, Emily Dekimpe, Brecht Steelant, Peter W. Hellings Managing nasal valve compromise patients with nasal dilators: objective vs. subjective parameters *Rhinology* 2016; 54: 348-354



202303

## Eosinophilic angiocentric fibrosis presenting as a rare cause of nasal blockage

Abigail Walker, Angelos Mantelakis, Anastasia Rachmanidou, Irfan Syed

*Department of ENT Surgery, University Hospital Lewisham, London, UK.*

*Rhinology – miscellaneous 1, Building M1 Room Σ2, Sept 28, 14.45*

**Background:** Eosinophilic angiocentric fibrosis (EAF) is a rare condition with a predilection for the upper airways. It was first described in 1985, and in that time less than 100 cases have been described in the literature. Initially defying categorisation, EAF has variously been speculated to be a variant of conditions such as granulomatosis with polyangiitis or eosinophilic granulomatosis with polyangiitis. Emerging histological evidence however suggests that EAF may be part of the spectrum of IgG4 conditions. We describe here a case report of a young female presenting with nasal blockage secondary to EAF.

**Methodology/Principal:** case report and review of literature

**Results:** in-depth histologic analysis reveals that EAF shares many of the hallmarks of IgG4 disease, with nearly 80% meeting diagnostic criteria to be included as part of the IgG4 spectrum. These features include storiform-type fibrosis, lymphoplasmacytic infiltrate, and prominent eosinophils.

**Conclusions:** IgG4 disease is an evolving entity and there is compelling histological evidence that EAF may be a variant of it. Treatment avenues also continue to evolve with the development of recombinant monoclonal antibodies. We illustrate these up to date findings with a clinical case.

Please do not include any citations in the abstract. Avoid specialist abbreviations if possible

**Key words:** Eosinophilic angiocentric fibrosis, IgG4, blockage



**Marcel Marjanović Kavanagh<sup>1</sup>**, Tomislav Tokić<sup>1</sup>, Antonija Jakovčević<sup>2</sup>, Ranko Smiljanić<sup>3</sup>, Boris Bumber<sup>1</sup>, Ratko Prstacić<sup>1</sup>, Ranko Mladina<sup>1</sup>

<sup>1</sup>ENT Head and Neck Surgery Department, University Hospital Centre Zagreb, Zagreb, Croatia;

<sup>2</sup>Pathology and Cytology Department, University Hospital Centre Zagreb, Zagreb, Croatia;

<sup>3</sup>Department of Radiology, University Hospital Centre Zagreb, Zagreb, Croatia

*Imaging and investigations 1, Building M1 Room 24, Sept 29, 11.45*

**Background:** This is the first histopathological study that investigates the incidence of the pneumatized crista galli.

**Methodology/Principal:** 109 specimens of crista galli were obtained post mortem during 2018

from randomly chosen patients who have died at the University Hospital Centre Zagreb and had an autopsy at our Department of Pathology and Cytology. Specimens were histopathologically analyzed for the existence of pneumatization inside crista galli. The criterion to declare a specimen pneumatized was the presence of mucosa inside the cavity

**Results:** Pneumatized crista galli was found in 5/109 specimens (4.59%). In 5/5 cases (100%) of pneumatized crista galli, there was evidence of chronic inflammation.

**Conclusions:** We have found that the incidence of pneumatized crista galli is significantly lower in our histopathological study in comparison with the majority of previous radiological studies. Our study also found that all 5 specimens with PCG had chronic inflammation in the mucosa, which is a considerably higher incidence than in the previous studies. Due to the emerging evidence of pneumatized crista galli being of clinical importance, we suggest a larger study should be conducted before the results could be generalized to the general population.

**Key words:** crista galli, pneumatized crista galli, histopathology, chronic rhinosinusitis,

## Literature

1. Standring S., ed. Gray's Anatomy: The Anatomical Basis of Clinical Practice. 41 st edition. Edinburgh, United Kingdom: Elsevier; 2016.
2. Lee JM, Ransom E, Lee JYK, Palmer JN, Chiu AG. Endoscopic Anterior Skull Base Surgery: Intraoperative Considerations of the Crista Galli. Skull Base. 2011;21(2):83-86
3. Fadda GL, Rosso S, Aversa S, Petrelli A, Ondolo C, Succo G. Multiparametric statistical correlations between paranasal sinus anatomic variations and chronic rhinosinusitis. Acta Otorhinolaryngol Ital. 2012;32(4):244-251
4. Som PM, Park EE, Naidich TP, Lawson W. Crista Galli Pneumatization Is an Extension of the Adjacent Frontal Sinuses. Am J Neuroradiol. 2009;30(1):31-33
5. Kim JJ, Cho JH, Choi JW et al. Morphologic Analysis of Crista Galli Using Computed Tomography. J Rhinol. 2012;19(2):91-95
6. Poje G, Mladina R, Skitarelic N, Marjanovic Kavanagh M. Some radiological and clinical aspects of the sinus crista galli. Romanian Journal of Rhinology. 2014;4(13):31-36
7. Manea C, Mladina R. Crista galli sinusitis – a radiological impression or a real clinical entity. Romanian Journal of Rhinology. 2016;6(23):167-171
8. Tetiker H, Kosar MI, Cullu M, Sahan M, Gencer CU, Derin S. Pneumatization of crista

- galli in Pre-adult and Adult stages. *Int J Morphol*. 2016;34(2):541-544
9. Kamala E, Vijaya Shanmugam U, Gugapriya TS, Vinay Kumar N. A COMPUTERIZED TOMOGRAPHIC STUDY OF MORPHOLOGY AND PNEUMATIZATION OF CRISTA GALLI. *Int J Anat Res*. 2016;4(2):2429-2433
10. Wingate J, Rechtweg JS, Grand W, Jouandet M, Balos L, Wax MK. Mucocele of the crista galli. *J Otolaryngol*. 2001;30(1):43-46
11. Cervantes SS, Lal D. Crista galli mucocele: endoscopic marsupialization via frontoethmoid approach. *Int Forum Allergy Rhinol*. 2014;4(7):598-602
12. Shidanshid M, Taghi AS, Kuchai R, Saleh HA. Endoscopic resection of a mucocele of the crista galli. *Ear Nose Throat J*. 2015;94(9):e23-e25
13. Hajiioannou J, Owens D, Whittet HB. Evaluation of Anatomical Variation of the Crista Galli Using Computed Tomography. *Clin Anat*. 2010;23(4):370-373
14. Min HJ, Kim KS. Frontal Headache Caused by Infection of Pneumatized Crista Galli. *J Craniofac Surg*. 2016;27(4):e352-e354
15. Basic N, Basic V, Jukic T, Basic M, Jelic M. Computed tomographic imaging to determine the frequency of anatomical variations in pneumatization of the ethmoid bone. *Eur Arch Otorhinolaryngol*. 1999;256:69-71
16. Odat H, Al-Qudah M. Concha Bullosa and Ethmoid Structures Pneumatization: The Effect of Altitude and Other Variables. *J Craniofac Surg*. 2016;27(7):e667-e669
17. Mladina R, Antunovic R, Cingi C, Muluk NB, Skitarelic N, Malic M. An anatomical study of the pneumatized crista galli. *Neurosurg Rev*. 2017;40(4):671-67
18. Al-Qudah M. The relationship between anatomical variations of the sino-nasal region and chronic sinusitis extension in children. *Int J Pediatr Otorhi*. 2008;72:817-821
19. Al-Qudah M. Anatomical Variations in Sino-Nasal Region: A Computer Tomography (CT) Study. *J Med J*. 2010;44(3):290-297
20. Cobzeanu MD, Baldea V, Baldea MC, Vonica PS, Cobzeanu BM. The anatomo-radiological study of unusual extrasinusal pneumatizations: superior and supreme turbinate, crista galli process, uncinat process. *Rom J Morphol Embryol*. 2014;55(3 supl):1099-1104
21. Shah RK, Dhingra JK, Carter BL, Rebeiz EE. Paranasal Sinus Development: A Radiographic Study. *Laryngoscope*. 2003;113(2):205-209
22. Socher JA, Santos PG, Correa VC, de Barros e Silva LC. Endoscopic surgery in the treatment of crista galli pneumatization evolving with localized frontal headaches. *Int Arch Otorhinolaryngol*. 2013;17(3):246-250
23. Elvan O, Esen K, Celikcan HD, Havva D, Tezer MS, Ozgur A. Anatomic Variations of Paranasal Region in Migraine. *J Craniofac Surg*. 2019;Epub ahead of print

## Squamous cell carcinoma of the nasal cavity: implications for treatment

**Konstantinos Mantsopoulos**, Andreas Reichelt, Miguel Goncalves, Sarina Müller, Heinrich Iro*Department of Otorhinolaryngology, Head and Neck Surgery, University of Erlangen-Nuremberg Medical School, Erlangen, Germany**Sinonasal malignancy 2, Building M1 Room Σ3, Sept 28, 14.45*

**Background:** Squamous cell carcinoma of the nasal cavity is an infrequent malignant entity and is often analyzed in heterogeneous studies with other sinonasal tumors. The purpose of this study was to evaluate the oncologic outcomes of these patients with special emphasis on cervical lymph node treatment and recurrence.

**Methodology/Principal:** A retrospective study of patients treated at a single academic tertiary referral cancer center was performed. Demographic data, tumor characteristics, therapeutic management, and clinical outcome were analyzed.

**Results:** A total of 95 cases were identified in our database between 2001 and 2018. The mean age at diagnosis was 60 years. Stage I was 38.9%, 26.3% were stage II, 9.5% were stage III, and 25.3% were stage IV. Regarding T category, T1 was the most common (40.0%), followed by T2 (33.7%). Most cases had no nodal involvement at diagnosis (85.3%). Five-year overall survival was 88 %.

**Conclusions:** Radical tumor resection of these lesions warrants an acceptable local control. Cervical nodal involvement is extremely rare at the time of diagnosis but the possibility of regional recurrence should be always considered in follow-up examinations. The need for adjuvant therapy and the ideal time for local reconstruction depend on individual tumor characteristics.

**Keywords:** *squamous cell carcinoma, nasal cavity, neck dissection, recurrence, survival*

**Literature**

1. Hussain T, Mattheis S, Dominas N, Hoing B, Lang S, Stuck BA. Regional recurrence in a case series of patients with carcinoma of the nasal cavity - therapeutic implications. *Rhinology*. 2017 Dec 1;55(4):355-362.
2. Unsal AA, Dubal PM, Patel TD, Vazquez A, Baredes S, Liu JK, Eloy JA. Squamous cell carcinoma of the nasal cavity: A population-based analysis. *Laryngoscope*. 2016 Mar;126(3):560-5.

# Inverted papilloma, our experience with endoscopic management in last ten years.

**Zuzana Balatková<sup>1</sup>**, Adam Kešner<sup>1</sup>, Jan Plzák<sup>1</sup>

<sup>1</sup>*Department of otorhinolaryngology and head and neck surgery 1<sup>st</sup> Faculty of Medicine, University Hospital Motol, Prague, Czech Republic.*

**Background:** Our aim was to analyse retrospectively the data of patients treated for inverted papilloma especially focused on recurrence rate with respect to the grade of the disease and treatment strategy.

**Methodology/Principal:** 51 patients underwent surgery for inverted papilloma in years 2011-2018 with minimum follow up of 18 months. Surgical approach and technique, grade of the tumour and recurrence rate were observed.

**Results:** Endoscopic approach was used in the majority of patients and we observed 11.8% recurrence rate compared with external approach recurrence rate almost 70%. Although external approach was used for extensive disease. Surgical technique used for the tumour origo removal plays an important role. Laser vaporization or/and drilling were the most effective techniques. On the other hand mucosal stripping is not effective enough. In 3.9% of cases we observed spinocellular carcinoma in inverted papilloma. There was also seen inverted papilloma in bilateral recurrent polyposis in 4.5%.

**Conclusions:** Endoscopic approach for inverted papilloma reduces the risk of recurrence. It is important to treat the tumour origo with drill or laser. Follow up is a necessary part of patient care, it should last minimally 5 years. The recurrence may occur after many years.

Key words: inverted papilloma, endoscopic treatment, recurrence rate

## Literature

1. Hyams VJ. Papillomas of the nasal cavity and paranasal sinuses. A clinicopathological study of 315 cases. *Ann Otol Rhinol Laryngol* 1971; 80: 192–206.
2. Lund V, Stammberger H, Nicolai P, Castelnuovo P. European position paper on endoscopic management of tumours of the nose, paranasal sinuses and skull base. *Rhinology* 2010; Suppl. 22: 1–143.
3. Mirza S, Bradley PJ, Acharya A et al. Sinonasal inverted papillomas: recurrence, and synchronous and metachronous malignancy. *Journal of Laryngology & Otology* 2007; 121(9): 857–864.
4. Lawson W, Patel ZM. The evolution of management for inverted papilloma: an analysis of 200 cases. *Otolaryngology – Head & Neck Surgery* 2009; 140(3): 330–335.
5. Minni A, Gera R, Bulgheroni C et al. Endoscopic Resection of Sinonasal Inverted Papilloma: A Multivariate Retrospective Analysis of Factors Affecting Recurrence and Persistence. *Ear Nose Throat J.* 2019 Nov 28:145561319890454.
6. Krouse JH. Development of a staging system for inverted papilloma. *Laryngoscope* 2000; 110(6): 965–968.
7. Dragonetti A. Sinonasal inverted papilloma: 84 patients treated by endoscopy and proposal for a new classification. *Rhinology* 2011; 49(2): 207–213.
8. Kraft M, Simmen D, Kaufmann T, Holzmann D. Long-term results of endonasal sinus surgery

in sinonasal papillomas. *Laryngoscope* 2003; 113(9): 1541–1547.

9. Sautter NB, Cannady SB. Comparison of open versus endoscopic resection of inverted papilloma. *Am J Rhinol* 2007; 21(3): 320–323.

10. Lisan Q, Moya-Plana A, Bonfils P. Association of Krouse Classification for Sinonasal Inverted Papilloma With Recurrence: A Systematic Review and Meta-analysis. *JAMA Otolaryngol Head Neck Surg.* 2017 Nov 1;143(11):1104-1110.

## Ex vivo characterization of ciliary beating in chronic rhinosinusitis with nasal polyps

Justine Bécaud<sup>1,2,3,4\*</sup> ; **Marion Renaud<sup>1,2,3,4\*</sup>** ; Christelle Angely<sup>2,3,4</sup> ; Lucie Thomas<sup>5</sup> ; Marcel Filoche<sup>2,3,4</sup> ; Estelle Escudier<sup>5,6,7</sup> ; J.F. Papon<sup>2,4,8,9</sup> ; André Coste<sup>1,2,3,4</sup> ; Bruno Louis<sup>2,3,4</sup> ; Émilie Béquignon<sup>1,2,3,4</sup>

<sup>1</sup>AP-HP, Hôpital Henri Mondor et Centre Hospitalier Intercommunal de Créteil, service d'Oto-Rhino-Laryngologie et de Chirurgie cervico-faciale, Créteil, 94010, France ; <sup>2</sup>INSERM, U955, Créteil, 94010, France ;

<sup>3</sup>Université Paris-Est Créteil, Faculté de Médecine, Créteil, F-94010, France ; <sup>4</sup>CNRS, ERL 7000, Créteil, 94010, France ; <sup>5</sup>Inserm U933, Paris, France ;

<sup>6</sup>Université Pierre et Marie Curie, Paris, France ; <sup>7</sup>AP-HP Hôpital Armand-Trousseau, Service de génétique et d'embryologie médicale, Paris, France ; <sup>8</sup>AP-HP, Hôpital Bicêtre, service d'Oto-Rhino-Laryngologie et de Chirurgie cervico-faciale, Le Kremlin-Bicêtre, 94270, France ;

<sup>9</sup>Université Paris-Sud, Faculté de Médecine, Le Kremlin-Bicêtre, F-94275, France ;

\*These authors have contributed equally to this work

Abstract Session 13, Building M2 CR1, Sept 27, 14.45

**Background:** Alteration of mucociliary clearance could be involved in chronic rhinosinusitis with nasal polyps (CRSwNP). We defined ciliary beating efficiency index (CBEI) in CRSwNP with a microbead tracking method in order to measure the shear stress induced by the ciliary beating.

**Methodology:** Nasal brushings of nasal polyps (NP) and inferior turbinates (IT) were prospectively sampled in 45 patients during surgical procedures for CRSwNP and compared to 10 nasal brushings (IT) from control patients (CP). *Ex vivo* high-speed video-microscopy analysis of samples included: ciliary beating frequency (CBF), ciliary length, relative ciliary density, metachronal wavelength and CBEI.

**Results:** In CRSwNP, beating ciliated cell clusters were found in all NP but only in two-thirds of IT. Comparing CRSwNP to CP: CBF, ciliary length and metachronal wavelength were significantly lower while relative ciliary density was not different; CBEI was significantly lower (0.2 vs 0.87 mPa respectively). Into CRSwNP samples, CBEI in NP (0.38mPa) was significantly higher than in IT (0.2mPa).

**Conclusions:** Ciliary beating seems to be poorly coordinated and poorly efficient in CRSwNP. Our results support the hypothesis of acquired ciliary dyskinesia in CRSwNP that could participate in the chronic inflammatory process.

**Keywords:** Ciliary beating; Chronic rhinosinusitis with nasal polyps; efficiency; mucociliary clearance; Nasal polyps;

### Literature:

1. Sharma R, Lakhani R, Rimmer J, Hopkins C. Surgical interventions for chronic rhinosinusitis with nasal polyps. *Cochrane Database Syst Rev* 2014; : CD006990.
2. Kozlov VS, Shilenkov VV, Azatian AS, Kramnoï AI. [Mucociliary transport and motility of the ciliary system of the nasal mucosa in patients with chronic polypous rhinosinusitis]. *Vestn. Otorinolaringol.* 2008; : 10–13.
3. Slater A, Smallman LA, Logan AC, Drake-Lee AB. Mucociliary function in patients with nasal polyps. *Clin Otolaryngol Allied Sci* 1996; 21: 343–347.
4. Braverman I, Wright ED, Wang CG, Eidelman D, Frenkiel S. Human nasal ciliary-beat frequency in normal and chronic sinusitis subjects. *J Otolaryngol* 1998; 27: 145–152.

5. Li YY, Li CW, Chao SS, Yu FG, Yu XM, Liu J, Yan Y, Shen L, Gordon W, Shi L, Wang DY. Impairment of cilia architecture and ciliogenesis in hyperplastic nasal epithelium from nasal polyps. *J. Allergy Clin. Immunol.* 2014; 134: 1282–1292.
6. Bottier M, Blanchon S, Pelle G, Bequignon E, Isabey D, Coste A, Escudier E, Grotberg JB, Papon J-F, Filoche M, Louis B. A new index for characterizing micro-bead motion in a flow induced by ciliary beating: Part I, experimental analysis. *PLoS Comput. Biol.* 2017; 13: e1005605.
7. Lildholdt T, Rundcrantz H, Lindqvist N. Efficacy of topical corticosteroid powder for nasal polyps: a double-blind, placebo-controlled study of budesonide. *Clin Otolaryngol Allied Sci* 1995; 20: 26–30.
8. Global Initiative for Asthma. Global Strategy for Asthma Management and Prevention, 2019. Available from : [www.ginasthma.org](http://www.ginasthma.org). .
9. Navarro AM, Delgado J, Muñoz-Cano RM, Dordal MT, Valero A, Quirce S. Allergic respiratory disease (ARD), setting forth the basics: proposals of an expert consensus report. *Clin Transl Allergy* [Internet] 2017 [cited 2019 Jun 27]; 7Available from: <https://www.ncbi.nlm.nih.gov/pmc/articles/PMC5437581/>.
10. Green A, Smallman LA, Logan AC, Drake-Lee AB. The effect of temperature on nasal ciliary beat frequency. *Clin Otolaryngol Allied Sci* 1995; 20: 178–180.
11. Chilvers MA, O’Callaghan C. Analysis of ciliary beat pattern and beat frequency using digital high speed imaging: comparison with the photomultiplier and photodiode methods. *Thorax* 2000; 55: 314–317.
12. Dalrymple RA, Kenia P. European Respiratory Society guidelines for the diagnosis of primary ciliary dyskinesia: a guideline review. *Arch Dis Child Educ Pract Ed* 2018; .
13. Papon J-F, Bassinet L, Cariou-Patron G, Zerah-Lancner F, Vojtek A-M, Blanchon S, Crestani B, Amselem S, Coste A, Housset B, Escudier E, Louis B. Quantitative analysis of ciliary beating in primary ciliary dyskinesia: a pilot study. *Orphanet J Rare Dis* 2012; 7: 78.
14. Sleigh MA, Blake JR, Liron N. The propulsion of mucus by cilia. *Am. Rev. Respir. Dis.* 1988; 137: 726–741.
15. Gheber L, Priel Z. Metachronal activity of cultured mucociliary epithelium under normal and stimulated conditions. *Cell Motil. Cytoskeleton* 1994; 28: 333–345.
16. Brondeel L, Sönstabö R, Clement P, van Ryckeghem W, van den Broek M. Value of the Tc99m particle test and the saccharin test in mucociliary examinations. *Rhinology* 1983; 21: 135–142.
17. Guan W-J, Peng Y, Zi X-X, Tan KS, He T-T, Zhong N-S, Wang DY. Motile Ciliary Disorders in Chronic Airway Inflammatory Diseases: Critical Target for Interventions. *Curr Allergy Asthma Rep* 2018; 18: 48.
18. Fokkens WJ, Lund VJ, Mullol J, Bachert C, Alobid I, Baroody F, Cohen N, Cervin A, Douglas R, Gevaert P, Georgalas C, Goossens H, Harvey R, Hellings P, Hopkins C, Jones N, Joos G, Kalogjera L, Kern B, Kowalski M, Price D, Riechelmann H, Schlosser R, Senior B, Thomas M, Toskala E, Voegels R, Wang DY, Wormald PJ. European Position Paper on Rhinosinusitis and Nasal Polyps 2012. *Rhinol. Suppl.* 2012; 23: 3 p preceding table of contents, 1–298.
19. Jiao J, Duan S, Meng N, Li Y, Fan E, Zhang L. Role of IFN- $\gamma$ , IL-13, and IL-17 on mucociliary differentiation of nasal epithelial cells in chronic rhinosinusitis with nasal polyps. *Clin. Exp. Allergy* 2016; 46: 449–460.
20. Liu C, Li Q, Zhou X, Kolosov VP, Perelman JM. Cortactin mediates elevated shear stress-induced mucin hypersecretion via actin polymerization in human airway epithelial cells. *Int. J. Biochem. Cell Biol.* 2013; 45: 2756–2763.
21. White DE, Bartley J, Nates RJ. Model demonstrates functional purpose of the nasal cycle. *Biomed Eng Online* 2015; 14: 38.

202393

## The Expression of IL-25 Receptor in Nasal Polyps

**Jiao Xia**<sup>1,2</sup>, Semah Abdu<sup>2,3</sup>, Claire Hopkins<sup>4</sup>, Andrew Mckenzie<sup>5</sup>, \*Grzegorz Woszczek<sup>2,3</sup>

\*Stephen J. Till<sup>2,3</sup>

\*contributed equally to this work

<sup>1</sup>ENT Department, Beijing Friendship Hospital, Capital Medical University, Beijing, China; <sup>2</sup>School of Immunology & Microbial Science, King's College London, London, UK; <sup>3</sup>MRC& Asthma UK Centre in Allergic Mechanisms of Asthma, London, UK; <sup>4</sup>ENT Department, Guy's and St Thomas' NHS Foundation Trust, London, UK; <sup>5</sup>MRC Laboratory of Molecular Biology, Cambridge

\*contributed equally to this work

*CRS – pathophysiology 1, Building M1 Room Σ3, Sept 28, 11.45*

**Background:** IL-25 can induce Th2 inflammation, and its receptor (IL-17RB) is expressed on Th2 and ILC2s in eosinophilic nasal polyps. However, the wider pattern of expression has not been fully explored. We aimed to investigate surface expression of IL-17RB on major immune cells subsets in NP, and to compare this with non-NP tissue and peripheral blood.

**Methodology:** Samples (blood, polyp or turbinate) were obtained from patients undergoing polypectomy or turbinectomy. Tissue was digested to obtain single cells and mononuclear cells enriched by density gradient centrifugation. Phenotyping of major immune cells was achieved by flow cytometry, with IL-17RB expression analysed using the D9.2 mAb.

**Results:** Higher surface IL-17RB was observed in Th cells, macrophages, B cells, DC and mast cells derived from polyps when compared with control. Lower expression was seen in blood derived immune cells (Th cells, monocytes, B cells, DC) with no significant differences between polyp and control. Of note, an IL-17RB<sup>+</sup> subpopulation of polyp B cells was consistently observed but not in control.

**Conclusions:** IL-17RB is expressed by various polyp immune cell subsets, notably macrophages, B cells and mast cells, in addition to previously reported Th2 and ILC2s. This represents the first description of IL-17RB<sup>+</sup> human B cells.

**Key words:** Nasal polyps, IL-25R (IL-17RB), B cell, mast cell, macrophage



202411

## NASAL FUNCTION CHANGES AT HIGH ALTITUDE

**Andrea Pettorelli<sup>1</sup>**, Enrico Savietto<sup>1</sup>, Diletta Giulia Giuntoli<sup>1</sup>, Massimiliano Russo<sup>2</sup>, Andrea Ermolao<sup>3</sup>, Piero Nicolai<sup>1</sup>, Giancarlo Ottaviano<sup>1</sup>

<sup>1</sup>Dept. Neurosciences, Otolaryngology Section, Padova University, Italy; <sup>2</sup>Department of Statistical Sciences, University of Padova, Padova, Italy; <sup>3</sup>Department of Medicine, Sport and Exercise Medicine Division, University of Padova, Padova, Italy

*Rhinology – miscellaneous 4, Building M1 Room Σ1, Sept 27, 14.45*

**Background:** An ever-increasing number of people is involved in sports activities at high altitude. The present study aimed to evaluate the pulmonary and nasal functions, including nasal cytology, in healthy volunteers moving for one week from an altitude of 2000 meters to another of 3400 meters.

**Methodology/Principal** Peak nasal inspiratory flow, pulmonary function, mucociliary transport time (MCTt), nasal cytology and oxygen saturation were studied in five different occasions [T1: at base camp (2000 meters); T2: at the mountain refuge (3400 meters); T3: after 7 days at 3400 meters; T4: after the return at the base camp; T5: at the base camp after 15 days].

**Results** With respect to T1, PEF values decreased at T2(p=0.004), T3(p=0.004), T4(p=0.000) and T5(p=0.001). FEV1 and FVC did not differ among the five different times of measurements. In regard to T1, PNIF values increased at T2(p=0.003) and T3(p=0.001).

**Conclusions** Data seem to support the utility of MCTt for studying nasal mucosa damage induced by high altitude. Nasal cytology seems to be able to identify the inflammation of the nasal mucosa exposed to hypoxia. Further investigations on larger series are needed to confirm these results and, most importantly, the improvement of PNIF at high altitude.

**Key words:** PNIF, PEF, high altitude, O<sub>2</sub> sat, spirometry, FEV1, FVC, MCTt, nasal cytology.

### Literature:

1. Campos AL, Costa RV. Physical activity at moderate and high altitudes. Cardiovascular and respiratory morbidity. Arq Bras Cardiol 1999;73:113-128. Review
2. Burtcher M, Ponchia A. The risk of cardiovascular events during leisure time activities at altitude. Prog Cardiovasc Dis 2010;52:507-511
3. Prasad BK. ENT morbidity at high altitude. J Laryngol Otol 2011;125:188-192
4. Rodway GW, Windsor JS. Airway mucociliary function at high altitude. Wilderness Environ Med 2006;17:271-275. Review
5. Cingi C, Selcuk A, Oghan F, Firat Y, Guvey A. The physiological impact of high altitude on nasal and lower airway parameters. Eur Arch Otorhinolaryngol 2011;268:841-844
6. Roy R, Ramakrishnan N, Wankhede T, Roy KN. Evaluation of nasal obstruction in lowlander males in high altitude. Med J Armed Forces India 2018;74:116-119

7. Gelardi M, Landi M, Ciprandi G. The pragmatic role of nasal cytology: a point-of-care testing to implement precision medicine in clinical practice. *Rev Alerg Mex* 2018;65:259-263

202416

## Olfactory and Gustatory Function before and after Sleeve Gastrectomy.

**Diletta Giulia Giuntoli**<sup>1</sup>, Andrea Pettorelli<sup>1</sup>, Enrico Savietto<sup>1</sup>, Bruno Scarpa<sup>2</sup>, Mirto Foletto<sup>3</sup>, Piero Nicolai<sup>1</sup>, Giancarlo Ottaviano<sup>1</sup>.

<sup>1</sup>Dept. Neurosciences, Otolaryngology Section, Padova University, Italy; <sup>2</sup>Department of Statistical Sciences, University of Padova, Padova, Italy; <sup>3</sup>Department of Surgical, Oncological and Gastroenterological Sciences, Section of Surgery, University of Padua, Padua, Italy.

*Smell and taste 1, Building M2 CR3, Sept 27, 11.45*

**Background:** Bariatric surgery seems to modify smell and taste. Anyway, no definitive conclusions can be drawn given to the heterogeneity of the studies and the different results reported.

**Methodology/Principal:** 18 obese who underwent Laparoscopic Sleeve Gastrectomy (LSG) and 15 obese that did not undergo surgery were enrolled. At the first evaluation (T0) and 6 months after enrollment/surgery (T1), both groups underwent Sniffin' Sticks (TDI) and taste strips for gustatory screening. SNOT22, VAS for taste&smell and MMSE were filled-in. Qualitative taste variations were also analyzed.

**Results:** At T0 there were no differences between the groups. In the interval T0-T1 no smell and taste differences were observed between the groups, a part for the improvement of olfactory threshold in the former respect to the latter ( $p=0.03$ ). At multivariate analysis, the olfactory threshold differences observed in the study group correlated with MMSE ( $p=0.02$ ) and gustatory identification at T0 ( $p=0.01$ ). Analyzing qualitative taste variations, 9 subjects of the study group reported a worsening of taste and this correlated with the olfactory threshold difference between T0-T1 ( $p=0.05$ ) and negatively with age ( $p=0.0001$ ).

**Conclusions:** Olfactory threshold improved after LSG, being influenced by MMSE and taste. LSG produced a worsening of taste quality, being influenced by the age and the improvement of olfactory threshold.

**Key words:** smell, taste, olfactory threshold, bariatric surgery, sleeve gastrectomy, taste quality, MMSE.

### Literature:

1. Tadross JA, le Roux CW. The mechanisms of weight loss after bariatric surgery. *Int J Obes*. 2009;33 Suppl 1:S28-32.
2. Richardson BE, Vanderwoude EA, Sudan R, Leopold DA, Thompson JS. Gastric bypass does not influence olfactory function in obese patients. *Obes Surg*. 2012;22(2):283-286.
3. Holinski F, Menenakos C, Haber G, Olze H, Ordemann J. Olfactory and gustatory function after bariatric surgery. *Obes Surg*. 2015;25(12):2314-2320.
4. Hancı D, Altun H, Altun H, Batman B, Karip AB, Serin KR. Laparoscopic sleeve gastrectomy improves olfaction sensitivity in morbidly obese patients. *Obes Surg*. 2016;26(3):558-562.
5. Hummel T, Whitcroft KL, Andrews P, Altundag A, Cinghi C, Costanzo RM, Damm M, Frasnelli J, Gudziol H, Gupta N, Haehner A, Holbrook E, Hong SC, Hornung D, Hüttenbrink KB, Kamel R, Kobayashi M, Konstantinidis I, Landis BN, Leopold DA, Macchi A, Miwa T,

Moesges R, Mullol J, Mueller CA, Ottaviano G, Passali GC, Philpott C, Pinto JM, Ramakrishnan VJ, Rombaux P, Roth Y, Schlosser RA, Shu B, Soler G, Stjärne P, Stuck BA, Vodicka J, Welge-Luessen A. Position paper on olfactory dysfunction. *Rhinology*. 2016 Jan 31;56(1):1-30.

202422

Sniffing – a parafunction of the nose: history, future and medical aspects

**Klaus Vogt**<sup>1</sup>

<sup>1</sup>*Center of Experimental Surgery, Faculty of Medicine, University of Latvia; Riga/Latvia*

*Rhinology – miscellaneous 2, Building M1 Room Σ3, Sept 29, 14.45*

**Background:** Sniffing was the first way for the application of tabaco and was introduced by seafarers from South America to Europe 400 years ago. After the worldwide recession of smoking, sniffing is increasing again in regions with a respective tradition as Bavaria or regions with extended mining. Special tools (“snuff guns”) are in use and the art of tabatieres has a remarkable historical meaning in arts as well as some historical political decisions.

**Principal:** A multicentric study about the incidence of cancer in sniffing people has shown, that here is no significant evidence of a higher incidence in nasal cancer except in smokers using sniff in addition. Sniffing of wood dust or asbest has an increased cancer risiko. The application of drugs is a well known completely different problem.

**Conclusions:** Atypic variations of the anterior nasal mucosa may also be caused by intensive sniffing.

202427

## Expanded Lateral Endoscopic-Assisted Trans-Temporal Fossa Approach to Superior Parapharyngeal Space: A Cadaveric Study

**Abraam Yacoub**<sup>1,2</sup>, Giulia Molinari<sup>1,3</sup>, Lukas Anschuetz<sup>1</sup>, Marco Caversaccio<sup>1</sup>

<sup>1</sup>Department of Otorhinolaryngology, Head and Neck Surgery, Inselspital, Bern University Hospital, University of Bern, Bern, Switzerland; <sup>2</sup>Department of Otorhinolaryngology, Head and Neck Surgery, Ain Shams University Hospital, Ain Shams University, Cairo, Egypt; <sup>3</sup>Department of Otorhinolaryngology, Head and Neck Surgery, University Hospital of Modena, Modena, Italy

*Skull base surgery 1, Building M1 Room Σ4, Sept 28, 14.45*

**Background:** The endoscopic transpterygoid approach provides a unique corridor to the paramedian skull base. However, the surgical access to the superior parapharyngeal space (PPS) remains challenging. This study proposes a minimally invasive lateral endoscopic-assisted approach to the superior PPS.

**Methodology:** Six Thiel-fixed silicone-injected cadaveric heads (12 sides) were dissected. The infratemporal fossa (ITF) and PPS were examined under stereotactic neuronavigation guidance. Following a predetermined protocol, the feasibility and anatomical considerations of the proposed approach were analysed.

**Results:** The neurovascular contents of the ITF were exposed after resection of the lateral pterygoid muscle. Advancement to the PPS was achievable after planning the endoscopic corridor through the triangular area between the inferior alveolar nerve, the inner surface of the ascending ramus of the mandible, and the auriculotemporal nerve. The styloid diaphragm was a guiding landmark to localize the carotid sheath. Dissection of the pre- and post-styloid PPS compartments was performed.

**Conclusions:** The proposed approach provides adequate access to the posterior ITF and superior PPS without bone drilling or traversing important neurovascular structures. The technique may be used alone in lesions confined to the ITF and superior PPS or in combination with other endonasal, transoral or cervical approaches in more extensive pathologies.

**Key words:** Infratemporal fossa, Parapharyngeal space, Lateral endoscopic approach, Minimally invasive, Skull base surgery

202440

## Simulation of nasal airflow for validation of measurement techniques and to understand nasal air flow

**Klaus Vogt**<sup>1</sup>, Walter Koch<sup>2</sup>, Lucas van Boemmel<sup>1</sup>, Maximilian Sckell<sup>3</sup>, David Land<sup>4</sup>

<sup>1</sup>Center of Experimental Surgery, Faculty of Medicine, University of Latvia, Riga/Latvia; <sup>2</sup> Steinbeis Innovation Transfer Centre for Medical and Cultural Heritage Informatics, Graz, Austria; <sup>3</sup> Nanotec GmbH, Feldkirchen bei München, Germany; <sup>4</sup> Embex GmbH, Freiburg Bsg., Germany

*Technological advances 2, Building M1 Room Σ2, Sept 27, 14.45*

**Background:** The interpretation of rhinomanometric findings, testing the precision of measurement equipment and the measurement of pressure differences in different sections of the nasal cavity – in particular in models generated by CFD -need precise simulation of the air stream by simulators

**Methodology/Principal:** As a further development of formerly used simulators 2 different principles have been realized. One possibility is the generation of the air flow by a pump driven by step motors (linear actuators), which allow the precise reproduction of a human breath by using measured spirometric data together with standardized resistors (diaphragms, tubes). Another possibility is the application of a Francis turbine which combines radial and axial flow concepts. In combination with a cross valve the whole respiration cycle can be simulated.

**Results:** Beside of the testing of rhinomanometers as medical products it could be shown, that the “tube type” and “diaphragm type” as observed as rhinomanometric findings are reproducible . For an instrument measuring the Just Noticeable Difference of the sensation of obstruction suitable resistors could be developed.

**Conclusions:** Within the framework of developing the entity of a physically based diagnostic of the nasal air stream and its morphological analysis airflow simulators are an important tool for verification.

# Isolated paranasal sinus fungus ball. Pathogenetic, diagnostic and therapeutic considerations. Presentation of our case series.

G.P. Kotsis<sup>1</sup>, **A. Tsoumaridou<sup>2</sup>**, G. Kokolakis<sup>1</sup>, A. Bouladaki<sup>1</sup>, A.C. Sakellaris<sup>1</sup>

<sup>1</sup>Otorhinolaryngology/ Head & Neck Surgery Department, "Saint Savvas" General Anti-Cancer and Oncological Hospital of Athens, Athens, Greece; <sup>2</sup>Otorhinolaryngology/ Head & Neck Surgery Department, "Korgialenio-Benakio" General Hospital of Athens (Greek Red Cross Hospital), Athens, Greece

*Miscellaneous 1, Building M1 Room Σ1, Sept 28, 11.45*

**Background:** Fungus ball, the non-invasive and commonest form of fungal sinusitis, is described mostly in immunocompetent and non-atopic patients. Isolated or not, identification remains difficult, as symptoms are usually vague and major predisposing factors are yet to be found. Imaging findings arise the suspicion and surgery sets the final diagnosis.

**Methodology/Principal:** We collected data of patients admitted to our hospital during the last 3 years and were diagnosed with isolated paranasal sinus fungus ball (IPSFB), comparing demographics, previous medical history, clinical, radiological and intraoperative findings.

**Results:** 4 cases of IPSFB were treated in our clinic. 3 out of 4 were located in sphenoid and one in maxillary sinus. All patients were women, immunocompetent, aged 34-70 years, complaining of diffuse headache and mentioned chronic use of intranasal steroids. After imaging with HRCT scan, all cases were submitted to endoscopic sinus surgery with complete removal of the pathology. Patients were prescribed post-op saline irrigation only. There were no complications. All are found disease-free 4-30 months postoperatively.

**Conclusions:** IPSFBs are often misdiagnosed, as clinical features may be misleading. Based on imaging findings, endoscopic surgery remains a safe and efficient choice for treatment. Further pathogenetic process understanding will improve the management, from prevention to therapy.

**Key words:** Mycoses, Mycetoma, Sinusitis, Headache Disorders, Secondary

## Literature

1. Seo MY, Lee SH, Ryu G, Hong SD, Kim HY, Dhong HJ et al. Clinical pattern of fungal balls in the paranasal sinuses: our experience with 70 patients. *Eur Arch Otorhinolaryngol.* 2019 Apr;276(4):1035-1038
2. Lim HS, Yoon YH, Xu J, Kim YM, Rha KS. Isolated sphenoid sinus fungus ball: a retrospective study conducted at a tertiary care referral center in Korea. *Eur Arch Otorhinolaryngol.* 2017 Jun;274(6):2453-2459.
3. Kim DW, Kim YM, Min JY, Kim JW, Kim JK, Mo JH et al. Clinicopathologic characteristics of paranasal sinus fungus ball: retrospective, multicenter study in Korea. *Eur Arch Otorhinolaryngol.* 2020 Mar;277(3):761-765.
4. Bernardini E, Karligkiotis A, Fortunato S, Castelnovo P, Dallan I. Surgical and pathogenetic considerations of frontal sinus fungus ball. *Eur Arch Otorhinolaryngol.* 2017 Jun;274(6):2493-2497.
5. Wang LL, Chen FJ, Yang LS, Li J. Analysis of pathogenetic process of fungal rhinosinusitis: Report of two cases. *World J Clin Cases.* 2020 Jan 26;8(2):451-463.

## Advanced endonasal endoscopic approaches for sinonasal and anterior skull base tumors. Three extremely rare cases from an oncological referral center.

G.P. Kotsis<sup>1</sup>, **A. Tsoumaridou<sup>2</sup>**, G. Kokolakis<sup>1</sup>, A. Bouladaki<sup>1</sup>, A.C. Sakellaridis<sup>1</sup>, A.C. Miliadou<sup>3</sup>

<sup>1</sup>Otorhinolaryngology/ Head & Neck Surgery Department, "Saint Savvas" General Anti-Cancer and Oncological Hospital of Athens, Athens, Greece; <sup>2</sup>Otorhinolaryngology/ Head & Neck Surgery Department, "Korgialenio-Benakio" General Hospital of Athens (Greek Red Cross Hospital), Athens, Greece; <sup>3</sup>Radiation Oncology Department, "Saint Savvas" General Anti-Cancer and Oncological Hospital of Athens, Athens, Greece

*Sinonasal malignancy 1, Building M1 Room Σ3, Sept 27, 14.45*

**Background:** Traditional open surgeries are replaced lately by minimally invasive endoscopic approaches due to the development of imaging techniques, navigation systems and cumulative surgical experience. Numerous studies demonstrate their safety, low morbidity and ability to intervene in early stages, increasing survival rates.

**Methodology/Principal:** We collected data of patients with difficult to approach sinonasal and anterior skull base tumors treated with advanced endonasal endoscopic approaches during the past three years.

**Results:** We present three cases of extremely rare tumors. Case 1: Man, 83 years old, with a recurrent synovial sarcoma of nasal septum, underwent endoscopic resection of quadrangular cartilage, lower part of perpendicular plate and middle turbinate. Case 2: Man, 76 years old, with extended melanoma of the right nasal cavity underwent endoscopic medial maxillectomy. Case 3: Man, 66 years old, with a tumor located in the left pterygopalatine fossa, underwent transnasal endoscopic excision. The later was finally diagnosed with IgG4 syndrome. All tumors were resected in negative margins. There were no intra/postoperative complications. On their regular follow-up, all patients remain free of disease after 18, 11 and 30 months respectively.

**Conclusions:** When oncological principles are not violated and vital neurovascular structures are kept intact, endoscopic endonasal surgery can replace classic techniques.

**Key words:** Paranasal Sinus Neoplasms, Skull Base Neoplasm, Endoscopic Surgical Procedures

### Literature

1. Lund V, Stammberger H, Nicolai P. European position paper on endoscopic management of tumours of the nose and paranasal sinuses and skull base. *Rhinology*. 2010. 22(22). 30-31.
2. Kotsis GP, Peteinaki AP, Sakellaridis AC, et al. Immunoglobulin G4-related Disease: Presentation of the First Case with Isolated Pterygopalatine Fossa Involvement. *Cureus*. 2019 May. 11(5): e4719
3. Rawal RB, Farzal Z, Federspiel JJ, Sreenath SB, Thorp BD, Zanation AM. Endoscopic Resection of Sinonasal Malignancy: A Systematic Review and Meta-analysis. *Otolaryngol Head Neck Surg*. 2016 Sep;155(3):376-86.
4. Roxbury CR, Ishii M, Richmon JD, Blitz AM, Reh DD, Gallia GL. Endonasal Endoscopic Surgery in the Management of Sinonasal and Anterior Skull Base Malignancies. *Head Neck Pathol*. 2016 Mar;10(1):13-22.
5. Kasemsiri P, Prevedello DM, Otto BA, Old M, Ditzel Filho L, Kassam AB et al. Endoscopic endonasal technique: treatment of paranasal and anterior skull base malignancies. *Braz J Otorhinolaryngol*. 2013 Nov-Dec;79(6):760-79.

202468

## Clinicopathological Evaluation and Radiological Features of Unilateral Sinus Disease

**Awatif Alyousuf<sup>1</sup>**, Catherine Rennie, Hesham Saleh<sup>1</sup>

<sup>1</sup>*Department of Otolaryngology-Head and Neck, Charing Cross, Healthcare NHS Trust, LONDON, UK.*

*Miscellaneous 2, Building M1 Room Σ2, Sept 29, 11.45*

**Background:** Unilateral sinonasal disease is a common presentation. Patients often present with unilateral polyps on clinical examination, or total opacification of the sinus is detected in imaging. Unlike bilateral disease it is more likely to present sinister pathology until proven otherwise.

**Objective:** To analyse the clinical presentation, radiological and histopathological features of unilateral sinus disease.

**Method:** A retrospective review on patients with unilateral sinus disease over a 4 year period, mucous retention cysts were excluded.

**Result:** 60 patients identified with unilateral sinus pathology, male gender was predominant (M:F 36:24). Nasal congestion was the commonest presenting symptom accounting for 82% of cases, followed by purulent discharge in 42%. The maxillary sinus was the most affected in 81% with left side being predominantly involved in 52%. Seven cases were incidental findings picked up on imaging for other reasons. The majority of our cases were histologically diagnosed with inverted papilloma 43%, followed by inflammatory disease 25%, fungus disease 16%, and adenocarcinoma 2%. In 2% of cases with inverted papilloma histology revealed malignant transformation. 4% of the patients in the series had recurrent disease.

**Conclusion:** Unilateral sinus disease requires careful pre-operative diagnosis and histopathological assessment, in our series 4% had malignancy.



## Management of the orbit during endoscopic sinonasal tumour surgery – consecutive series of 14 patients

**Todor M. Popov<sup>1</sup>**, Stoyan Dimitrov<sup>1</sup>, Kiril Peev<sup>1</sup>, Nezi Nizamova<sup>1</sup>, Julide Kasaboglu<sup>1</sup>, Tsvetomir Marinov<sup>2</sup>

<sup>1</sup>Department of ENT, Medical University of Sofia, Sofia, Bulgaria; <sup>2</sup>Department of Anesthesiology and Intensive Care, Medical University of Sofia, Sofia, Bulgaria

*Orbital surgery 1, Building M2 CR3, Sept 29, 11.45*

**Background:** The aim of our study is to report intraoperative management of the orbit during endoscopic resection of benign and malignant sinonasal tumours and subsequent postoperative results.

**Methodology/Principal:** A total of fourteen patients met the main inclusion criteria – endoscopic resection should incorporate at least one subsite of the orbital interface. All patients underwent surgery at University Hospital "Queen Jovanna-ISUL", Medical University - Sofia, Bulgaria during the period 2016-2019 - single surgeon consecutive series.

**Results:** Squamous cell carcinoma (35.7%) and inverted papilloma (42.8%) comprise the majority of the cases. Most commonly surgical resection included lamina papyracea (85.7%), the inferomedial orbital strut (42.8%) and floor of the orbit (21.4%). Diplopia (28.5%) and exophthalmos (42.8%) were the most common preoperative ophthalmologic symptoms, which significantly improved after the surgical resection ( $\chi^2(1) = 0.645$ ,  $p=0.16$ ). Despite the fact that 42.8% of the patients underwent larger resections of the orbital bony interface (two or more anatomical subsites), we report only one case of temporary postoperative diplopia, which resolved in 4 weeks and two cases of mild to moderate enophthalmos.

**Conclusions:** Overall our data suggests that even larger resections of the orbital bony framework could be managed by a purely endoscopic approach with low complication and recurrence rates.

**Key words:** Papilloma, Inverted; Nose Neoplasms; Endoscopy; Orbit; Diplopia

202484

## An audit of the ubiquitous mobile phone as a light source for flexible nasal endoscopy

**EC Rajiah<sup>1</sup>**, K Chapple<sup>1</sup>, SA Hannan<sup>1</sup>, I Kwame<sup>1</sup>

<sup>1</sup>Otolaryngology, Royal National Throat Nose & Ear Hospital, London, UK

*Technological advances 3, Building M1 Room Σ1, Sept 28, 14.45*

**Background:** Flexible nasal endoscopy (FNE) is the mainstay of clinical assessment of the nose and pharynx. In an emergency setting ready access to a light source can be challenging, thereby hindering timely assessment. Here we have audited the use of the mobile phone as a light source compared to the two standard light sources used in current British clinical practice.

**Methodology/Principal:** Thirty consecutive patient encounters involving examination with FNE were audited to compare use of different mobile phones against the standard use of a handheld portable light source or a wired light box. Each modality was assessed in the first 10 patient encounters and the results interrogated against 3 key binary outcomes of satisfactory portability, reliability and rapid availability of the light source.

**Results:** Results showed the portable light source was 100% reliable and portable, but less satisfactory for availability. The wired light box was 100% reliable in all encounters however less satisfactory in portability and availability. The mobile phone was 100% satisfactory as a light source in all modalities.

**Conclusions:** Mobile phones should be considered as a light source for FNE when standard light sources are not readily available. This will aid rapid assessment of patients in emergency setting.

**Key words:** mobile phone; light source; nasal endoscopy

## The challenge of frontal sinus surgical management – case reports

**Cîrstea Anca Ionela<sup>1</sup>**, Berteșteanu Șerban<sup>1,2</sup>, Nițu Liliana<sup>1,2</sup>, Popescu Bogdan<sup>1,2</sup>, Condeescu Mihnea<sup>1,2</sup>, Bejenaru Paula<sup>1</sup>, Antonie Catrinel<sup>1</sup>, Munteanu Gloria<sup>1</sup>, Popa Teodora<sup>1</sup>, Dimcea Alisa<sup>1</sup>, Nedelcu Ruxandra<sup>1</sup>, Diaconu Teodora<sup>1</sup>, Taher Bianca<sup>1</sup>, Rujan Simona<sup>1</sup>, Sirețeanu Luiza<sup>1</sup>, Othman Amer<sup>1</sup>, Denisa Mitran<sup>1</sup>, Arjoca Elena<sup>1</sup>, Grigore Raluca<sup>1,2</sup>

<sup>1</sup>ENT Department, "Colțea" Clinical Hospital, Bucharest, Romania; <sup>2</sup>ENT Department, UMF "Carol Davila", Bucharest, Romania

*Rhinology – miscellaneous 3, Building M1 Room Σ1, Sept 27, 11.45*

The complexity of the frontal recess makes many surgeons think twice when it comes to dissect the frontal sinus.

A short reminder of the anatomy of the frontal recess will be present. We will discuss four cases with different pathologies in the frontal sinus and their particular management. The approach was distinct in every case. We proceed with an external approach to resect an osteoma, a combined external-endonasal technique for a mucocele, an endonasal endoscopic approach for an acute rhinosinusitis with periorbital complications and a nasal polyposis with frontal involvement. A preoperative CT was performed for every patient. Patients were followed up postoperatively with periodic nasal endoscopy.

At the long term follow up, the symptoms was completely resolved for all cases with no signs of recurrence in the patient with nasal polyposis.

The frontal sinus and the frontal recess should only be operated if there are symptoms that can be directly connected to the frontal sinus. In order to not fail, the anatomy of this region must be well known.

**Key words:** frontal sinus, frontal recess, anatomy

#### Literature

1. Cummings otolaryngology–head & neck surgery / [edited by] Paul W. Flint, Bruce H. Haughey, Valerie Lund, John K. Niparko, K. Thomas Robbins, J. Regan Thomas, Marci M. Wormald P, ed. 4th Edition. Thieme; 2017
2. Endoscopic Sinus Surgery: Anatomy, Three-Dimensional Reconstruction, and Surgical Technique. Wormald P, ed. 4th Edition. Thieme; 2017
3. Giant osteomas of the ethmoid and frontal sinuses: Clinical characteristics and review of the literature. KE-JIA CHENG, SHEN-QING WANG, and LIN LIN. Oncol Lett. 2013May; 5(5): 1724–1730.
4. Frontal sinus mucocele with orbital complications: Management by varied surgical approaches. Sushil Kumar Aggarwal, Kranti Bhavana, Amit Keshri, Raj Kumar, and Arun Srivastava. Asian J Neurosurg. 2012 Jul-Sep; 7(3): 135–140.

## COEXISTENCE OF CHRONIC RHINOSINUSITIS WITH POLYPOSIS AND OTITIS MEDIA WITH EFFUSION— STUDY OF 100 PATIENTS WITH CRSwNP

**Sandra Wawarczyk-Fröhlich<sup>1,4</sup>**, Iwonna Gwizdalska<sup>1,4</sup>, Aleksandra Dąbkowska<sup>1,4</sup>, Aleksandra Mickielewicz<sup>1,4</sup>, Henryk Skarżyński<sup>1,4</sup>, Piotr H. Skarżyński<sup>1,2,3,4</sup>

<sup>1</sup>World Hearing Center, Otorhinolaryngology Department, Institute of Physiology and Pathology of Hearing, Warsaw/Kajetany, Poland; <sup>2</sup>Department of Heart Failure and Cardiac Rehabilitation, 2<sup>nd</sup> Faculty, Medical University of Warsaw, Poland; <sup>3</sup>Institute of Sensory Organs, Kajetany, Poland; <sup>4</sup>Centre of Hearing and Speech Medincus in Kajetany, Poland

*CRS - diagnosis and investigations 3, Building M1 Room Σ4, Sept 29, 10.15*

**Background:** Otitis media with effusion (OME) can occur in chronic rhinosinusitis with polyposis (CRSwNP), the relationship between this pathology remains unclear. In 2019 we conducted a cross-sectional study of 100 patients with CRSwNP. Our goal was to determine the incidence of OME in patients with CRSwNP to determine if the severity of CRSwNP affects OME.

**Methodology:** The severity of CRSwNP was assessed based on nasal symptoms, nasal endoscopy and Lund-Mackay score. We collected information on the history of otitis media, otoscopy, tonal audiometry and tympanometry.

**Results:** We compared patients with CRSwNP with and without OME. OME was diagnosed in 5 patients. The tympanostomy tube was placed in patients with OME. Hearing improvement was achieved in all patients. All OME patients in our group had an aspirin triad.

**Conclusions:** In our group all patients with OME had an aspirin triad, so it should be assumed that the severity of sinus disease in the form of the aspirin triad can be considered statistically significant in terms of the risk of coexistence of chronic otitis media with effusion.

**Key words:** chronic rhinosinusitis with polyposis, otitis media with effusion

**Dilyana V. Vicheva**<sup>1,2</sup>

<sup>1</sup>Department of Otorhinolaryngology, Medical Faculty, Medical University - Plovdiv, Plovdiv, Bulgaria; <sup>2</sup>Research Institute at Medical University – Plovdiv, Plovdiv, Bulgaria

*Non-allergic rhinitis 1, Building M2 CR2, Sept 28, 11.45*

**Background:** Runny nose is excess drainage produced by nasal and adjacent tissues and blood vessels in the nose. This drainage may range from a clear fluid to thick mucus.

**Methodology/Principal:** Causes of a runny nose include: non-allergic rhinitis, diagnosed if the skin test is negative, but nasal smears show eosinophilia; the vasomotor rhinitis is presenting with clear rhinorrhea (especially in the morning), sneezing, nasal obstruction, negative allergen tests, no elevated IgE in the secretion; the atrophic rhinitis is unknown, but is multifactorial. The other causes are: ARS; CRS; common cold; drug induced rhinitis; rhinitis medicamentosa; rhinitis of pregnancy; honeymoon rhinitis; emotional rhinitis; rhinitis due to hypothyroidism; gustatory rhinitis; non-air flow rhinitis, aging-related rhinitis, dry air; tobacco smoke. Some cases with primary mucus defect and ciliary dyskinesia; immunodeficiency; granulomatous disease; malignancy and structural abnormalities are presenting with rhinitis also.

**Results:** Treatment is difficult and depends on how much it bothers you. For mild cases, home treatment and avoiding triggers may be enough. For more-bothersome symptoms, if either agent alone is not completely effective, then try adding the other drug.

**Conclusions:** In most patients, symptoms are lifelong, and some medication is usually needed on a daily and long-term basis. Patients clearly want treatment options that improve their quality of life.

**Key words:** runny nose, quality of life, treatment.

Literature:

1. Sur DKC, Plesa ML. Chronic Nonallergic Rhinitis. Am Fam Physician 2018; 98:171.
2. Hellings PW, Klimek L, Cingi C, et al. Non-allergic rhinitis: Position paper of the European Academy of Allergy and Clinical Immunology. Allergy 2017; 72:1657.
3. Greiwe J, Bernstein JA. Nonallergic Rhinitis: Diagnosis. Immunol Allergy Clin North Am 2016; 36:289.

## Surgical approach of the orbit when involved in paranasal sinuses pathology

**Grigore Raluca<sup>1,2</sup>**, Cîrstea Anca Ionela<sup>1</sup>, Nițu Liliana<sup>1,2</sup>, Popescu Bogdan<sup>1,2</sup>, Condeescu Mihnea<sup>1,2</sup>, Bejenaru Paula<sup>1</sup>, Antonie Catrinel<sup>1</sup>, Munteanu Gloria<sup>1</sup>, Dimcea Alisa<sup>1</sup>, Nedelcu Ruxandra<sup>1</sup>, Diaconu Teodora<sup>1</sup>, Taher Bianca<sup>1</sup>, Rujan Simona<sup>1</sup>, Nicolaescu Alexandru, Sirețeanu Luiza<sup>1</sup>, Popa Teodora<sup>1</sup>, Berteșteanu Șerban<sup>1,2</sup>

<sup>1</sup>ENT Department, "Colțea" Clinical Hospital, Bucharest, Romania; <sup>2</sup>UMF "Carol Davila", Bucharest, Romania

*Orbital surgery 1, Building M2 CR3, Sept 29, 11.45*

**Background:** Paranasal sinuses are in close contact with orbit this is why the pathology can involve important structure of the orbital content

**Methodology/Principal:** authors present experience regarding inflammatory pathology as well as tumoral involvement of the orbital content.

We are describing specific clinical cases of sinusitis with orbital complication, from chemozitis to orbital abscess and also the treatment, focusing on surgical treatment, endoscopic sinus surgery.

Also authors discuss involvement of the orbit by tumoral pathology, benign or carcinoma. We are discussing the surgical treatment using endoscopic technique with the aid of navigation or open approaches.

**Results:** we summarize local characteristics and results depending on pathology

**Conclusions:** the use of navigation if available when performing endoscopic approaches is useful for the control of sensitive anatomical areas. Still open approaches should be done in selected cases, sometimes with orbital exenteration.

**Key words:** orbit, sinusitis, tumor, neuronavigation, surgery

202516

## Metastatic renal cell carcinoma to the sinonasal cavity: a management challenge due to massive perioperative bleeding

**Aikaterini Tsagkovits<sup>1</sup>**, Shalini Patiar<sup>1</sup>, Jonathan Joseph<sup>2</sup>

<sup>1</sup>ENT Department, The Princess Alexandra Hospital NHS Trust, Harlow, UK; <sup>2</sup>ENT Department, University College London Hospitals NHS Trust, London, UK

*Sinonasal malignancy 1, Building M1 Room Σ3, Sept 27, 14.45*

**Background:** Malignant sinonasal tumours are uncommon, often diagnosed late due to their insidious clinical presentation. Most of these are primary in origin, though metastases to the nose and paranasal sinuses from kidney, lung and breast cancer have been described.

**Methodology:** We present the diagnostic workup and management of a 59-year-old man with unilateral nasal symptoms due to a left expansile maxillary lesion and a history of metastatic renal cell carcinoma and a left antrochoanal polyp with benign histology.

**Results:** Biopsy of the sinonasal lesion revealed renal cell carcinoma metastasis. The patient underwent combined endoscopic and open resection using lateral rhinotomy and Caldwell-Luc approach. Despite preoperative embolisation, there was significant intraoperative bleeding, which required intensive care unit admission. He was discharged and followed up with imaging, which did not reveal any signs of recurrence or residual disease. Second line targeted therapy for metastatic renal cell carcinoma was started as per multidisciplinary team recommendation.

**Conclusions:** Unilateral symptomatology should raise clinical suspicion and prompt specialist referral with urgent imaging. Metastatic renal cell carcinoma is a hypervascular tumour. The surgeon should anticipate significant haemorrhage and take any medical and surgical measure to minimise blood loss and improve patient outcome.

**Key words:** sinonasal neoplasm, renal cell carcinoma, embolisation

202520

## Sinus mucosa manipulation with a novel device - safety and tissue damage assessment

**Isaac Shochat**<sup>1</sup>; Itzhak Braverman<sup>1</sup>

<sup>1</sup>Hillel Yaffe Medical Center, Technion Faculty of Medicine, Haifa, Israel.

*Technological advances 3, Building M1 Room Σ1, Sept 28, 14.45*

**Background:** Current approach to rhinosinusitis offers three main modalities: Medical treatment; sinus surgery; and sinus puncture and lavage, which was used abundantly in the past but has fallen from grace. We aim to find a new way of treating rhinosinusitis, with minimum complications. The current study confronts the problem using the SinuSafe® device and examines its safety on an animal model.

**Methodology/Principal:** A device consists of a thin 1mm, flexible cannula, which enters the narrow & twisted sinuses openings and allows thin nitinol wire to rotate, grinding the mucus, reduces its viscosity thus allowing suction was tested on six ship heads (12 sinuses), as well as on a model consisting of cystic-fibrosis patients mucus and DNA-enriched mucus. Following the procedure, the sinuses were inspected visually and microscopically for damage.

**Results:** We found that a 0.24mm nitinol wire is elastic and durable enough for the task. Rotation of 5000rpm allowed suctioning of the material through the small cannula. No damage was found to the mucosa in the pathologic samples.

**Conclusions:** High-speed rotating 0.24<sub>mm</sub> nitinol wire allowed for non-traumatic suctioning of a model maxillary sinus, further, extensive research is needed to determine the device's safety and efficacy in human population.

**Key words:** Rhinosinusitis, Sinus puncture



**Andreea E. Bejenariu<sup>1</sup>**, Alex I. Milea<sup>1</sup>, Carmen Badea<sup>1</sup>, Codrut Sarafoleanu<sup>1,2</sup>

<sup>1</sup>ENT&HNS Department, "Sfanta Maria" Clinical Hospital, Bucharest, Romani; <sup>2</sup>"Carol Davila" University of Medicine and Pharmacy, Bucharest, Romania

*Facial Pain 1, Building M1 Room Σ3, Sept 27, 11.45*

**Background:** Fibrous dysplasia is a benign bone tumor with a high invalidating and destructive capacity, in which normal bone and marrow are replaced by fibrous tissue. There are two forms of fibrous dysplasia: monostotic, which affects one bone and remains relatively stable, and a polyostotic form, which involves multiple bones . The craniofacial lesions are typically unilateral.

**Methodology:** A retrospective review of 6 patients with craniofacial fibrous dysplasia. This paper provides a comprehensive illustration of craniofacial fibrous dysplasia and the diagnostic methods with different radiological findings. We also highlight the necessity of the surgical treatment or the medical one.

**Results:** Usually, the patients are asymptomatic and the diagnosis is random, they go to the hospital when the tumor extend to adjacent structures. The most common clinical manifestations include: hemicrania, vestibular syndrome and facial asymmetry. All cases were monostotic. Most commonly involved was the sphenoid bone, followed by mandible, maxilla and fronto-temporo-parietal bones.

**Conclusion:** Fibrous dysplasia is a very rare, genetic and nonhereditary illness. Most importantly, each patient can present with variable clinical manifestations and the treatment is concentrated to work out the complications or to reduce the pain. There is no etiological treatment.

**Keywords:** fibrous dysplasia, craniofacial, monostotic, hemicrania



202530

## Paediatric FESS –an 18 month review of elective and emergency cases

**Fazliddin Muradov<sup>1</sup>**, Octavian Konstantin Dirla<sup>1</sup>, Irfan Syed<sup>1</sup>, Anil Joshi<sup>1</sup>, Anastasia Rachmanidou<sup>1</sup>

<sup>1</sup>ENT Department, Lewisham & Greenwich NHS Trust, London, UK

*Paediatric rhinology 1, Building M2 CR3, Sept 28, 11.45*

A retrospective study of all paediatric FESS procedures (elective and emergency) performed in a busy ENT Department in South East London, in the period of 18 months.

We analyse the accuracy of data collection in elective and emergency cases, the indications and timing of surgery as well as outcomes.

A total of 23 paediatric cases (age range 0-18yrs) have been operated, of which 20 were elective and 3 were emergencies.

All elective cases were assessed looking at co-existing factors (ie allergic predisposition, medical treatment, previous surgical procedures). We also looked at the length of waiting time from referral to first appointment, waiting time for radiological investigations as well as total waiting time for surgery.

As paediatric FESS is not common practice, it is rather difficult to streamline the treatment pathway. Waiting times, diagnostic pathway and treatment options were relevant to the first treating doctor and the relevance of the clinic that the patients were seen. Only 3 Emergency FESS procedures have been recorded, which highlights the limitations of systems on non-elective procedures (i.e out of hours surgery, non-permanent nursing staff)

Data comparison is made with data of a previous departmental study and ways of outcome improvements have been identified.

**Key words:** Paediatric Endoscopic Sinus Surgery, Paediatric FESS

### Literature

#### 1) Functional Endoscopic Sinus Surgery in Children Using a Limited Approach

Po-Hung Chang, MD; Li-Ang Lee, MD; Chi-Che Huang, MD; et al Chi-Hsien Lai, MD; Ta-Jen Lee, MD

*Arch Otolaryngol Head Neck Surg.* 2004;130(9):1033-1036

#### 2) Paediatric endoscopic sinus surgery (PESS): Review of the indications

M. Bernal-Sprekelsen , H. Masegur Solench , M. Tomás Barberán

*Rev Laryngol Otol Rhinol.* 2003;124,3:145-150

*Skull base surgery 1, Building M1 Room Σ4, Sept 28, 14.45*

**Background:** Juvenile nasopharyngeal angiofibroma (JNA) is a combined vascular and fibrous neoplasm which arises from the posterior-lateral wall of the nose. Despite being microscopically benign, the tumor frequently exhibits destructive and aggressive behavior. Various staging classification had been suggested, but there is no universal agreement worldwide about the most accepted. Each author takes into consideration different perspective. The dural invasion is one of the most challenging and determinant factor in the management of this tumor. In the literature, there is a great debate regarding this point.

**Methodology:** One hundred sixteen cases (116) cases of JNA, 27 of them were having intracranial extension. Only four of them were with true dural invasion. Endonasal endoscopic approach is used for resection.

**Conclusion:** True dural invasion of JNA does really exist although rare. We describe our experience in dealing with advanced JNA including cases with true intradural extension.

**Rationale & Background:** FESS is a technique aimed to treat pathology in the nose and paranasal sinuses safely and efficiently. Although this surgical technique is not without complications as any other kind of surgeries. Mosher, 1929 stated that any surgery in the ethmoidal region should be simple, but it has proven to be one of the easiest ways to kill a patient. A 1990 survey of nearly 7000 American otolaryngologist showed 0.5% incidence of CSF leak for endoscopic ethmoidectomy, whereas orbital complications was significantly lower. "Kennedy et.al, 1994".

It is possible minimize complications with the following prerequisites: Good knowledge of anatomy& radiology, Learning curve, Good patient selection, adequate strategy for surgery.

**Methodology:** We list a number of complications during our practice in FESS in various sinonasal and skull base pathological lesions including minor and major complications

**Results:** we reported few complications during our FESS practice such as orbital injury, CSF leaks, bleeding. Dealing with these complications was possible but it needs patience, experience and tools.

**Conclusion:** FESS is a safe and efficient technique aimed to treat pathology in the nose and paranasal sinuses. Reported complication rate should be low with experts who should be capable of dealing with these complications.

FESS is a technique aimed to treat pathology in the nose and paranasal sinuses safely and efficiently. Mosher, 1929 stated that any surgery in the ethmoidal region should be simple, but it has proven to be one of the easiest ways to kill a patient. It is possible minimize complications with the following prerequisites: Good knowledge of anatomy& radiology, Learning curve, Good patient selection, adequate strategy for surgery.

We reported few complications during our FESS practice such as orbital injury, CSF leaks, bleeding. Dealing with these complications was possible but it needs patience, experience and tools.

Reported complication rate should be low with experts who should be capable of dealing with these complications.

**Rationale & Background:** FESS is a technique aimed to treat pathology in the nose and paranasal sinuses safely and efficiently. Although this surgical technique is not without complications as any other kind of surgeries. Mosher, 1929 stated that any surgery in the ethmoidal region should be simple, but it has proven to be one of the easiest ways to kill a patient. A 1990 survey of nearly 7000 American otolaryngologist showed 0.5% incidence of CSF leak for endoscopic ethmoidectomy, whereas orbital complications was significantly lower. "Kennedy et.al, 1994".

It is possible minimize complications with the following prerequisites: Good knowledge of anatomy& radiology, Learning curve, Good patient selection, adequate strategy for surgery.

**Material & Methods:** We list a number of complications during our practice in FESS in various sinonasal and skull base pathologies including congenital, inflammatory, malignant lesions...

**Results:** we reported few complications during our FESS practice such as orbital injury like the mere breaching of the periorbital to serious orbital hematoma,, CSF leaks, bleeding of various degrees. Dealing with these complications was possible but it needs patience, experience and

tools and the rapid precise decision.

**Conclusion:** FESS is a safe and efficient technique aimed to treat pathology in the nose and paranasal sinuses. Reported complication rate should be low with experts who should be capable of dealing with these complications.

202539

## Odontogenic sinusitis causing unilateral chronic rhinosinusitis and lessons learnt: A retrospective study with review of literature

Leanne O W Hamilton<sup>1</sup>, Nichola Philp<sup>1</sup>, Siew Min Keh<sup>1</sup>

<sup>1</sup>ENT department, Queen Elizabeth University Hospital, Glasgow, UK

*CRS - surgical management 3, Building M2 CR3, Sept 28, 10.15*

**Background:** To determine the incidence, clinical and radiological presentation, and outcome in patients with chronic odontogenic maxillary sinusitis (OMS).

**Methodology:** A retrospective case series of 80 patients (M=F; mean 50 years) requiring FESS from Jan 2015 to 2019 was performed. Patients were categorized as having unilateral OMS based on clinical history, nasendoscopy finding and sinus CT imaging.

**Results:** A positive dental history was found in 41.3% cases. Positive radiological dental features were identified in 96.2% of CT scans of which a quarter did not have these signs mentioned in their radiology report. 35.8% had attended pre-op, and 13.6% had post-op, dental review. Pre- operative antibiotics were given in 68%. 44% of the positive microbiology swab cultures were polymicrobial, with 56% being single organism species growth, predominantly *staph. aureus*. 72.5% patients had full resolution of their symptoms after FESS, 8.8% were lost to follow up and 17.5% required further treatment.

**Conclusion:** This study highlights the key clinical and radiological features to help the clinician identify odontogenic cases. Recalcitrant group requires more aggressive surgery to remove the infective sump. There needs to be an increase in the utilisation of dental review either pre or post FESS in these patients.

**Key words:** chronic maxillary sinusitis; odontogenic; microbiology

Rationale and background: Invasive fungal sinonasal disease has emerged as a more vital health problem in modern times because of increased travel into/out of endemic areas, immune deficient states; the more prevalent use of long-term, broad-spectrum antibiotic therapy, the poorly-controlled diabetes and of course the increased awareness and improved means of clinical detection and laboratory diagnosis.

Classification into acute and chronic types had evolved. This disease has a high morbidity and mortality rates. Surprisingly, not only adults, who could suffer, but also it may affect immunocompromised children. Unlike adult invasive fungal Rhinosinusitis, the prognosis in the pediatric age group is much better due to many reasons: Normal blood vessels in children, unlike the diseased BV in adults and the acute nature of the underlying disease, which is ready reversible with prompt treatment.

Methodology: children suffered from invasive fungal rhinosinusitis were managed by surgical debridement and anti-fungal drugs.

Conclusion: Invasive fungal rhinosinusitis is a disease entity which can be seen, although rare, in children with suppressed immunity. The early diagnosis and prompt are mandatory to achieve a favorable prognosis.



202541

## Chronic Rhinosinusitis with Nasal Polyposis: Analysis of Risk Factors for Early Versus Late Post Operative Polyp Recurrence

**Aiman Elmograbi**<sup>1</sup>, Yonatan Reuven<sup>1</sup>, Samih Badir<sup>1</sup>, Nimrod Amiti<sup>1</sup>, Ethan Soudry<sup>1</sup>, Gabriel Nakache<sup>1</sup>

<sup>1</sup>*Department of Otolaryngology Head and Neck Surgery, Rabin Medical Center, Petach- Tikva and Sackler Faculty of Medicine, Tel Aviv University, Tel Aviv, Israel.*

*CRS - surgical management 3, Building M2 CR3, Sept 28, 10.15*

**Background:** Endoscopic sinus surgery is the preferred treatment modality for medically refractory chronic rhinosinusitis with nasal polyposis (CRSwNP). Post operative disease recurrence is observed in 40% of patients within 18 months of surgery. Our objective was to analyze risk factors for early (<3months) versus late (>3 months) disease recurrence.

**Methods:** All patients with CRSwNP who underwent endoscopic sinus surgery (ESS) between 2015-2019 were reviewed. Only patients with a minimum follow up of 6 months were included.

**Results:** One hundred eighteen patients were identified. Disease recurrence was observed in 16% of patients. Early recurrence of polyps was observed in 9% of patients while late recurrence was observed in 7% of patients. 47% of patients received post-operative steroid therapy. Analysis of risk factors for early recurrence (asthma, allergy, disease severity) revealed that age below 40 was the only significant risk factor ( $p=0.01$ ) for early recurrence. Interestingly, there was no correlation between postoperative steroid treatment and early or late polyp recurrence ( $p=0.89$ ).

**Conclusion:** Young adults (<40) with CRSwNP are at a higher risk for postoperative disease recurrence. Further research is needed to analyze this age group.

202543

## Update on the microbiology and management of odontogenic sinusitis.

Leanne O W Hamilton<sup>1</sup>; Nichola Philp<sup>1</sup>; **Siew Min Keh**<sup>1</sup>

<sup>1</sup>ENT department, Queen Elizabeth University Hospital, Glasgow, UK.

*CRS - medical management 3, Building M2 CR2, Sept 29, 10.15*

**Background:** Odontogenic sinusitis requires tailored medical and surgical approaches to achieve resolution of symptoms. This paper aims to identify the common causative microbes, antimicrobial prescribing and surgical outcome.

**Method:** Retrospective study of patients having unilateral FESS with odontogenic origin in a secondary ENT unit between 2015- 2019.

**Results:** 80 patients were identified. 68% had tried antibiotic therapy for their symptoms pre FESS. 65% had a microbiology swab taken during surgery, of those, 64% were positive for bacterial culture.

44% of the cultures were polymicrobial, with 56% being single organism species growth. Of the single organism group, 37% were *staph. aureus* only. Anaerobes were present in 41% of the positive cultures, and the remainder were facultative anaerobes. There were 13 different microbial species cultured in total. There was one case of fungal infection. 72.5% had full resolution of their symptoms post FESS, with 17.5% requiring further treatment with antibiotics or surgery.

**Conclusions:** Our study indicates polymicrobial is common in odontogenic sinusitis and surgery is required to achieve complete resolution of symptoms in refractory cases. Removing the infected sump with the inflamed granulation tissue and addressing any pocket of infection in the retromaxillary cell is vital to achieve resolution of symptoms.

**Key words:** chronic unilateral sinusitis; odontogenic; microbiology.

202545

## Postoperative analysis of anterior skull base reconstruction failure after endoscopic carcinologic surgery

**N.Saroul<sup>1</sup>**, L.Montrieul<sup>1</sup>, C.Rumeau<sup>2</sup>, B.Verillaud<sup>3</sup>, V.Patron<sup>4</sup>, C.Righini<sup>5</sup>, G.De Bonnecaze<sup>6</sup>, C.Daveau<sup>7</sup>, G.Mortuaire<sup>8</sup>, T.Mom<sup>1</sup>, L.Gilain<sup>1</sup>

<sup>1</sup>Service d'ORL et Chirurgie Cervico-Faciale, CHU Gabriel-Montpied, Université Clermont-Auvergne, 58 rue montalembert, 63000 Clermont-ferrand, France, <sup>2</sup>Service d'ORL et de Chirurgie Cervico-Faciale, Hôpital de Brabois, 5, rue du Morvan, 54500 Vandoeuvre-lès-Nancy, France., <sup>3</sup>Service d'ORL, Hôpital Lariboisière, AP-HP, Université Paris 7, 2, Rue Ambroise Paré, 75010 Paris, France. , <sup>4</sup>Service d'ORL et de Chirurgie Cervico-Faciale, CHU de Caen, avenue de la Côte de Nacre, 14000 Caen, France. Electronic address: vtromps@yahoo.fr. , <sup>5</sup>Service d'ORL, CHU de Grenoble, PALCROS, CS 10217, 38043 Grenoble cedex 9, France. <sup>6</sup>Service d'ORL et Chirurgie Cervico-Faciale, CHU de Toulouse, Toulouse, France. , <sup>7</sup>Service d'ORL, Hospices Civils de Lyon, Centre Hospitalier Lyon Sud, Université de Lyon, Université Claude Bernard Lyon 1, 69495, Pierre-Bénite, France. , <sup>8</sup>Service d'ORL et de chirurgie cervicofaciale, hôpital Huriez, CHU de Lille, Lille, France.

*Skull base surgery 2, Building M2 CR3, Sept 29, 14.45*

**Objectives:** To standardize the follow-up after carcinologic endoscopic procedure of the anterior skull base and postoperative loss of tightness (LOT) (ie meningeal opening or removal during the procedure and failure of the reconstruction) by retrospective analysis.

**Methodology:** Multicenter retrospective study of endoscopic resection of the anterior skull base with reconstruction and post-operative LOT in adults operated between 2005 and 2018. A questionnaire with 68 questions was sent to the 8 participating center.

**Results:** 28 patients were included. The LOT was observed during the first week for 61%, the second week for 21% and after for 17%. 50% of the LOT were discovered by an isolated CSF (cerebrospinal fluid) leak, in 22% the CSF leak was associated with a meningitis and in 28 % there was no CSF leak (pneumencephaly meningitis, brain abscess). The LOT was treated in 50% of the case with a surgical procedure and in 50% with a medical procedure (lumbar puncture) with similar efficacy.

**Conclusion:** After resection and reconstruction of the anterior skull base, systematic monitoring and imaging appears to be indicated during the first week postoperatively. Management of the LOT seems to depend on the extent of the leak, but medical treatment seems to be effective.

**Key words :** CSF leak, skull base reconstruction, follow up, sinonasal cancer surgery

202582

A novel technique for nasal septal perforation repair: greater palatine artery pedicled flap. Radiological study and case series.

**Franklin Mariño-Sánchez<sup>1</sup>**, Alfonso Santamaría-Gadea<sup>1</sup>, Miguel Vaca<sup>1</sup>

<sup>1</sup>Rhinology and Skull Base Unit, Otorhinolaryngology Department, Ramón y Cajal University Hospital. Madrid, Spain.

*Septal and turbinate surgery 1, Building M2 CR3, Sept 28, 14.45*

The abstract should not exceed 200 words. The abstract is conceptually divided into three or four sections.

**Background:** The greater palatine artery (GPA) is one of the main vessels supplying the nasal septum. We recently described the use of a GPA flap to reconstruct a nasal septal perforation (NSP). This radiological study explores the feasibility and limits of using a GPA flap for an anterior NSP repair.

**Methodology/Principal:** We describe our technique for repairing anterior-most NSP. Radiological measurements of the GPA flap and their limits were analysed. Additionally, a cohort of five patients who underwent reconstruction of a NSP with a GPA flap was included. Patients were followed up for 60-279 days.

**Results:** The radiological study of 150 nasal cavities showed a  $31.5 \pm 2.7$  cm<sup>2</sup> maximum flap area. Taking into account the retraction process (30%), the remaining area was  $22.0 \pm 1.9$  cm<sup>2</sup>. The septal area anterior to the GPA was  $6.1 \pm 2.1$  cm<sup>2</sup>. The septal portion of the flap was larger than the area anterior to the GPA pedicle in all cases. Complete NSP repair was achieved in all 5 patients. All cases of NSP remained closed during the follow-up.

**Conclusions:** The unilateral GPA pedicled flap is a useful technique suitable for the reconstruction of anterior-most perforations that are difficult to cover with other endonasal techniques.

**Key words:** Septal perforation, septum reconstruction, greater palatine artery, endoscopic flap, endoscopic surgery.

202592

## Application of endoscopic craniotomy in the approach of anterior skull base lesions – case series.

**Nurdin A.**, Oliveira V., Silva C., Lança B., Eça T., Rodrigues P., Nicolau A., Martins P., Luís L.

*Otorhinolaryngology Department Hospital de Santa Maria, Lisbon, Portugal*

*Skull base surgery 1, Building M1 Room 24, Sept 28, 14.45*

**Background:** Endoscopic endonasal surgery have markedly progressed in the last decade. Surgical indications have been extended to address extensive benign and malignant skull base tumors. Transnasal endoscopic craniotomy have numerous advantages in comparison to gold standard transfacial approach, namely absence of postoperative scar or facial deformity, improved intraoperative visualization of anatomic structures and tumor extension and lower surgical morbidity and mortality.

**Methodology/Principal:** Retrospective study of seven patients submitted to transnasal endoscopic craniotomy in a tertiary hospital during the last 3 years. Indications were reviewed and surgical techniques reported.

**Results:** We present a consecutive series of 7 patients submitted to transnasal endoscopic craniotomy (5 males and 2 females, with a mean age of 51 years old). The pathologies included juvenile ossifying fibroma, neurofibroma with anterior fossa extension (2 cases), intestinal-type sinonasal adenocarcinoma, small cell neuroendocrine carcinoma, biphenotype sinonasal sarcoma and fibrous dysplasia of the anterior skull base. All patients underwent multilayer reconstruction of the defect using different techniques. Total resection was achieved in all cases. Postoperative CSF leak with pneumocephalus occurred in one case and frontal recess stenosis in another.

**Conclusions:** Transnasal endoscopic craniotomy is a safe and viable approach for resection of sinonasal lesions with intracranial extension with low morbidity.

**Key words:** Transnasal endoscopic craniotomy, sinonasal tumors, skull base lesions,

### Literature

Moya-Plana A, Bresson D, Temam S, Kolb F, Janot F, Herman P., Development of minimally invasive surgery for sinonasal malignancy, Eur Ann Otorhinolaryngol Head Neck Dis. 2016 Dec;133(6):405-411

Smruti K., Patel , Mickey L. Smith, Osamah J. Choudhry, Jean Anderson Eloy, James K. Liu, Endoscopic Endonasal Transcribriform Approach for Anterior Skull Base Tumors Involving the Cribriform Plate: Indications, Techniques, and Results in 13 Patients, Journal of Neurological Surgery Part B: Skull Base,

202593

## Endonasal Endoscopic Approach for Resection of Glomangiopericytoma: Our Technique

**Nuridin, A.**, Oliveira, V., Silva C., Rodrigues P., Fernandes A., Serras D., Martins P., Luís L.

*Otorhinolaryngology Department Hospital de Santa Maria, Lisbon, Portugal*

*Benign nasal tumours 1, Building M1 Room Σ3, Sept 29, 10.15*

**Background:** Glomangiopericytoma (GP) is a rare unique tumor originating from perivascular modified myoepithelial cells. These lesions are categorized as borderline and low malignancy potential tumors by WHO classification. Despite high recurrence, after complete surgical resection an overall good prognosis is usually achieved.

**Methodology/Principal:** Discuss the diagnostic workup, imaging and surgical approach of GP and review of the literature.

**Results:** Case report of a 21-year-old female patient with 1-month history of unilateral nasal obstruction and recurrent epistaxis. A reddish tumor filling the left nasal cavity was identified under endoscopic examination. Imaging showed an extensive lesion with erosion of the bony inferior turbinate and extension into the choana and nasopharynx. Due to recurrence a second transnasal approach was needed to achieve a complete resection. Case report of a 79-year-old male with 2-years unilateral nasal obstruction. Imaging documented the presence of an extensive lesion with implantation on the sphenoid rostrum. The patient was submitted to surgery by a bi-nostril approach to gain access to the area of implantation allowing a complete resection.

**Conclusions:** Complete resection of GP by endonasal endoscopic approach is feasible with very low morbidity. Regular post-operative follow-up is recommended in order to diagnose a possible recurrence.

**Key words:** Glomangiopericytoma, unilateral nasal obstruction, endonasal endoscopic approach, recurrence.

Wang C-C. Glomangiopericytoma of Nasal Cavity: A Rare Sinonasal Perivascular Tumor. JMS. Mathematical Association of America; 2013, Oct 1;2(33):107–11

Tessema B, Eloy JA, Folbe AJ, Anstead AS, Mirani NM, Jourdy DN, et al. Endoscopic management of sinonasal hemangiopericytoma., Otolaryngology - Head and Neck Surgery. SAGE Publications; 2012, Mar;146(3):483–6.

Jung ES, Yang S-W, Kim J-H, Kim SW. A case of glomangiopericytoma involving the orbital wall. Ear Nose Throat J. 2013 Apr;92(4-5):E13–5.

Oliveira, V. M., Gilberto, N., Marques, L., Almeida, G. N., Silva, D. R., & Escada, P. A. (2018). Tratamento endoscópico de glomangiopericitoma localmente invasivo pós-embolização. Caso clínico e revisão da literatura. Revista Portuguesa De Otorrinolaringologia E Cirurgia De Cabeça E Pescoço, 55(4), 205-210.

202594

## Intranasal steroid use and satisfaction in allergic rhinitis: A cross-sectional study from an Asian perspective.

**Bryan W W Lee<sup>1</sup>**, Chrisanda S Lee<sup>2</sup>, Eugene Lim<sup>3</sup>, Alex C Tham<sup>1,2,3</sup>

<sup>1</sup>Lee Kong Chian School of Medicine, Nanyang Technological University, Singapore, <sup>2</sup>Department of Otorhinolaryngology, Tan Tock Seng Hospital, Singapore, <sup>3</sup>Yong Loo Lin School of Medicine, National University of Singapore

*Allergic Rhinitis 1, Building M1 Room Σ3, Sept 28, 10.15*

**Background:** Intranasal steroid (INS) is the most effective medication class for controlling allergic rhinitis (AR) symptoms, however its effectiveness is limited by patient compliance. Previous studies have explored INS use, compliance, satisfaction and experience. There is, however, no Asian study on these factors in entirety. We aim to analyse the factors that affect compliance to INS from an Asian perspective.

**Methodology:** This is a prospective cross-sectional study on 63 AR patients in a tertiary hospital. Recruited patients were administered a questionnaire to collect data about symptoms, INS use and concerns they may have. Statistical analysis was performed using SPSS.

**Results:** The overall compliance rate is 65.1%. Eighty-four percent and 73.0% found it effective and worth using INS respectively. Non-compliance was associated with sensory attributes, younger age, forgetfulness, and perceived lack of worth in using INS. The top 3 most frequent sensory attributes experienced by patients include throat rundown (30.2%), immediate taste (20.6%) and aftertaste (20.6%). There was a significant difference between brands of INS and sensory attributes experienced ( $p=0.016$ ) but not side effects ( $p=0.115$ ).

**Conclusions:** Identifying risk factors for non-compliance to INS can help healthcare providers address difficulties faced by patients and hence increase compliance, allowing better control of AR.

**Key words:** Allergic Rhinitis, Intranasal Steroids, Compliance

(200 words)

**Walter Koch**<sup>1</sup>, Dietmar Rafolt<sup>2</sup>, Gerhard Ranner<sup>3</sup>, Jochen Schachenreiter<sup>4</sup>

<sup>1</sup> Steinbeis Innovation Transfer Centre for Medical and Cultural Informatics, Graz, Austria; <sup>2</sup> Medical University Vienna, Austria; <sup>3</sup>CT/MR Zentrum Privatklinik Kreuzschwestern, Graz, Austria; <sup>4</sup>Ordination Schachenreiter, Graz, Austria

*Technological advances 2, Building M1 Room Σ2, Sept 28, 10.15*

**Background:** Computer simulation (CFD) of the nasal airflow is topic of tons of scientific publications but still is not used as a standard tool for diagnostic purposes. Since a solution of the governing equations could consume much computer power an alternative in setting up high quality physical experiments was recently investigated [1].

**Methodology/Principal:** Using artificial intelligence based methods (deep learning, convolutional networks) the image segmentation of CT scans and reconstruction of high quality models of the nasal cavities can be done automatically in minutes. This approach allows the generation and additive manufacturing of a lot of 3D models for research and statistical analysis for example when trying to set up an average geometry of nasal cavities [2].

**Results:** The Rhinodiagnost Project delivered a Nasal Air Flow Simulator (NAS) which in combination with 3D printed models of the human nasal cavities provides an excellent tool for investigation of especially time dependent airflow simulation of the upper respiratory tract. The NAS system is based on low cost components, can be accessed as (edge) computing node [3] in the internet and is able to deliver large data for research using cloud based systems.

**Key words:** nasal airflow; edge computing; simulation tool; microelectronics; CFD

#### Literature

- [1] Marian Staggl, *Experimentelle und numerische Untersuchung der Luftströmung in der Nasenhaupthöhle*. Master Thesis, Technical University Graz, Austria (2019)
- [2] Brüning, J., Hildebrandt, T., Heppt, W. et al. *Characterization of the Airflow within an Average Geometry of the Healthy Human Nasal Cavity*. Sci Rep 10, 3755 (2020).
- [3] B. Varghese, N. Wang, S. Barbhuiya, P. Kilpatrick and D. S. Nikolopoulos, "Challenges and Opportunities in Edge Computing," 2016 IEEE International Conference on Smart Cloud (SmartCloud), New York, NY, 2016, pp. 20-26.



## Optimising a paediatric rhinology service – our experience

**Krishan Lodhia<sup>1</sup>**, Shifan Xie<sup>1</sup>, Karanjeet Sagoo<sup>1</sup>, Amtul Sami<sup>2</sup>, Irfan Syed<sup>2</sup>, Anastasia Rachmanidou<sup>2</sup>

<sup>1</sup>King's College London Medical School, London, UK, <sup>2</sup>ENT Department, Lewisham & Greenwich NHS Trust, London, UK

*Paediatric rhinology 1, Building M2 CR3, Sept 28, 11.45*

Aim of the study is to establish a clear pathway for managing paediatric patients with nasal symptoms (rhinitis/rhinosinusitis), starting from a general paediatric clinic referral base.

Previous departmental Audit demonstrated long waiting times in receiving optimal medical and surgical treatment. The study identifies and corrects inefficiencies.

A case note review approach was employed. A random sample of 60 participants completed the validated questionnaire. A database was developed to assess consistency of the indications for intervention and reported outcomes.

9 patients were discharged 5 were placed on surgical waiting list and subsequently had surgery, 46 are still in review. 21 had ear related problems, 5 have an unclear management plan. Of the 19 that presented with nasal symptoms, 3 are undergoing ongoing treatment, 9 have an unclear management plan, 1 had also throat problems and 2 were inappropriately referred.

Based on findings, we developed clear algorithms in identifying patients who need prolonged medical treatment or surgical intervention. Whilst, it is challenging to streamline a paediatric rhinology service, there are strategies to increase efficiency: A one-stop clinic with nasendoscopy and skin prick testing, prompt treatment with senior input and telephone follow up is the way forward for effective management of paediatric rhinitis/rhinosinusitis.

**Key words:** Paediatric Rhinitis, Paediatric Rhinosinusitis, Skin-prick testing,

#### Literature

- I. International Study of Asthma and Allergies in Childhood (ISAAC) - 2015
- II. Paediatric rhinitis: position paper of the European Academy of Allergy and Clinical Immunology - [G. Roberts](#) [M. Xatzipsalti](#) [L. M. Borrego](#) [A. Custovic](#) [S. Halken](#) [P. W. Hellings](#) [N. G. Papadopoulos](#) [G. Rotiroti](#) [G. Scadding](#) [F. Timmermans](#) [E. Valovi](#)

## Is nasal compliance predictive of CPAP observance in patients with severe OSA? CRISTAL study

Emeline Malheiro<sup>1,2</sup>, Laurent Boyer<sup>1,3,4</sup>, Françoise Zerah Lancner<sup>1,3,4,5</sup>, Florence Canouï-Poitrine<sup>1,4</sup>, Marcel Filoche<sup>3,4,5</sup>, Bruno Louis<sup>3,4,5</sup>, André Coste<sup>1,2,3,4</sup> \*\*, Ala Covali<sup>1\*\*</sup>, **Emilie Béquignon**<sup>1,2,3,4\*\*</sup>

<sup>1</sup>AP-HP, Hôpital Henri Mondor, Créteil, 94010, France;; <sup>2</sup> ENT department, Centre Hospitalier Intercommunal de Créteil, , Créteil, 94010, France;; <sup>3</sup>INSERM, U955, Créteil, 94010, France;

<sup>4</sup>Université Paris-Est, Faculté de Médecine, Créteil, F-94010, France;; <sup>5</sup>CNRS, ERL 7000, Créteil, 94010, France;

\*\*These authors have contributed equally to this work

*Snoring and OSA 1, Building M2 CR2, Sept 28, 14.45*

**Background:** Observance of CPAP treatment remains a challenge and nasal poor tolerance is frequently observed. We evaluated if nasal compliance could be predictive of CPAP poor observance.

**Methodology :** Prospective monocentric observational study including patients with severe OSA (AHI $\geq$ 30) under CPAP treatment. Before CPAP introduction (D0), each patient had a complete rhinologic examination including endoscopy, rhinomanometry and acoustic rhinometry with nasal compliance measurements in each nasal fossa with increasing levels of positive pressure of CPAP. All patients were evaluated after 3 months of CPAP treatment (D90), especially regarding observance of CPAP, tolerance of nasal mask, Epworth and CES-D score.

**Results :** 91 out of 161 patients included (65.9%) had a good CPAP observance ( $\geq$ 4 hours/night). Initial AHI ( $p=0.004$ ), highest D0-D90 decrease in Epworth score ( $p=0.006$ ), lowest D0 CES-D score ( $p=0.019$ ) and good tolerance of nasal mask ( $p<0.0001$ ) were predictive of CPAP observance. Concerning nasal items, CPAP observance was significantly better in patient with nasal resistance below 4 cmH<sub>2</sub>O/L/s ( $p=0.028$ ), but there was no difference in CPAP observance regarding nasal compliance, nasal valve collapse or nasal deformities.

**Conclusion :** Nasal compliance measured with positive nasal pressure is not predictive of CPAP poor observance while low nasal resistance is associated with good CPAP observance.

**Key-words :**

- CPAP
- CPAP
- Observance
- Nasal Compliance
- Nasal Résistance

## Transcription factors gene expression in chronic rhinosinusitis with and without nasal polyps

**Tanja K. Soklic**<sup>1,2</sup>, Matija Rijavec<sup>3</sup>, Mira Silar<sup>3</sup>, Ana Koren<sup>3</sup>, Izidor Kern<sup>3</sup>, Irena Hocevar-Boltezar<sup>1,2</sup> and Peter Korosec<sup>3</sup>

<sup>1</sup>Department of Otorhinolaryngology and Head & Neck Surgery, University Medical Centre, Ljubljana, Slovenia, <sup>2</sup>University of Ljubljana, Faculty of Medicine, Ljubljana, Slovenia, <sup>3</sup>University Clinic of Respiratory and Allergic Diseases Golnik, Golnik 36, 4204 Golnik, Slovenia

*CRS – pathophysiology 2, Building M1 Room Σ1, Sept 29, 10.15*

**Background:** We aimed to evaluate the master transcription factors gene expression levels of T cell subtypes in chronic rhinosinusitis with nasal polyps (CRSwNP) and chronic rhinosinusitis without nasal polyps (CRSsNP) that could represent new, up-stream targets for topical DNzyme treatment.

**Methods:** 22 newly diagnosed CRS patients (14 CRSwNP and 8 CRSsNP) were prospectively biopsied and examined histopathologically. Gene expression levels of T-box transcription factor (T-bet, TBX21), GATA binding protein 3 (GATA3), Retinoic acid-related orphan receptor C (RORC) and Forkhead box P3 (FOXP3) were analyzed by real-time quantitative polymerase chain reaction (RT-qPCR).

**Results:** Eosinophilic CRSwNP was characterized by higher level of GATA3 gene expression compared to noneosinophilic CRSwNP (0.7 (0.6-1.3) vs. 0.3 (0.1-0.4),  $p=0.02$ ). In CRSsNP in comparison to CRSwNP, we found simultaneous upregulation of T-bet, GATA3 and RORC gene expression levels: 7.9 (4.4-11.8) vs. 1.6 (0.5-2.4),  $p=0.0003$ ; 4.1 (2.3-9.6) vs. 0.6 (0.3-0.8),  $p=0.0003$ ; 6.9 (3.8-13.3) vs. 1.7 (0.5-4.0),  $p=0.006$ , respectively.

**Conclusions:** In eosinophilic CRSwNP, we confirmed the type 2 inflammation. In CRSsNP, we unexpectedly found simultaneous upregulation of T-bet and GATA3 that is currently unexplained; however, it might originate from activated CD8+ cells in CRSsNP. The elevated RORC as a sign of type 3 inflammation in CRSsNP could serve as a marker to for anti-IL17 treatment.

**Key words:** Chronic rhinosinusitis; Nasal polyps; Th1 cells; Th2 Cells; Th17 Cells; Transcription factors

202664

## Rhinogenic headache and facial pain diagnosis and surgical treatment at University medical centre Ljubljana, Slovenia

**Tanja K. Soklic**<sup>1,2</sup>, Jure Urbancic<sup>1,2</sup>

<sup>1</sup>Department of Otorhinolaryngology and Head & Neck Surgery, University Medical Centre, Ljubljana, Slovenia,

<sup>2</sup>University of Ljubljana, Faculty of Medicine, Ljubljana, Slovenia

*Facial Pain 1, Building M1 Room Σ3, Sept 27, 11.45*

**Background:** Acute rhinosinusitis (ARS) and chronic rhinosinusitis (CRS) exacerbations with their orbital and intracranial complications are the leading rhinogenic headache cause. Additionally, contact points in the nose can cause localized periorbital, medial canthus or temporomandibular intermittent facial pain.

**Methodology/Principal:** Retrospective analysis of diagnosis and treatment success of rhinogenic headache and facial pain patients at University medical centre Ljubljana, Slovenia, was performed.

**Results:** All of the contact point facial pain and pneumatosinus dilatants patients were successfully treated by endoscopic nasal surgery. Similarly, patients with orbital and intracranial complications of ARS and CRS were without pain after complication resolution. However, many CRS patients still experience frequent exacerbations with concomitant headaches. Additionally, in a few patients, the CT signs of CRS disappeared after surgical treatment, meanwhile, the pain remained unchanged, revealing a probable migraine or tension-type headache.

**Conclusions:** The diagnosis of the rhinogenic headache should always be established by nasal endoscopy and computer tomography (CT) and/or magnetic resonance imaging (MRI) to avoid unnecessary medical and/or surgical treatment, especially if headache or facial pain is the only symptom not accompanied by nasal symptoms.

**Key words:** Facial pain, Acute rhinosinusitis, Chronic rhinosinusitis, Headache

202687

## Severe eosinophilic asthma with nasal polyposis: A phenotype for improved sino-nasal and asthma outcomes with mepolizumab therapy

**Peter Howarth**<sup>1</sup>, Geoffrey Chupp<sup>2</sup>, Eric S. Bradford<sup>3</sup>, Daniel J. Bratton<sup>4</sup>, Steven G. Smith<sup>3</sup>, Frank C. Albers<sup>5\*</sup>, Guy Brusselle<sup>6</sup>, Claus Bachert<sup>7</sup>

<sup>1</sup>Global Medical Franchise, GSK House, Brentford, Middlesex, UK; <sup>2</sup>Yale Center for Asthma and Airways Disease (YCAAD), Yale School of Medicine, New Haven, CT, USA; <sup>3</sup>Respiratory Therapeutic Area, GSK, Research Triangle Park, NC, USA; <sup>4</sup>Clinical Statistics, GSK, Stockley Park, Uxbridge, Middlesex, UK; <sup>5</sup>Respiratory Medical Franchise, GSK, Research Triangle Park, NC, USA; <sup>6</sup>Department of Respiratory Medicine, University Hospital Ghent, C. Heymanslaan 10, 9000 Ghent, Belgium; <sup>7</sup>Upper Airways Research Laboratory, University Hospital Ghent, C. Heymanslaan 10, 9000 Ghent, Belgium

\*Affiliation at time of study, currently employed by Avillion US, Inc., IL, USA

CRS - medical management 2, Building M2 CR2, Sept 28, 10.15

**Background:** Nasal polyposis (NP) is a common co-morbidity in severe eosinophilic asthma (SEA). The anti-interleukin (IL)-5 monoclonal antibody, mepolizumab (MEPO), improves health-related quality of life (HRQoL) and exacerbation rates in patients with SEA, however, the impact of NP on outcomes has not been examined.

**Methodology/Principal:** Post hoc analysis of placebo-controlled randomized trials of MEPO (100mg sc every 4 weeks) in SEA (MUSCA, n=551; MENSA, n=576) evaluated outcomes in relationship to the presence/absence of NP. MUSCA assessed change in SinoNasal Outcomes Test (SNOT-22) whilst the combined analysis investigated SEA exacerbation reduction based on polyp presence.

**Results:** Among patients with NP, MEPO had a greater impact than placebo in reducing SNOT-22, treatment difference of -11.8 (95% confidence interval [CI]: -19.8, -3.9), which was greater than the -4.9 (95% CI: -8.3, -1.6) in those with SEA without polyps. MEPO versus placebo reduced the annual rate of severe exacerbations in SEA regardless of NP status, but to a greater extent in patients with NP (80%) than without NP (49%).

**Conclusions:** Although MEPO is effective in SEA, patients with SEA and comorbid NP represent a phenotype that demonstrates greater benefit with mepolizumab therapy compared with patients with SEA in the absence of NP.

**Funding:** GSK (200862 & meta-analysis 208115)

**Key words:** Mepolizumab, Severe eosinophilic asthma, Nasal polyps, Asthma exacerbations, SNOT-22

202690

## IMRT vs. 3D-conformal radiotherapy of nasopharyngeal carcinoma: Survival outcome and complications rate analysis in a Spanish Population.

**Maria M. Soriano Reixach**, Ariadna Valldeperes Vilanova, Carlos M. Chiesa Estomba.

*Otorhinolaryngology – Head & Neck Surgery Department, Donostia University Hospital, San Sebastian-Donostia, Guipuzcoa, Spain.*

*Sinonasal malignancy 3, Building M2 CR2, Sept 29, 14.45*

**Background:** intensity-modulated radiation therapy (IMRT) have been suggested to be superior to three-dimensional conformal radiotherapy (3D-RT) in salivary preservation and good locoregional control of nasopharyngeal carcinomas.

**Methodology:** in this retrospective analysis of 35 patients diagnosed of nasopharyngeal carcinoma from 2000 until 2014. We compared treatment outcomes and complications rates of two different treatment approach: IMRT) versus 3D-RT.

**Results:** During this period, 13 patients received IMRT and 22 3D-RT. According to stage patients received or not concomitant chemotherapy. The most common histology was type 3 Undifferentiated Nasopharyngeal Carcinoma affecting 17 (48,5%) of patients. Three-year overall survival rate was 61.5% in the IMRT group and 54,5% in the 3D-RT group ( $p = 0.0001$ ), and three-year disease-specific survival rate was 88,9% in the IMRT group and 65,4% in 3D-RT group ( $p = 0.004$ ). The most common complications described was Xerostomia and G2 mucositis, being more common in the 3D-RT group without statistically significance when patient receive ( $p = 0.122$ ) or not additional chemotherapy ( $p = 0.376$ ).

**Conclusions:** According to our results IMRT provides better locoregional relapse-free survival and overall survival, and is associated with a lower (Non-Significant) incidence of complications compared with 3D-RT.

**Key words:** nasopharyngeal carcinoma, radiotherapy, intensity-modulated radiation therapy.

**Alexandru. R. Hut<sup>1</sup>**, C.S. Gionea<sup>1</sup>, L. Miksa<sup>1</sup>, N.C. Balica<sup>1,2</sup>, M. Poenaru<sup>1,2</sup>, E.R.Boia<sup>1,2</sup>

<sup>1</sup>ENT Clinic of Timisoara, Romania, <sup>2</sup>The Victor Babeş University of Medicine and Pharmacy of Timișoara, Romania

*Epistaxis and HHT 1, Building M1 Room Σ4, Sept 28, 11.45*

**Background:** The aim of this study was to achieve a better management of patients with epistaxis, admitted to the ENT Clinic Timisoara.

**Methodology/Principal:** During the 8-year retrospective study, the observation sheets of 900 patients admitted in the Otorhinolaryngology Clinic with nasal hemorrhagic pathology were evaluated. In this study we included anterior epistaxis and posterior epistaxis patients. Age, gender, provenience, associated comorbidities, hemorrhage location, and, in particular, the treatment method and the outcome were assessed, creating thus a thorough database for future case management.

**Results:** 900 patients were evaluated, 729 cases presented anterior epistaxis and 171 posterior epistaxis. 765 cases were treated with anterior and posterior nasal packaging and in 135 patients endoscopic hemorrhage cauterization was performed. Out of the 900 patients only 3 cases of death were reported, for the rest 897 the outcome was favorable.

**Conclusions:** Because of the increased frequency of this pathology, management of epistaxis remains a priority for the ENT physician, because of complexity and especially due to the associated comorbidities. Further study is needed to elucidate the most efficacious treatment modality based on epistaxis severity.

**Key words:** epistaxis, management, comorbidities, treatment, severity.

202713

## Practical efficacy of novel medical software for the pre-operational simulation of the frontal sinus in cases with challenging anatomy

**Maria Kiakou**<sup>1</sup>, Meletis Liaskos<sup>3</sup>, George K. Matsopoulos<sup>3</sup>, Georgios F. Karkanis<sup>2</sup>, Alexandros Ninos<sup>2</sup>, Evangelos Alogdianakis<sup>2</sup>

<sup>1</sup>ENT Department, Mid Essex Hospital NHS Trust, Chelmsford, Essex, United Kingdom, <sup>2</sup>ENT Department, 401 General Army Hospital of Athens, Athens, Attiki, Greece, <sup>3</sup>School of Electrical and Computer Engineering, National Technical University of Athens, Greece

*CRS - surgical management 1, Building M2 CR3, Sept 29, 10.15*

**Background:** We previously developed a DICOM Viewer allowing a user to highlight (in 3 axes) anatomical points and surfaces of interest. The current study aims to demonstrate the advantages this system has conferred to safe dissection of the frontal sinus drainage pathway (FSDP), avoidance of skull base complications and confirmation of image guidance calibration.

**Methodology/Principal:** Nine participants with bilateral and eight with unilateral frontal chronic sinusitis, undergoing functional endoscopic sinus surgery (FESS), had their CT scans analysed preoperatively using the new and conventional DICOM viewers. The three FSDP cell groups of the IFAC classification were highlighted, as well as a point of anatomical reference to orientate and confirm image guidance accuracy during surgery. The highlighted data sets were loaded into the image guidance system and used during surgery.

**Results:** Twenty-two FSDP dissections were completed, including fifteen cases (58%, 95%CI 39-77%) considered unsafe with conventional analysis. The surgeon felt greater confidence using the system to ensure guidance calibration.

**Conclusions:** Our novel DICOM viewer increases the surgeon's anatomical awareness and confers a better understanding of the individual patient's anatomy, increasing the number of successful uncomplicated surgeries. The system increased the time the operating surgeon spent studying and more importantly, understanding the scans, while also improving orientation.

**Key words:** DICOM viewer, frontal sinus surgery, challenging anatomy, frontal drainage pathway, navigation systems



Mucosal leishmaniasis (ML) occurs mainly in areas where *Leishmania braziliensis* is transmitted. It affects predominantly the nasal mucosa and, in more severe forms, can lead to significant tissue destruction. There is no standard method for grading the severity of disease. We categorised 50 patients with ML according to a proposed new clinical staging system. Their age ranged from 10 to 86 y (mean±SD: 36±16 y) and 43 (86%) patients were male. The different degrees of evolution of mucosal disease, from the initial stage to the more severe long-term cases, enabled ML to be graded into five stages. Stage I is characterised by nodular lesions of the mucosa without ulceration. Stage II is represented by superficial mucosal ulcerations with concomitant fine granular lesions. Stage III is characterised by deep mucosal ulcerations with granular tissue formation. In stage IV there are irreversible lesions leading to perforation of the cartilaginous nasal septum with necrosis. In stage V the nasal pyramid is compromised with alterations of facial features as a consequence of severe tissue destruction. These stages may be useful in characterising the severity of the lesion and optimising therapeutic outcome.

202727

## Management of skull base CSF leak: Is addition of tissue sealant really necessary?

**Aga Alfred<sup>1</sup>**, Vajushi Emirjona<sup>1</sup>, Kaba Armida<sup>1</sup>, Xhumari Artur<sup>2</sup>

<sup>1</sup>ENT Department, American Hospital, Tirana-Albania, <sup>2</sup>Neurosurgery Department, American Hospital, Tiana-Albania

*CSF leaks and management 1, Building M1 Room Σ2, Sept 27, 10.15*

**Background** Tissue glue is used in endoscopic skull base surgery for reduction of postoperative CSF-leaks. However, it is not clearly evident in literature, and there is no specific data available to confirm its utility.

**Methodology** From June 2017 to November 2019 in our department 33 patients presented with CSF leak. The aetiology was: in 9 patients, traumatic anterior skull base fracture and 24 patients, iatrogenic fistula (skull base surgery). All patients underwent endoscopic endonasal technique for closure of CSF leaks without using any tissue glue.

**Results** 32 of the 33 patients had a successful primary closure of their CSF leak. Only one patient required a repeat procedure. This gives a primary closure success rate of 96,9% and a secondary closure rate of 100%. Only autologous grafts were used and in most of the cases fat and Hadad flap (76%) was the preferred material. Sometimes we used iliotibial tract fascia as the first choice especially for anterior skull base defects.

**Conclusions** Different methods are proposed to repair the CSF leak. In this study we propose the use of only autologous material without need to any tissue collant with the same success rate of other methods.

**Key words:** CSF-leak, tissue collant, skull base surgery

## Expression of Receptor for Advanced Glycation End Products (RAGE), and its ligand High Mobility Group Box 1 (HMGB1) in orbit tissue in Graves' orbitopathy

**Mirosław J. Szczepanski<sup>1,2</sup>**, Dominika Lacheta<sup>1</sup>, Krzysztof B. Poslednik<sup>2</sup>, Katarzyna Czerwaty<sup>2</sup>, Anna Jablonska-Pawlak<sup>3</sup>, Piotr Miskiewicz<sup>4</sup>, Marta Molinska-Glura<sup>5</sup>, Nils Ludwig<sup>6</sup>, Anna Cyran<sup>7</sup>, Ireneusz Kantor<sup>2</sup>

<sup>1</sup>Department of Biochemistry, Medical University of Warsaw, Poland;; <sup>2</sup>Department of Otolaryngology, Centre of Postgraduate Medical Education, Warsaw, Poland;; <sup>3</sup>Department of Ophthalmology, Medical University of Warsaw, Poland;; <sup>4</sup>Chair and Department of Internal Medicine and Endocrinology, Medical University of Warsaw, Poland;; <sup>5</sup>Department of Forest Technology of Poznan University of Life Sciences, Poznan, Poland;; <sup>6</sup>University of Pittsburgh Cancer Institute, Pittsburgh, PA 15232, USA;; <sup>7</sup>Department of Pathology and Laboratory Medicine, Brown University, Providence, RI 02912, USA;

*Orbital surgery 1, Building M2 CR3, Sept 29, 11.45*

**Background:** RAGE (receptor for advanced glycation endproducts) and its ligand HMGB1 (high mobility group box 1) trigger inflammatory signalling and are implicated in various inflammatory disorders. We evaluated RAGE and HMGB1 expression in orbital tissue from patients with Graves' orbitopathy (GO) and assess their potential role in GO.

**Methodology/Principal:** RAGE and HMGB1 expression was evaluated by immunohistochemistry in orbital tissues from patients undergoing transnasal endoscopic orbital decompression for GO (n=17, 29 orbits) and from patients operated on the orbit due to trauma (normal control; NC) (n=15, 15 orbits). Additionally, we analyzed correlation between RAGE expression and some clinical and laboratory results, i.e. preoperative TSH-receptor antibodies (TRAb) level, intraocular pressure (IOP), keratitis and proptosis.

**Results:** RAGE and HMGB1 were moderately or strongly expressed in GO tissue. No or weak RAGE expression was found in NC. HMGB1 was equally moderate expressed in NC. Elevated RAGE expression levels in tissues was significantly associated with increased TRAb level, preoperative intraocular pressure (IOP), keratitis and proptosis ( $p<0.05$ ). Decreased HMGB1 expression levels in tissues was significantly associated with increased TRAb level, preoperative proptosis, and with decreased intraocular pressure (IOP) ( $p<0.05$ ).

**Conclusions:** GO pathogenesis might be related to RAGE and HMGB1 expression.

**Key words:** Graves' orbitopathy, RAGE, HMGB1, immunohistochemistry

### Literature:

1. Han SY et al. High-Mobility Group Box 1 Is Associated with the Inflammatory Pathogenesis of Graves' Orbitopathy. *Thyroid*. 2019 Jun;29(6):868-878.
  2. Szczepanski MJ et al. Molecular signaling of the HMGB1/RAGE axis contributes to cholesteatoma pathogenesis. *J Mol Med (Berl)*. 2015 Mar;93(3):305-14
- Dzaman K, Szczepanski MJ et al. Expression of the receptor for advanced glycation end products, a target for high mobility group box 1 protein, and its role in chronic recalcitrant rhinosinusitis with nasal polyps. *Arch Immunol Ther Exp (Warsz)*. 2015 Jun;63(3):223-30

## Computed tomography score seems to predict need for revision surgery in chronic rhinosinusitis: a pilot study

**Markus J. Lilja**<sup>1,2</sup>, Anni Koskinen<sup>1,2</sup>, Anna Julkunen<sup>3</sup>, Antti Mäkitie<sup>2</sup>, Jura Numminen<sup>4</sup>, Markus Rautiainen<sup>4,5</sup>, Jyri P. Myller<sup>6</sup>, Antti Markkola<sup>7</sup>, Mikko Suvinen<sup>8</sup>, Mika J. Mäkelä<sup>1</sup>, Risto Renkonen<sup>3,9</sup>, Juha Pekkanen<sup>10</sup>, Sanna K. Toppila-Salmi<sup>1,3</sup>

<sup>1</sup>Skin and Allergy Hospital, University of Helsinki and Helsinki University Hospital, Helsinki, Finland, <sup>2</sup>Department of Otorhinolaryngology - Head and Neck Surgery, Helsinki University Hospital and University of Helsinki, Helsinki, Finland, <sup>3</sup>Haartman institute, University of Helsinki, Helsinki, Finland, <sup>4</sup>Department of Otorhinolaryngology, Tampere University Hospital, Tampere, Finland, <sup>5</sup>Department of Otorhinolaryngology, University of Tampere, Tampere, Finland, <sup>6</sup>Department of Otorhinolaryngology, Päijät-Häme Central Hospital, Lahti, Finland, <sup>7</sup>University of Helsinki and HUS Imaging, Helsinki, Finland, <sup>8</sup>Department of Otorhinolaryngology, Tampere City Hospital, Tampere, Finland, <sup>9</sup>HUS Diagnostic Center, Helsinki, Finland, <sup>10</sup>Department of Department of Public Health, Helsinki, Finland

*CRS - diagnosis and investigations 2, Building M1 Room Σ2, Sept 28, 10.15*

**Background:** Chronic rhinosinusitis (CRS) can be divided into forms with nasal polyps and without. Surgery is considered if conservative treatment is insufficient. The predictive factors for the need for revision surgery are not fully understood. The aim of this study was to evaluate the signs in sinonasal computed tomography (CT) that will predict need for revision surgery in CRS.

**Methodology/Principal:** In this prospective follow-up study, 93 CRS patients underwent sinus CT during 2006-2011. Lund-Mackay (LM) scores and 43 other structural parameters were analysed. Patients filled a questionnaire of symptoms and associated traits during the day of CT scanning. Follow-up data were collected from hospital records.

**Results:** Total LM score was associated with the need for baseline CRS surgery within one year after sinus CT scanning ( $P < 0.001$ ). We were able to detect additional CT signs that associated with the need for revision CRS surgery during follow-up. These additional signs were related to non-detectable anatomy of inferior/middle turbinates, obstructed frontal recess, and CT signs of previous sinus surgery.

**Conclusions:** This pilot study suggests that baseline CT scans can predict not only the need for baseline surgery, but also the need for revision CRS surgery during follow-up.

**Key words:** rhinosinusitis, chronic, CRS, CRSwNP, CRSsNP, computed tomography, nasal polyps, prediction

202826

An inertial sensor-based system designed to measure and prevent undesired camera rotation during endoscopic sinus surgery.

**Jaime Viera-Artiles**<sup>1</sup>, José J. Valdiande<sup>2</sup>, Javier Ospina<sup>3</sup>, María Costales<sup>4</sup>, José M. López-Higuera<sup>2,5</sup>.

<sup>1</sup>ENT department, Hospital Universitario Marqués de Valdecilla, Santander, Spain., <sup>2</sup>Photonics Engineering Group, Universidad de Cantabria, Santander, Spain., <sup>3</sup>Division of Otolaryngology - Sinus and Skull Base Surgery, Fundación Santa Fe de Bogotá, Bogotá, Colombia., <sup>4</sup>ENT department, Hospital Universitario Central de Asturias, Oviedo, Spain., <sup>5</sup>CIBER-BBN and IDIVAL, Santander, Spain.

*CRS - surgical management 4, Building M1 Room Σ2, Sept 29, 10.15*

**Background:** Maintaining a stable visual horizon during endoscopic sinus surgery is essential to preserve spatial orientation. A constant camera movement generates a rotation which tilts the operating field's view, producing a visuomotor incongruence with detrimental effects in surgical performance and safety, especially above 15 degrees. We aimed to study this phenomenon on endoscopic sinus surgery.

**Methodology/Principal:** We developed a system that can be attached to any conventional endoscopic camera and can measure camera movement parameters and their variation from a reference position, feeding back this information in real-time as a reference guide overlay over the original image to aid in maintaining a stable visual horizon. A pilot study was conducted to test the utility and feasibility of the system.

**Results:** There was a 52.2% ( $\pm 18.3\%$ ) reduction in camera roll in tasks with the reference guides active. Specifically, there was 86.8% reduction in the total amount of time where camera roll was above 15 degrees. The impact of the reference guides, nonetheless, was greater in inexperienced participants.

**Conclusions** Undesired camera rotation is a latent factor inherent in endoscopic procedures. The designed reference guide strategy effectively reduced camera roll during endoscopic sinus surgery with a potential benefit increasing the safety of this and other procedures.

**Key words:** Endoscopy, Nasal Surgical Procedures, Sinusitis, Spatial Orientation.

202827

Office-based polypectomy efficacy and patients' tolerability using an electrically-powered microdebrider in 45 patients.

**J. Viera-Artiles**, P. Corriols, E. López-Simón, D. Lobo, R. Megía

*ENT Department, Hospital Universitario Marqués de Valdecilla, Santander, Spain.*

*CRS - surgical management 4, Building M1 Room Σ2, Sept 29, 10.15*

**Background:** In-office polypectomies under local anaesthesia in selected chronic rhinosinusitis (CRS) patients with obstructive nasal polyps has become popularized in North America, in opposition to functional endoscopic sinus surgery. However, the impact and expansion in Europe are very low in comparison. We aim to provide more in-depth evidence about the patient's experience, safety and effectivity of this procedure to help widespread implementation.

**Methodology/Principal:** A prospective study of 45 consecutive CRS patients who underwent in-office "microdebrider-assisted" polypectomy was performed. Patients' tolerability was measured objectively through vital signs monitoring and subjectively with a visual analogue scale (VAS) for pain. The effectivity was assessed using the SNOT-22 questionnaire pre-surgery, 1 and 3 months afterwards. Surgical complications and post-operative events were recorded.

**Results:** The procedure was very well tolerated with a mean VAS for the pain of 2,75 out of 10. The vasovagal presyncope was the most common incident (10%). One complication with severe bradycardia was registered caused by the trigemino-cardiac reflex. The SNOT-22 questionnaires' score showed a 60% reduction in the first month which was maintained later.

**Conclusions:** In-office polypectomy is a well-tolerated and effective for selected CRS patients. Severe complications are rare but might happen. Therefore, it is important to perform this procedure under safe conditions.

**Key words:** Nasal Polyps, Sinusitis, Local Anesthesia.

AERD is a distinct phenotype in CRSwNP and may predict poor post-operative evolution

**Leandra Mfuna Endam**<sup>1</sup>, Axel Eluid Renteria Flores<sup>1,2</sup>, Anastasios Maniakas<sup>1,2,3</sup>, Pierre Boisvert<sup>4</sup>, Louis-Philippe Boulet<sup>5</sup>, Martin Desrosiers<sup>1,2</sup>

<sup>1</sup>Centre de Recherche du Centre Hospitalier de l'Université de Montréal (CRCHUM), Montreal, QC, Canada;;

<sup>2</sup>Division of Otolaryngology-Head & Neck Surgery, Centre Hospitalier de l'Université de Montréal (CHUM), Montreal, QC, Canada; <sup>3</sup>Division of Experimental Surgery, McGill University, Montreal, QC, Canada; <sup>4</sup>Department of Otolaryngology, Saint-François d'Assise Hospital, Québec, QC, Canada; <sup>5</sup>Centre de Recherche Institut Universitaire de Cardiologie et de Pneumologie de Québec, Québec, QC, Canada.

*CRS – pathophysiology 2, Building M1 Room Σ1, Sept 29, 10.15*

**Background:** CRS patients with aspirin-exacerbated respiratory disease (AERD) are increasingly considered a distinct form of CRS, and may represent a distinct phenotype. We wished to verify whether AERD impacted disease presentation, evolution and response to surgery in CRS.

**Methodology/Principal:** Existing research databases (GCRS1, GCRS2, AZI) in our group were retrospectively interrogated for associations of markers of AERD disease or outcomes with. Groups are compared using T-test.

**Results:** In GCRS1 (AERD=59, non-AERD=145) AERD patients were younger at time of first ESS, more frequent ESS, more asthma, and less bronchiectasis ( $p<0.05$ ). In GCRS2 (AERD=129, non-AERD=342), AERD patients were younger at first ESS, reported more ESS, a higher frequency of asthma, with younger age at diagnosis, more frequent respiratory allergies, and more frequent colonisation with *Haemophilus influenzae* (all  $p<0.05$ ). In AZI (AERD=18, non-AERD=78), patients with AERD were more frequently asthmatic and showed a poor outcome at four months following surgery and an almost uniform lack of response to subsequent treatment with azithromycin. No differences in serum eosinophilia were seen.

**Conclusions:** AERD appears to represent a distinct phenotype independent of eosinophilia yet associated with more severe disease. AERD may thus prove to be useful as a marker for outcome and for selection of therapy.

**Key words:** AERD, CRSwNP, biomarkers, asthma, outcomes

**Julien W. Hsieh**<sup>1</sup>, Vincent Lenoir<sup>2</sup>, Marianne Hugentobler<sup>1</sup>, Minerva Becker<sup>2</sup>, Basile N. Landis<sup>1</sup>

<sup>1</sup> Rhinology–Olfactology Unit, Service of Otorhinolaryngology Head and Neck Surgery, Department of Clinical Neurosciences, Geneva University Hospital, Geneva, Switzerland, <sup>2</sup> Department of Radiology, Geneva University Hospital, Geneva, Switzerland

*Smell and taste 3, Building M2 CR3, Sept 27, 14.45*

**INTRODUCTION:** The aim of this paper is to identify clusters of posttraumatic brain lesion pattern and analyze whether they can predict chemosensory testing scores and olfactory recovery.

**MATERIALS AND METHODS:** This is a retrospective cohort study. A total of n=56 patients were included in the study. They underwent clinical evaluation, Sniffin' Sticks test (olfaction), lateralization test (trigeminal), taste strips test (taste), and MRI with a focus on chemosensory-related brain regions. A total of n=34 out of 56 patients were followed up on average at 41 months.

**RESULTS:** We identified four clusters of brain lesion pattern that differed in lesion severity and localization. These clusters were strongly associated with degrees of olfactory function ( $\chi^2(6, n=56) = 15.5, p=0.015$ ), but not with trigeminal and gustatory function. Binary logistic with forward regression identified only the clusters as predictor of smell improvement (Chi-square=14.3, df=3 and p=0.003). The model correctly predicted 58.3% of patients who subjectively improved and 95.5% of patients who did not improve.

**CONCLUSION:** Brain lesion pattern assessed by MRI could be used as an objective marker to support the diagnosis of olfactory dysfunction in posttraumatic patients and predict olfactory recovery.

**Key words:** Traumatic brain injury, olfaction, taste, trigeminal, MRI,



## The development of a smell resolution test

**Julien Wen Hsieh**<sup>1,2</sup>, Andreas Keller<sup>1</sup>, Michele Wong<sup>1</sup>, Rong-San Jiang<sup>3</sup>, Leslie Birgit Vosshall<sup>1, 4, 5</sup>

<sup>1</sup> Laboratory of Neurogenetics and Behavior, The Rockefeller University, New York, USA, New York City, <sup>2</sup> Rhinology–Olfactology Unit, Service of Otorhinolaryngology Head and Neck Surgery, Department of Clinical Neurosciences, Geneva, <sup>3</sup> Department of Otolaryngology, Taichung Veterans General Hospital, Taichung, <sup>4</sup> Howard Hughes Medical Institute, New York City, <sup>5</sup> Kavli Neural Systems Institute, New York City

*Smell and taste 3, Building M2 CR3, Sept 27, 14.45*

**INTRODUCTION:**Current smell tests are biased by cultural factors. Furthermore, there is no tool to measure the resolution of human olfactory system. To overcome these, we created a smell resolution test based on complex odor-mixtures and tested its reliability, accuracy and cross-cultural administration.

**MATERIALS AND METHODS:**We enrolled 75 subjects who underwent a reliability study. Then, we recruited 23 healthy subjects and 10 participants complaining of smell loss to perform an accuracy study. Finally, 36 healthy Americans in New York City and 36 Taiwanese in Taichung participated to an equivalence study.

**RESULTS:**The intraclass correlation between test-retest was 0.75. The area under the ROC curve was 0.82 (95% confidence interval: 0.65–0.93). The difference between the Taiwanese and the Americans was much smaller for the smell resolution test than the Smell Identification Test (from Sensonics), as determined by calculating the difference in z scores.

**CONCLUSIONS:**This proof-of-principle results suggest that the resolution of the olfactory system can be reliably measured. It can accurately distinguish subjects with normal and abnormal sense of smell. This test avoids the cultural bias seen for the Smell Identification Test, in which test performance is systematically higher in the population for which the test was developed.

**Key words:** Smell, olfactory, resolution, smell loss, SMELL-RS

## Intra-tonsillar allergen specific immunotherapy

**Sverre K. Steinsvåg**<sup>1,2</sup>, Anne Cathrine Lønnerød<sup>1</sup>, Kristine Thomassen Berget<sup>3</sup>, Hans Jørgen Aarstad<sup>2</sup>.

<sup>1</sup> Dept. of ORL, Sørlandet Hospital, Norway. <sup>2</sup> Dept. of ORL Haukeland University Hospital, Norway. <sup>3</sup> Dept. of Immuno-Haematology, Sørlandet Hospital, Norway

*Allergic Rhinitis 1, Building M1 Room Σ3, Sept 28, 10.15*

**Background:** Allergen specific immunotherapy is currently administered either subcutaneously (SCIT) or sublingually (SLIT). Long duration of treatment and low bioavailability of allergens make it relevant to look for alternative ways of administration. We have looked at the effect of allergen injections into the pharyngeal tonsils.

**Methodology/Principal:** Twelve patients got 0,1 ml. timothy extract (ALK Alutard, 100 000 IE) injected into their left pharyngeal tonsil 4 times with 4 weeks intervals. Specific IgG4 and IgE against timothy were measured prior to and after each injection. Numbers of questionnaires about general health, sino-nasal, and allergy related symptoms as well as general satisfaction with the treatment were completed before each of the injections and 1 year after the last one.

**Results:** Specific IgG4 increased between all injections ( $p=0.067/0.005$ ). Specific IgE against timothy increased between the first, second and third injections, and decreased between injection. 3 and 4 ( $p=0.008/0.001$ ). The clinical effect and general satisfaction with the treatment measured on VAS was excellent. Seven out of 12 patients got symptoms of anaphylaxis at the time of the 2 first injections. None at injections 3 and 4

**Conclusions** ITIT appears to have immunological and clinical effects comparable to SLIT and SCIT.

**Key words:** Allergen specific immunotherapy.

## Is there anything new about Local Allergic Rhinitis?

**Alexios S. Vardouniotis**<sup>1</sup>, Alexander Karatzanis<sup>2</sup>, Maria Doulaptsi<sup>2</sup>, Stylianos Velegrakis<sup>2</sup>, Emmanuel Prokopakis<sup>2</sup>

<sup>1</sup> NHS Treatment Center, Portsmouth, UK, <sup>2</sup>Department of Otorhinolaryngology, University of Crete, School of Medicine, Greece

*Non-allergic rhinitis 1, Building M2 CR2, Sept 28, 11.45*

**Background:** Local Allergic Rhinitis (LAR) is a localized allergic response in the nasal mucosa with the absence of systemic atopy as assessed by conventional diagnostic tests, such as SPT or determination of sIgE in serum. It is characterized strictly by local production of specific IgE antibodies, a T<sub>H</sub>2 pattern of mucosal cell infiltration during natural exposure to aeroallergens, with a positive nasal allergen provocation test response with release of inflammatory mediators characteristic of an IgE immediate response.

**Principal:** We describe existing principles in definition, classification, mechanisms, comorbidities, recommendations for diagnosis and treatment of LAR and define unmet needs in these areas.

**Conclusions:** LAR has to be considered in the process of differential diagnosis in children and adults with rhinitis. Diagnosis of LAR is crucial in order to start an etiologic treatment such as allergen immunotherapy, which has proven to be very effective in these patients.

**Keywords:** Local allergic rhinitis, allergic rhinitis, nasal IgE, nasal provocation test, allergen immunotherapy

#### Literature:

Rondón, C.; Campo, P.; Togias, A.; Fokkens, W.J.; Durham, S.R.; Powe, D.G.; Mullol, J.; Blanca, M. Local allergic rhinitis: Concept, pathophysiology, and management. *J. Allergy Clin. Immunol.* 2012; 129, 1460–1467. DOI: [10.1016/j.jaci.2012.02.032](https://doi.org/10.1016/j.jaci.2012.02.032).

Hellings, P.W.; Klimek, L.; Cingi, C.; Agache, I.; Akdis, C.; Bachert, C.; Bousquet, J.; Demoly, P.; Gevaert, P.; Hox, V.; et al. Non-allergic rhinitis: Position paper of the European Academy of Allergy and Clinical Immunology. *Allergy* 2017, 72, 1657–1665.

Rondon, C.; Eguiluz-Gracia, I.; Campo, P. Is the evidence of local allergic rhinitis growing? *Curr. Opin. Allergy Clin. Immunol.* 2018; 18, 342–349. DOI: [10.1097/ACI.0000000000000456](https://doi.org/10.1097/ACI.0000000000000456).

Campo, P.; Eguiluz-Gracia, I.; Bogas, G.; Salas, M.; Plaza Seron, C.; Perez, N.; Mayorga, C.; Torres, M.J.; Shamji, M.H.; Rondon, C. Local allergic rhinitis: Implications for management. *Clin. Exp. Allergy* 2019, 49, 6–16. DOI: [10.1111/cea.13192](https://doi.org/10.1111/cea.13192).

## The impact of chemosensory disorders on weight loss

**Dimitrios Daskalou<sup>1</sup>**, Julien W. Hsieh<sup>1</sup>, Basile N. Landis<sup>1</sup>

<sup>1</sup> Department of Otorhinolaryngology Head and Neck Surgery, University Hospital of Geneva, Geneva, Switzerland.

*Abstract Session 32, Building M2 CR1, Sept 28, 14.45*

**Background:** The aim of this study is to investigate which smell and taste symptoms are most likely to cause weight loss.

**Methodology/Principal:** This is a retrospective study based on a validated questionnaire for smell and taste disorders.

**Results:** We included a total of 552 patients (312 females) with a mean age of  $50.4 \pm 17.2$  years. Among them, 169 (30.7%) participants reported chemosensory disorders with taste impairment, and 383 (69.3%) had smell disorders only. The presence of taste alteration is a significant predictor for weight loss as the odds for individuals with taste disorder to lose weight are 1.69 times higher than for patients with smell disorder only (p-value=0.038; 95% CI 1.02 to 2.77). Parosmia but not phantosmia or quantitative smell impairment (anosmia and hyposmia) is a significant predictor for weight loss as the odds for patients with parosmia to lose weight are 2.5 higher than for patients with no qualitative olfactory disorders (p-value=0.005; 95% CI 1.27 to 4.73).

**Conclusions:** Parosmia and gustatory disturbance seem to be more often associated with weight loss than simple hyposmia or anosmia alone. These findings should help to identify potential patients in danger of weight loss and favor adequate counseling.

**Key words:** Olfaction disorders, taste disorders, weight loss.

202872

## Retrospective review of nasal fracture outcomes & indications for post-traumatic septorhinoplasty in Glasgow, UK

**Hiteshkumar Tailor**, Josh Sutherland, Susan McFaul, Carl Mulholland, Siew Min Keh

*ENT Department, Greater Glasgow & Clyde NHS, Glasgow, UK*

*Nasal and facial trauma 1, Building M1 Room Σ3, Sept 27, 11.45*

**Background:** Nasal fractures are common fractures in facial injuries. We wanted to review outcomes of treated nasal fractures, reason for re-referrals and factors that predict subsequent septorhinoplasty.

**Methodology/Principal:** Casenotes for patients undergoing closed manipulation of nasal fracture between January 2015 and July 2017 were reviewed, particularly pathways and outcomes.

**Results:** 409 patients were identified. 94% were referred by the Emergency Department. Average times for: injury to ENT assessment was 9.7 days; injury to local anaesthesia (LA) and general anaesthesia manipulation was 10 and 15 days, respectively.

51% of cases were performed under LA.

5.6% of patients were re-referred for septorhinoplasty. Of these, 39% did not qualify or had underlying rhinitis. 35% of re-referrals went on to have a septorhinoplasty.

While 11% had initial inadequate outcome at manipulation, only 3% had septorhinoplasty with marginally more originally having a LA manipulation. The main indication for septorhinoplasty was failed/inadequate initial reduction with residual dorsal hump or obstructive symptoms of significant septal deformity.

**Conclusions:** Vast majority of our patients (97%) had an adequate outcome following manipulation. We propose that patients should be offered a follow up appointment if inadequate initial reduction or if seen to have a residual dorsal hump or significant septal deformity

**Key words:** Nasal, fracture, trauma, manipulation, septorhinoplasty,

202881

## Pathogenesis of chronic rhinosinusitis with nasal polyps: role of IL-6 in airway epithelial cell dysfunction

**Emilie Béguignon**<sup>1,2,3,4\*</sup>, David Mangin<sup>1,2,3,4\*</sup>, Justine Bécaud<sup>1,2,3,4</sup>, Jennifer Pasquier<sup>5,6</sup>, Christelle Angely<sup>2,3,4</sup>, Mathieu Bottier<sup>2,3,4</sup>, Estelle Escudier<sup>7,8,9</sup>, Daniel Isabey<sup>2,3,4</sup>, Marcel Filoche<sup>2,3,4</sup>, Bruno Louis<sup>2,3,4</sup>, Jean-François Papon<sup>2,4,10,11 \*\*</sup>, André Coste<sup>1,2,3,4 \*\*</sup>

<sup>1</sup>ENT department, AP-HP, Hôpital Henri Mondor et Centre Hospitalier Intercommunal de Créteil, Créteil, 94010, France;; <sup>2</sup>INSERM, U955, Créteil, 94010, France;; <sup>3</sup>Université Paris-Est, Faculté de Médecine, Créteil, F-94010, France;; <sup>4</sup>CNRS, ERL 7000, Créteil, 94010, France;; <sup>5</sup>Nice Breast Institute, 06000 Nice, France, <sup>6</sup>Weill Cornell Medicine-Qatar, Stem Cell & Microenvironment Laboratory, Doha, State of Qatar, <sup>7</sup>INSERM U933, Paris, France, <sup>8</sup>Université Pierre et Marie Curie, Paris, France, <sup>9</sup>AP-HP Hôpital Armand-Trousseau, Service de génétique et d'embryologie médicale, Paris, France, <sup>10</sup>ENT department, AP-HP, Hôpital Bicêtre, Le Kremlin-Bicêtre, 94270, France, <sup>11</sup>Université Paris-Sud, Faculté de Médecine, Le Kremlin-Bicêtre, F-94275, France

\*These authors have contributed equally to this work

\*\*These authors have contributed equally to this work

*CRS – pathophysiology 2, Building M1 Room Σ1, Sept 29, 10.15*

**Background:** In chronic rhinosinusitis with nasal polyps (CRSwNP), interleukins (IL) could induce an alteration in epithelial cell function including epithelial repair and ciliary beating.

**Methodology:** We evaluated the effects of IL-6 (1, 10 and 100 ng/mL) and other ILs (IL-5, IL-9, IL-10) on epithelial repair mechanisms (wound repair kinetic, cellularity and cell differentiation) and on ciliary beating in primary cultures of Human Nasal Epithelial Cells sampled in 38 patients (surgery for CRSwNP), under basal conditions and after IL-supplementation. Ciliary beating was analyzed by high-speed video-microscopy to measure ciliary beating frequency (CBF), ciliary length, relative ciliary density, metachronal wavelength and the ciliary beating efficiency index.

**Results:** Only IL-6 accelerated significantly wound repair (71% with IL6-1ng/mL vs 52% in unstimulated cultures ( $p = 0.02$ ) after 18 hours) with a dose-response effect and increased cellularity on day 12 after wound closure. IL-6 significantly increased CBF and metachronal wave length but didn't modified ciliary density, length of cilia and efficiency index.

**Conclusion:** Epithelial wound closure is significantly faster and CBF is significantly increased under IL-6 stimulation. Thus, IL-6 could be involved in the growth of nasal polyps. This information would be useful in developing new research and therapeutic approaches regarding epithelium dysfunction in CRSwNP.

**Keywords:** IL-6; repair mechanisms, mucociliary clearance; Chronic rhinosinusitis with nasal polyps (CRSwNP); wound healing; epithelial cell;

## Multidisciplinary care (MDC) for severe or uncontrolled chronic airways diseases.

Ioannis Vlastos<sup>1</sup>, **Maria Doulaptsi**<sup>2</sup>, Valerie Hox<sup>3</sup>, Joaquim Mullol<sup>4</sup>, Alexander Karatzanis<sup>2</sup>, Sven Seys<sup>5</sup>, Gert Marien<sup>5</sup>, Peter Hellings<sup>6</sup>, Emmanuel Prokopakis<sup>2</sup>

<sup>1</sup>Private practice, 28 V.Ipirou ENT office, <sup>2</sup>Department of Otolaryngology-Head and Neck Surgery, Heraklion University Hospital, Crete, Greece, <sup>3</sup>Service Otorhinolaryngologie – Rhinologie Cliniques universitaires Saint-Luc – Av. Hippocrate 10 – 1200 Bruxelles – Belgium, IREC/Pôle Pneu/ORL/Dermato – Université Catholique de Louvain, <sup>4</sup>Clinical and Experimental Respiratory Immunoallergy, Hospital Clínic, IDIBAPS, Barcelona, Spain, <sup>5</sup>European Forum for Research and Education in allergy and Airway Diseases (EUFOREA), Brussels, Belgium, <sup>6</sup>Clinical Division of Otorhinolaryngology, Head and Neck Surgery, University Hospitals Leuven, Leuven, Belgium

*CRS - diagnosis and investigations 3, Building M1 Room Σ4, Sept 29, 10.15*

**Background:** A multidisciplinary approach is regarded as best practice for many chronic diseases, such as cancer and asthma with well documented value. There is also evidence that it may be beneficial to patients presenting to tertiary referral centres with chronic rhinosinusitis (CRS) and atopic conditions. The aim of this presentation is to discuss whether and how organizing this kind of healthcare transition into a more integrated care pathways would benefit severe chronic airways disease management.

**Methodology:** Based on a recent related EUFOREA panel discussion, literature search and review of the best overseas organizational practices, an appropriate implementation strategy of multidisciplinary care (MDC) and its potential results are presented

**Results:** Organizational principles mostly in relation to MDC team involvement and coordination, clear referral pathways and integration of novel technologies such as m-health are analysed. Hurdles and challenges of the process are also being reported

**Conclusions:** Currently, efficiency of care and quality control assessment are becoming important concepts. At the same time novel treatment options based on molecular and precision medicine advancements, such as biologics, are being increasingly utilized. Appropriate organized MDC teams can adapt to new demands, data and discoveries and assure maximum benefit for both patients and healthcare professionals

**Key words:** Severe sinusitis, multidisciplinary

**Daniel Lupoi<sup>1,2,3</sup>**, Mihai Dragomir<sup>1</sup>, Ionut Tanase<sup>2,3</sup>, Codrut Sarafoleanu<sup>1,2,3</sup>

<sup>1</sup>"Carol Davila" University of Medicine and Pharmacy, Bucharest, Romania, <sup>2</sup>Center of excellence for research of sensorial and sensitive disorders, study of infecto-inflammatory, tumoral and obstructive aero-digestive pathology (CESITO), ENT & HNS Department, „Sfanta Maria" Clinical Hospital, Bucharest, Romania, <sup>3</sup> ENT&HNS Department, „Sfanta Maria" Hospital, Bucharest, Romania

CRS - outcome assessment 2, Building M1 Room Σ1, Sept 28, 10.15

**Background:** Chronic rhinosinusitis is one of the most common chronic diseases, affecting predominantly socially active segment of the population. We tried to establish if there are some correlations between histopathologic score and quality of life (QoL) of patients with chronic rhinosinusitis underwent endoscopic sinus surgery.

**Methodology/Principal:** Prospective study was done between 2009-2019 on 384 adult patients with chronic rhinosinusitis underwent endoscopic sinus surgery. Patients were assessed preop and postop at 3, 6 and 12 months using QoL tests. Mucosal samples were sent to histopathology department to establish histopathologic score.

**Results:** We obtained a medium score of QoL scores (47.3 points for SNOT-20 and 33.2 for VAS) which we compared with HP score of every patient. Postop, at 3, 6 and 12 months, most of patients obtained an improvement of QoL, patients with an HP higher than 7 points obtained less improvements in QoL compared with those with a low HP score (<7).

**Conclusions:** There are strong correlations between histopathologic score and QoL of patients, a high HP score at the time of surgery predicted less improvement in QoL and vice versa.

**Key words:** Histopathologic score, chronic rhinosinusitis, QoL



202950

## Pulmonary tuberculosis with rhinosinusal and otic manifestations - diagnostic challenge (case report)

**Alex Milea**<sup>1</sup>, Gabriela - Violeta Melinte<sup>1,2,3</sup>, Codrut Sarafoleanu<sup>1,2,3</sup>

<sup>1</sup>"Carol Davila" University of Medicine and Pharmacy, Bucharest, Romania, <sup>2</sup> Center of excellence for research of sensorial and sensitive disorders, study of infecto-inflammatory, tumoral and obstructive aero-digestive pathology (CESITO), ENT & HNS Department, „Sfanta Maria" Clinical Hospital, Bucharest, Romania, <sup>3</sup> ENT&HNS Department, "Sfanta Maria" Hospital, Bucharest, Romania

*Granulomatous diseases of the nose 1, Building M1 Room E3, Sept 28, 11.45*

**Background:** Unfortunately, tuberculosis is still being diagnosed among patients, independent of their age, gender, provenance or social category. The most common localization is pulmonary, but it can affect, secondary, other organs, especially in the ENT regions, mimicking other systemic diseases.

**Methodology/Principal:** We are presenting a case of a 51 years old female patient, who was referred to our ENT clinic with the suspicion of Behcet disease, with rhinosinusal manifestations. She was pulmonary assessed in another hospital, as she was known with left lung bronchiectasis, but the sputum samples were negative. Clinical otorhinolaryngologic examination together with the rheumatological assessment and the result of the nasal mucosa biopsy were suggestive for Behcet disease and the patient received 6 weeks of Prednisolone. The patient returned to our clinic after 2 months, accusing symptomatology reactivation with right otorrhea and bilateral hearing loss aggravation. Nasal and rhinopharyngeal mucosa biopsy was repeated and the anatomopathological result was tuberculosis.

**Results:** She was referred to the Pneumology Service where she received the diagnosis of pulmonary tuberculosis with rhinosinusal and otic manifestations.

**Conclusions:** Thorough examination and multidisciplinary approach are mandatory in order to establish a correct diagnosis followed by an appropriate treatment.

**Key words:** tuberculosis, rhinologic manifestations

202978

## Statistical investigations about the repeatability and reproducibility of a 4-phase-rhinomanometer and PNIF

Klaus-Dieter Wernecke<sup>1</sup>, Rudolf Viksne<sup>2</sup>, Klaus Vogt<sup>3</sup>

<sup>1</sup>SOSTANA GmbH Berlin, <sup>2</sup> Center of Experimental Surgery; Faculty of Medicine, University of Latvia, Riga/Latvia,

<sup>3</sup> Center of Experimental Surgery; Faculty of Medicine, University of Latvia, Riga/Latvia

*Technological advances 2, Building M1 Room Σ2, Sept 27, 14.45*

**Background:** The precision of a diagnostical gauge depends on the repeatability (several measurements by the same investigator) and the reproducibility (several measurements of the same patient by different investigators). While the technical reliability can be registered by models and simulators, reproducibility and repeatability have to be examined in clinical tests and approved by statistical methodology.

**Methods:** 10 healthy volunteers were tested with 4-Phase-Rhinomanometry (4PR; 4RHINO, Rhinolab/Germany, version 5.07) by 3 different (and independent) investigators. Peak Nasal Inspiratory Flow (PNIF) as well as Logarithmic Calculated Nasal Resistance (LReff) before and after decongestion with 0.1% Xylometazoline spray were 4 times measured, each. Analysis of variance was applied for statistical evaluation.

**Results:** The precision / tolerance ratio was with 10% and 30% acceptable. PNIF as well as LReff results showed no significant investigator effect before and after decongestion, whereas the patient's effect has been highly significant. Model fit was high ( $R^2(\text{PNIF}) = 0.9$ ) to moderate ( $R^2(\text{LReff}) = 0.4$  to  $0.5$ ).

**Conclusions:** 4PR is a precise method with no investigator effect, i.e. the results of the gauge are independent from the chosen investigator. The significant patient's effect testifies that the gauge can detect the differences between patients. PNIF is an easy, quick and simple method but produces hidden errors by excluding systematically the information about elastic properties of the lateral nasal wall, which is closing the nose in maximum inspiration.

202988

## An audit on consenting process for endoscopic sinus surgery

**Mandy Mak**<sup>1</sup>, Annakan Navaratnam<sup>1</sup>, Jonathan Joseph<sup>1</sup>

*Otorhinolaryngology, University College London, United Kingdom*

*Miscellaneous 2, Building M1 Room Σ2, Sept 29, 11.45*

**Background:** In the current medicolegal climate, issues surrounding consenting can lead to high litigation costs. This is an audit on the consenting process for endoscopic sinus surgery (ESS), before and after the introduction of electronic patient records (EPR).

**Methods:** A retrospective audit reviewing medical records over two three-month periods before and after introduction of EPR (1/4/2019-30/6/2019 and 2/12/2019-24/2/2020) for patients undergoing ESS. Documentation in outpatient clinic letters and on consent form were reviewed and compared against national guidance (ENT UK patient information leaflets).

**Results:** 162 patients were included, 99 before and 63 after the introduction of EPR. In outpatient clinic documentation, 92% (before EPR) vs. 98% (after EPR) included intended benefits; 61% vs. 84% had all risks (as per guidance) documented. Orbital complications were documented the least often (33% vs. 55%). Documentation of risks was incomplete in outpatient clinic documentation more often compared to consent forms during both study periods ( $p < 0.05$ ), however with EPR this has improved ( $p < 0.05$ ).

**Conclusion:** This audit identifies limitations of current consenting practice in ESS, which may leave the specialty vulnerable to medicolegal interrogation. While the advent of EPR has potential to improve consenting practice, there needs to be more focus in developing a robust patient-specific consenting process.

**Key words:** Consent, endoscopic sinus surgery, medicolegal

## The intestinal dysbiosis in patients suffering from resistant chronic rhinosinusitis (rCRS).

*CRS – pathophysiology 1, Building M1 Room Σ3, Sept 28, 11.45*

**Background :**Chronic rhinosinusitis is one of the most common chronic infections seen by physicians. Despite considerable progress and ongoing research programs, the pathogenesis of CRS remains poorly understood. Based on current knowledge the question rises, if immunological disability caused by the gut dysbiosis could potentially affect the persistence and exacerbation of the mucosal inflammation in sinuses and if it could be influenced by probiotic intervention.

**Methods:** 48 consecutive patients with resistant CRS have been enrolled to the study group in the tertiary referral Department of Otolaryngology in Poznan. The results was based on clinical data collected from ENT and gastroenterology examination, blood tests, and filling the SNOT-22 and the Questionnaire. Each of patient also has administrated probiotic by 3 months.

**Results:**The research showed a change in diet and/or probiotic supplementation alleviates sinus complaints. The allergy occurred in 13/18 (72.2%) patients with intestinal complaints and only in 9/30 (30.0%) patients from the control group. We observed significant difference in SNOT-22 measurement between the intestinal group (SNOT-22 - 15,5) and the control group (SNOT-22 - 19,78).

**Conclusions:** In our study we have established a unique research group of patients with severe CRS. We have found relation between intestinal dysbiosis and exacerbation of disease.

**Keywords:** recurrent chronic rhinoinusitis, gut microbiota, dysbiosis, disease exacerbation, immune deficiencies

## Gigantic paranasal sinuses osteomas: Clinical features, management considerations, and outcomes of 10 cases

**Valentin Sofokleous<sup>1</sup>**, Georgios Pallis<sup>1</sup>, Andriana Razou<sup>1</sup>, Alexandra Karakasi<sup>1</sup>, Aikaterini Demagkou<sup>2</sup>, Efthymios Kyrodimos<sup>1</sup>, Pavlos Maragoudakis<sup>2</sup>, Evangelos Giotakis<sup>1</sup>

<sup>1</sup>*1<sup>st</sup> Department of Otorhinolaryngology - Head & Neck Surgery, National and Kapodistrian University of Athens, General Hospital of Athens "Hippokration", Athens, Greece*, <sup>2</sup>*2<sup>nd</sup> Department of Otorhinolaryngology - Head & Neck Surgery, National and Kapodistrian University of Athens, "Attikon" University Hospital, Athens, Greece*

*Benign nasal tumours 2, Building M1 Room Σ4, Sept 28, 10.15*

**Background:** Osteomas are benign, slow-growing, bony tumours. When larger than 30mm, they are termed "gigantic". Special considerations apply for tumours of this caliber. Less than a hundred cases have been described in the literature, and this makes their management fairly controversial.

**Methodology:** We retrospectively reviewed the files of patients treated for a gigantic osteoma in our Institutions in years 2008-2019.

**Results:** Ten patients were included (mean age: 53.8 years, equal sex ratio). The leading presenting findings were proptosis (80%) and diplopia (70%), while the frequency of transient visual impairment was remarkably high (30%). A coexisting mucocele was seen in half of our patients. Five patients were managed with an open approach, two with an endoscopic, and three with a combined technique. Intraoperatively, one patient necessitated a lateral canthotomy with inferior cantholysis due to intraorbital bleeding, and another a duraplasty due to intraoperative CSF leak. No major postoperative complications were observed, and also no recurrences (mean follow-up: 42.4 months).

**Conclusions:** Despite their benign nature, osteomas may occasionally grow significantly and prod into adjacent noble structures. Managing these massive tumours solely endoscopically could, in certain cases, be inefficacious or impossible. Open approaches remain valuable, representing a safe and straightforward method for adequate exposure.

**Key words:** gigantic osteoma, frontal sinus, ethmoid sinus, endoscopic sinus surgery, osteoplastic flap procedure

### Literature

1. Lund, V. J. et al. European position paper on endoscopic management of tumours of the nose, paranasal sinuses and skull base. *Rhinol. Suppl.* 22, 1–143 (2010).
2. Cheng, K. J., Wang, S. Q. & Lin, L. Giant osteomas of the ethmoid and frontal sinuses: Clinical characteristics and review of the literature. *Oncology Letters* 5, 1724–1730 (2013).
3. Nguyen, S. & Nadeau, S. Giant Frontal Sinus Osteomas: Demographic, Clinical Presentation, and Management of 10 Cases. *Am. J. Rhinol. Allergy* 33, 36-43 (2018).
4. Turri-Zanoni, M. et al. Frontoethmoidal and intraorbital osteomas: Exploring the limits of the endoscopic approach. *Arch. Otolaryngol. - Head Neck Surg.* 138, 498–504 (2012).
5. Seiberling, K., Floreani, S., Robinson, S. & Wormald, P.-J. Endoscopic Management of Frontal Sinus Osteomas Revisited. *Am. J. Rhinol. Allergy* 23, 331–336 (2009).

## A Prospective Evaluation of Quality of Life in Patients Undergoing Endoscopic Trans-Sphenoidal Surgery

Narin N Carmel Neiderman, Anat Wengier, Omri Dominsky, others others, Zvi Ram, Dan M Fliss, **Avraham Abergerl**

*Department of Otolaryngology–Head and Neck Surgery, Tel-Aviv Sourasky Medical Center, affiliated to Sackler Faculty of Medicine, Tel-Aviv University, Tel Aviv, Israel*

*Pituitary Surgery 1, Building M1 Room Σ2, Sept 27, 11.45*

**Introduction:** Endoscopic endonasal surgery has become the preferred approach for pituitary tumor resection. The benefits and postoperative complications of this approach have been discussed extensively in the literature. Nevertheless quality of life (QOL) issues related to pituitary adenoma surgery are rarely investigated in the literature .

**Aim:** To evaluate the short-term QOL after endoscopic endonasal resection of pituitary tumors and to find predictors for poor QOL outcome.

**Materials and Methods:** A prospective cohort study, including all patients who underwent endoscopic trans-sphenoidal surgery (ETSS) for pituitary tumors in Tel Aviv Sorasky Medical Center. Patients completed anterior skull base disease specific QOL (ASBS) questionnaire and Sinonasal Outcome Test 22 (SNOT-22) questionnaires prior to surgery, 2 and 4-6 month after surgery.

**Results:** Our study included 49 patients. The overall ASBS Questionnaire scores significantly improved 4-6 month after surgery (overall average score of 4.46 vs 4.2,  $P < 0.05$ ). Analysis of the different QOL dimensions demonstrated a significant improvement in role emotional dimension was found after 2 month (average score of 4.41 vs 3.87,  $P < 0.05$ ), and only borderline significant improvement was found after 4-6 month. Significant QOL improvement was found after 4-6 month in 2 dimensions: pain (subscale average score of 4.5 vs 4.08,  $P < 0.05$ ) and vitality (average score of 4.43 vs 4.16,  $P < 0.05$ ). No statistical difference was found in SNOT-22 scores before and after surgery. No significant differences were found in quality of life scores between patients with secreting and non-secreting tumors, patients with huge adenomas, patients with intra-operative CSF leak and patients with nasoseptal flap reconstruction.

**Conclusion:** Endoscopic transphenoidal approach for pituitary tumor is not related with negative impact on QOL. On the contrary, in our cohort, patient overall quality of life 4 to 6 month post operatively significantly improved, with specific significant improvement of the dimensions of pain and vitality.

## Multifactorial immunodeficiency and nasal mucormycosis. Disease free against all odds- a case report.

**Eleni Chalkiadaki**<sup>1</sup>, Thiresia Kefalogianni<sup>1</sup>, Ioanna Manika<sup>2</sup>, Christos Simantirakis<sup>1</sup>, Anna Stavrianaki<sup>1</sup>, George Lagoudianakis<sup>1</sup>, Efthimios Karakostas<sup>1</sup>

<sup>1</sup>Department of Otorhinolaryngology, General Hospital Venizeleio, Heraklion, Greece

<sup>2</sup>Department of Hematology, General Hospital Venizeleio, Heraklion, Greece

*Miscellaneous 1, Building M1 Room Σ1, Sept 28, 11.45*

**Introduction:** Mucormycosis (Zygomycosis) is a rare, fungal infection with a fulminant course and fatal outcome unless diagnosed early and treated rapidly. Predisposing factors are hematological malignancies, uncontrolled diabetes, organ transplant, trauma and immunosuppressive therapy.

**Case description:** A 49-year-old male with multiple myeloma was referred for nasal stuffiness and facial pain.

His underlying conditions apart from relapsed multiple myeloma after autologous stem cell transplantation, were hemophagocytic lymphohistiocytosis (HLH), leishmania and Hepatitis B. Immunosuppression due to the disease (low immunoglobulins) and the intense chemotherapy along with HLH, a fatal syndrome which among others causes pancytopenia and high level of ferritin, composed an ideal background for both common and opportunistic nasal infections.

Clinical examination revealed blackish eschar and necrotic areas of the nasal cavity with osseous exposure, indicative for invasive fungal infection. Due to high suspicion, cultures and tissue samples were immediately obtained, CT scan was requested and amphotericin B was administered empirically. Mucormycosis was confirmed and although surgical debridement was postponed by 2 months, due to forbiddingly low platelets count and unstable underlying patient's condition, he remained disease-free with no new deficits for a 5 months' follow-up.

**Discussion:** Early diagnosis and treatment are of extreme importance for successful eradication of invasive fungal infection. High suspicion in immunocompromised patients is fundamental.

**Key words:** mucormycosis, invasive fungal infection, hemophagocytic lymphohistiocytosis, hematological malignancies

### Literature

1. Blitzler A, Lawson W, Meyers BR, Biller HF. [Patient survival factors in paranasal sinus mucormycosis](#). The Laryngoscope, 1980; 90(4):635-648. doi:10.1288/00005537-198004000-00010
2. Fahimzad A, Chavoshzadeh Z, Abdollahpour H, Klein C et al. Necrosis of Nasal Cartilage due to Mucormycosis in a Patient With Severe Congenital Neutropenia due to HAX1 Deficiency. J Investig Allergol Clin Immunol, 2008;18(6): 469-472
3. Ferguson BJ. Mucormycosis of the nose and paranasal sinuses. Otolaryngol Clin North Am, 2000;33(2): 349-365, doi:10.1016/S0030-6665(00)80010-9
4. Auluck A. Maxillary necrosis by mucormycosis. a case report and literature review. Medicina Oral, Patologia Oral y Cirugia Bucal, 2007, 12(5):360-364. PMID: 17767099

5. Nussbaum E, Hall W. Rhinocerebral Mucormycosis: Changing Patterns of Disease. *Surgical Neurology*, 1994;41(2):152-156 doi: [https://doi.org/10.1016/0090-3019\(94\)90114-7](https://doi.org/10.1016/0090-3019(94)90114-7)
6. Pillsbury H, Fischer N. Rhinocerebral Mucormycosis. *Arch Otolaryngol*, 1977;103(10):600-604. doi:10.1001/archotol.1977.00780270068011
7. Fisher EW, Toma A, Fisher PH, Cheesman AD, Rhinocerebral mucormycosis: Use of liposomal amphotericin B. *The Journal of Laryngology and Otology*, 1991;105: 575-577 doi: <https://doi.org/10.1017/S0022215100116652>
8. Peterson KL, Wang M, Canalis RF, Abemayor E, Rhinocerebral Mucormycosis: Evolution of the Disease and Treatment Options. *The laryngoscope*, 1997;107(7):855-862. Doi: <https://doi.org/10.1097/00005537-199707000-00004>



203097

## A molecular trigger of Post-anosmic parosmia.

**S. Gane**<sup>1</sup>, Chrissi Kelly<sup>2</sup>, Jane K. Parker<sup>3</sup>

*Royal National Ear, Nose and Throat and Eastman Dental Hospital, University College London Hospital, London, UK, AbScent, 14 London Road, Andover, Hampshire, UK, Department of Food and Nutritional Sciences, University of Reading, Whiteknights, Reading, RG6 6AP, UK*

*Smell and taste 3, Building M2 CR3, Sept 27, 14.45*

**Background:** Parosmia is often the most debilitating part of the recovery period after smell loss. It can lead to weight loss and persistent difficulties with diet. Often parosmia sufferers report the same few foods as triggers, (e.g. coffee) which would not be explained by the "miswiring" of the olfactory bulb hypothesis.

**Methodology/Principal:** Using a smelling port on a gas chromatograph it is possible to fractionate the odorants from a given food odour and expose parosmic volunteers to them one at a time, correlating their olfactory percepts with mass spectra to identify the trigger molecules.

**Results:** Whereas on average normosmics (n=13) detected 40 compounds from an extract of coffee, the parosmics (n=14) detected just 20. However, there was a small group of highly odour-active compounds which elicited disgust and distortion in the parosmic group. Of these, furfural mercaptan was most frequently reported as distorted (12/14). In contrast, diacetyl (buttery, toffee) was always pleasant and never described as distorted.

**Conclusions:** We propose that there is a trigger molecule for coffee parosmia: furfuryl mercaptan. This has implications for our understanding of the regeneration of olfactory mucosa after smell loss as well as the underlying mechanism of parosmia.

**Key words:** Anosmia, parosmia, post-infectious smell loss, olfaction, smell

Literature

**B. Duhlenki<sup>1</sup>**, Al.Valkov<sup>1</sup>, Tsv.Mladenov<sup>1</sup>, Tsv. Stoyanov<sup>1</sup>, G.Nikolov<sup>1</sup>, M. Yildiz<sup>1</sup>

<sup>1</sup>*Clinic of ENT and Maxillofacial surgery UMHAT "D-r Georgi Stransky" - Pleven, Bulgaria*

*Snoring and OSA 1, Building M2 CR2, Sept 28, 14.45*

**Background:** Obstructive Sleep Apnea (OSA) is a sleep-related breathing disorder, leading to decreased quality of life, increased risk of cardiovascular morbidity and mortality, increased frequency of automobile accidents. Continuous positive airway pressure (CPAP) remains the first line of treatment for OSA. Many patients are unwilling or incapable to tolerate the treatment and therefore turn to surgical options to alleviate symptoms and sequelae of the disease.

**Aim:** To present our experience in the surgical treatment of OSA.

**Materials and Methods:** 50 patients (48 male / 2 female) underwent surgical treatment for OSA in our clinic over a 10-year period. Subjective complaints were evaluated by interview of the patient and partner pre- and postoperatively, with key factors studied being snoring level (visual analogue 1-10) and Epworth Sleepiness Scale (ESS). Objective data were Body Mass Index (BMI), nasal endoscopy, pre and postoperative polysomnographic data, Mallampati score, diagnostic imaging of the nose and sinuses.

**Results:** The mean BMI of the patients was  $29.8 \pm 3.4$ . 21 patients had nasal obstruction for which they underwent surgical treatment. 5 patients had micro or retrognathia. 37 patients had a Mallampati score of 3 and 13 of 4. All 50 patients underwent Uvulopalatopharyngoplasty (UPPP) and 6 patients also had Radiofrequency tongue base reduction. There were no serious complications. Subjective improvement in the severity of the symptoms was obtained in 88% (44) of patients. Objective success was obtained in 56% (28) of the patients.

**Conclusions:** Surgical treatment of OSA leads to a significant subjective improvement in the severity of symptoms and acceptable objective results. For optimal results a multidisciplinary approach is required, for the complex treatment of OSA.

**Key words:** UPPP, OSA, surgical treatment

## Sinonasal malignancies: a retrospective review of a Portuguese cancer centre's experience

**L. Castelhana**<sup>1</sup>, F. Correia<sup>1</sup>, D. Raposo<sup>2</sup>, A. Campos<sup>3</sup>, M. Melo<sup>2</sup>, S. Pereira<sup>4</sup>, M. Mariano<sup>4</sup>, L. Ferreira<sup>5</sup>, P. Montalvão<sup>5</sup>, M. Magalhães<sup>5</sup>

<sup>1</sup>Department of Otolaryngology, Hospital de Egas Moniz, Centro Hospitalar Lisboa Ocidental, Lisbon, Portugal,

<sup>2</sup>Department of Otolaryngology, Hospital Fernando da Fonseca, Lisbon, Portugal, <sup>3</sup>Department of Otolaryngology, Hospital CUF Infante Santo, Lisbon, Portugal, <sup>4</sup>Department of Otolaryngology, Hospital de São José, Centro Hospitalar Lisboa Central, Lisbon, Portugal, <sup>5</sup>Department of Otolaryngology, Instituto Português de Oncologia Francisco Gentil, Lisbon, Portugal

*Sinonasal malignancy 4, Building M1 Room 24, Sept 27, 14.45*

**Background:** The purpose of this study was to characterise a Portuguese cancer centre's experience regarding sinonasal malignancies.

**Methodology:** Retrospective review of patients with malignancies of the nose and paranasal sinus from 2010 to 2014. Univariate and multivariate analysis were performed.

**Results:** We identified 90 patients with malignant tumours of the sinonasal tract; 58 men and 32 women. The mean age at diagnosis was 62.82 years and median follow-up was 44.46 months. . The maxillary sinus (33.33%) and the nasal cavity (32.22%) were the most frequent sites of origin. Squamous cell carcinoma (36.66%), mucosal melanoma (15.56%) and adenoid cystic carcinoma (10%) were the most common histologic subtypes. Neck metastasis occurred in 13.56% of patients, whereas distant metastasis occurred in 3.39%. Surgery was the primary treatment for 86.67% of patients. In 38.46% surgical resection was incomplete, with positive margins. Recurrence occurred in 31 patients (34.44%). The overall 5-year survival rate was 46.67%. Survival was significantly decreased in patients with T3-4 tumours ( $p=.007$ ), positive lymph nodes ( $p<.001$ ), non-epithelial tumours ( $p=.036$ ) and positive margins ( $p=.032$ ). Survival was not affected by surgical approach ( $p=.088$ ).

**Conclusions:** Non-epithelial tumours, advanced-stage and positive margins portend a poor prognosis. In selected patients, endoscopic resections can provide acceptable outcomes.

**Key words:** Sinonasal tract malignancies, squamous cell carcinoma, mucosal melanoma, endoscopic sinus surgery

### Literature

Bhayani MK, et al. Sinonasal adenocarcinoma: A 16-year experience at a single institution. Head Neck. 2014 Oct;36(10):1490-6

Higgins TS, et al. Outcome results of endoscopic vs craniofacial resection of sinonasal malignancies: a systematic review and pooled-data analysis. Forum Allergy Rhinol. 2011 Jul-Aug;1(4):255-61

Goldenberg, et al. Malignant tumors of the nose and paranasal sinuses: A retrospective review of 291 cases. Ear Nose Throat J. 2001 Apr;80(4):272-7

Meccariello G, et al. Endoscopic nasal versus open approach for the management of sinonasal adenocarcinoma: A pooled-analysis of 1826 patients. Head Neck. 2016 Apr;38 Suppl 1:E2267-74

Cabrerizo JR, et al. Revision of Carcinomas in Paranasal Sinus. Acta Otolaringol Esp. 2007 Jan;58(6):266-75

Suh JD, et al. Outcomes and Complications of Endoscopic Approaches for Malignancies of the Paranasal Sinuses and Anterior Skull Base. Ann Otol Rhinol Laryngol. 2013 Jan;122(1):54-9

## Epistaxis severity and quality of life in Hereditary Haemorrhagic Telangiectasia: a cross-sectional study

**Eugenia Maiorano**<sup>1</sup>, Elina Matti<sup>2</sup>, Sara Ugolini<sup>1</sup>, Roberta Lizzio<sup>1</sup>, Rosolino Mirabella<sup>1</sup>, Ludovica Nanfitò<sup>1</sup>, Alessandro Pusateri<sup>3</sup>, Giuseppe Spinozzi<sup>2</sup>, Fabio Pagella<sup>1</sup>,

<sup>1</sup>Department of Otorhinolaryngology, Fondazione IRCCS Policlinico San Matteo, University of Pavia, Pavia, Italy,

<sup>2</sup> Department of Otorhinolaryngology, Fondazione IRCCS Policlinico San Matteo, Pavia, Italy, <sup>3</sup> Otorhinolaryngology Unit, ASST Papa Giovanni XXIII, Bergamo, Italy

*Epistaxis and HHT 2, Building M1 Room E3, Sept 29, 11.45*

**Background:** Epistaxis is the most common cause of disability and social impairment in Hereditary haemorrhagic telangiectasia (HHT) patients. The aim of this study was to analyse epistaxis severity and quality of life (QoL) in a cohort of HHT patients, stratifying the results according to clinical findings typical of the disease or even not directly associated with HHT.

**Methodology:** This is a descriptive, cross-sectional, observational study that included 234 HHT patients. All patients underwent physical examination, nasal endoscopy and filled in the Short Form Health Survey (SF-36) and the Epistaxis Severity Score (ESS). The Shapiro-Wilk test was used to test the normal distribution of quantitative variables. Correlation between quantitative variables was evaluated with Person's coefficient. Uni- and multivariate linear regression models were fitted to find associations between demographic or clinical factors and ESS score or SF-36.

**Results:** ESS is significantly affected by high blood pressure, arteriovenous malformation (AVMs), nocturnal epistaxis, septal perforation and hormonal therapy. AVMs, high blood pressure, hormonal therapy, nocturnal epistaxis, blood transfusions, previous surgery and in particular the presence of septal perforation play an important role in determining various aspects of health.

**Conclusions:** It's the first study in Europe involving such a large number of HHT patients and the first overall taking into account different clinical parameters to analyse their correlation with epistaxis severity and QoL.

**Key words:** Hereditary haemorrhagic telangiectasia HHT, epistaxis severity, quality of life, ESS, SF-36

### Literature

1. Faughnan, M. E. et al. International guidelines for the diagnosis and management of hereditary haemorrhagic telangiectasia. *J. Med. Genet.* **48**, 73–87 (2011).
2. Sadick, H. et al. Hereditary hemorrhagic telangiectasia: an update on clinical manifestations and diagnostic measures. *Wien. Klin. Wochenschr.* **118**, 72–80 (2006).
3. Shovlin, C. L. et al. Diagnostic criteria for hereditary hemorrhagic telangiectasia (Rendu-Osler-Weber syndrome). *Am. J. Med. Genet.* **91**, 66–7 (2000).
4. McDonald, J., Bayrak-Toydemir, P. & Pyeritz, R. E. Hereditary hemorrhagic telangiectasia: An overview of diagnosis, management, and pathogenesis. *Genet. Med.* **13**, 607–616 (2011).
5. Azuma, H. Genetic and molecular pathogenesis of hereditary hemorrhagic telangiectasia. *J. Med. Invest.* **47**, 81–90 (2000).
6. Merlo, C. A., Yin, L. X., Hoag, J. B., Mitchell, S. E. & Reh, D. D. The effects of epistaxis on health-related quality of life in patients with hereditary hemorrhagic telangiectasia. *Int. Forum Allergy Rhinol.* **4**, 921–5 (2014).
7. Andrejcsk, J. W. et al. Executive summary of the 12th HHT international scientific

- conference. *Angiogenesis* (2017). doi:10.1007/s10456-017-9585-2
8. Pagella, F. et al. Correlation of Severity of Epistaxis with Nasal Telangiectasias in Hereditary Hemorrhagic Telangiectasia (HHT) Patients. *Am. J. Rhinol. Allergy* **23**, 52–58 (2009).
  9. Hoag, J. B., Terry, P., Mitchell, S., Reh, D. & Merlo, C. A. An epistaxis severity score for hereditary hemorrhagic telangiectasia. *Laryngoscope* **120**, 838–843 (2010).
  10. Ware JE Jr, Snowk K, Kosinski M, G. B. SF-36 Health Survey Manual and Interpretation Guide. Boston, Ma Heal. Institute, New Engl. Med. Cent. (1993).
  11. Apolone, G. & Mosconi, P. The Italian SF-36 Health Survey: translation, validation and norming. *J. Clin. Epidemiol.* **51**, 1025–36 (1998).
  12. Pagella, F. et al. Treatment of epistaxis in hereditary hemorrhagic telangiectasia patients by argon plasma coagulation with local anesthesia. *Am. J. Rhinol.* **20**, 421–5 (2006).
  13. Pasculli, G. et al. Health-related quality of life in a rare disease: Hereditary hemorrhagic telangiectasia (HHT) or Rendu?Osler?Weber Disease. *Qual. Life Res.* **13**, 1715–1723 (2004).
  14. Lennox, P. A., Hitchings, A. E., Lund, V. J. & Howard, D. J. The SF-36 health status questionnaire in assessing patients with epistaxis secondary to hereditary hemorrhagic telangiectasia. *Am. J. Rhinol.* **19**, 71–4 (2005).
  15. Geisthoff, U. W. et al. Health-Related Quality of Life in Hereditary Hemorrhagic Telangiectasia. *Otolaryngol. Neck Surg.* **136**, 726–733 (2007).
  16. Ingrand, I. et al. Altered quality of life in Rendu-Osler-Weber disease related to recurrent epistaxis. *Rhinology* **49**, 155–62 (2011).
  17. Geirdal, A. Ø., Dheyauldeen, S., Bachmann-Harildstad, G. & Heimdal, K. Quality of life in patients with hereditary hemorrhagic telangiectasia in Norway: A population based study. *Am. J. Med. Genet. Part A* **158A**, 1269–1278 (2012).
  18. Loaëc, M. et al. Psychosocial quality of life in hereditary haemorrhagic telangiectasia patients. *Rhinology* **49**, 164–7 (2011).
  19. Higa, L. A., McDonald, J., Himes, D. O. & Rothwell, E. Life experiences of individuals with hereditary hemorrhagic telangiectasia and disclosing outside the family: a qualitative analysis. *J. Community Genet.* **7**, 81–9 (2016).
  20. Zarrabeitia, R. et al. Quality of life in patients with hereditary haemorrhagic telangiectasia (HHT). *Health Qual. Life Outcomes* **15**, 19 (2017).
  21. Edwards, C. P., Shehata, N. & Faughnan, M. E. Hereditary hemorrhagic telangiectasia patients can tolerate anticoagulation. *Ann. Hematol.* **91**, 1959–68 (2012).
  22. Devlin, H. L., Hosman, A. E. & Shovlin, C. L. Antiplatelet and Anticoagulant Agents in Hereditary Hemorrhagic Telangiectasia. *N. Engl. J. Med.* **368**, 876–878 (2013).
  23. Jameson, J. J. & Cave, D. R. Hormonal and antihormonal therapy for epistaxis in hereditary hemorrhagic telangiectasia. *Laryngoscope* **114**, 705–9 (2004).
  24. Yaniv, E., Preis, M., Shevro, J., Nageris, B. & Hadar, T. Anti-estrogen therapy for hereditary hemorrhagic telangiectasia - a long-term clinical trial. *Rhinology* **49**, 214–6 (2011).
  25. Shovlin CL, Buscarini E, Kjeldsen AD, et al. European Reference Network For Rare Vascular Diseases (VASCERN) Outcome Measures For Hereditary Haemorrhagic Telangiectasia (HHT). *Orphanet J. Rare Dis.* 2018; 13:136.
  26. Dheyauldeen S, Abdelnoor M and Bachmann-Harildstad G. The natural history of epistaxis in patients with hereditary hemorrhagic teleangiectasia in the Norwegian population: a cross-sectional study. *Am. J. Rhinol. Allergy* 2011; 25 (4): 214-218.
  27. Al-Deen S, Bachmann-Harildstad G. A grading scale for epistaxis in hereditary haemorrhagic teleangiectasia. *Rhinology* 2008; 46:281–4.



203114

Our preliminary experience in the use of an ultrasonic scalpel in endoscopic transnasal approaches to infratemporal fossa: a report of three cases.

Federico Russo<sup>1</sup>, Elisa Coden<sup>1</sup>, Mario Turri Zaroni<sup>1;2</sup>, Paolo Castelnovo<sup>1;2</sup>, Paolo Battaglia<sup>1;2</sup>

<sup>1</sup>Department of Otorhinolaryngology, University of Insubria and ASST Sette Laghi, Varese, Italy

<sup>2</sup>Department of Biotechnology and Life Sciences, University of Insubria, Varese, Italy

*Abstract Session 32, Building M2 CR1, Sept 28, 14.45*

**Background.** Ultrasound-based surgical instruments have been widely used in head and neck surgery for coagulation and cut of different soft tissues. Nonetheless, their application in endoscopic endonasal surgery is so far limited.

**Methodology.** We present a series of 3 patients who were submitted to endoscopic endonasal resection of infratemporal fossa (ITF) tumors using an ultrasound scalpel.

**Results.** The patients enrolled were the following: a 31-year old woman with mature teratoma; a 32-year old woman with hemangiopericytoma; a 13-year old boy with juvenile nasopharyngeal angiofibroma. Transnasal endoscopic partial maxillectomy and trans-ethmoid-pterygoid approach to ITF were performed. The ultrasonic scalpel was used in cauterization and section of vascular structures and pterygoid muscles; it also improved pericapsular dissection along the tumor. Complete removal was obtained in all cases with reduced operating times; no intra/postoperative complications occurred. After a mean follow-up of 36 months, no recurrences were observed.

**Conclusions.** Compared to traditional instruments, advantages of the ultrasonic scalpel include easier pericapsular dissection and improved hemostatic efficacy with reduced heat-induced tissue damages. The main drawback is the excessive dimension of the tip for sinonasal spaces. Future adaptations might promote further minimally-invasive surgical developments for an anatomically complex and highly vascularized region such as the ITF.

**Key words:** ultrasound; ultrasonic scalpel; infratemporal fossa; cauterization; endoscopic surgery

Literature:

1. Bozkurt G, Turri-Zaroni M, Russo F, Elhassan H, Castelnovo P, Battaglia P Ultrasonic Scalpel–Assisted Endoscopic Endonasal Surgery of Infratemporal Fossa: Our First Impressions. *World Neurosurgery* 123 (2018)



## Surgical treatment of epistaxis in Hereditary Haemorrhagic Telangiectasia: our experience

**Eugenia Maiorano<sup>1</sup>**, Elina Matti<sup>2</sup>, Sara Ugolini<sup>1</sup>, Roberta Lizzio<sup>1</sup>, Rosolino Mirabella<sup>1</sup>, Valeria Pizzoglio<sup>1</sup>, Alessandro Pusateri<sup>3</sup>, Giuseppe Spinozzi<sup>2</sup>, Carmine Tinelli<sup>4</sup>, Carla Olivieri<sup>5</sup>, Fabio Pagella<sup>1</sup>

<sup>1</sup> Department of Otorhinolaryngology, Fondazione IRCCS Policlinico San Matteo, University of Pavia, Pavia, Italy,

<sup>2</sup> Department of Otorhinolaryngology, Fondazione IRCCS Policlinico San Matteo, Pavia, Italy, <sup>3</sup> Otorhinolaryngology Unit, ASST Papa Giovanni XXIII, Bergamo, Italy, <sup>4</sup> Clinical Epidemiology and Biometry Unit, Fondazione IRCCS Policlinico San Matteo, Pavia, Italy, <sup>5</sup> Molecular Medicine Department, General Biology and Medical Genetics Unit, University of Pavia, Italy

*Epistaxis and HHT 2, Building M1 Room Σ3, Sept 29, 11.45*

**Background:** Epistaxis from nasal telangiectasia are present in more than 95% of Hereditary Haemorrhagic Telangiectasia patients. Surgical procedures for epistaxis may be classified as mini-invasive and more invasive. The main advantages of mini-invasive techniques are less morbidity, reduced trauma of nasal mucosa, low-risk of septal perforation, treatment repeatability, no need for post-surgical nasal packing and short time of hospitalization. The aim of this paper is to report our experience in surgical management of epistaxis in HHT patients.

**Methodology:** This is a descriptive, observational study that included 591 patients hospitalized and screened for the HHT in our Department; 327 underwent surgery for epistaxis, for a total of 683 procedures. In most cases, an endoscopic endonasal mini-invasive surgical procedure was performed.

**Results:** Mean age at first surgery was 56 years. In 177 patients (54.1%), one surgical procedure was effective in order to control epistaxis, while 150 patients (45.9%) required more than one procedure over time. A detailed summary of each surgical technique is described in this report.

**Conclusions:** In our experience, endoscopic endonasal mini-invasive surgical options allow a control of epistaxis in HHT patients. These treatment modalities are minimally invasive, well tolerated, and could be used as a first step even in patients with severe epistaxis.

**Key words:** Hereditary Haemorrhagic Telangiectasia HHT, epistaxis, nosebleed, endoscopy, Argon Plasma Coagulation

### Literature

1. Porteous MEM, Burns J, Proctor SJ (1992) Hereditary haemorrhagic telangiectasia: A clinical analysis. *J Med Genet* 29:527–530.
2. Cottin V, Plauchu H, Bayle JY, et al. (2004) Pulmonary arteriovenous malformations in patients with hereditary hemorrhagic telangiectasia. *Am J Respir Crit Care Med* 169:994–1000.
3. Govani F, Shovlin C (2009) Hereditary haemorrhagic telangiectasia: a clinical and scientific review. *Eur J Hum Genet* 17:860–871.
4. Shovlin CL, Guttmacher AE, Buscarini E, et al. (2000) Diagnostic criteria for hereditary hemorrhagic telangiectasia (Rendu-Osler-Weber syndrome). *Am J Genet* 91:66–67.
5. Bergler W, Sadick H, Gotte K, et al. (2002) Topical estrogens combined with argon plasma coagulation in the management of epistaxis in hereditary hemorrhagic telangiectasia. *Ann Otol Rhinol Laryngol* 111:222–228.

6. Al-Deen S, Bachmann-Harildstad G (2008) A grading scale for epistaxis in hereditary haemorrhagic telangiectasia. *Rhinology* 46:281–284.
7. Pagella F, Colombo A, Matti E, et al. (2009) Correlation of severity of epistaxis with nasal telangiectasias in hereditary hemorrhagic telangiectasia (HHT) patients. *Am J Rhinol Allergy* 23:52–58.
8. Hoag J, Terry P, Mitchell S, Reh D, Merlo C (2010) An epistaxis severity score for hereditary hemorrhagic telangiectasia. *Laryngoscope* 120:838–843.
9. Pagella F, Pusateri A, Chu F, et al. (2013) Narrow-Band Imaging in the Endoscopic Evaluation of Hereditary Hemorrhagic Telangiectasia Patients. *Laryngoscope* 123:2967–2968.
10. Geisthoff U, Fiorella M, Fiorella R (2006) Treatment of recurrent epistaxis in HHT. *Curr Pharm Des* 12:1237–1242.
11. Invernizzi R, Quaglia F, Klersy C, et al. (2015) Efficacy and safety of thalidomide for the treatment of severe recurrent epistaxis in hereditary haemorrhagic telangiectasia: results of a non-randomised, single-centre, phase 2 study. *Lancet Haematol* 2:e465–473.
12. Gaillard S, Dupuis-Girod S, Boutitie F, et al. (2014) Tranexamic acid for epistaxis in hereditary hemorrhagic telangiectasia patients: a European cross-over controlled trial in a rare disease. *J Thromb Haemost* 12:1494–1502.
13. Dupuis-Girod S, Ambrun A, Decullier E. (2014) ELLIPSE Study: a phase 1 study evaluating the tolerance of bevacizumab nasal spray in the treatment of epistaxis in hereditary hemorrhagic telangiectasia. *MAbs* 6:794–799.
14. Lund V, Howard D. A treatment algorithm for the management of epistaxis in hereditary hemorrhagic telangiectasia. *Am J Rhinol*. 1999; 13:319–322.
15. Lund V, Howard D (1997) Closure of the nasal cavities in the treatment of refractory hereditary haemorrhagic telangiectasia. *J Laryngol Otol* 111:30–33.
16. Gluckman J, Portugal L (1994) Modified Young's procedure for refractory epistaxis due to hereditary hemorrhagic telangiectasia. *Laryngoscope* 104:1174–1177.
17. Hosni A, Innes A (1994) Hereditary haemorrhagic telangiectasia: Young's procedure in the management of epistaxis. *J Laryngol Otol* 108:754–757.
18. Serrano E, Percodani J, Pessey J (1998) Bilateral closure of the nasal cavity. An original surgical technique of treatment of severe recurrent epistaxis in Rendu-Osler disease. *Ann Otolaryngol Chir Cervicofac* 115:169–173.
19. Pagella F, Semino L, Olivieri C, et al. (2006) Treatment of epistaxis in Hereditary Hemorrhagic Telangiectasia (HHT) patients by argon plasma coagulation with local anesthesia. *Am J Rhinol* 20:421–425.
20. Lesnik GT, Ross DA, Henderson KJ, et al. (2007) Septectomy and septal dermoplasty for the treatment of severe transfusion-dependent epistaxis in patients with hereditary hemorrhagic telangiectasia and septal perforation. *Am J Rhinol* 21:312–315
21. Pagella F, Matti E, Chu F, et al. (2013) Argon plasma coagulation is an effective treatment for hereditary hemorrhagic telangiectasia patients with severe nosebleeds. *Acta Oto-Laryngologica* 133:174–180
22. Bergler W, Riedel F, Baker-Schreyer A, et al. (1999) Argon Plasma coagulation for the treatment of hereditary hemorrhagic telangiectasia. *Laryngoscope* 109:15–20.
23. Olivieri C, Pagella F, Semino L, et al. (2007) Analysis of ENG and ACVRL1 genes in 137 HHT Italian families identifies 76 different mutations (24 novel). Comparison with other European studies. *J Hum Genet* 52:820–829.

24. Silva BM, Hosman AE, Devlin HL, et al. (2013) Lifestyle and dietary influences on nosebleed severity in hereditary hemorrhagic telangiectasia. *Laryngoscope*; 123:1092–1099.
25. Sautter NB, Smith TL (2016) Treatment of Hereditary Hemorrhagic Telangiectasia-Related Epistaxis. *Otolaryngol Clin North Am* 49:639–654.
26. Chen S, Karnezis T, Davidson TM (2010) Safety of intranasal bevacizumab (Avastin) treatment in patients with hereditary hemorrhagic telangiectasia-associated epistaxis. *Laryngoscope* 121:644–646.
27. Chin CJ, Rotenberg BW, Witterick IJ (2016) Epistaxis in hereditary hemorrhagic telangiectasia: an evidence based review of surgical management. *J Otolaryngol Head Neck Surg* 45:3.
28. Ghaheri BA, Fong KJ, Hwang PH (2006) The utility of bipolar electrocautery in hereditary hemorrhagic telangiectasia. *Otolaryngol Head Neck Surg* 134:1006–1009.
29. Ishibashi T, Takamatsu S (2003) Hereditary hemorrhagic telangiectasis treated by the harmonic scalpel. *Head Neck* 25:333–336.
30. Luk L, Mace JC, Bhandarkar ND, Sautter NB (2014) Comparison of electrosurgical plasma coagulation and potassium-titanyl-phosphate laser photocoagulation for treatment of hereditary hemorrhagic telangiectasia-related epistaxis. *Int Forum Allergy Rhinol* 4:640–645.
31. Rotenberg BW, Noyek S, Chin CJ (2015) Radiofrequency ablation for treatment of hereditary hemorrhagic telangiectasia lesions: “How I do it”. *Am J Rhinol Allergy* 29:226–227.
32. Joshi H, Woodworth BA, Carney AS (2011) Coblation for epistaxis management in patients with hereditary haemorrhagic telangiectasia: a multicentre case series. *J Laryngol Otol* 125:1176–1180.
33. Whitehead KJ, Sautter NB, McWilliams JP et al. (2016). Effect of Topical Intranasal Therapy on Epistaxis Frequency in Patients With Hereditary Hemorrhagic Telangiectasia: A Randomized Clinical Trial. *JAMA*, 316(9), 943–951.
34. Papaspyrou G, Schick B, Al Kadah B (2016). Nd:YAG Laser Treatment for Extranasal Telangiectasias: A Retrospective Analysis of 38 Patients with Hereditary Hemorrhagic Telangiectasia and Review of the Literature. *ORL; journal for otorhino-laryngology and its related specialties*, 78(5), 245–251.
35. Wirsching K, Kühnel TS (2017). Update on Clinical Strategies in Hereditary Hemorrhagic Telangiectasia from an ENT Point of View. *Clinical and experimental otorhinolaryngology*, 10(2), 153–157.
36. Lund VJ, Darby Y, Rimmer J et al. (2017). Nasal closure for severe hereditary haemorrhagic telangiectasia in 100 patients. The Lund modification of the Young's procedure: a 22-year experience. *Rhinology*, 55(2), 135–141.
37. Poetker DM (2017). Endoscopic-guided coblation treatment of nasal telangiectasias in hereditary hemorrhagic telangiectasia: "How I do it". *American journal of rhinology & allergy*, 31(3), 205–206.
38. Steineger J, Merckoll E, Slåstad JM et al (2018). Osteonecrosis after intranasal injection with bevacizumab in treating hereditary hemorrhagic telangiectasia: A case report. *The Laryngoscope*, 128(3), 593–596.
39. Poje G, Kavanagh MM (2017). Hereditary hemorrhagic telangiectasia-laser treatment of epistaxis. *Ear, nose, & throat journal*, 96(9), E10–E14.



**Saroul N<sup>1</sup>**, Montrieul L<sup>1</sup>, Outh R<sup>2</sup>, Mom T<sup>2</sup>, Andre M<sup>2</sup>, Aumaitre O<sup>2</sup>, Gilain L<sup>1</sup>.

<sup>1</sup>Otolaryngology and head and neck surgery department, University hospital from Clermont-ferrand, 58 rue montalembert, Clermont-ferrand, France, <sup>2</sup>Internal medicine department, University hospital from Clermont-ferrand, 58 rue montalembert, Clermont-ferrand, France

*Granulomatous diseases of the nose 1, Building M1 Room Σ2, Sept 28, 11.45*

**Background :** Retrospective analysis of the rhinologic manifestations in a cohort of 155 patients with ANCA-positive vasculitis.

**Methodology:** 79 men and 76 women were included. The average age at diagnosis was 61 +/- 15.8 years. ANCA-positive vasculitis was divided into 104 granulomatoses with polyangiitis (GPA), 35 eosinophilic granulomatoses with polyangiitis (EGPA) and 16 microscopic polyangiitis (MPA). The rhinologic manifestations were noted at the time of diagnosis of vasculitis.

**Results:** ENT disorders were found in 119 cases (76.8%). They were present in 81.7% of the GPAs, 82.9% of the EGPA and 31.2% of the MAPs respectively. The vasculitis began by ENT symptoms in 45,2% of the GPA patients, 20% of the EGPA and 6,2 % of the MAP. Among ENT symptoms, rhinologic manifestations were predominant (93.3%). Chronic rhinosinusitis with pseudotumour presentation (44.9%) and crusting (32%) predominated in the GPA group and were rare in the EGPA group (3.4% each). Conversely, the existence of nasal polyposis was significantly higher in the EGPA group (75.9%) compared to the GPA group (3.8%).

**Conclusion:** This study confirms the high frequency of rhinologic symptoms in ANCA-positive vasculitis with the high frequency of patients beginning the disease with rhinologic symptoms.

**Key words:** Vasculitis, GPA, EGPA, MPA, rhinologic symptoms

## The orbital depth in European adult dry skulls

Konstantinos Natsis<sup>1</sup>, Maria Piagkou<sup>2</sup>, Paraskevas Vrochidis<sup>1</sup>, Nikolaos Lazaridis<sup>1</sup>, Jannis Konstantinidis<sup>3</sup>

<sup>1</sup>Department of Anatomy and Surgical Anatomy, Medical School, Aristotle University of Thessaloniki, Greece,

<sup>2</sup>Department of Anatomy, Medical School, National and Kapodistrian University of Athens, Greece, <sup>3</sup>1<sup>st</sup> Academic ENT Department, Aristotle University of Thessaloniki, AHEPA Hospital, Thessaloniki, Greece.

*Orbital surgery 1, Building M2 CR3, Sept 29, 11.45*

**Background:** In orbital floor and medial wall fractures, complex orbital geometry makes reconstruction extremely challenging. Current study determines the impact of gender, age and asymmetry on orbital depth and highlights criteria for safe orbital surgery navigation.

**Methothology/Principal:** One hundred and ninety four Greek adult orbits were studied. The following distances were measured:

1. Supraorbital foramen (SOF) inferior border - superior border of the optic foramen midpoint (OFM),
2. Crossing point of the zygomaticomaxillary suture (ZMS) and inferior orbital rim - inferior border of OFM,
3. Frontozygomatic suture (FZS) inner border - lateral border of OFM and
4. Anterior lacrimal crest midpoint (ALCM) - medial border of OFM.

**Results:** The ZMS-OF were 46.42 mm (right side-R) and 45.30 ± 2.65 mm (left side-L), with a right dominance. The ALCM-OF was longer on the R, while SOF-OF had a left preponderance. Symmetry existed in FZS-OF. Gender dimorphism was observed in all parameters with a male preponderance. No correlation was found between the orbital wall lengths and the age. A right dominance was detected for the medial and inferior depth and left dominance for the superior depth.

**Conclusions:** Surgeons must consider differences among various populations when determining navigation landmarks in order to be safely guided to the OF.

**Key words:** orbit, optic foramen, orbital floor, reconstruction, landmarks, surgery

#### Literature

1. Fitzhugh A, Naveed H, Davagnanam I, Messiha A. Proposed three-dimensional model of the orbit and relevance to orbital fracture repair. *Surg Radiol Anat.* 2016;38(5):557–561. doi:10.1007/s00276-015-1561-1
2. Singh J, Rahman RA, Rajion ZA, Abdullah J, Mohamad I. Orbital Morphometry: A Computed Tomography Analysis. *J Craniofac Surg.* 2017;28(1):e64–e70. doi:10.1097/SCS.00000000000003218
3. El-Garem YF. Estimation of bony orbit depth for optimal selection of the injection technique to correct the tear trough and palpebromalar groove. *Dermatol Surg.* 2015;41(1):94–101. doi:10.1097/DSS.0000000000000206

## Morphologic and Morphometric study of the anterior cranial fossa in a Greek population focused on anatomical variations

Panayiotis Papadopoulos<sup>1</sup>, Maria Piagkou<sup>1</sup>, **Paraskevas Vrochidis<sup>2</sup>**, Nikolaos Lazaridis<sup>2</sup>, Jannis Constantinidis<sup>4</sup>, Konstantinos Natsis<sup>2</sup>

<sup>1</sup>Department of Anatomy, School of Medicine, National and Kapodistrian University of Athens, Greece,

<sup>2</sup>Department of Anatomy and Surgical Anatomy, School of Medicine, Aristotle University of Thessaloniki, Greece

, <sup>3</sup>Department of Neurosurgery, General Hospital of Nikaia - Piraeus, Athens, Greece, <sup>4</sup>1<sup>st</sup> Academic ENT Department, Aristotle University of Thessaloniki, AHEPA Hospital, Thessaloniki, Greece.

*Skull base surgery 2, Building M2 CR3, Sept 29, 14.45*

**Background:** In skull base and endoscopic nasal surgery, the in depth anatomical knowledge is of paramount importance in order to achieve an uneventful surgical outcome. Practicing in the dissection room makes surgeon familiar with typical and variant structures. The olfactory fossa (OF) variant morphology and morphometry, possible asymmetry, gender dimorphism or laterality in Greeks were investigated.

**Methodology/Principal:** Fifty adult dried skulls and corresponding computed tomography scans were studied. The anterior cranial fossa sutures, the OF outline and crista galli (CG) morphometry were recorded and correlated, taking into account the gender as well. The morphometric study of each OF was carried out taking into consideration Keros classification.

**Results:** The median maximum CG length, height and thickness were  $19.46 \pm 2.35$ ,  $12.69 \pm 2.7$  and  $5.18 \pm 1.11$ mm, respectively. The median OF length was  $22.29 \pm 2.17$  (right) and  $22.1 \pm 2.44$  (left), the median depth was  $5.08 \pm 2.18$ mm (anterior),  $4.84 \pm 1.95$ mm (middle) and  $2.92 \pm 1.2$ mm (posterior third). Symmetry was recorded for the anterior and middle third, while the posterior third was swallower. The dangerous ethmoid (Keros type III) was found in up to 13%, while types II and I were detected in up to 50% and 37%, respectively. The median OF width was 3.69-23.13 mm gradually increasing from the anterior to the posterior third. A positive linear correlation found between OF and CG length. A statistically significant strong negative linear correlation between OF depth and width was also observed.

**Conclusions:** The OF is the most vulnerable region of skull base and exhibits a remarkable diversity. Three-dimensional imaging of the area should be regarded part of the preoperative planning in order to avoid intraoperative complications.

**Key words:** Keros classification, Olfactory fossa, Anterior cranial base, Cribriform plate, FESS

### Literature

1. ADEEL, M., IKRAM, M., RAJPUT, M. S., ARAIN, A. & KHATTAK, Y. J. 2013. Asymmetry of lateral lamella of the cribriform plate: a software-based analysis of coronal computed tomography and its clinical relevance in endoscopic sinus surgery. *Surg Radiol Anat*, 35, 843-7.
2. ALAZZAWI, S., OMAR, R., RAHMAT, K. & ALLI, K. 2012. Radiological analysis of the ethmoid roof in the Malaysian population. *Auris Nasus Larynx*, 39, 393-396.
3. COELHO, D. H., PENCE, T. S., ABDEL-HAMID, M. & COSTANZO, R. M. 2018. Cribriform plate width is highly variable within and between subjects. *Auris Nasus Larynx*, 45, 1000-1005.

4. GÜLDNER, C., DIOGO, I., WINDFUHR, J., BIEN, S., TEYMOORTASH, A., WERNER, J. A. & BREMKE, M. 2011. Analysis of the fossa olfactoria using cone beam tomography (CBT). *Acta Oto-Laryngologica*, 131, 72-78.
5. GULER, C., UYSAL, I. O., POLAT, K., SALK, I., MUDERRIS, T. & KOSAR, M. I. 2012. Analysis of ethmoid roof and skull base with coronal section paranasal sinus computed tomography. *J Craniofac Surg*, 23, 1460-4.
6. SOLARES, C. A., LEE, W. T., BATRA, P. S. & CITARDI, M. J. 2008. Lateral lamella of the cribriform plate: software-enabled computed tomographic analysis and its clinical relevance in skull base surgery. *Arch Otolaryngol Head Neck Surg*, 134, 285-9.
7. SOUZA, S. A., SOUZA, M. M. A. D., IDAGAWA, M., WOLOSKE, Â. M. B. & AJZEN, S. A. 2008. Computed tomography assessment of the ethmoid roof: a relevant region at risk in endoscopic sinus surgery. *Radiologia Brasileira*, 41, 143-147.
8. VASVARI, G., REISCH, R. & PATONAY, L. 2005. Surgical anatomy of the cribriform plate and adjacent areas. *Minim Invasive Neurosurg*, 48, 25-33.



**Introduction:** Various graft materials have been used in endoscopic repair of skull base defects . Based on its origin , grafts can be classified to autografts , xenografts, allografts or alloplastic . Tutoplast® (Tutogen Medical GmbH) is an allogeneic natural collagen matrix that is processed through chemical sterilization process that preserves tissue biocompatibility and structural integrity.

The purpose of this study is to report our experience in the management of skull base defects with the use of Tutoplast as primary graft material or as a part of a multilayer repair in the endoscopic reconstruction of skull base defects.

**Methodology** It is a retrospective study for patients who underwent endoscopic reconstruction of skull base defects for the repair of primary cerebrospinal fluid leak or post tumor resection at three tertiary care centers (King Faisal Specialist Hospital and Research Center, King Fahad Medical City and Prince Sultan Military Medical City) in Riyadh Saudi Arabia. Data were collected during the period between 2017 and 2020 .

All repairs were performed by a transnasal, endoscopic approach.

**Results :** Tutoplast® (allogeneic , Tutogen Medical GmbH) was used as the primary graft material or as a part of a multilayer repair in 30 cases . Outcome of this study showed success of graft take in 28/30 of cases .

2 cases needed further intervention in the form of lumbar drain placement.

**Conclusion :** Tutoplast can be used safely and effectively for skull base repair defects

203169

Postoperative pain following endoscopic sinus surgery: correlation with radiological and surgical Lund-Mackay score.

**A. Liapi**, A. Marinou, S. Papouliakos, A. Leventi, A. Pavlou, E. Zaharioudaki

*ENT Department, General Hospital of Athens "G.GENNIMATAS", Athens, Greece*

*CRS - outcome assessment 2, Building M1 Room Σ1, Sept 28, 10.15*

**Background:** Pain following endoscopic sinus surgery is a matter of interest in the literature during the past few years. In this prospective study we aim to establish whether there is a correlation between postoperative pain and: i) radiological extent of disease pre-operatively, ii) extent of surgery.

**Methodology:** We enrolled patients who underwent endoscopic sinus surgery between 2018 and 2019 (n=110). Their preoperative CT scans and their operative notes were reviewed by two otolaryngologists to determine radiological and surgical Lund-Mackay score. We also noted whether septoplasty was performed as an adjunct procedure and the type of nasal dressing. Patients reported on their facial pain on a visual analogue scale (VAS) three hours after removal of their nasal packing.

**Results:** Pain after endoscopic sinus surgery was reported as "zero" or "minimal" in all cases (0 to 2 on a ten-point VAS). Postoperative pain was significantly related to radiological Lund-Mackay score (Pearson's  $r = 0.536$ ,  $p = 0.001$ ). It was also significantly related to the surgical score ( $r = 0.610$ ,  $p = 0.001$ ). The type of nasal dressing and the addition of septoplasty as an ancillary procedure did not influence pain scores.

**Conclusion:** Patient discomfort following endoscopic sinus surgery although mild is both related to the magnitude of radiological findings and the extent of surgery.

**Key words:** pain; discomfort; endoscopic sinus surgery; Lund-Mackay score



## The effect of septoplasty on voice: a literature review.

A.Liapi<sup>1</sup>, S. Hirani<sup>2</sup>, J. Rubin<sup>3</sup>

<sup>1</sup>Department of Otolaryngology Head and Neck Surgery, General Hospital of Athens "G. GENNIMATAS", <sup>2</sup> Centre for Health Services Research, School of Health Services, City University, London, UK, <sup>3</sup> University College London Hospitals NHS Trust and University College London, London, UK

*Septal and turbinate surgery 2, Building M2 Study Hall , Sept 29, 14.45*

**Background** Patients undergoing surgery for a deviated nasal septum (septoplasty) often report that their voice sounds different or less hyponasal. However, such a relationship between septoplasty and vocal resonance remains without scientific evidence. The purpose of this study was to systematically review the literature and provide pooled summary estimates to evaluate the effect of septoplasty on voice.

**Methodology** MEDLINE, EMBASE and Google Scholar were searched for relevant studies using the following keywords in various combinations: "septoplasty", "nasal/septal correction", "voice", "nasal resonance", "hyponasal voice".

**Results** Thirteen studies were identified in total. The researchers attempted to identify voice changes after nasal/septal surgery using a variety of measures; such as nasalance scores, acoustic analysis of audio recordings, Voice Handicap Index scores and patient perception through purpose-designed questionnaires. Most authors report minimal or no significant changes in their chosen parameters. The variability in study design, methodology and outcome measures prohibited a systematic approach and summary of pooled estimates.

**Conclusion** Current literature does not support the hypothesis that the voice may sound "less hyponasal" after surgical correction of septal deviations. Lack of homogeneity in study design and outcome measures precludes extraction of reliable results.



# The role of endoscopic Denker's approach in the management of giant juvenile nasopharyngeal angiofibroma with anterolateral extension.

**Sarafidou A.**, Tsinaslanidou Z., Xanthou I., Constantinidis J.

<sup>1st</sup> Academic ENT Department, Aristotle University of Thessaloniki, Greece.

*Benign nasal tumours 1, Building M1 Room Σ3 , Sept 29, 10.15*

**Background:** Juvenile Nasopharyngeal Angiofibroma (JNA) is a rare, benign, locally aggressive tumour, thus always surgically difficult to treat. Various surgical techniques, such as traditional external approaches and endoscopic procedures, have been described for excising those tumours. We describe the use of endoscopic Denker's approach for the resection of giant JNAs.

**Methodology/Principal:** During 2003 and 2018 we treated endoscopically 28 patients with JNA. In seven cases with extensive JNA, stage IIC and IIIA according to the Radkowski classification, we have used the transnasal endoscopic Denker's approach, combined with total ethmoidectomy and sphenoidectomy. All patients underwent preoperative embolization within 48 hours prior to surgery.

**Results:** Total resection of the tumour was possible in all cases using the endoscopic Denker's approach. The intraoperative blood loss was not excessive (300 -900 ml, mean: 580 ml). Mean follow up was 60.1 months. All patients underwent MRI 3, 6, 12, 24 months postoperatively and then if indicated clinically.

**Conclusions:** The endoscopic Denker's approach is an integral part of our armamentarium for the therapeutic management of sinonasal and skull base tumours, especially for such with large anterolateral extension. It is a safe and effective treatment modality due to the lack of external scars and minimal bone resection.

**Key words:** Juvenile Nasopharyngeal Angiofibroma, Endoscopic Denker's approach

## Literature

- Bradoo, R., Joshi, A., Shah, K., Patel, T., & Lohiya, T. (2017). The Four-Port Bradoo Technique: An Alternative to the Modified Endoscopic Denker's Approach for Giant JNA. *Indian Journal of Otolaryngology and Head and Neck Surgery*, 69(3), 277–281. <https://doi.org/10.1007/s12070-017-1150-1>
- Lee, J. T., Suh, J. D., Carrau, R. L., Chu, M. W., & Chiu, A. G. (2017). Endoscopic Denker's approach for resection of lesions involving the anteroinferior maxillary sinus and infratemporal fossa. *Laryngoscope*, 127(3), 556–560. <https://doi.org/10.1002/lary.26237>
- Prosser, J. D., Figueroa, R., Carrau, R. I., Ong, Y. K., & Solares, C. A. (2011). Quantitative analysis of endoscopic endonasal approaches to the infratemporal fossa. *Laryngoscope*, 121(8), 1601–1605. <https://doi.org/10.1002/lary.21863>
- Pamuk, A. E., Özer, S., Süslü, A. E., Akgöz, A., & Önerci, M. (2018). Juvenile nasopharyngeal angiofibroma: A single centre's 11-year experience. *Journal of Laryngology and Otology*. <https://doi.org/10.1017/S0022215118001779>
- Shenouda, K., Yuhán, B. T., Mir, A., Gonik, N., Eloy, J. A., Liu, J. K., Folbe, A. J., & Svider, P. F. (2019). Endoscopic Resection of Pediatric Skull Base Tumors: An Evidence-Based Review. In *Journal of Neurological Surgery, Part B: Skull Base*. <https://doi.org/10.1055/s-0038-1676305>

## The role of endoscopic Denker's approach in the management of giant juvenile nasopharyngeal angiofibroma with anterolateral extension.

Sarafidou A.<sup>1</sup>, Tsinaslanidou Z.<sup>1</sup>, Xanthou I.<sup>1</sup>, Constantinidis J.<sup>1</sup>

<sup>1</sup>*1<sup>st</sup> Academic ENT Department, Aristotle University of Thessaloniki, Greece.*

**Background:** Juvenile Nasopharyngeal Angiofibroma (JNA) is a rare, benign, locally aggressive tumour, thus always surgically difficult to treat. Various surgical techniques, such as traditional external approaches and endoscopic procedures, have been described for excising those tumours. We describe the use of endoscopic Denker's approach for the resection of giant JNAs.

**Methodology/Principal:** During 2003 and 2018 we treated endoscopically 28 patients with JNA. In seven cases with extensive JNA, stage IIC and IIIA according to the Radkowski classification, we have used the transnasal endoscopic Denker's approach, combined with total ethmoidectomy and sphenoidectomy. All patients underwent preoperative embolization within 48 hours prior to surgery.

**Results:** Total resection of the tumour was possible in all cases using the endoscopic Denker's approach. The intraoperative blood loss was not excessive (300 -900 ml, mean: 580 ml). Mean follow up was 60.1 months. All patients underwent MRI 3, 6, 12, 24 months postoperatively and then if indicated clinically.

**Conclusions:** The endoscopic Denker's approach is an integral part of our armamentarium for the therapeutic management of sinonasal and skull base tumours, especially for such with large anterolateral extension. It is a safe and effective treatment modality due to the lack of external scars and minimal bone resection.

Key words: Juvenile Nasopharyngeal Angiofibroma, Endoscopic Denker's approach

### Literature

- Bradoo, R., Joshi, A., Shah, K., Patel, T., & Lohiya, T. (2017). The Four-Port Bradoo Technique: An Alternative to the Modified Endoscopic Denker's Approach for Giant JNA. *Indian Journal of Otolaryngology and Head and Neck Surgery*, 69(3), 277–281. <https://doi.org/10.1007/s12070-017-1150-1>
- Lee, J. T., Suh, J. D., Carrau, R. L., Chu, M. W., & Chiu, A. G. (2017). Endoscopic Denker's approach for resection of lesions involving the anteroinferior maxillary sinus and infratemporal fossa. *Laryngoscope*, 127(3), 556–560. <https://doi.org/10.1002/lary.26237>
- Prosser, J. D., Figueroa, R., Carrau, R. I., Ong, Y. K., & Solares, C. A. (2011). Quantitative analysis of endoscopic endonasal approaches to the infratemporal fossa. *Laryngoscope*, 121(8), 1601–1605. <https://doi.org/10.1002/lary.21863>
- Pamuk, A. E., Özer, S., Süslü, A. E., Akgöz, A., & Önerci, M. (2018). Juvenile nasopharyngeal angiofibroma: A single centre's 11-year experience. *Journal of Laryngology and Otology*. <https://doi.org/10.1017/S0022215118001779>
- Shenouda, K., Yuhan, B. T., Mir, A., Gonik, N., Eloy, J. A., Liu, J. K., Folbe, A. J., & Svider, P. F. (2019). Endoscopic Resection of Pediatric Skull Base Tumors: An Evidence-Based Review. In *Journal of Neurological Surgery, Part B: Skull Base*. <https://doi.org/10.1055/s-0038-1676305>

## Orbital and intracranial complications of paediatric acute rhinosinusitis: a 20-year experience

Francesca De Bernardi<sup>1</sup>, Elisa Coden<sup>1</sup>, Luca Spirito<sup>1</sup>, Stefania Gallo<sup>1</sup>, Francesco Bandi<sup>1</sup>, Alessia Lambertoni<sup>1</sup>, Paolo Castelnovo<sup>1</sup>, Paolo Battaglia<sup>1</sup>, **Mario Turri-Zanoni<sup>1</sup>**.

<sup>1</sup>*Department of Otolaryngology, University of Insubria, Varese, Italy*

*Paediatric rhinology 3, Building M1 Room Σ1, Sept 29, 11.45*

**Background.** Complications of paediatric acute rhinosinusitis are generally divided into two categories: orbital (OC) and intracranial (IC). Although rare, these complications have a significant morbidity and their rates continue to increase over the years. The objectives of this study are to report our experience in the management of OC and IC in children and to evaluate the role of surgery in this field.

**Methodology.** Retrospective case-series of paediatric patients who experienced acute rhinosinusitis with orbital and/or intracranial complications from 2000 to 2020 in a single tertiary-care referral centre. Clinical features, pre-treatment and post-treatment imaging studies and surgical procedure performed for each subject were analysed.

**Results.** A total of 27 children were included. The age ranged from 2 to 18 years (mean, 12 years). The OCs were observed in 85% of cases while ICs in 15%. Endoscopic sinus surgery was performed in all patients to drain the purulent collection(s), eventually associated with an external approach (transcranial or superior eyelid incision) in 6 cases.

**Conclusions.** Orbital and intracranial complications of acute rhinosinusitis are rare but dangerous and should be diagnosed and treated promptly. Functional endoscopic sinus surgery eventually associated with external approaches are mandatory for cases non-responsive to medical treatments.

**Key words:** Acute rhinosinusitis; Intracranial complications; Orbital complications; Paediatric rhinosinusitis; Sinusitis complications.

### Literature

- Hospital utilization for orbital and intracranial complications of pediatric acute rhinosinusitis. Levy DA, et al. Int J Pediatr Otorhinolaryngol 2020.
- Trends in complications of pediatric rhinosinusitis in the United States from 2006 to 2016. Levy DA, et al. Int J Pediatr Otorhinolaryngol 2020.
- Fokkens WJ, Lund VJ, Hopkins C, et al. European Position Paper on Rhinosinusitis and Nasal Polyps 2020. Rhinology. 2020;58(Suppl S29):1–464. Published 2020 Feb 20.
- Neurological Complications of Acute and Chronic Sinusitis. Ziegler A, et al. Curr Neurol Neurosci Rep 2018
- Imaging of Intracranial and Orbital Complications of Sinusitis and Atypical Sinus Infection: What the Radiologist Needs to Know. Velayudhan V, et al. Curr Probl Diagn Radiol 2017
- Orbital Complications Associated with the Treatment of Chronic Rhino sinusitis. Patel AB, et al. Otolaryngol Clin North Am 2015
- Management of pediatric orbital cellulitis: A systematic review. Wong SJ and Levi J. Int J Pediatr Otorhinolaryngol 2018



203179

## Radiofrequency ablation of inferior turbinate for nasal obstruction: subgroup analysis

**Narin N. Carmel-Neiderman** , Inbar Caspi , Netanela Eisenberg , Barak Ringel , Avraham Abergel .

*Department of Otolaryngology Head and Neck Surgery and Maxillofacial Surgery, Tel-Aviv Sourasky Medical Center, affiliated to the Sackler Faculty of Medicine, Tel Aviv University, Tel Aviv, Israel*

*Septal and turbinate surgery, Building M2 CR3, Sept 28, 14.45*

**Introduction:** Radiofrequency ablation of the Inferior turbinate is an in-office procedure to alleviate nasal obstruction. It is considered relatively safe, well tolerated and can be done under local anesthetics.

**Objective:** To present the outcomes and disease specific quality of life among patients underwent inferior turbinate radiofrequency ablation. We emphasized two main sub populations: patients suffering from rhinitis medicamentosa, and patients presenting with septal deviation in physical examination.

**Methods:** A prospective cohort study was performed in the rhinology clinic at Tel Aviv Sourasky medical center between December 2017 and November 2018. Demographic and clinical data, patient satisfaction or other subjective complaints were gathered. Nasal related quality of life was evaluated by the Sino-nasal outcome test (SNOT-22) questionnaire, pre-operatively and 60 days after the ablation.

**Results:** Our study included 67 patients. No complications were noted. QOL measured by SNOT Questionnaire improved significantly over all after radiofrequency ablation ( $38 \pm 18$  vrs  $25 \pm 21$ ,  $Pv=0.001$ ). Special benefit was found in the rhinitis medicamentosa subgroup ( $n=19$ ) when compared with rest of the cohort( $n=45$ ) ( $15.18 \pm 16.6$  vrs  $28.37$ ,  $Pv=0.01$ ). None of the patients with Rhinitis medicamentosa returned to use topical nasal anti-congestions spray. The septal deviation patient subgroup ( $n=48$ ) did not report worse QOL scores in comparison of the study population ( $n=20$ ) ( $23.4 \pm 20.9$  vrs  $26.55 \pm 20.4$ ,  $Pv=0.51$ .)

**Conclusions:** The study demonstrated that radiofrequency ablation is efficient and improves quality of life among patients with nasal obstruction and inferior turbinate hypertrophy. It is a highly effective method to treat patients with rhinitis medicamentosa both improving their QOL and stopping the anti- decongestion substance abuse. Patient with Septal deviation may benefit from this procedure as a sole treatment.

## New oral anticoagulant treatment is not associated with an increased risk for recurrent epistaxis or associated complications - a retrospective study

Daniel Runggaldier<sup>1,3</sup>, Yiwen Luo<sup>1,3</sup>, Valeria Schindler<sup>2,3</sup>, **Seraina Kunz<sup>1,3</sup>**, Michael B. Soyka<sup>1,3</sup>

<sup>1</sup>Department of Otorhinolaryngology, Head and Neck Surgery, University Hospital Zurich, Switzerland, <sup>2</sup>Department of Gastroenterology and Hepatology, University Hospital Zurich, Switzerland, <sup>3</sup>University of Zurich, Zurich, Switzerland

*Epistaxis and HHT, Building M1 Room Σ4, Sept 28, 11.45*

**Background:** Long-term treatment with classic anticoagulation drugs (COAC) and thrombocyte aggregation inhibitors (TAI) is widely spread in the population. These drugs are known to be major risk factors for epistaxis. New oral anticoagulants (NOAC), such as Rivaroxaban, are becoming more popular, while their effect on epistaxis and its complications is still poorly understood. The aim of this study was firstly to analyze the impact of NOAC treatment on the occurrence of epistaxis and its complications, and secondly to compare it to COAC and TAI with regard to the abovementioned adverse effects.

**Methodology:** Single-centre, retrospective cohort study.

**Results:** 507 patients with epistaxis were included, out of which 41.3% were taking TAI, 14.5% COAC, 10.4% NOAC and 43.4% no such medication. COAC treatment was associated with an increased risk for recurring epistaxis compared to all other groups. (OR: 3.1,  $p < 0.05$ ) The usage of TAI was also associated with an increased rate of nose packaging alone or in combination with other treatment methods (OR 2.4,  $p < 0.05$ ). None of the analyzed treatments, however, was associated with an increased risk of hospitalization.

**Conclusion:** NOAC treatment was not associated with an increased risk for recurring epistaxis or other epistaxis complications that were analyzed in this study.

**Key words:** Epistaxis, Nose diseases, Anticoagulants, Platelet aggregation inhibitors

### Literature

1. Buchberger AMS, Baumann A, Johnson F, Peters N, Piontek G, Storck K, et al. The role of oral anticoagulants in epistaxis. *European archives of oto-rhino-laryngology : official journal of the European Federation of Oto-Rhino-Laryngological Societies (EUFOS) : affiliated with the German Society for Oto-Rhino-Laryngology - Head and Neck Surgery*. 2018;275(8):2035-43.
2. Glikson E, Chavkin U, Madgar O, Sagiv D, Nakache G, Yakirevitch A, et al. Epistaxis in the setting of antithrombotic therapy: A comparison between factor Xa inhibitors, warfarin, and antiplatelet agents. *Laryngoscope*. 2019;129(1):119-23.

## Taste modification and they implication on quality of life during radiotherapy at patients with laryngeal tumour

**Adriana Neagos<sup>1</sup>**, Larisa Irimia<sup>2</sup>, Anda Stefan <sup>2</sup>, Neculcea Tiberiu <sup>2</sup> El Achi Zouhir <sup>2</sup> Cristian Neagos<sup>3</sup>

<sup>1</sup>Otorhinologic Department , University of Medicine , Pharmacy, Science and Technology, "George Emil Palade " Targu Mures, Mures, Romania, <sup>2</sup>Otorhinologic Department, Emergency County Hospital, Targu Mures, Mures, Romania, <sup>3</sup>University of Medicine and Pharmacy Carol Davila, Bucharest, Romania

*Smell and taste 1, "Building M2 CR3, Sept 28, 11.45*

**Background:** Over the Years , anticancer therapy has evolved,. A side effect of the treatment, rated as having a high negative impact on the quality of life of the patient is the taste disorder. This sense is quite frequently affected by radiotherapy followed by head and neck pathology including the laryngeal one.

**Methodology/Principal:** We have made a prospective observational study , which includes 52 patients treated in ENT Hospital Targu Mures, Romania, diagnosed with laryngeal carcinoma. The taste assessment was performed weekly before operation, and during radiotherapy. It was decide to evaluate how to decrease the taste sensitivity and how it is influence the quality of life. We have used EORTC QLQ-35,

**Results:** At the end of radiotherapy all patients had taste disorders and 71.15% of them lost their total taste. It has been shown through the weekly evaluation that taste quality is first affected being attributed this fact to the "salty" sensitivity, followed by bitter and sour

**Conclusions:** Patients develop taste disorders at the end of oncological treatment . The taste disorder is also highlighted by certain parameters that make up the quality of life questionnaires.EORTC QLQ 35 is a very good evaluator of the malignant pathology.

**Key words:** laryngeal cancer, radiotherapy, taste, quality of life, salty

### Literature

1. Ponticelli E, Clari M, Frigerio S et al- *Dysgeusia and health-related quality of life of cancer patients receiving chemotherapy: A cross-sectional study*, Eur J Cancer Care(Engl.), 2017, 26: 1-7
2. Baharvand M, ShoalehSaadi N, Barakian R et al- *Taste alteration and impact on quality of life after head and neck radiotherapy*, J Oral Pathol Med, 2012, 42: 106-112.
3. Kannan P, Mukherji A, Saravanan K et al- *Change in the quality of life in oropharyngeal, laryngeal and hypopharyngeal cancer patients treated with volumetric modulated arc-based concomitant boost radiotherapy*, Gulf J Oncolog, 2016, 1: 36-45.
4. Karlsen T, Sandvik L, Heimdal JH et al- *Health-related QOL as studied by EORTC QOL and voice handicap index among various patients with laryngeal disease*, J Voice, 2017, 31: 251.e17-251.

## OSATS-based assessment of basic ENT skills on a 3D printed sinus model: a pilot study

**M.Stavrakas**<sup>1</sup>, G. Menexes<sup>2</sup>, S. Triaridis<sup>1</sup>, P. Bamidis<sup>3</sup>, P.D. Karkos<sup>1</sup>

<sup>1</sup>ENT Department, AHEPA University Hospital, Thessaloniki, Greece, <sup>2</sup>Department of Field Crops and Ecology, School of Agriculture, Faculty of Agriculture, Forestry and Natural Environment, Aristotle University of Thessaloniki, <sup>3</sup>Aristotle University of Thessaloniki, School of Medicine, Lab of Medical Physics

*Rhinology – miscellaneous 1, Building M1 Room Σ2, Sept 28, 14.45*

**Background:** Teaching of technical skills has increasingly drifted towards the use of simulators and the perception of ‘see one, do one’ tends to be a historical quotation. Several bootcamp-type approaches have been reported in the literature, aiming to consolidate practical skills. The use of OSATS can depict more accurately the performance as it represents a standardised tool. This study aims to validate OSATS tools for three basic ENT skills, studied in a group of medical students.

**Methodology:** We used a 3D printed of nasal cavity and paranasal sinuses and asked 11 medical students to perform rigid nasendoscopy, anterior nasal packing and foreign body removal after a short tutorial and practical demonstration. We also asked them to score their confidence levels before and after the practical part. Their performance was recorded and analysed by two external assessors.

**Results:** Statistical analysis demonstrated significant inter-rater reliability for the OSATS scores. Interestingly, on average, the participants reported an increase in their confidence levels at least by one unit in the confidence scale ranged from 1 to 5 (median score before 3 vs median score after 4.)

**Conclusions:** OSATS in basic ENT skills are valid tools which can be incorporated in the undergraduate teaching and student evaluation. Also, 3D printing is a rapidly evolving technology which allows simulation at low cost, offering anatomical accuracy and easy reproduction.

**Keywords:** OSATS; Rhinology; Simulation; Surgical Education

203195

A rare case report of meningitis secondary to ethmoidal osteoma and a literature review of other known intracranial complications.

Evans V<sup>1</sup>, Brahmabhatt P<sup>1</sup>, Farmer SE<sup>1</sup>

<sup>1</sup>*Department of Otolaryngology, Royal Gwent Hospital, Newport, United Kingdom*

*Benign nasal tumours 2, Building M1 Room Σ4, Sept 28, 10.15*

**Background:** Osteomas are benign tumours of bone, typically developing on the surfaces of the craniofacial skeleton, with a predilection for frontal and ethmoidal sinuses. The overwhelming majority are asymptomatic and discovered as incidental radiographic findings.

**Case Description:** We report a rare case of a 38 year old gentleman presenting with pneumococcal meningitis secondary to sinusitis. The presence of an left ethmoidal osteoma extending into the ipsilateral frontal sinus was deemed responsible for obstruction and accumulation of fluid. This patient recovered fully with intravenous antibiotics and intranasal steroids, and remained asymptomatic with no significant lesion progression after 2 years of observation with interval CT sinuses.

**Literature Review:** A thorough literature review of the PubMed database was undertaken, with the focus restricted to frontal or ethmoidal sinus osteomas presenting with intracranial complications. We found only 6 other reported cases of meningitis associated with osteoma, typically in conjunction with intracranial extension, e.g. fistula. Other reported complications of paranasal osteomas presenting with neurological sequelae included mucocele, pneumatocele and intracranial abscess. Surgical and conservative management approaches were reviewed and outcomes considered.

**Conclusions:** Although the vast majority of osteomas are incidentally discovered, symptomatic paranasal osteomas require careful management, with robust MDT assessment on a case-by-case basis.

**Key words:** osteoma, paranasal sinus, meningitis, complications

203201

Combined approach: middle and inferior antrostomy for a tooth root in the maxillary sinus : clinical case

**Alexandra Gheorghe<sup>1</sup>**, Silviu Crăc<sup>1</sup>, Vlad Budu<sup>1,2</sup>

<sup>1</sup>IFACF ORL "Prof. Dr. Dorin Hociotă", București, România, <sup>2</sup>UMF Carol Davila, București

*CRS - diagnosis and investigations, Building M1 Room Σ3, Sept 27, 10.15*

The development of stomatology in recent years, with emphasis on dental implants procedures has led to an increase in the number of sinonasal complications. Sinonasal complications of dental disease and treatment are an important cause of sinus pathology, being responsible for 10-12% of all causes of chronic maxillary rhinosinusitis.

The main etiological factors involved in odontogenic rhinosinusitis are represented by dental filings, tooth roots in traumatic extraction, dental implants displacement and parts of broken instruments. The diagnostic work-up includes evaluation of symptoms, history of dental treatment, dental examination, CT scan and nasal endoscopy.

The treatment is surgical and can be a transnasal endoscopic technique performed by the otorhinolaryngologist or a transoral technique performed by the maxillofacial surgeon. The endoscopic approach is preferable, but has limits when the tooth root is placed in the alveolar recess, the anterior, medial and lateral wall of the maxillary sinus. Concurrent middle and inferior antrostomy provides a better outlook of the sinus and increases effectiveness of the surgical treatment with minimal physiological damage.

**Key words:** FESS, tooth root, antrostomy

## The correlation of systemic corticosteroids with bone mineral density in patients with Chronic Rhinosinusitis with Nasal Polyps

**E.S. Lourijsen<sup>1</sup>**, S. Reitsma<sup>1</sup>, W.J. Fokkens<sup>1</sup>

<sup>1</sup>*Department of otorhinolaryngology, Amsterdam UMC, location AMC, the Netherlands*

*CRS - medical management 2, Building M2 CR2, Sept 28, 10.15*

**Background:** The risk of developing osteoporosis from bursts of corticosteroids is unclear. In this study the influence of systemic corticosteroids (SCS) on bone mineral density (BMD) in patients with CRSwNP was evaluated.

**Methods:** A retrospective study was conducted in patients  $\geq 40$  years of age with CRSwNP, which used at least one short course of SCS any time in the past 5 years. A Dual-Energy X-Ray absorptiometry (DXA scan) was reviewed for T-score and Z-score of femoral neck and lumbar spine. Primary outcome was the prevalence of low BMD of the left femoral neck and the correlation of the cumulative dose of SCS with BMD.

**Results:** A total of 103 patients were included. Z-scores were normal in all patients (mean score 0.24). There were no patients with osteoporosis at the femoral neck. Patients used a median 1730 mg (IQR 930.0-3660.0) of prednisolone equivalent without a significant dose-response relationship between the cumulative dose and BMD. Only BMI was significantly associated with BMD.

**Conclusion:** BMD results were within the expected range. There was no linear correlation between cumulative dose of SCS and Z-score of the femoral neck. Lower ( $\leq 3000$  mg) or higher ( $> 3000$  mg) cumulative doses of SCS did not influence BMD significantly.

**Key words:** Chronic Rhinosinusitis with nasal polyps, Systemic corticosteroids, Osteoporosis, Bone Mineral Density, Adverse effects

**Sean Fang<sup>1</sup>**, Humera Babar-Craig<sup>1</sup>, Natasha Choudhury<sup>1</sup>

<sup>1</sup>Department of Otolaryngology, Surrey and Sussex Healthcare Trust, United Kingdom.

*CRS - surgical management 1, Building M2 CR3, Sept 29, 10.15*

**Background:** Functional endoscopic sinus surgery (FESS) typically encompasses numerous component procedures. Our Hospital Trust is remunerated for each operation based on the complexity of procedures performed. Misinterpretation by clinical coders of the surgeons' notes can result in under-payment. Our novel documentation tool aims to improve the accuracy of coding each procedure.

**Methodology/Principal:** include here the techniques used without going into methodological detail.

The FESS documentation tool was implemented in our hospital from April 2019 and remains in use. The codes and costs applied to each patient undergoing FESS for a 6-month period between April to October 2019 was compared with the same period in 2018. T-test analysis was used to calculate statistical significance.

**Results:** give a summary of the most important findings with key numerical results given, with measures of error and not just p values.

66 patients underwent FESS in 2018 compared to 70 in 2019. The average cost applied to each FESS case in 2018 was £1,676, compared to £1,953 in the 2019 group, representing an average increase of £277 in revenue per patient ( $p=0.003$ ). Approximately 140 patients undergo FESS per year in our Trust, resulting in a potential increase in revenue of £38,780 per year.

**Conclusions:** concisely summarise the study's implications.

Please do not include any citations in the abstract. Avoid specialist abbreviations if possible. Our documentation tool improves accuracy of clinical coding for each procedure to ensure hospital Trusts are correctly remunerated. It also aids in understanding the extent of surgical dissection performed during future review and planning for revision surgery.

**Key words:** Provide up to 5 key words using Mesh terms for indexing purposes

Paranasal sinus diseases

Nasal obstruction

Clinical coding

Documentation

Otolaryngology

Literature



**Background:** Complications of rhinosinusitis can cause severe morbidity and mortality in some cases. Prompt recognition and management are essential to avoid potentially devastating outcomes. This study aims to represent our experience regarding complications of rhinosinusitis and associated clinical factors.

**Methodology/Principal:** A retrospective chart review was performed on patients who admitted to our hospital with complications of rhinosinusitis between 2013 and 2019. Characteristic features and age distribution of complications were defined.

**Results:** Fifty patients were treated for complications of rhinosinusitis. This cohort included 22 (44%) children (<18 age) and 28 (56%) adults. Twenty (40%) patients (9 children) diagnosed with preseptal cellulitis. 16 (32%) patients (4 children) underwent surgery for the diagnosis of orbital cellulitis/subperiosteal abscess. Subdural empyema and cerebral abscess like intracranial complications were seen in 6 children (27%) whereas only 2 (7%) intracranial complications were encountered in adults. 8 patients (4 (18%) children) having Pott's Puffy tumor-like osseous complications were treated with surgery.

**Conclusions:** We observed an increase in the annual incidence of complications of rhinosinusitis within the last few years. Also, the distribution of complications differed between children and adults in accordance with the literature.

**Keywords:** Rhinosinusitis, complication, intracranial, orbital

**I.Dobele<sup>1</sup>**, D.Raumane<sup>1</sup>

<sup>1</sup>Department of Otorhinolaryngology, Rīga Stradiņš University, Rīga, Latvia

*Smell and taste 2, Building M2 CR2, Sept 27, 14.45*

**Background:** Taste and smell disorders affect the quality of life and have a heterogeneous etiology. Impact of quality of life and socioemotional rehabilitation strategies for olfactory dysfunction is evaluated.

**Methodology/Principal:** Clinical signs of two unusual cases- idiopathic paraosmia and parageusia, and late manifestation of traumatic brain injury are reported. A forty-five-year-old female suddenly realized an unpleasant odour perception and therefore an altered taste for many flavours. Certain substances are perceived with foul smelling odour which cannot create any association with others. A forty-four -year old woman whose olfactory changes manifested until several months after the head injury. A sense of loss of olfactory appearance coincided with episodic CSF rhinorrhea.

**Results:** Results of radiological, physical examination and patient reported taste and smell perception in table are presented. Psychophysical testing allowed to demonstrate the functional nature in olfactory loss, while the MRI identified the post-traumatic injury of the frontal lobes and olfactory bulbs.

**Conclusions:** Smell and taste disturbances disrupt the quality of life. Rehabilitation include focus on adequate nutrition, social functioning and mental wellbeing.

**Key words:** Olfactory dysfunction, CSF leak, quality of life

## External approaches to frontal sinus with obliteration – are they still indicated? – a case series

**Jorge Canha Dentinho<sup>1</sup>**, Filipa Ferreira<sup>1</sup>, Lília Ferraria<sup>1</sup>, Sílvia Fidalgo Alves<sup>1</sup>, Luís Antunes<sup>1</sup>

<sup>1</sup>Otorrhinolaryngology Department, Hospital Garcia de Orta, Almada, Portugal.

*Miscellaneous 2, Building M1 Room 22, Sept 29, 11.45*

**Background:** The frontal sinus (FS) presents a surgical challenge. Not all cases respond to the endoscopic approach.

**Methodology:** Clinical cases of patients indicated for frontal sinus obliteration by external approach in the last 5 years in our institution are presented.

**Results:** Case 1: A girl presented two pneumococcal meningitis in one year. The defect in right FS was visualized with extracranial approach and, after being repaired, the sinus was obliterated, without recurrence after 22 months.

Case 2: A man with chronic rhinosinusitis with polyposis presented diplopia due to erosion of superior wall of left orbit. After the medical and endoscopic treatments failed, FS obliteration was performed, without recurrence after 6 months.

Cases 3 and 4: Two men had frontoethmoidal mucoceles with erosion of the orbit and diplopia. Sinus obliteration was performed after excision of mucocoele and reconstruction of orbit with titanium plate, without recurrence after 24 and 22 months, respectively.

**Conclusions:** FS obliteration is an option to be accounted in selected cases. It is mandatory to remove all the mucosa previously in order to prevent mucocoele formation.

**Key words:** frontal sinus obliteration

### Literature

Ravindra VM, Neil JA, Shah LM, Schmidt RH, Bisson EF. Surgical management of traumatic frontal sinus fractures:

Case series from a single institution and literature review. *Surg Neurol Int.* 2015 Aug 24;6:141  
Das PT, Balasubramanian D. External frontal sinusotomy and endoscopic repair of cerebrospinal fluid fistula in the posterior wall: preliminary report of a new technique. *J Laryngol Otol.* 2011;125:802-6

Petruzzelli GJ, Stankiewicz JA. Frontal sinus obliteration with hydroxyapatite cement. *Laryngoscope.* 2002; 112:32-6

Bernal-Sprekelsen M, Bleda-Vazquez C, Carrau RL. Ascending meningitis secondary to traumatic cerebrospinal fluid leaks. *Am J Rhinol* 2000;14: 257–59

Bernal-Sprekelsen M, Bleda-Vazquez C, Carrau RL. Ascending meningitis secondary to traumatic cerebrospinal fluid leaks. *Am J Rhinol* 2000;14: 257–59

Aggarwal SK, Bhavana K, Keshri A, Kumar R, Srivastava A. Frontal sinus mucocoele with orbital complications: Management by varied surgical approaches. *Asian J Neurosurg.* 2012; 7:135-40

James S, Dutta Wg, Swami Sqn, Ramakrishnan R. Frontal Mucocoele causing Unilateral Proptosis. *MJAFI* 2009;65:73-74;

Vicente A, Chaves A, Takahashi E, Akaki F, Sampaio A, Matsuyama C. Frontoethmoidal mucocoele: a case report and literature review. *Rev Bras Otorrinolaringol* 2004;70:850-4; 5-  
Peixoto C, Andrade S, Simões M, Bastos J, Ribeiro C. Frontal mucocoele: Surgical approach? Two cases report. *Rev Port Otorrinolaringol* 2013;51:127-32

203227

Is skin prick testing important in patients' compliance with treatment?

**Alistair Chambers**<sup>1</sup>, Jane Ndomahina<sup>1</sup>, Abigail Walker<sup>1</sup>, Irfan Syed<sup>1</sup>, Anastasia Rachmanidou<sup>1</sup>

<sup>1</sup>ENT Department, Lewisham & Greenwich NHS Trust, London, UK

*Allergic Rhinitis 1, Building M1 Room Σ3, Sept 28, 10.15*

**Background:** The study is trying to establish if the availability of skin prick testing, in an one-stop rhinitis clinic has an impact in the patients' compliance with medical treatment for their allergic disease.

**Methodology/Principal:** We followed 50 patients that were seen in our Rhinology clinics, using a symptom assessment questionnaire. All patients had positive skin prick tests for common inhalant allergens and were given advice on allergen avoidance by the nurse performing the tests as well as medical treatment by the examining doctor. All patients were then followed up

4-6 weeks later and their symptoms as well as their compliance with treatment was monitored.

We also recorded the size of the wheal (s) and tried to correlate this with symptom improvement post treatment.

**Results:** It is evident that the availability of skin prick testing improves the patients' understanding of their condition as well as their compliance with treatment.

**Conclusions:** Skin prick testing is a very important and affordable investigation, that should be available in every one stop rhinitis clinic as it is not only facilitating the diagnosis but improves the patients' compliance with treatment.

**Key words:** Skin prick testing, treatment compliance, allergic rhinitis

Literature

**Susana Amaral Pereira<sup>1</sup>**, José Pinto Sousa<sup>1</sup>, João Cabral Pimentel<sup>2</sup>, Ezequiel Barros<sup>1</sup>

<sup>1</sup>*Serviço de Otorrinolaringologia e Cirurgia da Cabeça e Pescoço, Centro Hospitalar e Universitário de Lisboa Central, Lisboa, Portugal*, <sup>2</sup>*Serviço de Anatomia Patológica, Centro Hospitalar e Universitário de Lisboa Central, Lisboa, Portugal*

*Sinonasal malignancy 2, Building M1 Room Σ3, Sept 28, 14.45*

**Background:** Solitary fibrous tumours (SFTs) are extremely rare, accounting for < 0.1% of all sinonasal neoplasms. These were originally described as neoplasms of the pleura.

**Methodology:** This study presents two cases of SFTs operated in *Centro Hospitalar Universitário de Lisboa Central*. A review of the literature was made.

**Results:** Two females, mean age 70, one presenting a reddish mass completely obliterating the nasal cavity with external extension through the nasal vestibule and the other with a tumour involving the sphenoid sinus, rhinopharynx and both nasal cavities. The lesions were treated via an endonasal approach using endoscopic piecemeal resection. Histologically, tumours were composed of spindle cells, the mitotic activity being low (2/10 high power fields (HPF)) in one patient and high in the other (8/10 HPF). The lesional cells were positive for STAT6. Endoscopic and imaging follow-up demonstrated absence of recurrence after 11 months.

**Conclusions:** Although patients had factors that suggested more aggressive behaviour (age >55 years, >4 mitoses per 10 HPF), the tumours were successfully removed through endonasal endoscopic surgery without evidence of disease at 11 months of follow-up. In accordance to the 72 cases reported in the literature there were no instances of metastasis or death due to disease.

**Key words:** Solitary fibrous tumour, Nasal cavity, Paranasal sinuses, Endoscopic endonasal surgery, Immunohistochemistry

**Literature:** El-Naggar AK, Chan JKC, Grandis JR, Takata T, Slootweg PJ, WHO Classification of Head and Neck Tumours. Lyon: International Agency for Research on Cancer. 2017. pp 45  
Thompson LD et al, Sinonasal Tract Solitary Fibrous Tumor: A Clinicopathologic Study of Six Cases with a Comprehensive Review of the Literature. *Head and Neck Pathology*. 2018; 12:471–480

Mathew GA et al, Solitary Fibrous Tumor of Nasal Cavity: A Case Report. *Iranian Journal of Otorhinolaryngology*. 2015; 27(4): 307-312

Rizzo S et al, Sinonasal and rhinopharyngeal solitary fibrous tumour: a case report and review of the literature. *Acta Otorhinolaryngologica Italica*. 2015; 3

203236

## Anterior Skull Base Surgery: A retrospective study of multidisciplinary approach with Otolaryngologists and neurosurgeons during last 3 years

**Silva, C.**<sup>1</sup>, Oliveira V.<sup>1</sup>, Nurdin A.<sup>1</sup>, Lança B.<sup>1</sup>, Carvalho T.<sup>1</sup>, Luís L.<sup>1</sup>

<sup>1</sup>Otorhinolaryngology Department Hospital de Santa Maria, Lisbon, Portugal

*Skull base surgery 2, Building M2 CR3, Sept 29, 14.45*

**Background:** The skull base is an anatomically complex area with noble vasculonervous structures. The skull base surgery is challenging and requires multidisciplinary teams and several surgical approaches, in which Otolaryngologists and Neurosurgeons collaborate. This area is difficult to access and view directly and can be instrumented by endoscopy, namely endonasal, allowing better surgical visualization with less invasive approaches.

**Methodology:** Retrospective observational study of patients undergoing multidisciplinary skull base surgery, involving the specialties of Neurosurgery and Otorhinolaryngology, between 2017 and 2019. (After consulting clinical processes, demographic data, diagnosis, comorbidities, surgical approach and associated complications were collected.) We demonstrate several surgical approaches performed using videos and photos from different surgeries and follow-up evaluations.

**Results:** A total of 46 patients were included in this study (33 men and 12 women ranging, in age, from 1-82 years). Comprising 36 pituitary adenomas, 1 pituitary apoplexy, 3 craniopharyngiomas, 1 Rathke cleft cyst, 1 congenital nasal dermoid cyst, 3 clivus chordomas and 1 Tuberculum sellae meningioma. A transphenoidal approach was performed in 42 patients, a transclival approach in 3 patients and a bicoronal approach in 1 patient. Only one revision surgery was required, a CSF leak repair after the excision of a pituitary adenoma.

**Conclusions:** A multidisciplinary surgical approach allows a combination of surgical techniques and knowledge, with a consequent increase in safety and effectiveness, as well as lower rates of complications and morbimortality. This cooperation allowed the surgical resolution of many different pathologies in our hospital, with almost no complications associated.

**Key words:** Skull Base Surgery; Otorhinolaryngology; Neurosurgery; Endonasal endoscopic surgery

**Susana Amaral Pereira<sup>1</sup>**, Joana Nascimento<sup>1</sup>, Carla Moreira<sup>1</sup>, José Pinto Sousa<sup>1</sup>, Patrícia Melo<sup>1</sup>, João Cabral Pimentel<sup>2</sup>, Ezequiel Barros<sup>1</sup>

<sup>1</sup>*Serviço de Otorrinolaringologia e Cirurgia da Cabeça e Pescoço, Centro Hospitalar e Universitário de Lisboa Central, Lisboa, Portugal*, <sup>2</sup>*Serviço de Anatomia Patológica, Centro Hospitalar e Universitário de Lisboa Central, Lisboa, Portugal*

*Sinonasal malignancy 2, Building M1 Room Σ3, Sept 28, 14.45*

**Background:** Glomangiopericytoma is a rare sinonasal tumour with a perivascular myoid differentiation. It accounts for less than 0.5% of all sinonasal tumours and is classified as a borderline/low-grade malignant soft tissue tumour.

**Methodology:** We report two cases of glomangiopericytoma operated in Centro Hospitalar Universitário de Lisboa Central discussing characteristics and management of this rare tumour. A review of the literature was made.

**Results:** Two patients, mean age 59, presented with persistent unilateral nasal obstruction. Endoscopic evaluation showed a friable mass with 5 cm occupying the posterior part of the left nasal cavity. The tumours were removed successfully by endoscopic endonasal surgery. Histological examination showed tumoral proliferation of spindle-shaped cells with a perivascular hyalinization, without necrosis or increased mitoses. The lesional cells were positive to smooth muscle-actin in one patient and negative to CD34 in both. No evidence of recurrence was noted.

**Conclusions:** According to the literature patients with glomangiopericytoma had a tendency toward longer overall survival when they showed actin immunopositive and CD34 immunonegative. The gold standard for treatment is resection with tumor-free margins and endoscopic surgery now enables resection with less morbidity and complications. To improve our understanding of this diagnostic entity, more cases need to be reported.

**Key words:** Glomangiopericytoma, Nasal cavity, Endoscopic endonasal surgery, Immunohistochemistry

**Literature:** El-Naggar AK, Chan JKC, Grandis JR, Takata T, Slootweg PJ, WHO Classification of Head and Neck Tumours. Lyon: International Agency for Research on Cancer. 2017. pp 45  
Park ES et al, Characteristics and prognosis of glomangiopericytomas: A systematic review. Head & Neck. 2017;1–13

Asimakopoulou P et al, Sinonasal glomangiopericytoma: Is anything new?. Entjournal.com. 2016. Volume 95, Number 2

**Hrvoje Mihalj**<sup>1,2</sup>, Željko Zubčić<sup>1,2</sup>, Josip Maleš<sup>1,2</sup>, Andrijana Včeva<sup>1,2</sup>, Tihana Mendeš<sup>1,2</sup>, Vjeran Bogović<sup>1</sup>, Stjepan Grga Milanković<sup>1</sup>, Anamarija Šestak<sup>3</sup>, Ivan Abičić<sup>1</sup>, Tin Prpić<sup>1</sup>, Matej Rezo<sup>1</sup>

<sup>1</sup>Department of Otorhinolaryngology and Head and Neck Surgery, Clinical Hospital Centre Osijek, J. Hottlera 4, 31000 Osijek, Croatia, <sup>2</sup>Department of Otorhinolaryngology and Maxillofacial Surgery, Medical Faculty Osijek, University J.J. Strossmayer Osijek, J. Hottlera 4, 31000 Osijek, Croatia, <sup>3</sup>Department of Otolaryngology, County General and Veterans Hospital Vukovar, Zupanijska 35, 32000 Vukovar, Croatia

*Rhinoplasty 2, Building M2 CR2, Sept 27, 11.45*

**Background:** The aim of this study was to present advantages and disadvantages of an open approach rhinoplasty. Here we also demonstrate development of this technique in Croatia and investigate its application in the last 3 years at the Department of Otorhinolaryngology and Head and Neck Surgery University Hospital Center Osijek.

**Methodology/Principal:** In a retrospective study, from 2017 till January 2020, we have identified 75 patients with septal deviation and/or pyramidal deformities that underwent rhinoplasty. The patients were photographed in 6 projections before and after the operation, and followed up.

**Results:** Of the 75 included patients, 42 were women, and the mean age was 30.6 years. There were 68 patients that underwent closed approach, and 7 underwent open approach rhinoplasty. No significant difference was observed clinically in postoperative complications between open and closed approach rhinoplasty.

**Conclusions:** The authors observed no clinically difference in comparing open and closed approach rhinoplasty.

**Key words:** rhinoplasty; diagnosis; follow up

#### Literature:

1. Bogović V, Milanković SG, Zubčić Ž, Včeva A, Mihalj M, Maleš J, Kotromanović Ž, Grebenar M, Mendeš T, Mihalj H. Open Approach in Rhinoplasty. *SEEMEDJ* 2019; 3(2):56-63.
2. Rohrich R, Ahmad J. Rhinoplasty. *Plast Reconstr Surg* 2011;128(2):49-73.
3. Vilar-Sancho B. Rhinoseptoplasty. *Aesthetic Plast Surg* 1984;8(2):61-65.
4. Greco M, Ciriaco AG, Vonella M, Vitagliano T. The primacy of the Vianeo family i the invention of nasal reconstruction technique. *Ann Plast Surg* 2010;64:702-5.
5. Bhattacharya S. Jacques Joseph: Father of modern aesthetic surgery. *Indian J Plast Surg*. 2008;41(suppl): S3-S8.
6. Šercer A. Otorinolaringologija 2, Klinika. Zagreb: JLZ, 1965, 356-357.
7. Gunter JP, Rohrich RJ, Adams, WP (Eds.). *Dallas Rhinoplasty Nasal Surgery by the Masters*, 2nd edn., St.Louis: Quality Medical Publishing Inc; 2007.
8. Sercer A, Mundich K. *Plastische Operationen an der nase und an der Ohrmuschel*, Stuttgart: Georg thieme verlag, 1962.
9. Leong S, Eccles. A systematic review of the nasal index and the significance of the shape and size of the nose in rhinology. *Clin Otolaryngol* 2009; 34(3):191- 8. doi: 10.1111/j.1749-4486.2009.01905.x.
10. Naraghi M, Atari M. Development and Validation of the Expectationsof Aesthetic Rhinoplasty Scale. *Arch Plastic Surgery* 2016; 43(4):365-370.
11. Cochran CS, Landecker A. Prevention and management of rhinoplasty complications. *Plast Reconstr Surg* 2008; 122:60 -67.



12. Rettinger G. *Risks and complications in rhinoplasty.* *GMS Curr Top Otorhinolaryngol Head Neck Surg.* 2007;6:Doc08.
13. Gruber RP, Noland S, Belek KA. *Discussion: what motivates secondary rhinoplasty? A study of 150 consecutive patients.* *Plast Reconstr Surg* 2012; 130:679-80.
14. Philpott CM, Clark A, McKiernan DC. *Function or cosmesis what is the predominant concern in patients with nasal trauma presenting for rhinoplasty?* *Eplasty* 2009;9:e11. Daniel R. *Secondary Rhinoplasty Following Open Rhinoplasty.* *Plast Reconstr Surg* 1995;96(7):1539-1546.

203281

Respiratory epithelial adenomatoid hamartoma is frequent in olfactory cleft after nasalization

**Duc Trung NGUYEN**<sup>1</sup>, MD, PhD, MPH, Roger JANKOWSKI<sup>1,2</sup>, MD, PhD, Ayoub BEY<sup>1</sup>, MD, Guillaume GAUCHOTTE, M.D, Ph.D<sup>3</sup>, Jean Matthieu CASSE<sup>3</sup>, MD, Pedro Augusto GONDIM TEIXEIRA<sup>4</sup>, MD, Patrice GALLET<sup>1,2</sup>, MD, Cécile RUMEAU<sup>1,2,5</sup>, MD, PhD

<sup>1</sup> University Hospital of Nancy, Department of Otorhinolaryngology – Head and Neck Surgery, Nancy, France, <sup>2</sup> Faculty of Medicine, University of Lorraine, France, <sup>3</sup> University Hospital of Nancy, Department of Pathology, Nancy, France., <sup>4</sup>University Hospital of Nancy, Guilloz Imaging department, Nancy, France, <sup>5</sup> EA 3450 DevAH (Développement, Adaptation et Handicap), University of Lorraine, France

*CRS - outcome assessment 1, Building M1 Room Σ4, Sept 27, 10.15*

**Objectives:** To assess the site and histopathology of polyps at the first revision surgery for recurrent nasal polyposis (NP) after radical ethmoidectomy (nasalization).

**Study Design:** Retrospective study

**Methods:** Between January 2008 and December 2015, a total of 62 patients having undergone revision surgery for recurrent NP after nasalization were included. The site and histology of the recurrence of polyps were analyzed according to operative and pathological reports.

**Results:** Histology showed classical inflammatory nasal polyps (CINP) in 91% of nasal cavities at primary surgery *versus* respiratory epithelial adenomatoid hamartoma (REAH) or REAH associated to CINP in 54.8% at revision surgery ( $p<0.0001$ ). Polyps were principally observed in the ethmoidal complex in 70% of nasal cavities during primary surgery and in the olfactory clefts in 88.7% during revision surgery ( $p<0.0001$ ). The mean interval between nasalization and first revision surgery was  $8.8\pm4.4$  years (0.4-21.7 years). This interval was significantly shorter for grade 3 polyps, polyps removed from both ethmoidal complex and olfactory cleft at primary surgery, association of CINP and REAH at primary surgery, and when primary surgery had preserved the middle turbinates.

**Conclusion:** Polyp recurrences after nasalization were mainly observed in the olfactory clefts and can be different histological features: inflammatory polyps, respiratory epithelial adenomatoid hamartoma, or a combination of both.

203285

## Retrospective analysis of Revision Endoscopic Dacryocystorhinostomy results and findings of primary surgery failure

**Marta Melo<sup>1</sup>**, Diogo Raposo<sup>1</sup>, João Órfão<sup>1</sup>, Marta Cardoso<sup>1</sup>, Filipe Freire<sup>1</sup>

<sup>1</sup>Hospital Professor Doutor Fernando Fonseca, Lisbon, Portugal

*Lacrimal Surgery1, Building M1 Room Σ4, Sept 27, 11.45*

**Background:** Revision endoscopic dacryocystorhinostomy (DCR) has lower success rate than primary DCR. Findings as lacrimal sac fibrosis or synechia may be reasons of primary surgery failure. The aim of our study is to access the results of revision DCR and causes of primary surgery failure.

**Methodology/Principal:** Retrospective analysis of patients submitted to revision endoscopic DCR between 2012 and 2018. Evaluation of epidemiological data, surgical findings, technique and success rate.

**Results:** 34 patients underwent revision DCR, with a mean age of  $63,4 \pm 13,6$  years. The success rate was 70,6%. Surgical finding were lacrimal sac fibrosis 29,4%, inadequate bone window 23,5%, synechia 17,6%, septal deviation 11,8% and polyposis 5,9%. Topical mitomycin-c was applied in 29,4% and corticosteroids in 17,6%.

**Conclusions:** Assessment of surgical findings in revision DCR, that may contribute to primary surgery failure, help to achieve more success and optimize the surgical technique.

**Key words:** Dacryocystorhinostomy, Lacrimal Apparatus Diseases, Endoscopy

### Literature

- 1- Cohen, O., Amos, I., Halperin, D., Bavnik, Y. et al, Five- and 10-Year Outcomes for Primary Endoscopic Dacryocystorhinostomy: Failure Rate and Risk Factors. The Laryngoscope. Laryngoscope, 00:1–7, 2020
- 2- Lehmann AE, Scangas GA, Jafari A, Banks CG, Fullerton ZH, Metson R. Predictors of long-term success and failure in primary and revision endoscopic dacryocystorhinostomy. Int Forum Allergy Rhinol. 2019;00:1-7
- 3- Dalgic A, Ceylan ME, Çelik Ç, Aliyeva A et al, Outcomes of Endoscopic Powered Revision Dacryocystorhinostomy, J Craniofac Surg. 2018 Oct;29(7):1960-1962
- 4- Elina Penttilä, Grigori Smirnov et al, Mitomycin C in revision endoscopic dacryocystorhinostomy: A prospective randomized study. Am J Rhinol Allergy 25, 425–428, 2011

203288

## Outcomes in non-melanoma skin cancer

Han Y. Sook<sup>1</sup>, Ishtiak Mahamud<sup>1</sup>, Nadia Ashraf<sup>1</sup>

<sup>1</sup>Department of ENT-Head & Neck Surgery, University Hospitals of Derby & Burton, UK

*Facial Plastic surgery beyond the nose 1, Building M1 Room Σ3, Sept 27, 11.45*

**Background/Aim:** To assess the clinical and patient-reported outcomes of non-melanoma skin cancer treated through a cross-specialty service

**Methodology:** A retrospective case note review and telephone questionnaire was conducted of 100 consecutive non-melanoma skin cancer cases undergoing excision and reconstruction by the senior author (NA) from January 2018 to January 2019. Data was collected on: 1) histology, including radial and deep margins 2) lesion location and reconstruction 3) patient satisfaction with the streamlined service; dermatological diagnosis and direct listing onto an ENT operating session.

**Results:** Histology confirmed 80% of lesions as basal cell carcinoma; 11% squamous cell carcinoma and 9% other skin lesions. 95% of cases had clear radial and deep margins at first excision. 70% had primary closure, 22% required local flap reconstruction and 7% full thickness skin graft. 94% of patients were satisfied with the scar; with 91% rating the scar as 4 or 5 out of 5 on a visual analogue scale. 100% were satisfied with the care provided and would recommend the streamlined cross-specialty service.

**Conclusion:** Excellent tumour clearance and patient-reported satisfaction can be achieved with a streamlined service provided in collaboration with Dermatology. A preoperative virtual ENT Clinic could further enhance the patient experience.

**Key words:**

Skin neoplasms

Patient-reported Outcome Measures

Dermatologic Surgical Procedures

**Predictors of patient satisfaction following septorhinoplasty: a prospective cohort study**Ishtiak Mahamud<sup>1</sup>, Anna Hong<sup>1</sup>, Nadia Ashraf<sup>1</sup><sup>1</sup>Department of ENT-Head & Neck Surgery, University Hospitals of Derby & Burton, UK*Rhinoplasty 1, Building M2 CR1, Sept 29, 14.45*

**Background:** Careful patient selection in septorhinoplasty is critical to good patient outcomes. Body Dysmorphic Disorder (BDD) is a known risk factor for poor postoperative satisfaction. Our aim was to refine factors influencing patient satisfaction following septorhinoplasty.

**Methodology:** A prospective cohort study was conducted, including 16 consecutive patients undergoing septorhinoplasty and 32 controls. All participants completed FACE-Q and BDDQ (Body Dysmorphic Disorder Questionnaire) pre- and post-operatively; both validated tools in septorhinoplasty assessment.

**Results:** Mean functional FACE-Q score improved from 3.8 to 1.7 following septorhinoplasty (1.0 in controls),  $p=0.00002$ , SD1.42 and mean aesthetic FACE-Q from 3.5 to 1.4 (0.2 in controls),  $p=0.00003$ , SD1.51. 38% (five female and one male) screened positively preoperatively on BDDQ and 31% (four male and one female) were borderline (0% in controls). Postoperatively 19% screened positively on BDDQ; one male identified preoperatively, and two males converting from borderline to BDD. All female patients positive on BDDQ preoperatively were non-BDD postoperatively.

**Conclusions:** BDDQ is a useful screening tool for patients who may be dissatisfied with septorhinoplasty outcome. Satisfaction is high in female patients overall, although they are more likely to screen positive for BDD preoperatively. Particular caution should be exercised in male patients scoring borderline or positive on BDDQ.

**Key words:**

Rhinoplasty

Patient-reported Outcome Measures

Body Dysmorphic Disorders

203294

## The effect of sphenoid pneumatization on vidian canal endoscopic landmarks: an anatomic relationship

**Jabarin B**, MD, MHA<sup>1</sup>, Liu A<sup>1</sup>, Thamboo A, MD, MHSc, FRCSC<sup>1</sup>

<sup>1</sup>*Division of Otolaryngology – Head and Neck Surgery, Department of Surgery, University of British Columbia, Vancouver, Canada*

*Miscellaneous 2, Building M1 Room Σ2, Sept 29, 11.45*

**Background:** Vidian canal (VC) serves as an important anatomic landmark in endonasal endoscopic approaches to lateral skull base pathologies. The goal of this study was to better define the relationship between the VC and other landmarks.

**Methods:** CT sinus of 80 patients were analyzed. Measurements were recorded of the VC to the sphenopalatine foramen (SPF), the palatovaginal canal (PVC), the maxillary nerve (V2) and the medial pterygoid plate. Onodi cells and the type of sphenoid pneumatization were logged. A two-tailed t-test and ANOVA were run to determine statistical significance.

**Results:** In 76.5% of cases, the VC was superior or at the same height as the SPF. In 55% of cases, the VC was medial to the SPF. VC was always lateral to the PVC and medial to V2. When Onodi cells were present (11.3% of cases), the VC was lower compared to the SPF ( $p < 0.011$ ). Type C sphenoid pneumatization was correlated to the VC being lateral to the SPF and Type D was correlated to the VC being medial to the SPF ( $p < 0.05$ ).

**Conclusions:** VC was superior or at the same height as the SPF and medial to the SPF. The type of sphenoid pneumatization affected the location of the VC.

203295

## Determination of the “Just Noticeable Difference” (JND) in sensing of obstruction related to cross sectional area and resistance parameters

**Patricia Neumaier**<sup>1</sup>, Klaus Vogt<sup>2</sup>, Eliza Poikane<sup>2</sup>, Klaus-Dieter Wernecke<sup>3</sup>

<sup>1</sup>ENT-Department, Paracelsus-University-Hospital, Salzburg/Austria, <sup>2</sup>University of Latvia, Faculty of Medicine, Center of Experimental Surgery, Riga, Latvia, <sup>3</sup>Sosatana GmbH, Berlin/Germany and Charité University Hospital Berlin/Germany

*Septal and turbinate surgery 2, Building M2 Study Hall, Sept 29, 14.45*

**Background:** It is unknown, which difference in width or resistance of the nasal airway determine the feeling of obstruction

**Methodology/Principal:** A special device was constructed and produced by 3D-printing consisting of a holder for 2 parallel stripes with holes in the range between 2mm and 8mm diameter. This can be attached to a normal breathing mask. The patient/subject is breathing subsequently through 2 holes and determines the just noticeable difference.

**Results:** Because of the actual pandemic crisis the study could not be completed yet, but the first results show clearly that differences in a range up to 4 mm<sup>2</sup> are much better to differentiate as higher diameters. The method will be demonstrated during the congress and exhibition.

**Conclusions:** The study confirms the introduction of logarithmic parameters into rhinomanometry as recommended and realized in 4PR and justifies the proposed classification of onstruction

**Key words:** Nasal obstruction, rhinomanometry, sensing of obstruction

203298

## Simulation of the nasal airflow with Computational Fluid Dynamics in Nasal Breathing Difficulties: RANS and LES approach

**L. Castellani**<sup>1</sup>, C. Pipolo<sup>1</sup>, A. Bulfamante<sup>1</sup>, A.M. Saibene<sup>1</sup>, M. Quadrio<sup>2</sup>, G. Felisati<sup>1</sup>

<sup>1</sup>Unit of Otorhinolaryngology, Department of Health Sciences, Università degli Studi di Milano, Milan, Italy,

<sup>2</sup>Department of Aerospace Science and Technologies, Politecnico di Milano, Milan, Italy

*Technological advances 3, Building M1 Room Σ1, Sept 28, 14.45*

**Background:** Nasal Breathing Difficulties (NBD) represent one of the most common medical conditions but its surgical treatment is still highly subjective to the surgeons' experience since, at the current state of the art, it is impossible to rationally assess the relevance of every single anatomic anomaly and its possible surgical modification on the overall nasal flow quality. With new investigation techniques based on Computational Fluid Dynamics (CFD) simulations it is possible to produce faithful models of the nasal air flow of the individual patient.

**Methodology/Principal** CT images were converted into an accurate tridimensional geometrical description of the boundary of the volume of interest used as an input for generating the computational mesh running into CFD software. The next step is the actual execution of the flow solver and its visualization of results with a dedicated software.

**Results:** We completed both RANS (Reynolds Averaged Navier-Stokes) and LES (Large Eddy Simulation) simulations in two conditions of inspiration and expiration comparing numerous results such as velocity, vorticity, wall shear stress and pressure field.

**Conclusions:** These results allow for an optimistic outlook towards the near creation of a reliable, stable and efficient tool for an objective pre-surgical assessment of the nasal airflow.

**Key words:** nasal breath difficulties, nasal airflow, CFD, LES

The use of a robotic arm in frontal skull base surgery

C. Hintschich<sup>1</sup>, K. H. Schebesch<sup>2</sup>, T. Kühnel<sup>1</sup>

1.Klinik und Poliklinik für Hals-Nasen-Ohren-Heilkunde, Universitätsklinikum Regensburg, Regensburg, Germany

2.Klinik und Poliklinik für Neurochirurgie, Universitätsklinikum Regensburg, Regensburg, Germany



**C. Hintschich**<sup>1</sup>, K. H. Schebesch<sup>2</sup>, T. Kühnel<sup>1</sup>

<sup>1</sup> Klinik und Poliklinik für Hals-Nasen-Ohren-Heilkunde, Universitätsklinikum Regensburg, Regensburg, Germany; <sup>2</sup> Klinik und Poliklinik für Neurochirurgie, Universitätsklinikum Regensburg, Regensburg, Germany

*Technological advances 3, Building M1 Room Σ1, Sept 28, 14.45*

**Background:** Extended endoscopic endonasal operations of the sinuses, the orbit and the frontal skull base require in many cases a bimanual action of the surgeon. Thus, typically a second surgeon guides the endoscope and canters the field of view. In this study we investigate in which cases a robotic arm can be used alternatively.

**Methodology:** The electromagnetic system produced by AKTORmed was used in different surgical interventions of the sinuses, the pituitary gland and tumours questioning ergometry and geometrical limitations. The realized degrees of freedom were documented, and a topography of possible applications compiled.

**Results:** The presented system is limited through the geometry of the anterior ethmoid and changing working conditions in the sagittal direction. Especially in extended interventions in the posterior ethmoid, in which parts of the nasal septum have been resected and a static position of the endoscope is desired the surgeon can greatly benefit from the robotic arm.

**Conclusions:** Under the impression of an urging staff shortage and due to the unlimited patience, a robotic arm seems promising. Hence, we see especially in the surgery of the pituitary gland and skull base tumours a favourable field of application.

**Key words:** Robotic surgical procedures, Endoscopy, Skull base, Endoscopy, Paranasal sinus disease, Pituitary gland

## Introduction of Superior Lateral Osteotomy as a valuable addition/modification to common Piezo osteotomies

George Mireas<sup>1,2</sup>, Georgia Katsouli<sup>1</sup>, Vasilios Mpakas<sup>2</sup>, Christos Katsantonis<sup>2</sup>, Antonios Gkotsis<sup>2</sup>, Athanasios Saratziotis<sup>3</sup>,

<sup>1</sup>Facial Plastic Surgery Dpt, Mediterraneo Hospital, Athens, Greece, <sup>2</sup>ENT Dpt, 251 Hellenic Airforce Hospital, Athens, Greece, <sup>3</sup>ENT Dpt, University Hospital, Larisa, Greece

*Rhinoplasty 2, Building M2 CR2, Sept 27, 11.45*

**Background:** Ultrasonic rhinosculpture, as well as U-Shape and V-Shape Osteotomies are utilized during a Piezo rhinoplasty to address bony vault deformities. Sometimes the results are not satisfactory, and more improvement is needed.

**Methodology/Principal:** The authors suggest the introduction of the Superior Lateral Osteotomy (SL-OT), a new osteotomy which creates a small bony portion at the upper part of the lateral bony wall. The SL-OT is either parallel to a low-to-low OT or to the dorsal aesthetic line, while the starting point and level of it depends on the final shape we want to achieve. Addition of medial/paramedial or transverse OT is often needed for better bone shaping.

**Results:** Superior lateral osteotomy was utilized in cases with extra thin nasal walls, specific local deformities as well as in noses with a very wide hump and verticalized nasal walls. The particular osteotomy was easily and quickly performed, and desired result was achieved totally avoiding extended elevation and lateral osteotomies. Furthermore, the SL-OT was performed always under direct vision and with great accuracy.

Fixation of the new structure at the desired angulation and position can be done with sutures (PDS or Nylon 5.0, 4.0) that pass through the bones, the upper later cartilages, or possibly created spreader grafts/flaps.

The osteotomy has shown impressive results especially in revision cases, while no complications were observed

**Conclusions:** Superior Lateral Osteotomy can be considered as a valuable alternative or addition to common Piezo osteotomies

**Key words:** Rhinoplasty, Osteotomy, Osteotomies, Piezo, Ultrasonic

A randomized controlled trial comparing a seawater-based osmotic nasal decongestant versus xylometazolin 0.1% in the relief of acute rhinitis symptoms

**Ludovic de Gabory**<sup>1</sup>, Jana Skoupa<sup>2</sup>

<sup>1</sup>ENT, Head and Neck Surgery Department, University Hospital of Bordeaux - Pellegrin hospital, France, <sup>2</sup>Czechta Institute, Praha, Czech Republic;

*CRS - medical management 3, Building M2 CR2, Sept 29, 10.15*

**Background:** A number of contraindications limits the use of local vasoconstrictors for the symptomatic treatment of common cold. This study aimed at comparing the efficacy of a seawater-based osmotic nasal decongestant (Rhinaction®) vs xylometazoline nasal spray in the relief of common cold.

**Methodology/Principal:** In this multicenter, randomized, parallel group study, 553 adults with common cold were treated either with Rhinaction® (hypertonic seawater with essential oils, 6times/day) or xylometazoline 0.1% (3times/day) over a maximum 8 days-period. Symptoms severity was monitored with the Wisconsin Upper Respiratory Symptom Survey (WURSS-21). Adverse events and tolerability (nasal burning, irritation, itching, bleeding, dryness) were also evaluated.

**Results:** No significant difference was found between the WURSS-21 AUC of Rhinaction® and xylometazoline (respectively: 120.76, IC<sub>95</sub>[108.99-133.79] and 106.34, IC<sub>95</sub>[95.95-117.85]; p=0.053). Nasal congestion was similarly reduced in both groups over the treatment period (Rhinaction®: from 4.71±0.1 to 1.26±0.07; xylometazoline: from 4.12±0.1 to 1.27±0.07, p=0.38). Few mild to moderate adverse events occurred in both groups (Rhinaction®: 7 unrelated AEs, xylometazoline: 11 AEs including 1 related AE). Both treatments were well tolerated.

**Conclusions:** This study shows the efficacy of a seawater-based osmotic nasal decongestant (Rhinaction®) vs xylometazoline in the relief of common cold. It can be considered as a natural and safe alternative to xylometazoline.

**Key words:** decongestant; seawater; osmotic; hypertonic; rhinitis.

## Prospective, randomized, controlled, open-label study to compare efficacy of a mineral-rich solution vs normal saline after complete ethmoidectomy

**Ludovic de Gabory**<sup>1</sup>, Virginie Escabasse<sup>2</sup>, Philippe Boudard<sup>3</sup>, Guillaume de Bonnecaze<sup>4</sup>, Cécile Rumeau<sup>5</sup>, Roger Jankowski<sup>5</sup>, Christian Debry<sup>7</sup>, Sylvain Morinière<sup>8</sup>, Geoffrey Mortuaire<sup>9</sup>, Olivier Malard<sup>10</sup>

<sup>1</sup>ENT Department, CHU Bordeaux, 33000 Bordeaux, France ; <sup>2</sup>ENT Department, Intercommunal Hospital of Créteil, Paris, France ; <sup>3</sup>ENT Department, Saint-Augustin Private Hospital, Bordeaux, France; <sup>4</sup>ENT Department, University Hospital of Toulouse, Toulouse, France; <sup>5</sup>ENT Department, University Hospital of Nancy, Nancy, France; <sup>6</sup>ENT Department, University Hospital of Strasbourg, Strasbourg, France; <sup>7</sup>ENT Department, University Hospital of Tours, Tours, France; <sup>8</sup>ENT Department, University Hospital of Lille, Lille, France; <sup>9</sup>ENT Department, University Hospital of Nantes, Nantes, France.

*CRS - surgical management 3, Building M2 CR3, Sept 28, 10.15*

**Background:** Our study aimed at comparing the efficacy of a mineral-rich solution vs normal saline (0.9% NaCl) following endoscopic complete bilateral ethmoidectomy.

**Methodology/Principal:** Prospective, multicenter, randomized, controlled trial: 189 patients performed post-operatively, 4-daily nasal washes with a squeezable device (Netiflow®) with a mineral-rich solution (Respimer® Netiflow®: R-group), or normal saline (NS-group) during 28 days. Mineral-rich solution composition: sodium chloride, potassium chloride, calcium chloride, magnesium chloride, and sodium bicarbonate. Symptoms were assessed with RhinoQoL and NOSE questionnaires and endoscopic features with the Lund-Kennedy Score.

**Results:** Clinically relevant improvements (> 20 points) in RhinoQOL and NOSE scores were measured in both groups without significant inter-group difference. Among subjects with impaired RhinoQOL at pre-inclusion, the change in Impact-RhinoQOL score was significantly superior in R-group vs NS-group at day 21 & 28 (p=0.028 and p=0.027). The Lund–Kennedy score continuously improved in both groups, earlier in R-group. Crusts were significantly fewer and less severe/obstructive in R-group vs NS-group at day 7 & 14 (p=0.026 and p=0.016). Secretions disappeared significantly quicker and were less thick/purulent in R-group at day 14 & 21 (p=0.002 and p=0.043). Less epistaxis was reported in R-group vs NS-group (p=0.008 at day 21).

**Conclusions:** Our results suggest a better efficacy on nasal mucosa healing of a mineral-rich solution for nasal irrigation in post-operative period.

**Key words:** Nasal irrigation, Chronic rhinosinusitis, Nasal polyposis, Lund–Kennedy endoscopic score

## Assessment of the quality and safety of ambulatory surgery in rhinology

**Ludovic de Gabory,MD,PhD,<sup>1,2</sup>** Mélodie Kérimian,MD,<sup>1</sup> Pauline Legrenzi,MD,<sup>1</sup> Ahmed Alharbi,MD,<sup>1</sup> Severin Belleudy,MD,<sup>1,2</sup>

<sup>1</sup>Departement of Otorhinolaryngology, University Hospital of Bordeaux, France., <sup>2</sup>Univ. Bordeaux, F-33000 Bordeaux, France

*CRS - medical management 3, Building M2 CR2, Sept 29, 10.15*

**Background:** to assess and compare the safety and quality of the management of sinonasal surgeries between ambulatory and traditional hospitalization.

**Methodology:** This is a 2-year retrospective study including all patients undergoing functional naso-septal surgery, ethmoidectomy, middle antrostomy, frontal sinusotomy and endoscopic sphenoidotomy, performed as an outpatient or inpatient hospitalization. Demographic, operative, anesthetic data, per- and postoperative, as well as complications, the rate of emergency consultations and readmissions over the 30 days postoperative were collected. These data were compared between ambulatory and hospitalized patients.

**Results:** 909 patients were included: 569 functional naso-septal surgeries, 180 ethmoidectomies, 101 middle antrostomies, 40 Draf procedures and 19 sphenoidotomies of which 60 - 21 - 54 - 20 and 37% were respectively performed in ambulatory care unit, without statistical difference on the number of emergency room visits and readmissions between the two groups. There were more complications in the hospitalized group ( $p < 0.0001$ ) (4.9% anticoagulant and 12% antiplatelet treatment, 18% obstructive apnea syndrome). The conversion rate of ambulatory stays in hospitalizations was 4.6%. The antiplatelet treatment or postoperative nasal packing was not a risk factor for complications or readmission (not significant).

**Conclusion:** ambulatory sinonasal surgeries do not appear to be overrisk for the patient and the surgeon when the eligibility criteria are met.

## Do Clinicians Assess Local Extension Of Sinonasal Cancer In The Same Way? The Example Of Adenocarcinoma

Sylvestre Fierens, MD,<sup>1</sup> Antoine Moya-Plana, MD,<sup>2</sup> Sebastien Vergez, MD, PhD,<sup>3</sup> Antoine Bénard, MD, PhD,<sup>4</sup> Romain Gallard, MD,<sup>4</sup> Sandrine Molinier-Blossier, MD,<sup>5</sup> Claire Castain, MD,<sup>6</sup> Stephane Orsel, MD,<sup>7</sup> Benjamin Verillaud, MD,<sup>8</sup> Geoffrey Mortuaire, MD,<sup>9</sup> **Ludovic de Gabory, MD, PhD,<sup>1,10</sup>**

<sup>1</sup>Department of Otorhinolaryngology – Head and Neck Surgery, University Hospital of Bordeaux, Bordeaux, France, <sup>2</sup>Department of Otorhinolaryngology – Head and Neck Surgery, Gustave Roussy Cancer Center, Villejuif, France, <sup>3</sup>Department of Otorhinolaryngology – Head and Neck Surgery, University Hospital of Toulouse, Toulouse, France, <sup>4</sup>Pôle de Santé Publique, Clinical Epidemiology Unit (USMR), F-33000 Bordeaux, France, <sup>5</sup>Department of Neuroradiology, University Hospital of Bordeaux, F-33000 Bordeaux, France, <sup>6</sup>Department of Pathology, University Hospital of Bordeaux, Bordeaux, France, <sup>7</sup>Department of Otorhinolaryngology – Head and Neck Surgery, University Hospital of Limoges, Limoges, France, <sup>8</sup>Department of Otorhinolaryngology – Head and Neck Surgery, University Hospital of Lariboisière, Paris, France, <sup>9</sup>Department of Otorhinolaryngology – Head and Neck Surgery, University Hospital of Lille, Lille, France, <sup>10</sup>Univ. Bordeaux, 33000, France

*Sinonasal malignancy 3, Building M2 CR2, Sept 29, 14.45*

**Background:** Our hypothesis was that members of a head and neck multidisciplinary team meeting have their own representation of what tumoral extension is, and that the local extension is over-evaluated perioperatively. The objective was to evaluate the radiologic, surgical and pathologic concordance of the local extension of sinonasal malignant tumors.

**Methods:** An observational, prospective, multicenter, multidisciplinary study was conducted in 6 ENT departments. Each tumoral extension of untreated sinonasal adenocarcinoma was evaluated independently by experienced members of the dedicated head and neck team: the radiologist (R), the surgeon (S), and the pathologist (P). Pre- peri- and post-therapeutic data of tumoral extension were analyzed and compared with the AJCC TNM classification. The cross-disciplinary concordance of tumoral extension was evaluated using Cohen's Kappa coefficient ( $\kappa$ ).

**Results:** Twenty-one patients were included. The cT stages were significantly higher than the pT stages ( $p=0.007$ ). The global R-P concordance was poor ( $\kappa=0.18$  [0-0.38]), while the global S-P concordance was good ( $\kappa=0.70$  [0.40-0.88]). The radiologist significantly over-evaluated the local extension compared to the surgeon ( $p<0.001$ ) and the pathologist ( $p<0.001$ ).

**Conclusion:** The professionals did not have the same representation of the local extension of adenocarcinoma. This discrepancy must be considered during multidisciplinary team meetings.

**Key words:** Tumor board, multidisciplinary team meeting, patient perspectives, healthcare survey, sinonasal cancer, intestinal type adenocarcinoma

203340

Multicentric evaluation of skull base repair during the treatment of sino-nasal cancers.

**Ludovic de Gabory MD PhD<sup>1\*</sup>**, Benjamin Verillaud MD<sup>2</sup>, Cécile Rumeau MD<sup>3</sup>, Philippe Herman MD PhD<sup>2</sup>, Roger Jankowski, MD PhD<sup>3</sup>, Justin Michel MD<sup>4</sup>, Héloïse de Kermadec MD<sup>5</sup>, André Coste MD PhD<sup>5</sup>, Geoffrey Mortuaire MD PhD<sup>6</sup>, Christian Righini, MD PhD<sup>7</sup>, Emile Reyt, MD PhD<sup>7</sup>, Olivier Choussy MD PhD<sup>8</sup>, Vincent Trévillot MD<sup>9</sup>, Louis Crampette MD<sup>9</sup>, Elie Serrano, MD MSc<sup>10</sup>, Mélodie Kérimian, MD<sup>1</sup>, Sebastien Vergez MD PhD<sup>10</sup>

<sup>1</sup>Otorhinolaryngology, Head and Neck Surgery Department, University Hospital Pellegrin, Bordeaux, France

<sup>2</sup>Otorhinolaryngology, Head and Neck Surgery Department, University Hospital Lariboisière, Paris, France

<sup>3</sup>Otorhinolaryngology, Head and Neck Surgery Department, University Hospital of Nancy, France

<sup>4</sup>Otorhinolaryngology, Head and Neck Surgery Department, University Hospital, Marseille, France

<sup>5</sup>Otorhinolaryngology, Head and Neck Surgery Department, University Hospital Creteil, France

<sup>6</sup>Otorhinolaryngology, Head and Neck Surgery Department, University Hospital Charles Nicolle, Lille, France

<sup>7</sup>Otorhinolaryngology, Head and Neck Surgery Department, University Hospital Grenoble, France

<sup>8</sup>Otorhinolaryngology, Head and Neck Surgery Department, University Hospital Charles Nicolle, Rouen, France

<sup>9</sup>Otorhinolaryngology, Head and Neck Surgery Department, University Hospital Guy de Chauliac, Montpellier, France, <sup>10</sup>Otorhinolaryngology, Head and Neck Surgery Department, University Hospital Rangueil-Larrey, Toulouse, France

*Skull base surgery 1, Building M1 Room Σ4, Sept 28, 14.45*

**Background:** Indications and reconstruction techniques for skull base resection during sino-nasal cancer extirpation

**Methodology:** This was a retrospective, multicenter study of ten French tertiary referral centers, including untreated patients of adenocarcinoma (ADK) and neuroblastoma (NBO). All patients were operated by an endoscopic approach. The rate of skull base resection according histologies, positive margins, materials and number of layers to skull base repair were compared.

**Results:** We included 159 ADK and 53 NBO: 35T1, 70T2, 55T3, 52T4. The rates of skull base resection were 46.5% vs 49%, respectively ( $p>0.05$ ): it concerned 8cT1, 20cT2, 32cT3, 39cT4. Histologic margins were positive in 18.5% (5cT1, 5cT2, 5cT3, 14cT4). The materials to rebuilt the skull base were Surgicel®+fibrin glue (30%), nasal mucosa (18%), abdominal fat (22%), Fascia lata (22%) and fascia lata+abdominal fat (8%). The number of layer was 1(59%), 2(28%) or 3(13%). The distribution of materials and layers was heterogeneous according to the tumor stages. It was a significant difference of the number of layer between ADK vs NBO ( $p<0.0006$ ). The complication rate was 7 meningitis (4%), 6 CSF leaks (3%).

**Conclusions:** the attitudes of reconstruction are heterogeneous with a rational depending on each center. The defect sizes were not known.

**Key words:** skull base repair, sinonasal cancer, adenocarcinoma, neuroblastoma, endonasal surgery

203374

## Orbitary and periorbital pediatric cellulitis: the experience of a tertiary hospital center

**Pedro Santos<sup>1</sup>**, André Machado<sup>1</sup>, Gonçalo Mendes<sup>1</sup>, Isabel Carvalho<sup>1</sup>, Cecília Sousa<sup>1</sup>

<sup>1</sup>Department of Otolaryngology and Head and Neck Surgery, Centro Hospitalar do Porto, Porto, Portugal

*Paediatric rhinology 1, Building M2 CR3, Sept 28, 11.45*

**Background:** Orbital (OC) and periorbital cellulitis (PC) are the main infections of the orbital tissue, being frequent pathologies in pediatric age, of varying severity and etiologies.

The otolaryngologist is essential in the assessment of the severity and extension of the disease.

The objective of this study is to describe and analyze the epidemiological, clinical and treatment characteristics of children with PC or OC admitted to Centro Hospitalar e Universitário do Porto over a 10-year period and to determine the factors that differentiate children with PC and CP in terms of clinic, diagnostic investigation, treatment and prognosis.

**Methodology/Principal:** Review of the clinical records of patients admitted to the hospital center diagnosed with PC or OC between January 2009 and December 2019.

**Results:** 79 patients were evaluated, with a mean age of 5.2 years, with a predominance of males, with the majority of patients with a predominant sinonasal etiology.

Epidemiology was according to the literature, with varied signs and symptoms, which were sometimes discrete: more than a third of patients presented without fever, with predominantly local signs. As expected, headache and proptosis and pain with eye movements were more associated with orbital cellulitis.

Regarding patient management generalized analytical study and blood culture were found not decisive in the patient approach, therefore we highlight the importance in monitoring the response to treatment.

**Conclusions:** Orbital and periorbital cellulitis are frequent in pediatric age, thus being familiar with clinical manifestations and therapeutic approach becomes an important aim for the otolaryngologist.

Determination of the extension of disease is vital for treatment and prognosis.

Generally, a favorable evolution is accomplished, but close follow-up for early identification of complications and timely intervention is of utmost importance.

**Key words:** rhinosinusitis, pediatric, cellulitis, orbital, periorbital

Literature:

Flint, Paul W., and Charles W. Cummings. 2010. *Cummings otolaryngology head & neck surgery*.

Bergin DJ, Wright JE. Orbital cellulitis. *Br J Ophthalmol*. 1986 Mar.

Jackson K, Baker SR. Clinical implications of orbital cellulitis. *Laryngoscope*. 1986 May. 96(5):568-74. 70(3):174-8



## Resection classification in sinonasal tumours: Is R0 a reliable attribution?

Thomas Kühnel<sup>1</sup>, Werner Hosemann<sup>2</sup>, Rainer Weber<sup>3</sup>, René Fischer<sup>1</sup>

<sup>1</sup>ENT Department, University Greifswald, Germany; <sup>2</sup>ENT Department, Clinic Karlsruhe, Germany

*Sinonasal malignancy 3, Building M2 CR2, Sept 29, 14.45*

**Background:** To determine whether or not the attribution of R- is reasonable in sinonasal tumours that adhere to the skull base or orbit. Endonasal resection has become a mainstay in treatment of sinonasal tumours. TNM-Classification is a routine action to classify the tumor and to determine necessity of additional radiation therapy. The R-attribution is of paramount importance in the scope of this decision. Nevertheless, it seems to be close to impossible to safely judge this aspect in a great many of cases. We disapprove of resecting dura just to obtain tissue free of tumour as the possible side effects may be severe (loss of barrier, CSF-leak).

**Methodology/Principal:** We revised 60 cases of sinonasal tumours that had been operated on in the past seven years. The decision making in terms of postoperative radiotherapy was analysed in the context of R-attribution.

**Results:** Radiotherapy was offered in most cases (85%) due to T-values. In 15% the decision was based on R-value non-zero. As free margins can not be achieved as a matter of principle in cases of bony skull base encroachment in many cases, we took the individual decision for radiation therapy.

**Conclusions:** Tumour resection of endonasal malignancies remains a technical and strategical challenge. R-attribution in TNM-classification seems inappropriate in cases when achieving clear margins can only be achieved by sacrificing tumour free dura or periorbital tissue. In these cases we propose to apply the neurosurgical system (gross total vs near total).

**Key words:** sinonasal tumours, skull base encroachment, resection, TNM-classification

203386

## Smoking as a modifying factor in chronic rhinosinusitis: Data from the National Chronic Rhinosinusitis Epidemiology Study.

Kristian H Hutson<sup>1</sup>, Carl Philpott<sup>1</sup>, Dr Allan Clark<sup>2</sup>, Mr Shahzada Ahmed<sup>3</sup>, Prof B. Nirmal Kumar<sup>4</sup>, Mr San Sunkaraneni<sup>5</sup>.

<sup>1</sup>ENT department, James Paget University Hospital UK; <sup>2</sup> Norwich Medical School, University of East Anglia, Norfolk, UK; <sup>3</sup>University Hospitals Birmingham NHS Foundation Trust, Birmingham, UK; <sup>4</sup>Wrightington Wigan and Leigh NHS Foundation Trust, Wigan, UK; <sup>5</sup> Royal Surrey County Hospital, Guildford, UK

*CRS – pathophysiology 2, Building M1 Room Σ1, Sept 29, 10.15*

**Background:** The Chronic Rhinosinusitis Epidemiology Study (CRES) was a prospective, questionnaire-based, case-control study conducted between 2007 and 2013 at thirty UK hospitals.

**Methods:** Analysis of the CRES database to determine whether smoking represents a risk factor for CRS and whether smokers experience worse symptoms than non-smokers. There were 219 controls, 546 CRS patients without nasal polyps (CRSsNPs) and 685 CRS patients with nasal polyp (CRSwNPs+).

**Results:** The greatest number of smokers was found amongst controls (15%) with lower rate of smokers in both CRSwNPs+ and CRSsNPs patients. In both CRSsNPs and CRSwNPs+ groups, smokers had significantly worse SNOT-22 scores than non-smokers by a mean magnitude of 10 points. This remained significant after adjusting for age and sex, asthma and SF-36 scores ( $p = 0.001$  and  $0.02$ ). Non smokers also demonstrated a higher percentage of surgical procedures (one or more) although this was not statistically different ( $p=0.098$ ).

**Conclusions:** We could find no association between current smoking status and prevalence of disease, however smoking does have a significant impact upon disease specific patient quality of life. There was no strong demonstrable evidence that smoking increases the likelihood of need for revision sinus surgery.

Key words: rhinosinusitis, smoking, quality of life

# Reconstruction options of the external nose following major oncological excisions creating composite defects: a case series

S.Triaridis<sup>1</sup>, G.A.Spyropoulou<sup>2</sup>, **M.Givannakis**<sup>1</sup>, G.Tsiropoulos<sup>1</sup>, E.Demiri<sup>2</sup>, J.Constantinidis<sup>1</sup>

<sup>1</sup>1<sup>st</sup> Department of Otolaryngology, AHEPA University Hospital, Aristotle University of Thessaloniki, Greece, <sup>2</sup> Department of Plastic Surgery, "Papageorgiou" General Hospital, Aristotle University of Thessaloniki, Greece

*Sinonasal malignancy 2, Building M1 Room Σ3, Sept 28, 14.45*

**Introduction:** Extensive skin malignancies of the external nose necessitate major oncological excision creating aesthetic and functional defects that need to be addressed in one or multiple stages in order to reconstruct the nasal pyramid and restore the function of the nasal airway. Several factors influence the decision of the reconstruction option to utilize, including comorbidity, previous treatment influencing local donor sites, surgical expertise, and physician and patient preferences.

**Case Series:** We report a series of cases who underwent surgical excision of extensive skin malignancies or involving the underlying cartilaginous framework and/or mucosa. Oncological excision with frozen section margins created extensive and/or composite defects, including the dorsum, nasal tip, alae, and/or columella. These defects were treated in one or multiple stages with a variety of local flaps including forehead flap, prelaminate with cartilage template forehead flap, Converse forehead scalp flap, dorsal nasal flap, unilateral or bilateral nasolabial flaps, free auricular and free forearm flaps. Also, we utilized mucosal flap from the nasal vestibule, and septal or auricular cartilage grafts (as required) for reinvesting the lining and reconstructing the framework, respectively. The majority of patients had basal or squamous cell carcinomas, and three had skin melanomas; patients' age ranged from 45-88 years. One melanoma patient had more than two operations due to local recurrence, and three patients refused planned second stage for thinning the flap.

**Conclusion:** Successful treatment of extensive skin tumors of the external nose besides adequate surgical excision with clear margins, involves addressing large and/or composite defects that can be reconstructed with a variety of options. In this illustrative case series, we present several reconstruction options and the treatment choices made based on patients' comorbidity, previous treatment, expertise, and preferences.

**Keywords:** basal cell carcinoma, squamous cell carcinoma, melanoma, extensive excision, composite defect, reconstruction

**J BATES<sup>1</sup>**, D YAPP<sup>1</sup>, M BRIMILO<sup>1</sup>, M DRAPER<sup>1</sup>

<sup>1</sup>Milton Keynes University Hospital, Standing Way, Eaglestone, Milton Keynes MK6 5LD

*Nasal and facial trauma 1, Building M1 Room Σ3, Sept 27, 11.45*

**Background:** Nasal injuries are common and contribute a significant proportion of emergency referrals in ENT. In the UK the majority of nasal fracture manipulations are performed under general anaesthetic (MUA), within fourteen days of the initial injury.

This project however presents a redesigned pathway for managing nasal injuries in an outpatient 'one-stop' nasal injury clinic and also assesses the safety & effectiveness of a novel new sedation technique.

**Methodology:** This project is divided into two parts;

- 1) A retrospective audit over a 6-month period was completed and analysis of this audit led to a redesign of the nasal injury pathway into a 'one-stop' nasal injury clinic.
- 2) A prospective interventional study of all patients referred and assessed in the newly designed 'one-stop' nasal injury clinic over a six-month period. If appropriate all patients were offered nasal fracture manipulation under local anaesthetic with sedation.

**Results:** Retrospectively 89 patients were referred, 20 patients underwent MUA, with 40% of the manipulations occurred within 14 days of the initial injury.

Prospectively 75 patients were referred, 29 underwent MUA (86% with local and sedation) and 91% of manipulations occurred within 14 days.

Post-operative telephone interviews demonstrated reproducible results for both groups and for patient undergoing the local anaesthetic & sedation technique visual analogue scoring of pain reported low (0-2) scores at manipulation.

**Conclusions:** The redesigned 'one-stop' nasal injury clinic was shown to be effective at both reducing waiting times to manipulation and produced high quality results.

**Paresh Pramod Naik**<sup>1</sup>, Shahzada Ahmed<sup>1</sup>, Niki Karavitaki<sup>2</sup>

<sup>1</sup>Department of Otolaryngology University hospital Birmingham, Birmingham, United Kingdom, <sup>2</sup>Department of Endocrinology University Hospital Birmingham, Birmingham, United Kingdom

*Pituitary Surgery 1, Building M1 Room Σ2, Sept 27, 11.45*

**Background:** Endoscopic transsphenoidal surgery is the treatment of choice for all functioning pituitary adenomas other than most prolactinomas. We data series from a single pituitary surgeon, with a remarkable remission rate. We also successfully adopted a novel “Diving technique” for achieving clearance of functioning adenomas.

**Methodology:** This is a retrospective case control study in a tertiary care institute in United Kingdom. 32 patients who underwent surgery for functioning pituitary adenoma were analysed. Patients were divided into two groups; A – who underwent standard transsphenoidal endoscopic surgery; and , B – who underwent clearance by the diving technique.

**Results:** A total of 32 patients were analysed, Group A – had 16 patients who underwent surgery, Group B – had 16 sequential patients who also had the new Diving Technique. In total there were 10 Cushings , 18 acromegaly and 4 prolactinomas. The overall remission rate of our pituitary surgeon was 68.75% for group A and 81.25% for group B. The remission rate using diving technique in Cushings patients was 100%.

**Conclusion:** The Diving technique, a unique and simple technique is easy to learn and can be utilised with equipment present in most theatres undertaking pituitary surgery, this yields high remission rate and should be considered by all pituitary surgeons.

**Key words:** Diving Technique , High Remission, pituitary adenoma, transsphenoidal surgery

## Scarification of olfactory cleft in patient with severe parosmia – case report

**Jan Vodička<sup>1</sup>**, Pavlína Brothánková<sup>1</sup>

<sup>1</sup>Department of Otorhinolaryngology and Head and Neck Surgery, Pardubice Hospital; Faculty of Health Studies, University of Pardubice

*Smell and taste 1, Building M2 CR3, Sept 27, 11.45*

**Background:** Severe form of parosmia decreases quality of life and can have further consequences such as weight loss. It is usually self-limited, but it can persevere for a long period.

**Methodology/Principal:** We present a case study of patient (man, 34 years old), who suffered from severe parosmia after head trauma. After 2 months began severe parosmia. Anosmia was stated by Sniffin' Sticks test and Odorized Markers Test. There were lesions in frontobasal region on MRI scans. Systemic steroids and local anesthesia of the nasal cavity were unsuccessful. 9 months after head trauma he lost 20 kg of his weight. Silver nitrate locally had only temporary positive effect. 2 years after head trauma he decided to undergo scarification of olfactory cleft on both sides endoscopically.

**Results:** The surgery was performed on both sides without complications. Parosmia disappeared. He gained weight (5kg) after three months. One year later he underwent second scarification of olfactory cleft due to intermittent parosmia. Parosmia disappeared and patient is now satisfied, he has still anosmia.

**Conclusions:** We consider scarification of olfactory cleft as one of possible method to treat severe parosmia. Indication to surgery is possible only when conservative treatment fails.

**Key words:** Olfaction, parosmia, endoscopic surgery, olfactory cleft

203457

## Audit of a pre-operative endoscopic sinus surgery clinic to reduce cancellations for surgery

**Sean Fang<sup>1</sup>**, Anastasia Rachmanidou<sup>1</sup>, Irfan Syed<sup>1</sup>

<sup>1</sup>*Department of Otolaryngology, University Hospital Lewisham, London, United Kingdom*

*CRS - medical management 1, Building M2 CR2, Sept 27, 10.15*

**Background:** include here a statement of the main research question.

The EPOS 2012 guidelines advise that endoscopic sinus surgery (ESS) is indicated for the treatment of symptomatic chronic rhinosinusitis (CRS) which has failed to respond to maximal medical therapy. At our Hospital, all patients due to undergo ESS are reviewed within two weeks of their operation. The aim of the consultation is to review pre-operative imaging, ensure pre-operative medication is provided and obtain informed consent. A significant number of patients were inappropriately listed for ESS - not meeting the criteria, potentially resulting in sub-optimal management and increase in waiting times for surgical treatment for CRS.

**Methodology/Principal:** include here the techniques used without going into methodological detail.

A retrospective audit of all pre-operative consultations for ESS between April and July 2019 identified number and cause of cancellation.

**Results:** give a summary of the most important findings with key numerical results given, with measures of error and not just p values.

Out of 25 patients. 7 (28%) were inappropriately listed for surgery. 5 had not received the maximal medical therapy, 1 was asymptomatic and one had an entirely normal CT sinus scan.

**Conclusions:** concisely summarise the study's implications.

Please do not include any citations in the abstract. Avoid specialist abbreviations if possible. Cancellation of planned surgeries at short notice adversely impacts both patients and the ENT theatre utilisation. We have since introduced a management pathway for CRS which aligns with EPOS and ENT UK guidelines tailored to our Trust. We are currently re-auditing our practice to assess for reductions in cancellation rates.

**Key words:** Provide up to 5 key words using Mesh terms for indexing purposes

Chronic sinusitis

Paranasal sinus diseases

Waiting lists

Surgical protocol

Functional endoscopic sinus surgery

Literature

**Background:** One of the first transsphenoidal pituitary operations ever recorded was performed by Viennese otolaryngologist Oskar Hirsh in 1910. Pituitary surgery has evolved massively and the reported results are continuing to improve. There is a learning curve in all craft based disciplines and surgery is no different. This clinical study evaluates the learning curve of transsphenoidal pituitary adenoma excision.

**Methodology:** This is a retrospective study done in a tertiary care centre in United Kingdom. 10 years data was analysed for a single pituitary surgeon and compared with literature.

**Results:** More than 300 patients underwent transsphenoidal approach for pituitary adenoma excision by a single pituitary surgeon. We found a statistically significant decrease in the complication rate with more procedures performed.

**Conclusion:** Pituitary adenomas excision may provide excellent clinical outcomes. Surgical proficiency is improved with ongoing innovations in surgical instrumentation and technology. The acquisition of competency in novel surgical techniques represents a “learning curve”. The learning curve, in addition to being a function of the surgeon’s understanding of the new technique, technical modifications to the technique, and improvements in support staff and perioperative care, is a function of the surgeon’s evolving ease with the procedure and performance in more challenging cases.



## Treatment results of transnasal endoscopic orbital decompression in Graves' orbitopathy

**Mirosław J. Szczepanski<sup>1,2</sup>**, Krzysztof B. Poslednik<sup>2</sup>, Katarzyna Czerwaty<sup>2</sup>, Anna Jablonska-Pawlak<sup>3</sup>, Piotr Miskiewicz<sup>4</sup>, Janusz Sierdzinski<sup>5</sup>, Nils Ludwig<sup>6</sup>, Anna Cyran<sup>7</sup>, Dominika Lacheta<sup>1</sup>, Ireneusz Kantor<sup>2</sup>

<sup>1</sup>Department of Biochemistry, Medical University of Warsaw, Poland; , <sup>2</sup>Department of Otolaryngology, Centre of Postgraduate Medical Education, Warsaw, Poland, <sup>3</sup>Department of Ophthalmology, Medical University of Warsaw, Poland; , <sup>4</sup>Department of Internal Medicine and Endocrinology, Medical University of Warsaw, Poland; , <sup>5</sup>Department of Medical Informatics and Telemedicine, Medical University of Warsaw, Poland; , <sup>6</sup>University of Pittsburgh Cancer Institute, Pittsburgh, PA 15232, USA; , <sup>7</sup>Department of Pathology and Laboratory Medicine, Brown University, Providence, RI 02912, USA;

*Orbital surgery 1, Building M2 CR3, Sept 29, 11.45*

**Background:** Graves orbitopathy (GO) is an autoimmune inflammation of the orbital soft tissue, leading to an increase in the volume of its contents. Various techniques for removing orbital walls to lower the intraorbital pressure exist. Here, we present the results of transnasal endoscopic orbital decompression (TEOD) and assess the suitability of this approach in GO.

**Methods:** Sixteen patients with GO (29 orbits) were referred to our institution between 2017 and 2019 for TEOD. The preoperative evaluation included: GO clinical activity score (CAS), best-corrected visual acuity (BCVA), exophthalmometry, tonometry, as well as evaluation of diplopia and exposure keratitis. The complete ophthalmologic assessment was repeated at 1-month follow-up.

**Results:** TEOD resulted in a significant decrease in exophthalmos from a preoperative mean of  $23.09 \pm 1.92$  mm to  $21.04 \pm 2.02$  mm ( $\pm$  standard deviation;  $p < 0.05$ ). Intraocular pressure (IOP) decreased from  $16.56 \pm 1.94$  mmHg to  $16.03 \pm 4.41$  mmHg ( $p < 0.05$ ) and BCVA improved from  $0.52 \pm 0.33$  to  $0.76 \pm 0.3$  ( $p < 0.05$ ). TEOD also alleviated exposure keratitis and led to a significant reduction in CAS from  $2.38 \pm 1.89$  to  $1.5 \pm 1.55$  ( $p < 0.05$ ). There were no statistically significant differences in reduction or development of diplopia. No postoperative complications occurred.

**Conclusions:** TEOD is a safe and effective therapeutic modality for patients with GO. It improves BCVA, reduces exophthalmos, IOP and CAS while maintaining minimal therapeutic morbidity.

**Keywords:** Graves' orbitopathy, decompression, endoscopic surgery

**Literature:**

1. Rootman DB. Orbital decompression for thyroid eye disease. *Surv Ophthalmol.* 2018;63(1):86-104. doi:10.1016/j.survophthal.2017.03.007.
2. Jefferis JM, Jones RK, Currie ZI, Tan JH, Salvi SM. Orbital decompression for thyroid eye disease: methods, outcomes, and complications. *Eye (Lond).* 2018;32(3):626-636. doi:10.1038/eye.2017.260.
3. She Y-Y, Chi C-C, Chu S-T. Transnasal endoscopic orbital decompression: 15-year clinical experience in Southern Taiwan. *J Formos Med Assoc.* 2014;113(9):648-655. doi:10.1016/j.jfma.2012.08.009

**Background:** Olfactory neuroblastoma (ONB) is an uncommon malignant neuroectodermal nasal tumor. To describe our experience of olfactory outcomes in unilateral skull base resection for skull base lesions.

**Method:** A 64 year old man presented with left sided nasal obstruction for 12 months along with intermittent episodes with epistaxis. His biopsy confirmed a Hyams grade II, olfactory neuroblastoma and Kadish grade II on imaging. He subsequently underwent excision and reconstruction with a novel (FLIP FLAP) flap. Excision and Reconstruction was undertaken using a contralateral nasoseptal flap pedicled on the contralateral skull base.

**Results:** Formal Sniffin sticks smell testing was done before and after surgery. A post-operative MRI showed no evidence of any residuum and after discussing his case in the Birmingham skull base MDT he was placed on active surveillance without post operative radiotherapy.

**Conclusion:** The Flip Flap is a simple, and effective flap for reconstruction of the contralateral skull base. It is less traumatic to the olfactory epithelium and should in theory give better olfactory outcomes compared to the standard Hadad nasoseptal flap. We go through olfactory outcomes for this patient and discuss our outcomes in our series of six unilateral skull base resections

**Keywords:** Olfactory neuroblastoma, flip flap, olfaction, esthenioblastoma

# A twelve-years prospective series of inverted papillomas with intracranial/intraorbital involvement: management and treatment strategies

**Dimitrios Spinos<sup>1</sup>**, Dimitrios Terzakis<sup>2</sup>, Christos Georgalas<sup>2,3</sup>

<sup>1</sup>Department of Otolaryngology, Royal Derby Hospital, University Hospitals of Derby & Burton NHS Trust, Derby, United Kingdom, <sup>2</sup>Department of Endoscopic Skull Base Surgery, Hygeia Hospital, Athens, Greece, <sup>3</sup>Medical school of University of Nicosia, Nicosia, Cyprus

*Skull base surgery 2, Building M2 CR3, Sept 29, 14.45*

**Background:** Sinonasal inverted papillomas (IP) are challenging benign tumors of the nasal cavity, due to their high recurrence rates and the lifetime malignant transformation risk of 10%, as well as their locally aggressive behavior. Our aim is to describe treatment strategies for IPs with intracranial/intraorbital involvement.

**Methodology/Principal:** This is a prospective case series of 18 patients with IP with intracranial/intraorbital involvement. Patient demographics, imaging, pathology, surgical technique and recurrences were recorded prospectively over a period of 12 years.

**Results:** 83% of our patients had been previously operated, consisting of 8 cases with intracranial involvement, 1 case with intraorbital and 9 with both. During a follow up of median 57 (30-115) months we report two recurrences.

**Conclusions:** We postulate the intracranial/intraorbital involvement observed in this series was the result of multiple revisions. However, using accurate imaging protocols and the pedicle-oriented approach for tumor excision, we achieved complete removal in most cases with minimal post-operative complications.

**Key words:** Inverted papilloma, skull base, otolaryngology, recurrence

## Literature

1. Lund VJ, Stammberger H, Nicolai P, Castelnuovo P, Beal T, Beham A, et al. European position paper on endoscopic management of tumours of the nose, paranasal sinuses and skull base. *Rhinol Suppl.* 2010 01;22:1–143.
2. Georgalas Christos, F Wytske J. RHINOLOGY AND SKULL BASE SURGERY: from the lab to the operating room - an evidence-based approach. Place of publication not identified: THIEME; 2013.
3. Adriaensen GFJPM, van der Hout MW, Reinartz SM, Georgalas C, Fokkens WJ. Endoscopic treatment of inverted papilloma attached in the frontal sinus/recess. *Rhinology.* 2015 Dec;53(4):317–24.
4. Pagella F, Pusateri A, Giourgos G, Tinelli C, Matti E. Evolution in the treatment of sinonasal inverted papilloma: pedicle-oriented endoscopic surgery. *Am J Rhinol Allergy.* 2014 Feb;28(1):75–81.
5. Castelnuovo P, Pistochini A, Locatelli D. Different surgical approaches to the sellar region: focusing on the “two nostrils four hands technique.” *Rhinology.* 2006 Mar;44(1):2–7.
6. Chiu AG, Jackman AH, Antunes MB, Feldman MD, Palmer JN. Radiographic and histologic analysis of the bone underlying inverted papillomas. *The Laryngoscope.* 2006 Sep;116(9):1617–20.
7. Adriaensen GFJPM, Lim K-H, Georgalas C, Reinartz SM, Fokkens WJ. Challenges in the Management of Inverted Papilloma: A Review of 72 Revision Cases. *The Laryngoscope.* 2016 Feb;126(2):322–8.

## Implementation of the EPOS2020 indication criteria for biologicals substantially improves the efficacy of dupilumab treatment of chronic rhinosinusitis with nasal polyps – a real-world prospective cohort study

**Rik J.L. van der Lans<sup>1</sup>**, Wytske J. Fokkens<sup>1</sup>, Sietze Reitsma<sup>1</sup>

<sup>1</sup>*Department of Otorhinolaryngology & Head and Neck Surgery, Amsterdam UMC, University of Amsterdam, Amsterdam, The Netherlands*

*Abstract Session 32, Building M2 CR1, Sept 28, 14:45 - 16:15*

**Background:** dupilumab is registered as an add-on therapy for recalcitrant, severe chronic rhinosinusitis with nasal polyps (CRSwNP) in adult patients. This study evaluates its clinical efficacy and safety, and the implementation of the EPOS2020 indication criteria for biologicals in a real-world setting.

**Methodology:** prospective study of adult patients ( $\geq 18$  years) with recalcitrant, severe CRSwNP indicated for biological therapy per the EPOS2020-criteria who started dupilumab as their primary biological treatment in our tertiary referral centre, with a minimum follow-up of 12 weeks up to and including May, 2021. Results were compared to the LIBERTY NP SINUS-24 & -52 trials.

**Results:** the vast majority of the 130 patients demonstrated clinically significant improvement of nasal polyp score, disease specific quality of life (SNOT-22), and/or olfactory functioning. Therapy was ceased in four patients: due to treatment failure (two patients) and (serious) adverse effects (two patients). Otherwise, adverse effects were mild, short-lasting, and well-tolerable. In comparison to the preliminary trials, differing in indication criteria, outcome after 24 weeks was substantially better.

**Conclusions:** dupilumab is a highly effective and generally safe treatment for recalcitrant, severe chronic rhinosinusitis with nasal polyps in adult patients. Therapy efficacy benefits substantially by implementation of the EPOS2020 indication criteria for biologicals.

**Key words:** biologicals, chronic rhinosinusitis with nasal polyps, dupilumab, treatment outcome

### Literature

Bachert, C. et al. Efficacy and safety of dupilumab in patients with severe chronic rhinosinusitis with nasal polyps (LIBERTY NP SINUS-24 and LIBERTY NP SINUS-52): results from two multicentre, randomised, double-blind, placebo-controlled, parallel-group phase 3 trials. *Lancet* 394, 1638–1650 (2019).

## Multiple defects of the skull base: diagnosis and surgical treatment.

**MD, Phd Shelesko E.V.**<sup>1</sup>, Chernikova N.A.<sup>1</sup>, Strunina Yu.V.<sup>1</sup>, Zinkevich D.N.<sup>1</sup>

<sup>1</sup>*Federal State Autonomous Institution "N.N. Burdenko National Medical Research Center of Neurosurgery" of the Ministry of Health of the Russian Federation, 4-Tverskaya-Yamskaya Str. 16, Moscow, Russia, 125047*

*CSF leaks and management 1, Building M1 Room Σ2, Sept 27, 10.15*

**Background:** Multiple skull base defects, accompanied by nasal liquorrhea, are difficult to diagnose and treat

**Methodology/Principal:** Retrospective analysis of case histories of patients who underwent surgical treatment at the N.N. Burdenko Center of Neurosurgery for nasal liquorrhea or pneumocephalus in the period from 2000 to 2019. The study included patients with multiple defects of the skull base.

**Results:** In a series of 39 people, 23 (59%) cases had traumatic etiology, 16 (41%) had spontaneous defects. The plastic efficiency was 97.3%. There was no statistically significant difference in age groups ( $p = 0.1$ ). There was a statistically significant relationship between sex and the cause of liquorrhea ( $p = 0.003$ ), as well as between body mass index and the cause of liquorrhea ( $p = 0.002$ ).

**Conclusions.**

The main statistically significant risk factors for the development of multiple defects of spontaneous etiology are the female sex and the excess weight.

When diagnosing defects, it is necessary to use high-resolution CT and carefully analyze tomograms, as well as view all suspicious and weak points during operations.

The endoscopic endonasal technique is an effective and safe method and has its own characteristics in the treatment of multiple defects of the skull base.

**Keywords:** skull base defect, csf leak, endoscopic endonasal surgery.

Literature

1. Radonjic A, Kassab AM, Moldovan ID, Kilty S, Alkherayf F. Idiopathic intracranial hypertension presenting as bilateral spontaneous lateral intrasphenoidal and transthemoidal meningoceles: a case report and review of the literature. J Med Case Rep. 2019 5;13(1):62. <https://doi.org/10.1186/s13256-018-1959-6>
2. Seth M. Lieberman, Si Chen, Daniel Jethanamest, Roy R. Casiano Spontaneous CSF Rhinorrhea: Prevalence of Multiple Simultaneous Skull Base Defects American Journal of Rhinology & Allergy 2015;29: 77–81. <https://doi.org/10.2500/ajra.2015.29.4121>
3. Jahanshahi J, Zeinalizadeh M, Reza Mohammadi H, Sadrehosseini SM. Endonasal Endoscopic Management of Frontal Sinus Cerebrospinal Fluid Leak Am J Rhinol Allergy. 2017;31(6):406-411. <https://doi.org/10.2500/ajra.2017.31.4478>
4. Bradford A. Woodworth, Anthony Prince, Alexander G. Chiu, Noam A. Cohen, Rodney J. Schlosser, William E. Bolger, David W. Kennedy, James N. Palmer Spontaneous CSF leaks: a paradigm for definitive repair and management of intracranial hypertension. Otolaryngol Head Neck Surg 138:715–720, 2008. <https://doi.org/10.1016/j.otohns.2008.02.010>
5. Ahmed Aly Ibrahim, Mohamed Okasha, Samy Elwany Endoscopic endonasal multilayer repair of traumatic CSF rhinorrhea European Archives of Oto-Rhino-Laryngology 2016; 273 (4):921-926 <https://doi.org/10.1007/s00405-015-3681-y>

## The Spare Roof Technique in reduction rhinoplasty in the patient with a crooked nose: Prospective study

**David Rodrigues Dias<sup>1</sup>**, Mariline Santos<sup>1</sup>, Cecília A. Sousa<sup>1</sup>, Nuno Dourado<sup>2</sup> Jorge Santos<sup>3</sup>, José Amarante<sup>4</sup>, Miguel Gonçalves Ferreira<sup>1,5</sup>

<sup>1</sup>*Centro Hospitalar Universitário do Porto, Instituto de Ciências Biomédicas Abel Salazar – Universidade do Porto – Otolaryngology-Head and Neck Surgery Department.*, <sup>2</sup>*Universidade do Minho, Departamento de Engenharia Mecânica, Guimarães, Portugal*

*Associate Professor - no funding or disclosure on this paper*, <sup>3</sup>*Universidade do Minho, Departamento de Engenharia Mecânica, Guimarães, Portugal*

*Associate Professor - no funding or disclosure on this paper*, <sup>4</sup>*Faculdade de Medicina da Universidade do Porto, Porto, Portugal*, <sup>5</sup>*Hospital da Luz – Arrábida, Porto*

*Rhinoplasty 1, Building M2 CR1, Sept 29, 14.45*

**Background:** We aimed to assess the aesthetic outcomes in patients presenting a crooked nose undergoing reduction rhinoplasty with the Spare Roof Technique (SRT).

**Methodology/Principal :** Prospective, interventional, and longitudinal study performed on patients presenting a crooked nose undergoing primary rhinoplasty by SRT. The validated Portuguese version of the Utrecht Questionnaire for Outcome Assessment in Aesthetic Rhinoplasty was used to assess aesthetic outcomes. Patients completed the questionnaire pre-operatively and again 3 and 12 months post-operatively.

**Results:** The study population included 51 Caucasian Mediterranean patients (33 males; 67 females). Mean age at surgery was 32.8 years.. Analysis of the five aesthetic Likert scale questions in the Utrecht Questionnaire all showed an highly significant improvement after rhinoplasty. The mean preoperative aesthetic sum score was 13.4 (SD 3.5), which improved to 9.24 (SD 3.5) and 9.04 (SD 3.4), respectively, 3 and 12 months postsurgery ( $P < 0.001$ ), indicating a significant improvement of subjective body image in relation to nasal appearance.

**Conclusions:** The Spare Roof Technique is a reliable technique that can help deliver consistently good results in reduction rhinoplasty in patients with a crooked nose.

**Key words:** Rhinoplasty; aesthetic; dorsal hump; crooked nose; spare roof technique.

## Sphenoidotomy through the sphenomaxillary plate – radioanatomic and clinical study

**T. Gotlib<sup>1</sup>**, M. Kuźmińska<sup>1</sup>, K. Bobecka-Wesołowska<sup>2</sup>

<sup>1</sup>Department of Otorhinolaryngology, Head and Neck Surgery, Medical University of Warsaw, Warsaw, Poland,

<sup>2</sup>Faculty of Mathematics and Information Science, Warsaw University of Technology, Warsaw, Poland

*CRS - surgical management 4, Building M1 Room Σ2, Sept 29, 10.15*

**Background:** Sphenomaxillary plate (SMP) is an inconstant bony septum separating the maxillary and sphenoid sinuses. Neglecting this structure during endoscopic sinus surgery may lead to mistaking the sphenoid sinus for the posterior ethmoid cell with potentially dangerous consequences. Its proper identification may allow planned sphenoidotomy through the posterior wall of the maxillary sinus. The aim of this study was to evaluate (1) the incidence and morphology of the SMP and (2) possibility and safety of trans-SMP sphenoidotomy.

**Methodology:** Radioanatomic: multiplanar reconstruction analysis of 117 consecutive paranasal sinus CT scans. Clinical: Trans-SMP sphenoidotomy was performed in consecutive patients operated on for chronic rhinosinusitis.

**Results:** Radioanatomic: The SMP was found in 25% of sides (34% of patients). It was constantly located superolateral to the posterior insertion of the middle turbinate. The SMP formed the prominence that could be identified using volume rendering in 11% of sides (19% of patients). Clinical: 30 trans-SMP sphenoidotomies were performed in 18 patients. The SMP prominence was identified in 15 sides. In absence of SMP prominence, identification of the SMP was still possible.

**Conclusion:** The SMP is present in over 30% Caucasian subjects at least on one side. Sphenoidotomy through the SMP is feasible and safe.

**Key words:** endoscopy, FESS, sphenoid sinus, sphenoidotomy, sphenomaxillary plate,

**Hisham S. Khalil<sup>1,2</sup>**, Marios Stavrakas<sup>1</sup>

<sup>1</sup>ENT Department, University Hospitals Plymouth NHS Trust and <sup>2</sup> Peninsula Medical School, University of Plymouth, Plymouth, UK

*Sinonasal malignancy 3, Building M2 CR2, Sept 29, 14.45*

**Background:** A retrospective audit of 55 patients with sinonasal cancer(SNC) presenting to our institution between 2007 and 2017 revealed that the vast majority presented as stage IV (56.4%) and stage III (16.4%).

**Methodology:** We carried out a retrospective review of the factors that influenced the decision-making process for the management of these patients with advanced cancer. These included histological type, recommendations of the Multidisciplinary team (MDT) and wishes of the patients.

**Results:**Half (50.9%) of the sinonasal malignancies in this cohort of patients were squamous cell carcinomas (SCC) with malignant melanoma accounting for 21.8%. Sinonasal undifferentiated carcinoma was diagnosed in 10.9% of patients, whereas adenocarcinoma was found in 7.3%. The rest of the histological diagnoses were chordoma, neuroblastoma, sarcomatoid carcinoma , haemangiopericytoma and carcinosarcoma. Factors that influenced the decision-making process included the wishes of the patient to avoid disfiguring surgery, surgery that would compromise vision, non-resectability of the tumour, the histological type and positive margins at the time of primary resection.

**Conclusions:**Clinical decision making in patients with advanced SNC remains a complex process and involves evidence-based practice, recommendations by the MDT team and shared-decision making with the patient.

**Key words:** Sinonasal malignancy, stage, patient choice



## Fatal Rhino-Orbital Mucormycosis associated with Covid-19: A case report

**Eleni Gkrinia<sup>1</sup>**, Athanasios Saratziotis<sup>1</sup>, Fani Saini<sup>1</sup>, Antigoni Ktisti<sup>1</sup>, Christos Terzoudis<sup>1</sup>, Ioannis Tsitiridis<sup>1</sup>, Jiannis Hajioannou<sup>1</sup>

<sup>1</sup>*Department of Otolaryngology-Head and Neck Surgery, University Hospital of Larisa, Prof. Charalampos Skoulakis, Larisa, Greece*

*Rhinology – miscellaneous 3, Building M1 Room Σ1, Sept 27, 11.45*

**Background:** Mucormycosis is an acute invasive fungal infection, characterized by high mortality, affecting primarily immunocompromised patients. COVID-19, induced by the severe acute respiratory syndrome coronavirus 2 (SARS-CoV-2), is associated with secondary infections, of both bacterial and fungal origin. We report a case of rhino-orbital mucormycosis in a patient undergoing treatment for COVID-19 infection, highlighting the importance of secondary mycoses' suspicion.

**Methodology/Principal:** A 72-year-old man with a history of diabetes, chronic kidney disease, tobacco/alcohol abuse and recent long-term hospitalization due to COVID-19, presented to the Emergency Department with exophthalmos and ophthalmoplegia bilaterally, inflammation of the facial soft tissue and hard palate's necrotic lesions. Computed Tomography revealed ethmoid and sphenoid sinuses occupation, accompanied by sphenoid bone erosions.

**Results:** Endoscopic maxillary antrostomy, ethmoidectomy and sphenoidotomy was performed bilaterally and diagnosis of rhino-orbital mucormycosis was established by histopathological examination. Subsequently, the patient was transferred to the Intensive Care Unit, where he expired from multi-organic failure because of septic shock.

**Conclusion:** COVID-19 is highly associated with co-infections, mostly of bacterial origin. Immune dysregulation caused by SARS-CoV2, in combination with patients' poor health background, may predispose high-risk fungal infections. Thus, physicians need to be conscious of this eventuality, so as prognosis to be optimized.

**Key-words:** Mucormycosis; Mucor; Fungal Infections; COVID-19; SARS-CoV-2

#### Literature

1. Comely OA, Maertens J, Bresnik M, Ebrahimi R, Ullmann AJ, Bouza E, et al. Liposomal amphotericin B as initial therapy for invasive mold infection: A randomized trial comparing a high-loading dose regimen with standard dosing (AmBiLoad Trial). *Clin Infect Dis*. 2007;44(10):1289–97.
2. Safi M, Ang MJ, Patel P, Silkiss RZ. Rhino-orbital-cerebral mucormycosis (ROCM) and associated cerebritis treated with adjuvant retrobulbar amphotericin B. *Am J Ophthalmol Case Reports* [Internet]. 2020;19:100771. Available from: <https://doi.org/10.1016/j.ajoc.2020.100771>
3. Mehta S, Pandey A. Rhino-Orbital Mucormycosis Associated With COVID-19. *Cureus*. 2020;12(9):10–4.
4. Song G, Liang G, Liu W. Fungal Co-infections Associated with Global COVID-19 Pandemic: A Clinical and Diagnostic Perspective from China. *Mycopathologia* [Internet]. 2020;185(4):599–606. Available from: <https://doi.org/10.1007/s11046-020-00462-9>

201588 TBC

Efficacy of low-dose azithromycin in refractory chronic rhinosinusitis following endoscopic sinus surgery and corticosteroid nasal irrigations: a double-blind, randomized, placebo-controlled trial

**Anastasios Maniakas**<sup>1,2,3</sup>, Marc-Henri Asmar<sup>1</sup>, Axel E.R. Flores<sup>1,2</sup>, Smriti Nayan<sup>4,5</sup>, Saud Alromaih<sup>2,6</sup>, Leandra M. Endam<sup>1</sup>, John S. Sampalis<sup>3,7</sup>, Martin Desrosiers<sup>1,2</sup>

<sup>1</sup>Centre de Recherche du Centre Hospitalier de l'Université de Montréal (CRCHUM), Montreal, QC, Canada,

<sup>2</sup>Division of Otolaryngology-Head & Neck Surgery, Centre Hospitalier de l'Université de Montréal (CHUM),

Montreal, QC, Canada, <sup>3</sup>Division of Experimental Surgery, McGill University, Montreal, QC, Canada,

<sup>4</sup>Division of Otolaryngology-Head & Neck Surgery, McMaster University, Hamilton, ON, Canada,

<sup>5</sup>Department of Surgery, Cambridge Memorial Hospital, Cambridge, ON, Canada, <sup>6</sup>Faculty of Medicine,

King Saud University, Riyadh, Saudi Arabia, <sup>7</sup>Medical affairs, JSS Medical Research, Montreal, QC, Canada

*Abstract Session 13, Building M2 CR1, Sept 27, 14:45 - 16:15*

**Background:** Macrolides are known to have both an immunomodulatory and anti-microbial effect. Our goal was to evaluate the efficacy of low-dose, long-term azithromycin in chronic rhinosinusitis (CRS) patients failing maximal medical therapy (budesonide nasal irrigations (BNI)) and endoscopic sinus surgery (ESS).

**Methods:** A double-blind, randomized, placebo-controlled trial was completed assessing the addition of azithromycin 250mg, 3x/week for 16 weeks in patients 18-years or older failing ESS followed by high-volume BNI. Symptomologic, microbiologic and serologic values were systematically collected.

**Results:** 128 patients were prospectively enrolled and underwent ESS followed by BNI. Four months post-ESS, 48 patients showed disease persistence and were randomized to azithromycin or placebo. Azithromycin, compared to placebo, did not show a statistically significant difference in disease clearance (54% vs. 33%, respectively;  $p=0.104$ ), although patients with favorable outcome on azithromycin, compared to placebo, showed significantly better mean SNOT-22 score improvements (18 vs. -0.9, respectively;  $p=0.026$ ). Excluding AERD patients, azithromycin led to a significantly higher rate of disease clearance, compared to placebo (71% vs. 35%, respectively;  $p=0.031$ ), with a number needed to treat of 3(2.8).

**Conclusion:** Low-dose azithromycin is a therapeutic option with few side-effects that shows favorable clinical outcomes in difficult-to-treat refractory CRS patients, especially if they are AERD-negative.

**Key words:** Chronic rhinosinusitis, Azithromycin, Staphylococcus aureus, Aspirin-exacerbated respiratory disease, double-blind randomized placebo-controlled trial

This study was registered on [Clinicatrials.gov](https://clinicaltrials.gov), NCT02307825

## New insights into tip supporting structures. Consequences for nasal surgery.

**Mariola Popko Zagor<sup>1</sup>**, Egbert H. Huizing<sup>2</sup>, Dirk J. Menger<sup>3</sup>, Suzanne A.M.W. Verlinde-Schellekens<sup>4</sup>, Claire Mackaaij<sup>4</sup>, Ronald L.A.W. Bleys<sup>4</sup>

<sup>1</sup>Department of Otorhinolaryngology, Faculty of Medicine and Dentistry, Medical University of Warsaw, Warsaw, Poland, <sup>2</sup>c/o Department of Anatomy, University Medical Centre Utrecht, Utrecht, The Netherlands, <sup>3</sup>Department of Otorhinolaryngology, University Medical Centre Utrecht, Utrecht, The Netherlands, <sup>4</sup>Department of Anatomy, University Medical Centre Utrecht, Utrecht, The Netherlands

### *Rhinoplasty 1,*

**Background:** Knowledge of tip supporting structures is crucial for successful rhinoplasty surgery. Emphasis is often put on ligamentous structures that are claimed to support the nasal tip. Up to now descriptions of these ligaments have been mainly based on dissection studies while histological evidence has been lacking. Therefore the aim of the present study was to provide precise and comprehensive anatomical and histological descriptions of the tip supporting structures.

**Methodology:** Serial coronal sections of the entire external noses from seven cadavers were studied after staining by Mallory-Cason and Verhoeff-Van Gieson procedures.

**Results:** No histological evidence of ligaments between the cartilaginous and bony parts of the nasal skeleton, and between the skin and the nasal skeleton was found. A continuous perichondrial-periosteal lining surrounding the bony skeleton, triangular, and lobular cartilages was identified within the soft tissue envelope.

**Conclusions:** The main tip supporting and shaping structures are: septal and lobular cartilages, premaxillae and soft tissue envelope with periosteal-perichondrial envelope/membrane.

These findings may have clinical relevance in functional and esthetic rhinoplasties.

**Key words:** tip, perichondrium, periosteum, rhinoplasty, septum

## A Review of Free to Access Rhinology Videos for Otolaryngology Trainees

**Mr Joe Stansfield**, MBBS MRCS(ENT), Northern Care Alliance NHS Trust, Manchester, UK

Dr Lydia Alexander, MBChB, Northern Care Alliance NHS Trust, Manchester, UK

Dr Srijan Sharma, Senior Clinical Fellow, Northern Care Alliance NHS Trust, Manchester, UK

### *Rhinology – miscellaneous 1,*

**Objectives:** To assess the quality of free to access online videos showing specific rhinology procedures of interest to otolaryngology trainees.

**Methods:** Using the Otolaryngology section in the procedure-based assessments of the Intercollegiate Surgical Curriculum Programme (ISCP), we identified 9 core rhinology procedures for inclusion. Specific search terms using the procedures' titles were used in the YouTube search engine, the largest free to access video sharing website. The top ten "most viewed" and "most relevant" videos were reviewed by two independent assessors and given a Global Quality Score (GQS) and a video quality score. A third reviewer decided on the overall score if there were any discrepancies.

**Results:** There were 8,311 videos, viewed more than 40 million times across the 9 categories. There was a large difference in the number of videos for each the procedure, for example, rhinoplasty having 6530 videos and middle meatal antrostomy, only 5 videos. The mean GQS and quality scores for the videos ranked by views were 2.4 and 2.7 respectively, and the mean GQS and quality scores for the videos ranked by relevance were 3.2 and 3.3 respectively.

**Conclusions:** Having separated the videos based on relevance and view count we have shown that searching by relevance tended to yield higher quality videos in terms of both information included and video quality. The study demonstrates that there is a large quantity of free to access videos of procedures that are of sufficient quality to be of use to otolaryngology trainees. However, caution is needed by users when filtering videos due to many available poor-quality videos.

## Reversible obstruction of the olfactory cleft: impact on olfactory perception and nasal patency

**Gerold Besser**<sup>1</sup>, David T. Liu<sup>1</sup>, Bertold Renner<sup>2,3</sup>, Thomas Hummel<sup>4</sup>, Christian A. Mueller<sup>1</sup>

<sup>1</sup>Department of Otorhinolaryngology and Head and Neck Surgery, Medical University of Vienna, Austria,,  
<sup>2</sup>Institute of Experimental and Clinical Pharmacology and Toxicology, Friedrich-Alexander-Universität Erlangen-Nürnberg, Erlangen, Germany, <sup>3</sup>Institute of Clinical Pharmacology, Medizinische Fakultät Carl Gustav Carus, Technische Universität Dresden, Dresden, Germany, <sup>4</sup>Smell and Taste Clinic, Department of Otorhinolaryngology, Technische Universität Dresden, Dresden, Germany

*Smell and taste 1, Building M2 CR3, Sept 27, 11.45*

**Background:** Temporary disruption of sensory input can be studied relatively easily for vision or hearing by covering the eyes or ears. In contrast, closing the nostrils affects not only the sense of smell, but also the ability to breathe through the nose and humidify and warm inhaled air. We hypothesized that filling the olfactory cleft (OC) with dissolvable nasal dressing (foam) would temporarily block olfaction while respecting nasal airflow.

**Methods:** In 30 healthy volunteers, the OC was unilaterally obstructed in a back-to-front fashion. Ortho- and retronasal olfactory function were tested before and after foam application. Ratings of odors and subjective nasal patency (SNP) were collected. Peak nasal inspiratory flow (PNIF) was used to measure nasal patency.

**Results:** Foam was safely applied in every case using minimal instruments. No complications were reported. Ortho- and retronasal test results decreased significantly in overall participants (all  $p < 0.0008$ ). Indicating temporary anosmia, 3 subjects reached the lowest possible score for odor-threshold testing, with corresponding drops in retronasal test scores. PNIF values before and after foam application were not significantly different ( $p = 0.11$ ). SNP ratings decreased slightly, but not significantly ( $p = 0.052$ ). Odor-intensity ratings dropped significantly (all  $p < 0.05$ ).

**Conclusion:** The olfactory cleft can be safely obstructed with dissolvable nasal dressing, resulting in a decrease in odor-intensity and ortho- and retronasal olfactory function test scores. This procedure may serve as a hyposmia model that maintains normal nasal airflow.

**Key Words:** anosmia, candies, flavor, obstruction, olfactory cleft, smell

## Self-reported nasal hyperreactivity is common in all chronic upper airway inflammatory phenotypes

**Wout Backaert**<sup>1,2</sup>, Brecht Steelant<sup>2</sup>, Mark Jorissen<sup>1,3</sup>, Karel Talavera<sup>4</sup>, Peter W. Hellings<sup>1,2,5,6</sup>, Laura Van Gerven<sup>1,2,3</sup>

<sup>1</sup>University hospitals Leuven, Department of Otorhinolaryngology, Leuven, Belgium, <sup>2</sup>KU Leuven, Department of Microbiology, Immunology and transplantation, Allergy and Clinical Immunology Research Unit, Leuven, Belgium, <sup>3</sup>KU Leuven, Department of Neurosciences, Experimental Otorhinolaryngology, Leuven, Belgium, <sup>4</sup>KU Leuven, Department of Cellular and Molecular Medicine, Laboratory of Ion Channel Research, VIB-KU Leuven Center for Brain & Disease Research, Leuven, Belgium, <sup>5</sup>U Ghent Department of Otorhinolaryngology, Laboratory of Upper Airways Research, University of Ghent, Ghent, Belgium, <sup>6</sup>Academic Medical Center, Department of Otorhinolaryngology, Amsterdam, The Netherlands

*Non-allergic rhinitis 1, Building M2 CR2, Sept 28, 11.45*

**Background:** Nasal hyperreactivity (NHR) is mainly studied in non-allergic rhinitis, and is defined as the aggravation of (sino)nasal symptoms by exposure to environmental stimuli that would produce little or no effect in healthy subjects.

**Methodology:** We performed a questionnaire-based study in 605 patients with physician-diagnosed chronic upper airway inflammation and 151 healthy controls enquiring disease severity, prevalence of self-reported NHR, and general wellbeing using validated scales.

**Results:** NHR was reported by 47% of patients compared to 9% of controls. Amongst patients, NHR was mostly reported by patients with a mixed phenotype (52.1%), followed by patients with allergic rhinitis (48.6%), non-allergic rhinitis (47.4%), and chronic rhinosinusitis without (42.1%) and with nasal polyps (40.5%). The presence of NHR correlated with symptom severity in patients with non-allergic rhinitis, but not in the overall cohort of patients. The effect of medication correlated negatively with symptom severity for most nasal symptoms, but not with the presence of NHR. Mental wellbeing was jeopardized by any type of chronic upper airway inflammation, negatively correlating with level of symptom control.

**Conclusions:** NHR is prevalent in all phenotypes of chronic upper airway inflammation regardless of disease severity and use of medication. Most upper airway symptoms respond to medication, but not NHR.

**Key words:** Rhinitis, sinusitis, nasal hyperreactivity

### Literature

Van Gerven L, Steelant B, Hellings PW. Nasal hyperreactivity in rhinitis: A diagnostic and therapeutic challenge. *Allergy*. 2018;73(9):1784–91.

Management of advanced sinonasal malignancies with orbital extension.  
The complex choice of orbital exenteration versus orbital preservation.  
Our experience.

**K. Dzhambazov**, A. Topalova, R..Anesteva, N. Traykova, K. Gigov, Ch. Zhelqzkov,

*Department of Otorhinolaryngology, "St. George", Plovdiv, Bulgaria, Medical University Plovdiv, Bulgaria*

*Sinonasal malignancy 4, Building M1 Room 24, Sept 27, 14.45*

**Background:** Sinonasal malignancies are rare and account for only 3% of all head and neck tumors. They are usually diagnosed at a locally advanced stage when reached a considerable size or infiltrates close proximity structures such as skull base, central nervous system or the orbit. The particularity of the management of orbital invasion is a highly significant and independent parameter for poor prognosis of patients with sinonasal malignancies and a true therapeutic dilemma.

**Material and methods:** 26 patients with sinonasal malignancies for the period of 5 years, treated by the use of the endoscopic endonasal approach. 7 cases with orbital invasion - 4 cases treated combined - endoscopically and external unilateral orbital exenteration and 3 cases with periorbital periosteal extension - treated with endoscopic tumor resection with orbital preservation plus radiotherapy.

**Results:** Due to non-statistically significant number of patients (7 cases with orbital invasion) for 5 years of period, we only discuss and present our experience in the diagnose and strategy in the treatment of this pathology.

**Conclusion:** The management of advanced sinonasal malignancies wit orbital extension requires a complex multidisciplinary approach in order to achieve satisfactory therapeutic and surgical results. The exenteration of the orbit is associated with a better outcome compared to orbital preservation plus radiotherapy for patients with sinonasal malignancies invading the orbit, but it is associated to worse quality of life.

**Key words:** sinonasal malignancy, orbital extension, orbital preservation, orbital exenteration,

## Quality of life after FESS surgery combined with diode laser in patients with chronic rhinosinusitis with nasal polyposis

**Mrvoje Mihalj**<sup>1,2</sup>, Željko Zubčić<sup>1,2</sup>, Josip Maleš<sup>1,2</sup>, Andrijana Včeva<sup>1,2</sup>, Anamarija Šestak<sup>1</sup>, Vjeran Bogović<sup>1,2</sup>, Stjepan Grga Milanković<sup>1</sup>, Tin Prpić<sup>1,2</sup>, Ivan Abičić<sup>1,2</sup>, Matej Rezo<sup>1</sup>, Oliver Pavlović<sup>3</sup>

<sup>1</sup>Department of Otorhinolaryngology and Head and Neck Surgery, Clinical Hospital Centre Osijek, J. Huttlera 4, 31000 Osijek, Croatia, <sup>2</sup>Department of Otorhinolaryngology and Maxillofacial Surgery, Medical Faculty Osijek, University J.J. Strossmayer Osijek, J. Huttlera 4, 31000 Osijek, Croatia, <sup>3</sup>Department of Urology, Clinical Hospital Centre Osijek, J. Huttlera 4, 31000 Osijek, Croatia

*CRS - surgical management 4, Building M1 Room Σ2, Sept 29, 10.45*

**Background:** Chronic rhinosinusitis with nasal polyposis (CRSwNP) is one of the most severe forms of chronic rhinosinusitis. The Sino-Nasal-Outcome Test (SNOT-20) is most commonly used to assess the quality of life of these patients. One of the new treatment options for patients with CRSwNP is endoscopic diode laser polypectomy (DLPE) in local anesthesia. This study aims to compare the quality of life of patients with CRSwNP who underwent FESS and who underwent DLPE before and after surgery.

**Methodology/Principal:** The study included a total of 59 patients with CRSwNP who had undergone FESS or DLPE under local anesthesia. The quality of life before and after surgery was examined using SNOT-20.

**Results:** A total of 59 patients (mean age 50.9±11.5 years) were included in the study, with a greater predominance of men than women (36:23). Endoscopic DLPE was performed in 4(6.8%) patients. The total SNOT-20 pre-surgery score was 43.9±24.3 and postoperative 25.1±22.3. There was no significant difference in pre- and postoperative SNOT-20 scores between patients who had undergone FESS and those who had undergone DLPE.

**Conclusions:** Endoscopic DLPE shows the same success in improving the quality of life as FESS and can be performed under local anesthesia, which is ideal for people with multiple comorbidities.

**Key words:** chronic rhinosinusitis with nasal polyposis; nasal polys; diode laser; SNOT-20

### Literature

1. Whitney WS, Robert PS, Robert CK. Chronic Rhinosinusitis with Nasal Polyps. J Allergy Clin Immunol Pract. 2016;4(4):565–572.
2. Casale M, Costantino A, Sabatino L, Luchena A, Moffa A, Cassano M, Rinaldi V, Baptista PM. Minimally invasive surgery under local anaesthesia for chronic rhinosinusitis with nasal polyps: our experience in older adults. J Laryngol Otol. 2020;12:1-5.
3. Caffier PP, Neumann K, Enzmann H, Paschen C, Scherer H, Göktas O. Endoscopic diode laser polypectomy and high-dose intranasal steroids in recurrent nasal polyposis. Am J Rhinol Allergy. 2010;24(2):143-9.
4. Mihalj H, Loncar MB, Mihalj M, Zubčić Z, Včeva A, Bujak M, Males J, Marić A. Influence of allergy and bacterial colonization on the quality of life in nasal polyposis patients. Coll Antropol. 2013;37(4):1139-46.
5. Mihalj M, Bujak M, Butković J, Zubčić Ž, Tolušić Levak M, Čes J, Kopic V, Baus Lončar M, Mihalj H. Differential Expression of TFF1 and TFF3 in Patients Suffering from Chronic Rhinosinusitis with Nasal Polyposis. Int J Mol Sci. 2019;20(21). pii: E5461.



## Reconstructive surgery with microvascular free flaps after extended resections of nasal tumors

**Agnieszka Piotrowska-Seweryn<sup>1</sup>**, Łukasz Krakowczyk<sup>1</sup>, Cezary Szymczyk<sup>1</sup>, Janusz Wierzgoń<sup>1</sup>, Ryszard Szumniak<sup>1</sup>, Maciej Grajek<sup>1</sup>, Mirosław Dobrut<sup>1</sup>, Piotr Drozdowski<sup>1</sup>, Dominik Walczak<sup>1</sup>, Jakub Opyrchał<sup>1</sup>, Daniel Bula, Adam Maciejewski<sup>1</sup>

<sup>1</sup>Department of Oncological and Reconstructive Surgery, National Institute of Oncology Maria Skłodowska-Curie National Research Institute, Gliwice Branch, Poland; Head: prof. Adam Maciejewski MD PhD

*Miscellaneous 1, Building M1 Room Σ1, Sept 28, 11.45*

**Introduction:** Reconstructive surgery of external nasal defects after tumor resection is a serious challenge.

When planning an appropriate method, one should take into account many factors influencing its success, such as: division of the face into aesthetic subunits, the distribution of natural skin tension lines, and the vascularization of individual areas of the face and nose.

Surgical techniques used in nasal reconstruction include many options for covering the postoperative defect. The most common restorative methods are locoregional techniques and microvascular free flaps.

The aim of the study was to present selected advanced clinical cases in which complex reconstructions with the use of free flaps based on microvascular anastomosis were applied.

**Materials and methods:** A total of 48 patients who were surgically treated at the Oncological and Reconstructive Surgery Clinic, National Cancer Institute in Gliwice, Poland in the years 2010-2020 were included in the study. The case histories of the patients were thoroughly analyzed. The functional and aesthetic outcome was assessed.

**Results :** 92 free microvascular free flaps were used for nasal reconstructions after extended resections. The following flaps were performed: radial forearm free flap in 24 patients, radial forearm free flap with radial bone in 14 patients, auricular free flap in 16 patients, radial forearm free flap in combination with auricle free flap in 7 patients, double auricular free flap in 6 patients, radial forearm free flap in combination with double auricular free flap in 4 patients. Total necrosis of the free flap was noted in 4 cases, partial in 6 patients.

**Conclusions:** The presented surgical techniques using microvascular free flaps constitute a recognized method of treatment which lead to optimal functional and aesthetic final outcome in majority of patients.

Clara Monica De Lima<sup>1</sup>*Miscellaneous 1, Building M1 Room Σ1, Sept 28, 11.45*

Leishmaniasis is a broad spectrum of diseases that affect humans, transmitted by females of sandfly vector insects infected by more than 20 species of protozoa of the genus *Leishmania*, and can manifest in various clinical forms.

The World Health Organization (WHO) considers leishmaniasis as one of the six most important infectious diseases, not only because of the high incidence and wide geographical distribution of the disease, but also because it can take forms that determine destructive, disfiguring and even incapacitating lesions. great impact on the individual's quality of life. American cutaneous leishmaniasis (ATL) is a non-contagious infectious disease caused by different species of protozoa of the genus *Leishmania*, which affect the skin (cutaneous leishmaniasis) and mucosae (mucous or mucocutaneous leishmaniasis). The disease has been described in almost all American countries, from the extreme south of the United States to northern Argentina, except Chile and Uruguay.

Approximately 3 to 5% of cutaneous leishmaniasis (CL) cases caused by *Leishmania Viannia braziliensis* are estimated to develop mucosal lesions, either concomitantly or after resolution of the cutaneous disease. The classic form of mucosal leishmaniasis (ML) occurs secondary to skin lesion. However, in a few cases, LM is primary, with no previous or concomitant history of cutaneous lesions.

In almost 90% of the cases, ML affects the nasal mucosa. The second site of involvement is the pharynx mucosa, followed by the larynx and mouth mucosa. Exceptionally the trachea and upper respiratory tree can also be sites of injury.

A proposal for clinical staging of mucosal leishmaniasis was recently published, characterizing five stages of the disease. Stage I being characterized by nodulation in the nasal septum mucosa, Stage II a fine-grained superficial ulceration, Stage III a deep-grained ulceration, Stage IV nasal septum perforation, and Stage V destruction of the nasal pyramid. It is known that antimony therapy is not the best drug for ATL, but due to the high cost of liposomal amphotericin B, antimony continues to be the first choice drug for treatment of ML in all counties of South and Central American. The standard treatment for the most cases of ML is pentavalent antimony 20 mg per kg of body weight per day for 30 days. However, this drug has several adverse effects and some contraindications. Of note, there has been greater use of newer and more efficacious therapies for cutaneous and ML over the past 20 years, including amphotericin B, pantamidine, miltefosine, combination of antimony and pentoxifylline and antimony with granulocyte/macrophage colony stimulating factor. The association of pentoxifylline, an inhibitor of TNF, plus antimony is more effective than antimony alone, and cure ML patients refractory to antimony. ML is associated with an exaggerated inflammatory response and TNF plays a key role in the pathology associated with these disease. Antimony therapy associated with pentoxifylline, a TNF inhibitor, has been shown to decrease the healing time in CL and ML patients, and cure patients refractory to antimony therapy. The treatment of ML is still a challenge.



## Nasopharyngeal defect due to Epstein-Barr virus-positive Mucocutaneous Ulcer (EBVMCU)

**BLK Wong<sup>1</sup>**, M Kiakou<sup>1</sup>, M Puvanendran<sup>1</sup>

<sup>1</sup>*Department of Otolaryngology, Broomfield Hospital, Mid and South Essex NHS Foundation Trust, UK*

*Sinonasal malignancy 1, Building M1 Room Σ3, Sept 27, 14.45*

**Background:** EBVMCU was described as a lymphoproliferative disorder and established as a new clinicopathologic entity by WHO in 2017. The lesions were characterized by proliferation of EBV-positive, atypical B-cells that resemble Hodgkin and Reed Sternberg (HRS)-like cells. Hence, EBVMCU may be misdiagnosed as diffuse large B-cell lymphoma or other lymphomas. Obtaining the correct diagnosis is therefore crucial.

**Methodology/Principal:** We present a case of EBVMCU occurring within the nasopharynx resulting in a large defect.

**Results:** A 71 year-old man with rheumatoid arthritis on methotrexate and insulin-dependent diabetes presented with pain in the throat and dysphagia secondary to nasal regurgitation. Clinical examination revealed multiple ulcers within the nasopharynx and a large nasopharyngeal defect involving the soft palate.

Biopsy of the ulcers showed polymorphic lymphoid infiltrate with HRS-like cells dispersed between lymphocytes. The cells showed strong positivity for CD20, Pax5, MUM1, CD30 and CD15 and EBV on EBER. No dysplasia or malignant cells were seen.

**Conclusions:** EBVMCU tends to affect the skin, gastrointestinal tract and oropharynx. It often occur in patients with immunodeficiency or autoimmune diseases and on immunosuppressants as in our case. EBVMCU has good prognosis with spontaneous regression or complete remission. Systemic chemotherapy or radiotherapy is often unnecessary. It is important for otolaryngologist to recognize this disease entity.

**Key words:** EBV mucocutaneous ulcer, lympho-proliferative disorder, immunodeficiency, nasopharynx

### Literature

1. Ikeda T, Gion Y, Nishimura Y, Nishimura MF, Yoshino T, Sato Y. Epstein-Barr Virus-Positive Mucocutaneous Ulcer: A Unique and Curious Disease Entity. *Int J Mol Sci.* 2021 Jan 21;22(3):1053

## The olfactory diary: Olfactory dysfunction over the course of the day

**David T. Liu<sup>1</sup>**, Gerold Besser<sup>1</sup>, Gunjan Sharma<sup>1</sup>, Bertold Renner<sup>2,3</sup>, Christian A. Mueller<sup>1</sup>

<sup>1</sup>Department of Otorhinolaryngology, Head and Neck Surgery, Medical University of Vienna, Vienna, Austria,,<sup>2</sup>Institute of Experimental and Clinical Pharmacology and Toxicology, Friedrich-Alexander Universität Erlangen-Nürnberg, Erlangen, Germany, <sup>3</sup>Institute of Clinical Pharmacology, TU Dresden, Dresden, Germany

*Smell and taste 2, Building M2 CR2, Sept 27, 14.45*

**Background:** Olfactory dysfunction (OD) impacts the daily life of affected individuals in areas related to cooking, eating, personal hygiene, safety, and social life. This study aimed to follow the daily course of patients with OD to assess (i) how many times a day, (i) at which daytime, and (iii) in which aspects of daily life patients miss their sense of smell.

**Methodology/Principal:** This was a prospective, longitudinal study that assessed the hourly course of smell loss based on hardcover diaries over 14 days. Fifty patients (28 females, mean/SD: age 50/15) with OD underwent psychophysical testing twice using the Sniffin' Sticks TDI test, and olfactory symptomatology was assessed based on validated questionnaires.

**Results:** Psychophysical test results and quality of life measures did not differ significantly over two weeks (both  $p > 0.05$ ). Patients were affected by their OD in everyday life on average eight times a day (range 0-24). In social life activities and personal hygiene, olfactory symptomatology followed a bi-daily peak, while eating/cooking-related activities peaked three times. Difficulties in social life were most common, followed by eating/cooking and personal hygiene.

**Conclusions:** During the counseling of patients with OD, particular emphasis should be placed on social life, food-related areas, and personal hygiene.

**Key words:** Smell loss, olfactory dysfunction, anosmia, hyposmia, olfactory diary

## Clinical use of mometasone furoate-coated sinus implant PROPEL® in Draf type III frontal sinus drainage

**Caroline T. Seebauer**<sup>1</sup>, René Fischer<sup>1</sup>, Kornelia E.C. Andorfer<sup>1</sup>, Veronika Vielsmeier<sup>1</sup>, Thomas S. Kühnel<sup>1</sup>

<sup>1</sup>Department of Otorhinolaryngology, University Hospital Regensburg, Regensburg, Germany

*Abstract Session 13, Building M2 CR1, Sept 27, 14:45 - 16:15*

**Background:** Stenosis of the sinus drainage after endonasal endoscopic frontal sinus surgery can lead to recurrent blockage with need of revision surgery. Steroid-eluting sinus implants enable targeted drug application into areas, in which local inflammation and scarring induce reduction of the drainage.

**Methodology/Principal:** A retrospective study enrolled 36 patients, who had frontal sinus surgery Draf type III with insertion of a mometasone furoate-coated sinus implant. Patients' data was investigated with regard to indication, surgical technique, postoperative follow up, aperture ratio of drainage pathway and compared to a matched cohort without insertion of sinus implants.

**Results:** 36 patients with steroid-eluting sinus implants were followed up for a median period of twelve months. In 30 patients raw bone surfaces were covered with pedicled mucosal grafts. The sinus implant was removed after a median of twelve days. During the follow up period 34 patients endoscopically showed an open drainage pathway, which was wide to maximally wide in 32 patients.

**Conclusions:** Placement of mometasone furoate-coated sinus implants after extended frontal sinus surgery may lead to open drainage pathways in long term follow up by reducing local tissue response. Additionally, frontal sinus stenting mechanically supports postoperative wound healing through adhesion of vascularized mucosal grafts to bony structures.

**Key words:** mometasone furoate-coated sinus implant, frontal sinus drainage, Draf type III, chronic sinusitis

## Morphological Changes in Nasal Mucosa in Patients with Sarcoidosis.

**Pavlos Pavlidis**<sup>1</sup>, Evangelia Fouka<sup>2</sup>, Georgios Katsilis<sup>1</sup>, Haralampos Gouveris<sup>3+</sup>, Despoina Papakosta<sup>2+</sup>

<sup>1</sup>ENT Clinic, Papanikolaou-Hospital, Thessaloniki, Greece, <sup>2</sup>Pulmonary Department of Aristotle University of Thessaloniki, Thessaloniki, Greece, <sup>3</sup>ENT Clinic, University Hospital Mainz, Mainz, Germany

(+) equal contribution

*Rhinology – miscellaneous 1, Building M1 Room Σ2, Sept 28, 14:45*

**Background:** Sarcoidosis is a chronic granulomatous disease, which affects mainly the lower respiratory tract. Involvement of the nose or the sinuses is a rare manifestation. The purpose of this study was the evaluation of any alterations in the microvascular network of the nasal mucosa in patients with pulmonary sarcoidosis and the investigation of potential correlations with olfactory acuity and levels of serum Angiotensin-Converting-Enzyme (sACE).

**Methods:** We analyzed retrospectively 15 cases of patients with pulmonary sarcoidosis with symptoms indicative of sinonasal involvement. Patients' nasal mucosa was examined directly with a contact endoscope. Olfactory acuity was also examined with Sniffin' Sticks. Patients' findings were also compared to those of 15 healthy subjects.

**Results:** Contact endoscopy revealed that nasal microvascular network was disrupted in the majority of the patients (14/15), while in one patient no vesicles could be detected.

Moreover, hyposmia was documented in four patients and complete anosmia in one patient. Statistical analysis showed only a weak correlation between vascularization patterns and Sniffin' Sticks Test results and sACE levels ( $r=0,2$  and  $r=0,4$  respectively).

**Conclusions:** Contact endoscopy, when combined with olfactory tests, is probably an emerging and promising procedure for an early diagnosis of inflammatory/affected lesions within the mucosa, in sarcoidosis patients with symptoms of sinonasal involvement.

**Keywords:** Sinonasal Sarcoidosis; vascularization patterns; contact endoscopy; sniffin's test

## Role of probiotics in patients with Allergic Rhinitis: A systematic review of systematic reviews

**Haissan Iftikhar**<sup>1</sup>, Mohammad Ozair Awan<sup>2</sup>, Mohammad Sohail Awan<sup>3</sup>, Khawaja Mustafa<sup>4</sup>, Jai K Das<sup>5</sup>, Shahzada Khuram Ahmed<sup>6</sup>

*Author (1,6) is affiliated with Department of Otolaryngology, Queen Elizabeth Hospital, Birmingham, United Kingdom, Author (2,3,4) are affiliated with Aga Khan University Medical College, Karachi, Pakistan, Author (5) is affiliated with Division of Women and Child health, Aga Khan University, Karachi, Pakistan*

*Allergic Rhinitis 1, Building M1 Room E3, Sept 28, 10:15*

**Background:** Allergic rhinitis is estimated to affect up to 30% of the global population. With rising cases, newer treatment modalities have been explored. Probiotics have shown to reduce symptoms of allergic rhinitis and improve quality of life. A few systematic reviews have been published aiming to assess the role of probiotics in allergic rhinitis. We aimed to consolidate the recent evidence with an overview of systematic reviews.

**Methodology:** We conducted literature search on four data bases: PubMed, EBSCO CINAHL, EBSCO Dentistry and Oral Science source and Wiley Cochrane library up to 14<sup>th</sup> April 2020. Data was extracted for subjective outcomes (Quality of Life questionnaire, Nasal Symptoms Score, Ocular Symptoms Score, Daily Total Symptoms Score, Incidence of AR and Rhinitis Total Symptom Score) and objective outcomes (Antigen Specific IgE, Total IgE, IL-10, IFN-Gamma, Th1/Th2 Ratio and Eosinophil Rates). Qualitative assessment was performed using AMSTAR-2.

**Results:** A total of 419 titles were screened, of which three systematic reviews met our eligibility criteria. Probiotics in the treatment of allergic rhinitis has shown to improve quality of life, nasal and ocular symptom score, daily total symptom scores and Th1/Th2 ratio. No difference was ascertained for rhinitis total symptom score, antigen specific IgE, total IgE, IL-10, INF-Gamma and eosinophil rates. Overall, the quality of reviews was moderate to low.

**Conclusion:** Our review showed that there is considerable evidence available that reports probiotics to be useful in the treatment of allergic rhinitis. Further randomized trials targeting the limitations of the current available evidence can help ascertain the usefulness of probiotics for allergic rhinitis.

**Keywords:** Allergic rhinitis; Probiotics; Nasal symptom score; Quality of life; Rhinosinusitis



## Two walls versus three wall orbital decompression for thyroid eye disease: A systematic review and meta-analysis

**Haissan Iftikhar**<sup>1</sup>, Muhammad Hammad Deewani<sup>2</sup>, Syed Akbar Abbas<sup>3</sup>, Zohra S Lassi<sup>4</sup>, Khawaja Mustafa<sup>5</sup>, Jai K Das<sup>6</sup>, Shahzada Khuram Ahmed<sup>7</sup>

*Author (1 and 7) are affiliated with Department of Otolaryngology, Queen Elizabeth Hospital, Birmingham, United Kingdom , Author (2,3 and 5) are affiliated to Department of Surgery, Aga Khan University Hospital, Karachi, Pakistan , Author (4) is affiliated with Robinson Research Institute, Faculty of Health and Medical Sciences, University of Adelaide, Australia. , Author (6) is affiliated with Division of Women and Child health, Aga Khan University, Karachi, Pakistan*

*Orbital surgery 1, Building M2 CR3, Sept 29, 11:45*

**Background:** Surgical orbital decompression for thyroid eye disease has proven to be a safe and an effective means to reduce proptosis and treat thyroid ophthalmopathy. There are a variety of approaches that have been used for orbital decompression without consensus. We aimed to assess the two wall versus three wall orbital decompression for thyroid eye disease.

**Methods:** We conducted a systematic review according to PRISMA guidelines. A literature search was performed on EBSCO CINAHL plus, Wiley Cochrane Library, Web of science and PubMed. We included all studies that compared two wall (medial and inferior) endoscopic decompression with three wall decompression. We extracted data from published literature and conducted a qualitative assessment using Cochrane EPOC criteria.

**Results:** The search identified a total of 111 articles of which two studies met the eligibility criteria. A total of 37 patients underwent two wall decompression and 35 patients underwent three wall decompression. There was significant difference seen with change in proptosis between two wall compared to three wall decompressions MD: 2.98 mm (95% CI: 1.36 – 4.60) favoring three wall decompression,  $Z = 3.60$  ( $p = 0.0003$ ). New onset diplopia showed a greater trend towards two wall decompression but it was statistically insignificant RR: 0.42 (95% CI: 0.06 – 3.11),  $Z = 0.85$  ( $p=0.39$ ). The quality of the included studies were graded from low to unclear risk of bias.

**Conclusion:** At present, there is limited evidence available to determine if three wall orbital decompression is superior to two wall orbital decompression for thyroid eye disease. There is a need for prospective randomized trials to accurately determine the superiority of either intervention.

**Keywords:** Thyroid eye disease; orbital decompression; endoscopic decompression; Orbit; Thyroid

## Optimum degree of head elevation/Reverse Trendelenburg Position for sinus surgery: Systematic review

**Haissan Iftikhar**<sup>1</sup>, Shahzada Khuram Ahmed<sup>2</sup>, Syed Akbar Abbas<sup>3</sup>, Mubasher Ikram<sup>4</sup>, Khawaja Mustafa<sup>5</sup>, Jai K Das<sup>6</sup>

*Author (1,2) are affiliated with Department of Otolaryngology, Queen Elizabeth Hospital, Birmingham, United Kingdom, Author (3,4) are affiliated to Department of Surgery, Aga Khan University Hospital, Karachi, Pakistan, Author (5) is affiliated with Aga Khan University Medical College, Karachi, Pakistan, Author (6) is affiliated with Division of Women and Child health, Aga Khan University, Karachi, Pakistan*

*Rhinology – miscellaneous 3, Building M1 Room Σ1, Sept 27, 11:45*

**Background:** This review aims to evaluate the effect of Reverse Trendelenburg Position (RTP) on bleeding and Boezaart score and to determine the optimum degree of head elevation through a systematic review and meta-analysis

**Methodology:** We conducted a systematic review according to PRISMA guidelines and a literature search was performed on PubMed, Web of Science, Cochrane, Dental and Oral Science, Google scholar and Clinicaltrials.gov and included randomized controlled trials (RCTs) in English language only. We extracted all relevant data and conducted quality assessment using Cochrane risk of Bias tool (Version 2). We also performed quality assessment of the outcomes using GRADE. Meta-analysis for all the outcomes using conducted on RevMan version 5.3.

**Results:** The search identified 629 articles and three RCTs that met our inclusion criteria. Two were included in the meta-analysis. A total of 124 patients were assessed for bleeding during sinus surgery and there was a significant reduction in total blood loss in RTP (10-15°) when compared to horizontal position by 134 ml (Mean Difference (MD): -134.23; 95% confidence interval (CI): -184.13 to -67.27). RTP also had a significant reduction in bleeding per minute by 1.07ml/min (MD: -1.07; 95%CI: (-1.69 to -0.44)), while the Boezaart score was significantly lower in the RTP group (MD: -0.69; 95%CI: -0.94 to -0.43) when compared to horizontal position.

**Conclusion:** Though with limited evidence RTP for ESS reduces total blood loss, blood loss per minute and improves visualization. Further studies are needed to assess the actual impact and optimal degree of head elevation.

**Keywords:** Reverse Trendelenburg Position, Head Elevation, Sinus Surgery, Chronic Rhinosinusitis, Sinusitis, Bleeding.

## Optimum degree of head elevation/Reverse Trendelenburg Position for sinus surgery: Systematic review

**Haissan Iftikhar**<sup>1</sup>, Shahzada Khuram Ahmed<sup>2</sup>, Syed Akbar Abbas<sup>3</sup>, Mubasher Ikram<sup>4</sup>, Khawaja Mustafa<sup>5</sup>, Jai K Das<sup>6</sup>

*Author (1,2) are affiliated with Department of Otolaryngology, Queen Elizabeth Hospital, Birmingham, United Kingdom, Author (3,4) are affiliated to Department of Surgery, Aga Khan University Hospital, Karachi, Pakistan, Author (5) is affiliated with Aga Khan University Medical College, Karachi, Pakistan, Author (6) is affiliated with Division of Women and Child health, Aga Khan University, Karachi, Pakistan*

*Rhinology – miscellaneous 3, Building M1 Room Σ1, Sept 27, 11:45*

**Background:** This review aims to evaluate the effect of Reverse Trendelenburg Position (RTP) on bleeding and Boezaart score and to determine the optimum degree of head elevation through a systematic review and meta-analysis

**Methodology:** We conducted a systematic review according to PRISMA guidelines and a literature search was performed on PubMed, Web of Science, Cochrane, Dental and Oral Science, Google scholar and Clinicaltrials.gov and included randomized controlled trials (RCTs) in English language only. We extracted all relevant data and conducted quality assessment using Cochrane risk of Bias tool (Version 2). We also performed quality assessment of the outcomes using GRADE. Meta-analysis for all the outcomes using conducted on RevMan version 5.3.

**Results:** The search identified 629 articles and three RCTs that met our inclusion criteria. Two were included in the meta-analysis. A total of 124 patients were assessed for bleeding during sinus surgery and there was a significant reduction in total blood loss in RTP (10-15°) when compared to horizontal position by 134 ml (Mean Difference (MD): -134.23; 95% confidence interval (CI): -184.13 to -67.27). RTP also had a significant reduction in bleeding per minute by 1.07ml/min (MD: -1.07; 95%CI: (-1.69 to -0.44)), while the Boezaart score was significantly lower in the RTP group (MD: -0.69; 95%CI: -0.94 to -0.43) when compared to horizontal position.

**Conclusion:** Though with limited evidence RTP for ESS reduces total blood loss, blood loss per minute and improves visualization. Further studies are needed to assess the actual impact and optimal degree of head elevation.

**Keywords:** Reverse Trendelenburg Position, Head Elevation, Sinus Surgery, Chronic Rhinosinusitis, Sinusitis, Bleeding.

## The safety and efficacy of intrathecal fluorescein in the management of cerebrospinal fluid repairs – a systematic review

**Keshav Kumar Gupta<sup>1</sup>**, Karan Jolly<sup>1</sup>, Jameel Muzzafar<sup>1</sup>, Shahzada K. Ahmed<sup>1</sup>

<sup>1</sup>*Department of Otorhinolaryngology, Queen Elizabeth Hospital, University Hospitals Birmingham NHS Foundation Trust. Birmingham. B15 2TH. United Kingdom.*

*CSF leaks and management 1, Building M1 Room Σ2, Sept 27, 10:15*

**Background:** Management of cerebrospinal fluid (CSF) leaks is crucial to reduce significant associated morbidity such as meningitis. Intrathecal fluorescein (IF) has proven to be a valuable intra-operative adjunct in successfully localising the site of CSF fistulae with its use was first documented over 40 years ago. The aim of this study was to assess the safety and efficacy of IF use in this cohort.

**Methodology:** A systematic review was conducted of all published data related to the use of IF in endoscopic CSF leak repairs.

**Results:** A total of 18 articles were included representing 327 procedures using IF. The positive localisation rate of CSF leak sites was 79.5% with an 11.9% peri-operative complication rate.

**Conclusions:** Our results demonstrate that IF is effective at localising CSF fistulae during endoscopic approaches in adults. While our data shows a complication rate of 11.9%, the true figure directly related to IF use is likely to be lower. Low doses of preservative free IF diluted in up to 10ml of CSF and administered slowly can be safely used in the endoscopic management of CSF fistulae. Whilst its use remains off licence in the UK, we propose that considerations are made with regards to licensing its use in this context.

**Key words:** CSF leak; endoscopic endonasal surgery; fluorescein; intrathecal fluorescein; skull base surgery

## Can Tachosil® be used as an adjunct to the nasoseptal flap following endoscopic transsphenoidal surgery?

Keshav Kumar Gupta<sup>1</sup>, Karan Jolly<sup>1</sup>, Ofuchi Egbuji<sup>2</sup>, Paresh Naik<sup>2</sup>, Shahzada K. Ahmed<sup>2</sup>

<sup>1</sup>Department of Otorhinolaryngology, New Cross Hospital, The Royal Wolverhampton NHS Trust. Wolverhampton. WV10 0QP. United Kingdom., <sup>2</sup>Department of Otorhinolaryngology, Queen Elizabeth Hospital, University Hospitals Birmingham NHS Foundation Trust. Birmingham. B15 2TH. United Kingdom.

*Skull base surgery 1, Building M1 Room Σ4, Sept 28, 14:45*

**Background:** CSF leak following endoscopic transsphenoidal surgery remains the most important measure in the success of any repair. The nasoseptal flap (NSF) has played a pivotal role in reconstruction. However, associated morbidity includes bleeding, septal injury and altered smell. The purpose of this study was to evaluate the effectiveness of Tachosil® to repair intraoperative defects during an endoscopic transsphenoidal approach.

**Methodology:** All patients who underwent an endoscopic transsphenoidal approach at our tertiary centre, between January 2013 and June 2020 were retrospectively analysed in this case series.

**Results:** A total of 52 procedures were included. The overall post-operative CSF leak rate was 7.8% (n=4), with all cases having had a Tachosil® overlay reconstruction with no NSF. A NSF was harvested in only 5 cases alongside the Tachosil® patch, none of which developed a post-operative leak. No patient had any post-operative adverse outcomes that were attributed to Tachosil®.

**Conclusions:** We believe this to be the largest case series evaluating the endoscopic use of Tachosil® in skull base reconstruction. Our data shows that in endoscopic transsphenoidal approach, Tachosil® may be used safely in a multi-layered approach as an effective alternative to the NSF in low flow CSF leak cases, or alongside a NSF in higher flow leaks.

**Key words:** CSF leak; endoscopic endonasal surgery; pituitary adenoma; Tachosil®; nasoseptal flap; transsphenoidal surgery; skull base surgery

## Coblation as a Novel Technique to Treat Severe Rhinophyma with Excellent outcomes. Case series of 4 patients.

**Joseph D. Sinnott**<sup>1</sup>, Michael Saunders<sup>2</sup>

<sup>1</sup>University Hospital Bristol and Weston, UK., <sup>2</sup>Bristol Royal Children's Hospital, UK.

*Facial Plastic surgery beyond the nose 1, Building M1 Room Σ3, Sept 27, 11:45*

**Background:** Severe Rhinophyma is a disfiguring abnormality which in the past has proved challenging to treat. Previous techniques such as cold steel removal and full thickness skin grafting or laser can leave unfavourable cosmetic outcomes. Coblation is a relatively new technique which can ablate tissues at lower temperatures,

**Methodology/Principal:** Small case series with preoperative, operative and postoperative clinical photographs to assess outcomes. Variety of cases performed under local and general anaesthetic. In some cases the technique was combined with cold steel techniques in order to obtain biopsy to rule out underlying malignancy.

**Results:** Clinical photographs show excellent outcomes from the procedure. Some of the procedures were performed as a 2 stage process due to very severe disease. Local anaesthetic procedures were tolerated extremely well and showed no obvious disadvantage in terms of outcomes in the operator's experience.

**Conclusions:** Coblation appears to be an effective, safe and simple technique for the cosmetic treatment of severe rhinophyma. Clinical photographs show the positive results in this small series. These results fit with the emerging literature of this novel use for this relatively new technology.

**Key words:** Coblation, rhinophyma, plastics

**Joseph D. Sinnott<sup>1</sup>**

<sup>1</sup>Royal United Hospitals, Bath, United Kingdom

*Miscellaneous 2, Building M1 Room Σ2, Sept 29, 11:45*

**Background:** Times of crisis and conflict can lead to great innovations and this was certainly seen within ENT departments across Europe in the COVID-19 pandemic. Innovation can be essential to overcome adversity but can increase risk. An acceptable level risk must be tolerated to allow innovation but this should be minimized and monitored. Traditional methods such as monthly mortality and morbidity meetings, incident reporting and Schwartz rounds are not effective during crisis. Mechanisms for maximising safety should be addressed before the next crisis.

**Methodology/Principal:** Within a medium sized UK hospital and ENT department, incident reporting and patient safety measures were recorded during height of the COVID 19 crisis and compared to the same period the year before the crisis. This included the number of Incident Reports (Datix) and Surveys of 205 staff. Questions relating to patient safety and reporting culture were taken directly from and compared to National Staff Survey (NSS) 2019 which acted as a base line.

**Results:** Reporting of errors using traditional methods decreased during crisis. Despite this staff felt an increase in psychological safety. Staff also felt more proud to be a healthcare working and there was increase positive morale towards the department and hospital in which they worked.

**Conclusions:** Traditional error and patient safety reporting systems such as Datix are not optimal during crisis. Innovation during crisis should not be prevented but other methods for error reporting should be developed to maximise safety and harness improvements. This is particular important as ENT departments where we worked at the forefront of the acute service. Other methods could include techniques borrowed from the military or emergency services such as debriefing, organisational learning and real time monitoring.

**Key words:** Safety, culture, management, COVID-19, pandemic

## Taste Dysfunction in Patients With COVID-19: A functional and Morphological Study-Preliminary Results.

**Pavlos Pavlidis**<sup>1</sup>, Afroditi Mpoutou<sup>2</sup>, Gregor Alexander Schitteck<sup>3</sup>, Efstathios Spyridonidis, Joulia Katsikari<sup>4</sup>, Haralampos Gouveris<sup>5</sup>

<sup>1</sup>ENT Clinic, Papanikolaou Hospital, Thessaloniki, Greece, <sup>2</sup>Pulmonary Department of Aristotle University of Thessaloniki, Thessaloniki, Greece, <sup>3</sup>Medical University of Graz, Division of General Anaesthesiology, Emergency- and Intensive Care Medicine, Graz, Austria, <sup>4</sup>Clinic of Internal Medicine, General Hospital Veria, Greece, <sup>5</sup>ENT Clinic, General Hospital Veria, Veria, Greece, <sup>6</sup>Department of Otorhinolaryngology, University Medical Centre Mainz, Mainz, Germany

*Smell and taste 2, Building M2 CR2, Sept 27, 14:45*

**Background:** Patients with COVID-19 often complain of smell and taste disorders (STD). STD emerge early in the course of the disease, seem to be more common in SARS-CoV-2 infection than in other upper respiratory tract infections, and could in some cases persist for long after resolution of respiratory symptoms. The aim of the present study was to find any possible morphological and functional changes of the oral mucosa in such patients.

**Methods:** Seventeen patients with COVID-19, who have been stationed, were prospectively examined. Electrogustometric (EGM) - thresholds at the tongue area supplied by the chorda tympani, at the soft palate and at the vallate papillae area were recorded bilaterally in both groups and were compared to those of 12 healthy individuals. Gustatory function was additionally tested with chemogustometry using taste strips at the anterior tongue third bilaterally. Morphology of the fungiform papillae (fPap) and blood vessels' density and morphology at the tip of the tongue were examined by contact endoscopy (CE). 17 healthy subjects have been used as control-group.

**Results:** Electrogustometric thresholds were significantly increased bilaterally at all six examined areas in all patients. Taste strips results were reduced bilaterally in both patient groups. Significant alterations in shape and vascularization of fPap were recorded bilaterally using CE in all patients.

**Conclusion:** Our evidence suggests that taste disorders probably result from a loss of function of taste buds, mainly caused by infection, inflammation, and subsequent dysfunction of supporting non-neuronal cells in the mucosa.

**Keywords:** COVID-19, Ageusia, electrogustometry, contact endoscopy, taste strips

### References

1. Wang Z, Yang B, Li Q, Wen L, Zhang R. Clinical features of 69 cases with coronavirus disease 2019 in Wuhan, China [manuscript published online ahead of print 16 March 2020]. Clin Infect Dis 2020; 71:769–77.
2. Huang C, Wang Y, Li X, et al. Clinical features of patients infected with 2019 novel coronavirus in Wuhan, China. Lancet 2020; 395:497–506 [erratum in: doi:10.1016/S0140-6736(20)30252-X].
3. Novel Coronavirus Pneumonia Emergency Response Epidemiology Team. The epidemiological characteristics of an outbreak of 2019 novel coronavirus diseases (COVID-19)—China, 2020. China CDC Wkly 2020; 2:113–22.
4. Hummel T, Landis BN, Hüttenbrink KB. Smell and taste disorders. GMS Curr Top Otorhinolaryngol Head Neck Surg 2011; 10:Doc04.
5. van Riel D, Verdijk R, Kuiken T. The olfactory nerve: a shortcut for influenza and other viral diseases into the central nervous system. J Pathol 2015; 235:277–87.



6. Netland J, Meyerholz DK, Moore S, Cassell M, Perlman S. Severe acute respiratory syndrome coronavirus infection causes neuronal death in the absence of encephalitis in mice transgenic for human ACE2. *J Virol* 2008; 82:7264–75.

**Objective:** The aim of this study was to perform a systematic review and meta-analysis of existing evidence on the role of hot saline irrigation (HSI) in patients undergoing functional endoscopic sinus surgery (FESS) and its impact on the visibility of the surgical field (VSF).

**Design:** A search of PubMed, Cochrane, Ovid (including Embase, Medline and Allied and Complementary Medicine Database) databases as well as Google Scholar was performed.

**Results:** Three randomised control trials (RCT) were included. All three were pooled into meta-analysis which demonstrated a statistically significant better VSF (MD -0.51; 95% CI -0.84, -0.18; P = 0.003), a reduction in total blood loss (TBL) (MD -56.40ml; 95% CI -57.30. -55.51; P = <0.0001) and a reduction in operating time (OT) (MD -7.01mins; 95% CI 9.02mins; 95% CI -11.76, -6.28; P = <0.0001) during FESS in the HSI group compared with the room temperature irrigation control group. Further subgroup analysis of studies that did not use topical vasoconstrictors showed a significant reduction in TBL and OT. There were no reported adverse events related to HSI.

**Conclusion:** This is the first systematic review that addresses HSI for haemostasis in FESS. The results suggest that HSI in FESS for chronic rhinosinusitis may significantly improve VSF, reduce TBL by 20% and decrease OT by 9 minutes. HSI is cheap and a readily available intervention with a low risk of morbidity and adverse events. However, there are limitations of the study due to significant heterogeneity of methods, quality, and size of the studies.

**Background:** A vast majority of previous studies have concluded that there is little correlation between subjective patient reported symptom outcome measures in chronic rhinosinusitis (CRS) and objective radiological scoring. Although it is generally accepted that both anxiety and depression impact on perceived symptom severity in CRS, previous studies have not divided patients into those who suffer with anxiety and depression and those who do not when analysing symptom scores against radiological staging.

**Methods:** A total of 100 patients with CRS were evaluated using the General Anxiety Disorder-7 (GAD-7), Patient Health Questionnaire-9 (PHQ-9) and Sino-nasal outcome test (SNOT-22) questionnaires as well as the Lund Mackay Computer Tomography Scoring (LMCTS) system.

**Results:** When analysing the group as whole, there was no correlation between SNOT-22 scores and LMCTS. However, in patients who do not suffer with anxiety and depression, there was a significant correlation between SNOT-22 and LMCTS scores ( $p=0.008$ ) using Spearman's Rank Correlation Coefficient. The Nasal domain of the SNOT-22 showed strongest correlation to LMCTS in this patient group. There was no correlation between SNOT-22 and LMCTS scores in patients with anxiety and depression. Patients with anxiety and depression reported significantly higher symptom severity when compared to patients without either co-morbidity.

**Conclusion:** This study has found that patients with anxiety and depression, which is highly prevalent in patients with CRS, may cause significantly increased symptom reporting and may account for the lack of correlation with radiological findings in previous studies. In patients without anxiety and depression there is strong correlation with radiological scoring.

## Topical intranasal fluorescein plays a significant role in the management of CSF leaks

**Anda Gâta<sup>1</sup>**, Silviu Albu<sup>1</sup>

<sup>1</sup>*Department of Otorhinolaryngology, University of Medicine and Pharmacy 'Iuliu Hațieganu', Cluj Napoca, Romania, 400349;*

*CSF leaks and management 1, Building M1 Room Σ2, Sept 27, 10:15*

**Background:** Endoscopic repair of CSF leaks has shown success rates of over 95%. Exact identification of the CSF leak is the foundation for successful surgery. Localization of dural defects has become more precise with modern techniques, but there is still place for improvement. The present study aims to evaluate the benefit of topical fluorescein in endoscopic closure of CSF leaks.

**Methods:** We retrospectively reviewed data of patients with CSF leaks between 2013 and 2020. Success rates were compared before and after 2017, when we included topical fluorescein in the CSF leaks protocol. Multilayer closure technique using autologous materials was employed, and has remained unchanged throughout the period.

**Results:** Twenty-nine patients underwent closure of CSF leaks until 2017, with 16 traumatic etiologies, 9 spontaneous and 4 iatrogenic. Success rate was 93,1%, with 2 patients presenting recurrence. After 2017, twenty- six patients were treated for CSF leaks, 17 being traumatic, 7 spontaneous and 2 iatrogenic. Success rate after including topical fluorescein in diagnosis and treatment protocol increased to 100%, with no recurrences over 26 months mean follow-up (range 6-72months).

**Conclusion:** Topical fluorescein is a safe and effective adjunct for pre- and postoperative diagnosis of CSF leaks, as well as intraoperative localization.

**Key words:** CSF leak, topical fluorescein, skull base surgery

### Literature

1. Barr J, Ni J, McGinn J, Goyal N. Topical intranasal fluorescein to localize a cerebrospinal fluid leak: a demonstration. *Am J Otolaryngol.* 2020;41(6):102413.
2. Cha HG, Kwon JG, Kim EK. Intraoperative Detection of Leakage Using Topical Fluorescein Following Free Flap Inset in Head and Neck Reconstruction. *J Craniofac Surg.* 2019;30(4):e333-e5.
3. Eren E, Güvenç G, İşlek A, Arslanoğlu S, Önal K, Yüceer N. Is topical fluorescein that effective in endoscopic CSF leak closure? *Eur Arch Otorhinolaryngol.* 2020;277(4):1073-7.
4. Liu HS, Chen YT, Wang D, Liang H, Wang Y, Wang SJ, et al. The use of topical intranasal fluorescein in endoscopic endonasal repair of cerebrospinal fluid rhinorrhea. *Surg Neurol.* 2009;72(4):341-5; discussion 6.
5. Ozturk K, Karabagli H, Bulut S, Egilmez M, Duran M. Is the use of topical fluorescein helpful for management of CSF leakage? *Laryngoscope.* 2012;122(6):1215-8.
6. Saafan ME, Ragab SM, Albirmawy OA. Topical intranasal fluorescein: the missing partner in algorithms of cerebrospinal fluid fistula detection. *Laryngoscope.* 2006;116(7):1158-61.

## Self-assembling peptides (PuraStat) contribute to haemostasis and adhesion prevention in functional endoscopic sinus surgery

**Maurice Bagot d’Arc<sup>1</sup>**, Claudia Delin<sup>2</sup>, Yael Friedland<sup>3</sup>, Jennifer F Ha<sup>4,5,6</sup>

<sup>1</sup>M. Bagot d’Arc, ENT specialist, BluePharm SAS, 17 rue Davioud 75016 Paris, France, <sup>2</sup>C. Delin, Methodologist, BluePharm SAS, 17 rue Davioud 75016 Paris, France, <sup>3</sup>Y. Friedland, ENT registrar, Department of Otolaryngology, Fiona Stanley Hospital, 11 Robin Warren Dr, Murdoch WA 6150, Western Australia, Australia, <sup>4</sup>J. Ha, MBBS, FRACS, ENT consultant, SJOG Hospital Murdoch, Wexford Medical Center, Suite 17-18, Level 1, 3 Barry Marshall Parade, Murdoch 6150, Western Australia, Australia, <sup>5</sup>J. Ha, MBBS, FRACS, ENT consultant, Department of Paediatrics Otolaryngology Head & Neck Surgery, Perth Children’s Hospital, 15 Hospital Avenue, Nedlands 6009, Western Australia, Australia, <sup>6</sup>J. Ha, MBBS, FRACS, ENT consultant, Department of Surgery, University of Western Australia, Stirling Highway, Nedlands 6009, Western Australia, Australia

CRS - surgical management 4, Building M1 Room Σ2, Sept 29, 10:15

**Background:** Functional endoscopic sinus surgery (FESS) is a treatment option for patients with chronic rhinosinusitis who have failed maximal medical therapy. Haemostasis is crucial to prevent postoperative complications, such as bleeding and adhesion formation<sup>1,2</sup>. PuraStat is a haemostatic solution composed of synthetic self-assembling peptides forming a solid matrix on exposure to blood<sup>3</sup>. This study aimed to assess the efficacy of PuraStat in FESS to achieve haemostasis and prevent adhesions.

**Methodology/Principal:** A retrospective chart review was performed on 95 consecutive patients undergoing FESS, using PuraStat in the absence of nasal packing.

**Results:** Of the 95 cases (39 males and 56 females with ages 18-83 years), 28 cases underwent full FESS and 67 cases limited FESS. Most of them (92/95) also underwent septoplasty and/or turbinate reduction. Six patients had bleeding in the postoperative period (6.32%), of which four required additional treatment (4.21%). The haemostatic efficacy rate was 95.78%.

Regarding adhesions, 90 patients were found to have no adhesions or adhesions that were easily removed by suction in the immediate postoperative period. The efficacy of PuraStat in adhesion prevention was 94.73%. No patients required revision surgery.

**Conclusions:** PuraStat was found to be effective in FESS in achieving haemostasis and preventing adhesions.

**Key words:** Provide up to 5 key words using Mesh terms for indexing purposes

Self-Assembling peptides, PuraStat, FESS, haemostasis, surgical management rhinosinusitis

### Literature

1. Weber RK, Hosemann W. Comprehensive review on endonasal endoscopic sinus surgery. *GMS Curr Top Otorhinolaryngol Head Neck Surg*. 2015 Dec 22;14:Doc08. doi: 10.3205/cto000123. eCollection 2015.
2. Antidel JL, Meyer A, Comer B, et al. Product comparison model in otolaryngology: Equivalency analysis of absorbable hemostatic agents after endoscopic sinus surgery. *Laryngoscope*. 2016 Jan;126 suppl2 :S5-13. Doi : 10.1002/lary.25678. Epub 2015 Oct 28
3. PuraStat Instructions For Use, 3D Matrix Medical Technology, Caluire et Cuire, France, IFU-002 Rev 1.2 2019/04



## Covid-19 outbreak: does the use of a surgical mask impact the sense of smell?

Clémentine Hyvrard<sup>1,2</sup>, Margaux Petitjean<sup>1,2</sup>, Maxime Fieux<sup>3,6,7</sup>, Françoise Zerah<sup>4,6,7</sup>, André Coste<sup>1,2,5,6,7</sup>, **Sophie Bartier<sup>1,2,5,6,7</sup>**

<sup>1</sup> Service d'ORL et de chirurgie cervico-faciale, Centre Hospitalier Intercommunal de Créteil, 94000 Créteil, France, <sup>2</sup> Service d'ORL et de chirurgie cervico-faciale, AP-HP, Centre Hospitalier Universitaire Henri Mondor, 94000 Créteil, France, <sup>3</sup> Hospices Civils de Lyon, Centre Hospitalier Lyon Sud, Service d'ORL, d'otoneurochirurgie et de chirurgie cervico-faciale, France, Pierre Bénite cedex F-69495, <sup>4</sup> Service de pneumologie, AP-HP, Centre Hospitalier Universitaire Henri Mondor, 94000, Créteil, France, <sup>5</sup> Université Paris-Est Créteil (UPEC), Ecole de Médecine, 94000 Créteil, France, <sup>6</sup> INSERM U955, 94000 Créteil, France, <sup>7</sup> CNRS, ERL 7240, 94000 Créteil, France

*Smell and taste 3, Building M2 CR3, Sept 27, 14:45*

**Background:** The current context of the Severe Acute Respiratory Syndrome Coronavirus-2 (SARS-CoV-2) pandemic has broadened surgical mask use. Our objective was to evaluate the impact of wearing a surgical mask on sense of smell by comparing the results of an olfactometry (sniffin' sticks test (SST)) with and without a surgical mask.

**Methodology:** We designed a crossover prospective comparative study between 2 groups of healthy volunteers. The results of SST with a mask were compared to the results without a mask: group 1 first performed SST with a surgical mask and then one week later performed SST without a mask, while group 2 started without a mask.

**Results:** 20 volunteers were included. In group 1 and 2, all the subjects, except one, had a significantly better total score (TDI) without a mask. The average standard deviation for the TDI score with and without a mask, was inferior to 5. 8/20 (40%) subjects had a TDI difference superior to 5 with and without mask, while 4/20 (20%) were normosmic without a mask, while being recategorized as hyposmic with a mask.

**Conclusions:** The present study shows that wearing a surgical mask does significantly decrease the sense of smell, in a cohort of young normosmic patients.

**Keywords:** anosmia; Covid-19; face mask; olfactometry; SARS-CoV-2; sniffin' sticks test.

## Mucormycosis of the nose and paranasal sinuses, a new challenging infection in post COVID-19 patients.

**Alfred Aga**<sup>1</sup>, Guardmond Ajsllari<sup>1</sup>, Artur Xhumari<sup>1</sup>

<sup>1</sup>ENT Department, American Hospital Tirana, Albania

*Miscellaneous 1, Building M1 Room Σ1, Sept 28, 11:45*

**Background:** Covid-19 pandemic has increased the susceptibility to rare fungal infections, such as mucormycosis which has a poor prognosis and a high mortality rate ranging from 20% to 50% in case of diagnostic and treatment delay.

**Methodology:** We conducted an analysis of three post Covid-19 patients who presented in our hospital in the span of 4 months from November 2020 to February 2021 (during the second wave). The diagnosis of mucormycosis required a thorough analysis of the combination of many meaningful findings such as clinical evaluation, nasoendoscopy, imaging such as MRI and CT and the biopsy. All the patients required endoscopic approach for the removal of the necrotic tissue.

**Results:** All three patients, two female and one male, aged respectively 65, 68 and 74 years old, developed rhino-orbital invasive mucormycosis. All of them were previously hospitalized for management of moderate Covid-19 infection. After the diagnosis was established, the patients underwent endoscopic sinus debridement, with two of the patients requiring orbital exenteration. As a result of tempestive treatment with aggressive surgery they are alive and free of disease.

**Conclusion:** This case series analysis confirms how early and aggressive endoscopic debridement of the paranasal sinuses and the involved adjacent tissue, improves the overall prognosis, and helps preventing further spread of the disease and severe complications associated to high mortality rate such as rhinocerebral mucormycosis.

**Key words:** Mucormycosis, Covid-19, Endoscopic sinus surgery,



## A case study of orbital complications due to sinusitis

**Venelin Marinov**, Orlin Stoyanov

*Department of E.N.T. Head and neck surgery, University hospital "Queen Joanna-ISUL", Sofia, Bulgaria*

*Paediatric rhinology 2, Building M2 CR3, Sept 28, 11:45*

**Background;** This is a retrospective case of an untreated 7-year old patient diagnosed with orbital involvement due to acute infective sinusitis, who presented to the emergency E.N.T room of University Hospital "Queen Joanna-ISUL".

**Methodology and results;** The major complaints consisted of nasal secretions, malaise, persistent headache and eye closure. The E.N.T examination revealed a purulent nasal secretion combined with a noticeable eyelid edema and local hyperthermia. The X-ray was followed by a contrasted CT scan both confirming the presence of a pansinusitis and a suprabulbar purulent collection, causing a prominent exophthalmus. The blood work showed a considerable leukocytosis with neutrophilia. The patient was hospitalized and put on antibiotic i.v. drip as the surgical team prepared for an evacuation of the abscess cavity under a general anesthesia. The rapid reaction led to a full recovery of the patient with no consequent eye damage.

**Conclusion:** The proximity of the eye to nose and paranasal sinuses is an anatomical predisposition for direct extension of an inflammatory process. This could cause a serious threat to the function of the eye or present a life-threatening situation such as thrombosis of sinus cavernosus. This underlines the importance of a rapid response and emergency procedures.

**Key words:** E.N.T, sinusitis, orbital complications, surgical, abscess

Literature:1. Welkoborsky HJ, Graß S, Deichmüller C, Bertram O, Hinni ML. Orbital complications in children: differential diagnosis of a challenging disease. *Eur Arch Otorhinolaryngol.* 2015 May;272(5):1157-63. doi: 10.1007/s00405-014-3195-z. Epub 2014 Jul 24. PMID: 25056021.

2. *Essential otolaryngology* 10th edition ISBN 978-0-07-1761447-5

3. *Otorhinolaryngology* D.Dimov and G.Georgiev 1<sup>st</sup> edition ISBN 954-621-039-0

## Posterior epistaxis management in the United Kingdom. A national survey.

Andrew J. Mowat<sup>1</sup>, Philip Meakin<sup>1</sup>, **Sofia Anastasiadou**<sup>1</sup>, Rohan Bidaye<sup>1</sup>, Shahram Anari<sup>1</sup>

<sup>1</sup>*Department of Otolaryngology, University Hospitals Birmingham, United Kingdom*

*Epistaxis and HHT 1, Building M1 Room Σ4, Sept 28, 11:45*

**Background:** Posterior bleeds account for 5% of epistaxis. The patient cohort is often elderly and has significant co-morbidities. Such cases have been managed historically with urinary catheters, held in place with umbilical clips. Recently bespoke, double balloon, posterior packs have been utilised. The treatments remain in clinical equipoise with no gold standard or clear national guideline.

**Methodology:** A ten question survey was sent out through [www.surveymonkey.com](http://www.surveymonkey.com). Attempts were made to contact all Trusts in the United Kingdom via the ENT on call service. A comparison of treatment costs was made.

**Results:** 112 response have been received. 54% of respondents reported a preference for bespoke posterior pack insertion, only 12% preferred catheters. Twice as many respondents have seen complications from urinary catheters: 14% vs 29%. The availability of posterior packs is inconsistent: 30% of respondents were not aware of the packs or reported them unavailable in their trust.

**Conclusions:** This survey provides the first comparison of the techniques in the United Kingdom. Bespoke packs have a lower complication rate and are preferred by ENT clinicians on the front line of patient care. We recommend that all UK trusts should stock posterior packs which should be used as first line treatment for cases of posterior epistaxis.

**Key words:** Epistaxis, Catheters

## Development of a New Device for Postoperative Self-Irrigation of the Maxillary and Frontal Sinus

**M. ALOMANI**<sup>1</sup>, M. Crepy-Ameil<sup>1</sup>, J. Grinholtz-Haddad<sup>1</sup>, S. Zaer<sup>1</sup>, H. BENKHATAR<sup>1</sup>

<sup>1</sup>Centre Hospitalier de Versailles, ENT & head and neck surgery , Le Chesnay, France

*Rhinology – miscellaneous 3, Building M1 Room Σ1, Sept 27, 11.45*

**Background:** Nasal saline irrigation is the corner stone of postoperative care after functional endoscopic sinus surgery for chronic rhinosinusitis. However, intrasinus penetration of the saline solution can be challenging, particularly for the frontal sinus. Our aim was to evaluate a novel device for direct intrasinus self-irrigation, usable at home for both maxillary and frontal sinus.

**Methodology:** Thirty devices were implemented in 23 patients: in the maxillary sinus for 18 patients and in the frontal sinus for 5 patients. The device was removed after 7 days, and nasal saline irrigation was carried on with a squeeze bottle for 6 weeks. Retrospective evaluation of the device included: device-related complication, patient satisfaction, and ostial or middle turbinate synechiae at 3 months

**Results:** No device-related complication occurred. Twenty-one (91.3%) patients were satisfied with the device. Two patients required the help of a nurse for irrigation. No ostial or middle turbinate synechiae was visualized at 3 months. This new endonasal device enables direct intrasinus self-irrigation after FESS for CRS.

**Conclusions:** This preliminary study showed that this device is safe and easy to use. However, further investigations are required to assess its potential role to reduce the risk of synechiae and revision surgery.

**Key words:** sinus surgery, postoperative care, sinus irrigation, chronic rhinosinusitis, frontal sinus, maxillary sinus

## The intra-operative use of biological products – a consenting conundrum?

Jolly, K<sup>1</sup>., **Bhamra, N<sup>1</sup>.**, Darr, A<sup>1</sup>., Aslanidou, A<sup>2</sup>., Bowyer, D<sup>3</sup>., Ahmed. SK<sup>2</sup>.

<sup>1</sup>Department of Otolaryngology, The Royal Wolverhampton NHS Trust, UK. , <sup>2</sup>Department of Otolaryngology, University Hospitals Birmingham NHS Trust, UK., <sup>3</sup>Department of Otolaryngology, Shrewsbury and Telford Hospitals NHS Trust, UK.

*Rhinology – miscellaneous 3, Building M1 Room Σ1, Sept 27, 11:45*

**Background:** The use of biological products in surgery is on the increase with limited awareness amongst patients and surgeons of the origins of the products which are being used.

**Methodology/Principal:** Questionnaires were distributed to patients in three otolaryngology departments in the West Midlands, UK collecting demographic data including religion and dietary beliefs to assess potential motives for the intra-operative use of biological materials. A further survey was distributed amongst UK based registrars, specialist associates/staff grades and consultants working within various surgical specialties assessing their knowledge of biological products as well as their consenting habits. This was tailored to each cohort reflecting commonly used products in that specialty.

**Results:** Amongst patients, 44% of our study population want to know if biological products are used in their surgery, with 17% objecting to their use. Amongst surgeons, we found that 68% of our study population do not routinely consent to the use of biological products and 74% felt that further education is required for clinicians in this area.

**Conclusions:** Lack of knowledge amongst clinicians and lack of routine consent for the use of biological products intra-operatively can not only conflict with a patient's religious, personal and/or ethical beliefs but also potential legal implications.

**Key words:** Biological products, consent, education, surgery

## Tapia's Syndrome: An Unexpected Complication of Rhinoplasty

**GULIGA Alexandra<sup>1</sup>**

<sup>1</sup>*University Hospital of Marseille, France*

*CRS - diagnosis and investigations 3, Building M1 Room Σ4, Sept 29, 10:15*

Tapia syndrome is a rare condition caused by involvement of the recurrent nerve and the hypoglossal nerve, which affects the vocal fold and ipsilateral hemi-tongue.

Although Tapia's syndrome after rhinoplasty appears to be rare, it should be considered. We report the case of a 53-year-old patient who develop a Tapia syndrome after an orotracheal intubation during general anesthesia for rhinoseptoplasty.

A review of the literature will allow us to trace the diagnosis and therapeutic management for this syndrome, with particular attention to the role of the professional team in the evaluation and treatment of this complication.

**Keywords:** rhinoseptoplasty, Tapia syndrome, general anesthesia, nerve palsy, rhinoplasty complication

## Sinonasal b-cell lymphomas – A Nationwide Retrospective study on subtypes, demographics, and prognosis.

**Patrick RG Eriksen**<sup>1</sup>, Erik Clasen-Linde<sup>2</sup>, Peter de Nully Brown<sup>3</sup>, Laura Haunstrup<sup>4</sup>, Mette Christoffersen<sup>5</sup>, Peter Asdahl<sup>6</sup>, Troels Møller Thomsen<sup>7</sup>, Steffen Heegaard<sup>8</sup>, Christian von Buchwald<sup>1</sup>

<sup>1</sup>Department of Otorhinolaryngology, Head and Neck Surgery and Audiology, Rigshospitalet, University of Copenhagen, Copenhagen, Denmark, <sup>2</sup>Hematopathology Section, Department of Pathology, Rigshospitalet, University of Copenhagen, Copenhagen, Denmark, <sup>3</sup>Department of Hematology, Rigshospitalet, University of Copenhagen, Copenhagen, Denmark, <sup>4</sup>Department of Hematology, Aalborg University Hospital, Aalborg, Denmark, <sup>5</sup>Department of Hematology, Odense University Hospital, Odense, Denmark., <sup>6</sup>Department of Hematology, Aarhus University Hospital, Aarhus, Denmark., <sup>7</sup>Department of Hematology, Holstebro Hospital, Holstebro, Denmark, <sup>8</sup>Eye Pathology Section, Department of Pathology, Rigshospitalet, University of Copenhagen, Copenhagen, Denmark

*Sinonasal malignancy 4, Building M1 Room Σ4, Sept 27, 14:45*

**Background:** Lymphomas of the nasal cavity and paranasal sinuses are rare. To create high-quality evidence, we have characterized all attainable sinonasal b-cell lymphomas (SNBCL) in Denmark during the last 38 years, focusing largely on primary sinonasal diffuse large b-cell lymphoma (PSN-DLBCL).

**Methodology/Principal:** This is a nationwide retrospective study of all Danish patients registered from 1980 until 2019. All tissue samples were collected, and the diagnosis was validated. Survival statistics were used to determine clinical- and demographic covariates predictive of mortality.

**Results:** We included 205 patients and found ten different histological subtypes of lymphoma. The incidence of SNBCL was 0.14/100,000 person-years (0.6% of all non-Hodgkin lymphomas). The most common site was the nasal cavity (37%) and maxillary sinuses (33%). Congestion was the most common symptom. When treated with immunochemotherapy 5-year overall survival of PSN-DLBCL was 73%, and progression-free survival was 69%. Rituximab showed a statistically significant reduction in hazard of death of 65%. No effect of adjunct radiotherapy was found.

**Conclusions:** Many different subtypes of lymphoma can affect the nasal cavity and paranasal sinuses. Sinonasal lymphomas account for a larger portion of all lymphomas than previously thought. Treatment with Rituximab showed great benefit for patients with PSN-DLBCL, while the effect of adjunct radiotherapy is questionable.

**Key words:** Lymphoma, Paranasal neoplasms, Nose Neoplasms, Rituximab, Radiotherapy

## The Use of Auricular Cartilage Grafts in Septorhinoplasty: A Novel Dual Centre Study of Donor Site Patient Reported Outcome Measures

Kumar, R.<sup>1</sup>, Darr, A.<sup>1</sup>, Gill, C.<sup>2</sup>, **Bhamra, N.<sup>1</sup>**, Mistry, N.<sup>3</sup>, Barraclough, J.<sup>1</sup>

<sup>1</sup>Department of Otolaryngology, The Royal Wolverhampton NHS Trust, UK, <sup>2</sup>Department of Otolaryngology, The Dudley Group NHS Foundation Trust, UK. , <sup>3</sup>Department of Otolaryngology, Gloucestershire Hospitals NHS Foundation Trust, UK.

*Rhinoplasty 1, Building M2 CR1, Sept 29, 14.45*

**Background:** The use of autologous grafts for structural and functional applications is a key aspect of contemporary septorhinoplasty. Our study is the first, to our knowledge, assessing donor site patient reported outcome measures (PROMs) where auricular cartilage has been harvested for use in septorhinoplasty.

**Methodology/Principal:** A dual centre, single-surgeon retrospective analysis of patients undergoing septorhinoplasty surgery with augmentation using auricular cartilage grafts was conducted. Donor site outcomes were assessed across several physical and psychological domains by adapting the EAR-Q questionnaire developed by Klassen et al, which was administered by two independent investigators via telephone consultation.

**Results:** A total of 22 patients were met our inclusion criteria. Four were lost to follow-up, 5 were non-responders, and 1 case was excluded due to documentation of body dysmorphic disorder. A significant proportion of patients reported no reduction in quality of life (QOL) or confidence attributed to donor site cosmesis. High satisfaction was noted with anti-helical donor site scars.

**Conclusions:** Preliminary results suggest high levels of patient satisfaction, with minimal physical and psychological donor site sequelae following auricular cartilage harvest in septorhinoplasty. Subsequent studies should involve the use of validated questionnaires, coupled with larger patient cohorts to provide further data for statistical analysis.

**Key words:** Auricular cartilage, graft, septorhinoplasty, nasal reconstruction.

## Safety of a New Sinus Irrigation Device in Rhinosinusitis: A Pilot Study

**Tali Teitelbaum<sup>1</sup>**, Isaac Shochat<sup>1</sup>, Howard Levine<sup>2</sup>, Izhak Braverman<sup>1</sup>.

<sup>1</sup>Otolaryngology, Head & Neck Surgery Department, Hillel Yaffe Medical Center, Hadera, Israel., <sup>2</sup>Cleveland nasal sinus & sleep center, head and neck institute, The Cleveland clinic, OH, USA.

*Acute Rhinosinusitis 1, Building M1 Room Σ1, Sept 27, 10.15*

**Background:** Puncture and lavage of the paranasal sinuses for unresponsive acute rhinosinusitis (ARS) have been abandoned due to procedural discomfort and advancements in antibiotic efficacy and endoscopic sinus surgery (ESS). The rise in antibiotic-resistant bacteria has renewed the interest in minimally invasive sinus lavage to avoid aggressive surgical interventions and identify appropriate antibiotic therapy. We describe the safety and feasibility of a new device and evaluate its efficacy as a treatment before the traditional ESS in ARS.

**Methodology:** The device with its seeker-shaped guiding tube and rotating wire can enter the sinus cavity through the natural ostium, pulverize the inspissated mucus, and enable lavage and culture sampling. It was tested in six patients with chronic sinusitis under general anesthesia during ESS and in additional ten patients with maxillary ARS in outpatient settings under local anesthesia.

**Results:** Overall, nine of ten patients with ARS demonstrated remarkable improvements and were discharged the following day without acute symptoms. The visual analog scale score for pain dropped from 8.9 to 0.4. The remaining one patient underwent ESS subsequently. None of the patients treated during ESS developed any adverse events.

**Conclusions:** The new sinusafe<sup>®</sup> device might offer an alternative to surgical treatment for non-responsive ARS.

**Key words:** rhinosinusitis, acute maxillary sinusitis, trephination, sinus lavage, endoscopic surgery



## Treatment of intracranial skull base lesions in children via transnasal endoscopic approach

**Inês Chang Mendes<sup>1</sup>**, Amets Sagarribay<sup>2</sup>, Herédio Sousa<sup>1</sup>, Ezequiel Barros<sup>1</sup>

<sup>1</sup>Otolaryngology department, Centro Hospitalar Universitário Lisboa Central, Lisbon, Portugal., <sup>2</sup>Neurosurgery department, Centro Hospitalar Universitário Lisboa Central, Lisbon, Portugal.

*Skull base surgery 2, Building M2 CR3, Sept 29, 14.45*

**Background:** the transnasal endoscopic approach to skull base lesions in children is a valuable and evolving technique becoming increasingly common as an alternative to traditional open methods. The authors present their experience.

**Methodology:** a retrospective review of pediatric patients who underwent transnasal endoscopic approach from 2012 to 2020. All operations were performed by a team of pediatric otolaryngologists and neurosurgeons.

**Results:** a total of 10 patients were submitted to a transnasal endoscopic approach for skull base lesions. Eight patients were male and the mean age at surgery was 10.5 years-old (range 3-16 year-old). Skull base tumors included craniopharyngiomas (n=4), dermoid cysts (n=2), pituitary adenoma (n=1) and Langerhans cell histiocytosis (n=1). Bony lesions included a skull base defect (n=1) and basilar invagination (n=1). Gross-total resection was primarily achieved in all skull base tumors, with one subsequent recurrence. One patient required two additional interventions for a cerebrospinal fluid leak. Five patients received hormonal therapy and one received chemotherapy.

The length of hospital stay ranged from 8 to 71 days and the mean follow-up time was 47 months.

**Conclusions:** the transnasal endoscopic approach has proved to be a safe, effective and minimally invasive technique for a variety of pediatric skull base pathologies.

**Key words:** endoscopy, transnasal approach, skull base lesion, pediatric, surgical outcomes

## Mepolizumab improves health related quality of life for patients with chronic rhinosinusitis with nasal polyps: data from the SYNAPSE study

**Joseph Han**<sup>1</sup>, Stella E. Lee<sup>2</sup>, Maggie Tabberer<sup>3\*</sup>, Andrew Trigg<sup>4</sup>, Wytske Fokkens<sup>5</sup>, Robert Naclerio<sup>6</sup>, Phillipe Gevaert<sup>7</sup>, Ana R. Sousa<sup>2</sup>, Peter Howarth<sup>8</sup>, Bhabita Mayer<sup>9</sup>, Steve Yancey<sup>10</sup>, Robert H Chan<sup>2</sup>

<sup>1</sup>Eastern Virginia Medical School, Norfolk, VA, USA; <sup>2</sup>Department of Otolaryngology, University of Pittsburgh, Pittsburgh, PA, USA; <sup>3</sup>Respiratory Patient Centered Outcomes, Value Evidence and Outcomes GSK, GSK House, Brentford, Middlesex, UK; <sup>4</sup>Patient-Centred Outcomes, Adelphi Values, Bollington, Cheshire, UK; <sup>5</sup>Department of Otolaryngology, University of Amsterdam, Amsterdam, the Netherlands; <sup>6</sup>John Hopkins School of Medicine, Baltimore, MD, USA; <sup>7</sup>Department of Otorhinolaryngology, Ghent University, Ghent, Belgium; <sup>8</sup>Global Medical Affairs, GSK, Brentford, Middlesex, UK; <sup>9</sup>Clinical Statistics, GSK, GSK House, Brentford, Middlesex, UK; <sup>10</sup>Respiratory Therapeutic Area, GSK, Research Triangle Park, NC, USA

*CRS - outcome assessment 2, Building M1 Room Σ1, Sept 28, 10.15*

**Background:** To report efficacy of 4-weekly add-on mepolizumab 100mg SC on health-related quality of life (HRQoL) in adults with Chronic Rhinosinusitis with Nasal Polyps (CRSwNP).

**Methodology/Principal:** Details of SYNAPSE (NCT03085797) are previously reported. HRQoL was measured every 4 weeks using SinoNasal Outcome Test. Blinded psychometric analysis of SYNAPSE data and prior qualitative research in patients with CRSwNP confirmed domain structure and meaningful within-patient change thresholds.

**Results:** Psychometric analyses support a six-domain solution: nasal, ear/facial and non-nasal symptoms, fatigue, impact on sleep, and emotional impact supporting validity of a total score. A -28-point threshold was defined using anchor-based methods and supported by distribution-based methods. Although greater than previously published thresholds, this value is supported by qualitative patient research. Least squares mean change from baseline (standard error) total score at Week 52: -29.5 (SE1.62) for mepolizumab and -15.6 (SE1.65) for placebo, with 54% and 32% responders respectively (post-hoc analyses). Odds ratio of response: 2.66 (95%CI: 1.75,4.04), favouring mepolizumab. Change from baseline in all domain scores was approximately twice as large for mepolizumab versus placebo, with similar improvements across all domains.

**Conclusions:** Mepolizumab significantly and meaningfully improves HRQoL in CRSwNP.

**Funding:** GSK [ID:205687/NCT03085797]. Previously presented at AAAAI 2021. [J Allergy Clin Immunol. 2021;147(2, Supplement):AB125].

**Key words:** Mepolizumab, Nasal Polyps, Quality of Life

## Retrospective analysis of Osseous and Osteocutaneous Free Flaps results in head and neck reconstructive surgery

**Marta Melo**<sup>1</sup>, Ricardo Pacheco<sup>2</sup>; Pedro Montalvão<sup>2</sup>; Miguel Magalhães<sup>2</sup>

<sup>1</sup>Hospital Professor Doutor Fernando Fonseca, Lisbon, Portugal <sup>2</sup>Instituto Português de Oncologia de Lisboa Francisco Gentil, Lisbon, Portugal

*Facial Plastic surgery beyond the nose 1, Building M1 Room Σ3, Sept 27, 11.45*

**Background:** The use of osseous and osteocutaneous free flaps(OCFF) in head and neck reconstructive surgery improves the quality of life and reduces surgical morbidity, as in cases of mandibular or maxillary resection. The aim of our study is to access the results of OCFF, complications and associated factors.

**Methodology/Principal:** Retrospective analysis of patients submitted to OCFF for mandibular or maxillary reconstruction between 2015 and 2020. Evaluation of epidemiological data, pre- and post-operative therapy, surgical technique, success rate and complications.

**Results:** Sixteen patients were evaluated, with a mean age of  $50.3 \pm 17.4$  years and 62.5% male. Nine free flaps from the fibula and seven from the scapula were performed, viable in 93.8% of the cases. Cases associated with malignant neoplasia were 75%. The mean follow-up time was  $26.3 \pm 19.1$  months. The functional result was successful in 81.2% of cases. Record of 2 major early complications, one hemorrhagic and one requiring flap resection. The most common late complications were infection (18,8%) and extrusion of the osteosynthesis material (12,5%). The diagnosis of malignant neoplasm and osteonecrosis prior to reconstructive surgery were factors associated with complications.

**Conclusions:** OCCF have high surgical and functional success rates, with a good long-term viability in head and neck reconstructive surgery.

**Key words:** Free Tissue Flaps, Fibula, Scapula, Complications

### Literature

- 1 - Swendseid B, Kumar A, Sweeny L, Wax MK et al, Long-Term Complications of Osteocutaneous Free Flaps in Head and Neck Reconstruction, Otolaryngol Head Neck Surg . 2020 May;162(5):641-648
- 2 - Crawley MB, Sweeny L, Ravipati P, Heffelfinger R et al, Factors Associated with Free Flap Failures in Head and Neck Reconstruction. Otolaryngol Head Neck Surg. 2019 Oct;161(4):598-604
- 3 - Meghan B Crawley, Larissa Sweeny, Prasanti Ravipati, Ryan Heffelfinger et al, Factors Associated with Free Flap Failures in Head and Neck Reconstruction, Otolaryngol Head Neck Surg. 2019 Oct;161(4):598-604

## Mepolizumab reduces disease symptoms for patients with chronic rhinosinusitis with nasal polyps: Data from the SYNAPSE study

**Valerie Lund**<sup>1</sup>, Maggie Tabberer<sup>2\*</sup>, Andrew Trigg<sup>3</sup>, William Busse<sup>4</sup>, Jason Lee<sup>5</sup>, Claus Bachert<sup>6</sup>, Brent Senior<sup>7</sup>, Kathleen M. Buchheit<sup>8</sup>, Zuzana Diamant<sup>9,10,11</sup>, Ana R. Sousa<sup>12</sup>, Steven G. Smith<sup>13</sup>, Bhabita Mayer<sup>14</sup>, Steve Yancey<sup>13</sup>, Robert H. Chan<sup>15</sup>

<sup>1</sup>Royal National Throat, Nose and Ear Hospital, UCLH, London, UK; <sup>2</sup>Respiratory Patient Centered Outcomes, Value Evidence and Outcomes, GSK, GSK House, Brentford, Middlesex, UK; <sup>3</sup>Patient-Centered Outcomes, Adelphi Values, Bollington, Cheshire, UK; <sup>4</sup>Department of Medicine, University of Wisconsin School of Medicine and Public Health, Madison, WI, USA; <sup>5</sup>Toronto Allergy and Asthma Centre, Evidence Based Medical Educator, Toronto, ON, Canada and University of Kansas Medical Center, Kansas City, KS, USA; <sup>6</sup>Upper Airways Research Laboratory and Department of Oto-Rhino-Laryngology, Ghent University and Ghent University Hospital, Ghent, Belgium and Division of ENT Diseases, CLINTEC, Karolinska Institute, University of Stockholm, Stockholm, Sweden; <sup>7</sup>UNC Otorhinolaryngology/Head and Neck Surgery, Division of Rhinology, Allergy, and Endoscopic Skull Base Surgery and Department of Neurosurgery, University of North Carolina School of Medicine, Chapel Hill, NC, USA; <sup>8</sup>Division of Allergy and Clinical Immunology, Brigham and Women's Hospital, MA, USA; <sup>9</sup>Department of Microbiology Immunology & Transplantation, KU Leuven, Catholic University of Leuven, Leuven, Belgium; <sup>10</sup>Department of Clinical Pharmacy & Pharmacology, UMCG, Groningen, the Netherlands; <sup>11</sup>Respiratory Medicine and Allergology, Skane University, Lund, Sweden; <sup>12</sup>Respiratory Therapy Unit, GSK, GSK House, Brentford, Middlesex, UK; <sup>13</sup>Respiratory Therapeutic Area Unit, GSK, Research Triangle Park, NC, USA; <sup>14</sup>Clinical Statistics, GSK, GSK House, Brentford, Middlesex, UK; <sup>15</sup>Clinical Sciences, GSK R&D, GSK House, Brentford, Middlesex, UK.

\*At the time of the study

*CRS - outcome assessment 2, Building M1 Room Σ1, Sept 28, 10.15*

**Background:** Co-primary endpoints assessing efficacy of 4-weekly add-on mepolizumab 100mg SC on patient-reported symptoms of Chronic Rhinosinusitis with Nasal Polyps (CRSwNP) have been previously reported.

**Methodology/Principal:** SYNAPSE (NCT03085797), a randomised, double-blind, placebo-controlled, multicentre, 52-week study, enrolled 407 highly symptomatic patients with CRSwNP uncontrolled by previous surgery, treated with intranasal corticosteroids. Nasal Obstruction, Nasal Discharge, Mucus in Throat, Loss of Smell, Facial Pain, Overall Symptoms visual analogue scale (VAS) scores (0-100) were completed daily, reported as 4-weekly means on 0-10 scale.

**Results:** Median change from baseline in VAS at weeks 49-52 and percentage responders (post-hoc analyses) for mepolizumab and placebo were: Nasal Obstruction, -4.41(60%), -0.82(36%); Nasal Discharge, -4.51(64%), -0.85(40%); Mucus in Throat, -4.21(57%), -0.97(36%); Loss of Smell, -0.53 (36%), 0.00 (19%); Facial Pain, -3.63(58%), -0.68(40%); Overall Symptoms, -4.48(64%), -0.90(40%). Loss of Smell VAS showed greater improvement for patients with one prior surgery; median change from baseline for mepolizumab, -1.87, placebo -0.07. No difference vs placebo in those with >2 prior surgeries.

**Conclusions:** Clinically and statistically significant improvements in symptoms were demonstrated with mepolizumab 100mg SC versus placebo. Improvement in sense of smell was related to prior NP surgery.

**Funding:** GSK[ID:205687/NCT03085797]. Previously presented at AAAAI 2021. [J Allergy Clin Immunol. 2021;147(2,Supplement):AB126].

**Key words:** Mepolizumab, symptoms, Chronic Rhinosinusitis, Nasal Polyps

## Mepolizumab reduces systemic corticosteroid use in patients with chronic rhinosinusitis with nasal polyps

**Adam M. Chaker**<sup>1</sup>, Geoffrey Chupp<sup>2</sup>, Isam Alobid<sup>3-6</sup>, Njira Lugogo<sup>7</sup>, Harsha H. Kariyawasam<sup>8</sup>, Arnaud Bourdin<sup>9,10</sup>, Ana R. Sousa<sup>11</sup>, Neil Martin<sup>12,13</sup>, Shibing Yang<sup>14</sup>, Bhabita Mayer<sup>15</sup>, Robert Chan<sup>11</sup>, Andrea Matucci<sup>16</sup>

<sup>1</sup>Department of Otolaryngology, Technical University Munich, Munich, Germany; <sup>2</sup>Department of Internal Medicine, Yale School of Medicine, New Haven, CT, USA; <sup>3</sup>Department of Otorhinolaryngology, Universitat de Barcelona, Barcelona, Spain; <sup>4</sup>Institut d'Investigacions Biomediques August Pi i Sunyer (IDIBAPS), Barcelona, Spain; <sup>5</sup>Centro de Investigacion Biomedica en Red de Enfermedades Respiratorias (CIBERES), Barcelona, Spain; <sup>6</sup>Unidad Alergo Rino, Centro Medico Teknon, Barcelona, Spain; <sup>7</sup>Department of Medicine, University of Michigan, Ann Arbor, MI, USA; <sup>8</sup>Royal National Throat, Nose and Ear Hospital, UCLH London, London, UK; <sup>9</sup>Departement de Pneumologie et Addictologie, Hôpital Arnaud de Villeneuve, CHU Montpellier, Montpellier, France; <sup>10</sup>PhyMedExp, University of Montpellier, Montpellier, France; <sup>11</sup>Clinical Sciences, GSK R&D, Brentford, London, UK; <sup>12</sup>Global Medical Affairs, GSK, Brentford, London, UK; <sup>13</sup>Institute for Lung Health, University of Leicester, Leicester, UK; <sup>14</sup>Value Evidence and Outcomes, GSK, Collegeville, PA, USA; <sup>15</sup>Clinical Statistics, GSK, Brentford, London, UK; <sup>16</sup>Immunoallergology Unit, University of Florence, Florence, Italy.

CRS - medical management 2, Building M2 CR2, Sept 28, 10.15

**Background:** Although systemic corticosteroids (SCS) may reduce NP size and improve symptoms, long-term use is associated with adverse effects; further treatment options are desired.

**Methodology/Principal:** SYNAPSE methodology has been reported. To control NP severity, standard-of-care SCS courses (courses <7days apart considered as one) were prescribed as required. Endpoints up to Week 52: number of SCS courses; mean days on SCS therapy for NP; prednisolone-equivalent oral corticosteroid (OCS) dose.

**Results:** Overall, 25% (52/206) and 37% (74/201) of patients receiving mepolizumab and placebo, respectively, were treated with  $\geq 1$  course of SCS for NP, indicating patients were 42% less likely to require  $\geq 1$  course of SCS for NP with mepolizumab versus placebo (odds ratio [95%CI]: 0.58 [0.36, 0.92],  $P=0.020$ ). For patients with SCS use for NP, a similar mean (SD) number of days on SCS was recorded with mepolizumab (21.9 [45.8]) and placebo (19.0 [18.5]). Mean (SD) total OCS dose was lower with mepolizumab (109 [257] mg/year) versus placebo (181 [364] mg/year).

**Conclusions:** Patients with CRSwNP treated with mepolizumab were less likely to require SCS to control NP severity versus placebo. Mepolizumab was associated with lower total OCS doses versus placebo.

**Funding:** GSK(ID:205687/NCT03085797). Previously presented: ATS 2021. [Am J Respir Crit Care Med.2021;203:A1344].

**Key words:** Mepolizumab, Rhinosinusitis, Nasal Polyps

## Long-acting implantable corticosteroid matrix for chronic rhinosinusitis: Results of LANTERN Phase 2 randomized study

Joanne Rimmer<sup>1</sup>, **Anders Cervin**<sup>2</sup>, Agnieszka Wrobel<sup>3</sup>, Yogen Abelak<sup>4</sup>, Lindsay Brayton<sup>5</sup>, Yina Kuang<sup>5</sup>

<sup>1</sup>Monash Health and Department of Surgery, Monash University, Melbourne, Australia; <sup>2</sup>University of Queensland Centre for Clinical Research, Royal Brisbane & Women's Hospital Campus, Herston, QLD, Australia; <sup>3</sup>Centrum Medyczne ALL-MED, Krakow, Poland; <sup>4</sup>Vistamed Sp. z o.o., Wroclaw, Poland; <sup>5</sup>Lyra Therapeutics, Inc., Watertown, MA, USA.

*CRS - outcome assessment 1, Building M1 Room Σ4, Sept 27, 10.15*

**Background:** Designed for chronic rhinosinusitis (CRS) patients who failed medical management, LYR-210 is an implantable matrix that locally elutes mometasone furoate to sinonasal tissue for 24 weeks. LYR-210 safety and efficacy in CRS were evaluated in the LANTERN Phase 2 study.

**Methodology/Principal:** Sixty-seven adult CRS patients with and without nasal polyps who failed previous medical management enrolled in a multicenter, blinded, controlled study. Patients were surgically naïve, exhibiting moderate-to-severe disease based on the 22-item Sinonasal Outcome Test (SNOT-22), with diagnosis confirmed by nasal endoscopy and MRI. Patients were randomized (1:1:1) to sham-procedure plus saline-irrigation control or bilateral in-office administration of LYR-210 (2500µg) or LYR-210 (7500µg). Safety and efficacy were evaluated over 24 weeks.

**Results:** LYR-210 was safe, well-tolerated, and demonstrated dose-dependent improvement. LYR-210 (7500µg) significantly reduced the composite 7-day average score of 4 CRS cardinal symptoms (nasal congestion, nasal discharge, facial pain/pressure, and loss of smell) ( $p=0.016$ ) and SNOT-22 total score ( $-40.7\pm5.8$  vs.  $-21.7\pm5.1$ ;  $p=0.001$ ) compared to control at week 24. Rescue treatment use and ethmoid opacification at week 24 were significantly decreased by LYR-210 (7500µg) compared to control ( $p<0.05$ ).

**Conclusions:** LYR-210 is the first implantable sinonasal treatment to achieve up to 24 weeks of benefit from a single administration in CRS patients.

**Key words:** Chronic rhinosinusitis, nasal implant, mometasone furoate, nasal polyps, randomized controlled study

## Occupational exposure has a negative effect on postoperative results after sinus surgery.

**G. Vansteelant**<sup>1</sup>, D.A.E. Dietz de Loos<sup>2</sup>, M. Samaha<sup>3</sup>, D. Langer<sup>4</sup>, S. Ronsmans<sup>5</sup>, S. Keirsbilck<sup>6</sup>, P. Rombaux<sup>1</sup>, C. Huart<sup>1</sup>, M. Jorissen<sup>7</sup>, W. Fokkens<sup>2</sup>, B. Nemery<sup>5</sup>, P.W. Hellings<sup>7</sup>, V. Hox<sup>1</sup>

<sup>1</sup>Department of Otorhinolaryngology, Cliniques Universitaires Saint-Luc, Brussels, Belgium, <sup>2</sup>Department of Otorhinolaryngology, Amsterdam University Medical Centres, location AMC, Amsterdam, The Netherlands, <sup>3</sup>Department of Otorhinolaryngology, Liege, <sup>4</sup>Respiratory Rehabilitation and Respiratory Division, University Hospitals Leuven, Belgium, <sup>5</sup>Department of Public Health and Primary Care, Centre for Environment and Health, KU Leuven, Leuven, Belgium, <sup>6</sup>IDWE, <sup>7</sup>Department of Otorhinolaryngology – Head and Neck Surgery, University Hospitals Leuven, Leuven, Belgium

*Abstract Session 13, Building M2 CR1, Sept 27, 14:45 - 16:15*

**Introduction:** Inhalation of sensitizers or irritants in the workplace can lead to occupational asthma and rhinitis, however, very little is known about its effect on rhinosinusitis. Two retrospective studies suggest that inhalant occupational exposures might negatively affect surgical outcomes in rhinosinusitis patients.

**Materials and methods:** In a prospective study, we included 226 rhinosinusitis patients with and without nasal polyps (NP) undergoing sinus surgery at 2 academic centres. Occupational histories were obtained with an extensive questionnaire and assessed by 3 independent specialists. Nasal endoscopy score (NES), nasal polyp score (NPS), SNOT-22 questionnaires and visual analogue symptoms scores (VAS) were recorded before and 3 months after sinus surgery.

**Results:** At 3 months post-surgery, improvement in NES and NPS were significantly better in 179 non-exposed patients than 38 exposed patients (both  $p < 0.05$ ). We found a reduced improvement in VAS for nasal obstruction ( $p < 0.05$ ) and sneezing ( $p < 0.01$ ) in occupationally exposed patients, but not for other symptoms or SNOT-22 results. Patients with NP and occupational exposure showed a significantly lower improvement in SNOT-22 compared to unexposed NP patients ( $p < 0.05$ )

**Conclusion:** Inhalant occupational exposures are related to worse objective and subjective post-operative outcomes.





## Real-world characterization of patients with nasal polyps with and without surgery in England

**Victoria S Benson<sup>1</sup>**, Qinggong Fu<sup>2</sup>, Shibing Yang<sup>2</sup>, Ana R Sousa<sup>3</sup>, Robert H Chan<sup>3</sup>, Peter Howarth<sup>4</sup>, Claire Hopkins<sup>5-6</sup>

<sup>1</sup>Epidemiology, Value Evidence and Outcomes, GSK, GSK House, Brentford, Middlesex, UK; <sup>2</sup>Value Evidence and Outcomes, GSK, Collegeville, PA, USA; <sup>3</sup>Respiratory Patient Centered Outcomes, Value Evidence and Outcomes, GSK, GSK House, Brentford, Middlesex, UK; <sup>4</sup>Global Medical Affairs, GSK, Brentford, Middlesex, UK; <sup>5</sup>ENT Department, Guys and St Thomas's Hospital; <sup>6</sup>King's College, London, UK.

*CRS - surgical management 1, Building M2 CR3, Sept 29, 10.15*

**Background:** The burden of nasal polyps (NP) and related surgery in England were assessed.

**Methodology/Principal:** Demographic/clinical data (UK Clinical Practice Research Datalink with Hospital Episodes Statistics linkage) were reported for 365 days before (baseline) the first NP diagnosis (index date); surgeries occurring  $\geq 180$  days apart post-index were described (follow-up:  $\geq 180$  days). This retrospective cohort study (2008–2018) stratified adult patients by number of NP surgeries. Point prevalence was estimated on December 31, 2018.

**Results:** NP prevalence was 476.17 per 100,000 persons. In the NP cohort, 7793/33,107 (23.5%) patients had  $\geq 1$  surgery during follow-up; 722 (2.2%) had  $\geq 2$  surgeries (mean follow-up: 2897 days). Patients with more surgeries ( $\geq 2/\geq 1/0$ ) were likely to be younger (mean age: 48.8/52.4/52.7 years), male (67.3%/69.0%/58.0%), have asthma (37.8%/28.2%/20.2%), and high blood eosinophil counts (BEC)  $\geq 300$  cells/ $\mu$ L (68.5%/66.0%/51.5%) at baseline. With increasing surgeries (1–2 vs 2–3), median time between surgeries decreased (1032 vs 719 days) and repeat surgeries within 24 months increased (3.5% vs 10.0%). Revision surgeries ( $\leq 180$  days post-surgery) increased with surgery number ( $\geq 1/\geq 2/\geq 3/\geq 4$ : 1.8%/5.0%/9.0%/21.2%).

**Conclusions:** With increasing NP surgery number, surgical intervals decreased and revision rates increased. Asthma and elevated BEC may help identify these patients, allowing consideration of alternative management options.

Funding: GSK [ID:213951]

**Key words:** nasal polyps, nasal surgical procedures, prevalence, retrospective studies, England

A novel technique for nasal septal perforation repair: greater palatine artery pedicled flap. Radiological study and case series.

**Franklin Mariño-Sánchez<sup>1</sup>**, Alfonso Santamaría-Gadea<sup>1</sup>, Miguel Vaca<sup>1</sup>

<sup>1</sup>*Rhinology and Skull Base Surgery Unit, Otorhinolaryngology Department, Ramón y Cajal University Hospital. Madrid, Spain.*

*Rhinoplasty 1, Building M2 CR1, Sept 29, 14.45*

**Background:** The greater palatine artery (GPA) is one of the main vessels supplying the nasal septum. We recently described the use of a GPA flap to reconstruct a nasal septal perforation (NSP). This radiological study explores the feasibility and limits of using a GPA flap for an anterior NSP repair.

**Methodology/Principal:** We describe our technique for repairing anterior-most NSP. Radiological measurements of the GPA flap and their limits were analysed. Additionally, a cohort of five patients who underwent reconstruction of a NSP with a GPA flap was included. Patients were followed up for 60-279 days.

**Results:** The radiological study of 150 nasal cavities showed a  $31.5 \pm 2.7$  cm<sup>2</sup> maximum flap area. Taking into account the retraction process (30%), the remaining area was  $22.0 \pm 1.9$  cm<sup>2</sup>. The septal area anterior to the GPA was  $6.1 \pm 2.1$  cm<sup>2</sup>. The septal portion of the flap was larger than the area anterior to the GPA pedicle in all cases. Complete NSP repair was achieved in all 5 patients. All cases of NSP remained closed during the follow-up.

**Conclusions:** The unilateral GPA pedicled flap is a useful technique suitable for the reconstruction of anterior-most perforations that are difficult to cover with other endonasal techniques.

**Key words:** Septal perforation, septum reconstruction, greater palatine artery, endoscopic flap, endoscopic surgery.

## Modern tactics of treatment of basal meningoencephalocele of the skull base in children.

**Chernikova N.A.**<sup>1</sup>, Shelesko E.V.<sup>1</sup>, Satanin L.A.<sup>1</sup>

<sup>1</sup>*Federal State Autonomous Institution "N.N. Burdenko National Medical Research Center of Neurosurgery" of the Ministry of Health of the Russian Federation, 4-Tverskaya-Yamskaya Str. 16, Moscow, Russia, 125047*

*Skull base surgery 1, Building M1 Room Σ4, Sept 28, 14.45*

**Background:** Basal meningoencephalocele is a rare pathology that causes the meninges and brain tissue to prolapse through a defect in the base of the skull. Due to the risk of developing meningitis, brain abscess, surgical intervention is necessary for treatment.

**Methodology/Principal:** At the "N.N. Burdenko Center of Neurosurgery" 100 patients with meningoencephalocele of the skull base were operated on. Comparison of the efficacy and safety of the use of endoscopic and transcranial approaches for the treatment.

**Results:** In a series of 100 patients, the transcranial approach was used in 44 (44%) cases. The indications for this approach were multiple defects, a depressed fracture of the frontal sinus, defects in the lateral sections of the posterior wall of the frontal sinus. Endoscopic endonasal approach was performed in 56 (56%) cases. The indications for the choice of access were single defects in the sphenoid, ethmoid, medial sections of the frontal sinus, cribrosa plate. The success rate of plastic surgery with endoscopic endonasal access is 86,5% (7 of 56) with transcranial access 95,5% (2 of 44).

**Conclusions.** For the treatment of basal meningoencephalocele transcranial and endoscopic approaches are used. The choice of access depends on the anatomical features and localization of the defect.

**Key words:** meningoencephalocele, skull base, endoscopic approach, sphenoid sinus, ethmoid sinus, frontal sinus.

### Literature

1. Joshua A. Leea , Young Jae Byuna, Shaun A. Nguyena , Rodney J. Schlossera , David A. Gudis Endonasal endoscopic surgery for pediatric anterior cranial fossa encephaloceles: A systematic review International Journal of Pediatric Otorhinolaryngology 132 (2020) <https://doi.org/10.1016/j.ijporl.2020.109919>
2. Chadi A. Makary, Habib G. Zalzal, Jad Ramadan, Hassan H. Ramadan Endoscopic endonasal CSF rhinorrhea repair in children: Systematic review with meta-analysis Journal of Pediatric Otorhinolaryngology International Journal of Pediatric Otorhinolaryngology 134 (2020) <https://doi.org/10.1016/j.ijporl.2020.110044>
3. Madhuri Tirumandas, Amit Sharma, Ikechi Gbenimacho, Mohammadali M. Shoja, R. Shane Tubbs, W. Jerry Oakes, Marios Loukas Nasal encephaloceles: a review of etiology, pathophysiology, clinical presentations, diagnosis, treatment, and complications Childs Nerv Syst (2013) 29:739–744 <https://doi.org/10.1007/s00381-012-1998-z>

## Real-world data on the effectiveness and safety of dupilumab in adult patients with uncontrolled severe chronic rhinosinusitis with nasal polyps (CRSwNP)

**Anna Sophie Hoffmann**<sup>1</sup>, J Eden<sup>1</sup>, F Jansen<sup>1</sup>, B Becker<sup>1</sup>, P Breda<sup>1</sup>, A Hot<sup>2</sup>, E Burandt<sup>3</sup>, Christian Betz<sup>1</sup>

<sup>1</sup>Department of Otorhinolaryngology, University Medical Center Hamburg-Eppendorf, Martinistraße 52, 20246, Hamburg, Germany., <sup>2</sup>Institute of Medical Biometry and Epidemiology, University Medical Center Hamburg-Eppendorf, Martinistraße 52, 20246, Hamburg, Germany., <sup>3</sup>Institute of Pathology, University Medical Center Hamburg-Eppendorf, Martinistr. 52, 20246 Hamburg, Germany

*CRS - medical management 1, Building M2 CR2, Sept 27, 10.15*

**Introduction:** CRSwNP is a type 2-mediated inflammatory disease associated with significant clinical, social, and economic burdens. The launch of dupilumab is the first targeted systemic treatment option approved in Germany for severe CRSwNP. Aim of this study is to compare and evaluate the parameters needed to monitor the therapy and better assess the effect of dupilumab in our clinic between 2019 and 2021.

**Methodology:** Since October 2019 we treated 27 patients (12 male, 15 female). The following parameters were collected at baseline, 1, 3, 6, 9 and 12 months: SNOT-22, FEV-1, olfactometry, VAS of the total complaints, NPS, histologic findings and blood parameters (total IgE, ECP and eosinophils).

**Results:** The average age was 53.9 years (SD±15.3). The follow-up period was 12 months. The SNOT-22 average was 55 (±20.5) at the first visit and 24.7 (±11.6) after 12 months. The NPS was 4.3 (± 1.1) and 1.5 (±0.5) after 12 months. Olfactometry showed 3.0 (±3.6) and 9.3 (±2.3) after 12 months. The other parameters also improved.

**Conclusion:** There is a significant improvement in the medical condition and symptoms in all categories under therapy with dupilumab, as well as a significant reduction in the need for systemic glucocorticoids and revision surgery.

**Key words:** CRSwNP, dupilumab, biologicals, nasal polyposis, type 2 inflammation

### Literature

1. Fokkens, W. J. *et al.* European Position Paper on Rhinosinusitis and Nasal Polyps 2020. *Rhinology* **58**, 1-464, doi:10.4193/Rhin20.600 (2020).
2. Shirley, M. Dupilumab: First Global Approval. *Drugs* **77**, 1115-1121, doi:10.1007/s40265-017-0768-3 (2017).
3. Bachert, C. *et al.* Effect of Subcutaneous Dupilumab on Nasal Polyp Burden in Patients With Chronic Sinusitis and Nasal Polyposis: A Randomized Clinical Trial. *JAMA* **315**, 469-479, doi:10.1001/jama.2015.19330 (2016).
4. Bachert, C. *et al.* Dupilumab improves health-related quality of life in patients with chronic rhinosinusitis with nasal polyposis. *Allergy* **75**, 148-157, doi:10.1111/all.13984 (2020).

# Evaluation of effectiveness and security of image-guided endoscopic endonasal surgery for paranasal sinuses and skull base lesions.

**V A Doronina<sup>1</sup>**, M V Nersesyan <sup>1</sup>

<sup>1</sup>N.N. Burdenko National Medical Research Center for Neurosurgery, Moscow, Russia, 125047.

*Technological advances 1, Building M1 Room Σ4, Sept 29, 14.45*

**Background:** The current complication rate of endoscopic sinus surgery for sinonasal lesions bordering the skull base reaches 12,9% <sup>1,2</sup>. This study aimed to evaluate the effectiveness of image-guided endoscopic endonasal surgery (IGEES) in such cases.

**Methodology/Principal:** 58 patients in 2 years with rhinologic pathology which underwent IGEES were reviewed. A unique questionnaire was developed by which demographics, pathology, complications, the navigation accuracy, setup time, probable cause of error and surgeon's assessment of the usefulness of navigation were evaluated.

**Results:** Average age was 45 [41; 52] years. Twenty-four patients (41%) had Functional Endoscopic Sinus Surgery, ten patients (17,2 %) had cerebrospinal fluid leak closure, twenty-four patients (41,4 %) underwent sinonasal and skull base tumour resection. No complications were reported. In 46 (79.3%) cases no visible error was detected, in other cases mainly because of bad-quality CT scans the error was 2 mm (18,9 %) or 3 mm (3,4 %). Mostly the error was vertical (p=0,021). The average setup time was 13 [12.6; 16.0] minutes. The median of the usefulness of using navigation was 7.8 [7; 8.9] points.

**Conclusions:** Image-guided endoscopic endonasal surgery appears to be secure and helpful in cases of paranasal sinuses and skull base lesions. The analyzed data will be presented.

**Key words:** navigation, image-guided surgery, endoscopic sinus surgery, skull base surgery, complications

## Literature

1. M Wagenmann, K Scheckenbach, B Kraus, I Stenin. Complications of anterior skull base surgery. *HNO*. 2018 Jun;66(6):438-446. doi: 10.1007/s00106-018-0508-3.
2. Jessica W Grayson, Sunny S Khichi, Do-Yeon Cho, Kristen O Riley, Bradford A Woodworth. Management Strategies for Skull Base Inverted Papilloma. *Otolaryngol Head Neck Surg*. 2016 Jul;155(1):179-83. doi: 10.1177/0194599816639019
3. Ramakrishnan VR, Orlandi RR, Citardi MJ, Smith TL, Fried MP, Kingdom TT. The use of image-guided surgery in endoscopic sinus surgery: an evidence-based review with recommendations. *Int Forum Allergy Rhinol*. 2013;3(3):236-241
4. Vorozhtsov I.N., Grachev N.S., Nasedkin A.N. Endoscopic surgery of the paranasal sinuses and skull base neoplasms with the use of the computerassisted navigation system (CANS) in pediatric practice. *Almanac of Clinical Medicine*. 2016;44(7):809-813. (In Russ.) <https://doi.org/10.18786/2072-0505-2016-44-7-809-813>
5. Nazarov VV. Use of navigation in skull base surgery. *Voprosy neirokhirurgii im. N.N. Burdenko*. 2019;83(5):109-118. (In Russ.) <https://doi.org/10.17116/neiro201983051109>

## Endonasal target localisation of Severe Acute Respiratory Syndrome Coronavirus 2

**Dorota Kuryga**<sup>1</sup>

<sup>1</sup>ENT Department, Voivodeship Hospital, Lomza, Podlachia, Poland

*Miscellaneous 2, Building M1 Room Σ2, Sept 29, 11.45*

**Background:** Problems of COVID-19 pandemic include diagnostic testing with its false negative results. The aim of the study is to determine the best endonasal localization for swab sampling for RT-PCR SARS-CoV-2 detection.

**Methodology:** Samples from patients suffering COVID-19 are collected from 7 different places during endoscopic endonasal procedures to detect SARS-CoV-2 genome with RT-PCR technique. Patients are divided into 3 groups: 1) hyposmia/hypogeusia due to COVID-19 2) hearing impairment due to COVID-19 3) the rest. The procedures are performed with the aid of computed tomography guided navigation systems. Swabs are taken from 5 different localisation: nasopharynx, Eustachian tube orifice, medial nasal turbinate, inferior nasal turbinate and fovea ethmoidalis. Then washings from maxillary sinus and from bronchial tube are collected.

**Results:** The study has just begun and the results are to be shown in September 2021.

**Conclusions:** Result will tell if the endonasal localisation of taken swabs plays a crucial role in SARA-CoV-2 detection. Secondly, we will answer which factor is more important in false negative results of COVID-19 testing: an individual personal technique of swabs collection or the place of taken samples. Finally, the influence of viral spread inside the nasal mucosa on smell/taste or hearing state will be described.

203671 - 157

A randomized placebo controlled clinical trial analyzing the effect of postoperative systemic steroids on long-term sinonasal and general quality of life, recurrence rate and biomarkers

**Mueller SK<sup>1</sup>**, Bleier BS<sup>2</sup>, Iro H<sup>1</sup> et al

<sup>1</sup>Friedrich-Alexander-Universität Erlangen-Nürnberg, Department of Otolaryngology, Head and Neck Surgery, Germany, <sup>2</sup>Massachusetts Eye and Ear Infirmary, Department of Otolaryngology, Harvard Medical School, Boston, USA

*Abstract Session 32, Building M2 CR1, Sept 28, 14:45 - 16:15*

**Background:** The objective of this study was to determine whether post-operative additive systemic steroid administration in Chronic Rhinosinusitis with Nasal Polyps(CRSwNP) impacted 1)the Nasal Polyp(NPS) and Lund-Kennedy-Score(LKS) 2)recurrence rates(RR) 3)long-term sinonasal and general quality of life(SNQOL, GQOL) 4)mucus biomarker levels and 5)smell scores.

**Methodology/Principal:** Prospective multi-centered randomized, placebo controlled trial of n=106 patients with CRSwNP. All patients underwent a functional endoscopic sinus surgery(FESS) followed by topical nasal steroids for 3 months. Additionally, all patients were randomized postoperatively to a systemic steroid or placebo for 1 month. Patients were followed for 24 months over 10 time points. The primary outcome measure was the difference between groups in NPS. Secondary outcome measures included interactions in LKS, RR, SNQOL, GQOL, smell scores and mucus biomarker levels.

**Results:** Postoperative systemic steroids were non-superior to placebo with respect to all primary and secondary outcome measures for a follow-up of 12, 18 and 24 months( $p>0.05$  for all). Reported adverse events were similar between the two groups.

**Conclusions:** The addition of postoperative systemic steroids after FESS did not confer a benefit over topical steroid nasal spray alone with respect to all outcome measures over a long-term follow-up of 24 months in CRSwNP patients.

**Key words:** steroids, postoperative, quality of life, biomarkers, recurrence

## Ethmoidal Point and Kyphion: Radiological assessment of two important anatomical landmarks in the Caucasian nasal hump

**David Rodrigues Dias<sup>1</sup>**, Luis Cardoso<sup>2</sup>, Mariline Santos<sup>1</sup>, Cecília A. Sousa<sup>1</sup>, Nuno Dourado<sup>3</sup> Jorge Santos<sup>4</sup>, José Amarante MD<sup>5</sup>, Miguel Gonçalves Ferreira<sup>1,6</sup>

<sup>1</sup>*Centro Hospitalar Universitário do Porto, Instituto de Ciências Biomédicas Abel Salazar – Universidade do Porto – Otolaryngology-Head and Neck Surgery Department.*, <sup>2</sup>*Centro Hospitalar Universitário do Porto, Instituto de Ciências Biomédicas Abel Salazar – Universidade do Porto - Neuroradiology Department*, <sup>3</sup>*Universidade do Minho, Departamento de Engenharia Mecânica, Guimarães, Portugal*

*Associate Professor - no funding or disclosure on this paper*, <sup>4</sup>*Universidade do Minho, Departamento de Engenharia Mecânica, Guimarães, Portugal*

*Associate Professor - no funding or disclosure on this paper*, <sup>5</sup>*Faculdade de Medicina da Universidade do Porto, Porto, Portugal*, <sup>6</sup>*Hospital da Luz – Arrábida, Porto*

*Rhinoplasty 1, Building M2 CR1, Sept 29, 14:45*

**Background:** The relation between osteocartilaginous nasal vault anatomy and superficial nasal hump characteristics has not been fully investigated

**Methodology/Principal:** Measurements were collected from computed tomography nasal scans in the mid-sagittal plane, in adult Caucasian patients presenting a nasal hump from January 2015 to December 2018. Measurements were compared to sex and age-matched patients not seeking rhinoplasty (control group). The relationship between the beginning and the apex of the nasal hump, as well as its height, with two anatomical landmarks (Kyphion and Ethmoidal points) was evaluated.

**Results:** The study included 134 patients (67 presenting nasal hump), mean aged 32.9 years old. The Ethmoidal point was located cephalic to the beginning of the nasal hump in 97% of nasal hump patients and it was located a mean distance of 2.3(±2.3)mm to the former. In all patients, the Kyphion was located underneath the nasal hump. Nasal hump height correlated with the angle over the Kyphion. In all patients, the nasal hump apex was situated over the septal cartilage.

**Conclusions:** The nasal hump characteristics are mainly due to the septal cartilage. The caudal aspect of the nasal bones contributes to the nasal hump whereas the posterior ethmoidal plate rarely does.

**Key words:** Rhinoplasty; Hump Reduction; Nose Anatomy; Nose Radiology



## Patient perceptions on the use of cocaine in sinonasal surgery

**Eamon Shamil**<sup>1,3</sup>, Patrick Cook<sup>2</sup>, Irfan Syed<sup>3</sup>, Anil Joshi<sup>3</sup>, Alwyn D'Souza<sup>3</sup>, Anastasia Rachmanidou<sup>3</sup>

<sup>1</sup>Specialist Registrar in Otolaryngology, South London Deanery, UK., <sup>2</sup>GKT School of Medicine, King's College London, UK., <sup>3</sup>Department of Otolaryngology, University Hospital Lewisham, London, England

*Rhinology – miscellaneous 2, Building M1 Room Σ3, Sept 29, 14:45*

**Background:** Medical cocaine has routinely been used in sinonasal surgery for decades. In an era where care has become more patient-centred and the population is more health-conscious, this is the first study that evaluates patient perception on the use of medical cocaine as well as the implications of occupational drug testing.

**Methods:** We prospectively surveyed 63 peri-operative patients attending a rhinology clinic in the University Hospital Lewisham, London. Ethical approval obtained.

**Results:** The majority of our patients, 35 (56%), felt they were not aware cocaine was used in nasal surgery. No patient felt they had been sufficiently informed about its side-effects. Four patients (6%) stated that their employer performed drug testing including cocaine, while 14 (23%) were unsure. Three patients (5%) were appropriately informed that an occupational drug test can be positive, whilst 49 (83%) patients stated they were not informed.

**Conclusions:** The majority of patients were unaware of the routine use of medical cocaine, nor did they know the side-effects. Given its implications, our study indicates we should improve our discussion with patients about the use and implications of medicinal cocaine, considering it can be detected weeks to months later. Preoperatively we provide an information leaflet to facilitate discussion.

**Key words:** cocaine, sinonasal surgery, drug testing

## A single center study investigating the olfactory dysfunction of hospitalized patients with PCR-confirmed, active COVID-19 disease

Tile Bußmann<sup>1</sup>, Nina Zeller<sup>1</sup>, Narineh-Shirvanian Klein<sup>1,a</sup>, Chia-Jung Busch<sup>1,b</sup>, Anna Sophie Hoffmann<sup>1</sup>, Marylyn Addo<sup>2</sup>, Robin Kobbe<sup>2</sup>, Matthias Belau<sup>3</sup>, **Christian Stephan Betz**<sup>1</sup>, Lara Bußmann<sup>1,4</sup>

<sup>1</sup>Department of Otorhinolaryngology, University Medical Center Hamburg-Eppendorf, Martinistrasse 52, 20246 Hamburg, Germany, <sup>2</sup>Section Infectiology and Tropical Medicine, I. Medical Clinic and Polyclinic, University Medical Center Hamburg-Eppendorf, Martinistrasse 52, 20246 Hamburg, Germany, <sup>3</sup>Institute of Medical Biometry and Epidemiology, University Medical Center Hamburg-Eppendorf, Martinistrasse 52, 20246 Hamburg, Germany, <sup>4</sup>Mildred Scheel Cancer Career Center HaTriCS4, University Medical Center Hamburg-Eppendorf, Hamburg, Germany, <sup>a</sup>Current affiliation: HNO Zentrum Mangfall-Inn, Praxis Wasserburg, Krankenhausstr. 2, 83512 Wasserburg, Germany, <sup>b</sup>Current affiliation: Department of Otorhinolaryngology, University Medical Center Greifswald, Ferdinand-Sauerbruch-Straße, 17475 Greifswald, Germany

*Smell and taste 2, Building M2 CR2, Sept 27, 14:45*

**Background:** A loss of smell is often the first symptom of a COVID-19 infection. This study examined olfactory dysfunction (OD) of hospitalized COVID-19 patients in a single centre in a cross-sectional and longitudinal fashion.

**Methodology/Principal:** 27 hospitalized patients with PCR-confirmed, active COVID-19 disease were included. Olfactory history was taken using a questionnaire. Olfactory function was evaluated with “Sniffin’ Sticks” tests (threshold-, discrimination- and identification test; TDI). Follow-up checks via identification testing were performed every two days during hospitalization, and 4 months after the first test.

**Results:** Looking at the TDI scores, 25 of 27 patients (93%) showed an OD. Of those, 16 patients (64%) reported a subjective normosmia. The assessment of the TDI score subcategories showed that the affected participants performed poor in the discrimination and the threshold tests, whereas the smell identification skills were impeded the least. When looking solely at the identification tests, only 17 of 27 individuals (63%) showed pathologic scores.

**Conclusions:** Olfactory testing reveals a higher rate of affected individuals than subjective evaluation in COVID-19 patients. In addition, a mere testing of the identification abilities seems insufficient to diagnose ODs in these patients. A comprehensive test battery looking at threshold, discrimination and identification skills is recommendable.

**Key words:** COVID-19, SARS-CoV-2, olfaction disorders, olfactometry

## Dizziness predicts history of migraine in chronic rhinosinusitis patients

**Marlene M. Speth**<sup>1</sup>, Katie M. Phillips<sup>2</sup> and Ahmad R. Sedaghat<sup>2</sup>*Department, university or organization, city, state/province (if applicable), and country - for all authors.*<sup>1</sup>Klinik für Hals-, Nasen-, Ohren- Krankheiten, Hals-und Gesichtschirurgie, Kantonsspital Aarau, Switzerland, <sup>2</sup>Department of Otolaryngology—Head and Neck Surgery, University of Cincinnati College of Medicine, Cincinnati, OH, USA*CRS - diagnosis and investigations 3, Building M1 Room 24, Sept 29, 10.15*

**Background:** Dizziness is a symptom that is commonly reported in patients with chronic rhinosinusitis (CRS) although its etiology is unclear. Herein, we report the association between dizziness and migraine in patients with chronic rhinosinusitis.

**Methodology:** Cross-sectional study of 135 CRS patients (31.1% CRSwNP, 68.9% CRSsNP). Participants were asked if they had ever been diagnosed with migraine by a physician in the past. Each participant completed the 22-item Sinonasal Outcome Test (SNOT-22) from which the nasal, sleep, ear/facial pain and emotional subdomain scores were calculated. Associations between SNOT-22 subdomain and individual item scores were sought with regression and receiver operating characteristic (ROC) curve analysis.

**Results:** A history of migraine was reported by 25.9% of participants. Using multivariable regression, a history of migraine was associated with the ear/facial pain subdomain score (odds ratio [OR]=1.11, 95%CI: 1.01–1.23, p=0.038) but not with any of the other SNOT-22 subdomain scores. Although a history of migraine was associated with all of the symptoms reflected in the ear/facial pain subdomain of the SNOT-22 (ear fullness, dizziness, ear pain/pressure and facial pain/pressure) on univariate regression, in a multivariable model accounting for all four symptoms, migraine was associated only with the burden of dizziness (OR=1.48, 95%CI: 1.11–1.98, p=0.008). On a scale of 0 – 5, a dizziness item score of ≥1 on the SNOT-22 predicted history of migraine with 80% sensitivity and 51% specificity (C-statistic=0.691, 95%CI: 0.592–0.791, p<0.001).

**Conclusion:** While CRS is associated with otologic conditions, dizziness in CRS patients may indicate an underlying migraine disorder.

## Endoscopic sinus surgery for chronic rhinosinusitis independently leads to less antibiotics and oral corticosteroids usage

**Marlene M. Speth**<sup>1</sup>, Isabelle Gengler<sup>2</sup>, Katie M. Phillips<sup>3</sup>, and Ahmad R. Sedaghat<sup>2</sup>

<sup>1</sup>Klinik für Hals-, Nasen-, Ohren- Krankheiten, Hals-und Gesichtschirurgie, Kantonsspital Aarau, Switzerland, ,

<sup>2</sup>Department of Otolaryngology—Head and Neck Surgery, University of Cincinnati College of Medicine, Cincinnati, OH, USA, <sup>3</sup>Department of Otolaryngology—Head and Neck Surgery, Stanford University, Stanford, CA, USA

*CRS - medical management 3, Building M2 CR2, Sept 29, 10.15*

**Background:** Antibiotics and oral corticosteroids usage for chronic rhinosinusitis (CRS) is reflective of poor disease control. We sought to determine how endoscopic sinus surgery (ESS) would impact the usage of these systemic medications for CRS.

**Methodology:** Prospective longitudinal study of 78 CRS patients undergoing comprehensive ESS for medically recalcitrant CRS. CRS burden was measured using SNOT-22 score, CRS-related antibiotics usage and CRS-related oral corticosteroids usage in past 3 months reported at time of ESS and 1 year after ESS.

**Results:** After ESS, SNOT-22 score decreased by mean 22.8 points, CRS-related antibiotics usage in the past 3 months decreased by mean 1.1 courses and CRS-related oral corticosteroids usage in the past 3 months decreased by mean 0.5 courses. In patients with usage of these systemic medications pre-operatively, antibiotics usage decreased by mean 1.7 courses and oral corticosteroids usage decreased by mean 1.0 course. Change in antibiotics usage was associated with pre-operative antibiotics usage ( $b=-1.1$ , 95%CI: -0.9 to -1.2,  $p<0.001$ ), oral corticosteroids usage ( $b=0.3$ , 95%CI: 0.1–0.5,  $p=0.041$ ) and smoking ( $b=2.0$ , 95%CI: 0.9–3.1,  $p<0.001$ ). Change in oral corticosteroids usage was associated with pre-operative oral corticosteroids usage ( $b=-0.7$ , 95%CI: -0.9 to -0.6,  $p<0.001$ ) and antibiotics usage ( $b=-0.1$ , 95%CI: -0.2–0.0,  $p=0.044$ ). Pre-operative SNOT-22 was not associated with change in systemic medication usage.

**Discussion:** ESS reduces systemic antibiotics and corticosteroids usage for CRS, independent of CRS symptomatology. CRS-related antibiotics and oral corticosteroids usage are independent measures of CRS disease control that should be assessed as ESS outcomes.

## The use of novel investigative techniques to monitor epidemiological trends

Abigail Walker<sup>1</sup>, Pavol Surda<sup>1</sup>, Claire Hopkins<sup>1</sup>

<sup>1</sup>Department of ENT surgery, Guy's Hospital, London, UK

*Rhinology – miscellaneous 2, Building M1 Room Σ3, Sept 29, 14.45*

**Background:** We sought to use Google Trends (GT) to investigate whether there was a surge in individuals searching for information related to smell loss during the COVID-19 epidemic in the United Kingdom, Spain, and Italy.

**Methods:** An iterative process was used to investigate GT records of search terms related to “smell” in English, Spanish, and Italian. Search frequency was then plotted by country against the daily confirmed cases of COVID-19 and deaths attributed to disease. Strength of association between search term frequency, confirmed cases, and deaths by Spearman rank correlation. As a control event, we also performed analysis of smell-related searches during the last UK Influenza epidemic of 2009.

**Results:** The strength of the association between daily increase of search terms, cases, and deaths and GT was then tested with Spearman rank correlation. We observed strong correlations ranging from 0.798 to 0.910. All correlations were statistically significant ( $p < 0.05$ ).

**Conclusion:** There is a strong correlation between the frequency of searches for smell-related information and the onset of COVID-19 infection in UK, Spain, and Italy. We would hypothesise this may relate to a previously under-recognised symptom which may occur in mildly symptomatic or asymptomatic individuals, and that GT may be adapted for use in real-time epidemiological surveillance.

**Key words:** Olfaction, Covid-19, anosmia

## Evaluation of immunological parameters in chronic sinusitis without polyps in adults during treatment with bacteriophages.

**I.M. Kirichenko**<sup>1</sup>, V. I. Popadyuk<sup>1</sup>, N.S. Kozlova.<sup>1</sup>

<sup>1</sup>ENT department, Peoples' Friendship University of Russian, Moscow, Russian.

*CRS - medical management 1, Building M2 CR2, Sept 27, 10.15*

**Background:** phagotherapy provides new opportunities for treatment upper respiratory tract disease and overcoming antibiotic resistance.

**Purpose:** assessment of immunological parameters of blood serum of patients with CRSsNP with prescribed standard therapy with the inclusion in the treatment protocol of a complex drug containing bacteriophages on a gel basis.

**Materials and methods:** 30 patients with CRSsNP with exacerbation (main group) and a group of 30 healthy people matched by sex and age. The gel was applied to the nose 2 ml 3 times a day for 21 days. Immunoglobulins, cytokines were determined in blood serum and sIgA saliva of patients before treatment and after 1 and 3 weeks after treatment.

**Results:** The concentration of sIgA in the saliva, the level of IL-10 and  $\alpha$ -interferon in blood serum in patients increased, simultaneously the level of IL-6 decreased after 3 weeks of treatment compared to the control group, which may indirectly be regarded as an improvement in the local immunity of the upper respiratory tract mucosa, a decrease in antigenic load, normalization of biocenosis.

**Conclusions:** improvement of immunological parameters in the treatment of patients with CRSsNP using bacteriophages is promising and requires further study.

**Key words:** immunological parameters, CRSsNP, bacteriophages, gel.

## Direct and indirect costs of adult patients with Chronic Rhinosinusitis with Nasal Polyps

**E.S. Lourijsen**<sup>1</sup>, S. Reitsma<sup>1</sup>, W.J. Fokkens<sup>1</sup>

<sup>1</sup>Department of otorhinolaryngology, Amsterdam UMC, location AMC, the Netherlands

*CRS - outcome assessment 1, Building M1 Room Σ4, Sept 27, 10.15*

**Background:** European direct and indirect cost data is missing for patients with Chronic Rhinosinusitis with nasal polyps (CRSwNP). This study was aimed to establish the economic burden of CRSwNP based on a Dutch cohort of patients.

**Methods:** A cross-sectional study was performed in adult patients with CRSwNP (N=115) to calculate mean annual direct medical costs and indirect costs per patient with CRSwNP. Outpatient visits, general practitioner visits, first aid visits, hospitalisation and patient travel expenses were measured with the iMTA medical consumption questionnaire. Missed workdays (absenteeism) and decreased productivity during paid work (presenteeism) or during daily life were measured with the iMTA productivity cost questionnaire.

**Results:** Total direct costs were €1501 per patient/year, primarily due to outpatient department visits and hospitalisation. Indirect costs were €5659 per patient/year, with productivity losses as major cost expense.

**Conclusion:** Adult patients with CRSwNP have higher indirect costs than direct costs and this forms a substantial burden to society. Total annual costs of patients with CRSwNP are estimated to be 1,9 billion/year in the Netherlands.

**Key words:** Chronic Rhinosinusitis with nasal polyps, Cost of illness, Economic Burden of Disease, Health Care Costs, Health surveys

### Literature

E.S. Lourijsen, W.J. Fokkens, S. Reitsma. Direct and indirect costs of adult patients with Chronic Rhinosinusitis with Nasal Polyps. *Rhinology* 2020 Jun 1;58(3):213-217.

Chronic rhinitis: does our definition cover all of it and what is the real prevalence in general population?

**Klementina S. Avdeeva**<sup>1</sup>, Wytske J. Fokkens<sup>1</sup>, Sietze Reitsma<sup>1</sup>

<sup>1</sup>*Department of Otorhinolaryngology, Amsterdam UMC, location Academic Medical Centre, Amsterdam, The Netherlands*

*Non-allergic rhinitis 1, Building M2 CR2, Sept 28, 11.45*

**Background:** The currently used definition of chronic rhinitis (CR) ( $\geq 2$  nasal symptoms for at least 1 hour/day for more than 12 weeks/year) lacks evidence-based foundation. CR patients are often divided into 'runners' and 'blockers', although the evidence behind is limited. Our aim was to define CR, to estimate its prevalence and the proportion of 'runners' and 'blockers' types.

**Methodology:** Cross-sectional study in general population of the Netherlands.

**Results:** We propose to define CR as at least 1 nasal complaint present for more than 3 weeks/year. The prevalence of CR in the general population was 40% (N=560, of those, 70% had NAR and 30% AR). There were 25% 'blockers' and 22% 'runners' in the CR group, whereas more than a half of the group could be classified in neither of these subgroups. Participants with nasal complaints present for 3-12 weeks per year (which would have been excluded by former definition) had a significantly higher VAS compared to the controls.

**Conclusions:** We suggest that the current definition of CR should be revised and propose a new definition: at least one nasal complaint present for at least 3 weeks per year; although future studies are needed to further validate this definition.

**Key words:** allergic rhinitis, non-allergic rhinitis, chronic rhinitis, prevalence, epidemiology



**Katarzyna Kowalik**<sup>1</sup>· Martyna Waniewska-Leczycka<sup>1</sup>· Elzbieta Sarnowska<sup>2</sup>· Natalia Rusetska<sup>2</sup>· Marcin Ligaj<sup>3</sup>· Alicja Chrzan<sup>3</sup>· Mariola Popko<sup>1</sup>.

<sup>1</sup>Department of Otorhinolaryngology, Faculty of Medicine and Dentistry, Medical University of Warsaw, Warsaw, Poland, <sup>2</sup>Department of Molecular and Translational Oncology, Maria Skłodowska-Curie National Research Institute of Oncology, Warsaw, Poland, <sup>3</sup>Department of Pathology, Maria Skłodowska-Curie National Research Institute of Oncology, Warsaw, Poland

CRS – pathophysiology 1, Building M1 Room Σ3, Sept 28, 11.45

**Background:** Chronic rhinosinusitis (CRS) can be classified as eosinophilic (eCRS) or non-eosinophilic (neCRS) based on infiltration type. The SWI/SNF complex may be involved in the pathophysiology of CRS.

**Metodology/Principal:** To assess the expression of the SWI/SNF complex in both CRS groups; to correlate blood eosinophil count (BEC), and histopathology eosinophil count (HPEC) with the SWI/ SNF expression level in eCRS and neCRS. The study population consisted of 96 patients (68 eCRS, 28 neCRS). Immunohistochemical staining was performed on sinonasal mucosa for assessment of SWI/SNF protein expression. Type of tissue infiltration was assessed in samples obtained from examined groups (HPEC). The diagnostic value of eCRS was 10 cells/HPF (high power field). Complete blood count was analysed in order to calculate BEC.

**Results:** BEC and HPEC correlated negatively with all the SWI/SNF subunits. HPEC and BEC correlated positively with clinical findings (L-M and SNOT-22), while SWI/SNF correlated negatively with clinical findings (L-M and SNOT-22).

**Conclusions:** The SWI/SNF was observed in both eCRS and neCRS, with lower expression in former. The meaning of its negative correlation with BEC, HPEC and clinical findings in eCRS group remains to be understood.

**Key words:** SWI/SNF, sinusitis, eosinophils, eCRS

Literature:

References:

1. Fokkens WJ, Lund VJ, Hopkins C, et al. *European Position Paper on Rhinosinusitis and Nasal Polyps 2020*. Rhinology 2020;58:1-464. doi:10.4193/Rhin20.600.
2. De Corso E, Baroni S, Battista M, et al. *Nasal fluid release of eotaxin-3 and eotaxin-2 in persistent sinonasal eosinophilic inflammation*. International forum of allergy & rhinology 2014;4:617-24. doi:10.1002/alr.21348.
3. De Corso E, Baroni S, Lucidi D, et al. *Nasal lavage levels of granulocyte-macrophage colony-stimulating factor and chronic nasal hypereosinophilia*. International forum of allergy & rhinology 2015;5:557-62. doi:10.1002/alr.21519.
4. Orlandi RR, Kingdom TT, Hwang PH, et al. *International Consensus Statement on Allergy and Rhinology: Rhinosinusitis*. International forum of allergy & rhinology 2016;6 Suppl 1:S22-209. doi:10.1002/alr.21695.
5. Brescia G, Zanotti C, Parrino D, et al. *Nasal polyposis pathophysiology: Endotype and phenotype open issues*. Am J Otolaryngol 2018;39:441-4. doi:10.1016/j.amjoto.2018.03.020.
6. Lou H, Zhang N, Bachert C, et al. *Highlights of eosinophilic chronic rhinosinusitis with nasal polyps in definition, prognosis, and advancement*. International forum of allergy & rhinology 2018;8:1218-25. doi:10.1002/alr.22214.

7. De Corso E, Lucidi D, Battista M, et al. *Prognostic value of nasal cytology and clinical factors in nasal polyps development in patients at risk: can the beginning predict the end?* International forum of allergy & rhinology 2017;7:861-7. doi:10.1002/alr.21979.
8. Kowalik K, Waniewska-Leczycka M, Sarnowska E, et al. *Role of Chromatin Remodeling Complex SWI/SNF and VDR in Chronic Rhinosinusitis.* Advances in Clinical and Experimental Medicine 2020;29(3). doi:10.17219/acem/117683.
9. Ramirez-Carrozzi VR, Nazarian AA, Li CC, et al. *Selective and antagonistic functions of SWI/SNF and Mi-2beta nucleosome remodeling complexes during an inflammatory response.* Genes Dev 2006;20:282-96. doi:10.1101/gad.1383206.
10. Trotter KW, King HA, Archer TK. *Glucocorticoid Receptor Transcriptional Activation via the BRG1-Dependent Recruitment of TOP2beta and Ku70/86.* Mol Cell Biol 2015;35:2799-817. doi:10.1128/mcb.00230-15.
11. King HA, Trotter KW, Archer TK. *Chromatin remodeling during glucocorticoid receptor regulated transactivation.* Biochim Biophys Acta 2012;1819:716-26. doi:10.1016/j.bbagr.2012.02.019.
12. Wei Z, Yoshihara E, He N, et al. *Vitamin D Switches BAF Complexes to Protect beta Cells.* Cell 2018;173:1135-49.e15. doi:10.1016/j.cell.2018.04.013.
13. Lund VJ, Mackay IS. *Staging in rhinosinusitis.* Rhinology 1993;31:183-4.
14. Psaltis AJ, Li G, Vaezeafshar R, et al. *Modification of the Lund-Kennedy endoscopic scoring system improves its reliability and correlation with patient-reported outcome measures.* The Laryngoscope 2014;124:2216-23. doi:10.1002/lary.24654.
15. Sakalar EG, Muluk NB, Kar M, et al. *Aspirin-exacerbated respiratory disease and current treatment modalities.* European archives of oto-rhino-laryngology : official journal of the European Federation of Oto-Rhino-Laryngological Societies (EUFOS) : affiliated with the German Society for Oto-Rhino-Laryngology - Head and Neck Surgery 2017;274:1291-300. doi:10.1007/s00405-016-4273-1.
16. Horak F, Doberer D, Eber E, et al. *Diagnosis and management of asthma - Statement on the 2015 GINA Guidelines.* Wien Klin Wochenschr 2016;128:541-54. doi:10.1007/s00508-016-1019-4.
17. Tomaszewska M, Sarnowska E, Rusetska N, et al. *Role of Vitamin D and Its Receptors in the Pathophysiology of Chronic Rhinosinusitis.* J Am Coll Nutr 2019;38:108-18. doi:10.1080/07315724.2018.1503102.
18. Bhattacharyya N, Vyas DK, Fechner FP, et al. *Tissue eosinophilia in chronic sinusitis: quantification techniques.* Archives of otolaryngology--head & neck surgery 2001;127:1102-5. doi:DOI: 10.1001/archotol.127.9.1102
19. Lang TA, Secic M. *How to report statistics in medicine.* American College of Physicians, Philadelphia, USA 2006:490. doi:10.1136/ebm.12.3.90
20. Wang F, Yang Y, Wu Q, et al. *Histopathologic analysis in chronic rhinosinusitis: Impact on quality of life outcomes.* Am J Otolaryngol 2019. doi:10.1016/j.amjoto.2019.03.014.
21. Jiang N, Kern RC, Altman KW. *Histopathological evaluation of chronic rhinosinusitis: a critical review.* American journal of rhinology & allergy 2013;27:396-402. doi:10.2500/ajra.2013.27.3916.
22. Tarte S, Matsushita K, Vandenbon A, et al. *Akirin2 is critical for inducing inflammatory genes by bridging I $\kappa$ B- $\zeta$  and the SWI/SNF complex.* Embo j 2014;33:2332-48. doi:10.15252/embj.201488447.
23. Hopkins C, Browne JP, Slack R, et al. *The Lund-Mackay staging system for chronic rhinosinusitis: how is it used and what does it predict?* Otolaryngology--head and neck surgery : official journal of American Academy of Otolaryngology-Head and Neck Surgery 2007;137:555-61. doi:10.1016/j.otohns.2007.02.004.

24. Kountakis SE, Arango P, Bradley D, et al. *Molecular and cellular staging for the severity of chronic rhinosinusitis*. The Laryngoscope 2004;114:1895-905. doi:10.1097/01.mlg.0000147917.43615.c0.
25. Tokunaga T, Sakashita M, Haruna T, et al. *Novel scoring system and algorithm for classifying chronic rhinosinusitis: the JESREC Study*. Allergy 2015;70:995-1003. doi:10.1111/all.12644.
26. Gallo S, Russo F, Mozzanica F, et al. *Prognostic value of the Sinonasal Outcome Test 22 (SNOT-22) in chronic rhinosinusitis*. Acta Otorhinolaryngol Ital 2020;40:113-21. doi:10.14639/0392-100x-n0364.
27. Ho J, Hamizan AW, Alvarado R, et al. *Systemic Predictors of Eosinophilic Chronic Rhinosinusitis*. American journal of rhinology & allergy 2018;32:252-7. doi:10.1177/1945892418779451.
28. Sreeparvathi A, Kalyanikuttyamma LK, Kumar M, et al. *Significance of Blood Eosinophil Count in Patients with Chronic Rhinosinusitis with Nasal Polyposis*. J Clin Diagn Res 2017;11:Mc08-mc11. doi:10.7860/jcdr/2017/25320.9445.
29. Brescia G, Barion U, Zanotti C, et al. *The prognostic role of serum eosinophil and basophil levels in sinonasal polyposis*. International forum of allergy & rhinology 2017;7:261-7. doi:10.1002/alr.21885.
30. Ravin KA, Loy M. *The Eosinophil in Infection*. Clinical reviews in allergy & immunology 2016;50:214-27. doi:10.1007/s12016-015-8525-4.
31. Kita H. *Eosinophils: multifunctional and distinctive properties*. International archives of allergy and immunology 2013;161 Suppl 2:3-9. doi:10.1159/000350662.

## ENDONASAL ENDOSCOPIC MANAGEMENT OF JNA: DEALING WITH THE LATERAL EXTENSION

*Benign nasal tumours 2, Building M1 Room Σ4, Sept 28, 10.15*

**BACKGROUND:** JUVENILE NASOPHARYNGEAL ANGIOFIBROMA (JNA) IS A COMBINED VASCULAR AND FIBROUS NEOPLASM WHICH ARISES FROM THE POSTERIOR-LATERAL WALL OF THE NOSE. DESPITE BEING MICROSCOPICALLY BENIGN, THE TUMOR FREQUENTLY EXHIBITS DESTRUCTIVE AND AGGRESSIVE BEHAVIOR. VARIOUS STAGING CLASSIFICATION HAD BEEN SUGGESTED, BUT THERE IS NO UNIVERSAL AGREEMENT WORLDWIDE ABOUT THE MOST ACCEPTED. EACH AUTHOR TAKES INTO CONSIDERATION DIFFERENT PERSPECTIVE. THE LATERAL EXTENSION INTO THE INFRATEMPORAL FOSSA OR FURTHER IS ONE OF THE MOST CHALLENGING AND DETERMINANT FACTORS IN THE MANAGEMENT OF THIS TUMOR, REGARDING THE CHOICE OF THE APPROACH TO ACHIEVE THE COMPLETE RESECTION...

**METHODOLOGY:** ONE HUNDRED forty-five (145) CASES OF JNA, 60 OF THEM WERE HAVING INFRATEMPORAL FOSSA EXTENSION OF VARIABLE DEGREE. ALL THESE CASES WERE OPERATED BY ENDONASAL ENDOSCOPIC RESECTION.

**CONCLUSION:** ENDONASAL ENDOSCOPIC RESECTION IS THE STATE OF ART MANAGEMENT FOR LARGE JNA WITH VARIABLE DEGREE OF LATERAL EXTENSION.

## Hide and seek: when magnetic resonance imaging finds endoscopic occult nasopharyngeal carcinoma

**Filipa Ferreira**<sup>(1)</sup>, Teresa Nunes<sup>(2)</sup>, Ricardo São Pedro<sup>(1)</sup>, Cristina Marques<sup>(2)</sup>, Carla André<sup>(1)</sup>, Vítor Proença<sup>(1)</sup>, Luis Antunes<sup>(1)</sup>

<sup>1</sup>ENT Department, Hospital Garcia de Orta, Almada, Portugal

<sup>2</sup>Neuroradiology Department, Hospital Garcia de Orta, Almada, Portugal

*Sinonasal malignancy 1, Building M1 Room E3, Sept 27, 14.45*

**Background:** Endoscopic examination has long been established as the preferential first step diagnostic procedure in suspected nasopharyngeal carcinoma (NC). However, some series show a significant percentage of tumours with normal or unsuspicious endoscopy, where NC is detected only on magnetic resonance imaging (MRI).

**Methodology:** The authors present three cases with normal endoscopic evaluation, where MRI had a decisive role on the diagnosis of NC.

**Results:** Two patients had a primary diagnosis and one patient had a tumoral recurrence of NC. The median age was 42 years, with male predominance. All patients presented with clinical signs of cranial nerve involvement, one of them had unilateral otitis media with effusion. The mean time between symptoms and diagnosis was 10 months. All had several unsuspicious endoscopies but MRI showed nasopharyngeal lateral recess lesions, two of them with skull base extension and involvement of the cavernous sinus and one with involvement of the jugular foramen and hypoglossal canal.

**Conclusions:** MRI is an accurate modality for the diagnosis and staging of NC and should even be considered in patients with normal endoscopy, particularly when cranial nerve involvement is present. MRI may play a crucial role in guiding biopsies when endoscopic evaluation is negative.

**Key words:** Nasopharyngeal carcinoma, magnetic resonance imaging, endoscopy

### Literature

1 - King AD, Woo JKS, Ai QY, Chan JSM, Lam WKJ, Tse IOL, Bhatia KS, Zee BCY, Hui EP, Ma BBY, Chiu RWK, van Hasselt AC, Chan ATC, Lo YMD, Chan KCA. Complementary roles of MRI and endoscopic examination in the early detection of nasopharyngeal carcinoma. *Ann Oncol*. 2019 Jun 1;30(6):977-982. doi: 10.1093/annonc/mdz106. PMID: 30912815.

2 - King AD, Vlantis AC, Bhatia KS, Zee BC, Woo JK, Tse GM, Chan AT, Ahuja AT. Primary nasopharyngeal carcinoma: diagnostic accuracy of MR imaging versus that of endoscopy and endoscopic biopsy. *Radiology*. 2011 Feb;258(2):531-7. doi: 10.1148/radiol.10101241. Epub 2010 Dec 3. PMID: 21131580.

3 - Wang KH, Austin SA, Chen SH, Sonne DC, Gurushanthaiah D. Nasopharyngeal Carcinoma Diagnostic Challenge in a Nonendemic Setting: Our Experience with 101 Patients. *Perm J*. 2017;21:16-180. doi: 10.7812/TPP/16-180. PMID: 28609261; PMCID: PMC5469434.

4 - Chen YP, Chan ATC, Le QT, Blanchard P, Sun Y, Ma J. Nasopharyngeal carcinoma. *Lancet*. 2019 Jul 6;394(10192):64-80. doi: 10.1016/S0140-6736(19)30956-0. Epub 2019 Jun 6. PMID: 31178151.

5 - Guo R, Mao YP, Tang LL, Chen L, Sun Y, Ma J. The evolution of nasopharyngeal carcinoma staging. *Br J Radiol*. 2019 Oct;92(1102):20190244. doi: 10.1259/bjr.20190244. Epub 2019 Jul 12. PMID: 31298937; PMCID: PMC6774596.

6 - Shayah A, Wickstone L, Kershaw E, Agada F. The role of cross-sectional imaging in suspected nasopharyngeal carcinoma. *Ann R Coll Surg Engl*. 2019 May;101(5):325-327. doi:



**Rationale and background:**

Invasive fungal sinonasal disease has emerged as a more vital health problem in modern times because of increased travel into/out of endemic areas, immune deficient states; the more prevalent use of long-term, broad-spectrum antibiotic therapy, the poorly-controlled diabetes with a marked rise of the incidence in the Covid 19 pandemic era. and of course, the increased awareness and improved means of clinical detection and laboratory diagnosis.

Classification into acute and chronic types had evolved. This disease has a high morbidity and mortality rates. Surprisingly, not only adults, who could suffer, but also it may affect immunocompromised children. Unlike adult invasive fungal Rhinosinusitis, the prognosis in the pediatric age group is much better due to many reasons: Normal blood vessels in children, unlike the diseased BV in adults and the acute nature of the underlying disease, which is ready reversible with prompt treatment.

**Methodology:** This study was conducted on 70 children with acute leukemia (46 female, 24 male), age range 2 to 19 years, 5 cases developed acute invasive fungal sinusitis. Incidence, clinical presentation, diagnosis, treatment and outcome were evaluated.

**Conclusion:** Invasive fungal rhinosinusitis is a disease entity which can be seen, although rare, in children with suppressed immunity. The early diagnosis and prompt are mandatory to achieve a favorable prognosis.

# EFFICIENT MUCOSAL ROUTE OF IMMUNOTHERAPY WITH TRANSGENIC RICE SEEDS EXPRESSING HYPOALLERGENIC WHOLE T CELL EPITOPES OF Cryj1 AND Cryj2 -an investigation in murine model of cedar pollinosis at eliciting phase-

**Hideyuki Kawauchi**<sup>1</sup>, Takaya Yamada<sup>2</sup>, Noriaki Aoi<sup>3</sup>, Ichiro Morikura<sup>3</sup>, Hidenori Takagi<sup>4</sup>, Fumio Takaiwa<sup>4</sup>

<sup>1</sup>Department of Microbiology, Shimane University, Faculty of Medicine, Izumo City, Japan, <sup>3</sup>Department of Otorhinolaryngology, Shimane University, Faculty of Medicine, Izumo city, Japan, <sup>4</sup>National Institute of Agrobiological Sciences, Ministry of Agriculture, Japan

*Allergic Rhinitis 1, Building M1 Room E3, Sept 28, 10.15*

**Background:** Allergen-specific subcutaneous immunotherapy with Japanese cedar pollen extract has been employed to desensitize patients with cedar pollinosis. Sublingual immunotherapy with cedar pollen extract is most recently developed and permitted in Japan to be utilized in clinical routine as a more safe and effective method. For the last decade, we have been investigating the therapeutic effect of mucosal route of administration of transgenic rice (Tg-rice) seeds, which contain T-cell epitopes of Cryj1 and Cryj2, on murine allergic rhinitis models at the induction phase and reported its clinical efficacy to actually attenuate nasal symptom<sup>1,2,3</sup>. However, its therapeutic effect has not been examined at the eliciting phase. Therefore, in this study, we have examined the effect of mucosal route of administration such as natural feeding and sublingual route, at the eliciting phase in a murine model of cedar pollinosis.

**Methodology:** Three different groups of Balb/c mice (N=7) were administered with Tg-rice seeds with a protocol. For natural feeding, Tg-rice introduced for two week. For an induction of murine model of cedar pollinosis, mice were systemically sensitized by intraperitoneal injections of 100µg of Cryj antigens with 5mg alum once a week for three times, and then intranasally challenged with 1 mg of Cryj for 14 days. Clinical symptoms were evaluated by counting the number of sneeze and scratch in 2 minutes at final intranasal challenge of Cryj antigens (1<sup>st</sup> intranasal challenge), to make sure if local sensitization could be the case. And later on so called eliciting phase of mucosal route of immunotherapies were performed and examined whether they are effective or not to downregulate nasal symptom after intranasal rechallenge of antigens with Cryj antigens (2<sup>nd</sup> intranasal challenge).

**Results:** The numbers of sneezing and scratching after in three different group of mice after 1<sup>st</sup> intranasal challenge indicated that these mice was well locally sensitized with Cryj antigen. The numbers of sneezing and scratching after final intranasal challenge in mice naturally fed with Tg-rice powder at eliciting phase were significantly decreased, in comparison with control non-Tg-rice powder. The numbers of sneezing and scratching after intranasal challenge in mice sublingually administered with Tg-rice powder at eliciting phase were also significantly decreased as well in comparison with control non-Tg-rice powder.

**Conclusion :** We previously demonstrated the efficacy of sublingual administration or natural feeding of Tg-rice at induction phase to attenuate nasal symptoms in murine model of cedar pollinosis<sup>4</sup>. In this study, this efficacy was demonstrated even at eliciting phase of mucosal route of administration such as natural feeding or sublingual administration. These results might be extrapolated into therapeutic immunotherapy for patients with cedar pollinosis. Now clinical trial is on-going as Phase I with enteric capsules containing Tg-rice powder, so clinical efficacy will be confirmed in the near future.

Key words: allergic rhinitis, cedar pollinosis, Transgenic Rice, Mucosal route immunotherapy



Surgiflo® hemostatic matrix vs NasoPore® nasal packing following KTP laser surgery for hereditary hemorrhagic telangiectasia: a randomized controlled trial.

**Justin M. Pyne**, Scott Murray, Andy Song, Brandon Rosvall, David W. J. Cote

*Department of Surgery, Division of Otolaryngology – Head and Neck Surgery, University of Alberta, Edmonton, Alberta, Canada*

*Abstract Session 32, Building M2 CR1, Sept 28, 14:45 - 16:15*

**Background:** Nasal packing postoperatively follow KTP laser surgery for hereditary hemorrhagic telangiectasia (HHT) has garnered mixed reviews. The purpose of this study was to compare a hemostatic fibrin matrix with traditional nasal packing following this procedure in terms of patient pain and comfort.

**Methodology:** This was a double-blinded non-inferiority study. Participants were selected from the practice of a single surgeon working in an academic center and randomized to the treatment group (Surgiflo®) or the control group (NasoPore®). During the first follow-up visit, each subject completed a comfort questionnaire, and a visual questionnaire was completed by the clinician. Non-parametric statistical analysis was employed with a p value of < 0.05 being considered significant.

**Results:** Fourteen patients were included in each group. The treatment group reported significantly less pain than the control group ( $p=0.043$ , S.D. .034-1.74). There was one major bleed in the control group following premature packing removal before follow-up due to discomfort. There was a trend towards less obstruction and facial pressure in the treatment group and less crusting in the control group, although these were not statistically significant.

**Conclusion:** Surgiflo® hemostatic matrix as nasal packing may offer a more comfortable recovery for the patient than traditional methods following KTP treatment for intranasal HHT.

**Key words:** Hereditary hemorrhagic telangiectasis, epistaxis, comfort, KTP laser

## Fatal Rhino-Orbital-Cerebral Mucormycosis as a presenting sign of Acute Myeloid Leukemia

**Tiago Chantre<sup>1</sup>**, Bernardo Carvalho Araújo<sup>1</sup>, Mafalda Barroso<sup>1</sup>, Ezequiel Barros<sup>1</sup>

<sup>1</sup>Department of Otorhinolaryngology, Head and Neck Surgery, Centro Hospitalar Universitário de Lisboa Central, Lisbon, Portugal

*Rhinology – miscellaneous 3, Building M1 Room Σ1, Sept 27, 11.45*

**Background:** Mucormycosis is a rare and life-threatening invasive fungal infection that primarily affect immunocompromised patients.

**Methodology/Principal:** Case report of fatal mucormycosis in a previously thought to be healthy patient and review of the literature concerning mucormycosis and hematologic disease in the last 10 years.

**Results:** We present a 61 year old male without significant medical history who was admitted to the emergency department for pain, edema and decreased visual acuity in both eyes for 15 days. The patient CT-scan showed pachymeningitis, cerebellitis, thrombosis of the right cavernous sinus and pansinusitis. Due the worsening of the clinical situation, radical surgical resection was performed with sphenoethmoidectomy, repermeabilization of the frontal sinus and bi-orbital exenteration. Examination of the biological material revealed *Mucor* sp. as the etiological agent and isavuconazole IV and hyperbaric oxygen therapy was started. Myelogram and bone marrow biopsy established the diagnosis of Acute Myeloid Leukemia associated with myelodysplasia. Despite treatment with azacitadine the patient died after 5 cycles due to progression of the hematological disease.

**Conclusions:** We call for attention that mucormycosis can be a presenting sign of Acute Myeloid Leukemia

**Key words:** Acute Myeloid Leukemia; Mucormycosis; Cavernous Sinus Thrombosis

**Emma C. Richards**, Paresh P. Naik, Shahzada K. Ahmed

ENT Department, Queen Elizabeth Hospital Birmingham, Birmingham, UK

*Benign nasal tumours 1, Building M1 Room Σ3, Sept 29, 10.15*

**Background:** Juvenile nasopharyngeal angiofibroma (JNA) is a locally aggressive tumour accounting for approximately 0.05% of all head and neck tumours. It is almost exclusively seen in young adolescent males. CT, MRI and angiography assist in defining the location, extent and relationship to neurovascular structures and the blood supply to the tumour, facilitating surgical planning. Pre-operative embolisation can give the impression of tumour shrinkage leading to incomplete resection.

**Methodology/Principal:** We propose undertaking navigation protocol CT immediately post embolisation facilitates surgical resection as the coil can be used as a landmark, improving resection rates and outcomes. For the past six years we have been using this principle.

**Results:** Three patients have been treated for JNA at our centre since 2015 and had imaging following this principle. They were all Radkowski type 2 JNAs. All patients have been successfully treated with no evidence of recurrence to date.

**Conclusions:** Post-embolisation scans enable accurate identification of the extent of the tumour post-embolisation, allowing the surgeon to use intraoperative surgical navigation to reach the embolisation coils and the main feeding arteries to the tumour. This ultimately facilitates the more radical resections required for this condition.

**Key words:** Nose Neoplasms, image guided surgery, angiofibroma

#### Literature

López, F., Triantafyllou, A., Snyderman, C. H., Hunt, J. L., Suárez, C., Lund, V. J., ... Ferlito, A. (2017). Nasal juvenile angiofibroma: Current perspectives with emphasis on management. *Head & Neck*, 39(5), 1033–1045. doi:10.1002/hed.24696

Lloyd G, Howard D, Lund VJ, Savy L. Imaging for juvenile angiofibroma. *J Laryngol Otol* 2000;114:727–730.

Mann WJ, Jecker P, Amedee RG. Juvenile angiofibromas: changing surgical concept over the last 20 years. *Laryngoscope* 2004;114:291–293

**Catrinel B. Simion-Antonie<sup>1</sup>**, Șerban V. G. Berteșteanu<sup>1,2</sup>, Bogdan Popescu<sup>1,2</sup>, Liliana Nițu<sup>1,2</sup>, Alina Oancea<sup>1,2</sup>, Gloria S. Munteanu<sup>1,3</sup>, Paula L. Bejenaru<sup>1,2</sup>, Mihnea Condeescu-Cojocăriță<sup>1,2</sup>, Alexandru Nicolaescu<sup>1,4</sup>, Anca I. Cîrstea<sup>2</sup>, Luiza M. Sirețeanu<sup>2</sup>, Ruxandra I. Nedelcu<sup>2</sup>, Irina Oașă<sup>2</sup>, Simona A. Rujan<sup>2</sup>, Bianca P. Taher<sup>2</sup>, Teodora E. Diaconu<sup>2</sup>, Amer Othman<sup>2</sup>, Iulia Vetrician<sup>2</sup>, Cătălin C. Mihalcea<sup>2</sup>, Mihai D. Tudosie<sup>2</sup>, Mădălin Magdan<sup>2</sup>, Cristian C. Paval<sup>2</sup>, Alexandru G. Enea<sup>2</sup>, Păun Oana<sup>5</sup>, Grigore Raluca<sup>1,2</sup>

<sup>1</sup>Universitatea de Medicină și Farmacie “Carol Davila”, Bucharest (ROMANIA), <sup>2</sup>Spitalul Clinic Colțea, Bucharest (ROMANIA), <sup>3</sup>Spitalul Universitar de Urgență Militar Central “Carol Davila”, Bucharest (ROMANIA), <sup>4</sup>Spitalul MAI Prof. Dr. Dimitrie Gerota, Bucharest (ROMANIA), <sup>5</sup>Clinica O.R.L.- Spitalul Județean de Urgență Râmnicu Vâlcea (ROMANIA)

*Sinonasal malignancy 2, Building M1 Room Σ3, Sept 28, 14.45*

**Background:** Malignant tumors of the nasal cavity and paranasal sinuses are rare tumors, with insidious onset and late diagnosis. Orbital involvement is a sign of advanced disease and is associated with a poor prognosis.

**Methodology/Principal:** The aim of this paper is to present a series of cases of advanced sino-nasal malignancies with involvement of the orbit, treated in our clinic over a period of three years (2018 – 2021). Management of these tumors requires a multidisciplinary approach, a combined modality therapy. Regarding the surgical treatment, either endoscopic or open approach, a complete resection with clear margins is mandatory.

**Results:** In such advanced cases, the external approach is often necessary despite the progress of endoscopic surgery. Patients often suffer from mutilating interventions, but they can be lifesaving. The risks, possible complications and outcomes of these complex procedures must be clearly explained to the patients prior surgery.

**Conclusions:** Sino-nasal malignancies are often diagnosed in an advanced stage, due to the misleading signs and symptoms. Despite the fact that patients can undergo extensive cosmetic and psychological trauma, complete surgical extirpation remains the primary goal. A well-planned reconstruction and rehabilitation helps in maintaining the quality of life.

**Key words:** sino-nasal, carcinoma, orbit, paranasal sinuses

**Medeiros Nuno<sup>1</sup>**

*Septal and turbinate surgery 2, Building M2 Study Hall, Sept 29, 14.45*

**Introduction:** Post-nasal surgery epistaxis is an infrequent complication, occurring in 0.9-5.8% of cases. Traditionally, many risk factors are pointed as possible culprits, but no consensus exists in the literature about their specific importance. The present study analyzed the most cited risk factors.

**Material and Methods:** Retrospective study involving patients submitted to naso-sinus surgery in a 24-months period. Relevant demographic and clinical variables were retrieved. Post-surgical epistaxis was considered if happening in the first month post-operative. Epistaxis incidence and possible associated risk factors were analyzed.

**Results:** 592 patients (39.2% females; mean of age 37.6 +/- 15.4 y.o) were analyzed. Epistaxis incidence was 4.7%. Hemorrhage was significantly correlated with nasal packing method ( $p=0,046$ ). Epistaxis was not correlated with other studied risk factors, namely age ( $p=0,30$ ), type of surgery ( $p=0,59$ ), anti-aggregants ( $p=0,64$ ); anti-coagulants ( $p=0,86$ ), altered coagulation tests ( $p=0,86$ ), hypertension ( $p=0,54$ ) or season of surgery ( $p=0,67$ )

**Conclusions:** Most frequently cited risk factors were not relevant in the studied sample, with the exception of nasal packing. Epistaxis frequency was in the expected range.

A case of intractable and recurrent epistaxis. A puzzle yet to be solved.

**Panagiotis Solomos<sup>1</sup>, Sotirios Karamagkiolas<sup>1</sup>, Nikolaos Papadimitriou<sup>1</sup>, Maragkoudakis Pavlos<sup>1</sup>, Alexander Delides<sup>1</sup>**

<sup>1</sup>National & Kapodistrian University of Athens, 2<sup>nd</sup> Otolaryngology Department, "Attikon" University Hospital, Athens, Greece.

*Epistaxis and HHT 2, Building M1 Room Σ3, Sept 29, 11.45*

Some cases of epistaxis can challenge even the most experienced and skilled otolaryngologists. Ultimately though, whether through nasal packing, in-office cauterization, surgery or embolization, most nosebleeds can be managed and controlled.

Here we present a case of a female patient who presented to our department with intractable and recurrent episodes of epistaxis. She was subjected to 2 embolizations, endoscopic sphenopalatine artery ligation, bilateral anterior and posterior ethmoidal artery ligations through Lynch incisions and anteroposterior packing placed under general anesthesia. After each method we attempted, the epistaxis episodes would recur. In the sphenoid a site of osteoradionecrosis was observed. This was due a history of a pituitary adenoma which was treated by transphenoidal resection and subsequent γknife irradiation. Attempts to cover the site with grafts (temporal fascia, muscle with fascia) all failed as they were expelled each time by subsequent nosebleeds. As the frequency and the intensity of epistaxis episodes decreased, hyperbaric oxygen therapy was implemented to help promote healing in the site of osteoradionecrosis which had encouraging results.

The patient still suffers from occasional mild epistaxis. We chose to share this case to show that sometimes epistaxis can be extremely difficult to treat and to stir up a constructive debate.

**Key words:** epistaxis, embolization, angiography, osteoradionecrosis

Raquel Freitas<sup>1</sup>, **Henrique Teixeira**<sup>2</sup>, Maria Helena Rosa<sup>2</sup>, Luís Antunes<sup>2</sup>, Maria José Santos<sup>1</sup>

<sup>1</sup>Rheumatology Department, Hospital Garcia de Orta, Almada, Portugal , <sup>2</sup>Otorhinolaryngology Department, Hospital Garcia de Orta, Almada, Portugal

*Granulomatous diseases of the nose 1, Building M1 Room Σ2, Sept 28, 11.45*

**Background:** Ear, nose and throat (ENT) involvement is common in ANCA associated vasculitis (AAV) and frequently precede other manifestations. It has been reported that ENT involvement is associated with lower mortality rates. Our objective was to characterize ENT involvement in AAV and describe the survival of those patients.

**Methodology/Principal:** Clinical and immunologic characteristics, medication and survival were analysed in adult AAV patients followed in our hospital.

**Results:** In total, 25 patients were evaluated, 64% females, mean age at diagnosis 56±16.5 years. The most common AAV subtype was Eosinophilic Granulomatosis with Polyangiitis (40%), followed by Granulomatosis with Polyangiitis (36%) and Microscopic Polyangiitis (24%). ENT involvement was present in 76% and in 64% was one of the inaugural manifestations. No differences in demographic and clinic features were found between patients with or without ENT involvement. The most frequent ENT symptoms were sensorineural deafness (57.9%), nasal ulceration (50%) and rhinorrhoea (47.4%). Most patients were treated with glucocorticoids (92%) and 68% with immunosuppressants. Survival rates were better in patients with ENT involvement when compared to patients without ENT involvement (p=0.026).

**Conclusions:** Our study confirms that ENT involvement is one of the most frequent clinical features and is associated with better survival in AAV patients.

**Key words:** ANCA-Associated Vasculitis, Granulomatosis with Polyangiitis, Eosinophilic Granulomatous Vasculitis, Microscopic Polyangiitis, Otorhinolaryngology, Rheumatology

## Occupational exposure influences control of disease in patients with chronic rhinosinusitis

**D.A.E. Dietz de Loos<sup>1</sup>**, S. Ronsmans<sup>2</sup>, M.E. Cornet<sup>1</sup>, P.W. Hellings<sup>1,3</sup>, V. Hox<sup>4, 5</sup>, W.J. Fokkens<sup>1</sup>, S. Reitsma<sup>1</sup>

<sup>1</sup>Department of Otorhinolaryngology, Amsterdam University Medical Centres, location AMC, Amsterdam, The Netherlands, <sup>2</sup>Department of Public Health and Primary Care, Centre for Environment and Health, KU Leuven, Leuven, Belgium, <sup>3</sup>Department of Otorhinolaryngology – Head and Neck Surgery, University Hospitals Leuven, Leuven, Belgium, <sup>4</sup>Department of Otorhinolaryngology, Cliniques Universitaires Saint-Luc, Brussels, Belgium, <sup>5</sup>Institute of Experimental and Clinical Research (IREC), Pole of Pulmonology, ENT and Dermatology; UCLouvain, Brussels, Belgium

*CRS - diagnosis and investigations 2, Building M1 Room S2, Sept 28, 10.15*

**Background:** Chronic rhinosinusitis (CRS) is a frequent condition that is treated by endoscopic sinus surgery (ESS) when medical treatment fails. Irritating or sensitizing airborne agents can contribute to uncontrolled CRS. A prior study showed a linear correlation between occupational exposure and the number of ESS.

**Methods:** In this cross-sectional study we tested the hypothesis that occupational exposure is a risk for undergoing ESS. We sent questionnaires enquiring occupational exposure in patients with CRS with nasal polyps (CRSwNP) or CRS without nasal polyps (CRSsNP). An expert assessed blindly the reported work exposures to inhaled agents. The relationship between occupational exposure on undergoing ESS was analysed.

**Results:** Among patients who underwent ESS (n=343), 30% reported a relevant occupational exposure, which is significantly higher than the 4.8% found among CRS patients that underwent no prior sinus surgery (n=21) ( $X^2=6.30$ ,  $p=0.04$ ). Besides occupational exposure (OR: 8.7; 95% CI: 1.15 – 65.71), self-reported doctor-diagnosed asthma (OR: 2; 95% CI: 0.93 – 5.70) were independent variables contributing to the chance of undergoing ESS.

**Conclusion:** In our study we confirm occupational exposure as a risk factor for uncontrolled CRS, if defined by undergoing ESS. In CRS patients with uncontrolled symptoms, the clinician should explore possible contribution of occupational exposure.

**Key words:** Occupational medicine, occupational exposure, paranasal sinus disease, control of disease, precision medicine



## Measuring control of disease in Chronic Rhinosinusitis; assessing the correlation between SNOT-22 and VAS.

**D.A.E. Dietz de Loos<sup>1,2</sup>**, M.E. Cornet<sup>3</sup>, C. Hopkins<sup>4</sup>, W.J. Fokkens<sup>2</sup>, S. Reitsma<sup>2</sup>

<sup>1</sup>Department of Otorhinolaryngology, Isala Hospital, Zwolle, The Netherlands, <sup>2</sup>Department of Otorhinolaryngology, Amsterdam University Medical Centres, location AMC, Amsterdam, The Netherlands, <sup>3</sup>Department of Otorhinolaryngology, Alrijne Hospital, Leiden, The Netherlands, <sup>4</sup>Department of Otorhinolaryngology, Guys and St Thomas Hospitals NHS Trust, London, United Kingdom

*CRS - diagnosis and investigations 2, Building M1 Room Σ2, Sept 28, 10.15*

**Background:** In chronic rhinosinusitis (CRS), aim of treatment is control of disease. EPOS2020 suggested the use of VAS measurement on several symptoms. We aim to determine if the SNOT-22 can be replaced by a single VAS 'overall sinus symptom' question, and to investigate or even validate the EPOS2020 suggestion to use a VAS or SNOT-22 scores for symptom-specific questions when determining control of disease.

**Methods:** Analysis were made on correlations between SNOT-22 (sub)scores, a single VAS, and symptom-specific questions from consecutive patients with CRS visiting our tertiary referral rhinologic clinic for the first time.

**Results:** 563 CRS patients were included. Correlation between VAS 'overall sinus symptoms' and SNOT-22 was moderate ( $r=.563$ ). Correlations of individual items were good ( $r>0.8$ ). An individual item score of  $VAS>50$  corresponds well with SNOT score  $>3$  and seems valid to use in measuring control of disease (controlled, partially controlled and uncontrolled) as proposed in EPOS2020.

**Conclusion:** A total SNOT-22 score and an overall VAS for sinus symptoms measure different dimensions of CRS and are not simply interchangeable. Item-specific scores show a good correlation. For definition of CRS disease control, as per EPOS2020, the use of symptom-specific VAS  $>50$  or SNOT  $>3$  is valid.

**Key words:** paranasal sinus disease, health-related quality of life, control of disease, precision medicine

## Challenges in the management of complicated rhinosinusitis in patients SARS-COV2 positive

**Catrinel B. Simion-Antonie<sup>1</sup>**, Șerban V. G. Berteșteanu<sup>1,2</sup>, Bogdan Popescu<sup>1,2</sup>, Liliana Nițu<sup>1,2</sup>, Gloria S. Munteanu<sup>1,3</sup>, Paula L. Bejenaru<sup>1</sup>, Mihnea Condeescu-Cojocăriță<sup>1,2</sup>, Alexandru Nicolaescu<sup>1,4</sup>, Anca I. Cîrstea<sup>2</sup>, Irina Oașă<sup>2</sup>, Simona A. Rujan<sup>2</sup>, Bianca P. Taher<sup>2</sup>, Teodora E. Diaconu<sup>2</sup>, Amer Othman<sup>2</sup>, Iulia Vetricean<sup>2</sup>, Alexandru G. Enea<sup>2</sup>, Grigore Raluca<sup>1,2</sup>

<sup>1</sup>Universitatea de Medicină și Farmacie "Carol Davila", Bucharest (ROMANIA), <sup>2</sup>Spitalul Clinic Colțea, Bucharest (ROMANIA), <sup>3</sup>Spitalul Universitar de Urgență Militar Central "Carol Davila", Bucharest (ROMANIA), <sup>4</sup>Spitalul MAI Prof. Dr. Dimitrie Gerota, Bucharest (ROMANIA)

*Acute Rhinosinusitis 1, Building M1 Room Σ1, Sept 27, 10.15*

**Background:** The COVID-19 pandemic has had a great impact on the healthcare system all over the world. Patients had limited access to medical care and SARS-COV2 coinfection influenced the management and the outcome of head and neck pathologies. Complications of acute rhinosinusitis are uncommon, affecting mostly the immunocompromised patients; however, it can be found in previously healthy patients.

**Methodology/Principal:** The access to medical care was limited during the COVID-19 pandemic so patients presented late to the ENT ward, thus raising the risk for complications. The management of patients that suffered from acute rhinosinusitis and were detected SARS-COV2 positive had certain particularities and represents a challenge for any rhinologist.

**Results:** The protocol of interacting with a patient diagnosed with COVID-19 is very strict and examination, medical and, most importantly, surgical treatment have certain particularities that make the management difficult. Starting with the isolation, waiting for the test results and ending with performing endoscopic sinus surgery while wearing chemise and three facial masks, each step is crucial for the outcome. Also, the evolution of COVID-19 is unpredictable and influences the treatment and outcome of complicate rhinosinusitis.

**Conclusions:** Complicated rhinosinusitis in a SARS-COV2 positive patient requires a multidisciplinary approach and a multimodal therapy, representing a challenge. COVID-19 is a yet incompletely know disease and its evolution and influence over other pathologies is a subject to nowadays research.

**Key words:** COVID-19, rhinosinusitis, complications

# Oral cavity morphology among children at risk of Obstructive Sleep Apnea Syndrome

Zofia Burska<sup>1</sup>, **Eliza Brożek-Mądry**<sup>2</sup>, Marcin Burghard<sup>3</sup>, Janusz Sierdziński<sup>4</sup>, Antoni Krzeski<sup>2</sup>

<sup>1</sup>Czerniakowski Hospital, Warsaw, Poland <sup>2</sup>Department of Otorhinolaryngology, Medical University of Warsaw, Warsaw, Poland <sup>3</sup>Medical Center in Ostrołęka, Ostrołęka, Poland <sup>4</sup>Department of Medical Informatics and Telemedicine, Medical University of Warsaw, Warsaw, Poland

*Snoring and OSA 1, Building M2 CR2, Sept 28, 14.45*

**Background:** Obstructive sleep apnea syndrome (OSAS) is a respiratory disorder that occurs during sleep with partial or complete obstruction of the upper airways that leads to impaired ventilation. The aim of this study was to evaluate oral cavity morphology in children at risk of OSAS.

**Methodology/Principal:** The study included children aged 3–17. The risk of OSAS was evaluated with the Pediatric Sleep Questionnaire (PSQ); afterwards, children at risk of OSAS were enrolled in the study group. A control group was randomly established from patients with negative PSQ results. The oral cavity morphology evaluation included assessment of oropharynx with Mallampati classification, palatine tonsils with the Pirquet scale, occlusion, lingual frenulum and presence of the high-arched palate.

**Results:** 135 children were evaluated, 67 in the study and 68 in the control group. Among children from the study group the presence of the higher grades in the Mallampati classification and the Pirquet scale, crossbite, high arched palate and short lingual frenulum were significantly more frequent.

**Conclusions:** The evaluation of oral morphology is an important part of pediatric examination. Enlarged palatine tonsils, higher scores in the Mallampati classification, crossbite, short lingual frenulum, and high-arched palate may suggest abnormal breathing during sleep in children.

Please do not include any citations in the abstract. Avoid specialist abbreviations if possible

**Key words:** Obstructive Sleep Apnea Syndrome, Oral Cavity, Palatine Tonsils, Ankyloglossia

## Literature

1. Kaditis AG, Alonso Alvarez ML, Boudewyns A, et al. Obstructive sleep disordered breathing in 2- to 18-year-old children: diagnosis and management. *Eur Respir J*. 2016;47(1):69-94.
2. Krzeski A, Burghard M. Obstructive sleep disordered breathing in children - an important problem in the light of current European guidelines. *Otolaryngol Pol*. 2018;72(5):9-16.
3. Blechner M, Williamson AA. Consequences of Obstructive Sleep Apnea in Children. *Curr Probl Pediatr Adolesc Health Care*. 2016;46(1):19-26.
4. Gulotta G, Iannella G, Vicini C, et al. Risk Factors for Obstructive Sleep Apnea Syndrome in Children: State of the Art. *Int J Environ Res Public Health*. 2019;16(18).
5. Villa MP, Evangelisti M, Barreto M, Cecili M, Kaditis A. Short lingual frenulum as a risk factor for sleep-disordered breathing in school-age children. *Sleep Med*. 2020;66:119-122.

6. Guilleminault C, Huseni S, Lo L. A frequent phenotype for paediatric sleep apnoea: short lingual frenulum. *ERJ Open Res.* 2016;2(3).
7. Nuckton TJ, Glidden DV, Browner WS, Claman DM. Physical examination: Mallampati score as an independent predictor of obstructive sleep apnea. *Sleep.* 2006;29(7):903-908.
8. Grippaudo C, Paolantonio EG, Antonini G, Saulle R, La Torre G, Deli R. Association between oral habits, mouth breathing and malocclusion. *Acta Otorhinolaryngol Ital.* 2016;36(5):386-394.
9. Galeotti A, Festa P, Viarani V, et al. Prevalence of malocclusion in children with obstructive sleep apnoea. *Orthod Craniofac Res.* 2018;21(4):242-247.
10. Samsoon GL, Young JR. Difficult tracheal intubation: a retrospective study. *Anaesthesia.* 1987;42(5):487-490.
11. A. Dobrzańska JR. *Pediatrica. Podręcznik do Państwowego Egzaminu Lekarskiego i egzaminu specjalizacyjnego.* In: Wrocław: Urban&Partner; 2005:p. 10.
12. Kotlow LA. Ankyloglossia (tongue-tie): a diagnostic and treatment quandary. *Quintessence Int.* 1999;30(4):259-262.
13. Villa MP, Paolino MC, Castaldo R, et al. Sleep clinical record: an aid to rapid and accurate diagnosis of paediatric sleep disordered breathing. *Eur Respir J.* 2013;41(6):1355-1361.
14. Kim JH, Guilleminault C. The nasomaxillary complex, the mandible, and sleep-disordered breathing. *Sleep Breath.* 2011;15(2):185-193.
15. Kumar HV, Schroeder JW, Gang Z, Sheldon SH. Mallampati score and pediatric obstructive sleep apnea. *J Clin Sleep Med.* 2014;10(9):985-990.
16. Overland B, Berdal H, Akre H. Obstructive sleep apnea in 2-6 year old children referred for adenotonsillectomy. *Eur Arch Otorhinolaryngol.* 2019;276(7):2097-2104.
17. Liistro G, Rombaux P, Belge C, Dury M, Aubert G, Rodenstein DO. High Mallampati score and nasal obstruction are associated risk factors for obstructive sleep apnoea. *Eur Respir J.* 2003;21(2):248-252.
18. Kale SS, Kakodkar P, Shetiya SH. Assessment of oral findings of dental patients who screen high and no risk for obstructive sleep apnea (OSA) reporting to a dental college - A cross sectional study. *Sleep Sci.* 2018;11(2):112-117.
19. Kang KT, Chou CH, Weng WC, Lee PL, Hsu WC. Associations between adenotonsillar hypertrophy, age, and obesity in children with obstructive sleep apnea. *PLoS One.* 2013;8(10):e78666.
20. Wang J, Zhao Y, Yang W, et al. Correlations between obstructive sleep apnea and adenotonsillar hypertrophy in children of different weight status. *Sci Rep.* 2019;9(1):11455.

## Short lingual frenulum and head-forward posture in children with the risk of Obstructive Sleep Apnea

**Eliza Brożek-Madry**<sup>1</sup>, Zofia Burska<sup>2</sup>, Zuzanna Steć<sup>1</sup>, Marcin Burghard<sup>3</sup>, Antoni Krzeski<sup>1</sup>

<sup>1</sup>Department of Otorhinolaryngology, Medical University of Warsaw, Warsaw, Poland, <sup>2</sup>Czerniakowski Hospital, Warsaw, Poland, <sup>3</sup>Medical Center in Ostrołęka, Ostrołęka, Poland

*Snoring and OSA 1, Building M2 CR2, Sept 28, 14.45*

**Background:** Recent studies have shown that short lingual frenulum is a potential risk factor for obstructive sleep apnea syndrome (OSAS) in children. The short frenulum leads to abnormal orofacial development and may contribute to sleep disordered breathing by narrowing the upper airways and increasing the risk of their collapsibility.

**Methodology/Principal:** Children aged 3-17 were included in the study. OSAS risk was assessed using Pediatric Sleep Questionnaire (PSQ). Children at risk of OSAS were enrolled into the study group and the control group was randomly established from patients with negative PSQ results. Physical examination, including head forward posture (HFP) and length of the tongue frenulum measurement was performed. Guardians were asked to assess their child's time spent with electronic mobile devices (smartphones, tablets) and fill the I'M SLEEPY questionnaire.

**Results:** 135 children were evaluated, 67 in the study and 68 in the control group. Children in the study group had significantly shorter lingual frenulum, higher HFP, spent longer time using mobile devices and had higher prevalence of high-arched palate.

**Conclusions:** Conducted study identified a relationship between short lingual frenulum and the risk of OSAS in children. Furthermore, the use of mobile devices by children was also associated with a higher risk of sleep apnea.

Please do not include any citations in the abstract. Avoid specialist abbreviations if possible

**Key words:** Obstructive Sleep Apnea, Ankyloglossia, Posture, Mobile Devices

### Literature

1. Brockmann PE, Schaefer C, Poets A, Poets CF, Urschitz MS. Diagnosis of obstructive sleep apnea in children: a systematic review. *Sleep Med Rev.* 2013;17(5):331-40.
2. Marcus CL, Brooks LJ, Draper KA, Gozal D, Halbower AC, Jones J, et al. Diagnosis and management of childhood obstructive sleep apnea syndrome. *Pediatrics.* 2012;130(3):576-84.
3. Guilleminault C, Huseni S, Lo L. A frequent phenotype for paediatric sleep apnoea: short lingual frenulum. *ERJ Open Res.* 2016;2(3).
4. Huang YS QS, Berkowski JA, Guilleminault C. Short Lingual Frenulum and Obstructive Sleep Apnea in Children. *International Journal of Pediatric Research.* 2015;1:003.
5. Villa MP, Evangelisti M, Barreto M, Cecili M, Kaditis A. Short lingual frenulum as a risk factor for sleep-disordered breathing in school-age children. *Sleep Med.* 2020;66:119-22.
6. Srinivasan B, Chitharanjan AB. Skeletal and dental characteristics in subjects with ankyloglossia. *Prog Orthod.* 2013;14:44.

7. Walsh J. TD. Diagnosis and Treatment of Ankyloglossia in Newborns and Infants A Review. *JAMA Otolaryngology–Head & Neck Surgery*. 2017;143(10)::1032-9.
8. Wallace H, Clarke S. Tongue tie division in infants with breast feeding difficulties. *Int J Pediatr Otorhinolaryngol*. 2006;70(7):1257-61.
9. Pompeia LE, Ilinsky RS, Ortolani CLF, Faltin KJ. Ankyloglossia and Its Influence on Growth and Development of the Stomatognathic System. *Rev Paul Pediatr*. 2017;35(2):216-21.
10. Defabianis P. Ankyloglossia and its influence on maxillary and mandibular development. (A seven year follow-up case report). *Funct Orthod*. 2000;17(4):25-33.
11. Lopatiene K, Sidlauskas A, Vasiliauskas A, Cecyte L, Svalkauskiene V, Sidlauskas M. Relationship between malocclusion, soft tissue profile, and pharyngeal airways: A cephalometric study. *Medicina (Kaunas)*. 2016;52(5):307-14.
12. Olivi G, Signore A, Olivi M, Genovese MD. Lingual frenectomy: functional evaluation and new therapeutical approach. *Eur J Paediatr Dent*. 2012;13(2):101-6.
13. Fung B. Mouth breathing and abnormal posture in childhood sub-heath. Conference presentation - AAMS (Academy of Applied Myofunctional Sciences). Rome; 2018.
14. Piccin CF, Pozzebon D, Scapini F, Correa EC. Craniocervical Posture in Patients with Obstructive Sleep Apnea. *Int Arch Otorhinolaryngol*. 2016;20(3):189-95.
15. Jung SI, Lee NK, Kang KW, Kim K, Lee DY. The effect of smartphone usage time on posture and respiratory function. *J Phys Ther Sci*. 2016;28(1):186-9.
16. Han H, Lee S, Shin G. Naturalistic data collection of head posture during smartphone use. *Ergonomics*. 2019;62(3):444-8.
17. Rideout V. Zero to eight: children's media use in America 2013. Common sense media research study; 2013.
18. Burghard M, Brozek-Madry E, Krzeski A. Sleep disordered breathing in children - Diagnostic questionnaires, comparative analysis. *Int J Pediatr Otorhinolaryngol*. 2019;120:108-11.
19. Chervin RD, Weatherly RA, Garetz SL, Ruzicka DL, Giordani BJ, Hodges EK, et al. Pediatric sleep questionnaire: prediction of sleep apnea and outcomes. *Arch Otolaryngol Head Neck Surg*. 2007;133(3):216-22.
20. Kadmon G, Chung SA, Shapiro CM. I'M SLEEPY: a short pediatric sleep apnea questionnaire. *Int J Pediatr Otorhinolaryngol*. 2014;78(12):2116-20.
21. Kotlow LA. Ankyloglossia (tongue-tie): a diagnostic and treatment quandary. *Quintessence Int*. 1999;30(4):259-62.
22. Yoon AJ, Zaghi S, Ha S, Law CS, Guilleminault C, Liu SY. Ankyloglossia as a risk factor for maxillary hypoplasia and soft palate elongation: A functional - morphological study. *Orthod Craniofac Res*. 2017;20(4):237-44.
23. Johal A, Conaghan C. Maxillary morphology in obstructive sleep apnea: a cephalometric and model study. *Angle Orthod*. 2004;74(5):648-56.
24. Kim MS, Cha YJ, Choi JD. Correlation between forward head posture, respiratory functions, and respiratory accessory muscles in young adults. *J Back Musculoskelet Rehabil*. 2017;30(4):711-5.

## Acinic Cell Carcinoma of the Nasal Cavity: A case report

**Eleni Gkrinia<sup>1</sup>**, Fani Saini<sup>1</sup>, Charikleia Maiou<sup>1</sup>, Athanasios Fountarlis<sup>1</sup>, Christos Korais<sup>1</sup>, Charalampos Skoulakis<sup>1</sup>

<sup>1</sup>*Department of Otolaryngology-Head and Neck Surgery, University Hospital of Larisa, Prof. Charalampos Skoulakis, Larisa, Greece*

*Sinonasal malignancy 3, Building M2 CR2, Sept 29, 14.45*

**Background:** Acinic cell carcinoma is a rare malignant salivary gland tumour, constituting 1% of salivary gland neoplasms and 10% to 15% of sialocarcinomas. It appears predominately in the parotid gland, while its occurrence in different locations is unusual. It is believed to arise from the intercalated duct reserve cells, most commonly during the fifth and sixth decade of life. Only 15 cases of sinonasal acinic cell carcinoma have been published in the English literature. We report a case of acinic cell carcinoma originating in the left nasal cavity.

**Methodology/Principal:** An 83-year-old man, with a history of chronic obstructive pulmonary disease, coronary artery disease and alcohol abuse presented to the Otolaryngology Department mentioning unilateral nasal obstruction from 3 years. A computerized tomography was conducted, reporting a polypoid mass of the left nasal cavity, infiltrating the nasal bone and the overlying skin.

**Results:** The patient underwent an endoscopic polypectomy and the histopathological examination confirmed the diagnosis of acinic cell carcinoma. Post-operative radiotherapy was proposed, which was refused by the patient. Two years after the surgery, the patient remains free of disease.

**Conclusion:** Sinonasal acinic cell carcinoma is a rare entity that otolaryngologists should be aware of, in order for the adequate management to be accomplished.

**Key words:** acinic cell carcinoma, sinus, malignancy, nasal cavity

### Literature

1. VALERDIZ-CASASOLA S, SOLA J, PARDO-MINDAN FJ. Acinic cell carcinoma of the sinonasal cavity with intracytoplasmic crystalloids. *Histopathology*. 1993;23(4):382–4.
2. Von Biberstein SE, Spiro JD, Mancoll W. Acinic cell carcinoma of the nasal cavity. *Otolaryngol - Head Neck Surg*. 1999;120(5):759–62.
3. Neto AG, Pineda-Daboin K, Spencer ML, Luna MA. Sinonasal acinic cell carcinoma: A clinicopathologic study of four cases. *Head Neck*. 2005;27(7):603–7.

## Retrospective study analyzing demographics and intra- and postoperative treatment in the success of surgery of choanal atresia

**Carolina G. R. van Schaik**<sup>1</sup>, Steffen Paasch<sup>1</sup>, Sven Becker<sup>1</sup>

<sup>1</sup>Otolaryngology, Head and Neck Department, University Hospital of Tübingen, Tübingen, Germany

*Paediatric rhinology 2, Building M2 CR3, Sept 28, 11.45*

**Background:** Choanal Atresia is a congenital condition with the presence of a blockage from the nasal cavity to the nasopharynx. According to the German statistical Institute (Statistisches Bundesamt), the incidence in 2018 reached 2.74 in 10000 live births.

It can present unilaterally or bilaterally. As newborns are obligate nasal breathers, management of bilateral atresia has to be performed early after birth. As for unilateral atresia, optimal age for treatment was determined to be between 6 and 12 months in a recently published consensus.

The purpose of this study is to characterize the cohort of patients treated in the Department of Otolaryngology of the University Hospital of Tübingen for choanal atresia and, based in the demographic characteristics as well as intra- and postoperative treatment, identify factors for success or failure of the surgery.

**Methodology/Principal:** Retrospective observational study including 29 patients with minimum follow up of one year who underwent surgical endoscopic correction of both unilateral and bilateral choanal atresia in this institution from 2003 to 2019. Analysis of the demographics, intraoperative and postoperative treatment and results was performed.

Statistical analysis performed with SPSS version 25 (IBM). Multinomial logistic regression applied for categorical values. Comparisons performed with fischer test/ chi square where applicable. Significance level of 0.05.

**Results:** Population comprised 29 patients, 37.9% male and 62.1% female. The age varied from two days to 26 years old, with a mean of 5.82 years and SD 7.93. The weight of the patients varied between 1.8 kg and 85.0 kg, with a mean of 21.6 and SD 25.1. Unilateral choanal atresia was present in 58,6% and bilateral in 41,4%. 44,8% presented associated malformations. The number of procedures per patient performed in general anesthesia varied from one to nine, with a mean of 2.38 and Standard Deviation of 2.1, being this statistically significant higher for patients presenting with bilateral atresia with a p value of 0.001 \*. 21 patients had a tube (Vygon, France) placed at surgery. In 4 patients a drug eluting stent (Propel mini <sup>(R)</sup>-(Intersect ent, USA) was applied intraoperatively, without complications.

In unilateral choanal atresia, a surgical and functional success was attained in 88,2% of the cases. In bilateral cases it reached 75%.

We observed a strong linear relationship between the weight of the patient and the size of the choana perioperatively : R quadrat 0.673.

Weight and age achieved statistical significance in the logistic regression model ( p respectively 0.002\*and 0.001\*).

Weight inferior to 3kg at first surgery showed to be highly significant for the result of the surgery ( p 0.003\*,chi square test).

**Conclusions:**Age and weight of the surgery are determinant to the results of the surgical endoscopic treatment of choanal atresia.

In particular patients under 3 Kg had to undergo more procedures in order to achieve patency. We believe this has implications for counseling and in planning further studies addressing the optimal management of the surgical wound in this population.



**Key words:** Choanal, atresia, congenital, endoscopy, airway

## Literature

- Bangiyev, J. N., Govil, N., Sheyn, A., Hauptert, M., & Thottam, P. J. (2017). Novel Application of Steroid Eluting Stents in Choanal Atresia Repair: A Case Series. *Annals of Otolaryngology and Laryngology*, 126(1), 79-82.
- Brihaye, P., Delpierre, I., De Ville, A., Johansson, A. B., Biarent, D., & Mansbach, A. L. (2017). Comprehensive management of congenital choanal atresia. *Int J Pediatr Otorhinolaryngol*, 98, 9-18.
- De Freitas, R. P., & Berkowitz, R. G. (2012). Bilateral choanal atresia repair in neonates--a single surgeon experience. *Int J Pediatr Otorhinolaryngol*, 76(6), 873-878.
- Eladl, H. M., & Khafagy, Y. W. (2016). Endoscopic bilateral congenital choanal atresia repair of 112 cases, evolving concept and technical experience. *Int J Pediatr Otorhinolaryngol*, 85, 40-45.
- Hengerer, A. S., Brickman, T. M., & Jeyakumar, A. (2008). Choanal atresia: embryologic analysis and evolution of treatment, a 30-year experience. *Laryngoscope*, 118(5), 862-866.
- Ibrahim, A. A., Magdy, E. A., & Hassab, M. H. (2010). Endoscopic choanoplasty without stenting for congenital choanal atresia repair. *Int J Pediatr Otorhinolaryngol*, 74(2), 144-150.
- Kancherla, V., Romitti, P. A., Sun, L., Carey, J. C., Burns, T. L., Siega-Riz, A. M., . . . National Birth Defects Prevention, S. (2014). Descriptive and risk factor analysis for choanal atresia: The National Birth Defects Prevention Study, 1997-2007. *Eur J Med Genet*, 57(5), 220-229.
- Karligkiotis, A., Farneti, P., Gallo, S., Pusateri, A., Zappoli-Thyrion, F., Sciarretta, V., . . . Pasquini, E. (2017). An Italian multicentre experience in endoscopic endonasal treatment of congenital choanal atresia: Proposal for a novel classification system of surgical outcomes. *J Craniomaxillofac Surg*, 45(6), 1018-1025.
- Kim, H., Park, J. H., Chung, H., Han, D. H., Kim, D. Y., Lee, C. H., & Rhee, C. S. (2012). Clinical features and surgical outcomes of congenital choanal atresia: factors influencing success from 20-year review in an institute. *Am J Otolaryngol*, 33(3), 308-312.
- Kinis, V., Ozbay, M., Akdag, M., Cetin, M., Gul, A., Yilmaz, B., . . . Topcu, I. (2014). Patients with congenital choanal atresia treated by transnasal endoscopic surgery. *J Craniofac Surg*, 25(3), 892-897.
- Moreddu, E., Rizzi, M., Adil, E., Balakrishnan, K., Chan, K., Cheng, A., . . . Nicollas, R. (2019). International Pediatric Otolaryngology Group (IPOG) consensus recommendations: Diagnosis, pre-operative, operative and post-operative pediatric choanal atresia care. *Int J Pediatr Otorhinolaryngol*, 123, 151-155.

- Moreddu, E., Rossi, M. E., Nicollas, R., & Triglia, J. M. (2019). Prognostic Factors and Management of Patients with Choanal Atresia. *J Pediatr*, 204, 234-239 e231.
- Newell-Morris, L., Sirianni, J. E., Shepard, T. H., Fantel, A. G., & Moffett, B. C. (1980). Teratogenic effects of retinoic acid in pigtail monkeys (*Macaca nemestrina*). II. Craniofacial features. *Teratology*, 22(1), 87-101.
- Ramadan, H. H. (1999). Surgical causes of failure in endoscopic sinus surgery. *Laryngoscope*, 109(1), 27-29.
- Romeh, H. E., & Albirmawy, O. A. (2010). A 13-year experience and predictors for success in transnasal endoscopic repair of congenital choanal obliteration. *Int J Pediatr Otorhinolaryngol*, 74(7), 737-742.
- Samadi, D. S., Shah, U. K., & Handler, S. D. (2003). Choanal atresia: a twenty-year review of medical comorbidities and surgical outcomes. *Laryngoscope*, 113(2), 254-258.
- Schraff, S. A., Vijayasekaran, S., Meinen-Derr, J., & Myer, C. M. (2006). Management of choanal atresia in CHARGE association patients: a retrospective review. *Int J Pediatr Otorhinolaryngol*, 70(7), 1291-1297.
- Singh, A., Luong, A. U., Fong, K. J., Ow, R. A., Han, J. K., Gerencer, R., . . . Raman, A. (2019). Bioabsorbable steroid-releasing implants in the frontal sinus ostia: a pooled analysis. *Int Forum Allergy Rhinol*, 9(2), 131-139.
- Stankiewicz, J. A. (1990). The endoscopic repair of choanal atresia. *Otolaryngol Head Neck Surg*, 103(6), 931-937.
- Stieve, M., Kempf, H. G., & Lenarz, T. (2009). Management of choanal atresia in cases of craniofacial malformation. *J Maxillofac Oral Surg*, 8(1), 52-54.
- Strychowsky, J. E., Kawai, K., Moritz, E., Rahbar, R., & Adil, E. A. (2016). To stent or not to stent? A meta-analysis of endonasal congenital bilateral choanal atresia repair. *Laryngoscope*, 126(1), 218-227.
- Tatar, E. C., Ocal, B., Dogan, E., Bayir, O., Saka, C., Ozdek, A., & Korkmaz, M. H. (2017). Stentless endoscopic repair of congenital choanal atresia: is it enough for maintaining choanal patency? *Eur Arch Otorhinolaryngol*, 274(10), 3673-3678.
- Teissier, N., Kaguelidou, F., Couloigner, V., Francois, M., & Van Den Abbeele, T. (2008). Predictive factors for success after transnasal endoscopic treatment of choanal atresia. *Arch Otolaryngol Head Neck Surg*, 134(1), 57-61.
- Uzomefuna, V., Glynn, F., Al-Omari, B., Hone, S., & Russell, J. (2012). Transnasal endoscopic repair of choanal atresia in a tertiary care centre: a review of outcomes. *Int J Pediatr Otorhinolaryngol*, 76(5), 613-617.

- Velegarakis, S., Mantsopoulos, K., Iro, H., & Zenk, J. (2013). Long-term outcomes of endonasal surgery for choanal atresia: 28 years experience in an academic medical centre. *Eur Arch Otorhinolaryngol*, 270(1), 113-116.
- Wilcox, L. J., Smith, M. M., de Alarcon, A., Epperson, M., Born, H., & Hart, C. K. (2020). Use of Steroid-Eluting Stents after Endoscopic Repair of Choanal Atresia: A Case Series with Review. *Ann Otol Rhinol Laryngol*, 129(10), 1003-1010.
- Wormald, P. J., Zhao, Y. C., Valdes, C. J., Pacheco, A. E., Ha, T. N., Tewfik, M. A., . . . Shaw, C. K. (2016). The endoscopic transseptal approach for choanal atresia repair. *Int Forum Allergy Rhinol*, 6(6), 654-660.

## Disease control in chronic rhinosinusitis: a qualitative study of patient perspectives

**Ahmad R. Sedaghat<sup>1</sup>**, Victoria Walker<sup>1</sup>, Michal Trope<sup>1</sup>, Antar A. Tichavakunda<sup>2</sup>, and Katie M. Phillips<sup>1</sup>

<sup>1</sup>*Department of Otolaryngology—Head and Neck Surgery, University of Cincinnati College of Medicine, Cincinnati, United States of America,* <sup>2</sup>*School of Education, University of Cincinnati, Cincinnati, United States of America*

*CRS - outcome assessment 2, Building M1 Room Σ1, Sept 28, 10.15*

**Background:** The definition of disease control in chronic rhinosinusitis (CRS) is an active area of study. However, investigations have not engaged CRS patients in how they think about disease control. This study seeks to understand the patient perspective for CRS disease control.

**Methodology:** Qualitative phenomenological study using constant comparative methodology was applied. The research team conducted 10, one-on-one interviews with CRS patients ranging from 45 to 90 minutes in length. The content of the interview protocol was determined through iterative discussion amongst all authors. Two authors served as coders to identify recurrent themes. Themes were analyzed for meaning and conclusions were summarized.

**Results:** Recurring themes included (1) the term “control” adequately represents this phenomenon; (2) components of CRS disease control include daily symptomatology, frequency and severity of exacerbations, and CRS impact on comorbid disease and quality of life; and (3) CRS disease control is a goal of treatment for patients—i.e. they are more likely to seek treatment escalation to achieve control.

**Conclusions:** CRS patients consider their daily symptoms, their exacerbations, the impact of CRS on their quality of life and exacerbation of comorbid disease when self-assessing their CRS disease control. Uncontrolled disease motivates patients to seek further treatment.

**Key words:** chronic rhinosinusitis, disease control; qualitative research; interview; sinonasal symptoms; exacerbations; quality of life

## Complications of Extended Endoscopic Approaches to the Maxillary Sinus

**Aiman El Mograbi<sup>1</sup>**, Daniel Ben Ner<sup>1</sup>, Nimrod Amitai<sup>1</sup>, Ethan Soudry<sup>1</sup>

*Department of Otolaryngology Head and Neck Surgery, Rabin Medical Center, Petah-Tikva  
Sackler Faculty of Medicine, Tel Aviv University, Tel Aviv, Israel*

*Miscellaneous 1, Building M1 Room Σ1, Sept 28, 11.45*

**Background:** Extended endoscopic approaches to the maxillary sinus (EEAMS) have become increasingly popular for both inflammatory and neoplastic conditions. However, there is limited data regarding the morbidity associated with these procedures. The aim of this study was to analyze the complications of these approaches.

**Methodology:** Retrospective cross-sectional study including all patients that underwent EEAMS between the years 2014-2021 for various pathologies.

**Results:** 76 patients underwent 92 EEAMS. 72 (78.2%) endoscopic medial maxillectomy (MM), 12 (13%) modified endoscopic medial maxillectomy (MEMM) and 8 (8.7%) endoscopic Denker's procedure. The most common complications were long-term crusting (28%) associated with bone exposure, followed by maxillary sinus contraction (12%), transient epiphora (6.5%), permanent epiphora (4.5%) and hypoesthesia (6.5%). Stenting of the nasolacrimal duct showed no benefit over non-stenting. Dacryocystorhinostomy was eventually required in 2.3%, only following post-operative radiation. Hypoesthesia was noted to be associated with injury of the middle or anterior alveolar nerves (branches of V2 nerve) due to drilling of either the anterior or inferior sinus walls.

**Conclusion:** EEAMS are associated with considerable temporary and permanent morbidity previously under reported in the literature. Both surgeons and patients should be aware of these complications. Additional research is needed to develop methods of minimizing these complications.

## 3D-printed models of the nasal cavity as extended preoperative anatomical and functional information

Patricia Neumaier<sup>1</sup>, **Klaus Vogt**<sup>2</sup>, Sebastian Rösch<sup>1</sup>

<sup>1</sup>ENT-Dept., Paracelsus Medical University, Salzburg/Austria, <sup>2</sup>University of Latvia, Faculty of Medicine, Center of Experimental Surgery, Riga/Latvia, Center of experimental surgery, faculty of medicine, University of Latvia, Riga/Latvia

*Imaging and investigations 1, Building M1 Room Σ4, Sept 29, 11.45*

**Background:** Incomplete preoperative anatomic and functional information about the nasal cavity is one of the reasons for unsuccessful nasal surgery. The new method can inform about complicated structures and its functional consequences

**Methodology/Principal:** The data format of CT or MRI can be easily transformed to stl.-files by which the nose and paranasal sinuses can be 3D - printed. The models can be divided by 3 or 4 horizontal levels allowing also a simulation of the intended surgical steps. The functional analysis of the model can be performed additionally by 4-phase-rhinomanometry.

**Results:** The axial information about the nasal cavity in real dimensions cannot be obtained by classic inspection or endoscopy as could be shown in 22 cases and is very important in cases with double-s-shaped septum or multiple posttraumatic abnormalities.

**Conclusions:** 3d-print of models of the nose with or without paranasal sinuses deliver an important preoperative information in addition to CFD-studies at a reasonable price. It is a completely new didactical medium

**Key words:** preoperative diagnostic, evaluation of CT and MRI, 3D-print, nasal surgery

## Psychophysiology of nasal breathing: determination of the “just noticeable difference” (JND) in nasal obstruction

Patricia Neumaier<sup>1</sup>, Klaus Vogt<sup>2</sup>, Eliza Poikane<sup>2</sup>, Sebastian Rösch<sup>1</sup>

<sup>1</sup>ENT-Dept., Paracelsus Medical University, Salzburg/Austria; <sup>2</sup>University of Latvia, Faculty of Medicine, Center of Experimental Surgery, Riga/Latvia

*Imaging and investigations 1, Building M1 Room Σ4, Sept 29, 11.45*

**Background:** During the discussion about the value of objective and subjective methods to determine nasal resistance the “just noticeable difference”(JND) of the size of an airway obstacle was never measured. JND is one of the most important parameters in psychophysiology.

**Methodology/Principal:** Through a special device consisting of a mask and 2 parallel strips with orifices one can breath alternatively through one of the orifices by nasal breathing or mouth breathing. The tested subject decides if he feels “no difference”, “possible” or “sure”

**Results:** The range of the orifices between 2.5 and 8mm covers all possible resistances as classified by logarithmic resistance parameters (4-phase-rhinomanometry). In 25 persons it was found that in small diameters (3.5 – 5.0 mm) differences of 0,5mm can be felt, while it is not reliable in diameters between 5-8 mm. In oral breathing the results are more reliable as in nasal breathing

**Conclusions:** Sensing of obstruction follows the basic law of Weber-Fechner in psychophysiology and the exponential dependency of orifice size and resistance. Logarithmic parameters in rhinomanometry are mandatory. Surgical widening of the nasal channel to a diameter above 8 mm cannot be felt as “improvement” and should be avoided.

**Key words:** Nasal breathing, psychophysiology, nasal obstruction

Literature: Klaus Vogt, Klaus-Dieter Wernecke, Hans Behrbohm, Wolfgang Gubisch & Mara Argale, Four-phase rhinomanometry: a multicentric retrospective analysis of 36,563 clinical measurements. Eur Arch Otorhinolaryngol DOI 10.1007/s00405-015-3723-5

## Critical evaluation of mathematical formulas describing the nasal air stream by air flow simulation and computational fluid dynamics

**Klaus Vogt**<sup>1</sup>, Sindija Gūtmane<sup>2</sup>, Kaspars Peksis<sup>2</sup>, Moritz Waldmann<sup>3</sup>

<sup>1</sup> University of Latvia, Faculty of Medicine, Center of Experimental Surgery, Riga, Latvia; <sup>2</sup> University of Latvia, Faculty of Medicine, Centre of Experimental Surgery, Clinic Headline, Riga, Latvia; <sup>4</sup> Aachen University, Chair of Fluid Mechanics and Institute of Aerodynamics, Aachen, Germany

*Imaging and investigations 1, Building M1 Room Σ4, Sept 29, 11.45*

**Background:** Total nasal resistance can be determined by active posterior rhinomanometry or calculated by 2 measurements of active anterior rhinomanometry using Kirchhoff's rule. The relation between resistance and dimensions is usually determined by Hagen-Poiseuille's law. Both formulas had to be checked experimentally.

**Methodology/Principal:** A simulator generates a flow (ARNO 5) as trapezoid curve with top fluxes of 250, 375 and 500 ccm /s. Models have been created by 3D-printing, representing orifices between 2.5 and 8 mm or tubes of 20 to 80 mm length and tested either as single concentric or 2 parallel tubes. Pressure and flux have been measured by the rhinomanometer 4RHINO. The models have been simulated also for Computational Fluid Dynamics (Institute of Aerodynamics, RWTH Aachen/Germany).

**Results:** Physical and simulations by CFD show very similar results. Nasal resistance depends exponentially on the diameter, but not to the 4<sup>th</sup> power as given by Hagen-Poiseuille. Also, the rule of Kirchhoff for parallel resistors is not simply applicable for the nasal resistances: the average error for calculated total resistance is about 33%.

**Conclusions:** In nasal obstruction the correction of the width is of higher importance as the length of an obstacle. Determination of total nasal resistance by calculation is a rough estimation to be corrected in commercial rhinomanometers.

**Key words:** airway resistance, simulation, calculation



203754-235

A five-year open follow up of a randomised double-blind placebo-controlled trial of intralymphatic immunotherapy for birch and grass, reveals remaining beneficial effects

**Laila Hellkvist**<sup>1,2</sup>, Eric Hjalmarsson<sup>2</sup>, Agneta Karlsson<sup>1,2</sup>, Ola Winqvist<sup>3</sup>, Susanna Kumlien Georén<sup>2</sup>, Ulla Westin<sup>4</sup>, Lars Olaf Cardell<sup>1,2</sup>

<sup>1</sup>Division of ENT Diseases, Department of Clinical Sciences, Intervention and Technology, Karolinska Institutet, Stockholm, Sweden. <sup>2</sup>Department of ENT Diseases, Karolinska University Hospital, Stockholm, Sweden; <sup>3</sup>Department of Clinical Immunology and Transfusion Medicine, Karolinska University Hospital, Stockholm, Sweden. <sup>4</sup>Laboratory of Clinical and Experimental Allergy Research, Department of Otorhinolaryngology Malmö, Lund University, Skåne University Hospital, Malmö, Sweden.

*Allergic Rhinitis 1, Building M1 Room Σ3, Sept 28, 10.15*

**Background:** Intralymphatic immunotherapy (ILIT) has been proposed as a novel, less time-consuming alternative to conventional allergy immunotherapy (AIT). Few studies have evaluated its long-term effects.

**Methodology:** 58 patients with allergic rhinitis were treated with either placebo or ALK Alutard Birch and Grass 1000 SQ-U with one-month intervals. Active treatment reduced nasal provocation test (NPT) symptoms the first year after the vaccination. 5-6 years later, 20 out of 26 actively treated patients were followed up with NPT, seasonal weekly registration of the combined symptoms and medications score (CSMS), IgE and IgG4 levels in blood along with immunological markers in blood and lymph nodes and compared with 13 unvaccinated controls.

**Results:** CSMS was lower in the ILIT-treated group compared to in the non-AIT-treated group 5 years later. The positive outcome of the NPTs could not be convincingly reproduced. Grass specific IgG4 was still slightly elevated. Grass specific IgE was reduced from median 8.7 kU/mL (IQR 1.9-25.1 [95% CI 6.6-29.4]) to 5.0 (IQR 1.7-11.8 [95% CI 4.0-20.5],  $p < 0.001$ ). An increased generation of memory T-cells in the lymph nodes further supports a long-term effect.

**Conclusions:** Some beneficial effects seem to remain 5 years after ILIT. This supports the concept of ILIT in treatment of pollen induced allergic rhinitis.

**Key words:** Allergic rhinitis, hay fever, intralymphatic immunotherapy, allergy immunotherapy, grass pollen

**Tanja K Soklic<sup>1</sup>**, Mira Silar<sup>2</sup>, Matija Rijavec<sup>2</sup>, Izidor Kern<sup>2</sup>, Ana Koren<sup>2</sup>, Peter Korosec<sup>2</sup>

<sup>1</sup>Department of Otorhinolaryngology and Head & Neck Surgery, University Medical Centre, Ljubljana, Slovenia;

<sup>2</sup>University Clinic of Respiratory and Allergic Diseases Golnik, Golnik, Slovenia

*CRS - diagnosis and investigations 3, Building M1 Room 24, Sept 29, 10.15*

**BACKGROUND:** At least 20 % of CRS patients suffer from uncontrolled CRS with persistent bothersome symptoms (≥5 score on the visual analog scale, VAS 0-10) and recurrences after endoscopic surgeries despite appropriate treatment. The type 2 inflammation, usually with adult onset asthma, is a recognized pathophysiological condition leading to uncontrolled CRS. Double negative (DN) CD4-CD8- T cells could play a role in type 2 inflammation.

**MATERIALS AND METHODS:** 13 eosinophilic CRSwNP with severe symptoms and >10 eosinophils per high power field in middle meatus polyp mucosa were analyzed by flow cytometry for T cell subtypes. GATA3 gene expression level was measured to confirm the eosinophilic CRSwNP. 5 of 13 CRSwNP had uncontrolled CRS after 2 years of extensive medical and surgical treatment.

**RESULTS:** We found surprisingly high percentages (10-20%) of mucosal DN T cells in CRSwNP in contrast to normal 1-5% blood level. We demonstrated 3-fold higher numbers of proinflammatory DN T cells and lower count of partly differentiated, effector memory CD28-CD27+ DN T cells in patients with uncontrolled CRSwNP compared to patients with well-controlled CRSwNP.

**CONCLUSIONS:** The source of DN T cells in CRS is currently unknown; however, DN T cells might also be an important producer of IL-5, the major type 2 cytokine. Further studies on DN T cells are needed.

**Key words:** Chronic sinusitis, T cell, CD4+, CD8+, CD4-CD8-

#### Literature

1. Fokkens WJ, Lund VJ, Bachert C, Alobid I, Baroody F, Cohen N, et al. EPOS 2020: European Position Paper on Rhinosinusitis and Nasal Polyps 2020. *Rhinology*. 2020;(Supplement 29):1–464.
2. Bachert C, Pawankar R, Zhang L, Bunnag C, Fokkens WJ, Hamilos DL, et al. ICON: chronic rhinosinusitis. *World Allergy Organ J*. 2014;7(1):25.
3. Hellings PW, Fokkens WJ, Akdis C, Bachert C, Cingi C, Dietz de Loos D, et al. Uncontrolled allergic rhinitis and chronic rhinosinusitis: where do we stand today? *Allergy*. 2013 Jan;68(1):1–7.
4. Fischer, K., Voelkl, S., Heymann, J., Przybylski, G. K., Mondal, K., Laumer, M., ... Mackensen, A. (2005). Isolation and characterization of human antigen-specific TCR alpha beta+ CD4(-)CD8- double-negative regulatory T cells. *Blood*, 105(7), 2828–2835. <https://doi.org/10.1182/blood-2004-07-2583>

A case series representative of a university hospital's experience regarding the surgical management of odontogenic cysts involving the maxillary sinus.

**Anna Maria Ntziovara**<sup>1</sup>, Nikolaos Kalogritsas<sup>1</sup>, Maria Minasidou<sup>1</sup>, Kyriaki Vallianou<sup>1</sup>, Rodopi Koursoumi<sup>2</sup>, Dimitrios Kanoutos<sup>2</sup>, Athanasios Saratziotis<sup>1</sup>

<sup>1</sup>Department of Otolaryngology-Head and Neck Surgery, General University Hospital of Larissa, Prof. Charalampos Skoulakis, Larissa, Greece; <sup>2</sup>Department of Oral and Maxillofacial Surgery, General University Hospital of Larissa, Head: Rodopi Koursoumi, Larissa, Greece

*Rhinology – miscellaneous 2, Building M1 Room Σ3, Sept 29, 14.45*

**Background:** Odontogenic cysts are originating from epithelial remains associated with odontogenesis and can be either inflammatory or developmental of origin. The traditional treatment involves a transoral approach, however, a combined, single-stage, transoral and endoscopic approach is also reported. We report eight cases of odontogenic cysts involving the maxillary sinus, chosen to represent the overall experience of two departments in a tertiary hospital.

**Methodology/Principal:** The most common presenting symptom was painful facial swelling. All patients underwent panoramic radiograph and contrast-enhanced CT scan preoperatively to determine expansion of the cyst. The surgical management was carried out by the oral and maxillofacial surgeons in four cases. Three cases were treated by a head and neck surgeon, while a single patient required a combined approach by both specialties.

**Results:** Caldwell-Luc operation was performed in the majority of cases, achieving the enucleation of the cyst. A single case involved recurrent sinusitis with nasal polyps and the elected surgical approach combined a Caldwell-Luc procedure with a functional endoscopic sinus surgery, ensuring osteomeatal complex patency.

**Conclusions:** Regarding our hospital, the preferable approach was the transoral, allowing direct visualization of the maxillary sinus. However, in cases of concurrent secondary sinusitis, a combined approach was successfully performed.

**Key words:** Odontogenic cyst; Maxillary sinus; Functional endoscopic sinus surgery

#### Literature

1. Safadi A et al., Surgical management of odontogenic cysts involving the maxillary sinus- a retrospective study, Journal of Cranio-Maxillo-Facial Surgery, <https://doi.org/10.1016/j.jcms.2020.06.011>
2. Meng Y, Zhao Y-N, Zhang Y-Q, Liu D-G, Gao Y. Three-dimensional radiographic features of ameloblastoma and cystic lesions in the maxilla. Dentomaxillofac Radiol 2019; 48: 20190066.
3. Marino MJ, Luong A, Yao WC, Citardi MJ. Management of odontogenic cysts by endonasal endoscopic techniques: A systematic review and case series. Am J Rhinol Allergy. 2018 Jan 1;32(1):40-45. doi: 10.2500/ajra.2018.32.4492. PMID: 29336289.

# The use of Computed Tomography (CT) guided navigation as a training tool for junior otolaryngology specialty registrars in Functional Endoscopic Sinus Surgery (FESS): A qualitative study.

**Rakesh Mistry<sup>1,2</sup>**, Eleanor J Crossley<sup>1,2</sup>, Raj Lakhani<sup>1,2</sup>

<sup>1</sup>Epsom and St Heliers University Hospitals NHS Trust; <sup>2</sup>St George's University Hospitals NHS Foundation Trust

*Technological advances 1, Building M1 Room Σ4, Sept 29, 14.45*

**Background:** Functional endoscopic sinus surgery (FESS) carries serious risks including loss of vision and cerebrospinal fluid leak.<sup>1</sup> Pre-operative computed tomography (CT) is therefore essential for surgical planning and intra-operative guidance due to complex anatomical variants within the paranasal sinuses.<sup>2</sup> This complexity in correctly identifying important anatomical landmarks can therefore make specialty registrar training in FESS challenging. A CT guided navigation system allows the user to identify the location of their instruments in real-time in relation to the pre-operative CT scan and subsequently provide immediate feedback to the user to enhance their learning curve when training in FESS. This also reassures seniors of their operating location, minimizing the risk of complications.

**Methodology/Principal:** We compare the qualitative experience of two specialty otolaryngology registrars' training in FESS using traditional means compared to a Medtronic CT guided navigation system, under the guidance of a rhinology consultant.

**Results:** The two specialty registrars' confidence in identifying anatomical variants, learning curve when completing aspects of FESS of differing complexity, and subjective risk of complications is discussed. The financial and time considerations in establishing this training system is also evaluated.

**Conclusions:** We report the experience of two specialist registrars with comparable experience with the CT guided navigation system.

## **Key words:**

Tomography, X-Ray Computed  
Endoscopy  
Surgery, Computer-Assisted  
Otolaryngology  
Learning curve

## Literature

1. Hosemann W, Draf C. Danger points, complications and medico-legal aspects in endoscopic sinus surgery. *GMS Curr Top Otorhinolaryngol Head Neck Surg.* 2013 Dec 13;12:Doc06. doi: 10.3205/cto000098. PMID: 24403974; PMCID: PMC3884541.
2. Cashman EC, Macmahon PJ, Smyth D. Computed tomography scans of paranasal sinuses before functional endoscopic sinus surgery. *World J Radiol.* 2011;3(8):199-204. doi:10.4329/wjr.v3.i8.199

**Alexander D. Karatzanis<sup>1</sup>**, Georgia A. Liva<sup>1</sup>, Antonis F. Vakis<sup>2</sup>, Paraskevi K. Xekouki<sup>3</sup>, Emmanuel P. Prokopakis<sup>1</sup>

<sup>1</sup>Department of Otorhinolaryngology, University of Crete School of Medicine, Heraklion, Crete, Greece

<sup>2</sup>Department of Neurosurgery, University of Crete School of Medicine, Heraklion, Crete, Greece

<sup>3</sup>Department of Endocrinology, University of Crete School of Medicine, Heraklion, Crete, Greece

*Pituitary Surgery 1, Building M1 Room Σ2, Sept 27, 11.45*

**Background:** Pituitary apoplexy represents a potentially life threatening endocrine emergency. As a primary event pituitary apoplexy often involves adenomas. Most cases present in the fifth or sixth decade with almost equal predominance among males and females. Clinical signs vary significantly. Typical clinical presentation includes severe headache, nausea, vomiting, affected level of consciousness, meningeal signs, decreased visual acuity and visual field defects. The management of pituitary apoplexy requires multi-disciplinary approach including endocrinologists, neurosurgeons, and otorhinolaryngologists.

**Methodology/ Principal:** A 59 year-old male patient, presented in the ER of a tertiary referral center complaining for occipital headache, blurred vision and diplopia. Clinical examination showed ptosis of the left upper eyelid and ipsilateral mydriasis, normal ocular movements and reduced peripheral vision to both sides with bilateral hemianopsia. The patient underwent brain CT which revealed a mass of the pituitary gland with characteristics of pituitary adenoma extending to the optic chiasm. Emergency management included haemodynamic stabilization and corticosteroid therapy. Due to severe symptoms and clinical signs of visual compression, emergency endoscopic, transnasal, transphenoid pituitary decompression was decided. A pituitary mass consistent with adenoma was encountered and removed.

**Results:** The histological examination confirmed the diagnosis of pituitary adenoma. Postoperative course was uneventful. Significant improvement of symptoms was immediately noted. Patient completely recovered from diplopia, blurred vision and visual field defects during the first few days following surgery.

**Conclusions:** Pituitary apoplexy is a rare endocrine emergency. While management is usually conservative, in cases of acute visual deficits, surgical pituitary decompression may be indicated. Transnasal transphenoidal approach is considered the gold standard approach due to low complication rates and excellent results.

**Key words:** pituitary apoplexy, adenoma, transphenoidal approach

#### Literature

- 1) Nawar RN, Abdel-Mannan D, Selma WR, Arafah BM. Pituitary tumor apoplexy: A review. J Intensive Care Med. 2008;23:75–89
- 2) Findling JW, Tyrreell JB, Aron DC, Fitzgerald PA, Wilson CB, Forsham PH. Silent pituitary apoplexy: Subclinical infarction of an adrenocorticotropin-producing adenoma. J Clin Endocrinol Metab. 1981;52:95–7
- 3) Biousse V, Newman NJ, Oyesiku NM. Precipitating factors in pituitary apoplexy. J Neurol Neurosurg Psychiatry. 2001;71:542–5
- 4) Elena Garcia –Garrigos, Juan Jose Jimenez, Irene Monjas Canovas, Javier Abarca Olivas, Jesus Julian Cortes Vela, Javier DE La Hoz-Rosa, Maria Dolores Guirau Rubio, Transsphenoidal Approach in Endoscopic Endonasal Surgery for Skull Base

Lesions:What a radiologist and Surgeons need to know? Radiographics 2015;35:1170-1185

- 5) Cappabianca P, de Divitiis E. Endoscopy and transsphenoidal surgery. Neurosurgery 2004;54(5):1043–1048, 1048–1050
- 6) Hamberger CA, Hammer G, Norlen G, Sjogren B. Transantrosphenoidal hypophysectomy. Arch Otolaryngol 1961;74:2–8

203764-248

A one stop outpatient nasal fracture clinic, streamlining the management of patients with nasal injuries.

**Avgi Loizidou**<sup>1</sup>, Ishika Bansal<sup>1</sup>, Anna Slovic<sup>1</sup>, Jonathan Joseph<sup>1</sup>

<sup>1</sup>Royal National ENT and Eastman Dental Hospitals, University College London, London, United Kingdom - for all authors.

*Nasal and facial trauma 1, Building M1 Room Σ3, Sept 27, 11.45*

**Background:** Nasal fractures require assessment and manipulation within 14 days of injury traditionally under general anesthetic (GA). However, safety measures imposed to prevent SARS-COV-2 transmission reduced operative space significantly. We established a one stop outpatient nasal fracture clinic for assessment and manipulation of nasal fractures under local anesthetic (LA) for children and adults.

**Methodology/Principal:** Our study aims to assess if manipulation under LA is as effective alternative to manipulation under GA. Prospective cohort study of 115 patients with nasal injury (n=21 children). SNOT 23, Visual analogue scale and patient satisfaction scores recorded 6 weeks post manipulation under LA.

**Results:** GA group (n=59) n=25 requiring manipulation, n=18 manipulation under GA, n=4 canceled, n=3 refused procedure; number of days from injury to review (10.7±9.91). LA group (n=56) n=32 requiring manipulation (n=31 manipulation under LA, n=1 manipulation under GA); number of days from injury to review (4.7±9.54). Assessment 6 week post manipulation under LA: SNOT23 (median 1 IQR 1,2) visual analogue scale 1-10, 10 perfect result (n=6 7/10, n=10 8/10, n=6 9/10, n=2 10/10), patient satisfaction scores (n=17 excellent, n=34 outstanding).

**Conclusions:** Manipulation of nasal fractures under local anesthetic is a safe and effective alternative to general anesthesia with high patient satisfaction rates.

**Key words:** nasal fracture, manipulation, local anesthetic

## The Ear-Nose-Throat (ENT) Prospective International Cohort of patients with Primary Ciliary Dyskinesia (EPIC-PCD).

Myrofora Goutaki<sup>1,2</sup>, Yin Ting Lam<sup>1</sup>, Mihaela Alexandru<sup>3,4</sup>, Andreas Anagiotos<sup>5</sup>, Miguel Armengot<sup>6-7</sup>, Emilie Bequignon<sup>8</sup>, Mieke Boon<sup>9</sup>, Andrea Burgess<sup>10</sup>, Caversaccio Nathalie<sup>11</sup>, Andre Coste<sup>8,12</sup>, Suzanne Crowley<sup>13</sup>, Sinan Ahmed. D. Dheyauldeen<sup>14</sup>, Nagehan Emiralioglu<sup>15</sup>, Ela Erdem<sup>16</sup>, Eric G. Haarman<sup>17</sup>, Amanda Harris<sup>18</sup>, Céline Kempeneers<sup>19</sup>, , Bulent Karadag<sup>16</sup>, Sookyung Kim<sup>3</sup>, Philipp Latzin<sup>2</sup>, Natalie Lorent<sup>20</sup>, Ugur Ozcelik<sup>14</sup>, Anne-Lise ML Poirrier<sup>21</sup>, Ana Reula<sup>22-23</sup>, Jobst Roehmel<sup>24</sup>, Christine van Gogh<sup>25</sup>, Panayiotis Yiallourous<sup>26-27</sup>, Soeren Marian Zappe<sup>28</sup>, Jean-François Papon<sup>3,29</sup>

<sup>1</sup>Institute of Social and Preventive Medicine, University of Bern, Switzerland; <sup>2</sup>Paediatric Respiratory Medicine, Children's University Hospital of Bern, University of Bern, Switzerland; <sup>3</sup>AP-HP, Hôpital Kremlin-Bicêtre, Service d'ORL et de Chirurgie Cervico-Faciale, Le Kremlin-Bicêtre, France; <sup>4</sup>Faculté de Médecine, Université Paris-Saclay, Le Kremlin-Bicêtre, France; <sup>5</sup>Department of Otorhinolaryngology, Nicosia General Hospital, Nicosia, Cyprus; <sup>6</sup>Department of Otorhinolaryngology, and Primary Ciliary Dyskinesia Unit, La Fe University and Polytechnic Hospital, Valencia, Spain; <sup>7</sup>Medical School, Valencia University, Valencia, Spain; <sup>8</sup>AP-HP, Hôpital Henri Mondor et Centre Hospitalier Intercommunal de Créteil, Service d'Oto-Rhino-Laryngologie et de Chirurgie Cervico-Faciale, Créteil, France; <sup>9</sup>Department of Paediatrics, University Hospital, Leuven, Belgium; <sup>10</sup>Primary Ciliary Dyskinesia Centre, Southampton Children's Hospital, Southampton NHS Foundation Trust, Southampton, UK; <sup>11</sup>Department of Otorhinolaryngology, Head and Neck Surgery, University Hospital of Bern, University of Bern, Switzerland; <sup>12</sup>Faculté de Médecine, Université Paris-Est Créteil, Institut National de la Santé et de la Recherche Médicale, Centre National de la Recherche Scientifique, Hôpital Henri Mondor, Créteil, France; <sup>13</sup>Paediatric Department of Allergy and Lung Diseases, Oslo University Hospital, Oslo, Norway; <sup>14</sup>Dept of Otorhinolaryngology, Head and Neck Surgery, Oslo University Hospital, Oslo, Norway; <sup>15</sup>Department of Pediatric Pulmonology, Hacettepe University, School of Medicine, Ankara, Turkey; <sup>16</sup>Department of Pediatric Pulmonology, Marmara University, School of Medicine, Istanbul, Turkey; <sup>17</sup>Department of pediatric pulmonology, Emma Children's Hospital, Amsterdam UMC, Vrije Universiteit, Amsterdam, The Netherlands; <sup>18</sup>Primary Ciliary Dyskinesia Centre, NIHR Respiratory Biomedical Research Centre, University of Southampton, Southampton, UK; <sup>19</sup>Division of Respiriology, Department of Pediatrics, University Hospital Liège, Liège, Belgium; <sup>20</sup>Department of Respiratory Diseases, University Hospital, Leuven, Belgium; <sup>21</sup>Department of Otorhinolaryngology, University Hospital Liège, Liège, Belgium; <sup>22</sup>Biomedical Sciences Department, CEU-Cardenal Herrera University, Castellón, Spain; <sup>23</sup>Molecular, Cellular and Genomic Biomedicine Group, IIS La Fe, Valencia, Spain; <sup>24</sup>Department of Pediatric Pulmonology, Immunology and Critical Care Medicine, Charité-Universitätsmedizin, Berlin, Germany; <sup>25</sup>Department of Otolaryngology/ Head and Neck Surgery, Amsterdam University Medical Center, Amsterdam, The Netherlands; <sup>26</sup>Medical School, University of Cyprus, Nicosia, Cyprus; <sup>27</sup>Pediatric Pulmonology Unit, Hospital 'Archbishop Makarios III', Nicosia, Cyprus; <sup>28</sup>Department of Otorhinolaryngology, Head and Neck Surgery, Charité-Universitätsmedizin, Berlin, Germany; <sup>29</sup>Faculté de Médecine, Université Paris-Saclay, Le Kremlin-Bicêtre, France.

*CRS - diagnosis and investigations 2, Building M1 Room Σ2, Sept 28, 10.15*

**Background:** Primary Ciliary Dyskinesia (PCD) is a rare genetic disease affecting mainly the airways causing impaired mucociliary clearance. Almost all patients have sinonasal or otologic (ENT) problems, however we know little about the spectrum and severity of PCD ENT disease and its course over life.

**Methodology:** Aiming to longitudinally characterise ENT disease in PCD patients, we set up the ENT Prospective International Cohort of PCD patients (EPIC-PCD), a multi-centre prospective standardised observational clinical cohort embedded into routine patient care. The study combines objective assessments of the upper airways and patient reported information on symptoms and health-related quality of life, all collected with disease-specific tools, in a standardised way (NCT04611516).

**Results:** Recruitment for EPIC-PCD has started in 13 centres in 10 European countries and so far we have recruited 217 patients. First analyses will focus on assessing the prevalence and severity of sinonasal and otologic symptoms and the frequency and range of signs and



physiological findings assessed during ENT physical examination, describing possible differences by age.

**Conclusions:** The EPIC-PCD has the potential to become a valuable research resource and to help better understand the disease in order to improve diagnosis, clinical care and quality of life of patients with PCD.

**Key words:** **Primary Ciliary** Dyskinesia, Orphan Diseases, Epidemiological Studies, Rhinology, **Otology**

#### Literature

Goutaki M, Papon JF, Boon M, Casaulta C, Eber E, Escudier E, Halbeisen FS, Harris A, Hogg C, Honore I, Jung A, Karadag B, Koerner-Rettberg C, Legendre M, Maitre B, Nielsen KG, Rubbo B, Rumman N, Schofield L, Shoemark A, Thouvenin G, Willkins H, Lucas JS, Kuehni CE. Standardised clinical data from patients with primary ciliary dyskinesia: FOLLOW-PCD. *ERJ Open Res.* 2020 Feb 10;6(1):00237-2019. doi: 10.1183/23120541.00237-2019. PMID: 32055632; PMCID: PMC7008138.

Crowley S, Azevedo I, Boon M, Bush A, Eber E, Haarman E, Karadag B, Kötz K, Leigh M, Moreno-Galdó A, Mussaffi H, Nielsen KG, Omran H, Papon JF, Pohunek P, Priftis K, Rindlisbacher B, Santamaria F, Valiulis A, Witt M, Yiallourous P, Zivkovic Z, Kuehni CE, Lucas JS. Access to medicines for rare diseases: beating the drum for primary ciliary dyskinesia. *ERJ Open Res.* 2020 Sep 14;6(3):00377-2020. doi: 10.1183/23120541.00377-2020. PMID: 32964005; PMCID: PMC7487359.

Shoemark A, Rubbo B, Legendre M, Fassad MR, Haarman EG, Best S, Bon ICM, Brandsma J, Burgel PR, Carlsson G, Carr SB, Carroll M, Edwards M, Escudier E, Honoré I, Hunt D, Jouvion G, Loebinger MR, Maitre B, Morris-Rosendahl D, Papon JF, Parsons CM, Patel MP, Thomas SN, Thouvenin G, Walker WT, Wilson R, Hogg C, Mitchison HM, Lucas JS. Topological data analysis reveals genotype-phenotype relationships in primary ciliary dyskinesia. *Eur Respir J.* 2021 Jan 21:2002359. doi: 10.1183/13993003.02359-2020. Epub ahead of print. PMID: 33479112.

# Hybrid positron emission tomography imaging for staging and re-staging of sinonasal tumours: prognosticators of treatment response and clinically relevant information

**Christian M. Meerwein**<sup>1</sup>, Alexander Maurer<sup>2</sup>, Michael B. Soyka<sup>1</sup>, Martin W. Hüllner<sup>2</sup>, David Holzmann<sup>1</sup>

<sup>1</sup>Department of Otorhinolaryngology, Head and Neck Surgery, University Hospital Zurich, University of Zurich, Zurich, Switzerland; <sup>2</sup>Department of Nuclear Medicine, University Hospital Zurich, University of Zurich, Zurich, Switzerland

*Sinonasal malignancy 4, Building M1 Room 24, Sept 27, 14.45*

**Background:** We aimed to assess hybrid positron emission tomography (PET) imaging in the initial staging and outcome prediction of primary sinonasal malignancies. Secondly, we investigated the additional clinically relevant information (CRI) derived from these techniques, compared to regional magnetic resonance imaging (MRI) alone.

**Methodology/Principal:** Retrospective study on consecutive patients with primary sinonasal malignancies undergoing hybrid PET imaging.

**Results:** Overall sensitivity for detection of primaries using 18F-fluoro-deoxy-d-glucose PET (FDG-PET) was 95.4%, for lymph node metastases 100% and distant metastases (DM) 100%. On univariate analysis, PET parameter total lesion glycolysis (TLG) was associated with achieving CR after primary treatment ( $176.8 \pm 157.2$  vs  $83.7 \pm 110.8$ ,  $p = 0.03$ ). Multivariate logistic regression demonstrated that TLG adjusted for the T classification best predicted achievement of CR. A total of 32/96 (33.3%) hybrid PET examinations revealed CRI.

**Conclusions:** Hybrid PET imaging yields an excellent sensitivity in detecting primary tumors, lymph node metastases and DM. TLG of the primary tumor is an independent prognostic factor for achieving CR after initial treatment. Hybrid PET imaging should be encouraged in all sinonasal tumor patients in addition to the mandatory regional sinonasal / neck MRI. Whole-body PET/MR including such a regionalized MRI may be the optimal approach, integrating both examinations into a single one

**Key words:** sinonasal, tumor, malignancy, imaging, PET

## Literature:

Ramakrishnan VR, Lee JY, O'Malley BW, Jr., Palmer JN, Chiu AG. 18-FDG-PET in the initial staging of sinonasal malignancy. *Laryngoscope*. 2013;123(12):2962-6.

Queiroz MA, Hüllner MW. PET/MR in cancers of the head and neck. *Semin Nucl Med*. 2015;45(3):248-65.

Lamarre ED, Batra PS, Lorenz RR, Citardi MJ, Adelstein DJ, Srinivas SM, et al. Role of positron emission tomography in management of sinonasal neoplasms--a single institution's experience. *American Journal of Otolaryngology*. 2012;33(3):289-95.

## Salvage surgery in recurrent sinonasal cancers: definition of a prognostic score to improve the decision-making process

**Davide Mattavelli,<sup>1,2</sup>** Michele Tomasoni,<sup>1,2</sup> Marco Ferrari,<sup>3</sup> Alessandra Compagnoni,<sup>1,2</sup> Alberto Schreiber,<sup>1</sup> Stefano Taboni,<sup>3</sup> Vittorio Rampinelli,<sup>1</sup> Elisa Marazzi,<sup>1,2</sup> Elena Raffetti,<sup>4</sup> Luca Oscar Redaelli de Zinis,<sup>1,2</sup> Alberto Deganello,<sup>1,2</sup> Roberto Maroldi,<sup>5</sup> Paolo Bossi,<sup>6</sup> Cesare Piazza,<sup>1,2</sup> Piero Nicolai, MD<sup>3</sup>

<sup>1</sup>Unit of Otorhinolaryngology – Head and Neck Surgery, ASST Spedali Civili of Brescia, Brescia, Italy; <sup>2</sup>Department of Medical and Surgical Specialties, Radiological Sciences, and Public Health, University of Brescia, Brescia, Italy; <sup>3</sup>Unit of Otorhinolaryngology – Head and Neck Surgery, Department of Neurosciences University of Padua, Padua, Italy; <sup>4</sup>Epidemiology and Public Health Intervention Research group (EPHIR), Department of Global Public Health, Karolinska Institute, Stockholm, Sweden; <sup>5</sup>Unit of Radiology and <sup>6</sup>Medical Oncology, Department of Medical and Surgical Specialties, Radiological Sciences, and Public Health, University of Brescia, Brescia, Italy

*Sinonasal malignancy 1, Building M1 Room Σ3, Sept 27, 14.45*

**Background** Decision-making for recurrent sinonasal cancers (SNC) retreatment is challenging. Current evidence is scarce.<sup>1</sup>

**Materials and Methods** Retrospective, single-centre analysis of recurrent SNC treated with a surgical-including curative protocol. Primary objective was the definition of a prognostic score to guide decision-making. Univariate and multivariable (Cox regression) analyses were performed.

**Results** 118 patients (82 males, median age: 66 years) were included. Recurrent SNC originated mostly in the naso-ethmoidal box (67.8%) and were mainly epithelial (76.2%), high grade (49.2%), locally advanced (rpT4, 60.1%) malignancies. Negative surgical margins were achieved in 56.6%. Adjuvant (chemo)radiotherapy was administered to 30.0% of patients. Two- and 5-year OS were 71.7% and 56%, respectively. Treatment-related mortality and overall complication rates were 1.7% and 29.6%, respectively. The prognostic score included treatment modality for primary tumour, histotype, rpT category, positive margins, perineural invasion, and adjuvant radiotherapy after salvage surgery and provided excellent discrimination of patients into 3 prognostic groups with favourable, intermediate, and poor survival estimates (2- and 5-year OS were 88.8% and 84.4%, 70.3% and 44.9%, 6.6% and 0%, respectively).

**Conclusions** Intensified treatment of recurrent SNCs can result in good long-term survival estimates with limited toxicity. Our score provides excellent prognostic stratification for patients' selection.

**Key words:** salvage surgery, recurrent sinonasal cancer, prognosticator, prognostic score, survival, endoscopic surgery

### Literature

1) Kaplan DJ, Kim JH, Wang E, Snyderman C. Prognostic Indicators for Salvage Surgery of Recurrent Sinonasal Malignancy. *Otolaryngol Head Neck Surg* 2016;154:104–12. <https://doi.org/10.1177/0194599815606699>.

## Additive Manufacturing for Personalized Skull Base Reconstruction in Endoscopic Transclival Surgery: A Proof of Concept

**Davide Mattavelli,<sup>1</sup>** Antonio Fiorentino,<sup>2</sup> Francesco Tengattini,<sup>3</sup> Alessandro Colpani,<sup>2</sup> Silvia Agnelli,<sup>2</sup> Barbara Buffoli,<sup>4</sup> Marco Ravanelli,<sup>5</sup> Marco Ferrari,<sup>1,6</sup> Alberto Schreiber,<sup>1</sup> Vittorio Rampinelli,<sup>1</sup> Stefano Taboni,<sup>1</sup> Vincenzo Verzeletti,<sup>1</sup> Alberto Deganello,<sup>1</sup> Luigi F. Rodella,<sup>4</sup> Roberto Maroldi,<sup>5</sup> Elisabetta Ceretti,<sup>2</sup> Luciana Sartore,<sup>2</sup> Marco M. Fontanella,<sup>3</sup> Piero Nicolai,<sup>6</sup> Francesco Doglietto<sup>3</sup>

<sup>1</sup>Otorhinolaryngology - Head and Neck Surgery, <sup>3</sup>Neurosurgery, <sup>5</sup>Radiology, Department of Surgical Specialties, Radiological Sciences and Public Health, University of Brescia, Brescia, Italy; <sup>2</sup>Department of Mechanical and Industrial Engineering, University of Brescia, Italy

<sup>4</sup>Section of Anatomy and Physiopathology, Department of Clinical and Experimental Sciences, University of Brescia, Brescia, Italy; <sup>6</sup>Otorhinolaryngology - Head and Neck Surgery, University of Padua, Padua, Italy.

*Skull base surgery 1, Building M1 Room Σ2, Sept 28, 14.45*

**Objective:** To investigate 3D printing to create a personalized, rigid, biocompatible scaffold for reconstruction of clival dural defects, which is burdened by high CSF leak rate.

**Methods:** 11 transclival approaches were simulated in 5 specimens. All scaffolds were manually designed in a computer-aided environment based on a real or predicted clival defect. They were printed in poly-lactic acid polymer with different offsets (0-2 mm). They were fixed either with the gasket seal technique, or with screws. Radiological evaluation of scaffold position was performed in all cases. In 3 specimens (5 simulated scenarios), the CSF leak pressure point was measured.<sup>1</sup>

**Results:** The production process took approximately 30 hours. The designed scaffolds were satisfactory when no offset was added. Accuracy of scaffold positioning was good to excellent in all cases except when the neuronavigation failed (1 case). Screws driving was always correct. The CSF leak pressure point was significantly higher when the cranioplasty was fixed with screws (68 and 120 cmH<sub>2</sub>O), as compared to gasket-seal reconstruction with cartilage (27 cmH<sub>2</sub>O) or the 3D printed scaffold only (18 and 40 cmH<sub>2</sub>O).

**Conclusions:** Additive manufacturing allows the creation of customized scaffolds that are effective in reconstructing even large and geometrically complex clival defects.

**Key words:** 3D printing, additive manufacturing, endoscopic transclival surgery, skull base reconstruction, cranioplasty, personalized bone reconstitution

### Literature

1) Mattavelli D, Ferrari M, Rampinelli V, Schreiber A, Buffoli B, Deganello A, et al: Development and validation of a preclinical model for training and assessment of cerebrospinal fluid leak repair in endoscopic skull base surgery. *Int Forum Allergy Rhinol* 10:89–96, 2020

Essayed WI, Unadkat P, Hosny A, Frisken S, Rassi MS, Mukundan S, et al: 3D printing and intraoperative neuronavigation tailoring for skull base reconstruction after extended endoscopic endonasal surgery: proof of concept. *J Neurosurg* 130:248–255, 2018

## The prevalence of type 2 inflammatory signatures in patients with chronic rhinosinusitis with nasal polyps from two phase 3 clinical trials, SINUS-24 and SINUS-52

**Claus Bachert**<sup>1-3</sup>, Stella E. Lee<sup>4</sup>, Claire Hopkins<sup>5</sup>, Anju T. Peters<sup>6</sup>, Wytske Fokkens<sup>7</sup>, Asif H. Khan<sup>8</sup>, Amy Praestgaard<sup>9</sup>, Shahid Siddiqui<sup>10</sup>, Scott Nash<sup>10</sup>, Juby A. Jacob-Nara<sup>11</sup>, Yamo Deniz<sup>10</sup>, Paul J. Rowe<sup>11</sup>

<sup>1</sup>Ghent University, Ghent, Belgium; <sup>2</sup>Karolinska Institutet, Stockholm, Sweden; <sup>3</sup>Sun Yat-sen University, The First Affiliated Hospital, Guangzhou, China; <sup>4</sup>Department of Otolaryngology—Head & Neck Surgery, University of Pittsburgh Medical Center, Pittsburgh, PA, USA; <sup>5</sup>Guy's and St Thomas' Hospitals, London, UK; <sup>6</sup>Allergy-Immunology Division and the Sinus and Allergy Center, Feinberg School of Medicine, Northwestern University, Chicago, IL, USA; <sup>7</sup>Academic Medical Center, Amsterdam, The Netherlands; <sup>8</sup>Sanofi, Chilly Mazarin, France; <sup>9</sup>Sanofi, Cambridge, MA, USA; <sup>10</sup>Regeneron Pharmaceuticals, Inc., Tarrytown, NY, USA; <sup>11</sup>Sanofi, Bridgewater, NJ, USA

*CRS – pathophysiology 1, Building M1 Room Σ3, Sept 28, 11.45*

**Background:** Chronic rhinosinusitis with nasal polyps (CRSwNP) is a disease of the nasal cavity and paranasal sinuses characterized by type 2 inflammation. Recent publications described algorithms for identification of type 2 inflammation in CRSwNP without tissue analysis. We assessed the prevalence of type 2 inflammation in patients with severe CRSwNP from two phase 3 studies (SINUS-24/SINUS-52 [NCT02912468/NCT02898454]).

**Methodology:** Type 2 inflammation was assessed at baseline (pooled SINUS-24/SINUS-52; N=724) according to: 1. EPOS consensus guidelines (eosinophils  $\geq 250$  cells/ $\mu$ L or IgE  $\geq 100$  IU/mL); 2. EUFOREA 2020 position paper (comorbid asthma or eosinophils  $\geq 300$  cells/ $\mu$ L); 3. GINA threshold for airway inflammation (eosinophils  $\geq 150$  cells/ $\mu$ L); 4. eosinophils  $\geq 150$  cells/ $\mu$ L or IgE  $\geq 100$  IU/mL; 5. type 2 comorbidity (atopic dermatitis/allergic rhinitis/asthma/nonsteroidal anti-inflammatory drug-exacerbated respiratory disease); 6. eosinophils  $\geq 150$  cells/ $\mu$ L or IgE  $\geq 100$  IU/mL or type 2 comorbidity.

**Results:** The proportions of patients by each type 2 inflammation definition were: 1. 83.4%; 2. 76.4%; 3. 85.8%; 4. 92.3%; 5. 78.6%; and 6. 96.7%. In patients without comorbid asthma (n=296) the proportions were: 1. 75.0%; 3. 79.1%; 4. 87.8%; 5. 47.6%; and 6. 91.9%.

### Conclusions:

Up to 96.7% of patients with CRSwNP, with or without comorbid asthma, displayed a type 2 inflammatory signature based on these algorithms.

**Key words:** Maximum 5 (required to be Mesh terms, for indexing purposes)

Comorbidity

Inflammation

Nasal polyps

Sinusitis

**Acknowledgments** Research sponsored by Sanofi and Regeneron Pharmaceuticals, Inc. ClinicalTrials.gov Identifiers: NCT02912468/NCT02898454. The authors would like to thank Nadia Daizadeh, PhD (formerly Sanofi) for statistical analyses. Medical writing support provided by Joseph Hodgson, PhD of Adelphi Group, Macclesfield, UK, and funded by Sanofi Genzyme and Regeneron Pharmaceuticals, Inc., according to the [Good Publication Practice guideline](#).

### Disclosures

**C. Bachert:** ALK, AstraZeneca, GlaxoSmithKline, Mylan, Novartis, Sanofi, Stallergenes Greer –

advisory board member and speakers' fees.

**S.E. Lee:** GlaxoSmithKline, Sanofi, AstraZeneca, Genentech – clinical trial funding, advisory board member.

**C. Hopkins:** GSK, OptiNose, Sanofi Genzyme, Smith & Nephew – advisory board member.

**A.T. Peters:** Regeneron Pharmaceuticals, Inc., Sanofi – advisory board member; AstraZeneca – research support and advisory board member; Optinose – consultant and research support.

**W. Fokkens:** BioInspire Technologies, GlaxoSmithKline, Meda Pharmaceuticals, Sanofi – research grants.

**A.H. Khan, A. Praestgaard, J.A. Jacob-Nara, P.J. Rowe:** Sanofi – employees, may hold stock and/or stock options in the company.

**S. Siddiqui, S. Nash, Y. Deniz:** Regeneron Pharmaceuticals, Inc. – employees, may hold stock and/or stock options in the company.

## CHronic RHINOSinusitis Outcome Registry (CHRINOSOR): development of an international outcome registry driven by mHealth technology.

**Sven F. Seys**<sup>1</sup>, Peter W. Hellings<sup>2</sup>, Isam Alobid<sup>3</sup>, Elisabeth Arndal<sup>4</sup>, Gregor Bachmann<sup>5</sup>, Vibeke Backer<sup>4</sup>, Florian Bast<sup>6</sup>, Manuel Bernal-Sprekelsen<sup>3</sup>, Lars Olaf Cardell<sup>7</sup>, Carlo Cavaliere<sup>8</sup>, Lauren Deneyer<sup>1</sup>, Wytske J. Fokkens<sup>9</sup>, Simon Gane<sup>10</sup>, Philippe Gevaert<sup>11</sup>, Clemens Holzmeister<sup>12</sup>, Claire Hopkins<sup>6</sup>, Valérie Hox<sup>13</sup>, Harald Hrubos<sup>5</sup>, Mark Jorissen<sup>2</sup>, Anu Laulajainen-Hongisto<sup>14</sup>, Valerie Lund<sup>10</sup>, Anette Kjeldsen<sup>15</sup>, Bibi Lange<sup>15</sup>, Kenneth Lenhardt<sup>15</sup>, Gert Mariën<sup>1</sup>, Simonetta Masieri<sup>8</sup>, Joaquim Mullol<sup>3</sup>, Sietze Reitsma<sup>9</sup>, Philippe Rombaux<sup>13</sup>, Pernilla Sahlstrand-Johnson<sup>16</sup>, Sven Schneider<sup>17</sup>, Andreas Steinsvik<sup>5</sup>, Igor Stenin<sup>18</sup>, Pavol Surda<sup>6</sup>, Peter-Valentin Tomazic<sup>12</sup>, Sanna K. Toppila-Salmi<sup>18</sup>, Laura Van Gerven<sup>2</sup>, Thibaut Van Zele<sup>11</sup>, Paula Virkkula<sup>14</sup>, Christian von Buchwald<sup>4</sup>, Martin Wagenmann<sup>19</sup>, Claus Bachert<sup>11</sup>

<sup>1</sup>Research department, Galenus Health, Hasselt, Belgium; <sup>2</sup>Department of Otorhinolaryngology-Head and Neck Surgery, UZ Leuven, Leuven, Belgium; <sup>3</sup>Hospital Clínic, IDIBAPS, Universitat de Barcelona, CIBERES, Barcelona, Catalonia, Spain; <sup>4</sup>Department of Otorhinolaryngology - Head and Neck Surgery and Audiology, Copenhagen University Hospital, Rigshospitalet, Copenhagen, Denmark; <sup>5</sup>Department of Otorhinolaryngology, Akershus University Hospital, Lørenskog, Norway; <sup>6</sup>ENT Department, Guy's and St Thomas' NHS Foundation Trust, London, United Kingdom; <sup>7</sup>Division of ENT Diseases, Department of Clinical Science, Intervention and Technology, Karolinska Institutet, Stockholm, Sweden; <sup>8</sup>Department of Oral and Maxillofacial Sciences, Sapienza University, Rome, Italy; <sup>9</sup>Department of Otorhinolaryngology, Amsterdam University Medical Centres, location AMC, Amsterdam, The Netherlands; <sup>10</sup>Department of Rhinology, Royal National Throat Nose and Ear Hospital, London, UK; <sup>11</sup>Upper Airways Research Laboratory, Department of Otorhinolaryngology, Ghent University, Ghent, Belgium; <sup>12</sup>Department of General ORL, Head and Neck Surgery, Medical University of Graz, Graz, Austria; <sup>13</sup>Département d'Otorhinolaryngologie, Cliniques Universitaires Saint-Luc, Brussels, Belgium; <sup>14</sup>Department of Otorhinolaryngology-Head and Neck Surgery, Helsinki University Hospital and University of Helsinki, Helsinki, Finland; <sup>15</sup>Department of Otorhinolaryngology, Odense University Hospital, Odense, Denmark; <sup>16</sup>Department of Oto-Rhino-Laryngology, Head and Neck Surgery, Lund University, Skåne University Hospital, Malmö, Sweden; <sup>17</sup>Department of Otorhinolaryngology, Head and Neck Surgery, Vienna General Hospital (AKH), Medical University of Vienna, Vienna, Austria; <sup>18</sup>Skin and Allergy Hospital, Helsinki University Hospital and University of Helsinki, Helsinki, Finland; <sup>19</sup>Department of Otorhinolaryngology, Universitätsklinikum Düsseldorf, Dusseldorf, Germany.

*CRS - outcome assessment 1, Building M1 Room Σ4, Sept 27, 10.15*

**Background:** Real-life data is important to better understand the burden of disease and effectiveness of therapies. So far there is limited real-life data to enable clinicians to take an informed decision on whom to give a biologic therapy when treating chronic rhinosinusitis with nasal polyps (CRSwNP) patients and how to position biologics in current care pathways of CRSwNP.

**Methodology/Principal:** An mHealth tool, Galenus Health, supporting patients and physicians in the management of chronic respiratory diseases, is used to collect data on patient profile, disease history, patient outcomes as well as a set of relevant clinical outcomes. Patients – aged 18 or above – with physician-diagnosed chronic rhinosinusitis are eligible for inclusion.

**Results:** A collaborative scientific network of 17 university ENT centres from 11 European countries has been composed with the aim to collect data in a longitudinal and standardized manner. The Galenus Health digital platform is currently being implemented in the various hospitals taking into account legal, privacy and data security aspects.

**Conclusions:** CHRINOSOR is a collaborative effort that aims at improving our understanding about chronic rhinosinusitis, its comorbidities and its treatments. Ultimately, these insights will guide us as scientific community to develop future care pathways informed by real-life data.

**Key words:** chronic rhinosinusitis, nasal polyps, biologic therapy, real-world evidence, mobile health technology.



# Endonasal confocal laser endomicroscopy- a novel avenue for real-time diagnosis and evaluation of sinonasal and skull base malignancies

**Nina Wenda**<sup>1</sup>, Ralf Kiesslich<sup>2</sup>, Jan Gosepath<sup>1</sup>

<sup>1</sup>Department of ORL-HNS, Helios Dr. Hort-Schmidt-Kliniken, Wiesbaden, Hessen, Germany; <sup>2</sup>Departement of gastroenterology, Helios Dr. Hort-Schmidt-Kliniken, Wiesbaden, Hessen, Germany

*Sinonasal malignancy 4, Building M1 Room Σ4, Sept 27, 14.45*

**Background:** Probe-based confocal laser endomicroscopy (p-CLE) is a technology for real-time in vivo visualization of mucosal changes on a cellular level. In initial investigations on head and neck carcinoma, we described the oropharyngeal application (1). The further miniaturization of the laser probe now allows for endonasal application and thus investigation of endonasal neoplasms. Based on the malignancy criteria validated in the oropharynx, we will now investigate whether these are applicable in sinonasal and skull base malignancies.

**Methodology/Principal:** We performed p-CLE (Cellvizio®, Mauna Kea, Paris, France) with intravenous fluorescein staining in patients with different neoplasms of the paranasal sinuses. Pathological changes were visualized and evaluated by independent pathologists to validate malignancy criteria and determine distinguishing characteristics of the different malignant entities.

**Results:** p-CLE allows for endonasal use and application of morphological criteria of malignancy in analogy to classic histological examination. Characteristic differences between tumor entities could be identified and validated in vivo.

**Conclusions:** Our results suggest that endonasal application of p-CLE represents a valuable extension of the diagnostic repertoire available to date by real-time analysis of nasal and skull base mucosa. This is of particular value in surgically challenging anatomical areas such as the paranasal sinuses, the orbit and skull base.

**Key words:** confocal laser endomicroscopy, sinonasal carcinoma, sinonasal malignancy, skull base malignancy

## Literature:

1. Pogorzelski B, Hanenkamp U et al. Systematic intraoperative application of confocal endomicroscopy for early detection and resection of squamous cell carcinoma of the head and neck: a preliminary report. Arch Otolaryngol Head Neck Surg., April 2012: 404-1.

**Simona Negoias<sup>1,2</sup>**, Sara-Lynn Hool<sup>1</sup>, Hergen Friedrich<sup>3</sup>, Basile N. Landis<sup>4</sup>, Marco-Domenico Caversaccio<sup>1</sup>, Franca Wagner<sup>5</sup>

<sup>1</sup>Department of Otorhinolaryngology, Head and Neck Surgery, Inselspital, Bern University Hospital, University of Bern, CH-3010 Bern, Switzerland; <sup>2</sup>Department of Otorhinolaryngology, Head and Neck Surgery, Basel University Hospital, CH-4051 Basel, Switzerland; <sup>3</sup>Department of Otorhinolaryngology, University Children's Hospital Zurich, Switzerland; <sup>4</sup>Rhinology-Olfactology Unit, Department of Otorhinolaryngology, Head and Neck Surgery, University Hospitals of Geneva, Geneva, Switzerland; <sup>5</sup>Department of Neuroradiology, Inselspital, Bern University Hospital, University of Bern, CH-3010 Bern, Switzerland

*Smell and taste 1, Building M2 CR3, Sept 27, 11.45*

**Background:** No data on utility of imaging diagnostic tools for taste disorders exists. The study aimed to investigate the frequency of MRI utilisation, MRI findings and cost-benefit aspects in the diagnosis of patients with taste disorders.

**Methodology:** Retrospective chart review of taste disorder patients that received an MRI, presenting at our tertiary smell and taste clinic between 2010-2019. All MRIs were reviewed by a highly trained neuroradiologist. Findings were classified according to their taste disorder relevance. Cost-benefit was calculated.

**Results:** Of the 125 patients with taste problems (37 female; 16-84years, 59.3+/- 13.8years), 70 received an MRI, of which 65 were retrievable (52%). Abnormalities were seen in 54 patients: 46 incidentalomas and 8 potentially taste relevant findings. After matching with clinical data, only 3 findings were classified as taste relevant. The performed MRIs total cost was 55'994.66 CHF. With 21.6 MRIs per taste relevant abnormality, the estimated cost per taste disorder relevant abnormality was 18'664.88 CHF.

**Conclusions:** MRI for the diagnostic of taste disorder of unclear cause rarely shows abnormal findings, with a rate of abnormal findings similar to that seen in the normal population. Therefore brain MRI should not be routinely used in the diagnostic of unclear taste disorder.

**Key words:** taste disorder, MRI, diagnostic, cost

## Endoscopic-assisted multi-portal compartmental resection of the masticatory space in oral cancer: Anatomical study and preliminary clinical experience

Alberto Schreiber,<sup>1</sup> **Davide Mattavelli,<sup>1,2</sup>** Remo Accorona,<sup>3</sup> Vittorio Rampinelli,<sup>1</sup> Marco Ferrari,<sup>4</sup> Alberto Grammatica,<sup>1</sup> Giovanni Leo Tomacelli,<sup>5</sup> Vincenzo Verzeletti,<sup>3</sup> Enrico Fazio,<sup>6</sup> Monir Abousiam,<sup>6</sup> Aurel Nebiaj f, Alberto Deganello,<sup>1,2</sup> Piero Nicolai,<sup>4</sup> Barbara Buffoli,<sup>7</sup> Rita Rezzani,<sup>7</sup> Cesare Piazza,<sup>1,2</sup> Luca Calabrese<sup>6</sup>

<sup>1</sup>Unit of Otorhinolaryngology – \_Head and Neck Surgery, ASST Spedali Civili of Brescia, Brescia, Italy; <sup>2</sup>Department of Medical and Surgical Specialties, Radiological Sciences, and Public Health, University of Brescia, Brescia, Italy; <sup>3</sup>Unit of Otorhinolaryngology – \_Head and Neck Surgery, Fondazione IRCCS Ca' \_Granda Ospedale Maggiore Policlinico, Milan, Italy

<sup>4</sup>Unit of Otorhinolaryngology – \_Head and Neck Surgery, Department of Neurosciences University of Padua, Padua, Italy; <sup>5</sup>Unit of Otorhinolaryngology – \_Head and Neck Surgery, Vito Fazzi Hospital, Lecce, Italy; <sup>6</sup>Unit of Otorhinolaryngology, "San Maurizio" \_Hospital of Bolzano, Bolzano, Italy; <sup>7</sup>Section of Anatomy and Physiopathology, Department of Clinical and Experimental Sciences, University of Brescia, Brescia, Italy

*Skull base surgery 1, Building M1 Room Σ2, Sept 28, 14.45*

**Objectives:** To present an anatomical cadaver dissection study and our preliminary surgical experience with endoscopic-assisted multi-portal compartmental resection of the masticatory space (MS) in locally advanced oral squamous cell carcinoma (OSCC).

**Methods:** Two fresh-frozen cadaver heads were dissected to define the surgical steps of an endoscopic-assisted multi-portal compartmental approach to the MS. After this preclinical anatomical study, patients affected by locally advanced OSCC originating from the retromolar area with extension to the MS were prospectively enrolled and operated at two Italian referral centers for head and neck cancer between October 2019 and May 2020.

**Results:** Surgical technique was preclinically defined step by step in 3 phases: transnasal, transoral/trancervical, and multi-portal. Compartmental resection of the MS was successfully completed in all specimens (4 MSs dissected). The surgical technique was subsequently applied in 3 patients affected by primary OSCC of the retromolar area, providing satisfactory results in terms of negative resection margins and local control.

**Conclusions:** Multi-portal compartmental resection of the MS combining the transnasal and transoral/transcervical corridors is technically feasible. Such an approach to the MS in locally advanced OSCC provides different angles of incidence to the target and full control of tumor margins.

**Key words:** advanced oral cancer, endoscopic endonasal surgery, compartmental surgery, masticatory space, infratemporal fossa

### Literature

Mair MD, Sawarkar N, Nikam S, et al. Impact of radical treatments on survival in locally advanced T4a and T4b buccal mucosa cancers: Selected surgically treated T4b cancers have similar control rates as T4a. *Oral Oncol* 2018;82:17–22. <https://doi.org/10.1016/j.oraloncology.2018.04.019>.

Piazza C, Grammatica A, Montalto N, Paderno A, Del Bon F, Nicolai P. Compartmental surgery for oral tongue and floor of the mouth cancer: Oncologic outcomes. *Head Neck* 2019;41(1):110–5. <https://doi.org/10.1002/hed.25480>.

Trivedi NP, Kekatpure V, Kuriakose MA. Radical (compartment) resection for advanced buccal cancer involving masticator space (T4b): Our experience in thirty patients. *Clin Otolaryngol*

## A single-centre 5-year experience using the triple-layer technique for surgical repair of nasal septal perforations

**Alfonso Luca Pendolino<sup>1,2</sup>**, Samit Unadkat<sup>1</sup>, Annakan V Navaratnam<sup>1</sup>, Premjit Randhawa<sup>1</sup>, Peter J. Andrews<sup>1,2</sup>.

<sup>1</sup>Department of ENT, Royal National ENT & Eastman Dental Hospitals, London, United Kingdom; <sup>2</sup>Ear Institute, UCL, London, UK.

*Septal and turbinate surgery 2, Building M2 Study Hall, Sept 29, 14.45*

**Background:** Septal perforation repair is considered technically challenging and successful closure has been reported to be lower for perforations bigger than 15 mm. We present our 5-year experience of septal perforations repair using a novel triple-layer technique involving a unilateral transpositional/rotational flap utilizing lateral nasal wall and inferior turbinate mucosa, a contralateral underlay porcine small intestinal submucosa mesh and the interposition of crushed cartilage.

**Methodology:** A retrospective review was performed to identify patients undergoing nasal septal perforation repair surgery with this technique between 2015 and 2020. A case series of 26 patients treated with this technique is presented.

**Results:** Perforation dimension ranged from 3–47 mm with a median size of 12 mm. Complete closure of the perforation was achieved in 84.6% of the cases, while partial closure in the remaining cases. No failure was reported. Median follow-up was 10 months.

**Conclusions:** The addition of inferior turbinate mucosa as part of the unilateral lateral nasal wall mucoperichondrium/periosteal flap combined with a contralateral acellular matrix underlay optimizes the repair of larger perforations. The underlay acellular matrix acts as a scaffold for the regeneration of healthy mucoperichondrium while the interposition of cartilage gives strength and support to the reconstruction.

**Key words:** Nasal Septal Perforation, Nasal Septum, Surgical Flaps, Reconstructive Surgical Procedures, Turbinates

### Literature

1. Delaney SW, Kridel RWH. Contemporary trends in the surgical management of nasal septal perforations: a community survey. *Facial Plast Surg.* 2019;35(1):78–84.
2. Kim SW, Rhee CS. Nasal septal perforation repair: predictive factors and systematic review of the literature. *Curr Opin Otolaryngol Head Neck Surg.* 2012;20:58–65.
3. Pendolino AL, Jaafar M, Unadkat S, Zhang H, Randhawa P, Andrews PJ. A unilateral mucoperichondrial/mucoperiosteal flap including inferior turbinate with contralateral underlay xenograft for a large nasal septal perforation repair. *Facial Plast Surg Aesthet Med.* 2020;22:386–388.
4. Greywoode J, Hamilton J, Malhotra PS, Saad AA, Pribitkin EA. Repair of nasal septal perforation with porcine small intestinal submucosa xenograft. *J Otol Rhinol.* 2012;1:2. DOI: 10.4172/2324-8785.1000101
5. Chhabra N, Houser SM. Endonasal repair of septal perforations using a rotational

mucosal flap and acellular dermal interposition graft. *Int Forum Allergy Rhinol.* 2012;2(5):392–396.

6. Lindberg K, Badylak SF. Porcine small intestinal submucosa (SIS): a bioscaffold supporting in vitro primary human epidermal cell differentiation and synthesis of basement membrane proteins. *Burns.* 2001;27(3):254–266.

## Challenges encountered in the complex management of patients with mucormycosis.

**Catalina Pietrosanu<sup>1,2</sup>**, Viorel Zainea<sup>1,2</sup>, Irina Gabriela Ionita<sup>1,2</sup>, Andreea Rusescu<sup>1</sup>, Ruxandra Oana Alius<sup>2</sup>, Raluca Oana Pulpa<sup>1</sup>, Mihai Catana<sup>2</sup>, Razvan Hainarosie<sup>1,2</sup>.

<sup>1</sup> "Carol Davila" University of Medicine and Pharmacy, Bucharest, Romania; <sup>2</sup> "Prof. Dr. D. Hociota" Institute of Phonoaudiology and Functional ENT Surgery, Bucharest, Romania

*Acute Rhinosinusitis 1, Building M1 Room Σ1, Sept 27, 10.15*

**Background:** Mucormycosis represents a fungal infection encountered in immunosuppressed patients. It is characterized by extreme local aggressiveness and the tendency towards invasion of the surrounding tissues. The management of such patients requires a multidisciplinary team, with a surgeon that resect all the infected tissue, an infectious disease specialist that will guide the medical treatment and any other specialty involved in treating the underlying disease.

**Methodology/Principal:** We wish to present the protocol followed in our clinic for patients with mucormycosis infection. The procedures may seem aggressive, but aim for total resection of fungi infected structures when possible.

**Results:** Surgical interventions under endoscopic control offer major advantages, such as increased safety, a better control of the hidden areas and the possibility to check and resect, if necessary, areas that were not accessible during conventional surgery. However, medical treatment also associates a great importance, along with the treatment of the immunosuppressive underlying condition, if possible.

**Conclusions:** Patients with mucormycosis require a complex, multidisciplinary approach, where the surgical intervention is just one of the mandatory steps. Complete debridement is necessary, associated with medical treatment and life support. If any of these steps is not followed the risk of fatality is even more increased in patients that are already at risk.

**Key words:** mucormycosis, management, surgical procedures, multidisciplinary.

## Pedicled mucosal grafts for reconstruction of mucosal defects in frontal sinus surgery

**René Fischer**<sup>1</sup>, Christopher Schwenn<sup>1</sup>, Caroline T. Seebauer<sup>1</sup>, Constantin A. Hintschich<sup>1</sup>, Thomas S. Kühnel<sup>1</sup>

<sup>1</sup>Department of Otorhinolaryngology, University of Regensburg, 93042 Regensburg, Germany

*Skull base surgery 2, Building M2 CR3, Sept 29, 14.45*

**Purpose:** In revision frontal sinus surgery the Lothrop drillout procedure is performed to provide a wide drainage pathway of the sinus into the nose. In spite of different surgical techniques, recurrent blockage is a challenging problem. A new pedicled mucosal flap is presented and tested against the conventional Lothrop drillout technique.

**Methods:** On 101 patients Draf type III frontal sinus surgery was performed between 2013 and 2020. Patients' data was analyzed retrospectively in terms of surgical indications, technique, postoperative follow-up and patency ratio of drainage pathway.

**Results:** Out of 101 patients conventional Lothrop drillout procedure was performed in 33 patients. In 68 cases the technique was modified by using a pedicled mucosal flap. The follow-up period was 12 months to 68 months. 29 (87.9%) patients treated with the conventional Lothrop drillout and 64 (94.1%) patients treated with the modified technique with reconstruction of the resulting mucosal defect showed an open drainage pathway in the clinical follow-up.

**Conclusions:** Using an endonasal mucosal pedicle flap for the reconstruction of mucosal defects reduces the risk of narrow to blocked frontal sinus drainage pathways. Covering the bony surface exposed by drillout with vital mucosa may lead to faster epithelization and reduced scarring or osteitis.

**Keywords:** Lothrop drillout, endonasal mucosal pedicle flap, frontal sinus surgery, reconstruction

**Fabrizio Bandino**<sup>1</sup>, Ramya Thota<sup>1</sup>, Konstantinos Chaidas<sup>1</sup>, Sanjeeva Jeyaretna<sup>2</sup>, Tim Lawrence<sup>2</sup>, Pablo Martinez-Devesa<sup>1</sup>, Ali Qureishi<sup>1</sup>

<sup>1</sup>ENT Department, Oxford University Hospital; <sup>2</sup>Neurosurgical Department, Oxford University Hospitals

*Acute Rhinosinusitis 1, Building M1 Room Σ1, Sept 27, 10.15*

**Background:** Sinusitis-induced brain abscesses are rare but can result in devastating long term sequelae and mortality.

**Methodology:** Retrospective analysis on 32 patients who were treated at Oxford University Hospitals for sinusitis-induced brain abscess between February 2013 and June 2020.

**Results:** Mean age of presentation was 30.66.

Ethmoid and frontal sinuses were involved 96.88% and 87.50% of the cases, respectively. Subdural collection was the most frequent abscess (43.75%) with the majority located in the frontal lobe (93.75%).

Streptococcus Milleri group and Staphylococcus Aureus were identified in 62.50% of the patients and this was treated with the association Ceftriaxone and Metronidazole.

Most patients were also treated surgically (93.75%) with an initial joint Neurosurgery-ENT procedure in the majority (60.00%). More than half of the patients were treated with a single surgical procedure.

Long term complications were observed in about one third of the patients; there were no deaths.

**Conclusions:** Sinogenic intracranial abscesses present sporadically in patients with no previous rhinological history requiring high index of suspicion with early recognition.

Patients should immediately be started on a long course of empiric antibiotic parenteral treatment and treated surgically with a combined neurosurgical and ENT endoscopic approach in the majority of the cases.

**Key words:** sinusitis • brain abscess • complications • adult • paediatric

#### Literature:

- Fokkens WJ, Lund VJ, Hopkins C, Hellings PW, Kern R, Reitsma S, et al. European Position Paper on Rhinosinusitis and Nasal Polyps 2020. Rhinology. 2020
- J.H. PJ. Intracranial suppuration complicating sinusitis among children: An epidemiological and clinical study - Clinical article. Journal of Neurosurgery: Pediatrics. 2011
- Jaume F, Quintó L, Alobid I, Mullol J. Overuse of diagnostic tools and medications in acute rhinosinusitis in Spain: A population-based study (the PROSINUS study). BMJ Open. 2018
- Osborn AJ, Blaser S, Papsin BC. Decisions regarding intracranial complications from acute mastoiditis in children. Curr Opin Otolaryngol Head Neck Surg. 2011;19(6):478–85
- Kombogiorgas D, Seth R, Athwal R, Modha J, Singh J. Suppurative intracranial complications of sinusitis in adolescence. Single institute experience and review of literature. Br J Neurosurg. 2007;21(6):603–9
- Khamassi K, Mahfoudhi M, Yahia A Ben, Moussa N Ben, Halila N, Boubaker A, et al. Management of Intracranial Complications of Sinusitis. Open J Clin Diagnostics. 2015;05(02):86–95



- Bayonne E, Kania R, Tran P, Huy B, Herman P. Intracranial complications of rhinosinusitis. A review, typical imaging data and algorithm of management. *Rhinology*. 2009
- Ziegler A, Patadia M, Stankiewicz J. Neurological Complications of Acute and Chronic Sinusitis. *Current Neurology and Neuroscience Reports*. 2018
- DelGaudio JM, Evans SH, Sobol SE, Parikh SL. Intracranial complications of sinusitis: what is the role of endoscopic sinus surgery in the acute setting. *Am J Otolaryngol - Head Neck Med Surg* [Internet]. 2010;31(1):25–8. Available from: <http://dx.doi.org/10.1016/j.amjoto.2008.09.009>
- Singh B, Ramjettan S, Dellen J Van, Maharaj TJ. Sinogenic intracranial complications. *J Laryngol Otol*. 1995;109(10):945–50
- Scullen T, Hanna J, Carr C, Mathkour M, Aslam R, Amenta P, et al. Surgical Approaches in the Treatment of Intracranial Complications of Paranasal Sinus Disease: A Review of the Literature. *World Neurosurg* [Internet]. 2019;130:24–9. Available from: <https://doi.org/10.1016/j.wneu.2019.06.135>
- Leong SC, Waugh LK, Sinha A, De S. Clinical outcomes of sinogenic intracranial suppuration: The alder hey experience. *Ann Otol Rhinol Laryngol*. 2011;120(5):320–5
- Patel AP, Masterson L, Deutsch CJ, Scoffings DJ, Fish BM. Management and outcomes in children with sinogenic intracranial abscesses. *Int J Pediatr Otorhinolaryngol*. 2015
- Germiller JA, Monin DL, Sparano AM, Tom LWC. Intracranial complications of sinusitis in children and adolescents and their outcomes. *Arch Otolaryngol - Head Neck Surg*. 2006;132(9):969–76
- Fernández-de Thomas RJ DJO. Subdural Empyema. *StatPearls* [Internet]
- Han JK, Kerschner JE. Streptococcus milleri. *Arch Otolaryngol Neck Surg*. 2001;127(6):650
- Jones NS, Walker JL, Bassi S, Jones T, Punt J. The intracranial complications of rhinosinusitis: Can they be prevented? *Laryngoscope*. 2002;112(1):59–63
- Ratnaike TE, Das S, Gregson BA, Mendelow AD. A review of brain abscess surgical treatment - 78 years: Aspiration versus excision. *World Neurosurg* [Internet]. 2011;76(5):431–6. Available from: <http://dx.doi.org/10.1016/j.wneu.2011.03.048>
- Barlas O, Sencer A, Erkan K, Eraksoy H, Sencer S, Bayindir Ç. Stereotactic surgery in the management of brain abscess. *Surg Neurol*. 1999
- Sonnevile R, Ruimy R, Benzonana N, Riffaud L, Carsin A, Tadié JM, et al. An update on bacterial brain abscess in immunocompetent patients. *Clin Microbiol Infect*. 2017;23(9):614–20
- Brook I, Friedman EM, Rodriguez WJ CG. Complications of sinusitis in children. *Pediatrics*. 66(4):568–72
- Dolan RW, Chowdhury K. Diagnosis and treatment of intracranial complications of paranasal sinus infections. *J Oral Maxillofac Surg*. 1995;53(9):1080–7
- Szyfter W, Kruk - Zagajewska A, Bartochowska A, Borucki Ł. Intracranial complications from sinusitis. *Otolaryngol Pol*. 2015;69(3):6–11

Garin A, Thierry B, Leboulanger N, Blauwblomme T, Grevent D, Blanot S, et al. Pediatric sinogenic epidural and subdural empyema: The role of endoscopic sinus surgery. *Int J Pediatr Otorhinolaryngol* [Internet]. 2015;79(10):1752–60. Available from: <http://dx.doi.org/10.1016/j.ijporl.2015.08.007>

# Validation of the CT-based Amsterdam classification of completeness of endoscopic sinus surgery (ACCESS) score in chronic rhinosinusitis.

**D.R. Hoven<sup>1</sup>**, G.F.J.P.M. Adriaensen<sup>1</sup>, W.J. Fokkens<sup>1</sup>, S. Reitsma<sup>1</sup>

<sup>1</sup>*Department of Otorhinolaryngology, Amsterdam University Medical Centres, location AMC, University of Amsterdam, Amsterdam, The Netherlands*

*Imaging and investigations 1, Building M1 Room Σ4, Sept 29, 11.45*

**Background:** To aid the ongoing debate on the role of the extent of sinus surgery in chronic rhinosinusitis (CRS), we recently developed the Amsterdam Classification on Completeness of Endoscopic Sinus Surgery (ACCESS). It is an easy-to-use tool to quantify extent of previous sinus surgery based on computed tomography (CT) of the paranasal sinuses. We now aimed to validate the use of the ACCESS score in a random set of CRS patients.

**Methodology/Principal:** the ACCESS scores of the sinus CT scans of forty CRS patients consecutively visiting our outpatient clinic were separately determined by four rhinologists.

**Results:** the interrater agreement of the ACCESS score in a random sample of CRS patients was comparable to the previously published excellent agreement in a set of CT scans from patients with a broader spectrum of sinus disease.

**Conclusions:** the ACCESS score is a reliable sinus CT-based tool to quantify extent of previous sinus surgery. This enables further studies into the role of extent of sinus surgery in disease control of CRS patients.

**Key words:** chronic rhinosinusitis, CT scan, endoscopic sinus surgery, extent of surgery, interrater agreement

## Literature

Reitsma S, Adriaensen GFJPM, Cornet ME, van Haastert RM, Raftopoulos MH, Fokkens WJ. The Amsterdam Classification of Completeness of Endoscopic Sinus Surgery (ACCESS): a new CT-based scoring system grading the extent of surgery. *Rhinology*. 2020 Dec 1;58(6):538-543. doi: 10.4193/Rhin20.165. PMID: 32720936.



Case Report and How I do it: Intraoperative haemostatic control of FESS in a HHT patient.

**Alexandros Koukkoullis<sup>1</sup>**, Maria Pulido<sup>1</sup>

<sup>1</sup>ENT Department, Whipps Cross University Hospital, London, UK

*Epistaxis and HHT 2, Building M1 Room Σ3, Sept 29,11.45*

**Background:** Functional Endoscopic Sinus Surgery (FESS) and polypectomy was performed on a patient with Hereditary Haemorrhagic Telangiectasia (HHT) diagnosed with chronic rhinosinusitis and nasal polyps. The challenge was to maintain an operating view by controlling bleeding intraoperatively. We present how we met this challenge through this case report, and we performed a literature review for each technique used in order to assess their effectiveness and general surgical opinion.

**Method:** The intraoperative time was divided in 3 distinct periods. Preparation, operation and completion. In preparation, Moffett's solution was injected intranasally and Otrivine soaked neuropatties were inserted in the middle meati. During operation, we used warm sterile water to wash away the clots and gave intravenous Tranexamic acid to improve coagulation. At completion, Nasopore dissolvable pack was inserted in both middle meati.

**Results:** Intraoperative blood loss was minimal, with no postoperative complications and with patient going home the same day. However, we decided to order Surgicell Fibrillar as an alternative to Nasopore.

**Conclusions:** Multiple techniques were needed to ensure adequate haemostatic control. The surgeon must have an extensive arsenal of haemostatic techniques at their disposal and must know their effectiveness.

MESH Terms: Sinusitis, Nasal Polyps, Epistaxis, Telangiectasis, Endoscopy

**Ricardo São Pedro<sup>1</sup>**, Filipa Ferreira<sup>1</sup>, Mário Santos<sup>1</sup>, Luís Antunes<sup>1</sup>

<sup>1</sup>Otorhinolaryngology Department, Hospital Garcia de Orta, Almada, Portugal

*Smell and taste 1, Building M2 CR3, Sept 27,11.45*

**Background:** Olfactory dysfunction can be the first and only manifestation of vascular malformations of the central nervous system.

**Methodology/Principal:** Case report.

**Results:** The authors describe a case of a 76-year-old woman without any relevant past medical history, who presented with a post viral hyposmia with 3 months duration. ENT examination showed a deviated nasal septum without any other signs of nasal disease. Olfactory testing with BAST-24 revealed severe hyposmia with better trigeminal performance. Computer tomography of the perinasal sinuses highlighted mild chronic sinusopathy and an intra-axial heterogeneous lesion, partially calcified, on the deep right parasagittal frontal topography. Magnetic resonance imaging showed an intra-axial lesion centered to the anterior portion of the right hemi-callosal commissure and extension to the ipsilateral cingulate gyrus. The lesion had well defined limits but irregular contour, hypointense signal in T1, predominantly hyperintense in T2, and did not had diffusion restriction on the ADC map. This description was highly suggestive of a cavernoma malformation. The patient was kept under closed follow up until now and developed no further symptoms besides olfactory dysfunction.

**Conclusions:** Olfactory dysfunction is a clinically important symptom that should prompt a thoughtful clinical investigation.

**Key words:** Cerebral cavernoma, olfactory dysfunction

**Agius AM**<sup>1</sup>, Muscat R<sup>2</sup>

<sup>1</sup> Department of Surgery, University of Malta, <sup>2</sup>Department of Physiology and Biochemistry, University of Malta

*Miscellaneous 1, Building M1 Room Σ1, Sept 28,11.45*

**Background:** This study looked at the association between serotonin transporter gene variants and with chronic persistent tension-type facial pain. Known as triallelic 5-HTTLPR, the serotonin transporter gene-linked polymorphic region and its rs25531 polymorphism have been linked to alterations in pain perception.

**Patients and Methods:** Genotype polymorphism analysis was carried out in 26 patients with chronic tension type facial pain unresponsive to or recurring after treatment with amitriptyline. Findings were compared to 33 asymptomatic age-and gender-matched controls. Blood serotonin levels in these two groups were also determined.

**Results:** Consistent with previous studies, patients with chronic pain had significantly lower blood serotonin compared to controls. In all genotypes, blood serotonin was low compared to controls and this was significant in the homozygous for the L allele.

**Conclusion:** Patients with the LL genotype had the best three-year clinical outcome.

**Key words:** chronic, tension-type pain, facial pain, blood serotonin levels, 5-HTTLPR

## Multidisciplinary approach of fronto-ethmoidal meningoencephalocele

Irina Gabriela Ionita<sup>1,2</sup>, Catalina Pietrosanu<sup>1,2</sup>, Viorel Zainea<sup>1,2</sup>, **Andreea Rusescu<sup>1</sup>**, Ruxandra Oana Alius<sup>2</sup>, Raluca Oana Pulpa<sup>1</sup>, Mihai Catana<sup>2</sup>, Razvan Hainarosie<sup>1,2</sup>.

<sup>1</sup>"Carol Davila" University of Medicine and Pharmacy, Bucharest, Romania, <sup>2</sup>"Prof. Dr. D. Hociota" Institute of Phonoaudiology and Functional ENT Surgery, Bucharest, Romania

*Benign nasal tumours 1, Building M1 Room Σ3, Sept 29,10.15*

**Background:** Meningoencephalocele is a rare condition consisting of a sac that herniates into the nasal cavities through a defect of the skull base; the content of the sac can be variable: meninges alone or associated with brain tissue. The most common sites of appearance are the fronto-ethmoidal region and the occipital region. The exact cause of the defect is not known, but a multifactorial etiology is considered (with the implication of genetic and environmental factors). Cerebrospinal fluid leak is associated with the meningoencephalocele.

**Methodology/Principal:** Our aim is to present the multidisciplinary approach used in our clinic. The history, clinical examination, interdisciplinary consults and imagistic assessments are of great value for the diagnosis and surgical planning.

**Results:** The transnasal endoscopic approach is suitable for a great number of cases. This approach allows the ENT surgeon and the neurosurgeon to address the tumor, to resect it and close the cerebrospinal fluid leak preventing further complications.

**Conclusions:** Early diagnosis and treatment are mandatory for good long-term clinical results. A multidisciplinary approach offers the possibility to cover all the aspects of the case in a holistic manner.

**Key words:** meningoencephalocele, multidisciplinary approach, endoscopic surgery

**Patrícia Silva Sousa<sup>1</sup>**, José Alberto Fernandes<sup>1</sup>, Clara Magalhães<sup>1</sup>, António Castanheira<sup>1</sup>

<sup>1</sup>*Centro Hospitalar de Trás-os-Montes e Alto Douro, Portugal*

*CRS - surgical management 4, Building M1 Room Σ2, Sept 29,10.15*

**Background:** Frontal osteoplastic flap (FOF) in frontal sinus surgery is performed whenever endoscopic approach is not suitable for frontal sinus disease resolution. Our aim is to present a case series of FOF, highlighting indications, surgical particularities and outcomes.

**Methodology:** A retrospective study including patients who underwent FOF surgery from 2007 to 2019 was performed.

**Results:** Eleven patients underwent FOF, 8 patients were male (73%), the mean age was 50.1 years, (range 22-69 years). Disorders included: 8 osteomas (73%), 2 mucocèles complicated with sinusitis (18%) and 1 case of chronic sinusitis with periorbital cellulitis (9%). Two patients had a previous history of endoscopic surgery or external puncture. The external approach were supraciliary (55%) or bicoronal (45%). Four patients underwent combined endoscopic and supraciliary approach. Two patients with frontal sinusitis and orbital involvement underwent frontal sinus obliteration and partial reconstruction of the orbital roof. Surgical revision was not required and no major complications were reported. Postoperative functional and aesthetic outcomes were very satisfactory.

**Conclusions:** FOF continues to play a main role in frontal sinus surgery for selected cases, providing excellent approach for large tumours or when disease extension remains away from midline. FOF usually has low complication rates and excellent long-term results.

**Key words:** Frontal sinus; Frontal osteoplastic flap; Osteoma; Mucocèle; Chronic sinusitis.

#### Literature

Rivera T, Rodríguez M, Pulido N, García-Alcántara F, Sanz L. Current indications for the osteoplastic flap. *Acta Otorrinolaringol Esp.* 2016;67(1):33-39.

doi:10.1016/j.otorri.2015.01.006

Banks CG, Garcia JAP, Grayson J, Yeon Cho D, Woodworth BA. Osteoplastic Flap Without Obliteration: How I Do It. *Am J Rhinol Allergy.* 2018;32(5):346-349.

doi:10.1177/1945892418782222

Kim M, Otten M, Kazim M, Gudis DA. Frontal osteoplastic flap without frontal sinus obliteration for orbital roof decompression. *Orbit.* 2021;40(2):145-149.

doi:10.1080/01676830.2020.1757126

Isa AY, Mennie J, McGarry GW. The frontal osteoplastic flap: does it still have a place in rhinological surgery?. *J Laryngol Otol.* 2011;125(2):162-168.

doi:10.1017/S0022215110002288

Ochsner MC, DelGaudio JM. The place of the osteoplastic flap in the endoscopic era: indications and pitfalls. *Laryngoscope.* 2015;125(4):801-806. doi:10.1002/lary.25014



Lee JM, Palmer JN. Indications for the osteoplastic flap in the endoscopic era. *Curr Opin Otolaryngol Head Neck Surg.* 2011;19(1):11-15. doi:10.1097/MOO.0b013e3283419453

Sinonasal stents coated with chlorhexidine varnish has sustained protection against bacterial biofilms

Alessandra Cataldo Russomando <sup>1</sup>

*Technological advances 1, Building M1 Room 24, Sept 29,14.45*

**Objectives:** To develop a sustained-release varnish (SRV) containing chlorhexidine (CHX) for sinonasal stents (SNS) to reduce bacterial growth and biofilm formation in the sinonasal cavity.

**Methods:** One-centimeter segments of standard SNS were coated with SRV-CHX or SRV-placebo, and exposed daily to fresh bacterial cultures of either *Staphylococcus aureus* or *Pseudomonas aeruginosa*. Anti-bacterial effects were assessed by disc diffusion assay and planktonic-based activity assay. Biofilm formation on the coated stents was visualized by confocal laser scanning microscopy (CLSM) and high-resolution-scanning electron microscopy (HR-SEM). The metabolic activity of the biofilms was determined using the 3-(4,5-Dimethyl-2-thiazolyl)-2,5-diphenyl-2H-tetrazolium bromide (MTT) method. Release of CHX from SNS in pH 6 media was measured using a Nanodrop spectrophotometer.

**Results:** Disc diffusion assay showed that SRV-CHX-coated SNS segments inhibited bacterial growth of *S. aureus* for 26 days and *P. aeruginosa* for 19 days. The CHX was released from SNS segments in a pH 6 medium up to 30 days, resulting in a growth inhibition of *S. aureus* for 22 days and *P. aeruginosa* for 24 days. The MTT assay showed reduction of biofilm growth on the SNS by 69 % for *S. aureus* and 40 % for *P. aeruginosa* compared to the placebo stent after repeated exposure to planktonic growing bacteria. Likewise, CLSM and HR-SEM showed significant reduction of biofilm formation on the SRC-CHX-coated SNS segments.

**Conclusion:** Coating of SNS with SRV-CHX effectively maintains a sustained delivery of CHX, providing an inhibitory effect on bacterial growth of *S. aureus* and *P. aeruginosa* for approximately 3 weeks.

A prospective clinical controlled trial comparing different treatment of post-infectious smell loss in COVID-19 patients.

Rusetsky Yu.Yu.<sup>1</sup>, Molodnitskaia A.Yu.<sup>2</sup>

ENT Department, Central State Medical Academy of Presidential Affairs<sup>1</sup>; Polyclinic No1 of Presidential Affairs<sup>2</sup>; Moscow, Russia

*Smell and taste 3, Building M2 CR3, Sept 27,14.45*

**Background:** The frequent association between coronavirus disease 2019 (COVID-19) and olfactory dysfunction is creating an unprecedented demand for a treatment of the olfactory loss. The chemosensory deficits are often the earliest, and sometimes the only signs in otherwise asymptomatic carriers of the SARS-CoV-2 virus.

**Methodology/Principal:** 3 groups of post-infectious smell loss in COVID-19 patients during more than 1 month (50 patients each): using intranasal corticosteroids, olfactory training, nothing. Every patient had an ENT examination, fibrolaryngoscopy, olfactory examination (University of Pennsylvania Smell Identification Test), SNOT-22 questionnaire and CT scanning if any ENT pathology was detected.

**Results:** If patients had any type of reported rhinitis before COVID-19 and nasal congestion, using of intranasal corticosteroids during 1 month the sense of smell was back in most cases. Using olfactory training during more than 2 months twice a day gives more positive result compared to the control group.

**Conclusions:** Further research is necessary.

**Key words:** anosmia, COVID-19, olfactory training, intranasal corticosteroids

#### Literature:

1. Croy I, Nordin S, Hummel T. Olfactory disorders and quality of life—an updated review. *Chem Senses* 2014;39:185-94
2. Erskine SE, Philpott CM. An unmet need: patients with smell and taste disorders. *Clin Otolaryngol* 2020;45:197-203.
3. Haehner A, Draf J, Dräger S, de With K, Hummel T. Predictive value of sudden olfactory loss in the diagnosis of COVID-19. *ORL J Otorhinolaryngol Relat Spec* 2020;82:175-80.
4. Le Bon SD, Pisarski N, Verbeke J, Prunier L, Cavelier G, Thill MP, et al. Psychophysical evaluation of chemosensory functions 5 weeks after olfactory loss due to COVID-19: a prospective cohort study on 72 patients. *Eur Arch Otorhinolaryngol*
5. Aziz M, Goyal H, Haghbin H, Lee-Smith WM, Gajendran M, Perisetti A. The Association of "Loss of Smell" to COVID-19: A Systematic Review and Meta-Analysis. *Am J Med Sci*. 2021 Feb;361(2):216-225
6. Rusetsky Y, Meytel I, Mokoyan Z, Fisenko A, Babayan A, Malyavina U. Smell Status in Children Infected with SARS-CoV-2. *Laryngoscope*. 2021 Jan
7. Reden J, Mueller A, Mueller C, Konstantinidis I, Frasnelli J, Landis BN, et al. Recovery of olfactory function following closed head injury or infections of the upper respiratory tract. *Arch Otolaryngol Head Neck Surg* 2006;132:265-9
8. Huart C, Philpott C, Konstantinidis I, Altundag A, Trecca EMC, Cassano M, et al. Comparison of COVID-19 and common cold chemosensory dysfunction. *Rhinology* 2020;58:623-5
9. Huart C, Philpott CM, Altundag A, Fjaeldstad AW, Frasnelli J, Gane S, Hsieh JW,

- Holbrook EH, Konstantinidis I, Landis BN, Macchi A, Mueller CA, Negoias S, Pinto JM, Poletti SC, Ramakrishnan VR, Rombaux P, Vodicka J, Welge-Lüssen A, Whitcroft KL, Hummel T. Systemic corticosteroids in coronavirus disease 2019 (COVID-19)-related smell dysfunction: an international view. *Int Forum Allergy Rhinol*. 2021 Mar 16. doi: 10.1002/alr.22788. Epub ahead of print. PMID: 33728824
10. Addison A, Philpott CM. A systematic review of therapeutic options for nonconductive olfactory dysfunction. *Otorhinolaryngologist* 2018;11:61-71
  11. Croy I, Olgun S, Mueller L, et al. Peripheral adaptive filtering in human olfaction? Three studies on prevalence and effects of olfactory training in specific anosmia in more than 1600 participants. *Cortex*. 2015;73:180-187. doi:10.1016/j.cortex.2015.08.018
  12. Blau JN, Solomon F. Smell and other sensory disturbances in migraine. *J Neurol*. 1985;232(5):275-276. doi:10.1007/BF00313864
  13. Position paper on olfactory dysfunction. *Rhinol Suppl*. 2017 Mar;54(26):1-30. doi: 10.4193/Rhino16.248. PMID: 29528615
  14. van Kempen M, Bachert C, Van Cauwenberge P. An update on the pathophysiology of rhinovirus upper respiratory tract infections. *Rhinology* 1999;37:97-103

Sinonasal-specific quality of life in chronic rhinosinusitis is reflected by four questions reflecting the subdomains of the 22-item Sinonasal Outcome Test

**Marlene M. Speth**<sup>1</sup>, Katie M. Phillips<sup>2</sup> and Ahmad R. Sedaghat<sup>2</sup>

<sup>1</sup>Department of Otorhinolaryngology, Kantonsspital Aarau, Aarau, Switzerland, <sup>2</sup>Department of Otolaryngology – Head & Neck Surgery, University of Cincinnati College of Medicine, Cincinnati, Ohio, USA

*CRS - outcome assessment 2, Building M1 Room Σ1, Sept 28,10.15*

**Background:** When there is a need for frequent sampling, a full 22-item Sinonasal Outcome Test (SNOT-22) to measure chronic rhinosinusitis (CRS) disease burden may be impractical, and an abbreviated measure may be useful. Herein, we study four questions reflecting the four SNOT-22 subdomains as accurate reflections of SNOT-22 content.

**Methodology:** Cross-sectional study of 211 CRS patients. Participants completed a 22-item Sinonasal Outcome Test (SNOT-22) and answered four questions about their nasal symptoms, poor sleep quality, ear/facial pain and mood (reflecting SNOT-22 subdomains) using visual analogue scales (VAS).

**Results:** The four SNOT-22 subdomain questions each correlated strongly with the corresponding SNOT-22 subdomain scores (nasal subdomain:  $r=0.57$ ,  $p<0.001$ ; ear/facial pain subdomain:  $r=0.70$ ,  $p<0.001$ ; sleep subdomain:  $r=0.72$ ,  $p<0.001$ ; emotional subdomain:  $r=0.67$ ,  $p<0.001$ ). Each of the four SNOT-22 subdomain question was also correlated with SNOT-22 items in the corresponding SNOT-22 subdomain. The sum of the 4 subdomain question VAS scores was highly correlated with the total SNOT-22 score ( $r=0.77$ ,  $p<0.001$ ).

**Conclusions:** Information from the SNOT-22 questionnaire, which is commonly used both in clinical and research settings, may be in part ascertained by through four questions reflecting the validated SNOT-22 subdomains. This may be useful in situations when completion of a full SNOT-22 may be impractical.

**Key words:** chronic rhinosinusitis, SNOT-22, subdomains, visual analogue scale, quality of life

**C. Hintschich**<sup>1</sup>, K. H. Schebesch<sup>2</sup>, T. Kühnel<sup>1</sup>

<sup>1</sup> Klinik und Poliklinik für Hals-Nasen-Ohren-Heilkunde, Universitätsklinikum Regensburg, Regensburg, Germany, <sup>2</sup> Klinik und Poliklinik für Neurochirurgie, Universitätsklinikum Regensburg, Regensburg, Germany

*Technological advances 3, Building M1 Room Σ1, Sept 28,14.45*

**Background:** Extended endoscopic endonasal operations of the sinuses, the orbit and the frontal skull base require in many cases a bimanual action of the surgeon. Thus, typically a second surgeon guides the endoscope and canters the field of view. In this study we investigate in which cases a robotic arm can be used alternatively.

**Methodology:** The electromagnetic system produced by AKTORmed was used in different surgical interventions of the sinuses, the pituitary gland and tumours questioning ergometry and geometrical limitations. The realized degrees of freedom were documented, and a topography of possible applications compiled.

**Results:** The presented system is limited through the geometry of the anterior ethmoid and changing working conditions in the sagittal direction. Especially in extended interventions in the posterior ethmoid, in which parts of the nasal septum have been resected and a static position of the endoscope is desired the surgeon can greatly benefit from the robotic arm.

**Conclusions:** Under the impression of an urging staff shortage and due to the unlimited patience, a robotic arm seems promising. Hence, we see especially in the surgery of the pituitary gland and skull base tumours a favourable field of application.

**Key words:**

Robotic surgical procedures, Endoscopy, Skull base, Endoscopy, Paranasal sinus disease, Pituitary gland

## Patient perspectives on acute exacerbations of chronic rhinosinusitis: a qualitative study

**Marlene M. Speth**<sup>1</sup>, Victoria Walker<sup>2</sup>, Michal Trope<sup>2</sup>, Antar A. Tichavakunda<sup>3</sup>, Ahmad R. Sedaghat<sup>2</sup>, Katie M. Phillips<sup>2</sup>

<sup>1</sup>Department of Otorhinolaryngology, Kantonsspital Aarau, Aarau, Switzerland, <sup>2</sup>Department of Otolaryngology—Head and Neck Surgery, University of Cincinnati College of Medicine, Cincinnati, United States of America, <sup>3</sup>School of Education, University of Cincinnati, Cincinnati, United States of America

*CRS - diagnosis and investigations 3, Building M1 Room Σ4, Sept 29,10.15*

**Background:** Acute exacerbations of chronic rhinosinusitis (AECRS) have been studied from the physician perspective, yet the perspective of a key stakeholder—the patient— is not well elucidated. The objective was to understand AECRS from the patient perspective.

**Methodology:** Qualitative phenomenological study using constant comparative methodology was applied. Ten, one-on-one interviews with CRS patients ranging from 45 to 90 minutes in length were conducted. The content of the interview protocol was determined through iterative discussion. Two of the authors served as coders to identify recurrent themes. The themes were analyzed for meaning and conclusions were summarized.

**Results:** Recurring themes included: (1) patients identify with the terms “flare” or “sinus infection” more than “exacerbation”; (2) consistent with the current definition, patients identify AECRS as worsening of sinonasal symptoms, but also associate extranasal symptoms of CRS—including poor sleep, fatigue, lower respiratory exacerbation and malaise—with AECRS; and (3) patients describe AECRS as a significant determinant of decreased quality of life, worse general health and decreased productivity.

**Conclusions:** AECRS have a significant impact on patients and are more complex than a “transient worsening of symptoms” with associated systemic manifestations and functional consequences. Understanding AECRS is pivotal in effectively managing CRS.

**Key words:** chronic rhinosinusitis; acute exacerbations; AECRS; qualitative research; interviews

Conservatory treatment versus oro-hypopharynx surgery in sleep apnea syndrome – a study of the efficiency of the mandibular advancement devices.

**Nicoleta Dumitrescu<sup>1</sup>**

<sup>1</sup>ENT Department, "Saint Spiridon" Clinic, Bucharest, Roumania

*Snoring and OSA 1, Building M2 CR2, Sept 28,14.45*

**Background:** The need for innovative treatment in sleep apnea syndrome is justified by the results of pharynx surgery that, in some cases, can worsen the apnea severity and increase the necessity for continuous positive airway pressure during sleep. This study aims to compare the efficiency of the oro and hypopharyngeal surgical treatment with that of the conservatory treatment by using the mandibular advancement devices.

**Methodology/Principal:** A total of 83 patients, diagnosed with obstructive sleep apnea syndrome, were evaluated at presentation and after 3 months of treatment. 67 patients underwent oro-hypopharyngeal surgical treatment as recommended and 16 patients wore, during sleep, a mandibular advancement device. The patients were assessed using the same protocol and the therapeutic results were quantified according to Sher's criteria.

**Results:** The surgical success evaluated at 3 months for surgery group was 46,26% and for non-surgery group was 56,25%. The apnea-hypopnea index and sleep quality improved in both groups. There were not noticed side effects of wearing the mandibular advancement devices after 3 months of treatment. In addition, the quality of life was considerably improved for non-surgery group.

**Conclusions:** The mandibular advancement devices enlarges the retropalatal and retrolingual space reflected by upgrade of the polysomnographic parameters, of the sleep quality and everyday activities.

**Key words:** mandibular advancement device, pharynx surgery.



## Deep learning automated segmentation of skull base structures for enhanced navigation

**Caio A. Neves<sup>1</sup>**, Emma Tran<sup>2</sup>, Nikolas H Blevins<sup>2</sup>, Peter H Hwang<sup>2</sup>

<sup>1</sup>Faculty of Medicine, University of Brasilia, Brasilia, DF, Brazil, <sup>2</sup>Department of Otolaryngology-Head & Neck Surgery, Stanford University School of Medicine, Stanford, CA, USA

*Technological advances 2, Building M1 Room Σ2, Sept 27,14.45*

**Background:** This study presents the automated segmentation of skull base anatomical structures by a deep learning (DL) approach and the incorporation of the predicted models to an enhanced 3D navigation system.

**Methodology:** The internal carotid artery (CA), the canalicular optic nerve (ON) and the sella turcica (ST) were manually segmented in 150 clinical CT scans to train a supervised DL algorithm. Objective assessment of the auto-segmented structures was performed using the Dice coefficient and Hausdorff's distance (HD) on a holdout set (20 CTs). A navigation system was developed to use the generated models to render a 3D endoscopic virtual scene, suitable for image guidance. The surface registration provided the Target registration error (TRE).

**Results:** The Dice coefficients were  $0.76 \pm 0.12$ ;  $0.81 \pm 0.10$ ;  $0.84 \pm 0.08$  and mean HD in mm were  $0.54 \pm 0.1$ ;  $0.32 \pm 0.09$  and  $0.47 \pm 0.12$  for the CA, ON and ST respectively. Our system was successfully implemented for the transsphenoidal approach to the pituitary on 3 cadaveric heads. The mean TRE was  $1.8 \pm 0.3$  mm, and the surgeon was able to successfully identify the neurovascular targets based on the auto-segmented rendering.

**Conclusions:** We present a solution for the auto-segmentation of middle skull base structures. It can provide valuable anatomical information to promote personalized surgical planning and intraoperative guidance.

**Key words:** Deep Learning, Skull Base, Surgical Navigation Systems, Intranasal Surgery, Computed Tomography

A retrospective study comparing postoperative pain after removal of the nasal hump with osteotome and rasp.

**Isabel E. Costa**<sup>1</sup>, Cátia Azevedo<sup>1</sup>, Diana P. Silva<sup>1</sup>, Mariana L. Graça<sup>1</sup>, Berta M. Rodrigues<sup>1</sup>, Luís Dias<sup>1</sup>.

<sup>1</sup>Otorhinolaryngology and Head and Neck Surgery department, Hospital de Braga, Portugal

*Rhinoplasty 2, Building M2 CR2, Sept 27,11.45*

**Background:** Despite being the most used methods for dorsal hump (DH) removal during a rhinoseptoplasty, the indications and advantages associated with osteotome and rasp are not consensual.

**Methodology/Principal:** Retrospective study including patients with DH deformity followed in our institution between 2013 and 2020. For comparing purposes, the authors assessed the postoperative pain associated with removal of the DH through the use of osteotome and rasp. Variables such as age, characteristics of the nasal deformity, pain (through visual analog scale) or aesthetic and functional satisfaction were collected and analyzed.

**Results:** The final sample was made up of 101 patients. DH was removed in 65 patients using the osteotome (64%) and in 36 using the rasp (36%). There was a statistically significant association between the presence of postoperative pain and the use of the rasp ( $p=.003$ ). In what concerns to functional satisfaction, 84.6% of the patients in the osteotome group revealed that they were “Satisfied”, compared to 63.9% of the individuals in the rasp group ( $p=.011$ ). Aesthetic satisfaction was slightly higher with the osteotome ( $p=.325$ ).

**Conclusions:** The authors concluded that the use of osteotome may be beneficial in relation to the use of rasp, especially from the functional point of view, pain and the need for future surgical interventions.

**Key words:** Rhinoplasty, Nasal Surgery, Pain, Quality of Life, Visual Analog Scale

#### Literature

- Azizzadeh B, Reilly M. Dorsal Hump Reduction and Osteotomies. Clin Plast Surg. 2016;43(1):47-58. doi:10.1016/j.cps.2015.09.022
- Ishii LE, Tollefson TT, Basura GJ, et al. Clinical Practice Guideline: Improving Nasal Form and Function after Rhinoplasty. Otolaryngol Head Neck Surg. 2017;156(2\_suppl):S1-S30. doi:10.1177/0194599816683153
- Taş S. Dorsal Roof Technique for Dorsum Preservation in Rhinoplasty. Aesthet Surg J. 2020;40(3):263-275. doi:10.1093/asj/sjz063
- Tirelli G, Tofanelli M, Bullo F, Bianchi M, Robiony M. External osteotomy in rhinoplasty: Piezosurgery vs osteotome. Am J Otolaryngol. 2015;36(5):666-671. doi:10.1016/j.amjoto.2015.05.006
- Zucchini S, Brancatelli S, Piccinato A, Marcuzzo AV, Bianchi M, Tirelli G. Evaluation of Surgical Outcome in Rhinoplasty: A Comparison Between Rasp and Osteotome in Dorsal Hump Removal. Ear Nose Throat J. 2019;145561319883529. doi:10.1177/0145561319883529
- Saleh AM, Younes A, Friedman O. Cosmetics and function: quality-of-life changes after rhinoplasty surgery. Laryngoscope. 2012;122(2):254-259. doi:10.1002/lary.22390
- Perkins SW, Shadfar S. Complications in Reductive Profileplasty. Facial Plast Surg. 2019;35(5):476-485. doi:10.1055/s-0039-1696990
- Sykes JM, Tapias V, Kim JE. Management of the nasal dorsum. Facial Plast Surg.

2011;27(2):192-202. doi:10.1055/s-0030-1271299

- Barrett DM, Casanueva F, Wang T. Understanding Approaches to the Dorsal Hump. *Facial Plast Surg.* 2017;33(2):125-132. doi:10.1055/s-0037-1598033

## Pleomorphic Adenoma, a Rare Benign Tumour of the Maxillary Sinus – Case report

**Sofia Polainas**<sup>1</sup>, Filipa Ferreira<sup>1</sup>, Catarina Areias<sup>1</sup>, Vítor Proença<sup>1</sup>, Luís Antunes<sup>1</sup>

<sup>1</sup>*Department of Otorhinolaryngology, Hospital Garcia de Orta, Almada, Portugal.*

*Benign nasal tumours 2, Building M1 Room Σ4, Sept 28,10.15*

**Background:** Benign tumours of the nose and nasal cavity are rare and comprise a number of different histological entities. They can cause nasal symptoms such as unilateral obstruction, epistaxis, headache and nasal discharge, or be diagnosed as radiologic incidental findings during imaging investigations for other reasons.

**Methodology/Principal:** the aim of the authors is to describe a clinical case of a patient with a unilateral intranasal mass arising from the maxillary sinus, with the histological diagnosis of pleomorphic adenoma.

**Results:** we present a case of a seventy-two year-old female, who was referred to otorhinolaryngology by her family doctor after an incidental finding in a brain computerized tomography scan. She was asymptomatic. Nasal endoscopy showed a hypervascularized mass in the left middle meatus. After further imaging studies, the hypothesis were antral maxillary mucocele or tumour. A biopsy under local anesthesia gave the histological diagnosis: pleomorphic adenoma. She underwent endoscopic resection, with an uneventful postoperative course.

**Conclusions:** pleomorphic adenoma is a rare benign tumour of the nasal cavity that should be included in the differential diagnosis of unilateral masses of the nasal cavity. Complete resection with sufficiently safe margins is mandatory.

**Key words:** pleomorphic adenoma, maxillary benign tumour

## Chronic rhinosinusitis with polyposis: prognostic factors for recurrence after endoscopic sinus surgery

**Ana Isabel C. Gonçalves<sup>1</sup>**, Pedro Miguel Gomes<sup>1</sup>, Delfim Duarte<sup>1</sup>, Ditzia de Vilhena<sup>1</sup>

<sup>1</sup>Hospital Pedro Hispano, Matosinhos, Porto, Portugal

CRS - surgical management 3, Building M2 CR3, Sept 28,10.15

**Background:** We aim to determine predictors of polyposis recurrence and revision surgery in patients with chronic rhinosinusitis with nasal polyposis (CRSwNP).

**Methodology:** Retrospective study of patients with CRSwNP who underwent endoscopic sinus surgery between January 2010-December 2018 in our center. *We analyzed:* age, gender, presence of asthma, intolerance to NSAIDs and allergic rhinitis, clinical grade of polyposis, Lund-Mackay (LM) score, tobacco use, occupational exposures, percentage of blood eosinophils, involvement of frontal sinus, intranasal corticosteroid therapy (CCT) *postoperatively*, nasal polyposis recurrence and revision surgery.

**Results:** 270 patients were included. Polyposis recurrence was observed in 31.3% with a revision surgery rate of 27.3%. There were statistically significant associations between recurrence and intolerance to aspirin (OR 0.284;  $p=0.008$ ), percentage of eosinophils in peripheral blood ( $p=0.006$ ), as well as with the preoperative LM score ( $p=0.006$ ), with the involvement of the frontal sinus (OR 7.169;  $p<0.001$ ) and with the use of intranasal corticosteroid therapy (OR 2.850;  $p=0.032$ ).

**Conclusions:** Patients with CRSwNP who have intolerance to NSAIDs, higher percentages of blood eosinophils, a higher LM score *or* involvement of frontal sinus seem to have a higher risk of recurrence and *revision surgery*. The use of intranasal CCT *postoperatively* is also associated with better long-term results.

### Literature

Du K, Zheng M, Zhao Y, Jiao C, Xu W et al. A nomogram combining peripheral parameters for estimation of CRSwNP recurrence. *Am J Rhinol Allergy*. 2020; 0(0): 1-9.

Vlaminck S, Acke F, Prokopakis E, Speleman K, Kawauchi H et al. Surgery in nasal polyp patients: outcome after a minimum observation of 10 years. *Am J Rhinol Allergy*. 2020; 0(0): 1-9.

Wang X, Meng Y, Lou H, Wang K, Wang C et al. Blood eosinophil count combined with asthma history could predict chronic rhinosinusitis with nasal polyp recurrence. *Acta Otolaryngol*. 2020; 1-7.

Wu C-L, Lee T-J, Huang C-C, Chang P-H, Fu C-H. Clinical predictors of revision surgery for chronic rhinosinusitis with nasal polyposis within 5-year follow-up. *Am J Otolaryngol*. 2020; 41:1-4.

**Christoforos Constantinou<sup>1</sup>**, Sanjeeva Jeyaretna<sup>2</sup>, Pablo Martinez-Devesa<sup>1</sup>, Ali Qureishi<sup>1</sup>

<sup>1</sup>Dept of ENT, Oxford University Hospitals NHS Foundation Trust, Dept of ENT, West Wing, John Radcliffe Hospital, Oxford, OX3 9DU, <sup>2</sup>.Dept of Neurosurgery Oxford University Hospitals NHS Foundation Trust, West Wing, John Radcliffe Hospital, Oxford, OX3 9DU

*Sinonasal malignancy 4, Building M1 Room Σ4, Sept 27,14.45*

We present the surgical management of a case of olfactory neuroblastoma, which is a rare malignant neuroectodermal neoplasm of the sinonasal cavity, with intracranial extension. A 50-year-old female presented with a 6-month history of Left-sided nasal obstruction and intermittent epistaxis. Initial examination revealed a unilateral nasal polyp that was thought to represent an olfactory neuroblastoma on MRI scanning and was later confirmed on histological assessment post biopsy.

Traditionally for complete surgical clearance, a bicranial-facial approach was used to resect such tumours. However, more recently endoscopic approaches have been used and we describe one of these cases here.

The patient underwent an endoscopic endonasal resection of the tumour.

Once macroscopic clearance of the tumour was achieved, the resection defect was sized and a left fascia lata graft was harvested. A multilayer reconstruction was then performed. Post-operatively, no residual disease was seen on imaging and the patient was referred for proton beam radiotherapy.

We present the steps used for successful resection of an olfactory neuroblastoma with intracranial extension using an endoscopic approach alone. We hope your readers find the technique instructive.

**Key words:** Sinonasal skull base, Olfactory Neuroblastoma, Endoscopic resection,

#### Literature

- 1) Bell D. Sinonasal Neuroendocrine Neoplasms: Current Challenges and Advances in Diagnosis and Treatment, with a Focus on Olfactory Neuroblastoma. Head Neck Pathol. 2018;12(1):22-30
- 2) Thompson LD. Olfactory neuroblastoma. Head Neck Pathol. 2009;3(3):252-259.
- 3) Hyams VJ, Batsakis JG, Michaels L. Tumors of the upper respiratory tract and ear. Armed Forces Institute of Pathology Fascicles. 2nd series. Washington: American registry of pathology press; 1988

**Taras Kunakh<sup>1</sup>**<sup>1</sup>ENT Center, Clinical Hospital "Feofaniya", Kyiv, Ukraine*CRS - surgical management 2, Building M2 CR3, Sept 27,10.15*

**Background:** Revision endoscopic surgery on the frontal sinuses are difficult, because of the altered anatomy and important adjacent structures, it has a high risk of complications. To prevent failures of revision frontal sinuses surgery, the key point in such operations is to ensure an adequate drainage pathway. If it is impossible to provide a stable drainage pathway, an obliteration of the frontal sinuses is considered.

**Methodology/Principal:** The study included 78 cases of revision endoscopic frontal sinus operations, performed in our institution from 2015 to 2021. Before surgery computed tomography of paranasal sinuses was performed for all patients.

Endoscopic frontal sinus drainage type I – III according to Draf was performed in classic way separately or combined with additional external approach.

**Results:** A total of 284 operations on the frontal sinuses were performed in our clinic during this period, 78 cases were revision surgery. Previous operations were performed in our clinic in 16 cases (rate of reoperation 5,97%), in other cases previous operations were performed in other clinics. In most cases, previous operations were endoscopic endonasal (67), in others external accesses (11).

Distribution by disease: Chronic rhinosinusitis with nasal polyps 73,1%, Chronic rhinosinusitis without nasal polyps 23,1%, Benign tumour 3,8%

Distribution by type of drainage: Draf I 2,56%, Draf IIa 44,87%, Draf IIb 39,74, Draf III 8,97. Additional external access was used in 6 cases. In 3 cases - fat obliteration (3,84%).

**Conclusions:** 1. The choice of access and type of enlargement of the drainage pathway depends on the features of the disease and the anatomy of the frontal recess and frontal sinus.

2. The use of external accesses during the previous operation is not a contraindication to endoscopic endonasal surgery.

3. If it is impossible to provide a stable drainage pathway, it is necessary to consider the obliteration of the frontal sinuses.

Key words: revision endoscopic sinus surgery, endoscopic sinus surgery, frontal sinus

## Experimental and computational fluid dynamics investigation of pressure distribution in a nasal cavity before and after maxillary sinus surgery

M. Abbasi<sup>1</sup>, H Amjadimanesh<sup>1</sup>, M. Faramarzi<sup>2</sup>, **S. Sadrizadeh**<sup>3</sup>, O. Abouali<sup>1,3</sup>

<sup>1</sup>School of Mechanical Engineering, Shiraz University, Shiraz, Iran, <sup>2</sup>Shiraz University of Medical Science, Shiraz, Iran, <sup>3</sup>Department of Civil and Architectural Engineering, KTH University, Stockholm, Sweden

*Rhinology – miscellaneous 3, Building M1 Room Σ1, Sept 27,11.45*

**Background:** How do the uncinectomy and middle meatal antrostomy (MMA) affect the air pressure in the Maxillary sinus?

**Methodology/Principal:** A 3D realistic model of the nasal cavity was developed based on CT images of a healthy adult human. The virtual uncinectomy and MMA were performed on this model. Two replicas corresponding to pre- and post-operative cases have been manufactured by a 3D printer. The pressure distribution in the human nasal cavity and the effect of maxillary sinus surgery were studied numerically and experimentally at three breathing rates of 10, 20, and 40 (L/min).

**Results:** Uncinectomy and MMA significantly increase ventilation of maxillary sinuses and this is more noticeable in higher inspiratory flow rates. In the inhalation phase, this functional endoscopic sinus surgery (FESS) decreases the pressure of the sinuses. The difference of pressure in the maxillary sinus between pre and postoperative cases increases with increasing respiratory rate.

**Conclusions:** Comparison of CFD (Computational fluid Dynamics) results with measured pressures data indicates a reasonable agreement. Hence, the outcome of the FESS on the airflow changes in the nasal cavity can be predicted by a CFD simulation before performing the real surgery. This is a big step toward the personal medicine.

**Key words:** CFD, Experimental investigation, Maxillary sinus, FESS, Pressure



## Using Item response theory for psychometric properties and possibilities to shorten the 22-Item Sino-Nasal Outcome Test (SNOT-22)

**David T. Liu<sup>1</sup>**, Katie M. Phillips<sup>2</sup>, Marlene M. Speth<sup>3</sup>, Gerold Besser<sup>1</sup>, Christian A. Mueller<sup>1</sup>, and Ahmad R. Sedaghat<sup>2</sup>

<sup>1</sup>Department of Otorhinolaryngology, Head and Neck Surgery, Medical University of Vienna, Vienna, Austria,

<sup>2</sup>Department of Otolaryngology—Head and Neck Surgery, University of Cincinnati College of Medicine, Cincinnati, United States of America, <sup>3</sup>Department of Otorhinolaryngology, Kantonsspital Aarau, Aarau, Switzerland

*CRS - outcome assessment 1, Building M1 Room Σ4, Sept 27,10.15*

**Background:** The 22-item Sinonasal Outcome Test (SNOT-22) is a high-quality outcome measure that assesses chronic rhinosinusitis (CRS)-specific quality of life. Even with such a high-quality instrument, patients can be overwhelmed by repeated completion of questionnaires. The aim of this study was to evaluate psychometric properties of the SNOT-22 and whether it could be made more concise without losing the valuable information that it provides.

**Methodology/Principal:** This study used a modern methodological framework, item response theory (IRT), on a sample of 800 patients with chronic rhinosinusitis (CRS) to determine psychometric properties of the SNOT-22. Two different IRT-approaches were then used to refine the SNOT-22, while correlation and reliability analyses were used to assess preliminary reliability and validity.

**Results:** IRT-parameters item discrimination, difficulty, and total information provided showed considerable variability between individual SNOT-22 items. Based on two different IRT-approaches, we found it possible to shorten the SNOT-22 to an 11-item and 6-item version. Preliminary reliability and validity analyses showed good to excellent reliability and validity of both shortened scales.

## Chronic rhinosinusitis symptoms differentially impact the likelihood of major depressive disorders

**David T. Liu<sup>1</sup>**, Tina J. Bartosik<sup>1</sup>, Nick Campion, Karina Bayer<sup>1</sup>; Aldine Tu<sup>1</sup>; Stanek V<sup>1</sup>, Gerold Besser<sup>1</sup>, Christian A. Mueller<sup>1</sup>, Katharina Gangl<sup>1</sup>, Julia Eckl-Dorna<sup>1</sup>, Sven Schneider<sup>1</sup>

<sup>1</sup>Department of Otorhinolaryngology, Head and Neck Surgery, Medical University of Vienna, Vienna, Austria

*CRS - diagnosis and investigations 1, Building M1 Room Σ3, Sept 27,10.15*

**Background:** The extent to which sino-nasal symptoms impact the likelihood of major depressive disorders in patients with chronic rhinosinusitis (CRS) remains incomplete characterized. We sought to determine whether individual symptom clusters differentially impact the likelihood of depression in a cohort of CRS patients with nasal polyposis (CRSwNP).

**Methodology/Principal:** Retrospective cross-sectional study of 77 CRSwNP patients. Sino-nasal symptom severity was assessed using the 22-item Sino-nasal Outcome Test (SNOT-22) and grouped according to a validated 4-subdomain structure: nasal, otologic/facial pain, sleep, and emotional subdomains. The likelihood of major depressive disorders was assessed using the Patient Health Questionnaire-2 (PHQ-2). Clinical characteristics of symptom severity (nasal polyp size) were also collected.

**Results:** The sleep subdomain was most strongly associated with the likelihood of major depressive disorders, followed by the otologic/facial pain subdomain, even after controlling for clinical indicators of symptom severity. We found the SNOT-22 threshold of 30.5 to be an accurate indicator to score greater or equal 2 on the PHQ-2 with a sensitivity of 83.33% and a specificity of 75.47%.

**Conclusions:** Different sino-nasal symptom clusters differentially impact the likelihood of depression in CRSwNP patients. Raising awareness for those with severe sino-nasal symptomatology might help to identify more patients with comorbid depression.

**Key words:** Chronic Rhinosinusitis, Depression, SNOT-22, Sino-nasal Outcome Test 22, Quality of Life, Anxiety, PROM, Outcome Research

## Four-year follow-up study after endoscopic sinus surgery (reboot technique) in patients with severe chronic rhinosinusitis with nasal polyps

**S. Lialiaris<sup>1</sup>**, M. Katsilidou<sup>1</sup>, P. Stamkopoulou<sup>1</sup>, M. Zisoglou<sup>1</sup>, G. Fyrmipas<sup>1</sup>, M. Katotomichelakis<sup>1</sup>

<sup>1</sup> Department of Otorhinolaryngology, Medical School, Democritus University of Thrace, Alexandroupolis, Greece

*CRS - surgical management 1, Building M2 CR3, Sept 29,10.15*

**Background:** Severe chronic rhinosinusitis with nasal polyps (CRSwNP) is a type 2 inflammation with multiple disease recurrences after surgical treatment. The reboot technique goal is to remove the entire sinus mucosa and allow healthy re-epithelialization from the preserved healthy mucosa. We present our clinical experience using this technique.

**Methodology:** Four patients with severe type 2 CRSwNP who underwent the reboot approach, were evaluated by endoscopy (Lund-Kennedy score), computed tomography scan (Lund-Mackay), Visual Analogue Scale symptom score and a Quality of Life test, the Sino-nasal outcome test (Snot-22), four years after surgery.

**Results:** All clinical parameters were significantly improved. Average endoscopy score was improved from 11.5 to 0.5, Lund-Mackay score from 21.75 to 0.75, Snot-22 score from 62.0 to 6.5 (all  $p < 0.001$ ) and symptom score went from 33.75 to 2.75 ( $p < 0.005$ ), within a period of 4 years.

**Conclusions:** All patients presented significant clinical improvement after the reboot operation. Despite the small number of patients treated, reboot sinus surgery offers a long lasting alternative surgical approach in type 2 nasal polyposis and warrants further scientific testing.

**Keywords:** Chronic rhinosinusitis with nasal polyps; Reboot technique; Snot-22; Lund Kennedy Endoscopy score, Lund-Mackay CT score

### Literature:

1. Calus L, Van Bruaene N, Bosteels C et al. Twelve-year follow-up study after endoscopic sinus surgery in patients with chronic rhinosinusitis with nasal polyposis. *Clin Transl Allergy* 2019; 14: 9-30.
2. De Conde AS, Mace JC, Levy JM et al. Prevalence of polyp recurrence after endoscopic sinus surgery for chronic rhinosinusitis with nasal polyposis. *Laryngoscope* 2017; 127: 550-555.
3. Alsharif S, Jonstam K, Thibaut van Zele et al. Endoscopic Sinus Surgery for Type-2 CRS wNP: An Endotype-Based Retrospective Study. *Laryngoscope* 2019; 129: 1286-1292.
4. Bachert C, Zhang N, Peter W Hellings PW and Bousquet J. Endotype-driven care pathways in patients with chronic rhinosinusitis. *J Allergy Clin Immunol* 2018; 141: 1543-1551.
5. Malvezzi L, Pirola F, De Virgilio A and Heffler E. Long-lasting clinical, radiological and immunological remission of severe nasal polyposis by means of 'reboot' surgery. *BMJ Case Rep.* 2020; 2;13(4): e233726

# Leukocyte- and Platelet-Rich Fibrin in endoscopic endonasal skull base reconstruction

**Birgit Coucke<sup>1,2,4</sup>**, Tom Theys<sup>1,4</sup>, Johannes van Loon<sup>1,4</sup>, Laura Van Gerven<sup>2,3</sup>

<sup>1</sup> KU Leuven, Department of Neurosciences, Laboratory for experimental Neurosurgery and Neuroanatomy, Leuven, Belgium and Leuven Brain Institute (LBI), <sup>2</sup> KU Leuven, Department of Microbiology, Immunology and Transplantation, Allergy and Clinical Immunology Research Group, KU Leuven, Leuven, Belgium, <sup>3</sup> UZ Leuven, Department of Otorhinolaryngology, Head and Neck Surgery, Leuven, Belgium, <sup>4</sup> UZ Leuven, Department of Neurosurgery, Leuven, Belgium

*Septal and turbinate surgery 1, Building M1 Room Σ2, Sept 27,10.15*

**Background:** Cerebrospinal fluid leakage represents a major complication after endoscopic endonasal skull base surgery. Adequate dural closure is necessary, but no standardized reconstruction method has been defined. The application of autologous materials, including leukocyte- and platelet-rich fibrin (L-PRF) membranes, has gained increasing interest. However, the characteristics of those materials need to be investigated.

**Methodology/Principal:** We determined the cellular content of L-PRF membranes with flow cytometry after one and two weeks of incubation. Growth factor concentrations in L-PRF conditioned medium were determined using ELISA on several time points between 2 days and 6 weeks. Cytokines studied included TGF-β, EGF, VEGF, bFGF, IGF-I and PDGF-AB.

**Results:** CD15+ granulocytes were predominant in fresh L-PRF samples (40.95% of CD45+ cells), whereas both one and two weeks incubated samples contained mostly CD4+ T cells (44.9% and 43.6% of CD45+ cells). TGF-β and PDGF-AB concentrations were highest in L-PRF conditioned medium up to 2 weeks (66.2 ng/mL and 6.8 ng/mL respectively).

**Conclusions:** L-PRF possesses distinct biological properties which could render it suitable for skull base reconstruction after endoscopic endonasal surgery. These characteristics include the autologous nature, possible enhanced healing and immunologic properties. However, safety and efficacy needs to be further elaborated in powered clinical trials.

**Key words:** Cerebrospinal fluid leak, dura mater, platelet-rich fibrin

## Literature

1. Choukroun J, Adda F, Schoeffler C, Vervelle A (2001) Une opportunité en parodontologie: le PRF. *Implantodontie* 42:e62
2. Theys T, Van Hoylandt A, Broeckx C-EE, Van Gerven L, Jonkergouw J, Quirynen M, van Loon J (2018) Plasma-rich fibrin in neurosurgery: a feasibility study. *Acta Neurochir (Wien)* 160:1497–1503. doi: 10.1007/s00701-018-3579-8

## Multi-institutional minimum clinically important difference of the 22-item Sinonasal Outcome Test in medically managed chronic rhinosinusitis

Katie M. Phillips, MD<sup>1</sup>, Firas A. Houssein, B.S.<sup>1</sup>, Lauren M. Boeckermann, B.S.<sup>1</sup>, Kyle W. Singerman, B.S.<sup>1</sup>, David T. Liu, M.D.<sup>2</sup>, and **Ahmad R. Sedaghat**, MD, PhD<sup>1</sup>

<sup>1</sup>Department of Otolaryngology – Head & Neck Surgery, University of Cincinnati College of Medicine, Cincinnati, Ohio, USA, <sup>2</sup>Department of Otorhinolaryngology, Head and Neck Surgery, Medical University of Vienna, Vienna, Austria

*CRS - outcome assessment 1, Building M1 Room 24, Sept 27, 2015*

**Background:** With rapid proliferation of clinical trials to study novel medical treatments for CRS, the objective of this study was to study the MCID of the 22-item Sinonasal Outcome Test (SNOT-22) in medically-managed CRS patients.

**Methods:** A total of 183 medically-treated CRS patients were recruited. All patients completed a SNOT-22 at enrollment and subsequent follow up visit. Distribution and anchor-based methods were used for MCID calculation. These data were combined with data from a previously published study on SNOT-22 MCID in 247 medically managed CRS patients to determine a final recommended MCID value using the combined cohort of 430 patients.

**Results:** In our cohort, we found greatest support for a 12-point SNOT-22 MCID, which had approximately 55% sensitivity but 81% specificity for detecting improved patients. In the combined cohort of 430 patients, we also found greatest support for a 12-point SNOT-22 MCID, which had approximately 57% sensitivity and 81% specificity for detecting improved patients. We also find evidence that the MCID value may be higher in CRS patients without nasal polyps compared to those with nasal polyps.

**Conclusions:** Our results—including patient data from two different institutions and regions—confirm a SNOT-22 MCID of 12 in medically managed CRS patients.

**Keywords:** chronic rhinosinusitis, SNOT-22, MCID, minimal clinically important difference, quality of life, patient-reported outcomes

## Consent for septoplasty: are we meeting patients' expectations?

Haseem Raja<sup>1</sup>, **Rishi Talwar**<sup>1</sup>

<sup>1</sup>ENT Department, Luton and Dunstable University Hospital, Luton, England.

*Septal and turbinate surgery 1, Building M2 CR3, Sept 28,14.45*

**Background:** The practice of consent was transformed in 2015 following the United Kingdom (UK) Supreme Court judgement of 'Montgomery v Lanarkshire Health Board'. This study examines the current standard of consent for septoplasty and whether the 'reasonable patient' and Ears, Nose and Throat (ENT) surgeon agree about which risks should be discussed during the consent process.

**Methodology/Principal:** Ten complications were identified from a literature search, including review of ENT UK Guidelines, as common or serious following septoplasty. ENT surgeons were asked which complications they routinely discussed and patients were asked how seriously they regarded these complications using a 5-point Likert scale. Results were compared with the Test of Proportions.

**Results:** Consent practice from 21 surgeons and data from 103 patients was analysed. Most surgeons routinely discussed all risks except negative change in sense of smell and numbness of upper incisors. The 'reasonable patient' regarded these two complications as serious or very serious. However, less than 70% of surgeons mentioned them.

**Conclusions:** A significant proportion of surgeons do not routinely mention all the risks that the 'reasonable patient' would want to know about before undergoing a septoplasty. This may lead to increased clinical negligence claims and, thus, warrants greater awareness and attention from surgeons.

**Key words:** Consent, Montgomery, Septoplasty

Haseem Raja<sup>1</sup>, **Rishi Talwar**<sup>1</sup>

<sup>1</sup>ENT Department, Luton and Dunstable University Hospital, Luton, England.

*Rhinology – miscellaneous 4, Building M1 Room Σ1, Sept 27,14.45*

**Background:** The 2015 United Kingdom (UK) Supreme Court judgment of ‘Montgomery v Lanarkshire Health Board’ set a precedent for the practice of consent. This study examines the current standard of consent for functional endoscopic sinus surgery (FESS) and whether it complies with the law.

**Methodology/Principal:** Ten complications were identified from a literature search, including review of ENT UK Guidelines, as common or serious following FESS. ENT surgeons were asked which complications they routinely discussed and patients were asked how seriously they regarded these complications using a 5-point Likert scale. Results were compared with the Test of Proportions.

**Results:** Consent practice from 21 surgeons and data from 103 patients was analysed. Most surgeons would routinely discuss all risks except for facial paraesthesia and damage to nasolacrimal duct. Most patients regarded facial paraesthesia and damage to nasolacrimal duct as serious/very serious (92% and 77%, respectively) however less than a third of surgeons mentioned them.

**Conclusions:** Most ENT surgeons do not routinely mention all the risks that the 'reasonable patient' would want to know about before undergoing FESS. This may lead to increased clinical negligence claims and, thus, warrants greater awareness and attention from surgeons.

**Key words:** Consent, Montgomery, FESS

## Reduction of otorhinolaryngological consultations and its impact on disease progression due to the COVID-19 lockdown.

**Sarina Bucher<sup>1</sup>**, Aline S. Neumann<sup>1</sup>, Christian M. Meerwein<sup>1</sup>, David Holzmann<sup>1</sup>, Michael B. Soyka<sup>1</sup>

<sup>1</sup> Department of Otorhinolaryngology Head and Neck Surgery, University and University Hospital Zurich, Zurich, Switzerland

*CRS - medical management 1, Building M2 CR2, Sept 27,10.15*

**Background:** To compare consultations at the Otorhinolaryngological Department between the COVID-19 lockdown in 2020 and the same period in 2019, as well as to study the impact of deferring visits on disease progression.

**Methods:** The emergency consultations during these time periods were analyzed retrospectively. The effect of postponing appointments on disease progression was examined for 122 patients with chronic rhinosinusitis (CRS), for 50 patients with a benign tumor and for 22 patients with the diagnosis of a malignant tumor. To compare disease progression patients with the diagnosis of a malignant tumor were matched to patients seen over the same period in 2019.

**Results:** During the lockdown, a reduction of 44.1% in emergency consultations compared to 2019 was observed. Disease progression was seen in 44.4% of CRS patients. In 2020, 18.8% of patients with the diagnosis of a malignant tumor showed disease progression, yet no difference to the previous year was observed.

**Conclusions:** Less emergency consultations took place during the COVID-19 lockdown, among others, less visits due to otitis media and tonsillitis; however, no change in the incidence of complications was noted. Almost 50% of CRS patients showed disease progression, leading to prolonged suffering due to the rescheduling of appointments. The treatment of patients with the diagnosis of a malignant tumor was not affected by the postponement of consultations.

**Key words:** COVID-19 pandemic, emergency visits, disease progression



**Jorge Canha Dentinho<sup>1</sup>**, Rita Ferreira<sup>2</sup>, Sofia Polainas<sup>1</sup>, Mariana Branco<sup>1</sup>, Sílvia Fidalgo Alves<sup>1</sup>, Susana Carmona<sup>2</sup>, Ana Isabel Santos<sup>2</sup>, Luís Antunes<sup>1</sup>

<sup>1</sup>Otorhinolaryngology Department – Hospital Garcia de Orta, Almada, Portugal, <sup>2</sup>Nuclear Medicine Department – Hospital Garcia de Orta, Almada, Portugal

*Lacrima Surgery 1, Building M1 Room Σ4, Sept 27,11.45*

**Background:** Endoscopic dacryocystorhinostomy (DCR) is the most suitable treatment for obstruction in the lacrimal sac or nasolacrimal duct. Recent studies show that the success is independent of the level of obstruction in Lacrimal Scintigraphy (LS).

**Methodology:** Clinical data of DCRs that had clinical information and had previous Computed Tomography (CT) or LS (n=56) were reviewed. Full improvement (FI) was defined as absence of epiphora, infections or revision surgery in follow-up time, up to 2 years. All the LS were reclassified by an independent expert. The data was analysed through SPSS 25 (IBM).

**Results:** In the presence of dacryocystocele the rate of FI was significantly higher (90,9%) than in the absence (54,3%), p=0.028.

When the level of obstruction in LS was pre-sac, 67,9% had FI vs. 87.5% when intra-sac or post-sac, p=0.274.

Patients with pre-sac obstruction in LS without dacryocystocele had FI rate of 58,8%, versus 89.5% when patients had dacryocystocele or lower levels obstruction in LS, p=0.034.

In all the patients with dacryocystoceles that had LS (n=5), it suggested pre-sac obstruction.

**Conclusions:** DCR has better results in the presence of dacryocystocele. Patients with pre-sac obstruction in LS, without dacryocystocele, had poorer outcomes. LS is not useful by itself to predict functional success.

**Key words:** Lacrimal scintigraphy, Endoscopic dacryocystorhinostomy, Computed Tomography, success, dacryocystocele

#### Literature

- Sagili S, Selva D, Malhotra R, Lacrimal scintigraphy: “Interpretation More art than science”. Orbit, 31(2), 77–85, 2012
- Kim DJ, Baek S, Chang M. Usefulness of the dacryoscintigraphy in patients with nasolacrimal duct obstruction prior to endoscopic dacryocystorhinostomy. Graefes Arch Clin Exp Ophthalmol. 2019 Jul;257(7):1535-1540. doi: 10.1007/s00417-019-04303-4. Epub 2019 Apr 29.
- Penttilä E, Grigori Smirnov G, Tuomilehto H, Kaarniranta K, Seppä J. Endoscopic dacryocystorhinostomy as treatment for lower lacrimal pathway obstructions in adults: Review article. Allergy Rhinol (Providence). 2015 Spring; 6(1): e12–e19.

## Early and late consequences of Nasal trauma in children and adolescents - Is the treatment same as in adults

**Gabriela Kopacheva – Barsova<sup>1</sup>**

<sup>1</sup>ENT University Hospital, University Campus "St. Mother Theresa" Skopje, North Macedonia

*Paediatric rhinology 1, Building M2 CR3, Sept 28,11.45*

**Background:** Nasal trauma in children should be properly treated, because it can lead to displacement or depression of the nasal bones or septum. Second, our A

**Aim:** for the patient to recognize and create a mature decision for eventual nose changes which will be made with the operative intervention or they are not mature enough and the decisions were made by their parents.

**Material and Methods:** Our retrospective study was made at University Clinic for Ear, Nose and Throat, Faculty of Medicine, Ss Cyril and Methodius University of Skopje in the period of 10 years (2010-2021). Seventy-three patients were admitted with recent or previous nasal trauma or nasal deformity. The first group of 32 was children and adolescents from 6-14 years old who were admitted to our hospital because of recent nasal trauma. The second group of 41 children and adolescents from 6-14 years old were admitted to our hospital because of previous nasal trauma, which was not treated on time, or it was not treated properly. They were admitted to our clinic for surgical intervention septo/rhinoplasty. The second group of patients fills the brief psychological questioner prepared by Clinical psychiatrist from University Clinic of Psychiatry, in Skopje, and their psychological reactions were taken into consideration.

**Results:** Eleven of the children and adolescents who had nasal fracture without dislocation, who have no symptoms, minimal swelling, and no septal deviation or hematoma, were observed with a specific follow-up: 3 days after nasal fracture, then every week in the first month, after 1 month, and after 3 months period. Sixteen of children and adolescents who had a nasal fracture with subluxation of nasal septum were operated with closed reduction (repositio nasi) under general anaesthesia. The others with septal hematomas and subperichondrial abscess were treated as in adults' patients. The second group of 41 children and adolescents from 6-14 years old consisted with the previous nasal trauma which was not treated on time or it was improperly treated. In 24 (58.54%) of these patients septoplasty was performed and in 17 (41.46%) was performed rhino septoplasty. Often, difficult septal deformations in children are followed with deformation of the nasal pyramid (rhino scoliosis, rhino lordosis). In those cases, we cannot solve septal pathology without nasal pyramid intervention in the same time and opposite.

**Conclusion:** Clinical reports have not produced solid evidence for the statement that septal surgery has no negative effect on nasal growth or can serve for correcting abnormal growth. The functional and esthetic problems of the patient, however, mean a continuous stimulus

for further clinical and experimental investigations.

Key words: nasal trauma, children and adolescents, treatment, septorhinoplasty

## The role of Loss of Smell and Taste in determining the development of antibody responses in recovered COVID-19 patients at 14 months

**Puya Dehgani-Mobaraki<sup>1</sup>**, Asiya K Zaidi<sup>1</sup>, Nidhi Yadav<sup>1</sup>, Alessandro Floridi<sup>2</sup>, Emanuela Floridi<sup>2</sup>

<sup>1</sup>Association “Naso Sano”, Umbria Regional Registry of Volunteer Activities, Corciano, Italy, <sup>2</sup>Laboratory of Nuclear Lipid BioPathology, Centro Ricerche Analisi Biochimico Specialistiche, Perugia, Italy

*Smell and taste 2, Building M2 CR2, Sept 27,14.45*

**Background:**The loss of smell and taste are significant symptoms experienced by patients infected by SARS-CoV-2 virus. A better understanding of immunological responses by recovered COVID-19 patients against SARS-CoV-2 after natural infection could provide valuable insights into the future implementation of health policies, including vaccination strategies.

**Methods:**A longitudinal observational analysis of IgG antibody titers was carried out in 32 recovered COVID-19 patients based in the Umbria region of Italy for 14 months after Mild and Moderately-Severe infection. Two FDA approved immunoassays against SARS-CoV-2 Nucleocapsid protein and anti-spike-receptor binding domain were used for sequential serological tests at different time points. The demographics, clinical history and symptom profile associated with the magnitude and longevity of antibody responses across 14 months were also analyzed.

**Results:**Neutralizing antibodies against the spike-receptor binding domain persisted in 96.8% (31 of 32) subjects at 14 months. Patients reporting loss of smell and taste during the clinical course of the disease developed significantly higher antibody titers ( $p = 0.043$  and  $p = 0.031$  respectively).

**Conclusions:**This study highlights a possible correlation between highly specific COVID-19 symptoms, such as altered sense of smell and taste, with respect to disease severity and the development of protective neutralizing antibodies against the virus.

**Key words:**Loss of smell and Taste, SARS-CoV-2, Covid19, Coronavirus, Humoral immunity, neutralizing antibodies

## The outcomes of FNE in 110 children from 3 to 10 years of age for adenoid hypertrophy and new concepts in management of associated OME

**Ved Narang**<sup>1</sup>, Anna Loro<sup>2</sup>

<sup>1</sup>Consultant ENT, University Hospital, Monklands, Airdrie, ML60JS, Scotland, UK, <sup>2</sup> Clinical Development Fellow, University Hospital, Monklands, Airdrie, ML60JS, Scotland, UK

*Paediatric rhinology 2, Building M2 CR3, Sept 28,11.45*

**Key Words:** Adenoid Hypertrophy, Fibre-optic Nasal Endoscopy (FNE), Non-obstructive adenoids (Grade 1 and 2), Obstructive adenoids (Grade 3 and 4), Otitis media with effusion (OME),

**Background:** Otolaryngologists often face a challenge in reaching a definitive diagnosis of adenoid hypertrophy. We share our clinical experience using readily available 4.0 mm fibre-optic nasal endoscopic examination (FNE) under LA.

We also re-examined the concept of managing patients of OME with obstructive adenoids (OA) with an initial conservative period followed by surgery.

**Methodology :** A one-armed retrospective cohort of 110 patients between 3 and 10 years of age, who were split into two groups by age, sitting unrestrained and examined by a single consultant.

We compared the acceptance rate to FNE between the two groups, analysed correlation between the adenoid size and key symptoms, size of the tonsils, theatre findings and management of OME.

**Results of 110 children:** 86% of children willingly cooperated through the procedure. There was no statistical difference observed between the two age groups. ( $p=0.8934$ ). 33% of patients with non-OA were discharged to home.

The findings of OA on FNE corroborated in all patients in operation room. The symptoms of "Snoring + Mouth breathing." ( $p=0.0076$ ) and apnoeic episodes ( $p=0.0088$ ) were significantly correlated with OA. The size of the tonsils and adenoids was independent of each other ( $p=0.1143$ ).

All patients with OA and Type b tympanogram needed adenoidectomy & grommet insertion ( $p=0.0119$ ).

**Conclusions:** FNE with 4.0 mm scopes can help us reach a quick, definitive diagnosis in most children above three years. Presence of significant symptoms can guide us schedule patients for EUA in children refusing FNE.

Narrow diameter scopes and X-rays are not essential for the diagnosis.

Since all patients with OA on FNE and persistent type B tympanogram needed adenoidectomy and grommet insertions, we propose surgery as the primary treatment

# Treatment of primary snoring using a non-ablative Er:YAG laser with SMOOTH mode (NightLase): a randomized controlled trial

**Valerie Picavet<sup>1</sup>**, Marc Dellian<sup>1</sup>, Alexander Sauter<sup>1</sup>, Katrin Hasselbacher<sup>1</sup>

<sup>1</sup>ENT Moser Gehrking Sauter and Partner, Augsburg, Bavaria, Germany

*Snoring and OSA 1, Building M2 CR2, Sept 28,14.45*

**Background:** For treatment of snoring, lasers traditionally have been used in an ablative way. Recently, a non-ablative Er:YAG laser treatment with SMOOTH mode has been shown promising results in treatment of snoring in adult patients. The aim of this study, was to assess safety and efficacy of this non-invasive treatment in a randomized controlled trial.

**Methodology/Principal:** 40 primary snoring patients (>18y, AHI< 15n/h, BMI < 30) were randomized to receive either 3 sessions NightLase or sham laser treatment. Outcome measures were Snore Outcomes Survey (SOS), Spouse/Bed Partner Survey (SBPS), a visual analogue snoring scale (bed partner) and a visual analogue pain scale.

**Results:** NightLase was well tolerated, no local anesthesia was required (mean VAS pain score in NightLase group was 3,0 +- 1,7). No complications occurred. SOS, SBPS and VAS snoring scores significantly improved in the NightLase group (33,0% +- 14,9 to 64,6% +-13,2) (35,2% +- 17,1 vs 65,1% +-17,9) and (7,9+-2,1 to 4,2 +- 2,8) while no changing in the sham group (32,2% +-14,5 to 31,2% +- 13,0) (39,0% +-13,1 vs 41,5%+-18,1) (8,1+-1,7 vs 8,0 +-1,6) respectively (p<0.001).

**Conclusions :** NightLase is a safe, minimal invasive treatment that significantly reduced snoring compared to sham treatment.

**Key words:** snoring, OSA, NightLase, laser, SMOOTH-mode

## Literature:

1. Shiffman HS, Khorsandi J, Cauwels NM. 2021. Minimally-Invasive Combined Nd:YAG and Er:YAG Laser-Assisted Uvulopalatoplasty for Treatment of Obstructive Sleep Apnea. Photobiomodul Photomed Laser Surg. A head of print Feb 25.
2. Frelich, H. et al., 2019. Minimally invasive erbium laser treatment for selected snorers. Lasers in medical science, 34(7), pp.1413–1420.
3. Fini Storchi, I. et al., 2018. Outpatient erbium:YAG (2940 nm) laser treatment for snoring: a prospective study on 40 patients. Lasers in medical science, 33(2), pp.399–406.
4. Lee, C.Y.S. & Lee, C.C.Y.,2015 Evaluation of a non-ablative Er: YAG laser procedure to increase the oropharyngeal airway volume: A pilot study. Dental, Oral and Craniofacial Research, 1(3), pp.56–59.

RETROSELLAR RECESS: CLIVUS EROSION INDUCED BY ALLERGIC FUNGAL SINUSITIS.

Bassam Alzuraiqi, Amr Arghus, Omar Abu suliman, Faris Alghmadi, Osamah Marglani

*Rhinology – miscellaneous 3, Building M1 Room 21, Sept 27, 11.45*

**Introduction:** Allergic fungal sinusitis is a benign, non-invasive inflammation caused by an allergic reaction in the nasal and paranasal mucosa mainly to aerosolized fungal allergens. The expansion of the fungal mucin inside the sinus cavity induced pressure effect erosion on the sinus and skull base bony wall. Bone erosion is not uncommon complication of the AFS.

**Case Report:** Here, we report AFRS patient with anterior cranial fossa erosion and retrosellar recess formation due to clivus erosion. A 19-year-old female with history of headache, nasal obstruction and anosmia was referred to our institution. Imaging showed hyperdense featureless tissue with signs of cribiform lamina and clivus erosions. Massive amounts of thick and grayish mucin material were evacuated during surgery. AFRS could usually be managed endoscopically. Appropriate medical management of the AFRS should be administered in order to prevent relapses.

**Conclusion:** Retrosellar recess is a rare clival erosion induced by allergic fungal sinusitis and sparing the thin bone of the sella.

A clinical case highlighting the utility of a new type of inflation device that provides pressure over the reconstructed area at the roof of the sphenoid sinus and support to the reconstruction.

**Peter M. Baptista<sup>1</sup>**

<sup>1</sup>ENT Department, Clinica Universidad de Navarra, Pamplona, Spain

*CSF leaks and management 1, Building M1 Room Σ2, Sept 27,10.15*

**Background:** A 63-year-old was diagnosed with a sphenoid CSF fistula. Repair was recommended. We assessed the utility of a new type of inflation device to support the reconstruction.

**Methodology/Principal:** A bilateral endoscopic transsphenoidal transnasal approach was performed. A pedunculated lesion adhering to the roof of the sphenoid sinus was identified, removed and hemostasis was performed. A sheet of resorbable material (DuraGen<sup>®</sup>) was inserted between the dura and brain tissue, and two sheets of nasal cartilage were inserted between the dura and bone. These were held in place with a sealant (Adherus), placed on a mucosa graft from the middle turbinate. This was fixed with fibrillar Surgicel and an asymmetric balloon (CAVI-T; dianosic, Strasbourg, France).

**Results:** The postoperative period was uneventful. A brain CT-scan was performed 24 hours after surgery, in which the correct placement of the balloon was verified, compressing the reconstructed region. It was removed 4 days postoperative. The patient shows no evidence of a CSF leak one month after the surgery.

**Conclusions:** This case report demonstrates the utility of a new type of asymmetrical inflation device that provides gentle pressure over the reconstructed area at the roof of the sphenoid sinus and support to the reconstruction.

**Key words:** CSF leak, skull base, sphenoid sinus



## Frontal Sinus Stenting in revision endoscopic sinus surgery using a novel stent: a case series and literature review.

Fabrizio Bandino<sup>1</sup>, **James E H M. Bates<sup>1</sup>**, Ali A S. Qureishi<sup>1</sup>, Pablo Martinez-Devesa<sup>1</sup>

<sup>1</sup>ENT Department, Oxford University Hospitals, Oxford, UK

*CRS - surgical management 2, Building M2 CR3, Sept 27,10.15*

**Background:** Recurrent frontal sinusitis following endoscopic sinus surgery is a challenge for rhinologists. Frontal sinus outflow is disposed to stenosis, leading to obstruction and recurrent disease. The use of frontal sinus stents is well described and are used to prevent adhesions and stenosis. The aetiology of chronic frontal sinusitis being hypothesized to be due to the frontal sinus recess characteristics rather than the frontal sinus itself. Hence frontal sinus stents aim to maintain the frontal recess caliber and reduce the restenosis rate.

**Methodology/Principal:** We present the results of a retrospective case series of nineteen patients undergoing frontal sinus stenting during primary versus revision endoscopic sinus surgery using a novel stent (Montgomery T-Tube tracheal stent).

**Results:** All nineteen patients had Montgomery T-tube tracheal stents inserted following frontal sinus surgery, specific surgical procedures including Draf I 15.7%, Draf IIa 10.5%, Draf IIb 5.26%, Draf III 68.4%.

Follow-up duration mean 20.6 months, length of stent placement mean 9.8 months and seventeen of the patients underwent revision FESS (mean number of operations 2.1, range 1-5). Patency of stent at last endoscopic assessment 78.95%.

**Conclusions:** Frontal sinus stenting with the novel use of Montgomery T-tube tracheal stents can be useful in selected patients to maintain frontal sinus patency.

**Key words:** Revision FESS, frontal sinus, stenting

## **ePosters**

## Recurrence of nasal polyps after endoscopic sinus surgery: evaluation of rate and associated risk factors.

**Nada A. Alshaikh**<sup>1</sup>, Yasmin Khali<sup>1</sup>, Fatma Albati<sup>1</sup>, Zainab Alawami<sup>1</sup>, Huda Bubshait<sup>1</sup>

<sup>1</sup>*Department of Otolaryngology Head and Neck Surgery, Dammam Medical Complex, KSA*

Poster Session, 26 Sept – 30 Sept, 2021, All day

**Aim:** Chronic rhinosinusitis constitutes one of the commonest conditions encountered in medical practice. Approximately 20% of cases of chronic rhinosinusitis are associated with nasal polyps. The aim of this study is to identify the recurrence rate of nasal polyposis after endoscopic sinus surgery and to evaluate the associated risk factors.

**Methods:** A prospective study of a retrospective data was conducted over a period of 4-years at the otolaryngology department of Dammam Medical Complex in Saudi Arabia. The records of patients who underwent endoscopic sinus surgery during the study period were reviewed. Statistical analysis was performed using PAWS version 18. The study was approved by the local scientific committee.

**Results:** 150 patients underwent endoscopic sinus surgery (ESS) during the study period. Only 108 cases (66 males and 42 females) met our inclusion/exclusion criteria. Mean age is  $35 \pm 13.8$  years. The most common presenting symptom was nasal obstruction (95 patients, 87.9%). Sixty-two-patients (57.4%) had concurrent allergic rhinitis, 46 (42.6%) were asthmatics, and 57 patients (52.7%) had deviation of the nasal septum. Recurrence of nasal polyps was observed in 48 patients (44.4%) and was significantly associated with the extent of disease based on CT scan scores ( $p= 0.002$ ). Presence of anatomic variations and concurrent medical conditions do not seem to be associated with increased risk for recurrence.

**Conclusion:** Recurrence rate of nasal polyposis is high and significantly associated with initial extent of disease. Further researches are required in order to study association between recurrence and other factors such as presence of allergic rhinitis and/or bronchial asthma, anatomic variations, and extent of surgery.

## Evaluation of the accuracy of acoustic rhinometry and symptoms score to detect allergic reactivity in nasal allergen challenge

**Ibon Eguiluz-Gracia<sup>1</sup>**, Almudena Testera<sup>1</sup>, María Salas<sup>1</sup>, Francisca Gómez<sup>1</sup>, Ana Prieto del Prado<sup>2</sup>, María Auxiliadora Guerrero<sup>1</sup>, Carmen Rondón<sup>1</sup>

<sup>1</sup>Allergy Department. IBIMA-Hospital Regional Universitario de Málaga-ARADyAL. Málaga, Spain; <sup>2</sup>Pediatric Allergy Department. Hospital Regional Universitario de Málaga. Málaga, Spain.

Poster Session, 26 Sept – 30 Sept, 2021, All day

**Background:** Nasal allergen challenge (NAC) is the gold standard for the diagnosis of allergic rhinitis (AR). We aim to identify optimal cut-off points for acoustic rhinometry (AcRh) and nasal-ocular symptom score (NOSS) to determine positivity in the NAC.

**Methodology/Principal:** Bilateral NAC were performed in 1165 AR, 361 healthy controls (HC) and 369 non-allergic rhinitis (NAR) individuals. NAC was monitored by both objective (change in volume 2-6cm (%Vol2-6cm) of AcRh) and subjective (changes in NOSS) parameters. Receiver operating characteristic (ROC) curves were constructed to identify optimal cut-off points and to calculate the area under the curves (AUC) the sensitivity, and the specificity. Positive and negative predictive values (PPV and NPV) and Likelihood ratios (LH+ and LH-) were also investigated.

**Results:** The optimal cut-off points for AR/HC discrimination were %Vol2-6cm $\geq$ 24.48% and NOSS $\geq$ 3.5 (AUC 1/0.944, p<0.001/p<0.001; sensitivity 99.7/67.1%, specificity 100%/99.4%, PPV 100%/100%, NPV 98.9%/47%, LH+ -/234.882, LH- 0/0.35, respectively). The optimal cut-off points for AR/NAR discrimination were %Vol2-6cm $\geq$ 24.40 and NOSS $\geq$ 4.5 (AUC 1/0.880, P<0.001/P<0.001; sensitivity 99.7%/65.1%, specificity 100%/91.6%, PPV 100%/96.1%, NPV 99.2%/45.4%, LH+ -/7.745, LH- 0/0.38 respectively). The combination of %Vol2-6cm and NOSS did not improve the diagnostic accuracy.

**Conclusions:** Vol2-6cm (AcRh) is a more sensitive and specific parameter than NOSS to evaluate NAC outcome in AR/NAR/HC subjects. In rhinitis patients, the most accurate cut-off point for NAC positivity was a reduction $\geq$ 24.40% in Vol 2-6cm after the challenge.

Key words: allergic rhinitis, nasal allergen challenge, acoustic rhinometry, symptoms score, cut-off point

201037

Balloon Sinuplasty: a case control study with 2-year follow-up assessing safety and efficacy of the new technique utilising SNOT-22 questionnaire.

**Joseph D Sinnott**<sup>1</sup>, Edward Chisholm<sup>2</sup>

<sup>1</sup>Royal United Hospitals, Bath, United Kingdom; <sup>2</sup>Musgrove Park Hospital, Taunton, United Kingdom

Poster Session, 26 Sept – 30 Sept, 2021, All day

**Background:** Balloon sinuplasty is a relatively new surgical technology proposed as a less invasive way of treating CRS and frontal sinus disease. It is crucial to monitor safety and efficacy to allow informed clinical decisions and appropriate counselling of patients. There are few papers with long term follow-up.

**Methodology/Principal:** patients were selected for surgery based on symptoms, pre-operative SNOT-22 scores and CT findings. All were resistant to maximum medical therapy. Balloon sinuplasty was performed followed by a SNOT-22 questionnaire at 2 months and then 2 years.

**Results:** All patients listed for surgery underwent successfully operations with no failure of the technology or technique. There were no significant complications. The average SNOT-22 score went from 46 (+/-17 SD N=9) preoperatively to 23 (+/- 20 SD N=7) at two months. At two years the average SNOT score was 22 (+/- 14 SD N=6).

**Conclusions:** There were no significant complications and no operative failures adding to the evidence of technique safety and feasibility. Efficacy was not universal but on average improved symptoms with a lasting effect. Although this is a small study the evidence adds to the current literature and the long follow-up adds new evidence.

Key words: Balloon, Sinuplasty, Frontal, CRS, Technology

201038

Histological and physiological outcomes of FDG-PET avid incidental findings within the nasopharynx. What are the chances of a malignant underlying cause?

**Joseph D. Sinnott**<sup>1</sup>, Jessica Ball<sup>2</sup>, Christopher Burgess<sup>2</sup>

<sup>1</sup>Royal United Hospitals, Bath, United Kingdom, <sup>2</sup>Musgrove Park Hospital, Taunton, United Kingdom

Poster Session, 26 Sept – 30 Sept, 2021, All day

**Background:** FDG-PET scanning is becoming increasingly common and there has been a correlated increase in incidental findings within the nasopharynx and oropharynx. The likelihood of a malignant underlying cause is unknown. This series looks at the histology and follow-up results of investigations into these incidental findings.

**Methodology/Principal:** Patients referred to the head and neck MDT for an incidental PET lesion. Results of subsequent investigations were collected and compared to the initial PET characteristics.

**Results:** A total of 31 incidental PET findings were referred over a 2-year period. There were 11 different indications for the initial PET scan. SUV max ranged from 4.3 to 17.2. There were 25 patients who had further investigation: 12 had at least additional imaging. Biopsy under general anaesthetic was undertaken in 17 patients. All clinical follow-ups, additional imaging and histology results showed no evidence of malignancies.

**Conclusions:** It is normal to have some PET avidity within the nasopharynx. As more evidence emerges, there is likely to be clear guidance in the future. This project adds to that evidence. We can now counsel patients more accurately on the likely outcomes of investigations for PET avid nasopharyngeal incidental lesions.

Key words: FDG-PET. Incidentaloma. Nasopharynx. Histology. Imaging.

## The usefulness of artificial nose in children measuring with acoustic rhinometry

**Motofumi Ohki**<sup>1</sup>, Kentaro Ohashi<sup>1,2</sup>, Tomomitsu Nasuno<sup>1</sup>, Akihiro Hatano<sup>2</sup><sup>1</sup>Dept. of Otorhinolaryngology, Kitasato University Medical Center, <sup>2</sup>Dept. of Otorhinolaryngology, Kitasato University School of Medicine

Poster Session, 26 Sept – 30 Sept, 2021, All day

**Background:** Objective assessment of nasal patency is important for nasal disease. Consensus report about evaluation of nasal obstruction with acoustic rhinometry was produced by International Standardization Committee on Objective Assessment of the Nasal Airway (ISCOANA). This report recommended using artificial nose before measurement as a standard in adults. Acoustic rhinometer for children has been also manufactured. Then, we tried to produce children's artificial nose and discussed its clinical usefulness.

**Methodology/Principal:** The artificial nose was made from average of area-distance curve in 4-10 years' normal children. Thirty-one children with complaining of nasal obstruction were measured with acoustic rhinometry and compared with the standard curve of artificial nose. The children were divided to mild, moderate, and severe group of nasal disease with symptom score.

**Results:** The area-distance curve in mild group was wider than it of artificial nose. On the other hand, the curve in moderate group was narrower than it of artificial nose. This result suggests that the display of standard curve of artificial nose is easy to diagnose nasal obstruction and will be decided proper treatment.

**Conclusions:** The artificial nose of children is useful to measure acoustic rhinometry and the international standard curve will be need in the future.

Key words: Nasal obstruction, Artificial nose, Acoustic rhinometry, Children

**S.Sanyal<sup>1</sup>**, R.Raychowdhury<sup>1</sup><sup>1</sup>*Department of ENT & Head-Neck Surgery, Vivekananda Institute of Medical Sciences, Kolkata, West Bengal, India.*

Poster Session, 26 Sept – 30 Sept, 2021, All day

**Background:** The craniofacial approach was first described by Smith and his colleagues in 1954 for disease clearance from the frontal sinus and adjacent areas. Survival rates for ethmoid adenocarcinoma treated by craniofacial resection have not improved significantly over the last 25 years.

A less extensive alternative to craniofacial resection was described by Knekt et al. They reported greater success, both in terms of clinical outcome and survival data, with a less aggressive surgical approach, coupled with repeated topical application of 5 fluorouracil (5FU).

Inverted papilloma is treated primarily by surgery, with a recurrence rate ranging from 17-50%. Use of topical 5-FU as an adjunct to surgery has been reported to reduce the recurrence rate to under 6%.

**Methodology/Principal:** We describe our experience of surgical debridement and adjuvant topical 5FU in four cases of sino-nasal neoplasia (inverted papilloma, adenocarcinoma, squamous cell, and undifferentiated carcinoma).

**Results:** Patients with adenocarcinoma and inverted papilloma responded well to our treatment protocol.

**Conclusions:** Surgical debridement with adjuvant topical 5 FU appears to be a useful alternative to ablative surgery in selected cases of sino-nasal neoplasia.

Key words: Inverted Papilloma, 5 fluorouracil, adenocarcinoma, squamous cell carcinoma

#### Literature

1. Choussy O, Ferron Ch, Ve'drine PO, et al. Adenocarcinoma of ethmoid: a GETTEC retrospective multicenter study of 418 cases. *Laryngoscope*. 2008;118:437–43.
2. MacBeth RG. Malignant disease of the paranasal sinuses. *Journal of Laryngology and Otolaryngology*. 1965;79:592-612.
3. Acheson E.D., Hadfield E.H. & Macbeth R.G. (1967) Carcinoma of the nasal cavity and accessory sinuses in woodworkers. *Lancet* 7485, 311–312
4. Smith R., Kloop C. & Williams J. (1954) Surgical treatment of cancer of the frontal sinus and adjacent areas. *Cancer* 7, 991–994
5. Howard D., Lund V. & Wei W. (2006) Craniofacial resection for tumours of the nasal cavity and paranasal sinuses: a 25-year experience. *Head Neck* 28, 867–873.
6. McCutcheon I., Blacklock J., Weber R. et al. (1996) Anterior transcranial (craniofacial) resection of tumours of the paranasal sinuses: surgical techniques and results. *Neurosurgery* 38, 471–479
7. Knekt P., de Jong P., van Andel J. et al. (1985) Carcinoma of the paranasal sinuses: results of a prospective pilot study. *Cancer* 56, 57–62
8. Knekt P., Ah-See K., vd Velden L. et al. (2001) Adenocarcinoma of the ethmoid sinus complex: surgical debulking and topical fluorouracil may be the optimal treatment. *Arch. Otolaryngol. Head Neck Surg.* 127, 141–146
9. Sato Y., Morita M., Takahashi H. et al. (1970) Combined surgery, radiotherapy and regional chemotherapy in carcinoma of the paranasal sinuses. *Cancer* 25, 571–579
10. Almeyda R, Capper J. Is surgical debridement and topical 5 fluorouracil the optimum



treatment for woodworkers' adenocarcinoma of the ethmoid sinuses? A case-controlled study of a 20-year experience. *Clinical otolaryngology*. 2008; 33(5):435-41

11. Singh N, Wong E, Huang J, et al Trans-Frontal Five-Fluorouracil (TraFFF): a novel technique for the application of adjuvant topical chemotherapeutic agents in sinonasal adenocarcinoma. *Case Reports* 2018;2018:bcr-2018-226234.

12. Longley, D. B., Harkin, D. P., & Johnston, P. G. (2003). 5-Fluorouracil: mechanisms of action and clinical strategies. *Nature Reviews Cancer*, 3(5), 330–338

13. Bossi, P., Perrone, F., Miceli, R., Cantù, G., Mariani, L., Orlandi, E., Pilotti, S. (2013). Tp53 status as guide for the management of ethmoid sinus intestinal-type adenocarcinoma. *Oral Oncology*, 49(5), 413–419.

14. Adriaensen GF, Lim KH, Georgalas C, Reinartz SM, Fokkens WJ. Challenges in the management of inverted papilloma: a review of 72 revision cases. *The Laryngoscope*. 2016 Feb;126(2):322-8.

15. Lund VJ, Stammberger H, Nicolai P, et al. European position paper on endoscopic management of tumours of the nose, paranasal sinuses and skull base. *Rhinol Suppl* 2010:1–143.

16. Lee TJ, Huang SF, Lee LA, Huang CC. Endoscopic surgery for recurrent inverted papilloma. *Laryngoscope* 2004;114:106–112.

**S.Sanyal<sup>1</sup>**, R.Raychowdhury<sup>1</sup><sup>1</sup>*Department of ENT & Head-Neck Surgery, Vivekananda Institute of Medical Sciences, Kolkata, West Bengal, India.*

Poster Session, 26 Sept – 30 Sept, 2021, All day

**Background:** The Caldwell Luc procedure was described independently by George Caldwell of United States and Henri Luc of France in the year 1893 and 1897 respectively. This procedure allowed radical removal of antral pathology.

With the advent of Computerized Tomography (CT) scans and nasal endoscopy, Endoscopic sinus surgery (ESS) has become the standard of care for chronic sinus disease, and selected neoplasms. Even with angled endoscopes it is difficult to visualize the entire maxillary sinus: failure to do so leads to incomplete disease clearance. Various endoscopic modifications of the Caldwell Luc approach have been described to deal with this.

**Methodology/Principal:** This paper describes a series of cases treated by our Mini Caldwell Luc procedure; the technique, indications, outcome and follow-up.

**Results:** We have used this technique in 8 patients with various recurrent lesions over the past two years. Complete clearance of disease from the antrum was achieved with minimal morbidity compared to the original open procedure. Post-operative pain and oedema were minimal. No facial numbness has been encountered so far.

**Conclusions:** Our technique provides excellent visualisation of the maxillary cavity without requiring angled endoscopes and allows instrumentation through the same port.

Key words: [Endoscopes](#), [Maxillary Sinus](#), [Neoplasms](#)

#### Literature

1. Macbeth R. Caldwell, Luc, and their operation. *The Laryngoscope*. 1971 Oct;81(10):1652-7.
2. Datta, R.K., Viswanatha, B. & Shree Harsha, M. *Indian J Otolaryngol Head Neck Surg* (2016) 68: 90
3. Seiberling K, Ooi E, MiinYip J, Wormald PJ. Canine fossa trephine for the severely diseased maxillary sinus. *American journal of rhinology & allergy*. 2009 Nov;23(6):615-8.
4. Sathananthar S, Nagaonkar S, Palleri V, Le T, Robinson S, Wormald PJ. Canine fossa puncture and clearance of the maxillary sinus for the severely diseased maxillary sinus. *Laryngoscope* 2005;115(6): 1026-1029
5. Robinson SR, Baird R, Le T, Wormald PJ. The incidence of complications after canine fossa puncture performed during endoscopic sinus surgery. *AmJ Rhinol* 2005;19(2):203-206
6. Bernal-Sprekelsen M, Kalweit H, Welkoborsky HJ. Discomforts after endoscopy of the maxillary sinus via canine fossa. *Rhinology* 1991;29(1):69-75
7. Robinson S, Wormald PJ. Patterns of innervation of the anterior maxilla: a cadaver study with relevance to canine fossa puncture of the maxillary sinus. *Laryngoscope* 2005; 115(10):1785-1788
8. Singhal D, Douglas R, Robinson S, Wormald PJ. The incidence of complications using new landmarks and a modified technique of canine fossa puncture. *AmJ Rhinol* 2007;21(3):316-319
9. Masterson L, Al Gargaz W, Bath AP. Endoscopic Caldwell–Luc technique. *The Journal of Laryngology & Otology*. 2010 Jun;124(6):663-5.
10. V. Anand, S. Santosh, A. Aishwarya. Canine fossa approaches in endoscopic sinus surgery - our experience. *Indian Journal of Otolaryngology and Head & Neck Surgery*, 2008;

201060

## Rhinofacial Entomophthoromycosis; Seven cases in a university hospital.

**Saisawat Chaiyasate**<sup>1</sup>, Parichat Salee<sup>2</sup>, Kornkanok Sukapan<sup>3</sup>, Tanyathorn Teeranoraseth<sup>1</sup>, Kannika Roongrotwattanasiri<sup>1</sup>

<sup>1</sup>Department of Otolaryngology, <sup>2</sup>Department of Internal Medicine, <sup>3</sup>Department of Pathology Faculty of Medicine, Chiang Mai University, Chiang Mai, 50200, Thailand.

Poster Session, 26 Sept – 30 Sept, 2021, All day

**Background:** Rhinofacial entomophthoromycosis is a specific fungal infection of the skin and subcutaneous tissue. It is considered as a rare and neglected disease in tropical and subtropical areas. As people travel around the world, we would like to present our cases to help other physicians in better recognition of the typical cases.

**Methodology/Principal:** A retrospective review was done on patients with the diagnosis of Conidiobolomycosis or Entomophthoromycosis in Chiang Mai University Hospital, Thailand from January 2009 to May 2019. There were seven cases with definite pathologic report or culture in this review.

**Results:** All seven patients were men and were referred to the university hospital for diagnosis and management. The mean age was 53+/- 15.7, ranging from 27-71 years. Most of the patients (85.7%) presented first with nasal or rhinofacial swelling and nasal obstruction. The definite diagnosis came from suspicion of this condition from clinical presentation and investigation with a tissue biopsy, culture and communication among physicians. Patients responded well with a combination of medical treatment: Potassium Iodide (KI), co-trimoxazole, or itraconazole.

**Conclusions:** Rhinofacial entomophthoromycosis or Conidiobolomycosis typically can be diagnosed under a suspicious clinical presentation. The obvious clinical response can be seen within several weeks after medication.

**Key words:** Conidiobolus, Entomophthora, Zygomycosis

## Stimulation of isolated CD4+ and CD8+ T cells with *Aspergillus fumigatus* in patients with chronic rhinosinusitis

**P. Ickrath<sup>1</sup>**, L. Sprügel<sup>1</sup>, N. Beyersdorf<sup>2</sup>, M. Bregenzer<sup>1</sup>, R. Hagen<sup>1</sup>, S. Hackenberg<sup>1</sup>

<sup>1</sup>Department of Oto-Rhino-Laryngology, Plastic, Aesthetic and Reconstructive Head and Neck Surgery, University of Wuerzburg, Germany, <sup>2</sup>Institute for Virology and Immunobiology, University of Wuerzburg, Germany

Poster Session, 26 Sept – 30 Sept, 2021, All day

**Background:** Bacteria and fungi can exhibit superantigens regarding T cell activation. In chronic rhinosinusitis (CRS), local intranasal *Staphylococcus aureus* is known to be the most relevant superantigen. Little is known about the role of *Aspergillus fumigatus*. The aim of the present study was to measure the influence of *A. fumigatus* on the activation of CD4+ and CD8+ T cells in patients with CRS.

**Methodology:** Tissue and blood samples were collected from patients suffering from CRSwNP, CRSsNP and healthy controls undergoing nasal sinus surgery. CD4+ and CD8+ cells were cultured together with antigen presenting cells (APC) and a peptide pool of *A. fumigatus* for 6 days, respectively. Afterwards, lymphocytes were analyzed by multicolor flow cytometry. Activation was assessed by Ki-67 and the cytokine secretion was measured in the supernatant.

**Results:** A significantly higher activation of tissue CD4+ T cells was observed in CRSwNP compared to CRSsNP. No differences were measured between tissue CD8+ T cells of CRSwNP compared to CRSsNP. Only in CRSwNP TH2-cytokine secretion was measured.

**Conclusions:** In this study, a reproducible activation of CD4+ T cells by *A. fumigatus* was seen. These data indicate a direct influence of *A. fumigatus* on the maintenance of the inflammatory reaction in this disease.

**Key words:** CRSsNP, CRSwNP, T cell activation, *Aspergillus fumigatus*, TH2-cytokines,

## Anti-Staphylococcal Humoral Immune Response in Patients with Chronic Rhinosinusitis

**Ulrica Thunberg**<sup>1,2</sup>, Svante Hugosson<sup>1,2</sup>, Hans Fredlund<sup>2,3</sup>, Yang Cao<sup>4,5</sup>, Ralf Ehricht<sup>6,7,8</sup>, Stefan Monecke<sup>6,7,9</sup>, Elke Müller<sup>6,7</sup>, Susanne Engelmann<sup>10,11</sup>, Bo Söderquist<sup>2,3</sup>

<sup>1</sup>Department of Otorhinolaryngology, Örebro University Hospital, Örebro, Sweden; , <sup>2</sup>Faculty of Medicine and Health, Örebro University, Sweden; , <sup>3</sup>Department of Laboratory Medicine, Clinical Microbiology, Örebro University Hospital, Örebro, Sweden; , <sup>4</sup>Clinical Epidemiology and Biostatistics, School of Medical Sciences, Örebro University, Örebro, Sweden; , <sup>5</sup>Unit of Biostatistics, Institute of Environmental Medicine, Karolinska Institute, Stockholm, Sweden; , <sup>6</sup>Abbott (Alere Technologies GmbH), Jena, Germany; , <sup>7</sup>InfectoGnostics Research Campus, Jena, Germany; , <sup>8</sup>Leibniz Institute of Photonic Technology (IPHT), Jena, Germany ; , <sup>9</sup>Institute for Medical Microbiology and Hygiene, Technical University of Dresden, Dresden, Germany; , <sup>10</sup>Institute for Microbiology, Technical University Braunschweig, Germany, <sup>11</sup>Microbial Proteomics, Helmholtz Center for Infection Research, Braunschweig, Germany

Poster Session, 26 Sept – 30 Sept, 2021, All day

**Background:** Staphylococcus aureus (S. aureus) can behave both as a harmless commensal and as a pathogen. Its significance in the pathogenesis of chronic rhinosinusitis (CRS) is not fully understood. This study aimed to determine serum antibody responses to specific staphylococcal antigens in patients with CRS and healthy controls, and to investigate the correlation between specific antibody response and severity of symptoms.

**Methodology/Principal:** Serum samples from 39 patients with CRS and 56 healthy controls were analyzed using a protein microarray to investigate the antibody response to S. aureus specific antigens, with a focus on immunoglobulin G (IgG) directed toward staphylococcal components accessible to the immune system. Holm-Bonferroni corrections were applied in all analyses. Clinical symptoms were assessed using a scoring system.

**Results:** IgG antibody levels toward staphylococcal TSST-1 and LukF-PV were significantly higher in the CRS patient group compared to healthy controls, and levels of anti-TSST-1 antibodies were significantly higher in the CRS patient group with S. aureus in maxillary sinus than in controls. There were no correlations between the severity of symptoms and levels of serum anti-staphylococcal IgG antibody levels for LukF-PV and TSST-1.

**Conclusions:** TSST-1 and LukF-PV could be interesting markers for future studies of the pathogenesis of CRS.

**Key words:** antibodies, chronic rhinosinusitis, immunoglobulin, G, protein microarray, staphylococcal antigen

201076

Establishing a new algorithm to improve the surgical field visualization during nasal polypsis surgery

G.B. Bebchuk

*Nose and throat disease department, Russian Federal Research Clinical Centre of Otorhinolaryngology, Moscow, Russia*

Poster Session, 26 Sept – 30 Sept, 2021, All day

**Background.** Endoscopic surgery for nasal polypsis is associated with bleeding. The impairment of the surgical field visualization (SFV) could possibly require an application of multiple techniques to achieve the hemostasis. Still there is no recommended algorithm for hemostasis based on grades of SFV, while considering specificity of the disease.

**Methodology.** 60 patients with nasal polypsis met the inclusion criteria. All of them had full-house ESS. SFV was graded by Wormald scale. Two study groups were formed. Group I consisted of 40 patients, in whom saline irrigations (49°C) were used with/without topical addition of xylometazoline (0.1%-10ml). Group II included 20 patients who underwent coagulation of sphenopalatine artery and/or its branches. The efficiency of hemostatic techniques were assessed by Wormald scale.

**Results.** In group I the mean grade of SFV before implementation of the hemostatic technique was  $7,3 \pm 8$ , after -  $4,2 \pm 1,2$  ( $p < 0,05$ ). In group II the mean grade of SFV before coagulation was  $8,2 \pm 0,8$ , after -  $5,2 \pm 0,8$  ( $p < 0,05$ ). The beneficial role of the coagulation is emphasised by the need to use this technique in 33,3% of cases.

**Conclusions.** The proposed stepwise combination of intraoperative hemostatic techniques is recommended as an effective algorithm to improve the SFV.

**Key words:** *endoscopic sinus surgery, surgical field visualization, bleeding, hemostasis, sphenopalatine artery.*

**M.Z. Dzhafarova<sup>1</sup>**<sup>1</sup>*Nose and throat disease department, Russian Federal Research Clinical Centre of Otorhinolaryngology, Moscow, Russia*

Poster Session, 26 Sept – 30 Sept, 2021, All day

**Background.** In most cases decrease of soft palate muscle tone causes snoring and mild/moderate OSA. To solve this problem a soft palate stiffening surgery was introduced. The aim of this study was to improve the surgical treatment of mild and moderate OSA.

**Methodology.** This study included 98 patients with mild and moderate OSA who underwent surgical treatment. Three clinical groups were formed. Group I included 30 patients who underwent Pillar-procedure simultaneously with cold ablation of uvula and posterior arches. Group II consisted of 34 patients, in whom anterior palatoplasty was performed. Group III – 34 patients who underwent anterior palatoplasty alongside with cold ablation of uvula and posterior arches. Polysomnography, drug-induced sleep endoscopy and special questionnaires (visual analogue scale of snoring intensity (VAS), Epworth Sleepiness Scale (ESS)) were used to rule out the most appropriate surgical strategy.

**Results.** Postoperative pain was significantly lower ( $p < 0,01$ ) in the group II. During the follow-up period of 1 year there were a significant reduction of VAS and ESS ( $p < 0,01$ ) in the group III. Apnoe/hypopnoe index decreased significantly ( $p < 0,05$ ) in groups II and III.

**Conclusions.** We recommend anterior palatoplasty with/without cold ablation of uvula and posterior arches as an effective surgical treatment of mild and moderate OSA.

**Key words:** OSA, mild and moderate OSA, anterior palatoplasty, cold ablation.

## Angiomyolipoma originating from the nasal vestibule: a case report

**Aleksandar Perić<sup>1</sup>**, Nenad Baletić<sup>1</sup>, Biserka Vukomanović Đurđević<sup>2</sup>

<sup>1</sup>Department of Otorhinolaryngology, Military Medical Academy Faculty of Medicine, Belgrade, Serbia, <sup>2</sup>Institute for Pathology, Military Medical Academy Faculty of Medicine, Belgrade, Serbia

Poster Session, 26 Sept – 30 Sept, 2021, All day

**Background:** Angiomyolipoma is a hamartomatous vascular benign tumour, usually of kidney origin. Nasal origin is extremely rare and less than 20 cases have been reported in the literature. We present a case of a patient with angiomyolipoma arising from the right nasal vestibule.

**Methodology/Principal:** Case report with short review of the literature.

**Results:** A 68-year-old male presented with spontaneous, recurrent right-sided epistaxis and nasal obstruction for 7 months. Rhinoscopy revealed a round, red and smooth surface lesion in the lateral part of the right nasal vestibule. Computed tomography (CT) scan showed a soft tissue mass in the right nasal vestibule, with dimensions of 15x10 mm, without signs of bone erosion. Except the arterial hypertension, the patient did not have comorbidities. After the surgical excision of a lobulated and partly haemorrhagic round lesion, histopathological analysis showed the presence of well circumscribed mass with admixture of smooth muscle cells, islands of adipose tissue and varying-sized thick-walled blood vessels. Follow-up at six and 12 months showed no evidence of residual and/or recurrent disease.

**Conclusions:** Angiomyolipoma should be considered as a differential diagnosis for unilateral nasal masses, especially those situated in the nasal vestibule.

Key words: Angiomyolipoma; Hamartoma; Nasal Cavity

## Literature

1. Dawlatly EE, Anim JT, El-Hassani AY. Angiomyolipoma of the nasal cavity. J Laryngol Otol 1988; 102: 1156-1158.
2. Aleem MA, Fatima A, Kumudachalam P, Priyadarshini R. Nasal angiomyolipoma: report of two cases of an extremely rare entity. Indian J Pathol Microbiol 2017; 60: 393-395.



## Translation and adaptation of the Swedish version of the Nasal Obstruction Symptom Evaluation (NOSE) scale, a pilot-study.

**Ola Sunnergren**<sup>1,2</sup>, Lovisa Hermansson<sup>1</sup>, Pär Stjärne<sup>3,4</sup>, Anders Broström<sup>5,6</sup>

<sup>1</sup>Department of Otorhinolaryngology, Ryhov County Hospital, Jönköping, Sweden, <sup>2</sup>Department of Clinical and Experimental Medicine, Linköping University, Linköping, Sweden, <sup>3</sup>Department of Otorhinolaryngology, Karolinska University Hospital, Stockholm, Sweden, <sup>4</sup>Department of Clinical Sciences, Intervention and Technology, Division of Otorhinolaryngology, Karolinska Institute, Stockholm, Sweden, <sup>5</sup>Department of Nursing Science, School of Health and Welfare, Jönköping University, Sweden, <sup>6</sup>Department of Clinical Neurophysiology, Linköping University Hospital, Linköping, Sweden.

Poster Session, 26 Sept – 30 Sept, 2021, All day

**Background:** Validated and adapted PROMs are needed for international comparisons of outcome after septoplasty. Therefore, the validated 5- item NOSE scale<sup>1,2</sup> was translated and adapted into Swedish (S-NOSE). The aim of this study was to test the basic functionality of the S-NOSE before a larger formal study was conducted.

**Methodology:** 16 adult patients (11 males) referred to an ENT department due to nasal breathing complaints and 10 adult healthy controls (8 males) completed the S-NOSE at two separate occasions. The 5 items are scored on a Likert-type scale (1-4), the sum x5 generates the score (0-100). No intervention was made between the occasions.

**Results:** The mean S-NOSE score in the patient group was 68 at baseline and 62 at follow-up. The corresponding means in the volunteer group was 4 and 5. The S-NOSE scores at baseline and follow-up are presented in figure 1. The scores on the individual items did not seem to overlap (figure 2) indicating that the items measure different properties of nasal problems.

**Conclusions:** The translated and adapted S-NOSE seems to have good test-retest characteristics and could discriminate between disease and no disease. A formal validation of S-NOSE in a larger population of both genders is underway.

**Key words:** Nasal obstruction, NOSE scale, septoplasty, validation, Swedish language

### Literature

1. Development and validation of the nasal obstruction symptom evaluation (NOSE) scale. Stewart MG, Witsell DL, Smith TL, Weaver EM, Yueh B, Hannley MT Otolaryngol Head Neck Surg 2004;130:157–163.

2. Outcomes after nasal septoplasty: results from the Nasal Obstruction Septoplasty Effectiveness (NOSE) study.

Stewart MG, Smith TL, Weaver EM, Witsell DL, Yueh B, Hannley MT, Johnson JT. Otolaryngol Head Neck Surg. 2004; 130:283-290.

Figure 1. S-NOSE score at baseline and follow up in patients and controls

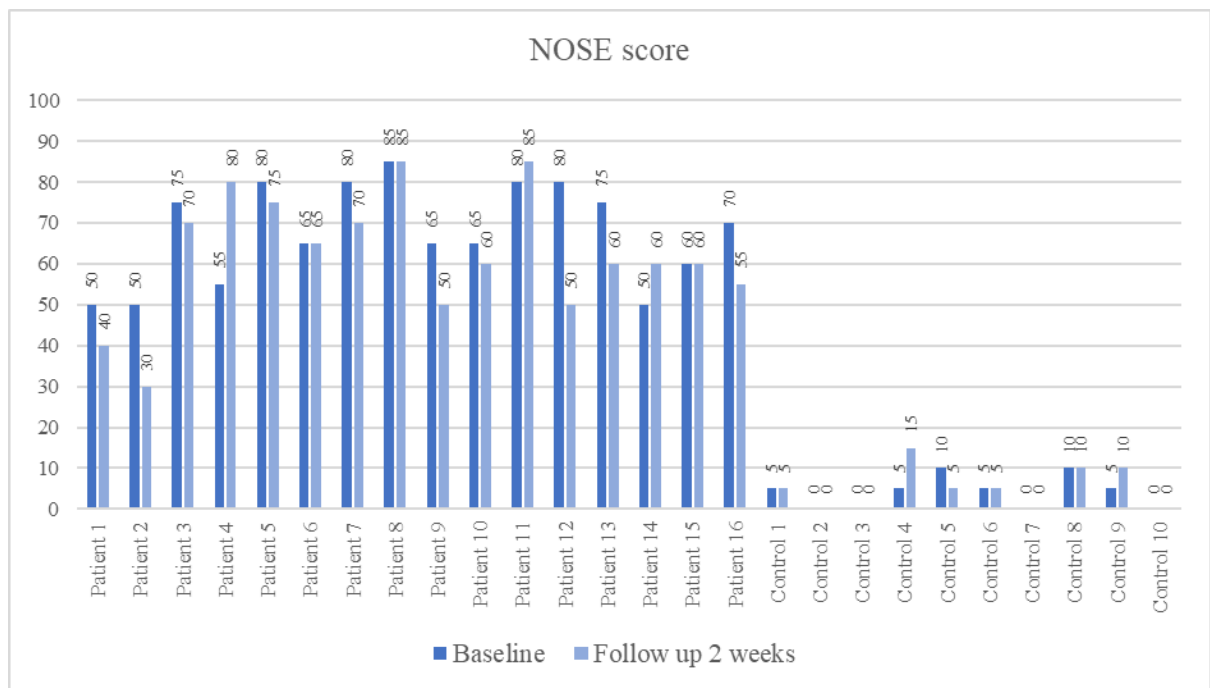
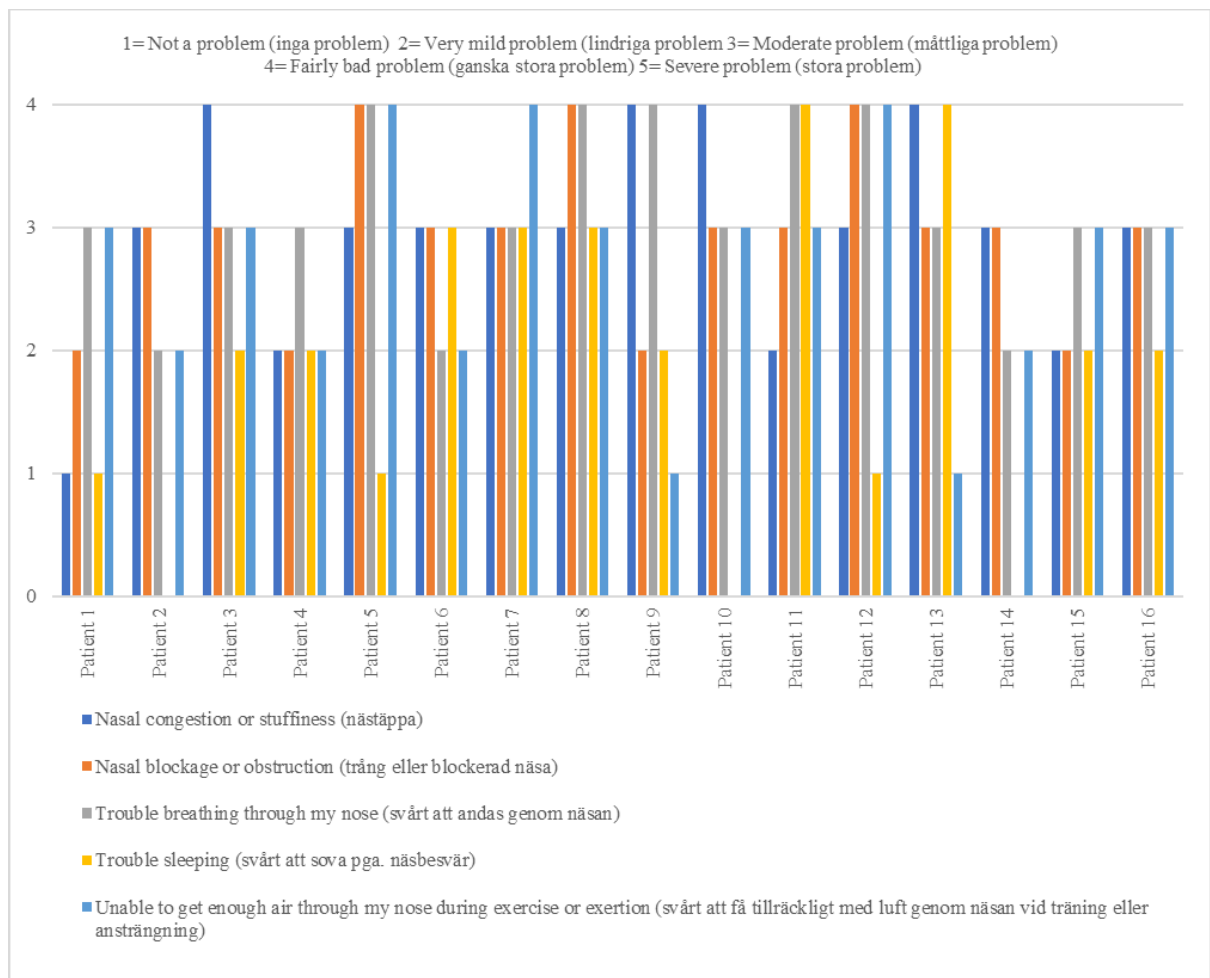


Figure 2. Individual patient score for each S-NOSE item at baseline (Swedish translation in brackets)



201110

## The Polish version of the Nasal Obstruction Symptom Evaluation (NOSE) Scale. Cross-cultural adaptation in a clinical population.

**J. Dąbrowska-Bień**<sup>1</sup>, M. Buksińska<sup>1</sup>, P.H. Skarżyński<sup>2</sup>, H. Skarżyński<sup>1</sup>

<sup>1</sup>Department of Oto-Rhino-Laryngosurgery, World Hearing Center, Institute of Physiology and Pathology of Hearing, Warsaw/Kajetany, Poland, <sup>2</sup> Department of Teleaudiology, World Hearing Center, Institute of Physiology and Pathology of Hearing, Warsaw/Kajetany, Poland, <sup>3</sup> Institute of Sensory Organs, Kajetany, Poland, <sup>4</sup>Heart Failure and Cardiac Rehabilitation Department, Medical Faculty, Medical University of Warsaw, Poland

Poster Session, 26 Sept – 30 Sept, 2021, All day

**Aim:** The Nasal Obstruction Symptom Evaluation (NOSE) Scale is a brief, self-administered questionnaire widely used for assessing quality of life related to nasal obstruction and is utilized in outcome studies. This study aimed to establish psychometric properties of the Polish version of this tool and test it among patients with nasal obstruction.

**Methods:** The controlled validation study was conducted in a tertiary referral center. The Polish version of the NOSE Scale was developed according to the guidelines for cross-cultural adaptation. Psychometric properties (internal consistency, reproducibility, validity, responsiveness and interpretability) were assessed in 51 consecutive patients and 51 controls matched according to gender and age.

**Results:** Internal consistency and reproducibility of The Polish version of the NOSE Scale were good. Construct validity was confirmed by inter-item and item-total correlations. The tool demonstrated adequate criterion validity (assessed by correlation with Visual Analogue Scale) and excellent discriminant validity (between patients and controls), as well as high responsiveness and adequate interpretability.

**Conclusions:** The Polish version of the NOSE Scale is a brief and robust tool very useful in clinical practice. We recommend its use in Polish speaking patients with nasal obstruction.

**Key words:** Nasal Obstruction Symptom Evaluation Scale, NOSE Scale, nasal obstruction

## Complications in septoplasty and septoplasty with turbinate surgery based on a large group of 5639 patients.

**J. Dąbrowska-Bień**<sup>1</sup>, M. Buksińska<sup>1</sup>, P.H. Skarżyński<sup>2</sup>, H. Skarżyński<sup>1</sup>

<sup>1</sup>Department of Oto-Rhino-Laryngosurgery, World Hearing Center, Institute of Physiology and Pathology of Hearing, Warsaw/Kajetany, Poland, <sup>2</sup> Department of Teleaudiology, World Hearing Center, Institute of Physiology and Pathology of Hearing, Warsaw/Kajetany, Poland, <sup>3</sup> Institute of Sensory Organs, Kajetany, Poland  
<sup>4</sup> Heart Failure and Cardiac Rehabilitation Department, Medical Faculty, Medical University of Warsaw, Poland

Poster Session, 26 Sept – 30 Sept, 2021, All day

**Aim:** Septoplasty is a common surgical procedure used for correction of the nasal obstruction caused by a deviated septum. It is often accompanied by inferior turbinate reduction, called turbinoplasty. Complications that may arise from this procedure include excessive bleeding, septal perforation, wound infection, septal abscess, saddle nose deformity, nasal tip asymmetry or depression, sensory changes such as hyposmia, or even ocular or intracranial complications. The aim of the study was to identify complications in septoplasty and analyze incidence depending on the surgical technique, based on material from 2009 till 2017.

**Methods:** Material consisted of 5639 medical records from patients aged 16-69, operated in the tertiary referral center. Patients were divided into 2 groups (2784 exclusively with septoplasty and 2855 with combined septoplasty and turbinoplasty). Z-test for the equality of two proportions was made to investigate the assumption that the proportions from two populations are equal, based on two samples, one from each population.

**Results:** Complications were listed according to international standards. Among the whole study group, different types of complications were noted in 193 patients (3,42%). The most frequent complication was excessive bleeding. Significant differences were observed between the two investigated groups. In patients with combined septoplasty and turbinoplasty septal hematoma, hyposmia, prolonged healing due to infection, adhesions and temporary reduced visual acuity were significantly more often encountered ( $p < 0.01$ ).

**Conclusion:** Meticulous attention to detail in identifying the appropriate anatomy and maintaining good visualization is the key to a safe and effective septoplasty, enabling for very low complications rate.

Key words: septoplasty, turbinate surgery, complications

## Nasal thallium-201 migration to olfactory bulb in rodents with the delayed olfactory nerve excitation

**Hideaki Shiga**<sup>1</sup>, Hiroshi Wakabayashi<sup>2</sup>, Kohshin Washiyama<sup>3</sup>, Tomohiro Noguchi<sup>4</sup>, Tomo Hiromasa<sup>2</sup>, Sadaharu Miyazono<sup>4</sup>, Masami Kumai<sup>1</sup>, Kazuma Ogawa<sup>5</sup>, Junichi Taki<sup>2</sup>, Seigo Kinuya<sup>2</sup>, and Takaki Miwa<sup>1</sup>

<sup>1</sup>Department of Otorhinolaryngology, Kanazawa Medical University, Ishikawa, Japan; <sup>2</sup>Department of Nuclear Medicine, Graduate School of Medical Science, Kanazawa University, Ishikawa, Japan; <sup>3</sup>Fukushima Global Medical Science Center, Fukushima Medical University, Fukushima, Japan; <sup>4</sup>Department of Sensory Physiology, Asahikawa Medical University, Asahikawa, Hokkaido, Japan; <sup>5</sup>Graduate School of Pharmaceutical Sciences, Kanazawa University, Ishikawa, Japan

Poster Session, 26 Sept – 30 Sept, 2021, All day

**Background:** To determine whether thallium-201 migration to the olfactory bulb is affected with olfactory nerve excitation in vivo.

**Methods:** After nasally administering rotenone, we assessed whether a decreased number of dopaminergic interneurons in the olfactory bulb would alter olfactory transport to the olfactory bulb in mice (6-7 per group). In mice, the nasal administration of rotenone decreases the number of dopaminergic interneurons in the olfactory bulb without damage to the olfactory sensory neurons.

**Results:** The migration rate of thallium-201 to the olfactory bulb was significantly increased 3h after the intranasal administration of thallium-201 and rotenone (10µg rotenone,  $p = 0.0012$ ,  $39.8\% \pm 6.1$ ; 20µg rotenone,  $p = 0.0012$ ,  $50.1\% \pm 9.1$ ), compared to the migration rate in the control mice ( $23.5\% \pm 7.2$ ). The numbers of action potentials decreased in olfactory sensory neurons only on the rotenone treated side, suggesting the delayed olfactory nerve excitation after nasal administration of rotenone.

**Conclusions:** The thallium-201 migration to the olfactory bulb increases with the delayed olfactory nerve excitation under reduced inhibitory input from damaged olfactory bulb interneurons in mice, with the intact olfactory sensory neurons. Our results suggests the disconnection of olfactory nerve in patients with decreased interneurons in the olfactory bulb.

**Key words:** olfactory dysfunction, dopaminergic interneuron, tyrosine hydroxylase, action potential, olfactory transport

### Literature

1. Kinoshita, Y., Shiga, H., Washiyama, K., Ogawa, D., Amano, R., Ito, M., Tsukatani, T., Furukawa, M., Miwa, T. Thallium transport and the evaluation of olfactory nerve connectivity between the nasal cavity and olfactory bulb. *Chem. Senses*. 33: 73–78, 2008.
2. Shiga H, Kinoshita Y, Washiyama K, Ogawa D, Amano R, Hirota K, Tsukatani T, Furukawa M, Miwa T. Odor detection ability and thallium-201 transport in the olfactory nerve of traumatic olfactory-impaired mice. *Chem Senses*. 33: 633-637, 2008.
3. Shiga H, Washiyama K, Hirota K, Amano R, Furukawa M, Miwa T. Use of thallium transport to visualize functional olfactory nerve regeneration in vivo. *Rhinology*. 47: 460-464, 2009.
4. Washiyama K, Shiga H, Hirota K, Tsuchida A, Yamamoto J, Yagi S, Yoshizaki T, Furukawa M, Amano R, Miwa T. Biological safety of nasal thallium-201 administration: a preclinical study for olfacto-scintigraphy. *J Radiat Res*. 52: 450-455, 2011.
5. Shiga, H., Taki, J., Yamada, M., Washiyama, K., Amano, R., Matsuura, Y., Matsui, O., Tatsutomi, S., Yagi, S., Tsuchida, A., Yoshizaki, T., Furukawa, M., Kinuya, S., Miwa, T. Evaluation of the olfactory nerve transport function by SPECT-MRI fusion image with nasal thallium-201 administration. *Mol. Imaging. Biol*. 13: 1262–1266, 2011.

6. Shiga, H., Taki, J., Washiyama, K., Yamamoto, J., Kinase, S., Okuda, K., Kinuya, S., Watanabe, N., Tonami, H., Koshida, K., Amano, R., Furukawa, M., Miwa, T. Assessment of olfactory nerve by SPECT-MRI image with nasal thallium-201 administration in patients with olfactory impairments in comparison to healthy volunteers. *PLoS One*. 8: e57671, 2013.
7. Sasajima, H., Miyazono, S., Noguchi, T., Kashiwayanagi, M. Intranasal administration of rotenone in mice attenuated olfactory functions through the lesion of dopaminergic neurons in the olfactory bulb. *Neurotoxicology*. 51: 106–115, 2015.
8. Shiga, H., Taki, J., Okuda, K., Watanabe, N., Tonami, H., Nakagawa, H., Kinuya, S., Miwa, T. Prognostic value of olfactory nerve damage measured with thallium-based olfactory imaging in patients with idiopathic olfactory dysfunction. *Sci. Rep*. 7: 3581, 2017.
9. Shiga H, Okuda K, Taki J, Watanabe N, Tonami H, Kinuya S, Miwa T. Nasal thallium-201 uptake in patients with parosmia with and without hyposmia after upper respiratory tract infection. *Int Forum Allergy Rhinol*. 9:1252-1256, 2019.

201161

## The sphenoid crest flap - a small sized nasoseptal flap to prevent postoperative crusting in endoscopic transsphenoidal pituitary gland surgery

**Kornelia E.C. Andorfer**<sup>1</sup>, Karl-M. Schebesch<sup>2</sup>, Caroline T. Seebauer<sup>1</sup>, Thomas S. Kuehnel<sup>1</sup>

<sup>1</sup>*Ear nose and throat Department, University of Regensburg, Regensburg, Bavaria/ Germany,* <sup>2</sup>*Neurosurgery Department, University of Regensburg, Regensburg, Bavaria/ Germany*

Poster Session, 26 Sept – 30 Sept, 2021, All day

**Background:** In terms of maximum exposure of the sphenoid sinus in pituitary gland surgery, removal of the sphenoidal facies is as necessary as the removal of the sphenoid crest down to the sphenoid rostrum. What remains of it postoperatively is a large bare bone area that tends to shrink and crust.

**Principal:** We present a flap to cover the bare bone area created in the course of transsphenoidal approach. Its pedicle is similar to the classical nasoseptal flap (Hadad-flap), yet the flap only covers the area of septal mucosa that is removed in the course of the reduction of the posterior septum.

**Results:** Covering the bare bone area of the sphenoid rostrum with a pedicled flap prevents postoperative bleeding, crusting and consequently infections.

**Conclusions:** The sphenoid crest flap is a good option to create better postoperative conditions in transsphenoidal approach.

Key words: pituitary, endocrine surgical procedure, transsphenoidal approach, sphenoid crest flap

## Clinical Efficacy of Topical Nasal Pomegranate Fruit Extract for Patients with Chronic Rhinitis and Chronic Sinusitis With or Without Nasal Polyps

**Isaac Shochat<sup>1</sup>**, Dor Maayan<sup>1</sup>, Miri Sarid, Itzhak Braverman<sup>1</sup>.

<sup>1</sup>Otolaryngology Head and Neck Surgery, Hillel Yaffe Medical Center, Technion Faculty of Medicine, Israel.

Poster Session, 26 Sept – 30 Sept, 2021, All day

**Background:** Chronic rhinosinusitis is a common disease, comprises of chronic inflammation of the paranasal-sinuses lining. Pomegranate is a source for bioactive compounds with known antioxidant, antimicrobial and anti-biofilm properties.

**Methodology:** Double-blinded study examining the effect of PFE-based nasal spray in CRSsNP, CRSwNP, and CR. Each group randomly divided into a group treated with PFE twice-a-day, and a group treated with placebo. The patients underwent ENT examination and filled SNOT-20 questionnaire pre-and-post treatment.

**Results:** 111 patients participated. 49 with CRSsNP, of which 24 treated with placebo and 25 with PFE; 35 with CRSwNP, of which 11 treated with placebo and 16 with PFE; and 27 with CR, of which 18 treated with placebo and 17 with PFE. Analysis showed decreased nasal discharge in the CR-group (Mean reduction from 3.43 to 1.75,  $p < .001$  vs. 2.27 to 1.6 among control); Also, significant decrease concerning sadness (from 2 to 1.375,  $p < .02$ ; vs. 0.81 to 0.81 among control), disturbance of sleep (from 2.06 to 1.06,  $p < 0.02$ ; vs. 1.4 to 1.9 among control) and distraction (from 1.29 to 0.41 vs. from 2.18 to 2.27 among control,  $p < 0.007$ ).

**Conclusions:** Topical nasal PFE could have an effect for CR patients.

**Key words:** Chronic Sinusitis, Chronic Rhinitis, Pomegranate Fruit Extract, Non-Allergic Rhinitis, Rhinitis



## Endoscopically derived middle meatal cultures compared to maxillary sinus aspirates in acute bacterial rhinosinusitis

**Jussi Virtanen<sup>1</sup>**, Jura Numminen<sup>1</sup>, Niku Oksala<sup>2</sup>, Antti Roine<sup>3</sup>, Markus Rautiainen<sup>1</sup>, Ilkka Kivekäs<sup>1</sup>

*<sup>1</sup>Department of Otorhinolaryngology, Faculty of Medicine and Life Sciences, Tampere University and Tampere University Hospital, Finland; <sup>2</sup>Centre for Vascular Surgery and Interventional Radiology, Tampere University Hospital, Finland; <sup>3</sup>Department of Surgery, Tampere University Hospital, Hatanpää Hospital, Tampere, Finland*

Poster Session, 26 Sept – 30 Sept, 2021, All day

**Background:** The aim of this study was to compare endoscopically derived middle meatal cultures to cultures acquired by maxillary sinus puncture and aspiration in acute rhinosinusitis patients

**Methodology/Principal:** Adult patients with acute rhinosinusitis symptoms were examined. Middle meatal cultures were taken with cotton-tipped aluminum swab under endoscopic control without use of topical anesthesia. Maxillary sinus puncture was performed through inferior meatus and sinus contents were aspirated for bacterial culture. The culture results were compared and sensitivity, specificity, accuracy, positive and negative predictive values were calculated for middle meatal cultures.

**Results:** Maxillary sinus puncture and aspiration revealed pus in 24 patients' 40 maxillary sinuses. Of those patients, bacterial cultures were positive in 10 (42 %) and negative in 14 (58 %). In per isolate comparison, middle meatal cultures had sensitivity of 79 %, specificity of 88 % and accuracy of 85 %. Positive and negative predictive values were 79 % and 88 %, respectively.

**Conclusions:** Our results are in line with previous works and prove that endoscopically derived middle meatal cultures have high correlation with maxillary sinus aspirate results.

**Key words:** acute rhinosinusitis, middle meatal culture, maxillary sinus aspirate

## In vitro detection of acute rhinosinusitis bacteria by electronic nose

**Jussi Virtanen<sup>1</sup>**, Lauri Hokkinen<sup>2</sup>, Markus Karjalainen<sup>3</sup>, Anton Kontunen<sup>3</sup>, Risto Vuento<sup>4</sup>, Jura Numminen<sup>1</sup>, Markus Rautiainen<sup>1</sup>, Niku Oksala<sup>5</sup>, Antti Roine<sup>6</sup>, Ilkka Kivekäs<sup>1</sup>

<sup>1</sup>Department of Otorhinolaryngology, Faculty of Medicine and Life Sciences, Tampere University and Tampere University Hospital, Finland; <sup>2</sup>Faculty of Medicine and Life Sciences, Tampere University, Finland; <sup>3</sup>Faculty of Medicine and Health Technology, Tampere University, Finland; <sup>4</sup>Department of Microbiology, Fimlab Laboratories Ltd, Tampere, Finland; <sup>5</sup>Centre for Vascular Surgery and Interventional Radiology, Tampere University Hospital, Finland; <sup>6</sup>Department of Surgery, Tampere University Hospital, Hatanpää Hospital, Tampere, Finland

Poster Session, 26 Sept – 30 Sept, 2021, All day

**Background:** Electronic nose has shown the ability to detect diseases from gas mixtures. The aim of this study was to examine whether electronic nose utilising differential mobility spectrometry (DMS) can differentiate acute rhinosinusitis bacteria in vitro.

**Methodology/Principal:** Four the most common acute rhinosinusitis bacteria (*S. pneumoniae*, *H. influenzae*, *M. catarrhalis* and *S. aureus*) were analysed in vitro with DMS. Classification was done using linear discriminant analysis (LDA) and k-nearest neighbour (KNN). The results were validated using separate train and test sets.

**Results:** After validation, 83 % of the bacteria were classified correctly with LDA. The comparative figure with kNN was 85 %.

**Conclusions:** DMS has shown its potential in detecting acute rhinosinusitis bacteria in vitro. The applicability of DMS needs to be studied with rhinosinusitis patients

**Key words:** acute rhinosinusitis, electronic nose, differential mobility spectrometry

#### Literature:

Virtanen J, Hokkinen L, Karjalainen M, Kontunen A, Vuento R, Numminen J, Rautiainen M, Oksala N, Roine A, Kivekäs I. In vitro detection of common rhinosinusitis bacteria by the eNose utilising differential mobility spectrometry. *Eur Arch Otorhinolaryngol.* 2018;275:2273-2279.

201287

## The Use of Polycaprolactone Mesh for Definitive Rhinoplasty on an Adult Female Patient with Cleft Nose: A Case Report Study

**Jacqueline T. Cua-Lim**<sup>1</sup>, Henry J.F. Claravall<sup>2</sup>

*St. Luke's Medical Center Philippines*

Poster Session, 26 Sept – 30 Sept, 2021, All day

**Background:** The use of polycaprolactone mesh for definitive rhinoplasty.

**Methodology/Principal:** A case report study

**Results:** The use of polycaprolactone mesh for definitive rhinoplasty in cleft lip is safe and effective in maintaining the implant volume without postoperative complications such as foreign body reaction. Histopathologic study obtained 6 months post operation using Hematoxylin and Eosin stain shows evidences of neocartilagenous and connective tissue formation with vascularization. These regenerative properties suggest that polycaprolactone mesh is safer and more effective in ensuring long-term stability post rhinoplasty.

**Conclusions:** Cleft lip nasal deformity remains a challenge to surgeons. Correction of cleft nose requires a meticulous treatment plan including the timing of surgery, surgical approach and implant of choice to ensure satisfactory aesthetic and functional results including improved breathing. Current implants used such as cartilage or allografts like silicone-based implants yield different aspects of clinical risks such as foreign-body reaction, extrusion, and total/partial resorption. Therefore, the use of polycaprolactone mesh provides a more biocompatible and more stable alternative for rhinoplasty.

**Key words:** polycaprolactone, cleft nose, rhinoplasty

### Literature

Wiggenhauser, P. S., Balmayor, E. R., Rotter, N., & Schantz, J. T. (2019). *In vivo evaluation of a regenerative approach to nasal dorsum augmentation with a polycaprolactone-based implant. European Journal of Medical Research*, 24(1).

Park, Y. J., Cha, J. H., Bang, S. I., & Kim, S. Y. (2018). *Clinical Application of Three-Dimensionally Printed Biomaterial Polycaprolactone (PCL) in Augmentation Rhinoplasty. Aesthetic Plastic Surgery*.

Loyo, M., & Wang, T. D. (2019). *Definitive Cleft Rhinoplasty for Unilateral Cleft Nasal Deformity. JAMA Facial Plastic Surgery*, 18(2), 144.

## Best treatments available for obstructive acquired lacrimal obstruction: a systematic review and meta-analysis

**Alessandro Vinciguerra MD<sup>1</sup>**, Alessandro Nonis MS<sup>2</sup>, Antonio Giordano Resti MD<sup>3</sup>, Mario Bussi MD<sup>1</sup>, Matteo Trimarchi MD<sup>1</sup>

<sup>1</sup>Otorhinolaryngology – Head & Neck Surgery Department, San Raffaele Hospital, Vita-Salute University, Milano, Italy; <sup>2</sup>CUSSEB, University Centre for Statistics in the Biomedical Sciences, San Raffaele Hospital, Vita-Salute University, Milano, Italy; <sup>3</sup>Ophthalmology Department, San Raffaele Hospital, Vita-Salute University, Milano, Italy.

Poster Session, 26 Sept – 30 Sept, 2021, All day

**Background:** Epiphora is a common clinical sign which primary cause identified in the literature is post-canalicular lacrimal obstruction which treatment present different procedures available, both surgical and non-surgical. In the literature, there are hints that some of these treatments are superior to others, but no directly comparison has ever been performed.

**Methods:** A systematic research was conducted in PubMed, EMBASE, SCOPUS, and Cochrane databases with a final search performed in November 2019. The search strategy identified articles published later than 2000 with at least 50 procedures performed both surgically [external dacryocystorhinostomy (EXT-DCR), endoscopic dacryocystorhinostomy (END-DCR) and trans-canalicular laser dacryocystorhinostomy (TCL-DCR)] and non-surgically [balloon dacryoplasty (DCP), stenting-probing (SP) and polyurethane stent (PoS)]. The primary outcome analysed was the functional success, defined as symptom resolution or less than MUNK 2 scale.

**Results:** In total, 14,958 papers were selected, 440 of which were reviewed after screening, and 55 included after full text review. Mean success rate was 54.5% for DCP, 53.75% for SP, 75.65% for PoS, 77.9% for TCL-DCR, 90.1% for EXT-DCR and 90.6% for END-DCR. Among all procedures, it has been observed a difference between DCP and END-DCR ( $p < .001$ ), DCP and EXT-DCR ( $p < .001$ ), SP and END-DCR ( $p < .001$ ), SP and EXT-DCR ( $p < .001$ ) and END-DCR and TCL-DCR ( $p = 0.04$ ); no differences were noted between END-DCR (90.6%) and EXT-DCR (90.1%).

**Conclusions:** Our analyses suggest that, among all procedures available, END-DCR and EXT-DCR should be considered the treatment of choice to resolve distal acquired lacrimal obstruction.

**Key words:** Systematic reviews, outcomes, Dacryocystorhinostomy, endoscopic sinus surgery and ophthalmology

### Literature

- Woog JJ. The incidence of symptomatic acquired lacrimal outflow obstruction among residents of Olmsted County, Minnesota, 1976-2000 (an American Ophthalmological Society thesis). *Trans Am Ophthalmol Soc.* 2007;105:649-666.
- Sobel RK, Aakalu VK, Wladis EJ, Bilyk JR, Yen MT, Mawn LA. A Comparison of Endonasal Dacryocystorhinostomy and External Dacryocystorhinostomy: A Report by the American Academy of Ophthalmology. *Ophthalmology.* 2019.
- Patella F, Panella S, Zannoni S, et al. The role of interventional radiology in the treatment of epiphora. *Gland Surg.* 2018;7:103-110.
- Huang J, Malek J, Chin D, et al. Systematic review and meta-analysis on outcomes for endoscopic versus external dacryocystorhinostomy. *Orbit.* 2014;33:81-90.

## Role of post-surgical therapy in endoscopic and external dacryocystorhinostomy: systematic review and metanalysis

**Alessandro Vinciguerra**<sup>1,2</sup>, Alessandro Nonis<sup>3</sup>, Antonio Giordano Resti<sup>4</sup>, Mario Bussi<sup>1,2</sup>, Matteo Trimarchi<sup>1,2</sup>

<sup>1</sup>Division of Head and Neck department, Otorhinolaryngology unit, IRCCS San Raffaele Scientific Institute, Milano, Italy; <sup>2</sup>School of Medicine, Vita-Salute San Raffaele University, Milano, Italy; <sup>3</sup>CUSSE, University Centre for Statistics in the Biomedical Sciences, Vita-Salute San Raffaele University, Milano, Italy; <sup>4</sup>Division of Head and Neck department, Ophthalmologic unit, IRCCS San Raffaele Scientific Institute, Milano, Italy.

Poster Session, 26 Sept – 30 Sept, 2021, All day

**Background:** Recent data have demonstrated how external dacryocystorhinostomy (EXT-DCR) and endoscopic endonasal dacryocystorhinostomy (END-DCR) can be considered the treatments of choice for distal acquired lacrimal obstruction (DALO). Additionally, different post-surgical medical treatments are available and currently used in order to increase their surgical outcome, however, at present no directly comparison has ever been performed.

**Methods:** A systematic review has been performed in order to analyse the influence of different post-surgical medical treatment in the outcome of END-DCR and EXT-DCR with a final search performed in January 2020. Particularly it was analysed the influence of systemic antibiotic/steroids, local application of mitomycin C, nasal/ocular antibiotic, nasal/ocular steroids and nasal decongestant.

**Results:** In total, 11.445 papers were selected, 2.741 of which were reviewed after screening, and 17 included after full text review, from which were pooled 3,336 procedures. When considered the post-surgical therapy, given the variable association between adjunctive medical therapies, pharmacologic molecular heterogeneity and modality/concentration of application, the statistical analyses were not feasible

**Conclusions:** The current literature indicates EXT-DCR and END-DCR as the treatment of choice for DALO, however, given the high success rate of these two surgical approaches and the heterogeneity of literature data, the effective influence of post-surgical medical therapy is difficult to identify. Future large prospective randomized studies could help in detecting the correct therapy after such surgeries.

**Key words:** Systematic reviews, outcomes, Dacryocystorhinostomy, endoscopic sinus surgery and ophthalmology

### Literature

- Sobel RK, Aakalu VK, Wladis EJ, Bilyk JR, Yen MT, Mawn LA. A Comparison of Endonasal Dacryocystorhinostomy and External Dacryocystorhinostomy: A Report by the American Academy of Ophthalmology. *Ophthalmology*. 2019.
- Ali MJ, Psaltis AJ, Murphy J, Wormald PJ. Outcomes in primary powered endoscopic dacryocystorhinostomy: comparison between experienced versus less experienced surgeons. *Am J Rhinol Allergy*. 2014;28(6):514-6.
- Ari Ş, Gun R, Surmeli S, Atay AE, Çaca İ. Use of adjunctive mitomycin C in external dacryocystorhinostomy surgery compared with surgery alone in patients with nasolacrimal duct obstruction: A prospective, double-masked, randomized, controlled trial. *Current Therapeutic Research - Clinical and Experimental*. 2009;70(4):267-73.
- Do JR, Lee H, Baek S, Lee TS, Chang M. Efficacy of postoperative mitomycin-C eye drops on the clinical outcome in endoscopic dacryocystorhinostomy. *Graefes Arch Clin Exp Ophthalmol*. 2016;254(4):785-90.

- Shin HY, Paik JS, Yang SW. Clinical Results of Anti-adhesion Adjuvants after Endonasal Dacryocystorhinostomy. *Korean J Ophthalmol*. 2018;32(6):433-7.
- Ta CN, Chang RT, Singh K, Egbert PR, Shriver EM, Blumenkranz MS, et al. Antibiotic resistance patterns of ocular bacterial flora: a prospective study of patients undergoing anterior segment surgery. *Ophthalmology*. 2003;110(10):1946-51.
- Blicher JA, Buffam FV. Lacrimal sac, conjunctival, and nasal culture results in dacryocystorhinostomy patients. *Ophthalmic Plast Reconstr Surg*. 1993;9(1):43-6.
- Hosal BM, Hosal SA, Hurwitz JJ, Freeman JL. A rationale for the selection of nasal decongestants in lacrimal drainage surgery. *Ophthalmic Plast Reconstr Surg*. 1995;11(3):215-20.
- Korkmaz H, Yao WC, Korkmaz M, Bleier BS. Safety and efficacy of concentrated topical epinephrine use in endoscopic endonasal surgery. *Int Forum Allergy Rhinol*. 2015;5(12):1118-23.

# ORBITAL AND SILENT INTRACRANIAL COMPLICATIONS OF ACUTE PANSINUSITIS: A CASE REPORT.

**Spyridon Lygeros**<sup>1</sup>, Stefanos Papaioannou<sup>1</sup>, Gerasimos Danielidis<sup>1</sup>, Nikolaos Mastronikolis<sup>1</sup>, Vasileios Danielidis<sup>1</sup>

<sup>1</sup>ENT Department of University Hospital of Patras, Greece

Poster Session, 26 Sept – 30 Sept, 2021, All day

**Introduction/Background:** Complicated acute sinusitis remains a significant modality despite the widespread use of antibiotics in our era, mostly due to a delay in the diagnosis of the disease.

**Case report/Methodology:** A 20-year-old male with a history of acute pansinusitis presented with subperiosteal abscess in the orbit together with subdural empyema and epidural abscess of the frontal lobe, identified by radiological evaluation. The patient had a 3-weeks history of nasal blockage, headache and facial pain. A periorbital swelling of his left eye was noticed and emerged the patient. The patient's parents had noticed an altered mental status over the last 5 days. FESS was performed to drain the sinuses and the subperiosteal abscess, followed by left frontal craniotomy in order to drain the intracranial abscesses. "Complete" clinical recovery was achieved after 2 months of medical treatment.

**Discussion/Results:** Orbital and intracranial complications of acute sinusitis often develop simultaneously requiring a high degree of suspicion. The indolent course of some intracranial complications makes it always necessary to rule out multiple-site involvement, so that extensive radiological evaluation including both CT and MRI are often advised.

**Conclusions:** Early diagnosis and combined treatment with a multidisciplinary approach among specialists is mandatory to reduce morbidity and mortality.

**Key words:** acute rhinosinusitis, orbital abscess, intracranial abscess

## Literature

1. Bayonne E, Kania R, Tran P, Huy B, Herman P Intracranial complications of rhinosinusitis A review, typical imaging data and algorithm of management *Rhinology*. 2009 Mar;47(1):59-65.
2. Clayman GL, Adams GL, Paugh DR, Koopmann CF Jr. (1991) Intracranial complications of paranasal sinusitis: a combined institutional review *Laryngoscope*. 1991 Mar;101(3):234-9
3. Dolan RW, Chowdhury K. (1995) Diagnosis and treatment of intracranial complications of paranasal sinus infections. *J Oral Maxillofac Surg*. 1995 Sep;53(9):1080-7.
4. Giannoni CM, Stewart MG, Alford EL (1997) Intracranial complications of sinusitis *Laryngoscope*. 1997 Jul;107(7):863-7.
5. Howe L, Jones NS. (2004) Guidelines for the management of periorbital cellulitis/abscess *Clin Otolaryngol Allied Sci*. 2004 Dec;29(6):725-8.
6. Herrmann BW, Forsen JW Jr. (2014) Simultaneous intracranial and orbital complications of acute rhinosinusitis in children. *Int J Pediatr Otorhinolaryngol*. 2004 May;68(5):619-25.
7. Jones NS, Walker JL, Bassi S, Jones T, Punt J. (2002) The intracranial complications of rhinosinusitis: can they be prevented? *Laryngoscope*. 2002 Jan;112(1):59-63.
8. Kayhan FT, Sayin I, Yazici ZM, Erdur O. (2010) Management of orbital subperiosteal abscess *J Craniofac Surg*. 2010 Jul;21(4):1114-7
9. Ketenci I, Unlü Y, Vural A, Doğan H, Sahin MI, Tuncer E (2012) Approaches to subperiosteal orbital abscesses *Eur Arch Otorhinolaryngol*. 2013 Mar;270(4):1317-27

10. Matthew T. Niehaus, DO, Kyli N. Krape, DO, Shawn M. Quinn, DO, and Bryan G. Kane, MD (2018) Frontal sinusitis complicated by a brain abscess and subdural empyema Radiol Case Rep. 2018 Apr; 13(2): 456–459.
11. Osborn MK, Steinberg JP (2007) Subdural empyema and other suppurative complications of paranasal sinusitis Lancet Infect Dis. 2007 Jan;7(1):62-7
12. Sobol SE, Marchand J, Tewfik TL, Manoukian JJ, Schloss MD (2002) Orbital complications of sinusitis in children. J Otolaryngol. 2002 Jun;31(3):131-6.
13. Witold Szyfter, Anna Bartochowska, Łukasz Borucki, Adrian Maciejewski, Aleksandra Kruk-Zagajewska (2018) Simultaneous treatment of intracranial complications of paranasal sinusitis Eur Arch Otorhinolaryngol. 2018; 275(5): 1165–1173



201393

## An update on the endoscopic endonasal approach to orbital and orbital apex lesions: a series of 97 patients

Joel Franco<sup>1</sup>, Nathan Zwagerman<sup>2</sup>, Carl H. Snyderman<sup>1</sup>, Paul A. Gardner<sup>2</sup>, S. Tonya Stefko<sup>3</sup>, **Eric W. Wang<sup>1</sup>**

<sup>1</sup>Departments of Otolaryngology, <sup>2</sup>Neurological Surgery and Ophthalmology, <sup>3</sup>University of Pittsburgh School of Medicine, Pittsburgh, Pennsylvania, USA

Poster Session, 26 Sept – 30 Sept, 2021, All day

**Background:** Traditional approaches to the orbit include transcranial and anterior orbitotomies. Endonasal endoscopic approach (EEA) has been increasingly employed for lesions to the inferior and medial orbit and orbital apex.

**Methodology/Principal:** A retrospective review was conducted of patients who underwent EEA for orbital pathology from 2002 to 2019 separating extraorbital (EO), intraorbital extraconal (IE), and intraorbital intraconal (II) pathology. The primary outcome measures were vision and complications.

**Results:** In the 101 patients, vision change was the most common symptom (64.9%). Meningioma was the most common pathology (33.7%). Of the 38 EO lesions, all patients had stable (73.7%) or improved vision (26.3%). Of the 29 IE, 27 patients had stable (48.3%) or improved vision (44.8%). Two patients (6.9%) suffered new deficits; one abducens palsy and 1 partial ptosis. Of the 34 II lesions, 30 patients had stable (47.1%) or improved vision (41.2%). Two orbital hematomas with worsening vision and 1 medial rectus palsy with slow improvement occurred. One patient (2.9%) had delayed worsening vision 2 years after surgery without recurrence.

**Conclusions:** The EEA is a safe and effective option for the treatment of select orbital and orbital apex lesions. Vision is improved or stable in the majority with increasing orbital complications in the intraorbital cohort.

**Key words:** EEA, orbit, vision, complications

## Sinonasal outcomes after pituitary surgery in patients with Cushing's disease

Nadeem R. Kolia, Paul A. Gardner<sup>2</sup>, Carl H. Snyderman<sup>1</sup>, **Eric W. Wang<sup>1</sup>**<sup>1</sup>*Departments of Otolaryngology and Neurological Surgery, <sup>2</sup>University of Pittsburgh School of Medicine, Pittsburgh, Pennsylvania, USA*

Poster Session, 26 Sept – 30 Sept, 2021, All day

**Background:** Endoscopic endonasal skull base surgery (ESBS) is a common intervention for pituitary tumors with minimal sinonasal morbidity. Cushing's disease may represent a subgroup with persistent sinonasal dysfunction.

**Methodology/Principal:** A retrospective case-match study was conducted comparing patients with Cushing's disease and non-functional pituitary adenoma who had undergone ESBS from 2016 to 2019. The primary outcome was the 22-item Sino-Nasal Outcome Test (SNOT-22) scores collected at 1, 3, and 6 months post-operatively. Statistical analysis utilized a two-tailed t-tests with p values < 0.05 were considered significant.

**Results:** Ten patients with Cushing's disease were compared with 17 controls. There was no difference in post-operative SNOT-22 score at 1 month (30.8 vs. 25.9, p = 0.71) and at 3 months (26.4 vs. 17.7, p = 0.21). At 6 months, SNOT-22 scores were significantly higher in Cushing's cohort (28.8 vs. 3.0, p = 0.04). While SNOT-22 scores improved in the control group (p < 0.01), the scores were not significantly different at 1 and 6 months in the Cushing's cohort (p = 0.71).

**Conclusions:** Patients with and without Cushing's disease have similar initial post-operative SNOT-22 scores after ESBS. Control patients return to baseline SNOT-22 scores after 6 months while Cushing's patients do not improve over time.

**Key words:** Endoscopic Endonasal, Outcomes, Cushing's disease, Pituitary

## 3D printing of the nasal cavities for clinical experiments

**Olli Valtonen**<sup>1,2</sup>, Jaakko Ormiskangas<sup>2</sup>, Ilkka Kivekäs<sup>1,2</sup>, Ville Rantanen<sup>2</sup>, Marc Dean<sup>3,4</sup>, Dennis Poe<sup>5</sup>, Jorma Järnstedt<sup>6</sup>, Jukka Leikkala<sup>2</sup>, Pentti Saarenrinne<sup>7</sup>, Markus Rautiainen<sup>1,2</sup>

<sup>1</sup>Department of Otorhinolaryngology – Head and Neck Surgery, Tampere University Hospital, Tampere, Finland, <sup>2</sup>Faculty of Medicine and Health Technology, Tampere University, Tampere, Finland, <sup>3</sup>Texas Tech University Health Sciences Center, Lubbock, Texas, U.S.A., <sup>4</sup>Ear & Sinus Institute, Fort Worth, Texas, U.S.A., <sup>5</sup>Boston Children's Hospital, Department of Otolaryngology, Boston, Massachusetts, U.S.A., <sup>6</sup>Medical Imaging Centre, Department of Radiology, Tampere University Hospital, Tampere, Finland, <sup>7</sup>Faculty of Engineering and Natural Sciences, Tampere University, Tampere, Finland

Poster Session, 26 Sept – 30 Sept, 2021, All day

**Background:** 3D printing has produced many beneficial applications for surgery. The technique's applicability in replicating nasal cavity anatomy for clinical use has not been studied. Our aim was to determine whether 3D printing could realistically replicate the nasal cavities and the airflow passing through them from a clinical point of view.

**Methodology:** We included Cone Beam Computed Tomography (CBCT) scans of five patients with symptoms of chronic nasal congestion. These CBCT scans were used to print plastic 3D prints of the nasal cavities, which were also CBCT scanned and the measurements were compared.

**Results:** The results in vivo were higher than the results in vitro in maxillary sinus volumes with a ratio of  $1.05 \pm 0.01$  (mean  $\pm$  SD) and in the nasal cavities with a ratio of  $1.20 \pm 0.1$  (mean  $\pm$  SD). Linear measurements in vitro were very close to those in vivo. Rhinomanometric results showed some differences, but rhinomanometric graphs in vitro were close to the graphs in vivo.

**Conclusions:** 3D printing proved to be a suitable and fast method for replicating nasal cavity structures and for the experimental testing of nasal function. It can be used as a complementary examination tool for rhinomanometry.

**Keywords:** printing, three-dimensional, rhinomanometry, cone-beam computed tomography, nasal cavity

201572

## Endoscopic sinus surgery patient reported outcome measures using a dedicated online website: our experience and results

**Jennifer Magill<sup>1</sup>**, James Arwyn-Jones<sup>1</sup>, Micaela Acosta<sup>2</sup>, Hesham Saleh<sup>1</sup>, Catherine Rennie<sup>1</sup>

<sup>1</sup>ENT Department, Imperial College Healthcare NHS Trust, London, UK; <sup>2</sup>ENT Department, Churruca Visca Hospital, Buenos Aires, Argentina

**Background:** Chronic rhinosinusitis (CRS) is a common chronic disease, significantly impacting quality of life. Improvement in symptoms is best measured using patient-reported outcome measures (PROMs) like the SNOT-22 questionnaire. Capturing data can be time consuming, and follow-up data is often missed. As such, we have trialled the use of online software by Otovalo.

**Methodology:** 50 patients were categorized into groups: CRS with comorbidities and CRS with or without polyposis. Pre-operative and 6-month post-operative SNOT-22 scores were stored in our database, as well as pre-operative Lund-Mackay scores. We evaluated the minimal clinically important difference (MCID) improvement of 9 points in the SNOT-22 after endoscopic sinus surgery (ESS). The correlation between the values of the pre-surgical SNOT-22 and Lund-Mackay scores was performed using the Pearson correlation coefficient (r).

**Results:** 60% achieved an MCID improvement of 9 points 6 months after ESS. This may reflect our tertiary practice and patient population with multiple comorbidities. In the group with comorbidities, there was no correlation between SNOT-22 and Lund-Mackay score ( $r=-0.15$ ). For those without comorbidities, there was a correlation with  $r=0.28$ .

**Conclusions:** Online recording of PROMs through a dedicated website can be a highly efficient and timely way of recording, analysing and presenting patient data.

**Key words:** CRS, FESS, PROMs, SNOT-22, Lund-Mackay

## Which is the best approach in giant maxillary sinus aspergilloma?

**Daniela Vrinceanu**<sup>1</sup>, Mihai Dumitru<sup>1,4</sup>, Bogdan Banica<sup>2</sup>, Adriana Elena Nica<sup>3,4</sup>

<sup>1</sup>ENT Department, Emergency University Hospital Bucharest, Romania; <sup>2</sup>OMF Department, Emergency University Hospital Bucharest, Romania; <sup>3</sup>Anesthesiology and Intensive Care Department, Emergency University Hospital Bucharest, Romania; <sup>4</sup>Carol Davila University of Medicine and Pharmacy, Bucharest, Romania

Poster Session, 26 Sept – 30 Sept, 2021, All day

**Background.** Maxillary sinus aspergilloma is not such a rare condition and may develop insidiously in an immunocompetent host. We diagnose it frequently when the aspergilloma has giant dimensions and is in the imminence of major complications. Always, the aspergilloma is in direct relation with the affected teeth on superior maxillar and may develop even after teeth extraction.

**Methodology.** We will present a series of 5 clinical cases of giant maxillary sinus aspergilloma with the imminence of major complications.

**Results.** The treatment in all cases was surgical, by a mixed approach (external and endoscopic). The external approach Caldwell-Luc type allowed the complete ablation for aspergilloma. The endoscopic approach allowed a large antrostomy to avoid recurrence. We made a mixed team with OMF surgeon to extract the affected teeth and to perform vestibuloplasty for oro-antral fistula after extraction when this complication occurs. In 3 cases we associated voriconazole for 7 days. The cases were monitored at 1, 3, 6, 12 months. The patients were without complaints and we had no recurrence.

**Conclusions.** Surgical drainage surgery for giant maxillary sinus aspergilloma should be done as quickly as possible after diagnosis because of the imminence of complications. We consider that systemic antifungal therapy is not necessary if we have an immunocompetent host, if the surgery is radical and if we have a large antrostomy.

**Keywords:** aspergilloma, maxillary sinus, mixed surgical approach.

## Literature

1. Daudia A et al. Advances in the management of paranasal sinus aspergillosis. *J Laryngol Otol.* 2008; 122(4):331-5
2. [Peral-Cagigal B](#) et al. Invasive maxillary sinus aspergillosis: A case report successfully treated with voriconazole and surgical debridement. *J Clin Exp Dent.* 2014 Oct; 6(4): e448-e451.
3. [Pagella F](#) et al. Paranasal sinus fungus ball: diagnosis and management. *Mycoses.* 2007 Nov;50(6):451-6

**Conceição Peixoto**<sup>1</sup>, Victor Correia da Silva<sup>1</sup><sup>1</sup>ENT department, Hospital Cuf Porto Hospital, Porto, Portugal

Poster Session, 26 Sept – 30 Sept, 2021, All day

**Background:** Schwannoma is a benign tumor, originating in the sheath of myelinated peripheral nerves. In the head and neck, the most common site is the VIII nerve, but other sites include the scalp, face, parotid gland, oral cavity, pharynx, larynx and trachea. Only 4% of Schwannomas appear at the nasal level. There, the most frequent location corresponds to the ethmoid, followed by the maxillary sinus, nasal cavity and sphenoid. Are usually slow-growing tumors, which remain asymptomatic until they reach large dimensions.

**Methodology/Principal:** Presentation of clinical case and literature review.

**Results:** Female patient, 38 years old, with complaints of nasal obstruction with a year of evolution, with recent onset of recurrent epistaxis of the right nasal cavity. Physical examination revealed a mass lesion at the medial aspect of the right middle turbinate, with a vegetative aspect, friable at touch. A CT scan identified a lesion in the right nasal cavity, apparently centered on the middle meatus, measuring about 2.7 x 1.6 x 3.1 cm, molding adjacent bone structures. Histological profile showed the characteristics of a benign nerve sheath tumor - nasal schwannoma.

**Conclusions:** Nasal schwannomas are very rare clinical entities to be considered in the differential diagnosis of nasal tumors.

Key words: Nose, schwannoma, benign tumor, peripheral nerve

#### Literature

1. Gulia JS, Yadav SS, Basur SK, Hooda A. Schwannoma of the membranous nasal septum. *Braz J Otorhinolaryngol.* 2013;79:789.
2. Yu E, Mikulis D, Nag S. CT and MR imaging findings in sinonasal schwannoma. *Am J Neuro Radiol.* 2006;27:929–30.
3. Pauna HF, Carvalho GM, Guimaraes AC, Maunsell RC, Sakano E. Schwannoma of the nasal septum: evaluation of unilateral nasal mass. *Braz J Otorhinolaryngol.* 2013;79:403.
4. Calceterra TC, Rich JR, Ward PW. Neurilemoma of the sphenoid sinus. *ArchOtolaryngol.* 1974;100:383–85.
5. Mey KH, Buchwald C, Daugaard S, Prause JU. Sinonasal schwannoma- a clinicopathological analysis of five rare cases. *Rhinology.* 2006;44:46–52.

**Background:** Odontogenic sinusitis (ODS) presents challenges because management requires multidisciplinary awareness and approach.

**Methodology:** Within a specialist rhinology clinic, we collected a prospective case series of 32 patients with ODS over 30 months, examining demographics; symptomatology; nasendoscopic findings; CT features; and recognition of ODS by relevant clinicians.

**Results:** Patients were aged 23–85 years (female:male=1.46). 43 teeth were affected: 7 patients (22%) had multiple pathological teeth. The most commonly involved was UL7 (n=12, 28%), with left-sided teeth more commonly implicated (n=25, 58%) than right. Nasal obstruction (n=19, 59%), rhinorrhoea (n=18, 56%), facial pressure and cacosmia/tasting drainage (both n=13, 41%) were typical symptoms. 9 patients (28%) demonstrated oedema on nasendoscopy, 9 purulence, and 7 polyps. On CT, 97% (n=31) had maxillary sinus disease (59% with full opacification); 75% (n=24) ipsilateral ethmoid sinus disease; and 56% normal contralateral appearances (mean Lund-Mackay score=7.65±4.47). Radiologists mentioned dentition in 3 cases (9%). 12 patients (38%) saw a dentist/oral surgeon; in 4 cases, they disagreed with the ODS diagnosis. In the appointment post-CT, otolaryngologists identified ODS in 11 cases (34%).

**Conclusions:** Awareness of ODS among relevant clinicians is sub-optimal. Otolaryngologists should consider ODS in patients presenting with features as described. Clinicians should routinely check dentition to enable appropriate multidisciplinary management.

Key words:

Sinusitis; focal infection, dental; sinusitis diagnostic imaging

**Daniela Vrinceanu**<sup>1</sup>, Mihai Dumitru<sup>1,4</sup>, Bogdan Banica<sup>2</sup>, Adriana Elena Nica<sup>3,4</sup>

<sup>1</sup>ENT Department, Emergency University Hospital Bucharest, Romania; <sup>2</sup>OMF Department, Emergency University Hospital Bucharest, Romania; <sup>3</sup>Anesthesiology and Intensive Care Department, Emergency University Hospital Bucharest, Romania; <sup>4</sup>Carol Davila University of Medicine and Pharmacy, Bucharest, Romania

Poster Session, 26 Sept – 30 Sept, 2021, All day

**Background.** Frontal sinus lipoma is a rare benign tumour, possibly congenital. There are only a few cases communicated in literature is a tumour with slow growth and insidious evolution which become evident after exteriorization in the frontal region by bony lysis or after the obstruction of the frontal nasal duct.

**Methodology.** We will present the clinical case of a 33-year-old male patient with cephalalgia and right frontal orbital tumefaction in evolution since 1 year. We believe at first examination that we have an exteriorized frontal sinus mucocoele. The CT scan examination suggested a tumour with fat density and lysis into the orbital floor of the right frontal sinus.

**Results.** We performed surgery with an external approach for right frontal sinus through the orbitary floor and we found a lipomatous yellow tumour coming from the sinus. We found no pathology on the frontal nasal canal. The ablation was radical and the surgical healing was very quick in 7 days. The histology confirm lipoma

**Conclusions.** Lipoma of frontal sinus is a rare condition which has to be differentiated from mucocoele, lipoma of subcutaneous tissue of frontal orbital region and of liposarcoma. The treatment is surgical and the certitude diagnosis is made by histology.

**Keywords:** lipoma, frontal sinus, surgery, histology

#### Literature

1. Carranza-Romero C, Armario-Hita JC, Fernandez-Vozmediano JM. Frontal congenital lipoma. *Pediatr Dermatol.* 2012;29(4):490-4.
2. Abdalla WM et al. Intraosseous lipoma of the left frontoethmoidal sinuses and nasal cavity. *AJNR AM J Neuroradiol.* 2007 Apr, 28(4):615-7
3. Leda RM et al. Giant frontal lipoma mimicking frontal mucocoele. *Rev bras. Oftalmol.* 2019 may/June, 78(3):199-201.



## A case presentation of a superiorly based subperiosteal orbital abscess

Georgios Chrysovisiotis, **Valentinos Sofokleous**, Pavlos Pantos, Vasileios S. Papanikolaou, Efthymios Kyrodimos, Aristeidis Chrysovergis

<sup>1</sup>Otorhinolaryngology Department, National and Kapodistrian University of Athens, General Hospital of Athens "Hippokrateio", Athens, Greece

Poster Session, 26 Sept – 30 Sept, 2021, All day

**Background:** A subperiosteal orbital abscess is a severe complication of acute rhinosinusitis that can ultimately endanger a patient's vision. The abscess is most commonly located on the medial orbital wall, as it usually results from the direct spread of infection from the ethmoid cells through the thin lamina papyracea. The rather uncommon superiorly based subperiosteal abscess occurs in a site harder to access endoscopically, superiorly to the frontoethmoidal suture line.

**Case presentation:** A 32-year-old female presented with severe facial pain, mostly on the right half of her face, along with ipsilateral periorbital edema, proptosis, and diplopia. Imaging studies demonstrated a subperiosteal abscess at the anteromedial part of her right orbital roof. The patient underwent endoscopic sinus surgery, whereby the affected sinuses were addressed. The drainage of the abscess was completed through a Lynch-Howarth incision. Postoperatively, the patient showed an immediate response, and she was discharged after completing a course of intravenous antibiotics.

**Conclusions:** The superiorly based subperiosteal abscess refers to a relatively rare site for an orbital abscess. Frontal sinusitis appears to be its cause in the majority of cases. Treating it solely endoscopically is more challenging than in medial wall abscesses, and a combined approach is often necessary.

**Keywords:** sinusitis/complications, frontal sinusitis, abscess/orbital, abscess/subperiosteal

#### Literature

1. Sciarretta V, Demattè M, Farneti P, Fornaciari M, Corsini I, Piccin O, Saggese D, Fernandez JJ. Int J Pediatr Otorhinolaryngol. 2017 May;96:72-76. doi: 10.1016/j.ijporl.2017.02.031
2. Gavriel H, Jabrin B, Eviatar E (2016) Management of superior subperiosteal orbital abscess. Eur Arch Otorhinolaryngol 273(1):145–150
3. Quintanilla-Dieck L, Chinnadurai S, Goudy SL, Virgin FW. Characteristics of superior orbital subperiosteal abscesses in children. Laryngoscope. 2017 Mar;127(3):735-740. doi: 10.1002/lary.26082
4. Kim J.H., Kim S.H., Song C.I., Kang J.W. Image-guided nasal endoscopic drainage of an orbital superior subperiosteal abscess. Br. J. Oral Maxillofac. Surg. 2016;54(2):e26–28
5. Ketenci I, Unlü Y, Vural A, Doğan H, Sahin MI, Tuncer E. Approaches to subperiosteal orbital abscesses. Eur Arch Otorhinolaryngol. 2013 Mar;270(4):1317-27. doi: 10.1007/s00405-012-2198-x

201892

## Cervical abscesses secondary to a skull base osteomyelitis. A case report.

**B. Mateos-Serrano<sup>1</sup>**, A. Pérez-Lázaro<sup>1</sup>, F. Pedrero-Escalas<sup>1</sup>, C. Alfonso<sup>1</sup>, J. Gavilán<sup>1</sup>

<sup>1</sup>Otolaryngology Department, La Paz University Hospital. Madrid. Spain.

Poster Session, 26 Sept – 30 Sept, 2021, All day

Clival osteomyelitis is a rare skull base osteomyelitis that affects mainly children. It usually originates from posterior ethmoid or sphenoidal sinusitis.

We present a 14 years-old girl who was admitted in the emergency department for presenting a lateral painful cervical mass. Nasal fibroendoscopy showed purulent rhinorrhoea and enlargement of posterior naso-oropharynx. Neurological exploration was normal.

Imagine tests showed large parapharyngeal, retropharyngeal and paravertebral abscesses, bilateral sphenoid sinus occupation and clival destruction consistent with osteomyelitis. C1 and C2 vertebral bones and occipital bone were affected too.

Emergency surgery was performed. Pharyngeal abscesses were intraorally drained and sphenoidal sinuses were opened by endoscopic approach. Paravertebral abscess was punctured. She was treated with different broad spectrum intravenous antibiotics during six weeks. During follow-up sphenoid had to be re-opened but, after that, the patient only showed a barely limited cervical mobility.

Sinonasal symptoms are not frequent in clival osteomyelitis even it is caused by a complicated sinusitis. Usually it presents meningeal or cavernous sinus related symptoms. Our patient shows a rare complication of this entity, where deep neck spaces were involved. Management of the disease is similar to other skull base infections, where systemic antibiotics and surgical debridement play an important role.

**Key words:** Cranial base osteomyelitis, clival osteomyelitis, complicated rhinosinusitis, cervical abscess, paediatric rhinosinusitis.

### Literature

Nabavizadeh SA, Vossough A, Pollock AN. Clival osteomyelitis. *Pediatr Emerg Care*. 2013;29(9):1030–1032.

Khan MA, Quadri SAQ, Kazmi AS, et al. A Comprehensive Review of Skull Base Osteomyelitis: Diagnostic and Therapeutic Challenges among Various Presentations. *Asian J Neurosurg*. 2018;13(4):959–970.

Trück J, Thompson A, Dwivedi R, Segal S, Anand G, Kelly DF. Nonotogenic Skull Base Osteomyelitis in Children: Two Cases and a Review of the Literature. *Pediatr Infect Dis J*. 2015;34(9):1025–1027.

## Adenoid cystic carcinoma of the paranasal sinuses. A single-institution analysis.

**B. Mateos-Serrano<sup>1</sup>**, C. Alfonso<sup>1</sup>, E Ruiz-Bravo<sup>2</sup>, J. Gavilán<sup>1</sup><sup>1</sup>Otolaryngology Department, La Paz University Hospital. Madrid. Spain., <sup>2</sup>Pathology Department, La Paz University Hospital. Madrid. Spain.

Poster Session, 26 Sept – 30 Sept, 2021, All day

**Background:** Adenoid cystic carcinomas are rare malignant epithelial tumours. Involvement of the nasal cavity and paranasal sinuses is uncommon. The purpose of this study was to identify the characteristics and prognosis of this tumours in our centre, a tertiary care hospital.**Methodology:** A single-centre retrospective study of 6 cases of adenoid cystic carcinoma managed between 2000 and 2020. Tumour characteristics, management, survival and disease-free survival were analysed.**Results:** Most patients had a locally-advanced tumour at diagnosis. The most common presenting symptom were unilateral blocked nose and epistaxis. Surgery was performed over 5 patients and all of them were treated with radiotherapy. The only patient who did not go into surgery presented non-resectable disease at the diagnosis. All of our patients presented local recurrence of the disease at any point of the follow-up.**Conclusions:** Adenoid cystic carcinomas are malignant tumours characterized by a high recurrence rate. Even surgery and radiotherapy are recommended treatment, local or distant recurrence are still present in all patients during the follow-up.

Key words: Adenoid cystic carcinoma, Nasal tumours.

## Literature

1. Unsal AA, Chung SY, Zhou AH, Baredes S, Eloy JA. Sinonasal adenoid cystic carcinoma: a population-based analysis of 694 cases. *Int Forum Allergy Rhinol.* 2017;7(3):312–320.
2. Chang CF, Hsieh MY, Chen MK, Chou MC. Adenoid cystic carcinoma of head and neck: A retrospective clinical analysis of a single institution. *Auris Nasus Larynx.* 2018;45(4):831–837.
3. Michel G, Joubert M, Delemazure AS, Espitalier F, Durand N, Malard O. Adenoid cystic carcinoma of the paranasal sinuses: retrospective series and review of the literature. *Eur Ann Otorhinolaryngol Head Neck Dis.* 2013;130(5):257–262.
4. Tirelli G, Capriotti V, Sartori G, Tofanelli M, Marcuzzo AV. Primary Adenoid Cystic Carcinoma of the Frontal Sinus: Case Description of a Previously Unreported Entity and Literature Review. *Ear Nose Throat J.* 2019;98(4):E8–E12.

**Pantazidou G.<sup>1</sup>**, Karagkouni E.<sup>1</sup>, Fountakis E.<sup>1</sup>, Heristanidou E.<sup>1</sup>, Sarris B.<sup>1</sup>.

<sup>1</sup>ENT Department, General Hospital of Patras, Patras, Greece.

Poster Session, 26 Sept – 30 Sept, 2021, All day

**Purpose:** The purpose of this work is to present a case of Thornwald's cyst and review of the relevant literature.

**Case\_Presentation:** A 37-year-old man developed a suspected nasal breathing difficulty congestion, oral respiration and persistent posterior secretions. On clinical examination, smooth mass was found in the nasopharynx causing complete occlusion of the right nasal funnel and almost 70% of the left. Computed tomography revealed a smooth cystic mass at nasopharynx, without enrichment, which respected the surrounding structures. Magnetic resonance imaging followed which showed a smooth cystic lesion of the nasopharynx, without enrichment, which respected the surrounding structures and intermediate-intensity magnetic signal in T1WI sequences and high in T2WI & STIR sequences. Removal of the cyst followed intraorally. Histology showed that the cyst was covered by a respiratory epithelium with minimal lymphoid tissue, making the diagnosis of the Thornwald's Cyst. Six months after the surgery, the patient has no symptoms with no recurrence.

**Conclusions:** Thornwald's Cysts are benign, usually asymptomatic and they are often a random finding of clinical or imaging examination of the nasopharynx. Excellent knowledge of their topographical appearance and radiological semantics necessary for accurate diagnosis and differential diagnosis of other lesions in the area of the nasopharynx.

**Key words:** nasopharynx, Thornwald's cyst, tumor.

1. Ben Salem D, Duvillard C, Assous D, Ballester M, Krausé D, Ricolfi F. Imaging of nasopharyngeal cysts and bursae. *Eur Radiol.* 2006; 16(10):2249-58.
2. Wilcox RA, Pathi R. Tornwaldt's cysts are sometimes a bit of a headache. *Intern Med J.* 2007; 37(1):67-8.
3. Palacios E, Valvassori G. Tornwaldt's cyst. *Ear Nose Throat J.* 2000; 79(5):348.
4. Eloy P, Watelet JB, Hatert AS, Bertrand B, Thornwaldt's cyst and surgery with powered instrumentation. *B-ENT* 2006; 2(3):135-9.

**Impact of surgical treatment on intensity and frequency of contact point headache**  
**Miljan Folic**<sup>1,2</sup>, Sasa Jakovljevic<sup>2</sup>, Milan Dragisic<sup>2</sup>, Aleksandar Ugrinovic<sup>2</sup>, Aleksandar Trivic<sup>1,2</sup>

<sup>1</sup>Belgrade University, School of Medicine, Serbia, <sup>2</sup>Clinic for Otorhinolaryngology and Maxillofacial Surgery, Clinical Center of Serbia, Belgrade, Serbia

Poster Session, 26 Sept – 30 Sept, 2021, All day

**Background:** Contact point headache is a type of secondary headache of rhinogenic origin in the absence of a nasal inflammatory process. Intranasal contact points refer to a contact between two opposing intranasal mucosal surfaces. Aim of the study is to present our experiences in treating patients suffering from contact point headache.

**Methodology/Principal:** Patients were divided into two groups based on contact of the nasal septum and inferior turbinate (first group) or middle turbinate (second group). Patients underwent classical septoplasty or endoscopic turbinoplasty and were monitored for changes in the intensity and frequency of headache before and after surgery.

**Results:** Patients in the second group had significantly higher intensity and frequency of headache before surgery than patients in the second group. The reduction of headache intensity after surgery was determined in both groups, with the reduction being more pronounced in the second group of subjects ( $p = 0.001$  and  $p = 0.000$ , respectively). There was also a reduction in the frequency of headache in subjects of both groups, to a similar extent.

**Conclusion:** Surgery provides benefit in intensity and frequency of contact point headache, although no patients with complete resolution were observed.

Key words: Headache, Nasal surgical procedures.

## Open Septorhinoplasty correct caudal deviation of nasal septum and improve function of air flow of nasal cavity, symptom of nasal obstruction.

**S. Kimura<sup>1</sup>**, Y. Nakamaru<sup>1</sup>, M. Suzuki<sup>1</sup>, A. Honma<sup>1</sup>, A. Nakazono<sup>1</sup>, A. Homma<sup>1</sup>

<sup>1</sup>*Department of Otolaryngology-Head & Neck Surgery, Faculty of Medicine and Graduate School of Medicine, Hokkaido University.*

Poster Session, 26 Sept – 30 Sept, 2021, All day

**Background:** Several methods were reported to correct caudal deviation of nasal septum, including Open Septorhinoplasty (OSR) and Killian incision (KI). In general, OSR were often applied for the caudal deviation rather than KI. However, little evidences were shown on the effect of OSR and KI for the caudal deviation in an objective manner.

**Methodology/Principal:** We retrospectively analyzed about 18 patients who underwent OSR and 11 patients who underwent traditional septoplasty with KI from June 2007 to October 2019. Caudal deviation was defined on the distance between anterior nasal spine (ANS) and most deviated point (MDP) in nasal septum on computerized tomography. The deformation rate of nasal septum was also calculated. Nasal airway resistance and visual analogue scale (VAS) score of nasal obstruction were examined.

**Results:** The distance between ANS and MDP was significantly correlated the VAS score. The deformation rate in patients with caudal septal deviation were significantly decreased with OSR ( $0.14 \pm 0.06$  to  $0.03 \pm 0.03$ ,  $p=0.004$ ), while not with KI ( $0.09 \pm 0.08$  to  $0.04 \pm 0.03$ ,  $p=0.25$ ). OSR also improved nasal airway resistance ( $1.10 \pm 0.44$  to  $0.42 \pm 0.15$ ,  $p=0.02$ ), and the VAS score ( $79.11 \pm 14.74$  to  $5.78 \pm 7.89$ ,  $p=0.004$ ).

**Conclusions:** OSR is more suitable than KI to correct the caudal deviation of nasal septum and improve symptom.

**Key words:** Open Septorhinoplasty, caudal deviation of nasal septum, Killian incision, Deformation rate, rhinomanometry

## Classification of endonasal HHT lesions using digital microscopy

**F. Kashani<sup>1</sup>**, A. Schneider<sup>2</sup>, H. Schinke<sup>1</sup>, M. Bertlich<sup>1</sup>, M. Canis<sup>1</sup>, F. Haubner<sup>1</sup>

<sup>1</sup> Department of Otorhinolaryngology, Head and Neck Surgery, University Hospital Munich, Munich, Germany, <sup>2</sup> ARRI Medical GmbH, Munich, Germany

Poster Session, 26 Sept – 30 Sept, 2021, All day

**Background:** Recurrent spontaneous epistaxis from nasal telangiectasias is the most common clinical manifestation and the most disturbing symptom in up to 95% of HHT (hereditary haemorrhagic telangiectasia) patients. A variety of treatment modalities are available for either acute or chronic management of epistaxis in HHT. Currently there exists only a classification of HHT patients by different genetic mutations. But there is no standard classification for the mucocutaneous endonasal manifestations of HHT. Aim of the present study was to document the variety of endonasal HHT lesions using digital microscopy and to establish a clinical classification.

**Methodology/Principal:** We classified endonasal manifestations in HHT patients in four severity classes, reflecting 3D morphology and localisation. For this purpose, we used a fully digital operating microscope delivering high-definition output streams in 3D (ARRISCOPE, ARRI Medical GmbH, Germany). We investigated the correlation between classes of endonasal manifestation and a) plasma VEGF level, b) severity of epistaxis, evaluated by epistaxis severity score (ESS), c) Haemoglobin level and d) quality of life, assessed by visual analogue scale (VAS).

**Results:** Plasma VEGF level and severity of epistaxis tended to increase with severity of endonasal manifestation. Quality of life showed a negative correlation to severity of endonasal manifestation. No relevant correlation was found between Haemoglobin and endonasal manifestation.

**Conclusions:** A standard classification for endonasal manifestation of HHT can give an indication of symptom severity and assists in the evaluation of the results of various treatment modalities in different endonasal severity classes. These warrant further investigation in larger prospective studies including also organ manifestations in M. Osler patients.

Key words: HHT, Morbus Osler, Epistaxis, ARRISCOPE, digital microscopy

#### Literature:

Kennedy DWH, Peter H.; Stammberger, Heinz R. et al. Rhinology. Diseases of the Nose, Sinuses, and Skull Base 2012.

Wirsching KEC, Kuhnel TS. Update on Clinical Strategies in Hereditary Hemorrhagic Telangiectasia from an ENT Point of View. Clin Exp Otorhinolaryngol. 2017.

McDonald J, Woolderchak-Donahue W, VanSant Webb C, Whitehead K, Stevenson DA, Bayrak-Toydemir P. Hereditary hemorrhagic telangiectasia: genetics and molecular diagnostics in a new era. Front Genet. 2015.

201984

## An unusual debut of Allergic Rhinitis with Asteraceae sensitization - oral allergy syndrome with genital localization

Ovidiu Berghi<sup>1</sup>, Daniela Lebit<sup>1</sup>, Daniela Vrinceanu<sup>2</sup>, **Mihai Dumitru**<sup>2</sup>

<sup>1</sup> Sfanta Maria Clinics and Laboratory, Bucharest, Romania, <sup>2</sup> UMF Carol Davila Bucharest, Romania

Poster Session, 26 Sept – 30 Sept, 2021, All day

**Background:** Oral allergy syndrome represents an allergic reaction subsequent to the consumption of fresh food like fruits and vegetables. Clinical picture includes itchy mouth, scratchy throat, or swelling of the lips, mouth, tongue, and throat. The patient is first sensitized by inhaling pollen that contains proteins similar with those from the foods. We present a case of unusual localization of this syndrome.

**Methodology/Principal:** We present a case of a 28 patient, female. She presented a local intense papulo-eritematous reaction in vagina after using herbals products with chamomile and yarrow (members of Asteraceae family) in spring of 2019 for a gynecological condition. In summer and autumn of 2019, she presented the first manifestations of allergic rhinitis (sneezing, rhinorrhea, nasal congestion and pruritus).

**Results:** Patient was investigated in order by gynecologist, allergist and ENT specialist. The patient was evaluated by skin prick test and found positive to ambrosia elatior (12 mm), Artemisia vulgaris (4 mm) and helianthus annuus pollen (12 mm), members of Asteraceae family. Flexible endoscopy revealed nasal mucosal hypertrophy.

**Conclusions:** Cross – reactivity in Asteraceae family may produce unexpected manifestations in other parts of the body (vagina) in patients with allergic rhinitis.

Key words: allergic rhinitis, asteraceae, local allergy

### Literature

1. Muluk NB, Cingi C. Oral allergy syndrome. Am J Rhinol Allergy. 2018;32(1):27–30. doi:10.2500/ajra.2018.32.4489
2. Saunders S, Platt MP. Oral allergy syndrome. Curr Opin Otolaryngol Head Neck Surg. 2015;23(3):230–234. doi:10.1097/MOO.0000000000000160
3. Kishikawa R, Koto E, Oshikawa C, et al. Arerugi. 2019;68(10):1221–1238. doi:10.15036/arerugi.68.1221



## Challenges and treatment options for locally advanced and recurrent Basal Cell Carcinoma of the Head and neck – case presentation and literature review

**Tsv.Mladenov**<sup>1</sup>, Al.Valkov<sup>1</sup>, V.Kirov<sup>2</sup>, B, Duhlenki<sup>1</sup>, Tsv. Stoyanov<sup>1</sup>, G.Nikolov<sup>1</sup>

<sup>1</sup>*Clinic of ENT and Maxillofacial surgery UMHAT “D-r Georgi Stransky” - Pleven, Bulgaria,* <sup>2</sup>*Onco-Dermatology, UMHAT “D-r Georgi Stransky” - Pleven, Bulgaria*

Poster Session, 26 Sept – 30 Sept, 2021, All day

**Introduction:** Basal cell carcinoma(BCC) is the most common cancer in the world. Although many treatment modalities with excellent outcomes exist locally advanced (laBCC) and recurrent BCC still presents a challenge, leading to functional loss and morbidity.

**Aim:** To present 3 cases of locally advanced and recurrent BCC in the nasal and orbital region and the results of their treatment.

**Case presentation** Case 1 – 69 y.o. male who has undergone multiple operations since 2013 due to recurrent BCC with exenteration of right ocular bulb. Radiotherapy and Hedgehog pathway inhibitor (HPI) were used in his treatment. His last operation was in November 2019 which proved recurrence of BCC.

Case 2 – male 66 y.o presents with BCC of the left nasal wall with invasion of the ethmoid cells bordering with left inferior eyelid. Surgical excision of the lesion was performed with adjuvant treatment with HPI in 2018. On subsequent checkups there is no data for tumour recurrence.

Case 3 – Female 76 y.o. presents with laBCC of the left nasal wall, left medial canthus and left infraorbital region. Treated only with HPI with excellent results.

**Discussion:** Radical surgical excision and radiotherapy remain a cornerstone in the treatment of BCC and provide optimal outcomes. HPI are a promising treatment which present new options for patients with locally advanced and recurrent BCC who will otherwise require extensive and potentially disfiguring operations. The successful combination of these three treatment modalities can lead total or longer remission of laBCC.

**Key words:** basal cell carcinoma, hedgehog pathway Inhibitor, locally advanced

201990

Coblation for rhinophyma; an update on the evidence.

**Anya C.E. Selwyn**<sup>1</sup>, Bertram Fu<sup>1</sup>

<sup>1</sup>ENT Department, East Kent Hospital University Foundation Trust, England.

Poster Session, 26 Sept – 30 Sept, 2021, All day

**Background:** Rhinophyma is the progressive disfiguring enlargement of the nasal tip soft tissues. Histologically, hyperplasia of the sebaceous glands can be seen. Various surgical techniques have been reported including; cold steel, coblation, electrocautery, laser, dermabrasion, and cryosurgery. Coblation has the advantage of giving a bloodless field with low energy transfer, allowing for optimal cosmetic outcome. We wish to examine the evidence supporting the use of coblation for the treatment of Rhinophyma.

**Methodology:** A literature search was conducted on OvidMedline®, Embase and Pubmed using the search terms ‘coblation’ and ‘rhinophyma’. Six relevant publications were identified, all case reports or series. Interventions and outcomes were examined and compared.

**Results:** A total of 14 patients were examined, all male between 46 and 83 years. The majority were performed under general anaesthetic. The Evac 70 wand was most commonly described with ablation levels set between 6-7. Most closure techniques involved topical antibiotic application with dressings, however one full thickness skin graft was used. Re-epithelialisation was reported between two to four weeks, all patients were satisfied with cosmetic outcome.

**Conclusions:** Examining this series of case reports, the use of coblation as a surgical approach to managing rhinophyma has shown positive outcomes with high patient satisfaction.

Key words: Rhinophyma

201991

A rare finding of osteochondroma in the maxillary sinus.

**Anya C.E. Selwyn**<sup>1</sup>, Bertram Fu<sup>1</sup>

<sup>1</sup>ENT Department, East Kent Hospital University Foundation Trust, England.

Poster Session, 26 Sept – 30 Sept, 2021, All day

**Background:** Osteochondromas are the most commonly found benign tumours of skeletal bone, the majority being found in long bones. However they are rarely found in the head and neck region and most frequently located in the mandible. To date there have been only three reported cases of osteochondromas of the maxillary sinus in literature. We wish to present our case of this rarely located sinus tumour and discuss our management in comparison to the three existing cases.

**Methods:** Electronic patient records and Radiological imaging were reviewed. A literature search was conducted on OvidMedline ® and Embase using search terms: ‘osteochondroma’, ‘maxillary sinus’ and ‘paranasal sinuses’.

**Results:** The patient was given the option of surgical excision versus conservative management. The patient opted for the latter in view of relative absence of symptoms. Interval CT imaging was performed at one year with follow up. The osteochondroma remained static and the patient was discharged. Comparisons are made with the three other existing cases in the literature.

**Conclusions:** This case is an example of how an extremely rare tumour of the sinus can be managed.

Key words: osteochondroma, maxillary sinus, paranasal sinuses, paranasal sinus disease

202013

Mucosal zinc level correlated with collagen expression in nasal mucosa.

**Masanobu Suzuki**<sup>1,2</sup>, Mahnaz Ramezanpour<sup>2</sup>, Yuji Nakamaru<sup>1</sup>, Takayoshi Suzuki<sup>1</sup>, Akihiro Homma<sup>1</sup>, Peter-John Wormald<sup>2</sup>, Sarah Vreugde<sup>2</sup>

<sup>1</sup>Department of Otolaryngology-Head & Neck Surgery, Faculty of Medicine and Graduate School of Medicine, Hokkaido University, Japan, <sup>2</sup>Department of Surgery—Otorhinolaryngology Head and Neck Surgery, the Queen Elizabeth Hospital, and the University of Adelaide, Adelaide, SA, 5061, Australia.

Poster Session, 26 Sept – 30 Sept, 2021, All day

**Background:** Recently, local zinc deficiency was reported in nasal polyp, although the significance of zinc in pathogenesis of nasal polyp is still unknown. Zinc is one of the most important enzymes for many signaling pathway including TGF- $\beta$  signaling, which regulates synthesis of collagen. Collagen depletion is one of hallmarks of nasal polyps and considered to be involved in the pathogenesis of nasal polyps. We examined the effect of local zinc deficiency on collagen expression in nasal mucosa.

**Material and methods:** Type I collagen expression and mucosal zinc level in nasal mucosa from non-CRS controls, CRS without and with nasal polyps (CRSsNP and CRSwNP) were examined with sirius-red stain and Zinquin fluorescent probe, respectively. To examine type I collagen expression, fibroblasts obtained from the nasal mucosa were incubated in zinc-depleted media, followed by qPCR and ELISA.

**Results:** Mucosal zinc level and collagen expression were significantly decreased in CRSwNP patient compared to controls ( $p < 0.05$ ). Mucosal zinc level was positively correlated to collagen expression ( $r = 0.41$ ,  $p = 0.01$ ). Zinc deficiency significantly suppressed collagen mRNA expression and secretion in fibroblast, in vitro.

**Conclusions:** Local zinc deficiency in nasal mucosa could be involved in the pathogenesis of nasal polyps through suppression of collagen synthesis in fibroblast.

Key words: CRSwNP, collagen, mucosal zinc, and fibroblasts.

## Sinonasal Malignancies: Regional Involvement and Long-term Oncological Outcome

**Lukas Anschuetz**<sup>1</sup>, Ralph Hohenberger<sup>2</sup>, Christoph Kaecker<sup>2</sup>, Olgun Elicin<sup>3</sup>, Roland Giger<sup>1</sup>, Marco Caversaccio<sup>1</sup>

<sup>1</sup> Department of Otorhinolaryngology, Head and Neck Surgery, Inselspital, Bern University Hospital, University of Bern, Bern, Switzerland, <sup>2</sup> Department of Otorhinolaryngology, Head and Neck Surgery, Heidelberg University Hospital, Heidelberg, Germany, <sup>3</sup> Department of Radiation Oncology, Inselspital, Bern University Hospital, University of Bern, Bern, Switzerland

Poster Session, 26 Sept – 30 Sept, 2021, All day

**Background:** This study aimed to assess a large cohort with sinonasal malignancies focusing on initial regional involvement, recurrence and its management. Additionally, prognostic factors for oncological outcome were identified.

**Methodology:** Patients (n=145) with malignant sinonasal tumours were treated in our tertiary reference center between 2008 and 2019. A retrospective chart review was performed. In multivariate analyses, prognostic factors on overall survival (OS), progression-free survival (PFS) were analyzed.

**Results:** Predominant histological types were squamous cell carcinoma (n=74), adenocarcinoma (n=24) and melanoma (n=18). Median follow-up was 47 months. Primary tumour therapy was in 65.5% surgical with 49% adjuvant radiotherapy. Definitive radiotherapy was applied to 22.7% patients. Recurrence was observed as: local n=27, loco-regional n=14, regional n=9, and distant metastasis n=14. Five-year OS was 74%, whereas PFS was 47%. In multivariate models, initial staging with cT>2 (HR 4.4, 95% CI 1.94-11.9), cN+ (HR 3.82, 95% CI 1.66-8.07) and age > 60 (HR 2.4, 95% CI 1.21 -5.0) were independent adverse risk factors for OS. Additionally cT>2 (HR 2.13, 95% CI 1.28-3.67) and cN+ (HR 2.12, 95% CI 1.05-3.93) were independent adverse risk factors for PFS.

**Conclusions:** Initial nodal involvement and locally advanced tumor stage are independent prognostic factors for poor PFS and OS.

Key words: Sinonasal malignancies, regional involvement, outcome, therapy

## Skull base osteomyelitis: clinical and radiologic analysis of a rare and multifaceted pathological entity

Vittorio Rampinelli<sup>1</sup>, Alberto Schreiber<sup>1</sup>, Marco Ravanelli<sup>2</sup>, Marco Ferrari<sup>1</sup>, Alperen Vural<sup>1,3</sup>, Davide Mattavelli<sup>1</sup>, Valerio Mazza<sup>2</sup>, Ivan Zorza<sup>2</sup>, Marco Lorenzo Bonù<sup>4</sup>, Liana Signorini<sup>5</sup>, Francesco Doglietto<sup>6</sup>, Davide Farina<sup>2</sup>, Roberto Maroldi<sup>2</sup>, Piero Nicolai<sup>1</sup>

<sup>1</sup> Unit of Otorhinolaryngology – Head and Neck Surgery, University of Brescia, Brescia, Italy

<sup>2</sup> Unit of Radiology, University of Brescia, Brescia, Italy

<sup>3</sup> Department of Otorhinolaryngology, Erciyes University, Kayseri, Turkey

<sup>4</sup> Unit of Radiation Oncology, University of Brescia, Brescia, Italy

<sup>5</sup> Unit of Infectious and Tropical Diseases, University of Brescia, Brescia, Italy

<sup>6</sup> Unit of Neurosurgery, University of Brescia, Brescia, Italy

Poster Session, 26 Sept – 30 Sept, 2021, All day

**Background:** Skull base osteomyelitis (SBO) is a potentially life-threatening inflammation of cranial base bony structures of variable origin. Criteria for diagnosis and treatment are still controversial.

**Methodology/Principal:** Demographics, predisposing factors, symptoms, imaging, and clinical, laboratory, histological, and microbiological data of patients managed for SBO at the University Hospital of Brescia between 2002 and 2017 were retrospectively reviewed. Patients were included in different etiological groups. The topographic distribution of magnetic resonance (MR) abnormalities was recorded. The association between variables and etiological groups was verified with appropriate statistical tests. A classification tree analysis was performed with the aim of inferring a clinical-radiological diagnostic algorithm for SBO.

**Results:** The study included 47 patients, divided into 5 etiological groups: otogenic (n = 5), radio- induced (n = 16), fungal (n = 14), immune-mediated (n = 6), and idiopathic (n = 6). At MR, five types of topographical distribution were identified (central symmetric, central asymmetric, orbital apex, sinonasal, maxillary). In patients with a history of radiotherapy, the probability to develop SBO was significantly increased in areas receiving the highest radiation dosage.

**Conclusions:** The integration of clinical and radiologic information is an efficient strategy to categorize SBO and potentially guide its complex management.

**Key words:** Skull base. Osteomyelitis. Algorithm. Diagnosis. Multidisciplinary.

### Literature

1. Ridder GJ, Breunig C, Kaminsky J, Pfeiffer J (2015) Central skull base osteomyelitis: new insights and implications for diagnosis and treatment. *Eur Arch Otorhinolaryngol* 272(5):1269–1276.
2. Clark MP, Pretorius PM, Byren I, Milford CA (2009) Central or atypical skull base osteomyelitis: diagnosis and treatment. *Skull Base* 19(4):247–254.
3. Blyth CC, Gomes L, Sorrell TC, da Cruz M, Sud A, Chen SC (2011) Skull-base osteomyelitis: fungal vs. bacterial infection. *Clin Microbiol Infect* 17(2):306–311.
4. Chang PC, Fischbein NJ, Holliday RA (2003) Central skull base osteomyelitis in patients without otitis externa: imaging findings. *AJNR Am J Neuroradiol* 24(7):1310–1316.
5. Mortazavi MM, Khan MA, Quadri SA, Suriya SS, Fahimdanesh KM, Fard SA, Hassanzadeh T, Taqi MA, Grossman H, Tubbs RS (2018) Cranial osteomyelitis: a comprehensive review of modern therapies. *World Neurosurg* 111:142–153.

202097

## Nasal metastasis of lung squamous cell carcinoma initially diagnosed as furunculosis

Helen Tsakiraki, Efklidis Proimos, Kalliopi Korakovouni, **Alexandros Ladias**, Theognosia Chimona, Chariton Papadakis.

<sup>1</sup>Otorhinolaryngology Dept. Chania General Hospital.

Poster Session, 26 Sept – 30 Sept, 2021, All day

**Background:** A 62 years-old patient was referred to ENT Clinic of Chania General Hospital for painful swelling and redness on top of nose with accompanying fever. Patient's medical history included non-microcellular squamous cell lung carcinoma treated with chemo (cisplatin and gemcitabine) and RT (50Gy).

**Methodology:** He was admitted in the ENT Dept. for iv. Antibiotics (ceftazidime 1gr x2 and clindamycin 600mg x3) and laboratory tests.

**Results:** Fifteen days after admission the patient's condition showed progressive deterioration with lesion increase in size, induration, ulcers and telangiectasias presentation. MRI scan programmed revealed a solid lesion with max. dimensions 3.5x2.8cm extended to the nasal septum and occupying the right nostril. Biopsy confirmed a low grade metastatic from the lung, squamous cell carcinoma.

**Conclusion:** Distant, head and neck skin metastasis related to lung squamous cell carcinoma are extremely rare. They have a rapid growth and are a poor prognostic indicator in patients with primary lung cancer. Otorhinolaryngologists should be alert of this condition in order to suspect and diagnose early this severe disease.

**Key words:** nasal skin metastasis, lung squamous cell carcinoma, furunculosis.

## Topical Steroids and Intraoperative Bleeding in FESS

**Alexandros Ladias**, Kalliopi Korakovouni, Helen Tsakiraki, Efklidis Proimos, Theognosia Chimona, Chariton Papadakis.

<sup>1</sup>*Otorhinolaryngology Dept. Chania General Hospital.*

Poster Session, 26 Sept – 30 Sept, 2021, All day

**Background:** Functional Endoscopic Sinus Surgery (FESS) improves paranasal sinuses ventilation and mucociliary clearance. Indications include inflammatory sinus diseases, such as Chronic Rhinosinusitis with Nasal Polyps (CRSwNP) refractory to maximal medical treatment. Intraoperative bleeding increases complications risk. The aim of this study is to evaluate the possible effect of chronic nasal corticosteroid use (in CRSwNP) on increased intraoperative bleeding during FESS.

**Methodology:** 43 patients were included in our study. Patients were divided in two groups (control and INC group) according to chronic nasal corticosteroid use ( $\geq 12$  weeks). Baseline assessment included medical history, full ENT examination, SNOT-22Gr and EAS record. Computed tomography of the sinuses performed before surgery was according to a certain protocol, and evaluated according to the Lund-Mackay scale. During surgery (under controlled hypotension) intraoperative bleeding was evaluated according Boezaart scale and total blood loss (measured in milliliters).

**Results:** Lund McKay score did not reveal statistical difference between the groups ( $p=0.0203$ ). Mean blood loss in the INC group was 87.7ml while in the C group was 51.3ml ( $p=0.002$ ). A statistically significant difference was also found for the Boezaart score ( $p=0.002$ ).

**Conclusion:** According to our study, chronic preoperative use of INCs is associated with increased intraoperative bleeding.

**Key words:** chronic rhinosinusitis, FESS, nasal steroids, intraoperative bleeding.



**Mirjana Stracenski-Perge<sup>1</sup>**<sup>1</sup>*General Hospital Sremska Mitrovica ,Srbija*

Poster Session, 26 Sept – 30 Sept, 2021, All day

Background- demonstrating a difference in the therapeutic effect of 2 drugs of different mechanisms of action.

Method- retrospective study ,data were obtained from the medical history of the ambulatory examined patients with Chronic rhinosinusitis ,different etiology. The study included 132 patients. In 99 patients it was administered Mometason furoat-intranasal spray ,and in 33 patients it was administered intranasal spray - Manitol+ Glicerizine acid. Patients of all the ages are represented. The most common symptoms in both groups are nasal blockage and nasal rhinorrhea.

Results- The visual analog scale was used to evaluate patients difficulties. Every patient ranked their own problems before starting the therapy and one month later. The improvement in symptoms was noticed in patients in both groups. In the first group 6,07 and in the second 5,50.

Conclusion – Although intranasal corticosteroids constitute first-line therapy in the medical management of Chronic rhinosinusitis, in some selected cases with less severe problems, an intranasal decongestans could be applied in the therapy. Eventhough in the study both medications led to improvement, the first group included patients with more severe symptoms.

Key words- Chronic rhinosinusitis,nasal obstruction,therapy.

## A phase II open-label randomized trial of tretinoin in patients with Chronic Rhinosinusitis with Nasal Polyps.

**Marcelo A. Antonio**<sup>1</sup>; Fernando A. L. Marson <sup>2</sup>; Marcelo H. Sampaio <sup>1</sup>; Mariana D. C. Toro <sup>1</sup>; Icleia S. Barreto<sup>3</sup>; Sérgio S. J. Dertkigil <sup>4</sup>; Emerson T. I. Sakuma <sup>4</sup>; Dioze Guadagnini <sup>5</sup> ; Eulalia Sakano <sup>1</sup>

<sup>1</sup>Department of Ophthalmology and Otorhinolaryngology, <sup>2</sup>Department of Medical Genetics and Genomic Medicine, <sup>3</sup>Department of Pathological Anatomy, <sup>4</sup>Department of Radiology, <sup>5</sup>Department of Internal Medicine, Faculty of Medical Sciences, State University of Campinas (UNICAMP), Campinas, São Paulo, Brazil

Poster Session, 26 Sept – 30 Sept, 2021, All day

Chronic rhinosinusitis with nasal polyps (CRSwNP) is usually treated with corticosteroids which can be ineffective. Topical tretinoin was supposed to be a treatment option, based on oral and ocular use. First-in-humans open-label trial, patients with CRSwNP were randomized into a control group (CTR: n = 15) treated with budesonide for 24 weeks and an intervention group (TRT: n = 15), who received budesonide either but associated to 0,1% tretinoin for the last 12 weeks. Primary endpoint was a comparison of endoscopy (modified Lund-Kennedy Score/LKS) at baseline, 12 and 24 weeks. Secondary objectives included evaluation of quality of life (Sinonasal Outcome Test-22/SNOT-22), histopathological and tomographic (Lund-Mackay Score/LMS) analysis, smell test, and tissue immunoassay (Multiplex) for TNF- $\alpha$ , IL-1 $\beta$ , IL-5 and MMP-9 before and after tretinoin use. Primary outcome: a greater statistical improvement in LKS between moments favoring TRT ( $p < 0,01$ ; CTR:  $p = 0,02$ ) and in smell test between groups ( $p = 0,018$ ; CTR = 0.272). Secondary outcomes: less microscopic edema on TRT group [2/13 (15.4%) vs 8/13 (61.5%),  $p = 0,044$ ] and tretinoin safety in view of few adverse events, endorsed by the lack of variations in pro-inflammatory cytokine between groups: TNF- $\alpha$  ( $p = 0,829$ ;  $p = 0,829$ ), IL-1b ( $p = 0,323$ ;  $p = 0,905$ ), MMP-9 ( $p = 0,323$ ;  $p = 1$ ) and IL-5 ( $p = 0,126$ ;  $p = 0,719$ ). No statistical changes were significant for SNOT-22 and LMS. Shortterm transnasal 0,1% tretinoin was safe and well-tolerated and more effective than budesonide monotherapy. Tretinoin could be an option for some CRSwNP phenotypes.

Keywords: retinoic acid; tretinoin; rhinosinusitis; nasal polyposis; immunomodulation

### Literature

1. Fokkens W, Lund V, Mullol J. European Position Paper on Rhinosinusitis and Nasal Polyps. *Rhinology*. 2012;50(23):1–298.
2. Liao B, Liu JX, Li ZY, Zhen Z, Cao PP, Yao Y, et al. Multidimensional endotypes of chronic rhinosinusitis and their association with treatment outcomes. *Allergy Eur J Allergy Clin Immunol*. 2018 Jul 1;73(7):1459–69.
3. De Greve G, Hellings PW, Fokkens WJ, Pugin B, Steelant B, Seys SF. Endotype-driven treatment in chronic upper airway diseases. Vol. 7, *Clinical and Translational Allergy*. BioMed Central Ltd.; 2017.
4. Smith KA, Orlandi RR, Rudmik L. Cost of adult chronic rhinosinusitis: A systematic review. *Laryngoscope*. 2015 Jul 1;125(7):1547–56.
5. Settipane GA, Chafee FH. Nasal polyps in asthma and rhinitis. A review of 6,037 patients. *J Allergy Clin Immunol*. 1977;59(1):17–21.
6. Johansson L, Akerlund A, Holmberg K, Melen I, Bende M. Prevalence of nasal polyps in adults: the Skovde population-based study. *Ann Otol Rhinol Laryngol*. 2003;112(7):625–9.
7. Kim HS, Surgery N. Prevalence and risk factors of chronic sinusitis in Korea : results of a nationwide survey. 1996;435–9.
8. Hedman J, Kaprio J, Poussa T, Nieminen MM. Prevalence of asthma, aspirin intolerance, nasal polyposis and chronic obstructive pulmonary disease in a population-

- based study. *Int J Epidemiol* [Internet]. 1999;28(4):717–22. Available from: <https://academic.oup.com/ije/article-lookup/doi/10.1093/ije/28.4.717>
9. Tomassen P, Vandeplas G, Van Zele T, Cardell LO, Arebro J, Olze H, et al. Inflammatory endotypes of chronic rhinosinusitis based on cluster analysis of biomarkers. *J Allergy Clin Immunol*. 2016;137(5):1449–1456.e4.
  10. Van Zele T, Claeys S, Gevaert P, Van Maele G, Holtappels G, Van Cauwenberge P, et al. Differentiation of chronic sinus diseases by measurement of inflammatory mediators. *Allergy Eur J Allergy Clin Immunol*. 2006;61(11):1280–9.
  11. Daines SM, Orlandi RR. Inflammatory cytokines in allergy and rhinosinusitis. *Curr Opin Otolaryngol Head Neck Surg*. 2010;18(3):187–90.
  12. Teran LM. Interleukin ( IL)-4 and to a lesser extent either IL-13 or interferon-gamma regulate the production of eotaxin-2/CCL24 in nasal polyps. *Allergy*. 2003;58:1011–7.
  13. Akdis CA, Bachert C, Cingi C, Dykewicz MS, Hellings PW, Naclerio RM, et al. Endotypes and phenotypes of chronic rhinosinusitis: A PRACTALL document of the European Academy of Allergy and Clinical Immunology and the American Academy of Allergy, Asthma & Immunology. *J Allergy Clin Immunol*. 2013;131(6):1479–90.
  14. Blaser K, Simon HU, Yousefi S, Schranz C, Schapowal A, Bachert C, et al. Direct Demonstration of Delayed Eosinophil Apoptosis as a Mechanism Causing Tissue Eosinophilia. *J Immunol* [Internet]. 1997;158:3902–8. Available from: <http://www.jimmunol.org/content/158/8/3902>
  15. Danielsen A, Tynning T, Brokstad KA, Olofsson J, Davidsson Å. Interleukin 5, IL6, IL12, IFN- $\gamma$ , RANTES and Fractalkine in human nasal polyps, turbinate mucosa and serum. *Eur Arch Oto-Rhino-Laryngology*. 2006;263(3):282–9.
  16. Bachert C, Zhang N, Holtappels G, De Lobel L, Van Cauwenberge P, Liu S, et al. Presence of IL-5 protein and IgE antibodies to staphylococcal enterotoxins in nasal polyps is associated with comorbid asthma. *J Allergy Clin Immunol*. 2010;126(5):962–8.
  17. Chen Y-S, Arab SF, Westhofen M, Lorenzen J. Expression of Interleukin-5, Interleukin-8, and Interleukin-10 mRNA in the Osteomeatal Complex in Nasal Polyposis. *Am J Rhinol*. 2005;19:117–23.
  18. Valera FCP, Queiroz R, Scrideli C, Tone LG, Anselmo-Lima WT. Evaluating budesonide efficacy in nasal polyposis and predicting the resistance to treatment. *Clin Exp Allergy*. 2009;39(1):81–8.
  19. Takeno S, Hirakawa K, Ueda T, Furukido K, Osada R, Yajin K. Nuclear factor-kappa B activation in the nasal polyp epithelium: relationship to local cytokine gene expression. *Laryngoscope*. 2002;112(1):53–8.
  20. Shin H-W, Kim D-K, Park M-H, Mi Eun K, Lee M, So D, et al. IL-25 as a novel therapeutic target in nasal polyps of patients with chronic rhinosinusitis. *J Allergy Clin Immunol*. 2015;135:1476–85.
  21. Chen F, Hong H, Sun Y, Hu X, Zhang J, Xu G, et al. Nasal interleukin 25 as a novel biomarker for patients with chronic rhinosinusitis with nasal polyps and airway hypersensitiveness: A pilot study. *Ann Allergy, Asthma Immunol*. 2017;119(4):310–6.
  22. Lam M, Hull L, Imrie A, Snidvongs K, Chin D, Pratt E, et al. Interleukin-25 and interleukin-33 as mediators of eosinophilic inflammation in chronic rhinosinusitis. *Am J Rhinol Allergy*. 2015;29(3):175–81.
  23. Zhang N, Van Zele T, Perez-Novo C, Van Bruaene N, Holtappels G, DeRuyck N et al. D. Different types of T-effector cells orchestrate mucosal inflammation in chronic sinus disease. *J Allergy Clin Immunol*. 2008;122:961–3.
  24. Lombardi V, Speak AO, Kerzerho J, Szely N, Akbari O. CD8 $\alpha$  $\beta$ <sup>–</sup> and CD8 $\alpha$  $\beta$ <sup>+</sup> plasmacytoid dendritic cells induce Foxp3<sup>+</sup> regulatory T cells and prevent the induction of airway hyper-reactivity. *Mucosal Immunol*. 2012;5(4):432–43.
  25. Sampaio SDAP, Bagatin E. Experiência de 65 anos no tratamento da acne e de 26 anos com isotretinoína oral. *An Bras Dermatol*. 2008;83(4):361–7.

26. Khoo K-C, Reik D, Colburn WA, Nutley NJ. Pharmacokinetics of Isotretinoin Following a Single Oral Dose. *J Clin Pharmacol*. 1982;22:395–402.
27. Colburn WA, Vane FM, Shorter HJ. Pharmacokinetics of isotretinoin and its major blood metabolite following a single oral dose to man. *Eur J Clin Pharmacol*. 1983;24(5):689–94.
28. ALLEN, J. G., BLOXHAM DP. The pharmacology and pharmacokinetics of the retinoids. *Pharmac Ther*. 1989;40(1):1–27.
29. Karadag AS, Ertugrul DT, Bilgili SG, Takci Z, Akin KO, Calka O. Immunoregulatory effects of isotretinoin in patients with acne. *Br J Dermatol*. 2012;167(2):433–5.
30. Borovaya A, Dombrowski Y, Zwicker S, Olisova O, Ruzicka T, Wolf R, et al. Isotretinoin therapy changes the expression of antimicrobial peptides in acne vulgaris. *Arch Dermatol Res*. 2014;306(8):689–700.
31. Camisa C, Eisenstat B, Ragaz A, Weissmann G. The effects of retinoids on neutrophil functions in vitro. *J Am Acad Dermatol*. 1982;6(4):620–9.
32. Liu PT, Krutzik SR, Kim J, Modlin RL. Cutting Edge: All-trans Retinoic Acid Down-Regulates TLR2 Expression and Function. *J Immunol*. 2005;174(5):2467–70.
33. Dillehay DL, Walia AS, Lamon EW. Effects of retinoids on macrophage function and IL-1 activity. *J Leukoc Biol*. 1988;44(5):353–60.
34. Na SY, Kang BY, Chung SW, Han SJ, Ma X, Trinchieri G, et al. Retinoids inhibit interleukin-12 production in macrophages through physical associations of retinoid X receptor and NF- $\kappa$ B. *J Biol Chem*. 1999;274(12):7674–80.
35. Watelet JB, Bachert C, Gevaert P, Van Cauwenberge P. Wound healing of the nasal and paranasal mucosa: A review. *Am J Rhinol*. 2002;16(2):77–84.
36. Van Bruaene N, Bachert C. Tissue remodeling in chronic rhinosinusitis. *Curr Opin Allergy Clin Immunol* [Internet]. 2011;11(1):8–11. Available from: <http://www.ncbi.nlm.nih.gov/pubmed/21150430>
37. Watelet JB, Bachert C, Claeys C, Van Cauwenberge P. Matrix metalloproteinases MMP-7, MMP-9 and their tissue inhibitor TIMP-1: Expression in chronic sinusitis vs nasal polypsis. *Allergy Eur J Allergy Clin Immunol*. 2004;59(1):54–60.
38. Wang LF, Chien CY, Tai CF, Kuo WR, Hsi E, Juo SHH. Matrix metalloproteinase-9 gene polymorphisms in nasal polypsis. *BMC Med Genet*. 2010;11(1):9–14.
39. Jalian HR, Liu PT, Kanchanapoomi M, Phan JN, Legaspi AJ, Kim J. All-trans retinoic acid shifts propionibacterium acnes-induced matrix degradation expression profile toward matrix preservation in human monocytes. *J Invest Dermatol* [Internet]. 2008;128(12):2777–82. Available from: <http://dx.doi.org/10.1038/jid.2008.155>
40. Van Bruaene N, Pérez-Novo CA, Basinski TM, Van Zele T, Holtappels G, De Ruyck N, et al. T-cell regulation in chronic paranasal sinus disease. *J Allergy Clin Immunol*. 2008;121(6):16–8.
41. Mucida D, Park Y, Kim G, Turovskaya O, Scott I, Kronenberg M, et al. Reciprocal TH17 and Regulatory T Cell Differentiation Mediated by Retinoic Acid. *Science* (80- ) [Internet]. 2007;317(5835):256–60. Available from: <http://www.sciencemag.org/cgi/doi/10.1126/science.1145697>
42. Kumar RK, Herbert C, Webb DC, Li L, Foster PS. Effects of anticytokine therapy in a mouse model of chronic asthma. *Am J Respir Crit Care Med*. 2004;170(10):1043–8.
43. Humbles AA, Lloyd CM, McMillan SJ, Friend DS, Xanthou G, McKenna EE, et al. A critical role for eosinophils in allergic airways remodeling. *Science* (80- ). 2004;305(5691):1776–9.
44. McMillan SJ, Xanthou G, Lloyd CM. Manipulation of allergen-induced airway remodeling by treatment with anti-TGF-beta antibody: effect on the Smad signaling pathway. *J Immunol* [Internet]. 2005;174(9):5774–80. Available from: <http://www.ncbi.nlm.nih.gov/pubmed/15843580>
45. Ueki S, Mahemuti G, Oyamada H, Kato H, Kihara J, Tanabe M, et al. Retinoic Acids Are Potent Inhibitors of Spontaneous Human Eosinophil Apoptosis. *J Immunol*

- [Internet]. 2008;181(11):7689–98. Available from: <http://www.jimmunol.org/cgi/doi/10.4049/jimmunol.181.11.7689>
46. Zhao J, Lloyd CM, Noble A. Th17 responses in chronic allergic airway inflammation abrogate regulatory T-cell-mediated tolerance and contribute to airway remodeling. *Mucosal Immunol*. 2013;6(2):335–46.
  47. Anselmo-Lima WT, Sakano E, Araripe Nunes AA, Fernandes AM, Tamashiro E, Pereira EA, et al. Rhinosinusitis: Evidence and experience. October 18 and 19, 2013- São Paulo. *Braz J Otorhinolaryngol*. 2015;81(Supl 1):S1–49.
  48. Xiao S, Jin H, Korn T, Liu SM, Oukka M, Lim B, et al. Retinoic Acid Increases Foxp3+ Regulatory T Cells and Inhibits Development of Th17 Cells by Enhancing TGF- $\beta$ -Driven Smad3 Signaling and Inhibiting IL-6 and IL-23 Receptor Expression. *J Immunol*. 2008;
  49. Cavallari FE, Valera FCP, Gallego AJ, Malinsky RR, Küpper DS, Milanezi C, et al. Expression of RANTES, eotaxin-2, ICAM-1, LFA-1 and CCR-3 in chronic rhinosinusitis patients with nasal polyposis. *Acta Cir Bras* [Internet]. 2012;27(9):645–9. Available from: <http://www.ncbi.nlm.nih.gov/pubmed/22936091>
  50. Zhang M, Zhu L, Feng Y, Yang Y, Liu L, Ran Y. Effects of acitretin on proliferative inhibition and RANTES production of HaCaT cells. *Arch Dermatol Res*. 2008;300(10):575–81.
  51. Mjösberg JM, Trifari S, Crellin NK, Peters CP, Van Drunen CM, Piet B, et al. Human IL-25-and IL-33-responsive type 2 innate lymphoid cells are defined by expression of CCR2 and CD161. *Nat Immunol*. 2011;12(11):1055–62.
  52. Spencer SP, Wilhelm C, Yang Q, Hall JA, Bouladoux N, Boyd A, et al. Adaptation of innate lymphoid cells to a micronutrient deficiency promotes type 2 barrier immunity. *Science* (80- ). 2014;343(6169):432–7.
  53. Moncada S, Palmer RMJ, Higgs EA. Biosynthesis of nitric oxide from l-arginine. A pathway for the regulation of cell function and communication. *Biochem Pharmacol*. 1989;38(11):1709–15.
  54. Ramis I, Lorente J, Roselló-Catafau J, Quesada P, Gelpí E, Bulbena O. Differential activity of nitric oxide synthase in human nasal mucosa and polyps. *Eur Respir J*. 1996;9(2):202–6.
  55. Lindberg S, Cervin A, Runer T. Nitric oxide (NO) production in the upper airways is decreased in chronic sinusitis. *Acta Otolaryngol*. 1997;117(1):113–7.
  56. Scadding G. Nitric oxide in the airways. *Curr Opin Otolaryngol Head Neck Surg*. 2007;15(4):258–63.
  57. Bécherel PA, Le Goff L, Ktorza S, Chosidow O, Francès C, Issaly F, et al. CD23-mediated nitric oxide synthase pathway induction in human keratinocytes is inhibited by retinoic acid derivatives. *J Invest Dermatol*. 1996;106(6):1182–6.
  58. Datta PK, Lianos EA. Retinoic acids inhibit inducible nitric oxide synthase expression in mesangial cells. *Kidney Int*. 1999;56(2):486–93.
  59. Bachert C, Mannent L, Naclerio RM, Mullol J, Ferguson BJ, Gevaert P, et al. Effect of Subcutaneous Dupilumab on Nasal Polyp Burden in Patients With Chronic Sinusitis and Nasal Polyposis. *Jama* [Internet]. 2016;315(5):469–79. Available from: <http://jama.jamanetwork.com/article.aspx?doi=10.1001/jama.2015.19330>
  60. Gevaert P, Van Bruaene N, Cattaert T, Van Steen K, Van Zele T, Acke F, et al. Mepolizumab, a humanized anti-IL-5 mAb, as a treatment option for severe nasal polyposis. *J Allergy Clin Immunol* [Internet]. 2011;128(5):989–95. Available from: <http://dx.doi.org/10.1016/j.jaci.2011.07.056>
  61. Gevaert P, Calus L, Van Zele T, Blomme K, De Ruyck N, Bauters W, et al. Omalizumab is effective in allergic and nonallergic patients with nasal polyps and asthma. *J Allergy Clin Immunol* [Internet]. 2013;131(1):1–8. Available from: <http://dx.doi.org/10.1016/j.jaci.2012.07.047>
  62. Piccirillo JF, Merritt MG, Richards ML. Psychometric and clinimetric validity of the 20-Item Sino-Nasal Outcome Test (SNOT-20). *Otolaryngol - Head Neck Surg*.

- 2002;126(1):41–7.
63. Hopkins C, Gillett S, Slack R, Lund VJ, Browne JP. Psychometric validity of the 22-item Sinonasal Outcome Test. *Clin Otolaryngol*. 2009;34(5):447–54.
  64. Kosugi EM, Chen VG, Guerreiro Da Fonseca VM, Martins M, Cursino P, Arruda J, et al. Translation, cross-cultural adaptation and validation of SinoNasal Outcome Test (SNOT)-22 to Brazilian Portuguese. *Braz J Otorhinolaryngol* [Internet]. 2011;77(5):663–9. Available from: <http://www.bjorl.org.br/>
  65. Cain WS et al. Evaluation of olfactory dysfunction in the Connecticut Chemosensory Clinical research center. *Laryngoscope*. 1988;98(1):83–8.
  66. lund kennedy INICIAL.
  67. Psaltis AJ, Li G, Vaezeafshar R, Cho KS, Hwang PH. Modification of the Lund-Kennedy endoscopic scoring system improves its reliability and correlation with patient-reported outcome measures. *Laryngoscope*. 2014;124(10):2216–23.
  68. Lund VJ, Lund ' VJ, Mackay2 IS. Staging in Rhinosinusitis. *Rhinology* [Internet]. 1993;31:183–4. Available from: <https://www.researchgate.net/publication/15059640>
  69. Al-Hashimi I, Schifter M, Lockhart PB et al. Oral lichen planus and oral lichenoid lesions: diagnostic and therapeutic considerations. *Oral Surg Oral Med Oral Pathol Oral Radiol Endod*. 2007;103(S25):S25.e1–S25.e12.
  70. Herbort CP, Zografos L, Zwingli M, Schoeneich M. Topical retinoic acid in dysplastic and metaplastic keratinization of corneconjunctival epithelium. *Graefe's Arch Clin Exp Ophthalmol*. 1988;226(1):22–6.
  71. Kim EC, Choi JS, Joo CK. A Comparison of Vitamin A and Cyclosporine A 0.05% Eye Drops for Treatment of Dry Eye Syndrome. *Am J Ophthalmol* [Internet]. 2009;147(2):206–213.e3. Available from: <http://dx.doi.org/10.1016/j.ajo.2008.08.015>
  72. Stevens WW, Ocampo CJ, Berdnikovs S, Sakashita M, Mahdavinia M, Suh Bs L, et al. Cytokines in Chronic Rhinosinusitis: Role in Eosinophilia and Aspirin Exacerbated Respiratory Disease. *Am J Respir Crit Care Med*. 2015;192(5):682–94.
  73. Schubert CR, Cruickshanks KJ, Klein BEK, Klein R, Nondahl DM. Olfactory impairment in older adults: Five-year incidence and risk factors. *Laryngoscope*. 2011;121(4):873–8.
  74. Bhattacharyya N. Test-Retest reliability of computed tomography in the assessment of chronic rhinosinusitis. *Laryngoscope*. 1999;109(7):1055–8.
  75. Bhattacharyya N. Radiographic stage fails to predict symptom outcomes after endoscopic sinus surgery for chronic rhinosinusitis. *Laryngoscope*. 2006;116(1):18–22.
  76. Bachert C, Ph D, Gevaert P, Holtappels G, Cuvelier C, Ph D, et al. Nasal polyposis: from cytokines to growth. *Am J Rhinol*. 2015;(c):279–90.
  77. Gorpelioglu C, Ozol D, Sarifakioglu E. Influence of isotretinoin on nasal mucociliary clearance and lung function in patients with acne vulgaris. *Int J Dermatol*. 2010;49(1):87–90.
  78. Paravar T. UC Davis Dermatology Online Journal Title Isotretinoin therapy for the treatment of acne in patients with cystic fibrosis: a case series and review of the literature Publication Date Case presentation Isotretinoin therapy for the treatment of acne in patients with cystic fibrosis: a case series and review of the literature. 2016;
  79. Erickson VR, Antunes M, Chen B, Cohen NA, Hwang PH. The effects of retinoic acid on ciliary function of regenerated sinus mucosa. *Am J Rhinol*. 2008;
  80. Vega B et al. Retinoid inhibition of expression of VEGF [Internet]. United States Patent. 1999. Available from: <https://linkinghub.elsevier.com/retrieve/pii/0375650585900112>
  81. Early SB, Hise K, Han JK, Borish L, Steinke JW. Hypoxia stimulates inflammatory and fibrotic responses from nasal-polyp derived fibroblasts. *Laryngoscope*. 2007;117(3):511–5.



202187

## Spindle cell carcinoma of the nasal cavity: a case report

**Valentinos Sofokleous**, Spyridon Potamianos, Georgios Chrysovitsiotis, Evangelos Giotakis, Efthymios Kyrodimos

<sup>1</sup>*Otorhinolaryngology Department, National and Kapodistrian University of Athens, General Hospital of Athens "Hippokrateio", Athens, Greece*

Poster Session, 26 Sept – 30 Sept, 2021, All day

**Background:** Spindle cell carcinoma is a rare, aggressive variant of squamous cell carcinoma. It is predominantly located in the larynx, followed by the hypopharynx. Occurrence in the nasal cavity is only sparsely reported in the literature.

**Case presentation:** A 66-year-old male patient presented with a history of intermittent epistaxis from the left nasal cavity and ipsilateral nasal blockage. Endoscopy revealed an exophytic mass, fully occupying the left middle and superior meatuses. Following appropriate imaging, the patient underwent endoscopic surgery. Intraoperative frozen sections demonstrated a squamous cell carcinoma, and an endoscopic total fronto-sphenoidectomy followed. Histopathology showed a carcinoma consisting of malignant spindle and giant cells. An FDG PET-CT was obtained six weeks later that showed residual disease on the nasal septum that was subsequently addressed with revision endoscopic excision. Following discharge, the patient received adjuvant chemoradiation. He is now followed up periodically and remains free of disease, two years postoperatively.

**Conclusions:** Spindle cell carcinoma of the head and neck is a neoplasm with both epithelial and sarcomatous components. It is considered to be a locally aggressive tumour with a high recurrence rate. Wide surgical excision is the primary treatment of choice. Adjuvant chemoradiation is usually considered in advanced-stage disease.

**Key words:** spindle cell carcinoma, giant cell carcinoma, epithelial tumour, sinonasal carcinoma

### Literature

1. Sachin Gupta Dominick Santoriello, Rosemary Wieczorek, Mark D. De Lacure, Spindle cell carcinoma of the nasal cavity, *Rare Tumors*. 2013 Feb 11; 5(1): 10
2. Muhammad Shahid Iqbal, Vinidh Paleri, Jolene Brown, Alastair Greystoke, Werner Dobrowsky, Charles Kelly, Josef Kovarik. Spindle cell carcinoma of the head and neck region: treatment and outcomes of 15 patients, *Ecancermedicalscience*. 2015; 9: 594
3. Gerry D, Fritsch VA, Lentsch EJ. Spindle cell carcinoma of the upper aerodigestive tract: an analysis of 341 cases with comparison to conventional squamous cell carcinoma. *Ann Otol Rhinol Laryngol*. 2014 Aug;123(8):576-83
4. .Matthew E. Spector, MD, Kevin F. Wilson, MD, Emily Light, MS, Jonathan B. McHugh, MD, Carol R. Bradford MD, Clinical and Pathologic Predictors of Recurrence and Survival in Spindle Cell Squamous Cell Carcinoma, *Otolaryngol Head Neck Surg*. 2011 Aug;145(2):242-7
5. Vazquez A, et al. Sinonasal squamous cell carcinoma and the prognostic implications of its histologic variants: a population-based study. *Int Forum Allergy Rhinol*. 2015;5(1):85–91

# Omalizumab responders analysis in nasal polyposis: A supplementary analysis of the co-primary endpoints of POLYP-1 and POLYP-2 trials

**Joaquim Mullol<sup>1</sup>**, Jonathan Corren,<sup>2</sup> Peter W. Hellings,<sup>3,4</sup> Philippe Gevaert,<sup>5</sup> Claus Bachert,<sup>5,6</sup> Xavier Jaumont,<sup>7</sup> Rui Zhao,<sup>8</sup> Rebecca Saenz,<sup>8</sup> Lutaf Islam,<sup>9</sup> Theodore Omachi<sup>8</sup>

<sup>1</sup>Rhinology Unit & Smell Clinic, ENT Department, Hospital Clinic, IDIBAPS, Universitat de Barcelona, CIBERES, Barcelona, Catalonia, Spain; <sup>2</sup>Departments of Medicine and Pediatrics, David Geffen School of Medicine at the University of California, LA, USA; <sup>3</sup>Clinical Division of Otorhinolaryngology, Head & Neck Surgery, University Hospitals Leuven, Leuven, Belgium; <sup>4</sup>Laboratory of Clinical Immunology, Department of Microbiology and Immunology, KU Leuven, Leuven, Belgium; <sup>5</sup>Upper Airway Research Laboratory, Department of Otorhinolaryngology, Ghent University Hospital, Ghent, Belgium; <sup>6</sup>Division of ENT Diseases, CLINTEC, Karolinska Institute, Stockholm, Sweden; <sup>7</sup>Novartis Pharma AG, Basel, Switzerland; <sup>8</sup>Genentech, Inc., South San Francisco, CA, USA; <sup>9</sup>Roche, Welwyn Garden City, Hertfordshire, UK

Poster Session, 26 Sept – 30 Sept, 2021, All day

**Background:** The data of the two identical, randomised, placebo-controlled, Phase-III trials of omalizumab (POLYP-1 and POLYP-2) were analysed to evaluate the improvements in nasal polyp score (NPS) and nasal congestion score (NCS) in patients with intranasal corticosteroid-refractory chronic rhinosinusitis with nasal polyps (CRSwNP).

**Methods:** Responders at Week 16 or Week 24 were defined as patients achieving improvements of  $\geq 1$  or  $\geq 2$  points in NPS and  $\geq 0.5$  or  $\geq 1$  points in average daily NCS. The responder analyses at Week 24 were prespecified exploratory outcomes, while the Week 16 outcome was conducted *post-hoc*. Assessments were conducted by treatment arm in POLYP-1 and POLYP-2 and the pooled population.

**Results:** In POLYP-1 (N=138) and POLYP-2 (N=127), patients were randomised to omalizumab or placebo. The baseline mean NPS was 6.2 and 6.3 and mean average daily NCS was 2.4 and 2.3 indicating severe disease and symptoms. At Week 24 and Week 16, a greater proportion of patients treated with omalizumab versus placebo achieved improvements in mean NPS and mean daily NCS (Table).

**Conclusion:** The consistently and significantly higher response rates in omalizumab arm compared with placebo, in pooled analyses of POLYP-1 and POLYP-2 patients with CRSwNP, provided clear evidence of omalizumab efficacy in nasal polyposis.

**Table.** Proportion of responders achieving defined thresholds of improvement in nasal polyp score (NPS) and nasal congestion score (NCS)

	Week 24			Week 16		
	Omalizumab	Placebo	P value	Omalizumab	Placebo	P value
<b>NPS</b>						
$\geq 1$ -point improvement	56.3%	28.7%	<0.0001	63.0%	30.7%	<0.0001
$\geq 2$ -point improvement	31.3%	11.6%	0.0003	37.0%	9.4%	<0.0001
<b>NCS</b>						
$\geq 0.5$ -point improvement	59.5%	29.5%	<0.0001	59.4%	32.6%	<0.0001
$\geq 1$ -point improvement	44.4%	21.4%	$\leq 0.0001$	46.9%	19.8%	<0.0001

Key words: Nasal polyposis, omalizumab, nasal polyp score, nasal congestion score





## Long-term clinical follow-up of patients with chronic rhinosinusitis

Ulrica Thunberg<sup>1,2</sup>, Amanj Saber<sup>1,2</sup>, Bo Söderquist<sup>2,3</sup>, Svante Hugosson<sup>1,2</sup>

<sup>1</sup>*Department of Otorhinolaryngology, Örebro University Hospital, Örebro, Sweden*

<sup>2</sup>*Faculty of Medicine and Health, Örebro University, Sweden*

<sup>3</sup>*Department of Laboratory Medicine, Clinical Microbiology, Örebro University Hospital, Örebro, Sweden*

Poster Session, 26 Sept – 30 Sept, 2021, All day

**Background:** A long-term follow-up of a cohort of patients with chronic rhinosinusitis (CRS) regarding clinical features and symptomatology.

**Methods:** Data from 42 patients with CRS were available from a previous study and were contacted for inclusion after approximately 10 years. Patients completed a questionnaire about disease and symptoms, and underwent a clinical examination.

**Results:** Thirty-four patients (85%) could be included. The median length of time between initial inclusion (C1) and follow-up (C2) was 11 years. In some patients phenotypes shifted from CRS with nasal polyposis to CRS without nasal polyposis or vice versa. The median total visual analogue score for combined sinonasal symptoms for all patients was statistically significantly reduced at follow-up. Individual patients, scores for nasal congestion, nasal discharge, facial pressure, and hyposmia were also statistically significantly reduced. The most frequently reported symptom-relieving treatments were nasal steroids and saline rinsing of the nose. Self-reported general quality of life was statistically significantly improved at C2.

**Conclusions:** At long-term follow-up, symptoms were generally reduced and patients reported an improved quality of life. Chronic rhinosinusitis disease seems to harbour the ability to alter its phenotype after several years. Topical corticosteroids and saline rinsing of the nose should be emphasized.

## PARANASAL MUCOCELES IN CHILDREN WITH CYSTIC FIBROSIS: THE BRESCIA EXPERIENCE ON A LARGE SERIES

Vittorio Rampinelli <sup>1</sup>, Marco Berlucchi <sup>2</sup>, Piercarlo Poli <sup>3</sup>, Marco Ferrari <sup>1,4</sup>, Davide Lancini <sup>1</sup>, Silvana Timpano <sup>3</sup>, Redaelli De Zinis Luca <sup>1-2</sup>, Raffaele Badolato <sup>3</sup>, Rita Padoan <sup>3</sup>.

<sup>1</sup> Unit of Otorhinolaryngology - Head and Neck Surgery, University of Brescia, Brescia, Italy

<sup>2</sup> Unit of Pediatric Otorhinolaryngology, Spedali Civili, Brescia, Italy

<sup>3</sup> Department of Pediatrics, Regional support Centre for Cystic Fibrosis, University of Brescia, Brescia, Italy.

<sup>4</sup> Section of Otorhinolaryngology – Head and Neck Surgery, Department of Neurosciences, University of Padua, Padua, Italy

Poster Session, 26 Sept – 30 Sept, 2021, All day

**Background:** Paranasal mucocoele (PM) is reported as a complication of cystic fibrosis (CF) in up to 4% of cases. In the present study, the authors reviewed their experience on diagnosis and management of PM in a series of children with CF.

**Materials and methods:** Medical records of children with CF and PM who were admitted and treated at the Department of Pediatric Otorhinolaryngology, Spedali Civili di Brescia, Italy between 2004 and 2018 were reviewed.

**Results:** Thirty-four patients were included (mean age 7.7 years). CT scan of sinuses showed a total of 53 PMs. Endoscopic findings suggestive for PM were present in almost 80% of patients. PMs were located in the maxillary, ethmoid, and sphenoid sinuses in 29/34 (85.3%, bilateral in 17 cases), 4/34 (11.8%) and 1/34 (2.9%) patient, respectively. Marsupialization of PMs was performed in all patients using an endoscopic transnasal approach. No complications were observed. Resolution of symptoms was evident in all patients. No recurrences were observed.

**Conclusions:** To the best of our knowledge, this is the largest series of CF patients with PM. PMs should not be considered an uncommon finding in patients affected by CF. Endoscopic transnasal marsupialization represents the gold standard of care for patients with CF and PM(s).

Key words: Cystic fibrosis, mucocoele, endoscopic endonasal surgery, pediatric

Literature:

1. Goetz D, Ren CL. Review of Cystic Fibrosis. *Pediatr Ann.* 2019 Apr 1; 48(4):e154-e161.
2. Berkhout MC, van Rooden CJ, Rijntjes E. Sinonasal manifestations of cystic fibrosis: a correlation between genotype and phenotype? *Journal of Cystic Fibrosis.* 2014 Jul; 13(4):442-8.
3. Di Cicco M, Costantini D, Padoan R, Colombo C. Paranasal mucocoeles in children with cystic fibrosis. *Int J Pediatr Otorhinolaryngol.* 2005 Oct; 69(10):1407-13.
4. Horesh E, Colin AA, Casiano R, Wester ST. An atypical presentation of sinus mucopyocoele in a pediatric cystic fibrosis patient. *Clin Ophthalmol.* 2015 May 6; 9:821-4.
5. Gentile VG, Isaacson G. Patterns of sinusitis in cystic fibrosis. *Laryngoscope.* 1996 Aug; 106(8):1005-9.

## Our method of joining dura mater of frontal sinus tumors with intracranial invading by electrocautery

Zabolotniy D.<sup>1</sup>, Rytska O.<sup>1</sup>, **Kvasha O.**<sup>1</sup>, Savchenko T.<sup>1</sup>, Zarytska I.<sup>1</sup>

<sup>1</sup>State Institution "Institute of otolaryngology named after Prof. O.S. Kolomiychenko of the National Academy of Medical Sciences of Ukraine"; Kyiv, Ukraine.

Poster Session, 26 Sept – 30 Sept, 2021, All day

**Introduction.** When tumors of frontal sinus invade dura mater, for surgeon, it is necessary to completely close the defect of the dura mater to avoid intra- and postoperative complications.

**Materials and methods.** 63 patients who underwent surgical treatment for tumors of frontal sinuses with intracranial invading during the last years were analyzed. Patonmed electric cauterizing technology was used.

**Results.** All patients were divided into 2 groups - in the first group – we use our special developed bipolar instrument and use them to connect surgically dura mater, and in the second group - electrocautery was not used, and the dura mater was connected in traditional surgical methods. After 10 months, 6.25% of patients were diagnosed with nasal liquor in the second group and 1 case of meningitis (3.13%) in the second group. The second group also diagnosed 2 cases of continued growth (6.25%).

**Conclusion.** We observed following advantages of using electrocautery and special bipolar instrument during surgery of tumors of frontal sinus with intracranial invading: significantly decreased the volume of intraoperative blood loss, decreased duration of surgical interventions, decrease traumatism of intervention and decreased frequency of intra- and postoperative complications and it is reliable to joint dura mater.

## AMBROSIA, A REAL PROBLEM OF BIOLOGICAL POLLUTION DUE TO CLIMATE CHANGE

**Ramona Ungureanu**<sup>1</sup>, Elena Mădălan<sup>2</sup>,

<sup>1</sup>ENT Department, Diagnostic and Treatment Center “Dr. Victor Babes”, Bucharest, Romania, <sup>2</sup>Allergology Department, Diagnostic and Treatment Center “Dr. Victor Babes”, Bucharest, Romania

Poster Session, 26 Sept – 30 Sept, 2021, All day

Allergic rhinitis is a common health problem with a substantial impact on public health and the economy. The rapid rise in allergic rhinitis incidence over recent decades, has been attributed to diverse factors, including global warming and climate change.

It is generally thought that for allergic disease to develop, both genetic predisposition and allergen exposure are required. It seems that climate change and exposure to increased CO<sub>2</sub> concentration is increasing the abundance of aeroallergens such as pollen, which may result in greater incidence and severity of allergic diseases.

Experimental studies on *ambrosia artemisiifolia* shown that exposure to increased levels of CO<sub>2</sub> determined the increased pollen production and the duration of the pollen season.

Studying the patients with allergic rhinitis presented in our clinic between 2016 and 2019, we have noticed a progressive increase in number of cases with sensitization to ambrosia pollen, this representing about 50% about sensitizations to common environmental allergens. A significant percentage of cases evolves into allergic asthma, thus increasing the burden of allergic condition, both social and economical.

In our paper we want to illustrate that the outdoor air pollution in our city may act as an environmental risk factor for the increasing the number and severity of cases of allergy to ambrosia.

# A multicentre, randomised, open-label, controlled pilot study on the efficacy of corticosteroids administered by pulsating aerosol-nebulization versus nasal spray for chronic rhinosinusitis without nasal polyps (CRSsNP)

**B. G. Weiss<sup>1</sup>**, M. Canis<sup>1</sup>, J. L. Spiegel<sup>1</sup>, U. Eichler<sup>2</sup>, M. Haack<sup>3</sup>, T. Huppertz<sup>4</sup>, R. Ledermueller<sup>5</sup>, H. Mentzel<sup>5</sup>, S. Becker<sup>6</sup>

<sup>1</sup> Department of Otorhinolaryngology, Klinikum der Universität München, Ludwig-Maximilians-Universität München, Munich, Germany; <sup>2</sup> Clifopex GmbH, München, Germany

<sup>3</sup> HNO-Zentrum Mangfall-Inn, Rosenheim, Germany; <sup>4</sup> Department of Otorhinolaryngology, Head and Neck Surgery, University Medical Center, Johannes Gutenberg University, Mainz, Germany; <sup>5</sup> Pari GmbH, Starnberg, Germany; <sup>6</sup> Department of Otorhinolaryngology, Universitätsklinikum Tübingen, Germany

Poster Session, 26 Sept – 30 Sept, 2021, All day

**Background:** Chronic rhinosinusitis without nasal polyps (CRSsNP) and unsuccessful conservative treatment often requires sinus surgery. Drug delivery to the paranasal sinuses by nasal spray is limited. A potential improvement in particle deposition may be achieved via pulsating airflow.

**Methodology/Principal:** Prospective, randomised, open-label, controlled multicentre pilot study to investigate the potential of budesonide nasal spray (BuNS; 400µg/d) versus budesonide pulsating aerosol-nebulization with PARI SINUS (BuPS; 280µg/d) to avoid or postpone sinus surgery in patients with CRSsNP (EudraCT-No. 2013-002421-30). Disease-specific health-related quality-of-life (SNOT-20 GAV), sinusitis-related impairment and rhinorrhea (visual analogue scales) were outcome measures.

**Results:** All patients (10 BuPS/9 BuNS) experienced significant improved quality-of-life after the 8-week treatment-course (median: BuPS -8.0/-22.9%; BuNS -7.5/-41.7%) that continued at 12 and 24 weeks in the BuPS-group (-10.0/-28.6%; -11.0/-31.4%), the BuNS-group declined back to baseline. After treatment, reduction of rhinorrhoea was achieved in the BuPS-group (-20.0/-50.0%) with no changes in the BuNS-group (+2.5/+7.1%), sinusitis-related impairment (BuPS -49.5/-62.3%; BuNS -24.0/-48.0%) and the need for sinus surgery (BuPS -66.7%; BuNS -62.5%) was reduced in both groups.

**Conclusions:** Pulsating airflow for aerosolized delivery of budesonide is effective to avoid or postpone sinus surgery for CRSsNP. In comparison to nasal spray a potentially prolonged treatment-effect may be achieved.

**Key words:** CRSsNP, chronic rhinosinusitis without nasal polyps, topical corticosteroids, pulsating aerosol



## Connecticut Olfactory Test (CCCRC): validation and cultural adaptation in Brazil

**Fabiana Cardoso Pereira Valera<sup>1</sup>**, Edwin Tamashiro<sup>1</sup>, Guilherme Henrique Mitikami Fenólio<sup>1</sup>, Gabriela Canina Tomazini<sup>1</sup>, Maria Stella Arantes do Amaral<sup>1</sup>, Marina Zilio Fantucci<sup>1</sup>, Inaê Mattoso Compagnoni<sup>1</sup>, Alessandro Fernandes Guimarães<sup>2</sup>, Eulalia Sakano<sup>3</sup>, Roberto Eustaquio Guimarães<sup>2</sup>, Wilma T. Anselmo Lima<sup>1</sup>

<sup>1</sup>Department of Ophthalmology, Otorhinolaryngology and Head and Neck Surgery, Ribeirão Preto Medical School, University of São Paulo, Brazil., <sup>2</sup>Department of Ophthalmology and Otorhinolaryngology, Medical School, University of Minas Gerais, <sup>3</sup>Department of Ophthalmology and Otorhinolaryngology, Faculty of Medical Sciences, State University of Campinas

Poster Session, 26 Sept – 30 Sept, 2021, All day

**Background:** the olfactory impairment is a significant disability that affects the quality of life. The current tests, available in Brazil, are very expensive, or they have not been validated for Brazilians. The objective was to standardize an accessible test.

**Methods:** using the CCCRC smell test, we interviewed volunteers with no smell dysfunction based on original article. We maintained the six fragrances as previously described at the original test. As peanut butter is not very known in Brazil, we changed it to a Brazilian peanut-based sweet called Paçoquita®. We kept de Vick VapoRub® as an eighth fragrance to test irritative mucous sensitivity; 336 volunteers were evaluated.

**Results:** the composite score of our volunteers was equivalent to the original paper, in which more than 95% scored 6 or 7 in each nostril. Paçoquita® was well accepted by volunteers and the rate of positive results was similar to the other fragrances. Higher scores were observed at the female group, and a decrease in score was observed with aging.

**Conclusion:** these results certify that the cultural adaptation of CCCRC to the Brazilian population can be considered adequate. Culturally adapted CCCRC can be a useful tool to assess olfaction in Brazilian patients.

**Key words:** olfactory impairment; smell test; cultural adaptation of CCCRC; useful tool to assess olfaction



## Endotyping and phenotyping as predictors of recurrence in patient with chronic rhinosinusitis with nasal polyp

**Wilma T. Anselmo-Lima**<sup>2</sup>, Edwin Tamashiro<sup>2</sup>, Ronaldo B. Martins<sup>1</sup>, Marcelo Gonçalves Junqueira Leite<sup>2</sup>, D. M. M. Jorge<sup>1</sup>, Davi Casale Aragon<sup>3</sup>, Mirela Cristina M. Prates<sup>2</sup>, Tamara H. Saturno<sup>1</sup>, José Luiz Proença-Modena<sup>1</sup>, Flavia E. de Paula<sup>1</sup>, Lucas R. Carenzi<sup>2</sup>, Eurico Arruda<sup>1</sup>, Fabiana Cardoso Pereira Valera<sup>2</sup>.

<sup>1</sup>Department of Cell Biology, Ribeirão Preto Medical School, University of São Paulo, Brazil., <sup>2</sup>Department of Ophthalmology, Otorhinolaryngology and Head and Neck Surgery, Ribeirão Preto Medical School, University of São Paulo, Brazil., <sup>3</sup>Department of Pediatrics, Ribeirão Preto Medical School, University of São Paulo, Brazil.

Poster Session, 26 Sept – 30 Sept, 2021, All day

**Background:** Chronic rhinosinusitis is a multifactorial disease. This study was done to determine whether endophenotypic characteristics of CRS patients are correlated with refractory disease after endoscopic sinus surgery.

**Methods:** Patients with CRSwNP, CRSsNP and controls were evaluated for 62 variables, including cytokines, respiratory viruses, pathogenic bacteria and clinical features. Principal component analysis (PCA) was used to identify determinants of unfavorable outcomes of CRS.

**Results:** 115 patients with CRSwNP (58.2%) had increased T1, T2, T17 and Treg cytokines; higher values of IFN- $\gamma$ , TGF- $\beta$ , IL-2, IL-1 $\beta$  and IL-10 as compared to those with CRSsNP; CRSsNP (23.5%) had increased IFN- $\beta$ 1, IFN- $\gamma$ , IL-10, IL-17A, IL-1b, IL-2, and IL-5. PCA revealed that there were three clusters within the CRSwNP group: one with increased cytokines of mixed profile; a second with asthma or NSAID intolerance; and a third with low cytokine profile in the absence of asthma or NSAID intolerance. A high cytokine profile (except for IL-33), and the presence of asthma or NSAID intolerance were independently associated with need for revisional surgery.

**Conclusion:** Patients with CRSwNP and CRSsNP have mixed inflammatory profiles, but CRSwNP patients with asthma/NSAID intolerance or high inflammatory cytokine profiles are more to require revisional surgery than CRSwNP patients without such features.

**Keywords:** chronic rhinosinusitis, phenotype, recurrence, cytokines, inflammation, microbes

Laterally located mucocoele in a hyperpneumatized frontal sinus causing exophthalmos. A total endoscopic approach.

**Christos Korais<sup>1</sup>**, Charikleia Maiou<sup>1</sup>, Eleni Gkrinia<sup>1</sup>, Charalampos Skoulakis<sup>1</sup>, Athanasios Saratziotis<sup>1</sup>, Jiannis Hajjioannou<sup>1</sup>

<sup>1</sup>*Department of Otolaryngology, University Hospital of Larissa, Larissa, Greece.*

Poster Session, 26 Sept – 30 Sept, 2021, All day

**Background:** Frontal sinus mucocoeles are mucous secretory lesions within the sinus, presenting a slow – growing pattern, mostly behaving like space-occupying masses with subtle symptoms until bone erosion of the surrounding structures takes place. Intracranial and intraorbital expansion are regarded as the most considerable complications, demanding adequate surgical management in order to avoid recurrence. Functional endoscopic drainage is thought to be the current treatment choice, with radical external approaches or combined approaches being considered for more severe cases where anatomy and disease extension restricts adequate endoscopic visualization of the lesion.

**Methodology/Principal:** The objective of this case report is to highlight a rare pathology of the frontal sinus along with the complications and the current treatment modalities as well.

**Results:** We present a case of a 31-year-old female with mucocoele in a hyperpneumatized left frontal sinus, demonstrating with an unusual lateral expansion and orbit invasion, causing exophthalmos and ophthalmoplegia. She was adequately managed by a Draf III endoscopic procedure achieving wide marsupialization and enough drainage of the mucocoele. No sign of recurrence was noticed during the last 2-month follow-up.

**Conclusions:** Laterally located mucocoeles of the frontal sinus are a rare pathology. To our knowledge endoscopic endonasal approach is a treatment modality that can provide an adequate drainage pathway, thus resulting in a better clinical outcome compared with external approaches.

**Key words:** mucocoele, frontal sinus, orbit, endoscopic drainage, marsupialization.

#### Literature:

1. Arrue P, Kany MT, Serrano E, Lacroix F, Percodani J, Yardeni E, et al. Mucocoeles of the paranasal sinuses: Uncommon location. *J Laryngol Otol* 1998; 112:840-4.
2. Lund VJ. Endoscopic management of paranasal sinus mucocoeles. *J Laryngol Otol* 1998; 112:36-40.
3. Tan CS, Yong VK, Yip LW, Amritj S. An unusual presentation of a giant frontal sinus mucocoele manifesting with a subcutaneous forehead mass. *Ann Acad Med Singapore* 2005; 34:397-8.
4. Terranova et al. Bone Regeneration After Sinonasal Mucocoele Marsupialization: What Really Happens Over Time? *The Laryngoscope* 2015; 125(7):1568-72
5. Lund VJ: Fronto-ethmoidal mucocoeles: A histopathological analysis. *J Laryngol Otol* 105:921,1991

## Nightmare in clinical practice: recognizing rare causes of nasal and gastrointestinal bleeding

**Anasuya Guha<sup>1</sup>**, Jan Matous<sup>2</sup>, Martin Chovanec<sup>1</sup>, Petr Schalek<sup>1</sup>

<sup>1</sup>Department of Otorhinolaryngology, 3rd Faculty of Medicine and University Hospital Kralovske Vinohrady, Charles University in Prague, Czech Republic; <sup>2</sup>2<sup>nd</sup> Department of Internal Medicine, 3rd Faculty of Medicine and University Hospital Kralovske Vinohrady, Charles University in Prague, Czech Republic.

Poster Session, 26 Sept – 30 Sept, 2021, All day

**Aims:** To ascertain conditions that have coexisting risk of nasal and gastrointestinal bleeds.

**Materials and methods:** We performed an extensive literature review of the web-based PubMed database from the National Library of Medicine to determine diseases or syndromes that are rare but can lead to intractable or frequent bleeds. The pathophysiological mechanism, inheritance pattern, genetic mutation, frequency, bleeding risk using WHO criteria were noted for each of these conditions in order to formulate a proposed management plan.

**Results:** Risk of epistaxis with haematemesis or haematochezia are seen in diseases that are usually related to vascular abnormalities or coagulation defects, however most of them have associated genetic mutations.

**Conclusions:** The uncommon nature of these ailments make diagnosis and management difficult. Elaborate tests are not carried out since the two types of bleeds are most frequently managed separately. Furthermore, in the absence of a positive family history or until more specific clinical features appear, rare disorders are not suspected and thus an accurate diagnosis remains undiscovered.

**Key words:** epistaxis, haematemesis, haematochezia, genetic mutation, syndrome

### Literature

1. Yau S An update on epistaxis. Aust Fam Physician 2015;44(9):653–656
2. Rudmik L, Smith TL. Management of intractable spontaneous epistaxis. Am J Rhinol Allergy. 2012;26(1):55–60
3. Guha A, Schalek P, Chovanec M. Syndromes that predispose to epistaxis. Eur Arch Otorhinolaryngol 2019;276:939-944
4. Zhang W, Manda E, Qiu M. Unusual causes of upper gastrointestinal bleeding: Review of Chinese literature. Intractable Rare Dis Res. 2012;1(1):18–22
5. Ghassemi KA, Jensen DM. Lower GI bleeding: epidemiology and management. Curr Gastroenterol Rep. 2013;15(7):333
6. Podda G, Femia EA, Pugliano M et al. Congenital defects of platelet function. Platelets. 2012;23(7):552-563
7. Orsini S, Noris P, Bury L et al. Bleeding risk of surgery and its prevention in patients with inherited platelet disorders. Haematologica 2017; 102 (7): 1192-1203
8. McClurg SW, Carrau R. Endoscopic management of posterior epistaxis: a review. ACTA Otorhinolaryngol Ital 2014;34:1–8
9. Pallin DJ, Chng YM, McKay MP, et al. Epidemiology of epistaxis in US emergency departments, 1992 to 2001. Ann Emerg Med 2005;46:77–81
10. Laine L, Yang H, Chang SC et al. Trends for incidence of hospitalization and death due to GI complications in the United States from 2001 to 2009. Am J Gastroenterol. 2012; 107:1190–5

## Total and Unilateral PNIF and Unilateral VAS: The rationale in Indication and Outcomes of Septoplasty?

**Anasuya Guha<sup>1</sup>**, Petr Schalek<sup>1</sup>

<sup>1</sup>*Department of Otorhinolaryngology, 3rd Faculty of Medicine and University Hospital Kralovske Vinohrady, Charles University in Prague, Czech Republic*

Poster Session, 26 Sept – 30 Sept, 2021, All day

**Aim:** To evaluate the suitability of combination of 2 simple, cheap, and easily performed examinations for indication and outcomes of septoplasty in order to evaluate the effectiveness in this type of surgery.

**Materials and methods:** 70 patients were enrolled from 2 tertiary centers from the period of April 2017 to March 2018, who all underwent septoplasty for nasal septal deviation. Total and unilateral peak nasal inspiratory flow (PNIF), unilateral visual analogue scale (VAS), and nasal endoscopy for indication and outcomes of septoplasty were performed. Furthermore, assessment of possible correlation between subjective and objective data before and 3 months after septoplasty was done. Statistical analysis was carried out on the obtained data.

**Results:** Postoperatively the total and both unilateral PNIF measurements increased significantly compared to the corresponding preoperative values and similarly means of VAS scores on both sides decreased 3 months after surgery.

**Conclusions:** The study confirmed the suitability of using PNIF as a simple and inexpensive tool that can be a reasonable alternative to rhinomanometry. Simultaneously, along with the expected improvement in the total PNIF and unilateral PNIF on deviated side, a slight but significant improvement in PNIF values on the non-deviated side was also demonstrated.

**Key words:** Human, nasal endoscopy, nasal obstruction, nasal septal deviation, quality of life

### Literature:

1. Van Egmond MMHT, Rovers MM, Tillema THJ, et al. Septoplasty for nasal obstruction due to deviated nasal septum in adults: a systematic review. *Rhinology* 2018;56:195–208
2. Haavisto LE, Sipilä JI. Acoustic rhinometry, rhinomanometry and visual analogue scale before and after septal surgery: a prospective 10-year follow-up. *Clin Otolaryngol* 2013;38:23–29
3. Ottaviano G, Scadding GK, Scarpa B, et al. Unilateral peak nasal inspiratory flow, normal values in adult population. *Rhinology* 2012;50:386–392
4. Eren SB, Tugrul S, Dogan R, et al. Objective and subjective evaluation of operation success in patients with nasal septal deviation based on septum type. *Ann J Rhinol* 2014;28:158–162
5. Mondina M, Marro M, Maurice S, et al. Assessment of nasal septoplasty using NOSE and RhinoQoL questionnaires. *Eur Arch Otorhinolaryngol* 2012;269:2189–2195
6. Hsu HC, Tan CD, Chang CW, et al. Evaluation of nasal patency by visual analogue scale/nasal obstruction symptom evaluation questionnaires and anterior active rhinomanometry after septoplasty: a retrospective one-year follow up cohort study. *Clin Otolaryngol* 2016;42:53–59
7. Moore M, Eccles R. Objective evidence for the efficacy of surgical management of deviated septum as a treatment for chronic nasal obstruction: a systematic review. *Clin Otolaryngol* 2011;36:109–113
8. Lodder WL, Leong SC. What are the clinically important outcome measures in the

- surgical management of nasal obstruction? Clin Otolaryngol 2018;43:567–571
9. Sahin C. Evaluation of patient satisfaction after nasal septoplasty operation using Peak Nasal Inspiratory Flow and Nasal Obstruction Symptom Score Questionnaire. J Craniofac Surg 2016;27:1289–1291
  10. Ozkul HM, Balikci HH, Gurdal MM, et al. Normal range of peak nasal inspiratory flow and its role in nasal septal surgery. J Craniofac Surg 2013;24:900–902
  11. Fuller JC, Bernstein CH, Levesque PA, et al. Peak nasal inspiratory flow as an objective measure of nasal obstruction and functional septorhinoplasty outcomes. JAMA Facial Plast Surg 2018;20: 175–176
  12. Tsounis M, Swart KM, Georgalas C, et al. The clinical value of peak nasal inspiratory flow, peak oral inspiratory flow and the nasal patency index. Laryngoscope 2014;124:2665–2669
  13. Dosen LK, Kvinnesland K, TerAngen M, et al. Unilateral and bilateral PNIF in quality control of nasal septal surgery. Int J Otolaryngol 2018;2018:7846843
  14. Klossek JM, Lebreton JP, Delagranda A, et al. PNIF measurement in a healthy French population. A prospective study about 234 patients. Rhinology 2009;47:389–392
  15. Schalek P, Hahn A. Anterior septal deviation and contralateral alar collapse. B-ENT 2011;7:185–188

## The use of 3D printing techniques in developing an anatomical model of the nose

**Mihai Dumitru**<sup>1</sup>, Theodor Badea<sup>2</sup>, Marina Cozma<sup>2</sup>, Daniela Vrinceanu<sup>3</sup>, Maria Mihali<sup>4</sup>, Ileana Rau<sup>4</sup>

<sup>1</sup>Anatomy Department, Carol Davila University of Medicine and Pharmacy, Bucharest, Romania; <sup>2</sup>Carol Davila University of Medicine and Pharmacy, Bucharest, Romania; <sup>3</sup>ENT Department, Bucharest University Emergency Hospital, Bucharest, Romania; <sup>4</sup>The Politehnica University of Bucharest, Bucharest, Romania

Poster Session, 26 Sept – 30 Sept, 2021, All day

**Background:** Currently there are various models of the nasal cavity used for training. New 3D printing techniques are becoming widely available. There are still many aspects that need improvement regarding the use of 3D printers in developing exact anatomical models of the nasal region.

**Methodology/Principal:** We used a commercially available 3D printer with Polylactic Acid (PLA). We analysed raw CT scan acquisitions of 5 patients with both normal and pathology of the nasal cavity. Using open access software, we designed the exact 3D model of each patient.

**Results:** We transformed every slice in the CT scan into a chart for the passage of the 3D printer. Therefore, bony and mucosal landmarks were identified by the printer as positive for PLA deposition and air-filled structures as negative for PLA deposition. We obtained a precise anatomical 3D printed model of normal cases and presenting pathology such as turbinate hypertrophy, polyposis or deviated nasal septum.

**Conclusions:** 3D printed anatomical models of the nasal cavity are cheap, available on a wider scale and could be used for training and surgical planning. From our experience CT acquisitions lower than 256 slices are not suitable for 3D printing an anatomical model of the nasal cavity.

**Key words:** nose, anatomy, model, 3D, printer

#### Literature

1. Hsieh TY, Cervenka B, Dedhia R, Strong EB, Steele T. Assessment of a Patient-Specific, 3-Dimensionally Printed Endoscopic Sinus and Skull Base Surgical Model. *JAMA Otolaryngol Head Neck Surg.* 2018 Jul 1;144(7):574-579. doi: 10.1001/jamaoto.2018.0473.
2. Huang X, Liu Z, Wang X, Li XD, Cheng K, Zhou Y, Jiang XB. A small 3D-printing model of macroadenomas for endoscopic endonasal surgery. *Pituitary.* 2019 Feb;22(1):46-53. doi: 10.1007/s11102-018-0927-x.

## A retrospective descriptive study about biological treatments in CRSwNP patients in Gran Canaria between 2017-2020.

M.S. Domínguez Sosa<sup>1</sup>, M.S. Cabrera Ramírez<sup>1</sup>, M.C. Marrero Ramos<sup>1</sup>, T. Carrillo Díaz<sup>2</sup>, C. Cabrera López<sup>3</sup>.

<sup>1</sup> E.N.T Department, Hospital Universitario de Gran Canaria, Dr. Negrín, Las Palmas de Gran Canaria, Spain.

<sup>2</sup> Allergy Department, Hospital Universitario de Gran Canaria, Dr. Negrín, Las Palmas de Gran Canaria, Spain.

<sup>3</sup> Respiratory Department, Hospital Universitario de Gran Canaria, Dr. Negrín, Las Palmas de Gran Canaria, Spain.

**Background:** Monoclonal antibodies have been proposed as a novel therapy in patients suffering from chronic rhinosinusitis with nasal polyposis (CRSwNP). The purpose of this review was to evaluate their efficacy and safety.

**Methodology:** Descriptive retrospective transversal study between 2017-2020. All patients received baseline nasal endoscopy quantified using nasal polyp score and radiological score, in order to determine the role of biologic therapy on sinonasal symptoms and objective outcomes in chronic rhinosinusitis with nasal polyposis.

77% of the patients have been treated with Mepolizumab, 33% with Omalizumab with an average treatment duration of 11.26 +/- 10.8 months.

**Results:** 61 CRSwNP patients having undergone ESS involving polypectomy were enrolled, 40 (65.6%) women and 21 (34.4%) men, and with a mean age of 54.5 +/- 11.8. The most frequent reason for consultation has been the alteration of smell (26.2%). 95% of patients have asthma as comorbidity and 56% AERD. 52.5% have been reoperated.

Significant improvement in endoscopic staging, clinical symptoms, need for rescue corticosteroids and mainly in SNOT-22. No side effects were found.

**Conclusions:** These treatments have promising results and may prove to be an important adjunct for patients with recalcitrant sinus disease.

**Key words:** Chronic rhinosinusitis, nasal polyposis, biologic agents, anti-IgE, anti-IL-5, omalizumab, mepolizumab, monoclonal antibodies.

## Nasal epithelial cells activated with *Alternaria* and house dust induce not only Th2 but also Th1 immune responses

**Seung-Heon Shin**<sup>1</sup>, Mi-Kyung Ye<sup>1</sup>, Dong-Won Lee MD<sup>1</sup>, Ba-Da Han<sup>1</sup>

<sup>1</sup>*Department of Otolaryngology-Head and Neck Surgery, School of Medicine, Catholic University of Daegu, Daegu, South Korea*

Poster Session, 26 Sept – 30 Sept, 2021, All day

**Background:** Airborne allergens are associated with airway inflammatory disease. Therefore, effects of airborne allergen stimulation in the nasal epithelial cells and their effect on the peripheral blood mononuclear cell (PBMCs) Th immune polarization were investigated.

**Methodology/Principal:** IL-10, IL-25, IL-33, and TSLP levels were determined using the ELISA in nasal polyp tissues. Cultured primary nasal epithelial cells were stimulated with *Alternaria*, *Aspergillus*, *Dermatophagoides pteronyssinus* (DP), and *Dermatophagoides farina* (DF) for 48 h. IL-6, IL-25, IL-33, and TSLP production was measured by ELISA, and NF- $\kappa$ B, AP-1, and MAPK expression were determined by western blot analysis. PBMCs were cultured with nasal epithelial cells conditioned media (NECM), and measured IL-5, IFN- $\gamma$ , and TNF- $\alpha$ . Innate lymphoid type2 cells (ILC2) were analyzed with flowcyotmetry.

**Results:** IL-25, IL-33, and TSLP levels were significantly higher in eosinophilic nasal polyps. *Alternaria*, DP, and DF enhanced IL-33 and TSLP production from the nasal epithelial cells through the NF- $\kappa$ B, AP-1, and MAPK pathway. NECM induced IL-5, IFN- $\gamma$ , and TNF- $\alpha$  production from PBMCs, without increasing the ILC2 expression.

**Conclusions:** *Alternaria* and HDM enhanced the chemical mediator production from nasal epithelial cells, and these allergens may induce not only Th2 inflammatory responses but also Th1 inflammatory responses in the nasal mucosa.

**Key words:** Nasal epithelial cell, *Alternaria*, House dust mite, Immune respons



Grigore Raluca<sup>1,2</sup>, **Bejenaru Paula<sup>1</sup>**, Simion- Antonie Catrinel<sup>1</sup>, Munteanu Gloria<sup>1</sup>, Cîrstea Anca<sup>1</sup>, Taher Bianca<sup>1</sup>, Rujan Andreea<sup>1</sup>, Diaconu Teodora<sup>1</sup>, Nedelcu Ruxandra<sup>1</sup>, Dimcea Alisa<sup>1</sup>, Nitu Liliana<sup>1,2</sup>, Popa Teodora<sup>1</sup>, Condeescu Mihnea<sup>1</sup>, Popescu Bogdan<sup>1,2</sup>, Mitran Denisa<sup>1</sup>, Arjoca Elena<sup>1</sup>, Curcă Claudiu<sup>1</sup>, Othman Amer<sup>1</sup>, Oasa Irina<sup>1</sup>, Sireteanu Luiza<sup>1</sup>, Nicolaescu Alexandru<sup>1</sup>, Berteşteanu Şerban<sup>1,2</sup>,

<sup>1</sup>“Coltea” Clinical Hospital, Bucharest, Romania; <sup>2</sup>“Carol Davila” University of pharmacy and medicine, Bucharest, Romania

Poster Session, 26 Sept – 30 Sept, 2021, All day

**Background.** Meningioma is a benign tumour which develops from arachnoid mater. In spite of the fact that it is a frequent endocranially tumour, in less than 2% of the cases it extends beyond that. In this case implies a multidisciplinary team and considerable risks.

**Methodology/Principal** We present the case of a 67 years old male, known with a cranial meningioma that required multiple surgeries. The evolution of the disease was unfavourable with extra cranial extension.

**Results:** At the moment of admission, he presented left nasal obstruction, seromucous rhinoreea, sight difficulties, frontal ache, left hearing loss. Clinical examination revealed facial asymmetry, postoperative scars, left exophthalmia, left sinus points painfully at palpation, mixed moderate left hearing loss; nasal tumour that occupied the whole left nasal fossa, nasopharynx, with compression over the nasal septum. IRM showed a large tumour 8/9 cm that involved in particular the left optic nerve and internal carotid artery. The surgical treatment will be adapted in case of compression.

**Conclusions:** Although it is a frequent intracranial tumour, with a rare extra cranial development, recurrences rate is very high and it implies a close follow-up. Even a few years miss out from follow-up can transform an operable case into an unfavourable prognosis.

**Key words:** meningioma, benign tumours, recurrences, follow-up

**I. Polymerou**<sup>1</sup>, H.S. Khalil<sup>2</sup><sup>1</sup>ENT Department, Derriford Hospital, Plymouth, UK, <sup>2</sup>Peninsula Medical School, University of Plymouth, UK

Poster Session, 26 Sept – 30 Sept, 2021, All day

**Background:** Research is the lifeline of medical advancement. Every treatment, diagnostic tool and medication in Medicine is a result of research activity.

Clinical research is a partnership between patients, clinicians, healthcare providers and research institutions to enhance patient care and promote health and wellbeing.

Access to Research training helps trainees expand understanding and knowledge of ethics, governance, methodology and good clinical practice.

**Methodology/Principal:** We explored pathways to research training as part of an overall training programme in ENT in a UK setting. This includes a review of websites of mainstream funding bodies, integrated academic training, ENT National Clinical Research Network and Trust Research and Development departments.

**Results:** Research statutory training includes Good Clinical Practice training available face to face and online, attendance of research courses. Formal routes include applying for Academic Clinical Fellow, Academic Clinical Lecturer and less formal research fellow posts. Increasingly, trainees can join national trials as Associate Principle Investigators. Other routes include out of training time for higher degrees (e.g. MD and PhD) and funded fellowship skins by the Royal Colleges and Funding bodies. We discuss challenges related to the above opportunities.

**Conclusions:** Research exposure in training is a very significant element for ENT trainees to progress in their career.

# A single-center, six-year experience in the management of choanal atresia.

Zacharias Kalentakis, Vasileios Chalkiadakis, Theodoros Pantazopoulos, Antonia Arvaniti, Nektarios Papapetropoulos, Sofia Stamataki

*Paediatric Otorhinolaryngology Department, "Agia Sofia" General Children's Hospital, Athens, Greece.*

Poster Session, 26 Sept – 30 Sept, 2021, All day

**Background:** Choanal atresia although rare, is the most common inborn nasal deformity and an important cause of newborn airway obstruction. This study aims to describe a single-center experience in the management of those patients.

**Methodology/Principal:** We retrospectively analyzed the treatment strategy of 18 patients with choanal atresia and their outcomes during the follow-up period.

**Results:** Bilateral choanal atresia was diagnosed in 9 patients, six of those had mixed bony-membranous type (66.6% versus 33.3% who had pure bony type). Almost half of the total cohort had a mixed bony-membranous type of atresia (55,5%). Interestingly, 89% of patients with bilateral atresia underwent transnasal endoscopic repair with stenting, compared to 44% of those with unilateral atresia ( $p=0.04$ ). A trend to preference of stent procedure in patients with bony type was also observed, in comparison with mixed bony-membranous type (89% versus 50%,  $p=0.09$ ). No significant difference in the need for revision treatment was noticed among the two treatment groups.

**Conclusions:** Although stents are more commonly used in revision surgery, both in our data and literature there is no clear supremacy of stenting. Considering the high incidence of re-stenosis, all patients should be under close follow up for a long term period.

**Key words:** choanal atresia, transnasal endoscopic approach, congenital nasal obstruction, re-stenosis, management

## Literature

1. Burrow TA, Saal HM, de Alarcon A, Martin LJ, Cotton RT, Hopkin RJ. Characterization of congenital anomalies in individuals with choanal atresia. *Arch Otolaryngol Head Neck Surg* (2009) 135(6):543–7. doi:10.1001/archoto.2009.53
2. Kim H, Park JH, Chung H, Han DH, Kim DY, Lee CH, et al. Clinical features and surgical outcomes of congenital choanal atresia: factors influencing success from 20-year review in an institute. *Am J Otolaryngol* (2012) 33(3):308–12. doi:10.1016/j.amjoto.2011.08.010
3. Corrales CE, Koltai PJ. Choanal atresia: current concepts and controversies. *Curr Opin Otolaryngol Head Neck Surg* (2009) 17(6):466–70. doi:10.1097/MOO.0b013e328332a4ce
4. Newman JR, Harmon P, Shirley WP, Hill JS, Woolley AL, Wiatrak BJ. Operative management of choanal atresia: a 15-year experience. *JAMA Otolaryngol Head Neck Surg* (2013) 139(1):71–5. doi:10.1001/jamaoto.2013.1111
5. Carter JM, Lawlor C, Guarisco JL. The efficacy of mitomycin and stenting in choanal atresia repair: a 20-year experience. *Int J Pediatr Otorhinolaryngol* (2014) 78(2):307–11. doi:10.1016/j.ijporl.2013.11.031

## Does *Staphylococcus aureus* nasal carriage affect nasal allergic response to house dust mites?

Dionyssia Papadopoulou<sup>1</sup>, **Dimitrios Rachovitsas<sup>1</sup>**, Efthymia Protonotariou<sup>2</sup>, Ioanna Gkeka<sup>2</sup>, Lemonia Skoura<sup>2</sup>, Jannis Constantinidis<sup>1</sup>, Konstantinos Markou<sup>3</sup>

<sup>1</sup>AHEPA University Hospital, 1st Department of Otorhinolaryngology-Head and Neck Surgery, Thessaloniki, Greece <sup>2</sup> AHEPA University Hospital, Department of Microbiology, Thessaloniki, Greece, <sup>3</sup>Papageorgiou General Hospital, Department of Otorhinolaryngology-Head and Neck Surgery, Thessaloniki, Greece

Poster Session, 26 Sept – 30 Sept, 2021, All day

**Background:** Although the link between nasal colonization with *S.aureus* and chronic rhinosinusitis is well documented, its role in allergic rhinitis (AR) is still under investigation. Aim of this prospective study was to determine and compare the prevalence of *S.aureus* nasal carriage in patients with AR to house dust mites (HDM) and to compare it against patients with other sinonasal diseases.

**Materials/methods:** During 2017-2019, 316 adult patients who visited the tertiary Rhinology and Allergic Rhinitis Clinic of AHEPA University Hospital were recruited. Clinical examination including nasal endoscopy and allergic skin prick test was performed. Nasal swab was taken from each patient and sent immediately to the lab.

**Results:** 144 patients were diagnosed with AR to HDM, and the rest 172 had other sinonasal conditions. *S.aureus* was isolated from the nose in 26(18%) patients with AR to house dust mites and in 14(8%) patients of the control group ( $p<0.01$ ).

**Conclusions:** Our preliminary results show that patients with AR to HDM have a statistically significant increased prevalence of nasal colonization with *S.aureus* in comparison with patients with other sinonasal diseases. These results suggest that either AR to HDM leads to colonization with *S.aureus* or/and nasal carriage of *S.aureus* aggravates allergic response to HDM.

**Keywords:** Allergic rhinitis, house dust mites, *Staphylococcus aureus*

## Sinonasal necrosis due to levamisole-induced vasculitis: a great simulator

**Iris Quero-Campos<sup>1</sup>**, Ana C. Ragoni<sup>2</sup>, Alfonso Santamaria-Gadea<sup>1</sup>, Claudio Fragola<sup>1</sup>, Gonzalo Santos-Granados<sup>1</sup>, Luciana E. Real<sup>2</sup>, Franklin Mariño-Santiago<sup>1</sup>.

<sup>1</sup>Rhinology and Skull Base Surgery Unit. Otorhinolaryngology Department. Hospital Universitario Ramón y Cajal, Madrid, Spain. , <sup>2</sup>Otorhinolaryngology Department. Hospital Churruca-Visca, Buenos Aires, Argentina.

Poster Session, 26 Sept – 30 Sept, 2021, All day

**Background:** Levamisole is an anthelmintic drug with mood stimulatory effects which is used as an adulterated compound of 70% of cocaine in the world. This drug can cause a systemic c-ANCA vasculitis. In sinonasal area, it can induce extensive necrosis with skin and mucous involvement.

**Methodology/Principal:** We describe two cases of male patients with midline destructive lesions associated with levamisole-induced vasculitis. Clinical characteristics were very similar to nasal signs and symptoms of a granulomatosis with polyangiitis.

**Results:** Granulomas were observed in the biopsy and malignancy was ruled out. Blood analysis showed positivity for C-ANCA. The CT scan showed septal destruction and signs of severe sinonasal inflammation. Despite both patients firmly denied cocaine nasal use, urine tests were positive. Patients improved with high doses of corticosteroids and cessation of cocaine abuse.

**Conclusions:** levamisole-induced vasculitis may appear as a midline destructive disease of the sinonasal tract. Most diagnostic tests do not allow differentiation of granulomatosis with polyangiitis. A thorough medical history and drug testing are the key for an accurate diagnosis.

*Key words: levamisole, cocaine, granulomatosis diseases, vasculitis, c-ANCA*

#### Literature

1. Berman, M., Paran, D. and Elkayam, O. (2016). Cocaine-induced Vasculitis. *Rambam Maimonides Medical Journal*, 7(4), p.e0036.
2. Desvignes, C., Becquart, C., Launay, D., Terriou, L., Patenotre, P., Deheul, S., Peytavin, G., Dupin, N., Delaporte, E. and Staumont-Sallé, D. (2017). Extensive levamisole-induced vasculitis. *Clinical and Experimental Dermatology*, 42(4), pp.413-415.
3. George, T., Freet, D., Cross, J. and Huzar, T. (2019). Levamisole-induced vasculitis. *Journal of the American Academy of Physician Assistants*, 32(1), pp.23-27.
4. Jin, Q., Kant, S., Alhariri, J. and Geetha, D. (2018). Levamisole adulterated cocaine associated ANCA vasculitis: review of literature and update on pathogenesis. *Journal of Community Hospital Internal Medicine Perspectives*, 8(6), pp.339-344.
5. Lutfy, J., Noland, M. and Jarmuske, M. (2013). How to Spot Cocaine-Induced Pseudovasculitis. *Annals of Plastic Surgery*, p.1.
6. McGrath, M., Isakova, T., Rennke, H., Mottola, A., Laliberte, K. and Niles, J. (2011). Contaminated Cocaine and Antineutrophil Cytoplasmic Antibody-Associated Disease. *Clinical Journal of the American Society of Nephrology*, 6(12), pp.2799-2805.
7. Roberts, J. and Chévez-Barrios, P. (2015). Levamisole-Induced Vasculitis: A Characteristic Cutaneous Vasculitis Associated With Levamisole-Adulterated Cocaine. *Archives of Pathology & Laboratory Medicine*, 139(8), pp.1058-1061.
8. Salehi, M., Morgan, M. and Gabriel, A. (2017). Levamisole-Induced Leukocytoclastic Vasculitis with Negative Serology in a Cocaine User. *American Journal of Case Reports*, 18, pp.641-643.

## Influence of storage temperature for respiratory epithelial samples on ciliary functional analysis

**L. Benchimol**<sup>1</sup>, N. Bricmont<sup>2</sup>, H. Boboli<sup>3</sup>, M.C. Seghaye<sup>4</sup>, R. Louis<sup>2,5</sup>, P.P. Lefebvre<sup>1</sup>, J.F. Papon<sup>6,7,8</sup>, B. Louis<sup>8</sup>, C. Kempeneers<sup>2,3</sup>, A.L. Poirrier<sup>1</sup>

<sup>1</sup>ENT Department, University Hospital of Liege, Belgium; <sup>2</sup>I3 Group, GIGA Research Centre, University of Liege, Belgium; <sup>3</sup>Division of Respiriology, Department of Pediatrics, University Hospital of Liege, Belgium;

<sup>4</sup>Division of Cardiology, Department of Pediatrics, University Hospital of Liege, Belgium; <sup>5</sup>Department of Pneumology, University Hospital of Liege, Belgium; <sup>6</sup>Assistance Publique-Hôpitaux de Paris (AP-HP), ENT Department, Hôpital Bicêtre, Le Kremlin-Bicêtre 94275, France ; <sup>7</sup>Université Paris-Saclay, Faculté de Médecine, Le Kremlin-Bicêtre 94275, France ; <sup>8</sup>Université Paris-Est, Faculté de Médecine, Institut National de la Santé et de la Recherche Médicale (INSERM U955), CNRS ERL7240, Hôpital Henri Mondor, Créteil 94010, France

Poster Session, 26 Sept – 30 Sept, 2021, All day

**Background:** Primary ciliary dyskinesia is characterized by inherited stationary or dyskinetic respiratory cilia. Digital high speed videomicroscopy is highly sensitive and specific for diagnosis but lacks standardization. Particularly, the temperature for samples conservation has never been studied. We aimed to compare ciliary analysis after samples storage at 4°C or 22°C.

**Methodology:** Ciliated epithelial samples were obtained by inferior turbinate brushing from 6 healthy subjects, divided equally and conserved at 4°C or at 22°C. Digital high speed videomicroscopy assessed ciliary beat frequency (CBF) and percentage of normal ciliary beat pattern (CBP) nine hours after sampling.

**Results:** There was no significant difference when samples were stored at 4°C or 22°C. CBF was 14.80 [13.30-16.76] Hz and 15.54 [14.40-18.19] Hz at 4°C and 22°C respectively (Wilcoxon p = 0.3125). Normal CBP was 72.85 [65.83-79.88] % and 80.80 [68.22-82.88] % at 4°C and 22°C respectively (Wilcoxon p = 0.6875).

**Conclusion:** This pilot study suggested that the temperature for respiratory ciliated samples conservation had no effect on ciliary function analysis. Larger studies are needed to confirm these preliminary results, notably in pathological conditions.

**Keywords:** Primary ciliary dyskinesia, Ciliary motility disorder, Diagnosis, Microscopy.

## Chronic invasive fungal rhinosinusitis granulomatous subtype with intracranial extension in immunocompetent patient

Poster Session, 26 Sept – 30 Sept, 2021, All day

**Background:** Chronic invasive fungal rhinosinusitis(CIFRS) is a well described but uncommon type of FRS.

**Methodology/Principal :** We report one case of CIFRS in immunocompetent male patient. 36 years old male patient presented to our clinic with a longstanding history of bilateral nasal obstruction associated with mucopurulent nasal discharge, hyposmia, headache and epiphora. Nasal endoscopy showed inflamed polypoid lesion in the both nasal cavities. The CT scan showed a heterogenous mass in the ethmoid and frontal sinuses causing destruction and expansion of the surrounding bone extending intracranially. Histopathological examination was done and yielded an inverted papilloma. The patient was then booked for functional endoscopic sinus surgery and base of skull surgery in collaboration with the neurosurgeons. Intraoperatively, the tumour was adherent and infiltrating the dura and could not be resected in toto. However, the final histopathological results revealed CIFRS granulomatous type. He was started on antifungal(Voriconazole) for at least 3 months and repeat scan showed no residual tumour.

**Results & conclusion:** CIFRS granulomatous- type is an uncommon disease pathology seen in immunocompetent patient which responds very well to antifungals. An appropriate diagnoses is needed in order to offer the correct treatment.

**Key words:** fungal rhinosinusitis, intracranial extension, Voriconazole, immunocompetent.

**Filipa C. Moreira<sup>1</sup>**, António F. Lima<sup>1</sup>, Daniel A. Miranda<sup>1</sup>

*<sup>1</sup>Department of Otorhinolaryngology and Head and Neck Surgery, Hospital de Braga, University of Minho, School of Medicine, Portugal*

Poster Session, 26 Sept – 30 Sept, 2021, All day

**Background:** Nasal reconstruction presents a challenge and several reconstructive options have been described for nasal ala defects. Successful repair requires attention to aesthetic symmetry but also nasal ala function. This work describes 3 cases of nasal ala defect, with different causes and reconstruction techniques.

**Results:** When planning the surgery, it is important to assess the primary defect on the nasal ala: size and location, depth, involvement of other cosmetic subunits and extension to the alar rim, nasal tip or adjacent cheek. Patient 1 with ala nasal defect resulted from basocellular carcinoma excision was reconstructed with a bilobed flap on a single procedure. Patient 2 full-thickness alar defect due to chainsaw accident was reconstructed using a three-layer reconstruction (free cartilage graft + melolabial flap+ mucosal flap) in two stage procedure. Patient 3 with small congenital nasal rim defect was reconstructed on a single procedure with auricular composite graft.

**Conclusions:** Mastering different techniques is essential for a surgeon to optimise treatment for each patient. Reconstruction should be based on the depth, size and location of the defect. The best choice depends on many factors and should be adapted on a case-by-case basis and to the surgeon's expertise.

**Key words:** nasal ala defect, nasal reconstruction techniques, composite grafts, locoregional flaps



## A Novel Suction Technique for FESS: An Easy and Effective Way of Irrigation under Direct Vision

**Basim Wahba**<sup>1,2</sup>, Anya Selwyn<sup>1</sup>, Alin Popescu<sup>1</sup>, Bertram Fu<sup>1</sup>.

<sup>1</sup>ENT Department, East Kent Hospitals University Foundation Trust, Canterbury, UK. , <sup>2</sup>ENT Department, Faculty of Medicine, Cairo University, Cairo, Egypt.

Poster Session, 26 Sept – 30 Sept, 2021, All day

**Background:** Irrigation of sinuses during Functional Endoscopic Sinus Surgery (FESS) is often useful, especially in clearing clots, mucopus, thick fungal materials, or calcified concretions. Traditional methods often cause smearing of endoscope lens with irrigation fluid, resulting in temporary loss of the endoscopic vision of the operative field. Overspillage of irrigation outside the nasal cavity may also occur due to relatively weak suction provided by a Zoellner sucker that is positioned in the same or contralateral nasal cavity.

We describe a simple and novel method that eliminate the above issues associated with irrigation during FESS.

**Methodology:** The white malleable plastic part of a suction tube tip is directly attached to the contralateral nasal alar rim during irrigation of the sinus. This creates a strong loop of suction which allows all the irrigation fluid to be suctioned to the postnasal space and then the contralateral nasal cavity, allowing one to leave the endoscope in without having to take it out for cleaning.

**Discussion:** There are various FESS irrigation techniques described and commercial intraoperative irrigation products available in the market. These are often of low effectiveness and can associate with additional cost for the procedure. The method we described uses an existing instrument available and allows for effective irrigation of sinuses during FESS. The only limitation we have experienced in a minority of cases is that the method may not be possible in patients with extremely small nasal alar rims.

**Conclusion:** We describe a safe and effective method of FESS irrigation. This technique reduces time for suction and improves operative field visualisation.

Key words: FESS, Suction, Irrigation

**Tetiana Zhulai**<sup>1,3</sup>, Igor Zupanets<sup>1</sup>, Sergii Shebeko<sup>1</sup>, Kateryna Yampolska<sup>2,3</sup>

<sup>1</sup>National University of Pharmacy, Kharkiv, Ukraine, <sup>2</sup>Kharkiv Medical Academy of Post-graduate Education, Kharkiv, Ukraine, <sup>3</sup>Non-profit municipal enterprise «City clinical hospital No 30», Kharkiv, Ukraine

Poster Session, 26 Sept – 30 Sept, 2021, All day

Nasal spray with Enisamium Iodide (EI) can be used to nasal congestion relief in acute rhinosinusitis (RS).

**Aims.** To substantiate EI (nasal spray) 10 mg/mL effectiveness on maxillary sinus ostium via nasal endoscopy (NE) in rabbits with experimental RS (ERS).

**Methods.** As a test object was used EI (nasal spray). As a reference drug, we used BNO-101. ERS was induced in the 1<sup>st</sup> day. On the 1<sup>st</sup>, 15<sup>th</sup> and 25<sup>th</sup> days in all groups (four groups, six rabbits in each group), we used NE and semi-quantitative assessment to the result objectivity.

**Results.** The total score (TS) in the intact control group: 0 (0 ÷ 0) on the 15<sup>th</sup> and 25<sup>th</sup> days (physiological state). TS in the control pathology group: 2.0 (2 ÷ 2) and 1.7 (1 ÷ 2) (severe RS) respectively. TS in EI treated group: 1.7 (1 ÷ 2) (severe RS) and 0.3 (0 ÷ 1) (mild RS). TS in BNO-101 treated group: 1.7 (1 ÷ 2) (severe RS) and 1.0 (1 ÷ 1) (moderate RS).

**Conclusions.** NE can be used as an informative visual method. EI (nasal spray) has been showed a positive effect by endoscopic evaluation of maxillary sinus ostium and exceeded activity of the reference drug.

## Problems at identifying CRS patients eligible for biologicals

**Ivana Tancer<sup>1</sup>**, Natalia Martin<sup>3</sup>, Tanja K Soklic<sup>1,2</sup>, Jure Urbancic<sup>1,2</sup>

<sup>1</sup>University Medical Centre Ljubljana, Department of Otorhinolaryngology and cervicofacial Surgery, Zaloska 2, Ljubljana, Slovenia, <sup>2</sup>University of Ljubljana, Medical faculty, Vrazov trg 2, Ljubljana, Slovenia, <sup>3</sup>Universidad Nacional de Tucuman, Facultad de Medicina, Lamadrid 875, San Miguel de Tucuman, Argentina.

Poster Session, 26 Sept – 30 Sept, 2021, All day

**Background:** New EPOS 2020 diagnostic and treatment protocols have taken new biologic treatment in serious consideration. Five criteria are important in the decision to prescribe biologicals in CRSwNP with prior sinus surgery. Evidence of type 2 inflammation, need for systemic corticosteroids in the past 2 years, significant quality of life impairment, loss of smell and asthma. Currently, five biologicals are being evaluated for treating CRSwNP. Anti Ig-E (Omalizumab), anti IL-5 (Mepolizumab, Reslizumab) and anti IL-4 (Benralizumab, Dupilumab).

**Materials and methods:** We have used our institutional database of patients with CRS to find eligible pathology to start treatment with biologicals. We identified sex, age, phenotype, family history, allergies, asthma, late-onset asthma, tissue eosinophilia, blood eosinophilia, number of oral GCS, number of surgical procedures, patient-reported quality of life questionnaire SNOT-22.

**Results:** We have reviewed 220 patients with CRSwNP and CRSwNP with AERD on their second visit. We found that 48,5% of our patients had asthma. We didn't have data on late onset asthma for 49,5% of the patients, from the remainder 86,7% had late onset. There was insufficient data for tissue eosinophilia in 96,8%. Blood eosinophilia (>150) was present in 80% of our patients. 23% received one or more rounds of oral GCS and 47,5% had at least one surgical procedure.

**Discussion:** The identification of patients for biological treatment may be more difficult than thought. Essentially only patients without controlled disease and adequate therapy can be considered for biologicals.

## Surgical intervention in severe epistaxis - an overlook of our experience and statistics

**Ivana Tancer<sup>1</sup>**, Martin Škrlec<sup>1</sup>, Jure Urbancic<sup>1,2</sup>

<sup>1</sup>University Medical Centre Ljubljana, Department of Otorhinolaryngology and cervicofacial Surgery, Zaloška 2, Ljubljana, Slovenia · <sup>2</sup>University of Ljubljana, Medical faculty, Vrazov trg 2, Ljubljana, Slovenia

Poster Session, 26 Sept – 30 Sept, 2021, All day

**Backgrounds:** Epistaxis is an emergency that we deal with daily in our ENT emergency room. It can be associated with different comorbidities, most commonly arterial hypertension and treatment with anticoagulants. The treatment options are numerous. We usually try to identify the causative vessel and use electrocoagulation to stop the bleeding. Alternatively we also use silver nitrate or trichloro-acetic acid to coagulate the bleeding site. If we cannot identify the causative vessel we use different tamponades, usually Merocel® and Rhinorapid®. In the later case and if we cannot stop the bleeding with nasal tampons we admit the patient to our ward.

**Methods:** We performed a retrospective study that included 143 of our patients admitted to the hospital for epistaxis, 42 of which needed surgical intervention. We looked at their comorbidities, risk factors, severity of the bleed and previous treatment.

**Results:** Most of the patients we had to admit to the hospital had severe nose bleeds and required posterior nasal tamponade with RhinoRapid® with 2 cuffs. 29% of our patients failed to improve after conservative treatment and had to be taken into the operating room. The most frequent surgery was endoscopic sphenopalatine artery ligation.

**Discussion and conclusions:** We found that the most common cause for surgical intervention in epistaxis is severe bleeding despite conservative treatment.

## Relationship between Allergic Rhinitis and Obstructive Sleep Apnea – a cross sectional study: preliminary results in conjunction with oropharynx's dimensions assessment

Angelos Saratsiotis<sup>1</sup>, **George Papacharalampous<sup>1</sup>**, Fotini Gkamari<sup>1</sup>, Dimitrios Davilis<sup>1</sup>, Michail Katotomichelakis<sup>2</sup>

<sup>1</sup>ENT Department, General Hospital "Elpis", Athens, Greece; <sup>2</sup>ENT Department, Democritus University of Thrace, University Hospital, Alexandroupolis, Greece

Poster Session, 26 Sept – 30 Sept, 2021, All day

**Background:** This study investigates the correlation between allergic rhinitis (AR) and obstructive sleep apnea (OSA), taking into account the dimensions of the oropharynx.

**Methodology/Principal:** In this cross-sectional study, the patients are divided into two different groups: A group with allergic rhinitis and a group with non allergic-related nasal breathing problems (control group). Medical history along with detailed ENT examination, skin prick tests for inhaled allergens, Rast test, Eosinophil Count Test of both nasal secretion and serum will be obtained from all participants. Furthermore, all patients will undergo sleep apnea test. Patients will also complete the SNOT-22 and VAS questionnaires, the Epworth scale and the STOP-Bang Questionnaire.

**Results:** A total number of 48 patients were recruited so far and they were classified into two groups, 28 of them with allergic rhinitis and 20 patients with non allergic-related nasal obstruction.

**Conclusions:** A strong correlation between allergic rhinitis and obstructive sleep apnea appears to be justified until now, according to the preliminary data analysis. On the contrary, there is no sufficient data to clearly document the impact of the oropharynx's dimensions to both AR and OSA. This fact could be attributed mainly to the small number of patients recruited so far.

**Key words:** Allergic Rhinitis, Obstructive Sleep Apnea, Oropharynx dimensions

### Literature

1. Asian Pac J Allergy Immunol. 2014 Dec;32(4):276-86. The linkage of allergic rhinitis and obstructive sleep apnea. Chirakalwasan N, Ruxrungtham K.
2. Current Opinion in Allergy and Clinical Immunology 2018 Feb;18(1):16-25. Association between allergic and non allergic rhinitis and obstructive sleep apnea. Zheng M, Wang X, Zhang L.

## TOMOGRAPHIC OVERDIAGNOSIS OF FRONTAL SINUS TUMOURS IN A PREOPERATIVE EXAMINATION OF CHRONIC FRONTAL RHINOSINUSITIS PATIENTS

Kateryna Yampolska<sup>1,3</sup>, Tetiana Pochuieva<sup>1</sup>, Oleksandr Merkulov<sup>1</sup>, Tetiana Zhulai<sup>2,3</sup>

<sup>1</sup>*Kharkiv Medical Academy of Post-graduate Education, Kharkiv, Ukraine*

<sup>2</sup>*National University of Pharmacy, Kharkiv, Ukraine*

<sup>3</sup>*Non-profit municipal enterprise «City clinical hospital No 30», Kharkiv, Ukraine*

Poster Session, 26 Sept – 30 Sept, 2021, All day

To the urgent surgical intervention (SI) planning in the chronic frontal rhinosinusitis (CFRS) with complications, evaluation of all pathological processes by imaging examination (IE) has to be important.

**Aims.** To determine the significance of IE for prevention frontal sinus (FS) tumour over-diagnosis before SI in CFRS with complications.

**Methods.** Nasal endoscopy (NE), spiral-computed tomography (SCT) and magnetic resonance imaging (MRI).

**Results.** The clinical examination (CE) with NE allows us to predict CFRS. SCT demonstrate FS anatomical features and localization of FS integrity disorders. Radiology conclusion is often controversial, which leads the need for differential diagnosis between inflammation and tumour using 1.5T-MRI. MRI-FS-mucocele is characterized by extension to the front of the orbit with T1-weighted images (WI) low signal and T2-WI high signal. MRI-FS-pyocoele will have T1-WI high signal and T2-WI low signal. The DWI mode for mucocele can be variable; therefore, MRI with contrast is used. Signal amplification on T1 C + (Gd) occurs only at the periphery at FS-mucocele and FS-pyocoele, and signal amplification on T1 C + (Gd) is generalized at FS-tumor.

**Conclusions.** CE and NE analysis with a comparison of CT and MRI for CFRS is a prerequisite for correct diagnosis and choosing of surgical intervention.

## Effectiveness of traditional Chinese medicine Shin'iseihaito (Magnolia Flower, Lung-Cleaning Decoction) on postnasal drip

**Hideki Hashimoto<sup>1</sup>**, Takashi Matsuzuka<sup>1</sup>, Shigeyuki Muro<sup>1</sup>

<sup>1</sup>Otolaryngology, Fukushima Medical University, Fukushima, Fukushima, Japan

Poster Session, 26 Sept – 30 Sept, 2021, All day

**Background:** Postnasal drip is one of common symptoms associated with upper respiratory tract disease. Western medicines are mainly used for therapeutic purpose. However, an alternative treatment is expected because postnasal drip is sometimes intractable. We examined the effectiveness of Shin'iseihaito (Magnolia Flower, Lung-Cleaning Decoction), which is one of traditional Chinese medicines, on this symptom.

**Method:** We examined the effect of Shin'iseihaito on postnasal drip in 63 patients based on their subjective symptoms. The mean age was 64 years old, ranging from 24 to 94.

**Results:** Shin'iseihaito was markedly and moderately effective in 38 (60%) and 8 (13%) patients, respectively, while it showed no effect in 17 (27%) patients. There was no apparent difference between responders and non-responders with respect to gender, disease duration and age.

**Conclusion:** This preliminary study showed that Shin'iseihaito was effective in 73% of cases with postnasal drip. This traditional Chinese medicine could be an effective alternative for patients with intractable postnasal drip.

**Key words:** Postnasal drip, Shin'iseihaito, Magnolia Flower, Lung-Cleaning Decoction

## Open vs closed functional rhinoplasty: surgeons' preference and patients' satisfaction

Anna Astreinidou<sup>1</sup>, Vasiliki Florou<sup>1</sup>, **Katerina Marini<sup>1</sup>**, Konstantinos Titelis<sup>1</sup>, Nikolaos Kamargiannis<sup>1</sup>

<sup>1</sup>General Hospital of "G.Gennimatas-St.Demetrios", Thessaloniki, Greece.

Poster Session, 26 Sept – 30 Sept, 2021, All day

**Background:** A worldwide increasing preference towards open rhinoplasties is mentioned. The experience of our ENT Dept in functional rhinoplasties for the last 30 years shows that an approximately 10% of all cases are selected for an open procedure. Moreover, the indications for the choice of endonasal or external approach remain the same during this long period.

**Methodology/Principal:** The last 5 years 541 patients underwent septorhinoplasty and 52 of them, rate 9.6%, had an open procedure. The indications for endonasal surgery were:

- revision rhinoplasty
- severe deformities after trauma or injury
- tip deformities

The Rhinoplasty Health Inventory and Nasal Outcomes (RHINO) scale was used in order to measure the patients' satisfaction, assessing both functional and aesthetic outcome.

**Results:** Improved RHINO score was detected in 95.8%, meaning 514 of the 536 patients that underwent closed rhinoplasty and to 80%, meaning 4 out of the 5 patients with the open procedure.

### Conclusions:

- In our hands closed rhinoplasty works better for most cases
- Specific complications demand an open approach
- Relative indications differ between plastic and ENT surgeons
- Function of the nose is the key to success even in aesthetic surgery

**Key words:** rhinoplasty, closed rhinoplasty, open rhinoplasty, indications

### Literature

1. Foda, H. M. T. (2005). Rhinoplasty for the multiply revised nose. *American Journal of Otolaryngology*, 26(1), 28–34. doi:10.1016/j.amjoto.2004.06.014
2. Cafferty, A., & Becker, D. G. (2016). Open and Closed Rhinoplasty. *Clinics in Plastic Surgery*, 43(1), 17–27. doi:10.1016/j.cps.2015.09.002
3. TEBBETTS, J. (2006). Open and closed rhinoplasty (minus the “versus”): analyzing processes. *Aesthetic Surgery Journal*, 26(4), 456–459. doi:10.1016/j.asj.2006.06.003
4. Harrison, D. H. (2013). Reflections on the open and closed rhinoplasty. *Journal of Plastic, Reconstructive & Aesthetic Surgery*, 66(10), 1356–1359. doi:10.1016/j.bjps.2013.05.041
5. Tasman AJ. Rhinoplasty – indications and techniques. *GMS Curr Top Otorhinolaryngol Head Neck Surg*. 2007;6:Doc09.
6. Lee, M. K., & Most, S. P. (2016). A Comprehensive Quality-of-Life Instrument for Aesthetic and Functional Rhinoplasty. *Plastic and Reconstructive Surgery - Global Open*, 4(2), e611. doi:10.1097/gox.0000000000000592



## Restoration and follow-up of congenital unilateral choanal atresia in an adult patient

Katerina Marini<sup>1</sup>, Vasiliki Florou<sup>1</sup>, Anna Astreinidou<sup>1</sup>, Konstantinos Titelis<sup>1</sup>, Nikolaos Kamargiannis<sup>1</sup>

<sup>1</sup>General Hospital of "G.Gennimatas-St.Demetrios", Thessaloniki, Greece

Poster Session, 26 Sept – 30 Sept, 2021, All day

**Background:** A 24-year-old male patient presented to the ENT outpatient clinic complaining for bilateral nasal obstruction, worse at the right nostril, sleep apnoea, mouth breathing and hyposmia since childhood. Anterior rhinoscopy revealed deviated septum to the left side, while at the right side he had hypertrophy of the inferior nasal turbinate and thick mucopurulent discharge in the inferior meatus. Rigid nasendoscopy and paranasal sinus tomography revealed unilateral right choanal atresia. He had no other anatomical congenital abnormalities.

**Methodology/Principal:** The patient underwent an endoscopic restoration of the atresia, using a 0° rigid endoscope and diamond burr drilling, under general anaesthesia. A silicon stent was placed and stayed for 2 months postoperatively. No mitomycin-C was applied.

**Results:** 3, 6 and 12 months follow-up showed significant improvement of patient's symptoms, while his olfaction was improved. Choana remained patent and noticeably at the 12-month follow-up it widened.

### Conclusions:

- Non-specific symptoms of unilateral choanal atresia could lead to delayed diagnosis or misdiagnosis.
- Each patient with obstructive nasal symptoms should undergo detailed examination of nasal cavity in order to exclude choanal atresia.
- 1 year after surgery nasal mucosa had normal appearance and function.

**Key words:** unilateral, congenital choanal atresia, nasal obstruction, adult, endoscopic repair

### Literature

1. Gulşen, S., Baysal, E., Celenk, F., Aytaç, I., Durucu, C., Kanlikama, M., & Mumbuç, S. (2017). Treatment of Congenital Choanal Atresia via Transnasal Endoscopic Method. *Journal of Craniofacial Surgery*, 28(2), 338–342. doi:10.1097/scs.0000000000003247
2. Wiatrak, B. J. (1998). Unilateral choanal atresia: initial presentation and endoscopic repair. *International Journal of Pediatric Otorhinolaryngology*, 46(1-2), 27–35. doi:10.1016/s0165-5876(98)00119-0
3. Pérez-Calderón, R., Gonzalo Garijo, M. A., Fernández de Alarcón, L., & Mogollón, T. (2001). Unilateral rhinorrhea and nasal obstruction in an adult. *Allergologia et Immunopathologia*, 29(5), 204–206. doi:10.1016/s0301-0546(01)79057-x
4. Wormald, P.-J., Zhao, Y. C., Valdes, C. J., Pacheco, A. E., Ha, T. N., Tewfik, M. A., ... Shaw, C. L. (2016). The endoscopic transseptal approach for choanal atresia repair. *International Forum of Allergy & Rhinology*, 6(6), 654–660. doi:10.1002/alr.21716

202781

Squamous cell carcinoma of the nasal valve: surgery and reconstruction with forehead flap, rib cartilage, bilateral Hadad nasoseptum flap and conchae cartilage graft.

**Maria M. Soriano Reixach**<sup>1</sup>, Jose A. González García<sup>1</sup>, Carlos M. Chiesa Estomba<sup>1</sup>, Carlos Saga Gutierrez<sup>1</sup>, Ekhiñe Larruscain Sarasola<sup>1</sup>, Leire Garcia Iza<sup>1</sup>, Jon A. Sistiaga Suarez<sup>1</sup>

<sup>1</sup>*Department of Otorhinolaryngology, Donostia Hospital, San Sebastian-Donostia, Guipuzcoa, Spain.*

Poster Session, 26 Sept – 30 Sept, 2021, All day

**Background:** nasal reconstruction after an oncological resection is a challenging surgery in order to achieve a good result both aesthetically and functionally.

**Methodology:** left subtotal anterior rhinectomy with forehead flap, bilateral Hadad-Bassagasteguy vascularized nasoseptal pedicled flap, rib cartilage and conchae cartilage stepwise reconstruction.

**Results:** We present a 40-year-old man with a 1-year ulcerative lesion at the left nasal valve with a positive result for squamous cell carcinoma without locoregional or distant extension. In December 2019, a left subtotal anterior rhinectomy was performed associating a reconstructive surgery using a pedicled frontal flap, a Hadad-Bassagasteguy flap and rib cartilage graft as a new septum. After 1 month, a second surgery was done to reconstruct the left nasal ala with a conchae cartilage graft. Eventually, a third surgery was performed in order to open up the nostril and to cut the pedicle of the forehead flap. 7 days after surgery, the aesthetic outcome was acceptable, the forehead flap vital and both nasal cavities were open, showing a moderate anterior nasal perforation with no functional consequences.

**Conclusions:** individualization of the reconstruction technique is needed after a nasal carcinoma excision in order to obtain the best functional and aesthetic results.

Key words: nasal septum, squamous carcinoma, surgical reconstruction

**Surgical management of dural extended frontal sinus squamous cell carcinoma**  
Andreea Rusescu<sup>1</sup>, Cătălina Pietroșanu<sup>1,2</sup>, Viorel Zainea<sup>1,2</sup>, Irina Gabriela Ioniță<sup>1,2</sup>, Ruxandra Oana Aliuș<sup>2</sup>, Raluca Oana Pulpă<sup>1</sup>, Mihai Eugen Catană<sup>2</sup>, Răzvan Hainăroșie<sup>1,2</sup>

<sup>1</sup> "Carol Davila" University of Medicine and Pharmacy, Bucharest, Romania

<sup>2</sup> "Prof. Dr. D. Hociota" Institute of Phonoaudiology and Functional ENT Surgery, Bucharest, Romania

Poster Session, 26 Sept – 30 Sept, 2021, All day

**Background:** Primary squamous cell carcinoma of the frontal sinus is a rare tumor with forms of manifestation and evolution that can often have an overwhelming impact on neighboring structures causing bone destruction and extensions that impact both the frontal bone plate and the dural protection of the frontal lobe and in some cases even infiltrate the frontal brain structure.

**Methodology/Principal:** We want to present the surgical conduct of a case of primary squamous cell carcinoma of the frontal sinus with anterior frontal bone destruction and dural extension but without infiltration of the brain structure.

**Results:** The surgical treatment of this type of tumour was performed through an external approach with the help of a mixed team (neurosurgeon and ENT surgeon), ensuring both the ablation of the tumour and the local defect reconstruction without causing any damage to the frontal lobe structure.

**Conclusions:** Cases of frontal carcinoma with dural extension are a challenge in terms of surgical conduct requiring the collaboration of a team of neurosurgeon and ENT surgeon to ensure optimal control of tumor extension and ablation and to ensure effective and viable coverage of postablative defects

**Keywords:** frontal sinus carcinoma, dural extension, external surgical approach, mixed surgical team

**C.S. Dumitru<sup>1</sup>**, N.C. Balica<sup>1</sup>, P.I. Rata<sup>1</sup>, C.I. Doros<sup>1</sup>

<sup>1</sup>ENT Department, "Victor Babes" University of Medicine and Pharmacy Timisoara

Poster Session, 26 Sept – 30 Sept, 2021, All day

**Background:** These fractures are very common (prominent position, central location, minimum impact resistance); aim: diagnosis and therapeutic management of nasal pyramid trauma (ENT Clinic Timisoara).

**Methodology:** Study (one year) on a group of 81 patients with nasal pyramid fractures, average age - 35 years (11-65 years). Etiology distribution: road accidents-30; aggression-21; accidents at work-12; sport activities-8; height falls-5; domestic accidents-3; same-level falls-2.

Diagnosis: anamnesis, symptomatology, ENT clinical examination and imaging (x-ray, CT).. Treatment: restoring skin lesions; septal hematoma drainage-5; simple reduction-48; lifting depressed segment of nasal bones-16; nasal pyramid repositioning and external fixation 7-8 days; drug treatment (antibiotic, antialgic, hemostatic); surgical treatment-12.

**Results:** Complications: septal hematoma (3), septic abscess (2), nasal synechiae (10), septic necrosis and nose cartilage (1), permanent nasal dysmorphisms by nasal obstruction, septal dislocation (14). Surgical treatment: subpericondo-mucosal septal resections, reposition, septoplastias. Septal correction associated with correction of nasal pyramid by resolution of aesthetic lesions-9.

**Conclusions:** Complete diagnosis and correct treatment of emergency situations - as soon as possible in order to achieve functional, aesthetic prognosis, avoiding further complications.

**Key words:** nasal pyramid fractures, management, complications.

### Literature

1. Brian P. Kelley, B.S., Cara R. Downey, M.D., Samuel Stal, M.D. Evaluation and Reduction of Nasal Trauma. *Semin Plast Surg.* 2010 Nov; 24(4): 339–347.
2. Repanos C, McDonald S E, Sadr A H. A survey of postoperative nasal packing among UK ENT surgeons. *Eur Arch Otorhinolaryngol.* 2009;266:1575–1577.
3. Higuera S, Lee EI, Cole P, Hollier LH Jr, Stal S. Nasal trauma and the deviated nose. *Plast Reconstr Surg.* 2007 Dec;120(7 Suppl 2):64S-75S.
4. Fattahi T, Steinberg B, Fernandes R, Mohan M, Reitter E. Repair of nasal complex fractures and the need for secondary septo-rhinoplasty. *J Oral Maxillofac Surg.* 2006 Dec;64(12):1785-9.
5. C. Coulson, R. De. Management of nasal injuries by UK accident and emergency consultants: a questionnaire survey. *Emerg Med J.* 2006 Jul; 23(7): 523–525.
6. Conforte, J. J., Alves, C. P., Sanchez, M. del P. R., Ponzoni, D. Impact of trauma and surgical treatment on the quality of life of patients with facial fractures. *INTERNATIONAL JOURNAL OF ORAL AND MAXILLOFACIAL SURGERY.* MAY 2016; 10.1016/j.ijom.2015.11.022: 575-581.
7. Wulkan, Marcelo; Parreira Jr, José Gustavo; Botter, Denise Aparecida. Epidemiologia do trauma facial. *Epidemiology of facial trauma. Revista da Associação Médica Brasileira* Volume: 51 Issue: 5 Pages: 290-295 Published: 2005-10.

# The management of maxillary and frontal sinusitis with sinus ultrasonography help

**C.S. Dumitru<sup>1</sup>**, P.I. Rata<sup>1</sup>, N.C. Balica<sup>1</sup>, C.I. Doros<sup>1</sup>

<sup>1</sup>ENT Department, "Victor Babes" University of Medicine and Pharmacy Timisoara

**Background** We present the efficiency of sinus ultrasonography (US) in the diagnosis of maxillary and frontal sinusitis. Image exploration together with anamnesis, endoscopic examination, play an important role in differential diagnosis, therapeutic strategy and post-therapeutic monitoring.

**Methodology** During one year, 163 patients underwent US (major and minor symptoms suggestive signs of maxillary and frontal sinusitis). Sex distribution: male-91 and female-72. Age distribution: 7-15 years (13); 16-25 years (23); 26-35 years (45); 36-45 years old (50); 46-55 years (21); over 56 years (11). Other imaging investigations: sinus x-ray-108 cases and CT-21 cases.

**Results** Normal appearance - 44 (28 adults, 7 children, 9 pregnant women); liquid collections: maxillary sinus - 63 (19 bilateral, 44 unilateral), frontal sinus - 29 (10 bilateral, 19 unilateral); mucosal thickening - 27 (21-maxillary sinus, 6-frontal sinus). The concordance between US and CT/x-ray was 75%.

**Conclusions** The US is fast, non-invasive, cheap and easy. It can be used routinely, representing a stage in the algorithm and management of the current diagnosis of the patient with suspected maxillary and frontal sinusitis.

**Key words:** maxillary and frontal sinusitis, sinus ultrasonography, management

## Literature

1. Varzhapetyan S. D. Feasibility of the maxillary sinus ultrasonic study in patients with iatrogenic sinusitis. 10.14739/2310-1210.2016.2.69238.
2. Tiedjen, KU; Becker, E; Helmann, KD; Knorz, S; Hildmann, H. B-Mode ultrasonography of the paranasal sinuses in comparison to computed tomography. DOI: 10.1055/s-2007-997023.
3. FORBES, WSC; FAWCITT, RA; ISHERWOOD, I; WEBB, R; FARRINGTON, T. COMPUTED TOMOGRAPHY IN DIAGNOSIS OF DISEASES OF PARA-NASAL SINUSES. DOI: 10.1016/S0009-9260(78)80037-3.
4. GIANOLI, GJ; MANN, WJ; MILLER, RH. B-MODE ULTRASONOGRAPHY OF THE PARANASAL SINUSES COMPARED WITH CT FINDINGS. DOI: 10.1177/019459988910700601.1.
5. Lucchin, F; Minicuci, N; Ravasi, MA; Cordella, L; Palu, M; Cetoli, M; Borin, P. Comparison of A-mode ultrasound and computed tomography: Detection of secretion in maxillary and frontal sinuses in ventilated patients. DOI: 10.1007/s001340050249.

## Pterygopalatine and infratemporal fossae: three-dimensional models for better surgical planning

L. Castelhana<sup>1</sup>, F. Raposo<sup>2</sup>, J. Pimentel<sup>1</sup>, L. Reis<sup>1</sup>, D. Silva<sup>1</sup>, P. Escada<sup>1</sup>

<sup>1</sup>Department of Otolaryngology, Hospital de Egas Moniz, Centro Hospitalar Lisboa Ocidental, Lisbon, Portugal,

<sup>2</sup>Department of Neurological Imaging, Hospital de Santa Maria, Centro Hospitalar Lisboa Norte, Lisbon, Portugal

Poster Session, 26 Sept – 30 Sept, 2021, All day

**Background:** The pterygopalatine and infratemporal fossae are complex spaces. Neoplastic and infectious processes can either arise from these areas or spread to them. This project aims to increase the anatomical awareness of the surgeon who addresses these locations.

**Methodology:** A computed-tomography scan of the head of a 36-year-old male with no apparent pathological condition was loaded into ITK-SNAP. Manual segmentation of each fossa was completed by a single operator. The foramen rotundum, Vidian, palatovaginal, greater and lesser palatine canals were also identified. Software tools were used to measure the volume of each fossa as well as the highest diameter on the axial and coronal planes.

**Results:** Three-dimensional models were created. The volume of the pterygopalatine fossa was 1.37 cm<sup>3</sup>, with a maximum width of 21.96 mm and a maximum height of 28.25 mm. These values were much higher for the infratemporal fossa (34.68 cm<sup>3</sup>, 54.2 mm and 59.53 mm, respectively).

**Conclusions:** Three-dimensional models, as opposed to two-dimensional schematics presented by textbooks, have clear learning benefits. The resulting models and measurements may help surgeons approaching these areas.

**Key words:** Pterygopalatine fossa, infratemporal fossa, ITK-SNAP, 3D models

### Literature

Yushkevich PA, et al. User-guided 3D active contour segmentation of anatomical structures: Significantly improved efficiency and reliability. *Neuroimage* 2006 Jul 1;31(3):1116-28

Gibelli D, et al. Anatomy of the pterygopalatine fossa: an innovative metrical assessment based on 3D segmentation on head CT-scan. *Surg Radiol Anat* 2019 May;41(5):523-528

Bannon R, et al. 3D printing the pterygopalatine fossa: a negative space model of a complex structure. *Surg Radiol Anat* 2018 Feb;40(2):185-191

Oakley GM, Harvey RJ. Endoscopic Ressection of Pterygopalatine and Infratemporal Fossa Malinancies. *Otolaryngol Clin North Am* 2017 Apr;50(2):301-313

Derinkuyu BE, et al. Pterygopalatine Fossa: Not a Mystery! *Can Assoc Radiol J* 2017 May;68(2):122-130

Fahmy CE, et al. Volumetric analysis of endoscopic and traditional surgical approaches to the infratemporal fossa. *Laryngoscope* 2014 May;124(5):1960-6

# Prevalence of adenoid hypertrophy in adults. Considerations. A retrospective study on patients over 18 years old with nasal obstruction or conductive hearing loss who underwent routine nasal endoscopy at ENT Department UMHAT Pulmed with a focus on adenoid hypertrophy

**I. Delchev**<sup>1,2</sup>, At. Gyulev<sup>1</sup>, N. Krivorov<sup>1</sup>

<sup>1</sup>ENT Department UMHAT Pulmed, <sup>2</sup>Medical University Plovdiv

Poster Session, 26 Sept – 30 Sept, 2021, All day

**Background:** Pharyngeal tonsil is a mass of lymphoid tissue on the posterosuperior wall of nasopharynx. Pathologically enlarged pharyngeal tonsil or adenoid hypertrophy is a relatively common problem in children in preschool age. It is the most prevalent cause of obstructed nasal breathing in children. Adenoid hypertrophy could also contribute to obstructive sleep apnea or cause Eustachean tube dysfunction and otitis media with effusion. In recent years a higher incidence of abnormal adenoid hypertrophy in adults is observed.

**Methodology/Principal:** All patients with nasal obstruction or conductive hearing loss above the age of 18, admitted at ENT Department UMHAT Pulmed undergo routine nasal endoscopy. Thorough ENT examination and medical history are mandatory with focus on risk factors. CT scans are performed in most cases of nasal obstruction and some cases of conductive hearing loss. Biopsy is only performed when there are suspicions of a neoplasm.

**Results:** Around 43% presence of significant lymphoid mass in the nasopharynx.

**Conclusions:** Adenoid hypertrophy in adults is not an uncommon finding in recent years. Whether this is a result of routine endoscopy of the nose or increase in occurrence due to modern day life is still to be assessed .

**Key words:** Adenoid hypertrophy, Nasal endoscopy, Nasal obstruction, Conductive hearing loss, Adults

## Literature

1. Thimmappa TD, Gangadhara KS. Adenoid hypertrophy in adults. *Int J Otorhinolaryngol Head Neck Surg* 2019;5:412-5.
2. Shetty S, Aroor R, Bhandary SK, Bhat VS, Saldanha M, Alva S. Adult adenoid hypertrophy, is it persistent childhood adenoid hypertrophy?. *Med J DY Patil Univ* 2016;9:216-8.
3. Yildirim N, Sahan M, Karsliglu Y (2008) Adenoid hypertrophy in adults: clinical and morphological characteristics. *J Int Med Res* 36:157–162
4. Manas Ranjan Rout, Diganta Mohanty, Y. Vijaylaxmi, Kamlesh Bobba, Chakradhar Metta Indian Adenoid Hypertrophy in Adults: A case Series *J Otolaryngol Head Neck Surg* (July–Sept 2013) 65(3):269–274
5. J Mitchell, I Pai, L Pitkin, V Moore-Gillon. A case for biopsying all adult adenoidal tissue. *The Internet Journal of Otorhinolaryngology*. 2008 Volume 9 Number 2.

Poster Session, 26 Sept – 30 Sept, 2021, All day

**Background:** Chronic abuse of cocaine can cause a myriad of local and systemic complications. Commonly cocaine is administered via the nasal or oral route, allowing direct contact with mucosal tissues. This causes local vasoconstrictive effects and can lead to ischaemia and necrosis of the tissues and over time, septal and palatal perforation.

**Case Report:** 48 year old female attended with a headache, facial pain, nasal obstruction, and foul odour. The patient has a history of alcohol dependence and cocaine misuse

Clinical examination demonstrated an obvious saddle nose deformity and on anterior rhinoscopy there was copious nasal crusting, which after removal demonstrated complete destruction of the nasal septum and perforation of the anterior hard palate leading to an oro-nasal fistula.

**Investigations:** CT of the sinuses demonstrated destruction of the medial antral sinus walls as well as septal destruction. Biopsy of nasal mucosa identified granulation tissue and chronic inflammatory cell infiltrate with no evidence of dysplasia or malignancy.

**Management and Follow-up :**After regular nasal washouts the symptoms of facial pain and obstruction settled. A cover plate was made for the hard palate to prevent further entry of food into the nasal cavity. No surgical intervention was offered until patient had demonstrated abstinence from cocaine. She is regularly being followed up in outpatient clinic.



## The association of cardiovascular diseases and its risk factors with olfactory dysfunction in Korean middle aged and older adults

**Ji-Hyeon Shin<sup>1</sup>**, Daeyoung Roh<sup>2</sup>

*Department of Otolaryngology-Head and Neck Surgery, College of Medicine, The Catholic University of Korea, Seoul, Korea, <sup>1</sup>Mind-neuromodulation Laboratory and Department of Psychiatry, Chuncheon Sacred Heart Hospital, Hallym University College of Medicine, Chuncheon-si, Gangwon-do, Republic of Korea*

Poster Session, 26 Sept – 30 Sept, 2021, All day

**Background:** Previous studies have reported olfactory dysfunction in relation to cardiovascular disease (CVD). Few population-based studies have investigated such associations differ by sex. The purpose of this study was to examine associations of olfactory dysfunction with CVD and its risk factors and their sex difference in general population.

**Methodology/Principal:** We analyzed for adults aged 40 years and older (n = 20,016) from the 2008-2012 Korean National Health and Nutrition Examination Survey. All subjects reported on their history of olfactory dysfunction. CVD and its risk factors included coronary artery disease, stroke, hypertension, diabetes, obesity, abdominal obesity, and dyslipidemia. Logistic regression was used to analyze associations of olfactory dysfunction and CVD and its risk factors.

**Results:** The overall prevalence of olfactory dysfunction was 6.4%. The prevalence of olfactory dysfunction in males and females was 6.0% and 6.8%, respectively, and there was no significant difference of it between sex groups. After adjustments, in both male and female group, older age group, rhinosinusitis and rhinitis was associated with olfactory dysfunction. In males, CAD had 1.81 times odds of olfactory dysfunction. In females, factors associated with olfactory dysfunction included abdominal obesity and low education level (1.39 times and 1.32 times, respectively). In both males and females, CVD and its risk factors had greater association with olfactory dysfunction than aging, a well-known risk factor of olfactory dysfunction (CAD vs. older age: 1.81 times vs. 1.52 times in male; abdominal obesity vs. older age: 1.38 times vs. 1.32 times in female).

**Conclusion:** In Korean middle-aged and older adults, CVD and its risk factors are associated with olfactory dysfunction. Especially, males with CAD had greater risk of olfactory dysfunction than those without CAD. In females, abdominal obesity was significantly associated with OD. Further studies are needed to reveal the underlying mechanisms of the relationship between olfactory dysfunction and CVD and its risk factors.

# Effects of advanced uvulopalatopharyngoplasty on the results of respiratory polygraphy in patients with low compliance to CPAP therapy

**R. Denysenko<sup>1</sup>**, O. Dikhtiaruk<sup>1</sup>, O. Naumenko<sup>1</sup>

<sup>1</sup>*Department of Otorhinolaryngology, Bogomolets National Medical University, Kyiv, Ukraine*

Poster Session, 26 Sept – 30 Sept, 2021, All day

**Background:** Obstructive sleep apnea (OSA) has become severe problem in the western lifestyle countries. Golden standard for the management of OSA included CPAP therapy. However, it creates significant inconvenience for patient and has low compliance. Surgical treatment is considered as an alternative but still lacks unified approaches and quality scientific data.

**Methodology:** Study involved 47 patients with II stage OSA caused by defects of soft palatine and uvula previously in compliance to CPAP that underwent uvulopalatopharyngoplasty (UPPP) by advanced low traumatic technic. Respiratory polygraphy (RP) was performed before(b) and after(a) operation to estimate the efficacy of procedure. Statistical analysis included max.apnea duration (MAD), max.hypopnea duration (MHD), apnea/hypopnea index (AHI) with median values, difference between the groups was evaluated by Wilcoxon signed-rank test with p-value=0.05.

**Results:** Average age of the patients was 42(SD=12) years (CV=28%), BMI=30,2(SD=2,7) (CV=9%). RP showed median MADb=41 sec, MHDb=39 sec, AH Ib=21,29, MADa=39 sec, MHDa=27 sec, AH Ia=3,71. Advanced low traumatic UPPP led to decrease of all indicators with high statistical significance (p<0,01).

**Conclusions:** Advanced UPPP has shown positive effects on the night respiration and lowers the severity of OSA in patient in compliance to CPAP therapy.

Key words: advanced uvulopalatopharyngoplasty, OSA, respiratory polygraphy

## Literature

- Corral, J., Sánchez-Quiroga, M. Á., Carmona-Bernal, C., Sánchez-Armengol, Á., de la Torre, A. S., Durán-Cantolla, J., ... & Alonso-Alvarez, M. L. (2017). Conventional polysomnography is not necessary for the management of most patients with suspected obstructive sleep apnea. Noninferiority, randomized controlled trial. *American journal of respiratory and critical care medicine*, 196(9), 1181-1190.
- Gurpinar, B., Friedman, M., Senel, G. B., Sayin, S., Boroosan, A., Uyar, Y., & Karadeniz, D. (2020). Impact of Upper Airway Collapse and Sleep Parameters on Daytime Sleepiness and Sleep Quality. *The Journal of craniofacial surgery*.
- Kerşin, B., Karaman, M., Aynacı, E., & Keleş, A. (2019). Investigation of the effectiveness of surgical treatment on respiratory functions in patients with obstructive sleep apnea syndrome. *Masa*, J. F., Corral, J., Pereira, R., Duran-Cantolla, J., Cabello, M., Hernández-Blasco, L., ... & Aizpuru, F. (2011). Therapeutic decision-making for sleep apnea and hypopnea syndrome using home respiratory polygraphy: a large multicentric study. *American journal of respiratory and critical care medicine*, 184(8), 964-971.
- Yin, G., He, M., Cao, X., Xu, J., Zhang, Y., Kang, D., & Ye, J. (2020). Five-year objective and subjective outcomes of velopharyngeal surgery for patients with obstructive sleep apnea. *Otolaryngology–Head and Neck Surgery*, 162(1), 148-154.
- Zhang, J., Li, Y., Cao, X., Xian, J., Tan, J., Dong, J., & Ye, J. (2014). The combination of anatomy and physiology in predicting the outcomes of velopharyngeal surgery. *The Laryngoscope*, 124(7), 1718-1723.

**Spyridon D. Gougousis**<sup>1</sup>, Ioanna Besli<sup>1</sup>, Ioannis Skoumpas<sup>1</sup>, Angelos Nikolaou<sup>1</sup>

<sup>1</sup>ENT Department of G.H. "G. Papanikolaou", Thessaloniki, Greece

Poster Session, 26 Sept – 30 Sept, 2021, All day

**Background:** Sinonasal polyposis represents a chronic inflammatory condition of unknown etiology. It is often associated with systemic diseases and is characterized by nasal obstruction, reduction of smell and infection. In this paper we analyze the results of our surgical techniques in relation to the particular characteristics of our patients, the outcomes of the surgery and the follow up.

**Methodology/Principal:** Review of 108 patients who were submitted to surgical treatment and were followed up within the last 3 years. We analyzed the factors that were considered as a predictor for the outcomes of FESS (age, sex, smoking, presence of asthma, AAS intolerance). The applied tomographic evaluation system was Lund-McKay score and the preoperative nasal endoscopy (Hadley's score). Also, we correlate the outcomes of the surgery with the preoperative and postoperative pharmaceutical treatment.

**Results:** There is no significant difference between the main complaints of the patients evaluated when compared to patients with AAS intolerance or asthma, but the severity of tomographic findings is higher in the last patients. We also confirm in our study that the extend of the disease strongly correlates with worse surgical outcomes.

**Conclusions:** Thorough dissection with mucosa-sparing techniques can successfully eliminate polypoid disease, however in absence of postoperative care and medical management, recurrence is highly likely. The extent of the surgery must be adjusted to the extent of the disease keeping in mind comorbidities of the patient.

**Keywords:** polyps, endoscopic surgery, extend of disease, surgical outcomes, follow-up

#### **Literature:**

1. Kennedy DW, Zinreich SJ, Rosenbaum AE, et al. Functional endoscopic sinus surgery. Theory and diagnostic evaluation. Arch Otolaryngol. 1985;111:576–82.
2. Bhattacharyya N. Influence of polyps on outcomes after endoscopic sinus surgery. Laryngoscope. 2007;117(10):1834–8
3. Rimmer J, Fokkens W, Chong LY, et al. Surgical versus medical interventions for chronic rhinosinusitis with nasal polyps. Cochrane Database Syst Rev. 2014.
4. Alobid I, Benítez P, Bernal-Sprekelsen M, et al. Nasal polyposis and its impact on quality of life: comparison between the effects of medical and surgical treatments. Allergy. 2005;60(4):452–8
5. Friedman M, Bliznikas D, Vidyasagar R, et al. Long-term results after endoscopic sinus surgery involving frontal recess dissection. Laryngoscope. 2006;116(4):573–9
6. Van Zele T, Holtappels G, Gevaert P, et al. Differences in initial immunoprofiles between recurrent and nonrecurrent chronic rhinosinusitis with nasal polyps. Am J Rhinol Allergy. 2014.
7. Kuehnemund M, Lopatin A, Amedee RG, et al. Endonasal sinus surgery: extended versus limited approach. Am J Rhinol. 2002;16(4):187–92.
8. Dalziel K, Stein K, Round A, et al. Endoscopic sinus surgery for the excision of nasal polyps: a systematic review of safety and effectiveness. Am J Rhinol. 2006;20(5):506–19.
9. Mendelsohn D, Jeremic G, Wright ED, et al. Revision rates after endoscopic sinus surgery: a recurrence analysis. Ann Otol Rhinol Laryngol. 2011;120(3):162–6

## Correlation of nasal manifestations with an innovative monoclonal antibody therapy (Rituximab) in patients with microscopic polyangiitis.

Spyridon D. Gougousis<sup>1</sup>, **Ioanna Besli**<sup>1</sup>, Gerasimos Bamichas<sup>2</sup>, Angeliki Cheva<sup>3</sup>, Jannis Constantinidis<sup>4</sup>

<sup>1</sup>ENT Department of G.H. "G.Papanikolaou", Thessaloniki, Greece, <sup>2</sup>Nephrology Department of G.H. "G.Papanikolaou", Thessaloniki, Greece, <sup>3</sup>Medical School, Aristotle University of Thessaloniki, Laboratory of General Pathology & Pathological Anatomy, <sup>4</sup>1st Academic ENT Department, AHEPA Hospital, Medical School and Aristotle University of Thessaloniki

Poster Session, 26 Sept – 30 Sept, 2021, All day

**Background:** Microscopic polyangiitis is a systemic disease that affects initially or later the nose and the paranasal sinuses by occurring many symptoms as nasal discharge, epistaxis, nasal congestion etc. Granulomatous vasculitis cause potentially reversible changes on nasal mucosa.

**Methodology/Principal:** In this present prospective study, that is a precursor of a greater, we want to highlight the role of an innovative monoclonal antibody therapy (Rituximab) in patients with microscopic polyangiitis, concerning nasal symptoms.

10 patients with microscopic polyangiitis participated in the study. They were treated initially with Rituximab according to the usual protocol. We applied endoscopic biopsy of nasal mucosa from the lateral nasal wall and from other suspect areas of the nasal cavity. The samples were sent for histopathological examination. Then, there will be an individualization of the treatment by B cells subpopulations and we will repeat the procedure.

**Results:** An improvement of the symptomatology was observed in 10 patients with microscopic polyangiitis, who were treated with Rituximab. This amelioration is consistent with the symptoms, the endoscopic findings and the histopathological picture.

**Conclusions:** Innovative monoclonal antibody therapy has a multifaceted role in microscopic polyangiitis. The ENT role in the diagnosis and treatment of the disease must be reevaluated in the new era of monoclonal antibody therapies.

**Keywords:** microscopic polyangiitis, monoclonal antibody, treatment, symptoms, endoscopy

### Literature:

1. Holle JU, Dubrau C, Herlyn K, Heller M, Ambrosch P, et al. (2012) Rituximab for refractory granulomatosis with polyangiitis (Wegener's granulomatosis): comparison of efficacy in granulomatosis versus vasculitic manifestations. *Ann Rheum Dis* 71(3): 327-333
- Cannady SB, Batra PS, Koenig C, Koenig C, Lorenz RR, Citardi MJ, et al. (2009) Sinonasal Wegener granulomatosis: a single-institution experience with 120 cases. *Laryngoscope* 119(4): 757-761
- Renaudineau Y, Le Meur Y (2008) Renal involvement in Wegener's granulomatosis. *Clin Rev Allergy Immunol* 35(1-2): 22-2
4. Avani Singla, Paritosh Garg, Nikhil Gupta. Granulomatosis with Polyangiitis of Sinonasal Tract *MOJ Orthopedics & Rheumatology* 2016; Volume 4 Issue 2
5. Tavakolpour S, Alesaeidi S. Rituximab as an effective and probably safe treatment for granulomatosis with polyangiitis (Wegener's Granulomatosis). *Int Immunopharmacol.* 2019 May; 70:67-68.
6. Singer O, McCune WJ. Update on maintenance therapy for granulomatosis with

polyangiitis and microscopic polyangiitis. *Curr Opin Rheumatol*. 2017 May; 29(3): 248-253.

7. Calich AL, Puéchal X, Pugnet G, London J, Terrier B, Charles P, Mouthon L, Guillevin L; French Vasculitis Study Group. Rituximab for induction and maintenance therapy in granulomatosis with polyangiitis (Wegener's). Results of a single-center cohort study on 66 patients. *J Autoimmun*. 2014 May; 50:135-41.
8. No authors listed, Rituximab (MABTHERA) and severe polyangiitis. An option for patients informed of the uncertainties. *Prescrire Int*. 2015 Jun;24(161):145-8.

Two case reports: Nasal findings of vasculitis that don't certificate with the pathological and immunological results. The role of the ENT.

**Ioanna Besli**, Ioannis Skoumpas, Alexandros Poutoglidis, Spyridon D. Gougousis

<sup>1</sup>ENT Department of G.H. "G.Papanikolaou", Thessaloniki, Greece

Poster Session, 26 Sept – 30 Sept, 2021, All day

**Introduction:** The diagnosis of a systemic disease affecting the nasal cavity and the paranasal sinuses is difficult. Various medical specialties should be actively involved in the diagnosis and management, because the current treatment is not familiar to the otolaryngologists.

**Case reports:** A 56-year-old female patient (A) and a 58-year-old male patient (B) were referred to the outpatient with nasal obstruction for over a year. None of the patients had a head injury, nor nasal surgery nor used nasal spray or drugs. In both patients was performed imaging (CT scan) and serological exam [cANCA(-)]. Endoscopically, patient A showed a nearly complete absence of the quadrilateral nasal septum and patient B degeneration of the quadrilateral cartilage and ulcerative lesions in the lateral nasal wall. Nasal mucosa biopsy was performed more than once to both patients: in patient A showed degenerative and inflammatory lesions and ulcers, without necrosis or granulomas, and in patient B inflammation with necrosis and vasculitis.

**Conclusions:** The initial manifestation of a systemic disease can be an effect of the nose and the paranasal sinuses and it is up to the ENT to recognize it, in order to start local and systemic treatment. Even when there are indications, final diagnosis may not support the initial clinical diagnosis and occasionally, becomes positive only after a period of time.

**Keywords:** granulomatous disease, manifestation, paranasal sinuses, final diagnosis

#### Literature:

1. Almouhawis HA, Leao JC, Fedele S, Porter SR. Wegener's granulomatosis: a review of clinical features and an update in diagnosis and treatment. *J Oral Pathol Med.* 2013;42(7):507–16.
2. Avani Singla, Paritosh Garg, Nikhil Gupta. Granulomatosis with Polyangiitis of Sinonasal Tract *MOJ Orthopedics & Rheumatology* 2016; Volume 4 Issue 2
3. Churg J, Strauss L. Allergic granulomatosis, allergic angiitis, and periarteritis nodosa. *Am J Pathol.* 1951;27(2):277–301.
4. Gottschlich S, Ambrosch P, Kramkowski D, et al. Head and neck manifestations of Wegener's granulomatosis. *Rhinology* 2006; 44:227-33.
5. McDonald TJ, DeRemee RA (1993) Head and neck involvement in Wegener's granulomatosis. In: Gross WL (Eds.), ANCA associated systemic vasculitis: immunological and clinical aspects. Plenum Press, New York, USA, pp: 309-313.
6. Rachapalli SM, Kiely PD (2008) Cocaine-induced midline destructive lesions mimicking ENT-limited Wegener's granulomatosis. *Scand J Rheumatol* 37(6): 477-480
7. Sinico RA, Bottero P. Churg-Strauss angiitis. *Best Pract Res Clin Rheumatol.* 2009;23(3):355-66
8. Razmjou AA, Seo YJ, Ayoub MF, Zuckerman J, Patel S. A Case of Granulomatosis with Polyangiitis: Consequences of Delayed Diagnosis in a Life-threatening Malady *Cureus.* 2019 Nov 18;11(11):e6182.

**A. Tsoumaridou<sup>1</sup>**, S. Triantos<sup>1</sup>, M. Nasta, V. Chatzinakis<sup>1</sup>, A. Karelis<sup>1</sup>

<sup>1</sup>Otorhinolaryngology/ Head & Neck Surgery Department, “Korgialenio- Benakio” General Hospital of Athens (Greek Red Cross Hospital), Athens, Greece

Poster Session, 26 Sept – 30 Sept, 2021, All day

**Background:** Isolated sphenoid sinus diseases (ISSDs) are relatively rare. Symptoms, if present, are not specific delaying the diagnosis in many cases. This study aims to review clinical characteristics, imaging findings, differential diagnostic dilemmas and therapeutic approaches of ISSD.

**Methodology/Principal:** Retrospective data of ISSD patients managed in our clinic during the last 10 years were collected (demographic data, symptoms on examination and endoscopic, imaging, intraoperative and histologic findings).

**Results:** 19 patients with isolated sphenoid sinus opacification (13 males- 6 females) aged 30-75 years old were treated in our clinic. The commonest symptom was headache, while nasal obstruction and eye complaints were scarcely mentioned. All cases underwent transnasal endoscopic sphenoidotomy for diagnostic and therapeutic purposes. 4 out of 19 cases (21%) did not reveal pathology after sphenoidotomy despite the preoperative imaging opacification. From the remaining 15 cases, we identified inflammatory and infectious diseases, benign/malignant neoplasms, a mucocele, a fibrous dysplasia and a CSF leak in order of frequency. No postoperative complications were noticed. Revision surgery was performed in 2 cases.

**Conclusions:** Early diagnosis of ISSD can be challenging and demands high clinical suspicion. Imaging studies followed by surgical intervention can confirm the diagnosis and direct the prompt treatment avoiding serious complications.

**Key words:** Sphenoid Sinusitis, Headache Disorders, Secondary, Cranial Nerve Diseases, Endoscopic Surgical Procedure

#### Literature

1. Moss WJ, Finegersh A, Jafari A, Panuganti B, Coffey CS, DeConde A et al. Isolated sphenoid sinus opacifications: a systematic review and meta-analysis. *Int Forum Allergy Rhinol.* 2017 Dec;7(12):1201-1206
2. Fooanant S, Angkurawaranon S, Angkurawaranon C, Roongrotwattanasiri K, Chaiyasate S. Sphenoid Sinus Diseases: A Review of 1,442 Patients. *Int J Otolaryngol.* 2017;2017:9650910
3. Knisely A, Holmes T, Barham H, Sacks R, Harvey R. Isolated sphenoid sinus opacification: A systematic review. *Am J Otolaryngol.* 2017 Mar - Apr;38(2):237-24
4. Grillone GA, Kasznica P. Isolated sphenoid sinus disease. *Otolaryngol Clin North Am.* 2004 Apr;37(2):435-51
5. Ng YH, Sethi DS. Isolated sphenoid sinus disease: differential diagnosis and management. *Curr Opin Otolaryngol Head Neck Surg.* 2011 Feb;19(1):16-20
6. Tang IP, Brand Y, Prepageran N. Evaluation and treatment of isolated sphenoid sinus diseases. *Curr Opin Otolaryngol Head Neck Surg.* 2016 Feb;24(1):43-9

## Symptoms outcomes after endoscopic sinus surgery for chronic rhinosinusitis with and without nasal polyps.

S. Triantos<sup>1</sup>, **A. Tsoumaridou<sup>1</sup>**, E. Exarchou<sup>1</sup>, F. Athanasiadi<sup>1</sup>, D. Lefantzis<sup>1</sup>

<sup>1</sup>Otorhinolaryngology/ Head & Neck Surgery Department, “Korgialenio- Benakio” General Hospital of Athens (Greek Red Cross Hospital), Athens, Greece

**Background:** Studies regarding CRS focus mainly on best practice standards or adherence to guidelines and less on patient-centered outcomes. This study aims to evaluate how functional endoscopic sinus surgery (FESS) can affect symptoms profile at chronic rhinosinusitis with (CRSwNP) and without nasal polyps (CRSsNP).

**Methodology/Principal:** From January 2014 to June 2018, we asked CRSw/sNP patients scheduled for FESS, to complete a questionnaire based on a 10-point visual analogue scale (VAS) before surgery, 6 and 18 months postoperatively. Patients were asked to grade major symptoms (nasal congestion, nasal discharge, postnasal drip, facial pain and smell disturbance). Type of surgery was designed according to preoperative endoscopy and CT scan.

**Results:** From 236 patients initially enrolled, 46 were lost in follow-up and 28 had a revision surgery, both excluded. 162 (92 males, 70 females), aged 28- 66 years old, finally participated. CRSwNP patients (n=118) had a smaller mean VAS (5,94) on major symptoms compared to CRSsNP patients (6,48). Total preoperative VAS (range 4,1-7,8) seemed to improve 6 and 18 months postoperatively up to 44% (1,8-2,8 and 1,8-3,1 respectively).

**Conclusions:** In our study, FESS seemed to improve significantly major nasal symptoms in both CRSwNP and CRSsNP patients.

Key words: Sinusitis, Nasal Polyps, Quality of Life, Endoscopic Surgical Procedure

### Literature

1. Fokkens WJ, Lund VJ, Mullol J, Bachert C, Alobid I, Baroody F et al. EPOS 2012: European position paper on rhinosinusitis and nasal polyps 2012. A summary for otorhinolaryngologists. *Rhinology*. 2012 Mar;50(1):1-12.
2. Soler ZM, Jones R, Le P, Rudmik L, Mattos JL, Nguyen S et al. Sino-Nasal outcome test-22 outcomes after sinus surgery: A systematic review and meta-analysis. *Laryngoscope*. 2018 Mar;128(3):581-592. doi: 10.1002/lary.27008. Epub 2017 Nov 22.
3. Kohli P, Naik AN, Farhood Z, Ong AA, Nguyen SA, Soler ZM, Schlosser RJ. Olfactory Outcomes after Endoscopic Sinus Surgery for Chronic Rhinosinusitis: A Meta-analysis. *Otolaryngol Head Neck Surg*. 2016 Dec;155(6):936-948.
4. Andrews PJ, Poirrier AL, Lund VJ, Choi D. Outcomes in endoscopic sinus surgery: olfaction, nose scale and quality of life in a prospective cohort study. *Clin Otolaryngol*. 2016 Dec;41(6):798-803.



## Association between the *NOS2* pentanucleotide repeat polymorphism and risk of postoperative recurrence of chronic rhinosinusitis with nasal polyps in a Japanese population

**Masanori Kidoguchi**<sup>1,2</sup>, Emiko Noguchi<sup>2</sup>, Shigeharu Fujieda<sup>1</sup>

<sup>1</sup>*Division of Otorhinolaryngology and Head & Neck Surgery, Department of Sensory and Locomotor Medicine, Faculty of Medical Science, University of Fukui, Yoshida-gun, Fukui, Japan,* <sup>2</sup>*Department of Medical Genetics, Faculty of Medicine, University of Tsukuba, Tsukuba-city, Ibaraki, Japan*

Poster Session, 26 Sept – 30 Sept, 2021, All day

**Background:** In airway epithelial cells, nitric oxide (NO) is mainly catalyzed by nitric oxide synthase 2 (NOS2). A pentanucleotide (CCTTT)<sub>n</sub> repeat polymorphism was previously identified in the NOS2 promoter region.

**Methodology:** We investigated the relationship between the NOS2 pentanucleotide repeat polymorphism and its effects on NOS2 expression in the nasal polyps (NP) of patients with chronic rhinosinusitis with nasal polyps (CRSwNP, n=63). Furthermore, we examined the association between the NOS2 pentanucleotide repeat polymorphism and risk of postoperative recurrence of CRSwNP in a multicenter cohort (n=191).

**Results:** NOS2 expression levels in NP gradually increased as the sum of pentanucleotide repeat numbers decreased (P=0.014). Subsequently, we classified the patients according to the NOS2 pentanucleotide repeat polymorphism: short alleles (S) comprise patients with ≤ 11 repeats, whilst long alleles (L) comprise those with > 11 repeats. The patients with the S/S genotype had highest levels of expression among those with the S/S, S/L, and L/L genotypes (P=0.023). In the multicenter cohort, CRSwNP patients with the S/S genotype had a higher risk of postoperative recurrence than did those with the S/L + L/L genotypes (P=0.036).

**Conclusions:** NOS2 pentanucleotide polymorphism may be one of the genetic risk factors for CRSwNP.

**Key words:** NOS2; microsatellite repeats; nasal polyp (NP); chronic rhinosinusitis with nasal polyps (CRSwNP); postoperative recurrence

## Treatment of vasomotor rhinitis with the help of therapeutic and surgical laser. Advantages and disadvantages.

**Maryana B. Cherkes<sup>1,2</sup>**, Khrystyna Ivasivka<sup>3</sup>, Adrian Onutchak<sup>4</sup>

<sup>1</sup>Department of otorhinolaryngology, Lviv City Children's Clinical Hospital, Lviv. Ukraine, <sup>2</sup>Department of clinical Anatomy, Lviv National Medical University, Lviv, Ukraine, <sup>3</sup>Department of otorhinolaryngology, Hospital Charitable Institution them. Metropolitan A. Sheptytsky. Lviv. Ukraine, <sup>4</sup>Department of otorhinolaryngology, Medical Center of doctor Onutchak. Lviv. Ukraine

Poster Session, 26 Sept – 30 Sept, 2021, All day

**Background:** Vasomotor rhinitis is one of the most common Otorhinolaryngological diseases caused by a mechanism of regulation disorders in the nasal cavity. An essential role in the treatment is use of laser. We explore therapeutic laser—a method of physiotherapy and a diode surgical laser.

The **aim** of our study—to find out advantages and disadvantages of patients' treatment with vasomotor rhinitis using a therapeutic and surgical laser.

**Materials and methods:** 50 patients with symptoms of vasomotor rhinitis, divided into 2 groups: group #1 – 30 persons, who received a course of laserotherapy consisting of 10-14 procedures, which was supplemented by nasal lavage and using intranasal corticosteroid spray; group #2—20 persons, who underwent surgery, using a surgical diode laser.

**Results:** out of the 30 patients from group #1, who underwent laserotherapy in 12—complete recovery was observed. In 6 patients—partial difficulty in nasal breathing persisted. In 12 patients, there was no positive effect. From the group #2—out of 20 patients, who were treated using a surgical diode laser in 15 persons—complete recovery was observed. In 5 persons still experienced symptoms of difficulty in nasal breathing. These patients underwent a second laser vasotomy one month after the first intervention and the effect was positive.

**Conclusions :** using a surgical diode laser—the effect was observed in 100% of cases, even if there was a need for reintervention; the method of laserotherapy has a significant place in the treatment of vasomotor rhinitis as an independent treatment method, and in addition to the other surgical interventions on the nasal turbinates. Key words: vasomotor rhinitis, therapeutic laser, diode laser.

203165

## A rare intracranial tumour – Case Report

**Alin Popescu**, Basim Whaba, Anya Selwyn, Bertram Fu

<sup>1</sup>ENT Department, William Harvey Hospital, Ashford, Kent, United Kingdom

Poster Session, 26 Sept – 30 Sept, 2021, All day

**Background:** Whilst very common in other parts of the body intracranial lipomas are extremely rare inside the brain accounting for up to 0.1% of all primary brain tumors. They most commonly affect the corpus callosum and they generally remain asymptomatic.

**Methodology/Principal:** In this report we describe the incidental finding of an intracranial lipoma during routine investigations in a patient presenting with chronic rhinosinusitis symptoms, we discuss the clinical and the radiological findings and we briefly review the existing literature.

**Conclusions:** Lipomas of the brain are rare benign fat containing tumors that can present asymptotically in patients investigated for chronic rhinosinusitis. They are known to generally have good prognosis though this depends on the existence of associated malformations. Surgical treatment is rarely a good idea and these lesions are usually best left alone

Please do not include any citations in the abstract. Avoid specialist abbreviations if possible

Key words: lipoma, brain, incidental finding, benign tumor, chronic rhinosinusitis

## Our first two years of experience with orbital surgery

**Tibor Szalóki**<sup>1</sup>, Katalin Korányi<sup>2</sup>, Bernadett Salomváry<sup>3</sup>, Zoltán Fent<sup>1</sup>, Gábor Forgács<sup>1</sup>, László Tamás<sup>1</sup>

<sup>1</sup>Department of Otorhinolaryngology, Head and Neck Surgery, Semmelweis University, Budapest, Hungary,

<sup>2</sup>Department of Ophthalmology, Semmelweis University, Budapest, Hungary, <sup>3</sup>National Institute of Clinical Neurosciences, Ophthalmology, Budapest, Hungary

Poster Session, 26 Sept – 30 Sept, 2021, All day

**Background:** The orbit is a multidisciplinary surgical field. Due to this fact, we have an orbital-team in our institute since 2018.

**Methodology/Principal:** We would like to present our orbital surgical cases, operated between 2018-2020.

**Results:** We had 50 cases in the last two years. We have done 24 balanced decompressions in 16 patients, bilateral optic nerve decompression in two patients 23 tumour surgeries and 9 vascular malformation removals. 23 surgeries were performed either through transnasal endoscopic way or by combined approach. 27 laesions needed external approach, 90% of them were removed via lateral orbitotomy

**Conclusions:** However the orbit is a relatively small anatomical space, we think, multidisciplinary is the only way to treat it's pathologies.

Key words: orbital surgery, cavernous hemangioma, balanced decompression, tumour removal, vision loss

# Transnasal-transpterygoid endoscopic removal of an $^{18}\text{F}$ -choline-avid parathyroid carcinoma metastasis in the skull base - a case report

Grégoire Morand<sup>1,5</sup>, **Seraina Kunz**<sup>1,5</sup>, Niels J. Rupp<sup>2,5</sup>, Martin W. Huellner<sup>3,5</sup>, Philipp A. Gerber<sup>4,5</sup>, Michael B. Soyka<sup>1,5</sup>, Martina A. Broglie<sup>1,5</sup>, David Holzmann<sup>1,5</sup>

<sup>1</sup>Department of Otorhinolaryngology, Head and Neck Surgery, University Hospital Zurich, Zurich, Switzerland, <sup>2</sup>Institute of Pathology and Molecular Pathology, University Hospital Zurich, Zurich, Switzerland, <sup>3</sup>Department of Nuclear Medicine, University Hospital Zurich, Zurich, Switzerland, <sup>4</sup>Department of Endocrinology, Diabetology and Clinical Nutrition, University Hospital Zurich, Zurich, Switzerland, <sup>5</sup>University of Zurich, Zurich, Switzerland

Poster Session, 26 Sept – 30 Sept, 2021, All day

**Background:** Parathyroid carcinoma is a rare endocrine malignant neoplasm, accounting for <1% of cases of primary hyperparathyroidism. Clinical features are primarily owing to the excessive secretion of parathyroid hormone (PTH). This case report presents findings of a patient who was diagnosed with a choline-avid metastasis of parathyroid carcinoma in the skull base six years after left inferior parathyroidectomy.

**Methodology/Principal:** The case of a patient with a solitary  $^{18}\text{F}$ -choline-avid parathyroid carcinoma metastasis located in the lateral skull base is presented.

**Results:** The patient discussed herein presented with recurrent hypercalcemia, which was rapidly progressing, such that medical therapy with cinacalcet became necessary. PTH levels reached 483 ng/L. Six years before, she was treated for an atypical, parathyroid adenoma. After discussion at the local multidisciplinary tumor board, an  $^{18}\text{F}$ -choline-PET with magnetic resonance imaging was recommended. An intensely choline-avid intraosseous nodule in the contralateral skull base was revealed. After transnasal-transpterygoid endoscopic removal, pathologic examination revealed an atypical parathyroid neoplasm. PTH levels decreased to 43.6 ng/L postoperatively.

**Conclusions:** This case confirms that at least a subset of parathyroid carcinomas is  $^{18}\text{F}$ -choline-positive, even when spreading to distant sites.  $^{18}\text{F}$ -choline-PET can guide involved specialists to perform selective metastasectomy to control hypercalcemia.

**Key words:** Choline, Hypercalcemia; Hyperparathyroidism, Parathyroid neoplasm, Positron emission tomography computed tomography

## Literature

1. Morand GB, Helmchen BM, Steinert HC, Schmid C, BroglieMA.  $^{18}\text{F}$ -Choline-PET in parathyroid carcinoma. Oral Oncol. 2018;86: 314-315. doi:10.1016/j.oraloncology.2018.09.009
2. Huber GF, Hüllner M, Schmid C, et al. Benefit of  $^{18}\text{F}$ -fluorocholinePET imaging in parathyroid surgery. Eur Radiol. 2018;28(6):2700-2707. doi:10.1007/s00330-017-5190-4
3. Deandreis D, Terroir M, AlGhuzlan A, et al.  $^{18}\text{F}$ -fluorocholinePET/CT in parathyroid carcinoma: a new tool for disease staging? Eur J Nucl Med Mol Imaging. 2015;42(12):1941-1942. doi:10.1007/s00259-015-3130-6

**Thiresia Kefalogianni**<sup>1</sup>, Eleni Chalkiadaki<sup>1</sup>, Georgia Malaxianaki<sup>2</sup>, Maria Kokkinaki<sup>2</sup>, Androniki Kozana<sup>2</sup>

<sup>1</sup>Otolaryngology, Head and Neck Surgery department of General Hospital of Heraklion "Venizeleio", Crete, Greece, <sup>2</sup>Diagnostic Imaging department of General Hospital of Heraklion "Venizeleio", Crete, Greece

Poster Session, 26 Sept – 30 Sept, 2021, All day

**Background:** The purpose of this retrospective pictorial review is to demonstrate the evolving, age-related anatomy of the paranasal sinuses in children through CT imaging. Sinonasal anatomy differs significantly between adult and pediatric populations. It is of paramount importance to understand the development of the nasal cavity and paranasal sinuses in pediatric populations in order to evaluate sinonasal disease and its complications. Revision of anatomy and its correlation with imaging findings are a prerequisite in everyday clinical practice.

**Methodology/Principal:** A retrospective study of our hospital's Computed Tomography database was performed.

Over a 3-year period we retrieved all 437 brain and paranasal sinuses CT examinations of patients younger than 16 years-old. Both normal and abnormal CT scans were included.

Multiplanar CT reconstructions and CT image volume rendering were applied to illustrate the different stages of sinonasal development, landmarks of exquisite anatomical importance as well as anatomical variations.

**Conclusions:** This pictorial review aims to illustrate the different age-associated sinonasal developmental stages in children. High quality imaging is essential for clinical assessment and to serve as a roadmap for surgical planning.

Keywords: sinonasal growth and development, anatomy, imaging, paediatric

#### Literature

1. Lund VJ, Stammberger H, Fokkens WJ et al. European position paper on the anatomical terminology of the internal nose and paranasal sinuses. *Rhinol Suppl.* 2014;24:1–34
2. Expert Panel on Pediatric Imaging: Tekes A, Palasis S et al. ACR Appropriateness Criteria® Sinusitis-Child. *J Am Coll Radiol.* 2018;15(11S):S403–S412. doi:10.1016/j.jacr.2018.09.029
3. Scuderi AJ, Harnsberger HR, Boyer RS. Pneumatization of the paranasal sinuses: normal features of importance to the accurate interpretation of CT scans and MR images. *AJR Am J Roentgenol.* 1993;160(5):1101–1104. doi:10.2214/ajr.160.5.8470585
4. Wolf G, Anderhuber W, Kuhn F. Development of the paranasal sinuses in children: implications for paranasal sinus surgery. *Ann Otol Rhinol Laryngol.* 1993;102(9):705–711. doi:10.1177/000348949310200911
5. Adibelli ZH, Songu M, Adibelli H. Paranasal sinus development in children: A magnetic resonance imaging analysis. *Am J Rhinol Allergy.* 2011;25(1):30–35. doi:10.2500/ajra.2011.25.3552
6. Shah RK, Dhingra JK, Carter BL et al. Paranasal sinus development: a radiographic study. *Laryngoscope.* 2003;113(2):205–209. doi:10.1097/00005537-200302000-00002
7. Kuntzler S and Jankowski R. L'arrêt de pneumatisation: Un témoin de la formation des sinus

paranasaux?. Annales françaises d'Oto-rhino-laryngologie et de Pathologie Cervico-faciale. 2014; 131. 152–156. 10.1016/j.aforl.2014.01.016.

8. Sakandar G, Haron J, Mohamad A et al. Adult and Pediatric Lateral Lamella Cribriform Plate Height: In Need for a Comparative Study. Allergy Rhinol (Providence). 2019;10:2152656719874775. Published 2019 Sep 9. doi:10.1177/2152656719874775

9. Cohen O, Adi M, Shapira-Galitz Y et al. Anatomic variations of the paranasal sinuses in the general pediatric population. Rhinology. 2019;57(3):206–212. doi:10.4193/Rhin18.193

10. Sánchez Fernández JM, Anta Escuredo JA, Sánchez Del Rey A et al. Morphometric study of the paranasal sinuses in normal and pathological conditions. Acta Otolaryngol. 2000;120(2):273–278. doi:10.1080/000164800750001080

11. Sivasli E, Sirikçi A, Bayazıt YA et al. Anatomic variations of the paranasal sinus area in pediatric patients with chronic sinusitis. Surg Radiol Anat. 2003;24(6):400–405. doi:10.1007/s00276-002-0074-x

12. Kim HJ, Jung Cho M, Lee JW et al. The relationship between anatomic variations of paranasal sinuses and chronic sinusitis in children. Acta Otolaryngol. 2006;126(10):1067–1072. doi:10.1080/00016480600606681

# Angioleiomyoma of nasal septum: Case report of a rare benign tumor.

G.P. Kotsis<sup>1</sup>, **A. Tsoumaridou<sup>2</sup>**, G. Kokolakis<sup>1</sup>, A.C. Sakellaris<sup>1</sup>, M.G. Lenos<sup>3</sup>

<sup>1</sup>Otorhinolaryngology/ Head & Neck Surgery Department, "Saint Savvas" General Anti-Cancer and Oncological Hospital of Athens, Athens, Greece, <sup>2</sup>Otorhinolaryngology/ Head & Neck Surgery Department, "Korgialenio-Benakio" General Hospital of Athens (Greek Red Cross Hospital), Athens, <sup>3</sup>Pathology Department, "Saint Savvas" General Anti-Cancer and Oncological Hospital of Athens, Athens, Greece

Poster Session, 26 Sept – 30 Sept, 2021, All day

**Background:** Angioleiomyomas (ALMs) are benign, slow growing tumors arising from vascular smooth muscle cells. They are usually found in uterus, skin of lower extremities and gastrointestinal tract. ALMs of sinonasal tract are rare (<1%). To our knowledge, there are less than 60 cases reported in literature. Nasal septum, specifically, is amongst the less common sites of origin.

**Methodology/Principal:** We review the case of a 71-year-old woman, who presented to our clinic complaining of nasal obstruction, commencing two years ago, and recent episodic epistaxis. Endoscopy revealed a reddish, well circumscribed, wide-based mass, with uneven surface, rising from the mucosa of anterior nasal septum. The mass was painless and smooth on indirect palpation. Patient underwent en bloc excision of the tumor under general anesthesia. No relation with the underlying cartilage was found intraoperatively.

**Results:** Histopathologic examination identified the presence of ALM, excised on negative margins. Two months later, patient is disease free. Next follow-up examination is scheduled on 6 months postoperatively.

**Conclusions:** Sinonasal ALMs are rare tumors, with no specific clinical, endoscopic or imaging characteristics. Diagnosis is based on histopathologic examination. When surgical resection is complete, malignant transformation or recurrence are seldom reported. Further studies are needed to confirm sex hormones significance on ALMs growth.

**Key words:** Angioleiomyoma, Unilateral Nasal Obstruction, Epistaxis, Nasal Neoplasm Literature

1. Ho CH, Lin HC, Chou CC, Huang HY. Sinonasal Angioleiomyoma. Ear Nose Throat J. 2019 Jul 4;145561319858913
2. Agaimy A, Michal M, Thompson LD, Michal M. Angioleiomyoma of the Sinonasal Tract: Analysis of 16 Cases and Review of the Literature. Head Neck Pathol. 2015 Dec;9(4):463-73
3. Varadarajan VV, Justice JM. Angioleiomyoma of nasal septum: Case report and literature review. Otolaryngology Case Reports. 2016; 1. 1-4
4. Lau YW, Vikneswaran T, Tan TY, Tang IP. Sinonasal angioleiomyoma. Med J Malaysia. 2016 Jun;71(3):154-5
5. Chen HH, Wang QY, Zhou SH. Transnasal endoscopic resection of vascular leiomyomas of the nasal septum. J Can Res Ther 2016;12:109-111
6. Ardekian L, Samet N, Talmi YP, Roth Y, Bendet E, Kronenberg J. Vascular leiomyoma of the nasal septum. Otolaryngol Head Neck Surg. 1996 Jun;114(6):798-800
7. Navarro Júnior CR, Fonseca AS, Mattos JR, Andrade NA. Angioleiomyoma of the nasal septum. Braz J Otorhinolaryngol. 2010 Sep-Oct;76(5):675
8. Zhu G, Xiao D, Sun P. Expression of estrogen and progesterone receptors in angioleiomyoma of the nasal cavity of six patients. Oncol Lett. 2016 Apr;11(4):2359-2364



## Frontal sinus obliteration with Bioactive Glass, our experience.

**Elisabeth R. Ninchritz-Becerra<sup>1</sup>**; Leire García-Iza<sup>1</sup>; María M. Soriano-Reixach<sup>1</sup>; Aitor Vargas-Alvarez<sup>1</sup>; Carlos Saga-Gutierrez<sup>1</sup>; Xabier Altuna-Mariezcurrana<sup>1</sup>.

<sup>1</sup>*Department of Otorhinolaryngology, Head and Neck Surgery, Hospital Universitario Donostia, San Sebastián, Spain.*

Poster Session, 26 Sept – 30 Sept, 2021, All day

**Background:** Despite advances in endoscopic sinus surgery, frontal sinus obliteration is still indicated. Autologous and synthetic materials could be used. Bioactive Glass S53P4 is a synthetic material that has the ability to stimulate bone formation and restore anatomical structures with the advantage of an antibacterial activity.

**Methods:** We did a retrospective review of five cases who underwent frontal sinus obliteration with Bioactive Glass at our tertiary center. Medical records were obtained. All of them were diagnosed of post-trauma frontal mucocele.

**Results:** In all the cases we did a combined supraciliary and endoscopic endonasal approach with frontal sinus obliteration with the Bioactive Glass. Compared to the sinus obliteration with fat, we observed a reduce in the surgical times. Two of the three cases had previously fractures of the posterior frontal sinus wall with cerebrospinal fluid leakage. Postoperatively, one patient had a scar infection with conservative resolution. One of the patients, could have a persistent dehiscence in the anterior wall with skin fluctuation during Valsalva maneuver. All of them reported a good cosmetic result and symptoms improvement.

**Conclusions:** Bioactive Glass S53P4 seems to be a good and safe material for frontal sinus surgery, with results comparable to other synthetic materials. The best material remains controversial.

Key words: frontal sinus, mucocele, sinus obliteration, bioactive glass.

## Surgical treatment of Rhinogenic Headache

**Athanasia Marinou**<sup>1</sup>, Sotirios Papouliakos<sup>1</sup>, Anastasia Liapi<sup>1</sup>, Panagiotis Fanaras<sup>1</sup>, Argiro Levendi<sup>1</sup>, Evangelia Zacharioudaki<sup>1</sup>

<sup>1</sup>ENT Department General Hospital of Athens 'Georgios Gennimatas', Athens, Greece

Poster Session, 26 Sept – 30 Sept, 2021, All day

**Background :** Headache is a common symptom that forces many people to seek medical help. Rhinogenic contact point headache (RCPH) is characterized as intermittent pain localized to periorbital or medial canthal and the existence of intranasal mucosal contact points due to intranasal anatomic variations. The aim of our study is to evaluate the outcomes of surgical treatments of patients with headaches and intranasal contact points.

**Methodology :** 28 patients enrolled to our study. All patients fulfilled the criteria for RCPH and preoperative diagnosis was made with nasal endoscopy and CT scan. 10 patients were diagnosed with septal spur (SS), 5 with concha bullosa (CB) and 13 with septal deviation (SD). Pain was evaluated with Visual Analog Scale preoperatively and 3 months postoperatively.

**Results:** The intensity of pain was higher in patients with SS (mean 8,4), followed by patients with CB (mean 7,4) and SD (mean 7,23). All patients reported an improvement in severity of pain postoperatively. The group which benefits most was patients with SS with postoperative VAS pain score mean 2,2 (p = 0,001)

**Conclusion:** Although RCPH is under dispute by many authors, according to our results surgical treatment in selected cases with septal spur has encouraging results in the relief of pain.

## Combined intranasal and transoral removal of odontogenic cyst in a Greek tertiary hospital

**Athanasia Marinou<sup>1</sup>**, Anastasia Liapi<sup>1</sup>, Dimitrios Anterriotis<sup>2</sup>, Sotirios Papouliakos<sup>1</sup>, Panagiotis Zavras<sup>1</sup>, Evangelia Zacharioudaki<sup>1</sup>

<sup>1</sup>ENT Department, General Hospital of Athens 'Georgios Gennimatas', Athens, Greece, <sup>2</sup>Maxillofacial Department, General Hospital of Athens 'Georgios Gennimatas', Athens, Greece

Poster Session, 26 Sept – 30 Sept, 2021, All day

**Background:** odontogenic cysts are common and usually benign lesions. However they can be locally aggressive and expand to the maxillary sinus. The traditional transoral surgical approach carries the disadvantage of inadequate exposure of the medial aspect of the lesion. On the other hand, the endoscopic transnasal approach is associated with the risk of incomplete removal. The aim of our study is to evaluate the efficacy of combined intra-oral and trans-nasal approach in patients with odontogenic cysts arising in the maxillary sinus.

**Methodology:** We enrolled sixteen (16) patients who underwent a combined- approach excision of the cyst between 2017 and 2019. Patients with chronic rhinosinusitis were excluded from the study. The preoperative work-up included maxillofacial examination, nasendoscopy and a sinus CT scan. The operations were all performed by ENT and Maxillofacial surgeons. Postoperative scans were obtained at three months. The scans were reviewed and the radiological Lund\_Mackay score was determined pre- and postoperative.

**Results:** We achieved complete removal of the cyst in all cases. Postoperative Lund\_Mackey score was significantly reduced in all cases ( $p=0,001$ ).

**Conclusion:** Collaboration of Otolaryngologists and Maxillofacial surgeons is recommended for adequate removal of odontogenic cysts whose exposure would have been technically difficult with a one-way approach.

203228

## Differential expression profiles between patients with chronic rhinosinusitis with nasal polyps treated with sensitive and drug-resistant intranasal corticosteroids - Preliminary results

**López-Chacón M<sup>1,2,3</sup>**, Alobid I<sup>1,2,3</sup>, Fuentes-Prado M<sup>2,3</sup>, Pujols L<sup>2,3</sup>, Mullol J<sup>1,2,3</sup>.

*Rhinology Unit and Smell Clinic, ENT Department, Hospital Clínic I Universitari, Institut d'Investigacions Biomèdiques August Pi i Sunyer (IDIBAPS), Centro de Investigación Biomédica en Red de Enfermedades Respiratorias (CIBERES), Barcelona, Catalonia, Spain*

Poster Session, 26 Sept – 30 Sept, 2021, All day

**Background:** To identify differential expression profiles between sensitive (S) and drug-resistant (R) patients with chronic-rhinosinusitis-with-nasal-polyps (CRSwNP) treated with intranasal-corticosteroids. To determine differently expressed pathways between both groups.

**Methodology:** Sixty-patients diagnosed with CRSwNP treated with intranasal-corticosteroids were evaluated at the time of inclusion and at three and six-months. After evaluations, four-patients with the worst response (R) and four-patients with the best response to treatment (S) were selected and a sample of nasal polyp was obtained. RNA-Seq sequencing and transcriptome analysis of the samples were performed.

**Results:** Two biostatistical packages were used for the analysis of RNA-Seq sequencing. After normalization, a PCA revealed that the first and second components explained 83% of the variability observed between samples. A clear division was observed in the unguided clustering between R and S-patients.

Readings were obtained for 19,891-genes. After DESeq2 and edgeR analyzes, 2,081 differentially expressed genes were identified (p-adj value<0.05). An enrichment analysis using GO-terms, KEGG and Reactome pathways identified several differentially expressed pathways.

**Conclusion:** Our results show a differential expression profile between S and R-patients. Differentially expressed relevant pathways were identified between both groups, suggesting the need to develop specific biomarkers and personalized therapeutics for the treatment of CRSwNP patients.

**Key words:** Chronic rhinosinusitis , gene expression profiles, transcriptome, response to treatment, nasal polyps.

## Nasal Septal Perforation: A Rare Complication after Balloon Nasal Packing

**Basim Wahba**<sup>1,2</sup>, Omar Ahmed<sup>1</sup>, Anya Selwyn<sup>1</sup>, Alin Popescu<sup>1</sup>, Bertram Fu<sup>1</sup>.

<sup>1</sup>ENT Department, East Kent Hospitals University Foundation Trust, Canterbury, UK. , <sup>2</sup>ENT Department, Faculty of Medicine, Cairo University, Cairo, Egypt.

Poster Session, 26 Sept – 30 Sept, 2021, All day

**Background:** Balloon nasal packing is used very commonly in the management of epistaxis. However, and despite its benefits, it could cause injury to the nasal mucosa and rarely may cause cartilage necrosis. Rare complications such as alar cartilage necrosis, septal cartilage necrosis and even cerebrospinal fluid rhinorrhea has been reported in literature.

**Methodology/Principal:** We describe a case which had a history of septoplasty then two years later had a turbinoplasty surgery which required balloon nasal packing postoperatively. Post-operative follow up revealed a huge septal perforation due to pressure necrosis by the cuffed balloon nasal pack.

**Conclusions:** Localization of the site of bleeding is recommended as the primary line of treatment and this is to be managed with cauterisation. This will reduce mucosal injury associated with nasal packing. If nasal packing is to be used, a gradual increase in cuff pressure until bleeding stops is recommended. Monitoring the cuff pressure is helpful and examination after deflation is important to assess and document nasal mucosa or septal cartilage injury.

Key words: Septal perforation – Balloon nasal packing

# CHARACTERISTICS OF CEREBROSPINAL FLUID RHINORRHEA FOLLOWING SEPTOPLASTY – REVIEW OF THE LITERATURE

**Konstatina Chrysouli<sup>1</sup>** , Vasileios Papanikolaou<sup>1</sup> , Euthimios Kyrodimos<sup>1</sup> , Aristeidis Chrysovergis<sup>1</sup>

<sup>1</sup>National & Kapodistrian University of Athens, 1st Department of Otorhinolaryngology - Head & Neck Surgery, Athens , Greece

**Background:** Cerebrospinal fluid rhinorrhea is a rare complication of septoplasty.

Its known cause is due to faulty surgical techniques in deviation of the perpendicular plate of ethmoid bone, which causes injury in lateral lamella .Injuries to the cribriform plate and fracture in the sphenoid sinus roof have been also reported.

**Methodology:** We identified the characteristics of cerebrospinal fluid (CSF) leak in patients who had undergone septoplasty .We found twelve patients reported till today in the literature. For all patients, we noted the main symptoms and compared the side of the defect, its size and the interval between the septoplasty and the surgery leak repair.

**Results:** Patients most often presented with clear rhinorrhea.The leaks were much more common on the right side and the sizes were comparable .The interval between septoplasty and leak repair ranged from three days to twenty years. Three of twelve had meningoencephalocele ,five patients had meningitis and three of them had pneumocephalus.

One patient required conservating management and the rest underwent surgical repair.

**Conclusions:** A good quality computed tomography of the paranasal sinuses is order to evaluate the anatomical variations and its relationship to the skullbase and avoid major complications in CSF leaks.

Key words: cerebrospinal fluid rhinorrhea, septoplasty, lateral lamella, skull base, complication

## Literature

- 1)Venkatesan NN et al, Cerebrospinal fluid leaks following septoplasty, Ear Nose Throat J. 2014 Dec
- 2) Youssef A et. al, Traumatic cerebrospinal fluid leakage following septorhinoplasty , Arch Plast Surg. 2018 Jul
- 3) Abdulkadir mrel et al., Ethmoidal meningoencephalocele and cerebrospinal fluid leak after septoplasty: a rare complication, Article in ENT Updates 7(2):108-111 · August 2017
- 4) Thakar A et al, Delayed cerebrospinal fluid leak following septoplasty, Ann Otol Rhinol Laryngol. 2009 Sep
- 5) Soni RS et al, Postoperative cerebrospinal fluid leak after septoplasty: A potential complication of occult anterior skull base encephalocele., Allergy Rhinol . 2013
- 6) Leong AC et al, Cerebrospinal fluid rhinorrhea complicating septoplasty: a novel mechanism of injury, Ear Nose Throat J. 2010 Jan
- 7) **Onerci TM et al** , Two consecutive cases of cerebrospinal fluid rhinorrhea after septoplasty operation, **Am J Otolaryngol.** 2004 Sep-Oct

## A novel technique in sinus surgery with turbinectomy – fewer complications and better life quality

**M.Y.L.Chou<sup>1,2</sup>**, Wang C.H.Wang<sup>1,2,3</sup>

<sup>1</sup>Department of Otolaryngology-Head and Neck Surgery, Taichung Armed Forces General Hospital, Taichung, Taiwan., <sup>2</sup>Department of Otolaryngology, National Defense Medical Center, Taipei, Taiwan, <sup>3</sup>Department of Otolaryngology-Head and Neck Surgery, Tri-Service General Hospital, Taipei, Taiwan

Poster Session, 26 Sept – 30 Sept, 2021, All day

**Background:** Sinus surgery with turbinectomy (SSwT) is a common surgery in people with intractable nasal symptoms. Nasal packing is widely used in such operations. However, this procedure results in severe discomfort, including pain, nasal blockage, headache, as well as nasal oozing. In addition, post-operative bleeding and nasal crusting occur in such cases. We have developed a novel technique for SSwT to improve the surgical quality and the quality of patients' lives.

**Methodology/Principal:** A modified S-shape vertical turbinectomy with lateralization was performed. The medial part of mucosa and medial one third of inferior turbinate were excised. Regular sinus surgery with minimal approach was carried out. To achieve hemostasis, fibrin sealant and hemostatic matrix were applied onto surgical wounds through appropriate procedures.

**Results:** Of 765 cases, 562 and 203 patients underwent new technique (NT) and 203 traditional methods (TM) with nasal packing respectively. The post-operative complications in NT were much lower than in TM ( $P < 0.05$ ). The discomfort scores in NT were significantly lower ( $P < 0.05$ ) as well.

**Conclusions :** The findings provide the simple and feasible procedure for controlling post-operative complications. The results of our study additionally indicate that the novel developed technique could significantly improve the life quality of these patients.

Key words: sinus surgery with turbinectomy, novel technique

# Sinonasal inverted papilloma: Special characteristics and a case series of an oncologic hospital.

G.P. Kotsis<sup>1</sup>, G. Kokolakis<sup>1</sup>, **A. Tsoumaridou<sup>2</sup>**, A.C. Sakellaris<sup>1</sup>

<sup>1</sup>Otorhinolaryngology/ Head & Neck Surgery Department, "Saint Savvas" General Anti-Cancer and Oncological Hospital of Athens, Athens, Greece, <sup>2</sup>Otorhinolaryngology/ Head & Neck Surgery Department, "Korgialenio-Benakio" General Hospital of Athens (Greek Red Cross Hospital), Athens, Greece

Poster Session, 26 Sept – 30 Sept, 2021, All day

**Background:** Inverted papilloma (IP) is a benign epithelial tumor. IPs account for 0,5-4% of excised sinonasal tumors. Most studies show a male preponderance and age of onset between fifth and sixth decade of life. Clinical and imaging features rise the suspicion, but histology sets the diagnosis. Malignant transformation can occur at <5%.

**Methodology/Principal:** We present a case series of patients with IP that were diagnosed, surgically treated and followed-up during the last three years.

**Results:** Seven cases of IPs (6/7 males, age 30-75 years), presented with nasal congestion and/or epistaxis and were treated with endoscopic sinus surgery (ESS) after CT scan. They accounted for 9,3% (7/75) of endoscopically excised tumors. Five IPs arised from middle turbinate, one from nasal septum and one from lateral wall extending to maxillary sinus. 6/7 were primary IPs. None specimen revealed synchronous/metachronous carcinoma. On follow-up examinations till today (4-29 months postoperatively), all patients are disease-free.

**Conclusions:** IPs, although benign, can behave aggressively on adjacent structures causing serious complications and transform in malignancy. Unilateral symptoms and clinical/imaging findings impose prompt wide resection. Once the diagnosis is confirmed histologically, follow-up for at least 3 years is indicated to diagnose early any recurrence/residual disease or carcinoma.

**Key words:** Inverted Papilloma, Nasal Neoplasm, Endoscopic Surgical Procedures, Precancerous Condition

## Literature

1. Lund V, Stammberger H, Nicolai P. European position paper on endoscopic management of tumours of the nose and paranasal sinuses and skull base. *Rhinology*. 2010. 22(22). 30-31
2. Goudakos JK, Blioskas S, Nikolaou A, Vlachtsis K, Karkos P, Markou KD. Endoscopic Resection of Sinonasal Inverted Papilloma: Systematic Review and Meta-Analysis. *Am J Rhinol Allergy*. 2018 May;32(3):167-174
3. Safadi A, Yafit D, Abu-Ghanem S, Ungar OJ, Wengier A, Abergel A, Fliss DM, Koren I. The clinical behavior of sinonasal inverted papilloma with cellular dysplasia: case series and review of the literature. *Eur Arch Otorhinolaryngol*. 2017 Sep;274(9):3375-3382
4. Re M, Gioacchini FM, Bajraktari A, Tomasetti M, Kaleci S, Rubini C, Bertini A, Magliulo G, Pasquini E. Malignant transformation of sinonasal inverted papilloma and related genetic alterations: a systematic review. *Eur Arch Otorhinolaryngol*. 2017 Aug;274(8):2991-3000
5. Attlmayr B, Derbyshire SG, Kasbekar AV, Swift AC. Management of inverted papilloma: review. *J Laryngol Otol*. 2017 Apr;131(4):284-289
6. Lisan Q, Laccourreye O, Bonfils P. Sinonasal inverted papilloma: From diagnosis to treatment. *Eur Ann Otorhinolaryngol Head Neck Dis*. 2016 Nov;133(5):337-341



## Short term olfactory and quality of life changes after endoscopic transsphenoidal pituitary surgeries: Identification, discrimination, threshold and sino-nasal outcome test results

H. Basak<sup>1</sup>, **D. Uluc**<sup>1</sup>, S. Beton<sup>1</sup>, G. Kahilogullari<sup>2</sup>, C. Meco<sup>1,3</sup>

<sup>1</sup>Department of Otorhinolaryngology-HNS, Ankara University Medical School, Ankara, Turkey., <sup>2</sup>Department of Neurosurgery, Ankara University Medical School, Ankara, Turkey., <sup>3</sup>Department of Otorhinolaryngology-HNS, Salzburg Paracelsus University, Salzburg, Austria.

Poster Session, 26 Sept – 30 Sept, 2021, All day

**Background:** Although it has been shown that endoscopic transsphenoidal pituitary surgery (ETPS) preserves olfaction better than microscopic techniques, olfaction can be affected. The aim of this study is to assess short term changes in olfaction and the quality of life in patients having ETPS.

**Methodology/Principal:** Patients who underwent ETPS between June 2017 to December 2018 were evaluated with preoperative, postoperative second and twelfth months Sniffin' Sticks identification, discrimination and threshold scores as well as Sino-nasal outcome test 22 (SNOT-22).

**Results:** From 73 patients included, 48 (65.8%) were female and 25 (34.2%) were male; the mean age was 44.8 (8-76,  $\pm$  16.4). There was intraoperative cerebrospinal fluid leakage in 50 (%68.4) patients. Nasoseptal pedicled flaps were used in 62 (%84.8) patients for reconstruction and Fascia Lata flaps were used in 32 (%43.8) patients jointly with nasoseptal pedicled flaps. The preoperative and postoperative mean scores for SNOT-22, odor identification, discrimination and threshold tests were 23.46-27.86, 7.29-5.43, 6.99-5.00, 6.58-3.70 respectively, showing worsening of scores in all components of olfactory tests postoperatively.

**Conclusions:** Although previous studies showed that olfaction preserved in ETPS, our data indicates that a worsening in olfaction is to be expected at postoperative short term. Patients should be informed on this fact preoperatively.

*Olfaction, SNOT-22, Pituitary*

## Frontal sinus CSF leakage management via external surgical approach, a case report

**Konstatina Chrysouli<sup>1</sup>**, Spyridon Potamianos<sup>1</sup>, Vasileios Papanikolaou<sup>1</sup>, Evangelos Giotakis<sup>1</sup>

<sup>1</sup>*Department of Otorhinolaryngology- Head and Neck Surgery, Hippokration General Hospital of Athens, Athens, Greece*

Poster Session, 26 Sept – 30 Sept, 2021, All day

**Background:** Cerebrospinal fluid (CSF) rhinorrhea is frequently encountered after a fracture of the skull base. Meningitis develops in 3% of patients with traumatic CSF leaks and increases to 20% as long as rhinorrhea persists beyond 7 days. Fractures of the posterior wall of the frontal sinus are rare.

**Methodology:** A 33 year old patient with history of brain injury after a traffic accident presented with intermittent rhinorrhea. The patient also reports 2 episodes of bacterial meningitis since the injury. CSF leakage was confirmed with  $\beta$ 2-transferrin testing of the nasal discharge. Imaging with computed tomography scan of the skull base and magnetic resonance of the brain revealed a defect of the posterior and superior wall of the left frontal sinus and an ipsilateral meningoencephalocele. Meningoplasty and closure of the osseous defect with an osteoplastic flap was performed via an external surgical approach.

**Results:** The patient was followed-up postoperatively for 12 months to date without rhinorrhea recurrence. Recovery was uneventful.

**Conclusions:** External surgical approach with osteoplasty technique is characterized by high success rates and is considered the treatment of choice for repairing defects in the posterior and external wall of the frontal sinus.

**Key words:** CSF rhinorrhea, frontal sinus, osteoplasty, meningoencephalocele,  $\beta$ 2-transferrin

### Literature

- 1) Gerbino G, Roccia F, Benech A, Caldarelli C. Analysis of 158 frontal sinus fractures: current surgical management and complications. J Craniomaxillofac Surg. 2000
- 2) Management of frontal sinus fractures. Changing concepts. Clin Plast Surg. 1992
- 3) Bachert, C., Verhaeghe, B., van Cauwenberge, P. and Daele, J. 2000 Endoscopic endonasal surgery (EES) in skull base repairs and CSF leakage. Acta Otorhinolaryngol. Belg.
- 4) Senior, B.A., Jafri, K. and Benninger, M. 2001 Safety and efficacy of endoscopic repair of CSF leaks and encephaloceles: A survey of the members of the American Rhinologic Society. Am. J. Rhinol.
- 5) Traumatic cerebrospinal fluid leakage. Otolaryngol. Clin. North Am., 16:623-632
- 6) Amin MU, Ghaffar A. Delayed appearance of posttraumatic cerebrospinal fluid fistula. J Coll Physicians Surg Pak 2006
- 7) Gumussoy M, Ugur O, Cukurova I, Uluyol S. Recurrent meningitis and frontal encephalocele as delayed complications of craniofacial trauma. J Craniofac Surg 2014
- 8) Lee DH, Lim SC, Joo YE. Treatment outcomes of endoscopic repairs of sinonasal cerebrospinal fluid leaks. J Craniofac Surg 2011

## A 10-year retrospective study of unilateral sinonasal masses in adult patients

**Sotirios Papouliakos<sup>1</sup>**, Athanasia Marinou<sup>1</sup>, Anastasia Liapi<sup>1</sup>, Vasilios Maniatakos<sup>1</sup>, Dimitrios Lasithiotakis<sup>1</sup>, Evaggelia Zacharioudaki<sup>1</sup>

<sup>1</sup>*Department of Otorhinolaryngology – Head and Neck Surgery, General Hospital of Athens “G.Gennimatas”, Athens, Greece*

Poster Session, 26 Sept – 30 Sept, 2021, All day

**Background:** A unilateral sinonasal mass is considered a common presentation in ENT clinical practice. The aim of this study is to investigate the histopathological diagnosis of these patients.

**Methodology/Principal:** A retrospective analysis of all cases treated in our hospital with unilateral sinonasal mass, from January 2010 to December 2019 was conducted. They were grouped according to their gender, age and histopathological diagnosis (benign, inverted papilloma, malignant).

**Results:** During this period, 494 patients were identified with unilateral sinonasal mass (males: 266, females: 228, age: 17-84 years). The histopathological diagnosis was benign disease in 392 (79,35%), inverted papilloma in 65 (13,15%) and malignant disease in 37 (7,5%) of the patients. The commonest diagnosis in the benign disease group was nasal polyp, while there were 9 different types of malignant tumours, commonest being squamous cell carcinoma, followed by lymphoma, melanoma and adenoid cystic carcinoma. Malignant disease was more common in males and elder patients.

**Conclusions:** A unilateral sinonasal mass is a rather common clinical diagnosis but according to our review more than 20% of the patients will be finally diagnosed with inverted papilloma or malignant disease. A high index of suspicion is required to rule out a neoplastic aetiology in all cases of unilateral sinonasal mass.

Key words: unilateral nasal mass, unilateral sinonasal disease, Inverted papilloma, nasal polyp

203356

## Nasal sarcoma: clinical characteristics and management of two cases.

**M. Chroni**<sup>1</sup>, A. Tavernaraki<sup>2</sup>, I. Provatas<sup>3</sup>

<sup>1</sup>Ent Dpt Evangelismos Hospital Athens Greece, <sup>2</sup>Radiology Dpt Evangelismos Hospital Athens Greece,

<sup>3</sup>Pathology Dpt Evangelismos Hospital Athens Greece

Poster Session, 26 Sept – 30 Sept, 2021, All day

**Background** : head and neck sarcomas are rare, they account for 3% of head and neck malignancies.

**Objective:** to present clinical characteristics and management of two nasal sarcoma cases

**Methodology:** Retrospective case series

**Results:** Two cases were diagnosed with nasal sarcomas, one aged 50 and the second aged 26 years old. Both patients presented with unilateral nasal obstruction, one had a visible nasal mass of the left nostril. Computed tomography scan and Magnetic resonance imaging showed a unilateral nasal mass occupying the nasal cavity, in the second case extending to the nasopharynx. One patient underwent total endoscopic removal and histology reported low grade biphenotypic sinonasal sarcoma. The second's case biopsy showed Ewing's sarcoma and was initially treated with chemotherapy.

**Conclusions:** Treatment of nasal sarcomas can vary according to histology and extent of the tumour.

Case 1 50 year old man presented with unilateral nasal onstruction

A 26 year old man presented with nasal obstruction and a visible nasal mass of the left nostril. CT scan and MRI showed nasal mass occupying left nasal cavity and nasopharynx. Biopsy

# LATE ONSET OF ACUTE SINUSITIS AFTER TRAUMATIC IMPLANTATION OF A FOREIGN BODY

Ant. GKOTSIS, Maria KORODIMA, Dim.GKAMPRANAS, Vas. MPAKAS,

<sup>1</sup>ENT Head & Neck Surgery Department, 251 Hellenic Air Force General Hospital, Athens, Greece.

Poster Session, 26 Sept – 30 Sept, 2021, All day

**Background:** Foreign bodies of the maxillary sinus are extremely rare, mainly seen in children usually due to accidents or iatrogenic. They are often asymptomatic or present with atypical clinical features.

**Methodology/Principal:** We report one case of a foreign body in the maxillary sinus, presented severe tenderness and swelling of the left maxilla. The patient was submitted to surgical treatment through endonasal endoscopic approach.

**Results:** Case Report. Our patient, a 44 year old male farmer, experienced severe tenderness and swelling of the left maxilla for a month before seeking medical care. He was initially evaluated by a dentist on suspicion of dental inflammation and a panoramic dental x-ray was performed which revealed an opaque foreign body inside the left maxillary sinus. He was referred for further otorhinolaryngology evaluation and treatment. The ENT examination showed clinical signs of acute sinusitis with pus outflow from the left middle meatus. Computed Tomography revealed a partial opacification of the left maxillary sinus by thickened mucosal lesions and the presence of a large convex foreign body. The patient's medical history records a hospital visit due to an accident, involving a fall from an agricultural machine 16 years ago, with slight facial injuries and without the need of undergoing any X-ray or CT imaging at that time. Endoscopic surgical removal of the foreign body (metallic tool accessory) was performed through a left medial antrostomy. Intraoperatively, the presence of adhesions of the left middle turbinate suggested that its entry to the maxillary sinus was probably through the nasal cavity.

**Conclusions:** Persistent or atypical symptoms of sinusitis combined with a positive history of head injury, might be suggestive of a foreign body presence, thus requiring further radiological evaluation.

## Efficacy & safety of steroid saline irrigation in patients with CRS: A systematic review

**G. Katsilis<sup>1</sup>, G. Fyrmpas<sup>2</sup>, V. Nikolaidis<sup>3</sup>, J. Konstantinidis<sup>4</sup>, K. Markou<sup>5</sup>**

<sup>1</sup>ENT Specialist, Department of Otolaryngology Head & Neck Surgery, Papanikolaou General Hospital, Thessaloniki, Greece, <sup>2</sup>ENT Consultant, Department of Otolaryngology Head & Neck Surgery, Papanikolaou General Hospital, Thessaloniki, Greece, <sup>3</sup>Assistant Professor, 2nd Department of Otolaryngology Head & Neck Surgery, Papageorgiou Hospital, Aristotle University of Thessaloniki, Thessaloniki, Greece, <sup>4</sup>Associate Professor, 2nd Department of Otolaryngology Head & Neck Surgery, Papageorgiou Hospital, Aristotle University of Thessaloniki, Thessaloniki, Greece, <sup>5</sup>Professor, 2nd Department of Otolaryngology Head & Neck Surgery, Papageorgiou Hospital, Aristotle University of Thessaloniki, Thessaloniki, Greece

Poster Session, 26 Sept – 30 Sept, 2021, All day

**Background:** Chronic Rhinosinusitis affects patients' quality of life. Etiology and pathogenesis still remain unclear and multiple treatment options have been proposed. Steroid saline irrigation has been investigated in several randomized controlled trials.

**Methodology/Principal:** To assess efficacy and safety of steroid saline irrigation in patients with CRS. An electronic literature search was performed in three databases, along with multiple trial registries and extensive hand-searching to identify relevant studies. Only RCTs comparing steroid saline irrigation with saline irrigation alone or other treatment were included.

**Results:** Four randomized controlled trials were identified and systematically reviewed. Intervention was assessed in three studies with participants having had endoscopic sinus surgery and two studies set the follow-up to one year. Steroid saline irrigation appeared to be effective in patients' symptoms improvement, as well as the endoscopic score and radiologic image change. Furthermore, one study assessed safety by counting intraocular pressure and ACTH levels. Overall, the treatment was deemed safe and well-tolerated.

**Conclusion:** Steroid saline irrigation in patients with chronic rhinosinusitis appears to be effective, safe and well-tolerated, without proven predominance over other topical therapies. Further research is needed to clarify the optimal period of local irrigation of saline and steroids in terms of safety and efficacy.

Key words: Rhinosinusitis, Nasal Irrigation, Steroids

### Literature

1. Harvey, R. J. et al., 2018. Corticosteroid nasal irrigations are more effective than simple sprays in a randomized double-blinded placebo-controlled trial for chronic rhinosinusitis after sinus surgery. *International Forum of Allergy & Rhinology*, 4, 8(4), pp. 461-470.
2. Rotenberg, B. W., Zhang, I., Arra, I. & Payton, K. B., 2011. Postoperative care for Samter's triad patients undergoing endoscopic sinus surgery: a double-blinded, randomized controlled trial. *Laryngoscope*, 121(12), p. 2702-2705.
3. Rawal, R. B. et al., 2015. Post-operative budesonide irrigations for patients with polyposis: a blinded, randomized controlled trial. *Rhinology*, 53(3), p. 227-234.
4. Tait, S. et al., 2018. Effect of budesonide added to large-volume, low-pressure saline sinus irrigation for chronic rhinosinusitis a randomized clinical trial. *JAMA otolaryngology - head and neck surgery*, 144(7), p. 605-612.

## Treatment of Chronic Rhinosinusitis with Nasal Polyps and Asthma with Reslizumab in a patient with Central Serous Chorioretinopathy – a case report

João M. C. Órfão<sup>1</sup>, Liliana Carvalho<sup>1</sup>, Anna Sokolova<sup>2</sup>, Leonel Barbosa<sup>1</sup>, Filipe Freire<sup>1</sup>

<sup>1</sup>Hospital Prof. Doutor Fernando Fonseca, Department of Otorhinolaryngology, Amadora, Portugal, <sup>2</sup>Hospital Prof. Doutor Fernando Fonseca, Department of Allergology, Amadora, Portugal

Poster Session, 26 Sept – 30 Sept, 2021, All day

**Background:** Chronic rhinosinusitis with nasal polyps (CRSwNP) occurs in 7% of patients with asthma and its mainstay treatment is topical steroids and saline irrigations. However, steroids are linked to the development and exacerbations of Central Serous Chorioretinopathy (CSR) and the management of patients with this pathology and CRSwNP poses a challenge. New biological treatments might be an option for these patients.

**Methodology/Principal:** Case report of a patient with CSR treated with Reslizumab for CRSwNP and asthma. Presentation of clinical and laboratorial results on follow-up.

**Results:** A 63 years old man with CRSwNP and asthma who could not be prescribed steroids because of comorbid CSR was submitted to functional endoscopic sinus surgery with reduction of SNOT 22 score from 89 to 19 points. He was proposed to subsequent treatment with Reslizumab in a dosage of 1mg/Kg/month. There was a significant decrease in mucus eosinophils and good control of asthma and nasal symptoms for 7,5 months, when the dosage was increased to 3mg/kg due to relapse of the nasal symptoms. Lower respiratory symptoms were controlled.

**Conclusions:** When conventional treatments are contraindicated in cases of CRSwNP and asthma, biological therapies might be an option to control symptomatology and increase patient's quality of life.

**Key words:** Chronic Rhinosinusitis, Nasal Polyps, Reslizumab, Central Serous Chorioretinopathy.

**M.Givannakis<sup>1</sup>**, I.Koskinas<sup>1</sup>, F.Iereidou<sup>1</sup>, K.Papadopoulos<sup>1</sup>, A.Sarafidou<sup>1</sup>, D.Anestakis<sup>2</sup>, S.Triaridis<sup>1</sup>, J.Constantinidis<sup>1</sup>

<sup>1</sup>1<sup>st</sup> Department of ENT, Head & Neck Surgery, AHEPA University hospital, Thessaloniki, Greece, <sup>2</sup> Department of Autopsy Histopathology, Laboratory of Forensic Medicine and Toxicology, Aristotle University, Thessaloniki, Greece

Poster Session, 26 Sept – 30 Sept, 2021, All day

**Introduction:** Primary septal squamous cell carcinomas constitute an infrequent entity. Its non-specific symptomatology can mimic a plethora of common rhinological and non-rhinological problems.

**Case presentation:** We report the case of a 68 years old male patient, who presented with nasal breathing difficulty, catarrh, combined with pain over the nasal dorsum, and referring to the left ear and temporal region. The symptoms persisted despite systematic treatment, followed by an episode of epistaxis. Anterior rhinoscopy revealed the presence of a left nasal cavity lesion arising from the anterior septum and obstructing the vestibule. Biopsy diagnosed squamous cell carcinoma, and a CT and MRI imaging was undertaken for tumor extend and staging. Through a lateral rhinotomy approach, the anterior septum tumor with the anterior half of the quadrilateral cartilage was excised, with frozen section confirmation of clear margins. Bilateral selective neck dissection was also performed. An auricle cartilage graft and an oral mucosal flap were used for septal reconstruction. Following the Oncology Board decision, he underwent adjuvant radiotherapy. On regular follow up two years post-op, no signs of recurrence or complications are recorded.

**Conclusion:** Treatment of malignant septal tumors includes surgical excision, radiotherapy, or a combination of treatment modalities. Despite the high recurrence rate, locoregional control of early stage squamous cell carcinomas is favorable. Thus, it is of importance to include this rare septal malignancy in the differential diagnosis in patients with common rhinological symptoms.

*Key words: septum, squamous cell carcinomas*

#### References:

1. Leeman DJ, Shuler KJ, Han K, Mirani N. Dedifferentiation of primary squamous cell carcinoma arising from the nasal septum. *Otolaryngol Head Neck Surg* 1996; 114:131-6.
2. G r  E, Ensari N,  enel D, Ceylan DG,  nol HH. Squamous Cell Carcinoma of Nasal Septum: Case Report. *J Ann Eu Med* 2016; DOI: 10.4328/AEMED.101.
3. .Ho Y M, Coman W B. Nasal septum malignancy *ANZ J Surg* 2011;81;533–6.
4. . Hukurova  , G m    oy M, Mercan G C, Yaz A, Bayol  . Tumors originating from the nasal septum. *Bidder Tıp Bilimleri Dergisi* 2010;2(3);22-5.
5. Fornelli R A, Fedok F G, Wilson E P, Rodman S M. Squamous cell carcinoma of the anterior nasal cavity: A dual institution review. *Otolaryngology– Head and Neck Surgery* 2000;123:207-10.
6. Allen M W, Schwartz D L, Rana V, Adapala P, Morrison W H, Hanna E Y, Weber R S, Garden A S, K an Ang K. Long-term radiotherapy ourcomes for nasal cavity and septal cancers. *Int J. Radiation Oncology Biology Physics* 2008;71(2);401-6.



## The use of the Propel mini-stent in complex frontal sinus disease: our clinical experience.

**Magill JC<sup>1</sup>**, Rennie C, Saleh H<sup>1</sup>.

<sup>1</sup>Charing Cross Hospital, London, UK.

Poster Session, 26 Sept – 30 Sept, 2021, All day

**Background:** The surgical management of complex frontal sinus disease can be challenging, with circumferential scarring and re-stenosis common complications. The Propel mini-stent implant is a mometasone furoate bioabsorbable stent, which has been shown to reduce scarring and adhesions. We present our experience using the Propel Mini-stent in the frontal sinus of a cohort of patients with complex challenging frontal sinus disease; many of which with difficult underlying medical co-morbidities.

**Method:** This was a prospective study. Patients with complex chronic rhinosinusitis underwent frontal sinus surgery, with insertion of a Propel mini-stent into the frontal sinus outflow (FSO). Endoscopic evaluation of the frontal sinus outflow was undertaken at follow up and patients assessed for symptom severity and post-operative complications.

**Results:** 11 patients underwent Propel mini-stent insertion between April and February 2020. 91% (10/11) patients had previous endoscopic frontal sinus surgery. Indications for surgery included CRS with/without polyps (6/11), mucocoele (3/11) and allergic fungal sinusitis (2/11). Patients often had concomitant cystic fibrosis (36%), PCD(10%) or Samters Triad (17%). 81% (9/11) attended follow up, with 100% of FSO tracts patent. 89%(8/9) of patients significantly improved following surgery. There were no post-operative complications.

**Conclusion:** The Propel mini stent is safe and effective adjunct to ESS, particularly in patients who have traditionally been considered high risk for poor surgical outcomes following frontal sinus surgery.

**Keywords:** Chronic Rhinosinusitis; Propel; Frontal sinus.

## Etiopatogenic and clinical aspects of chronic rhinosinusitis with and without nasal polyposis

**M. Caciandone**<sup>1</sup>, I. Anghel<sup>1,2</sup>

<sup>1</sup>Central Military University Emergency Hospital "Dr. Carol Davila", Bucharest, ENT Department, <sup>2</sup>University of Medicine and Pharmacy "Carol Davila" Bucharest

Poster Session, 26 Sept – 30 Sept, 2021, All day

**Background:** Chronic rhinosinusitis is a clinical pathology that reunites a group of heterogeneous inflammatory and infectious disease that affects both the nasal and paranasal sinus mucosa that can have multiple causes - local or systemic. Nasal polyposis is an inflammatory condition of the nasosinusal mucosa that can be uni- or bilateral, associated or not with chronic rhinosinusitis.

**Methodology:** We present a retrospective study on a lot of patients diagnosed with chronic rhinosinusitis with or without nasal polyposis admitted to C.M.U.E.H. "Dr. Carol Davila" ENT clinic in six years (may 2014-may 2020) in order to identify the etiology, the clinical aspects and the pathogenic mechanism of the disease.

**Results:** The main subjective complaints of the patients were unilateral or bilateral nasal obstruction, anterior or posterior nasal discharge, hyposmia or anosmia, facial pain or pressure, cough, fatigability, dental pain or otalgia.

From the total number of chronic rhinosinusitis cases, almost half (49%) of the cases were with nasal polyposis. The majority of patients had various local predisposing factors that triggered the onset of the disease or factors that appeared as a consequence that maintain the pathologic status. Therefore, anatomic defects such as obstructive deviated nasal septum and chronic hypertrophic rhinitis were most frequently identified, associated to other local factors like rhinosinusal tumors, trauma or odontogenic starting point or systemic factors like allergies.

**Conclusions:** The factors implied in the etiopathogeny of chronic rhinosinusitis with or without nasal polyposis can be classified in intrinsic: such as genetic or congenital abnormalities (the association with cystic fibrosis), anatomical defects, allergic status or extrinsic: viral, bacterial or fungal infections, trauma or foreign bodies, exposure to pollutants.

**Key words:** chronic rhinosinusitis, nasal polyposis,

## A Novel Cost Effective Safety Adjunct to Flexible Nasendoscopy During the Coronavirus Pandemic: The Personal Protective Endoscopy Mask (PPEM)

Jolly K.<sup>1</sup>, Darr A.<sup>1</sup>, Osborne MS.<sup>1</sup>, **Bhamra N.**<sup>1</sup>, Barraclough J.<sup>1</sup>

<sup>1</sup>*Department of Otolaryngology, The Royal Wolverhampton NHS Trust.*

Poster Session, 26 Sept – 30 Sept, 2021, All day

**Background:** Healthcare professionals (HCP) are considered high risk at contracting Coronavirus disease 19 (SARS-COV-2) due to a multitude of factors including exposure to higher viral loads and aerosolisation. Recent literature suggests an increased risk posed to otorhinolaryngologists, as diagnostic, interventional, and therapeutic procedures involving the upper aerodigestive tract, paranasal sinuses and middle ear exposes HCPs to both direct and indirect transmission of SARS-CoV-2. We describe a novel and cost-effective safety adjunct when undertaking flexible nasendoscopy (FNE) within ward/ outpatient settings.

**Methodology/Principal:** Our technique aims to utilise resources readily available within the healthcare service to construct a mask to aid safer FNE. Our device incorporates a standard anaesthetic air cushion face mask, double swivel elbow adapter and viral filter. In our case all components were manufactured by Intersurgical® at a total cost of £1.78 via NHS supply chain.

**Results:** Four sprays were then directed into the mask to simulate aerosol generation, whilst the paper was held an inch away from the bronchoscope port to detect any potential leakage. The PPEM demonstrated a significant reduction in potential aerosol/droplet exposure to the examiner.

**Conclusions:** Application of the PPEM reduces aerosolisation/ droplet exposure within the clinical environment, reducing time for air circulation between patients, thus increasing patient turnover.

**Key words:** COVID-19, nasendoscopy, PPE, safety, AGP

## Intra-sphenoidal lead bullet toxicity caused chronic rhinosinusitis with polyps.

**Ozolina L.**<sup>1</sup>, Isankova O.<sup>1</sup>, Novicka R.<sup>1</sup>, Apšeniece K.<sup>1</sup>, Peksis K.<sup>1</sup>

<sup>1</sup>Otorhinolaryngology clinic "Headline", University of Latvia, Riga, Latvia.

Poster Session, 26 Sept – 30 Sept, 2021, All day

**Background:** The lead is known as toxic agent which can affect all human body by slowly causing systemic and local complications<sup>1</sup>. In this case we present a 72-year-old male who turned to ENT clinic with main complaints of blocked nose, purulent discharge, severe headaches, and temperature 37,5<sup>0</sup>C notably for last 3 months. In 1973 he had gunshot with bullet and ever since the bullet retained in right sphenoid sinus. He also had nose operations in 1999 and 2006, practically with no improvement.

**Methodology/Principal:** Computer tomography scan revealed septal perforation, pansinusitis, polyps filling nasal cavities and sinuses, absent middle turbinates, and the metallic foreign body in the inferio-lateral part of the right sphenoidal sinus.

**Results:** The patient underwent functional endonasal sinus surgery with removal of the lead bullet at the end. The next post-operation day patient felt symptom improvement. He is still coming to regular checkups and notes that he feels less tired, has no headaches, no purulent discharge and overall breathing completely improved.

**Conclusions:** This report presents a rare case of chronic rhinosinusitis and complications which were caused by lead bullet intoxication. Surgical removal of lead bullet from this hard accessible area significantly improved patient's general wellbeing and nasal breathing.

**Key words:** Lead bullet; lead toxicity; chronic rhinosinusitis; nasal polyps; intra-sphenoidal bullet

### Literature:

<sup>1</sup>Jillian L. Theobald; Mark B. Mycyk. Rosen's Emergency Medicine: Concepts and Clinical Practice, Chapter 151: Iron and Heavy Metals, 1912-1920.e2, 2018.

## Efficacy and Safety Evaluation of a Hypertonic Seawater Solution Enriched with Manganese and Copper Salts

Samuel Constant<sup>1</sup>, Amina Saaïd<sup>2</sup>, **Marcos Alejandro Jimenez-Chobillon<sup>3</sup>**

<sup>1</sup>*Epithelix, 18 chemin des Aulx CH-1228 Plan-Les-Ouates, Geneva, Switzerland,* <sup>2</sup>*Laboratoire Fumouze, 110-114 rue Victor Hugo, 92686, Levallois-Perret, France,* <sup>3</sup>*National Institute of Respiratory Diseases "Ismael Cosío Villegas", México DF, Mexico*

Poster Session, 26 Sept – 30 Sept, 2021, All day

**Background:** Nasal irrigation is commonly recommended as an adjuvant treatment for blocked nose. In this study, the safety and efficacy profile of Stérimar Blocked Nose (SBN), a hypertonic seawater solution enriched with manganese and copper salts, has been evaluated on nasal epithelium, in vitro.

**Methodology/Principal:** 3D reconstituted human nasal epithelium tissue model, MucilAir™, model has been used to investigate the safety of SBN on nasal epithelium by measuring trans-epithelial electrical resistance, cytotoxicity (lactate dehydrogenase release) and phlogosis-related effects (interleukin-8 secretion). Efficacy assessment was measured by ciliary beat frequency, mucociliary clearance and antimicrobial activities (against *S. aureus* and *P. aeruginosa*).

**Results:** Four-day SBN treatment did not compromise the nasal epithelium integrity, nor exert cytotoxic or pro-inflammatory effects. SBN treatment significantly increased the ciliary beat frequency ( $p < 0.001$ ) and mucociliary clearance rates ( $p < 0.001$ ) compared to untreated cells. SBN treatment exerted a bactericidal effect on tested, whereas not-enriched seawater had only a bacteriostatic effect.

**Conclusions:** The results demonstrate that SBN is a safe formula for use on human nasal epithelium. The results also suggest a better potential therapeutic role for SBN in comparison to not-enriched seawater when used to control nasal congestion and inhibit bacterial growth which may cause nasal congestion.

**Key words:** Hypertonic seawater; nasal irrigation; nasal congestion: rhinosinusitis.

## The impact of nasal symptoms in life quality of AAV patients

**Theodora K. Avgeri<sup>1</sup>**, Aikaterini Demagkou<sup>1</sup>, Fanis Karagiorgas<sup>2</sup>, Dimitris Boubas<sup>2</sup>, Pavlos Maragkoudakis<sup>1</sup>, Alexandros Delidis<sup>1</sup>.

<sup>1</sup>ENT department, Attikon University Hospital, Athens, Greece, <sup>2</sup>Rheumatology department, , Attikon University Hospital, Athens, Greece

Poster Session, 26 Sept – 30 Sept, 2021, All day

**Background:** AAV causes destruction and inflammation of small vessels and characteristically affects the respiratory (upper and lower), renal and gastro-intestinal systems. Nasal symptoms influence the patient's life quality and play an important role for frequent hospital visits. On the other hand nasal disease is not attributed to serious disease progression

**Methodology/principal:** Patients of "Attikon" University hospital diagnosed with AAV from 2015 to 2019 were included. The presence of nasal symptoms and/ or findings (epistaxis, ulcers, sinusitis etc.) at the time of first diagnosis was recorded. The sample was separated in two groups (group A with nasal symptoms/ findings, group B without) and the SNOT 22 questionnaire was administered.

**Results:** 34 patients were included (19 women and 15 men). The mean age was 54,7 +/-18,7. 19 patients (group A) reported nasal symptoms (14 CRS, 6 epistaxis, 4 ulcers/crusts, 3 rhinitis) and 15 had none (group B). Returned questionnaires scored 0-50 and the mean score was 15,92 +/-15,80. No statistical significance was calculated (p=0,6). Measures of error were 3,51 and 4,41 respectively.

**Conclusion:** Both groups scored relatively low, without statistical significance between them. Nasal symptoms in patients with AAV have a limited impact in their life quality.

Key words: SNOT-22, sinusitis, vasculitis

#### Literature

1. Update on clinical, pathophysiological and therapeutic aspects in ANCA-associated vasculitides. Lamprecht P1, Holle J, Gross WL. Send to Curr Drug Discov Technol. 2009 Dec;6(4):241-51.
2. Sinonasal involvement in systemic vasculitides and cocaine-induced midline destructive lesions: Diagnostic controversies M. Armengot, A. Garcí'a-Llibero' s, M. J. Go'mez, A. Navarro, and A. Martorell, Allergy Rhinol (Providence) Summer 2013;4(2):e94-9.
- 3. Pagnoux Ch, and Wolter N. Vasculitis of the upper airways. Swiss Med Wkly 142:w13541, 2012.

## Lymphomas of the nasopharynx and paranasal sinuses. A case series presentation, diagnostic and therapeutic challenges.

G.P. Kotsis<sup>1</sup>, **A. Tsoumaridou<sup>2</sup>**, A. Razou<sup>1</sup>, P. Oikonomopoulos<sup>3</sup>, A. Sioni<sup>3</sup>, A.C. Sakellaridis<sup>1</sup>

<sup>1</sup>Otorhinolaryngology/ Head & Neck Surgery Department, "Saint Savvas" General Anti-Cancer and Oncological Hospital of Athens, Athens, Greece, <sup>2</sup>Otorhinolaryngology/ Head & Neck Surgery Department, "Korgialenio-Benakio" General Hospital of Athens (Greek Red Cross Hospital), Athens, Greece, <sup>3</sup>Hematology Department, "Saint Savvas" General Anti-Cancer and Oncological Hospital of Athens, Athens, Greece

Poster Session, 26 Sept – 30 Sept, 2021, All day

**Background:** Diagnosing nasopharyngeal and/or sinonasal lymphomas may be challenging in everyday practice due to their rarity. We present our experience citing a critical review of recent literature.

**Methodology/Principal:** History, clinical examination and paraclinical studies of 9 patients suspected for lymphoma were obtained, adding diagnostic procedures till targeted therapy.

Seven male patients presented with a neck mass of unknown origin. The nasal endoscopy revealed a nasopharyngeal mass in 6 of them, while 1 patient had a mass in his right paranasal sinuses. Two women had paranasal lymphomas, with intracranial and/or intraorbital extension.

**Results:** The patients with neck mass underwent a fine needle aspiration biopsy, while most of them had an office-based biopsy of the nasal focus apart from 1 male patient who underwent ESS. An open biopsy of the neck mass was required to establish the diagnosis in all cases. All patients received targeted therapy and they are under close surveillance till present apart from one female patient who died due to intracranial complications.

**Conclusions:** Extreme sparsity, short history and vague complaints may delay or disorientate the diagnosis of lymphoid origin malignancies. The benign appearance in contrast to aggressive behavior and variable prognosis demand clinical alertness and early histologic identification to guarantee the best treatment.

Key words: Lymphoma, Paranasal Sinus Neoplasms, Sinusitis, Skull Base Neoplasm

### Literature

1. Peng KA, Kita AE, Suh JD, Bhuta SM, Wang MB. Sinonasal lymphoma: case series and review of the literature. *Int Forum Allergy Rhinol.* 2014 Aug;4(8):670-4. doi: 10.1002/alr.21337. Epub 2014 Apr 23. PMID: 24760602
2. Kawaguchi M, Kato H, Tomita H, Mizuta K, Aoki M, Hara A, Matsuo M. Imaging Characteristics of Malignant Sinonasal Tumors. *J Clin Med.* 2017 Dec 6;6(12):116. doi: 10.3390/jcm6120116. PMID: 29211048
3. Crane GM, Duffield AS. Hematolymphoid lesions of the sinonasal tract. *Semin Diagn Pathol.* 2016 Mar;33(2):71-80. doi: 10.1053/j.semdp.2015.09.008. Epub 2015 Sep 9. PMID: 26472692
4. Lund VJ. Tumors of the nose, sinuses, and nasopharynx. Lund VJ, Howard DJ, Wei WI. Stuttgart, New York: Thieme; c2014. Chapter 14, Lymphoreticular Neoplasia and Other Lesions; p319- 328

**Frank Haubner<sup>1</sup>**

*<sup>1</sup>Department of Otorhinolaryngology, University Hospital, Ludwig-Maximilians; University of Munich, Marchioninstr. 15, 81377 Munich, Germany*

Poster Session, 26 Sept – 30 Sept, 2021, All day

**Background:** Nasal septal perforation closure represents a considerable surgical challenge. Numerous techniques as advancement flaps are surgically demanding and cause a considerable time to perform. Other techniques rely on the implantation of foreign materials, that pose a persisting threat of infection. Success rates vary and often show limited success especially in revision cases.

**Methodology/Principal:** The authors have identified a reliable technique closing septal perforations by an autologous “sandwich graft”. It is layered around a piece of auricular cartilage, covered with temporal fascia, thus emulating the physiological layers of the nasal septum.

**Results:** All perforations were medium sized: the largest perforation was 3x2.5 centimeters in size while the smallest was 1x1 centimeter in size. Average size of the perforations were  $3.1 \pm 1.7 \text{ cm}^2$ . Closure was successful in 10 out of the 11 patients. Mean follow up was 12 months. We saw no morbidity to the donor sites in any patients.

**Conclusions:** The technique using a “sandwich graft” to close nasal septal perforations is easily feasible also in scarred and revision cases and strives to reconstruct the nasal as physiological as possible.

Key words: nasal septal perforation; auricular cartilage; temporalis fascia



## Nasal septal cyst: an incidental radiological finding

Omar Ahmed, Ali Shaladi, **Bertram Fu**

<sup>1</sup>*East Kent Hospitals University NHS Foundation Trust, United Kingdom*

Poster Session, 26 Sept – 30 Sept, 2021, All day

**Background:** Cysts arising from the mucosa of the nasal septum are quite rare. Although most of the published cases are a consequence of nasal surgery particularly submucous resection, our case report is an entirely incidental finding with no previous history of nasal surgery.

**Methodology:** we report a rare incidental radiological finding that would add to the current literature.

**Results:** we describe a rare presentation of a 55-year old gentleman presented to the out patient clinic with left facial palsy along with left persistent ringing tinnitus for 3 weeks. Examination showed left lower motor neuron grade 5 House-Brackmann facial palsy. Cranial nerves examination was normal. Otoscopy could not be done due to impacted hard wax. He had a two-week course of prednisolone without significant improvement. Accordingly, urgent CT and MRI head were requested and he was advised to use sodium bicarbonate ear drops. One week later, the patient was seen again for microsuction and review of the scans which showed an incidental finding of 2 cm cyst arising from the nasal septum and causing narrowing of the right nostril.

After discussion with the patient, he was added to the waiting list for excisional biopsy via septorhinoplasty approach.

**Conclusions:** Nasal septal cysts are commonly iatrogenic; however, they can arise without previous surgery as well. Excisional biopsy for diagnosis is essential.

**Key Words:** Septal cyst, incidental, excisional biopsy.

## Endonasal endoscopic nasopharyngectomy for nasopharyngeal malignancies: A survival analysis

**Haissan Iftikhar**<sup>1</sup>, Paresh Parmod Naik<sup>2</sup>, Shahzada Khuram Ahmed<sup>3</sup>

All authors are affiliated with Department of Otolaryngology, Queen Elizabeth Hospital, Birmingham, United Kingdom

Poster Session, 26 Sept – 30 Sept, 2021, All day

**Background:** Nasopharyngeal malignancies have been traditionally treated with radiation ± chemotherapy with surgery reserved for select cases. Recent advances in endoscopic skull base surgery have enabled surgeons to achieve endoscopic nasopharyngectomy with adequate visualization. The aim of our study was to report survival outcomes amongst patients undergoing endonasal endoscopic nasopharyngectomy in our institute.

**Methodology:** We conducted a retrospective longitudinal cohort study. All patients who underwent endonasal endoscopic nasopharyngectomy from December 2017 till February 2021 were included. We reported the procedure using the Castelnuovo classification for endoscopic nasopharyngectomy. We collected data on age, gender, prior treatment, histology, extent of surgery, post-operative adjuvant therapy and recurrence and reported the survival along mean survival time using Kaplan Meire curves and log rank test.

**Results:** A total of six patients, three males and three females with a mean age of 43.7 years were included in our study. Five patients underwent type 3 nasopharyngectomy and three patients had en bloc resection of tumour. Three patients underwent a salvage procedure whereas three patients received upfront definitive surgical resection. Three patients developed recurrence with a mean survival time of 19.3 months. The disease-free survival at 1 and 2 years of surgery was 88.3% and 66% respectively.

**Conclusion:** Endonasal endoscopic nasopharyngectomy is an effective surgical procedure that can be undertaken for both salvage and primary cases. Our survival results are comparable to literature.

### Keywords

Skull Base, Nasopharyngeal carcinoma, Endoscopic Nasopharyngectomy, Nasopharyngectomy, Survival

## Impact of omalizumab therapy on sleep in patients with nasal polyps.

**Petter Olsson**<sup>1</sup>, Eli O. Meltzer<sup>2</sup>, Cecile T.J. Holweg<sup>3</sup>, Jinnie Ko<sup>3</sup>, Kelly Montalto<sup>4</sup>, Rebecca Saenz<sup>3</sup>, Lauren A. Millette<sup>3</sup>, Vijay Ramakrisnan<sup>5</sup>

<sup>1</sup>Novartis AB, Kista, Sweden; <sup>2</sup>University of California, San Diego, La Jolla, CA, USA; <sup>3</sup>Genentech, Inc., South San Francisco, CA, USA; <sup>4</sup>Novartis Pharmaceuticals Corporation, East Hanover, NJ, USA; <sup>5</sup>Department of Otolaryngology – Head and Neck Surgery, University of Colorado, Anschutz Medical Campus, Aurora, CO, USA

Poster Session, 26 Sept – 30 Sept, 2021, All day

**Background:** Sleep disturbance drives patients to seek care for chronic rhinosinusitis with nasal polyps (CRSwNP). The impact of omalizumab on sleep was assessed to understand benefits beyond rhinological symptoms in these patients.

**Methodology:** Assessments: patient-reported sleep outcomes over the previous 4 weeks (sleep disturbances, snoring, shortness of breath, sleep adequacy, somnolence, and sleep quantity) using the Medical Outcomes Study Sleep Scale from Weeks 24-76 of the POLYP 1/2 open-label extension (NCT03478930). Patients receiving placebo with intranasal corticosteroids during POLYP 1/2 switching to omalizumab at Week 24 (N=126) were included. Omalizumab discontinuation at Week 52 allowed for examination of response durability through Week 76.

**Results:** Mean [SD] improvements were observed in sleep disturbance (-6.85 [18.55]), snoring (-5.69 [27.76]), and Sleep Problems Indexes I/II (-4.25 [15.07]/-5.29 [14.07]) with greatest improvements in shortness of breath (-7.07 [24.21] points) from Weeks 24-52. Effects waned upon therapy discontinuation, but benefits over baseline persisted at Week 76. Minimal to no improvements were observed in sleep adequacy, somnolence, and sleep quantity.

**Conclusions:** Sleep improvements observed with omalizumab can provide value beyond rhinological symptoms in patients with CRSwNP.

Key words: nasal polyposis; omalizumab; patient-reported outcomes; sleep

Patient-reported improvements following omalizumab for nasal polyps during the POLYP 1 and 2 open-label extension.

**Joaquim Mullol<sup>1</sup>**, Rebecca Saenz<sup>2</sup>, Cecile T.J. Holweg<sup>2</sup>, Jinnie Ko<sup>2</sup>, Kelly Montalto<sup>3</sup>, Petter Olsson<sup>4</sup>, Lauren A. Millette<sup>2</sup>

<sup>1</sup>Rhinology Unit & Smell Clinic, ENT Department, Hospital Clinic, IDIBAPS, Universitat de Barcelona, CIBERES, Barcelona, Catalonia, Spain; <sup>2</sup>Genentech, Inc., South San Francisco, CA, USA; <sup>3</sup>Novartis Pharmaceuticals Corporation, East Hanover, NJ, USA; <sup>4</sup>Novartis AB, Kista, Sweden

Poster Session, 26 Sept – 30 Sept, 2021, All day

**Background:** Chronic rhinosinusitis with nasal polyps (CRSwNP) severely affects patients' lives. This prespecified analysis of POLYP 1/2 open-label extension (OLE) examined patient-reported outcomes (PROs) in patients with CRSwNP after omalizumab treatment.

**Methodology:** Patients in placebo arm of POLYP 1/2 studies who entered OLE received omalizumab 75-600mg every 2 or 4 weeks from Week 24 (baseline) until Week 52 (treatment phase) with a follow-up through Week 76 (N=126) (NCT03478930). PROs included: Patient Global Impression of Change (PGIC) in symptom severity from last visit, overall health in previous month per Healthy Days Core Module (HDCM).

**Results:** In total, 65% (76 of 117) of patients reported improvement in PGIC from Weeks 24-52, with 33.3% reported symptoms as very much better/much better. More patients reported no change (36.3%) vs worsening (33.6%) at Week 76. HDCM showed improvement in patients who rated their previous month's overall health as good/very good/excellent from 48.8% (baseline) to 65.8% (Week 52). At Week 76, more patients reported good/very good/excellent overall health in previous month (55.8%) vs baseline.

**Conclusions:** Patients reported improved health with omalizumab. Improvements waned following its discontinuation, but remained improved vs pretreatment indicating patient-centric benefits.

Key words: healthy days core module; nasal polyposis; omalizumab; patient global impression of change; patient-reported outcomes

## A systematic review assessing reconstruction methods and cerebrospinal fluid leaks using the endoscopic endonasal approach for the management of clival chordomas

**Keshav Kumar Gupta<sup>1</sup>**, Edward Balai<sup>1</sup>, Adnan Darr<sup>2</sup>, Karan Jolly<sup>3</sup>

<sup>1</sup>Department of surgery. Sandwell General Hospital. Sandwell and West Birmingham Hospitals NHS Trust. West Bromwich. B71 4HJ. United Kingdom.

<sup>2</sup>Department of otorhinolaryngology. New Cross Hospital. Royal Wolverhampton NHS Trust. Wolverhampton. WV10 0QP. United Kingdom.

<sup>3</sup>Department of otorhinolaryngology. Queen Elizabeth Hospital. University Hospitals Birmingham NHS Trust. Birmingham. B15 2TH. United Kingdom.

Poster Session, 26 Sept – 30 Sept, 2021, All day

**Background:** There is currently no consensus regarding the ideal reconstructive technique to minimise post-operative complications in the endoscopic endonasal approach (EEA) to clival chordomas (CC). Our systematic review aims to evaluate the existing literature to assess reconstructive techniques utilised and post-operative cerebrospinal fluid (CSF) leak rates in this cohort.

**Methodology:** A systematic review was performed of all published data related to CC patients managed with EEA.

**Results:** A total of 33 articles were included, representing 380 patients and 413 procedures. The post-operative CSF leak rate was 10.7%. There were a wide variety of reconstruction methods used. The CSF leak rate was less than the overall leak rate in subgroups using a NSF (10.1%), where no glue/haemostat was used (7.3%) and where no pack was used (8.8%).

**Conclusions:** Given the heterogeneity in the existing literature with respect to reconstruction, it is challenging to provide a consensus regarding ideal reconstructive techniques. We therefore recommend a tailored approach to EEA for CC's depending on the location and size. This review can serve as a reference for acceptable CSF leak rates for surgeons performing EEA to CC's and act as a trigger for detailed reporting of repair so that future research can reach a consensus regarding optimal reconstruction.

**Key words:** clival chordoma; cerebrospinal fluid leak; endoscopic surgery; rhinology; skull base; skull base reconstruction

## The management of spontaneous cerebrospinal fluid leaks with an endoscopic endonasal approach

**Keshav Kumar Gupta**<sup>1</sup>, Karan Jolly<sup>1</sup>, Navdeep Bhamra<sup>1</sup>, Anastasia Aslanidou<sup>2</sup>, Ruchika Batra<sup>2</sup>, Shahzada K. Ahmed<sup>2</sup>

<sup>1</sup>Department of Otorhinolaryngology, New Cross Hospital, The Royal Wolverhampton NHS Trust. Wolverhampton. WV10 0QP. United Kingdom., <sup>2</sup>Department of Otorhinolaryngology, Queen Elizabeth Hospital, University Hospitals Birmingham NHS Foundation Trust. Birmingham. B15 2TH. United Kingdom.

Poster Session, 26 Sept – 30 Sept, 2021, All day

**Background:** The cause of spontaneous cerebrospinal fluid (CSF) leaks (SCSFL) is unclear. They may be related to underlying connective tissue disorders, problems of spinal venous drainage systems or linked to idiopathic intracranial hypertension (IIH). We present our experience of SCSFL management via the endoscopic endonasal approach.

**Methodology:** All patients who underwent a CSF leak repair at our tertiary centre between 1<sup>st</sup> January 2012 and 31<sup>st</sup> December 2019 were retrospectively analysed in this case series. Results: Thirty-three patients underwent SCSFL repair with a wide variety of repair methods used. There were 81.8% (n=27) females, ranging in age from 31-81 years (mean age 55.2 ± 13.2 years). Combined CT/MRI imaging identified the leak site in 30 patients (91%). The average length of stay was 1.6 days. Post-operative complications occurred in 2 patients (6.1%) (meningitis and epistaxis). Overall, there was a successful primary repair in 32 (97.0%) cases.

**Conclusions:** Our study adds to the existing evidence that endoscopic repair of SCSFL has become the gold standard with good outcomes in terms of first-time repair success and complication rates. Based on the existing literature and our study, we have created a proposed treatment algorithm to aid management of these patients.

**Key words:** CSF repair; CSF leak; endoscopic endonasal repair; skull base defect; idiopathic intracranial hypertension.

## The changing face of sinus surgery in England over the last decade

**Keshav Kumar Gupta**<sup>1</sup>, Karan Jolly<sup>1</sup>, Navdeep Bhamra<sup>1</sup>, Max Sallis Osborne<sup>1</sup>, Shahzada K. Ahmed<sup>2</sup>

<sup>1</sup>Department of Otorhinolaryngology, New Cross Hospital, The Royal Wolverhampton NHS Trust. Wolverhampton. WV10 0QP. United Kingdom., <sup>2</sup>Department of Otorhinolaryngology, Queen Elizabeth Hospital, University Hospitals Birmingham NHS Foundation Trust. Birmingham. B15 2TH. United Kingdom.

Poster Session, 26 Sept – 30 Sept, 2021, All day

**Background:** Sinus surgery has seen significant changes over the years with advancements in instruments, endoscopes and imaging. This study aimed to use HES data to review the total number of sinus related procedures performed across England and identify whether there were any trends across the study period.

**Methodology:** Data from Hospital Episode Statistics (HES) was extracted for the years 2010-2019. After examination of overall sinus related procedures, further subgroup analysis was performed with regards to open or endoscopic techniques.

**Results:** The total number of sinus procedures performed between 2010-2019 was 89,495. There was an increase in endoscopic surgeries by 21.1% and a decrease of open surgeries 35.3% during this time. There was an overall increase in maxillary, frontal and sphenoid sinus procedures, with a decrease in ethmoid sinus and lateral rhinotomy operations. There was an increase in the proportion of endoscopic cases overall by 5.7% and for all sinuses individually.

**Conclusions:** Although our data set is limited by coding, and lack of patient factors, it represents most, if not all, of the data in England over a large study period. It is therefore useful to add to previous studies when demonstrating the increasing popularity of endoscopic sinus surgery over open procedures.

**Key words:** endoscopic sinus surgery; sphenoid; ethmoid; frontal; maxillary; sinus.

## Application of the Magic Leap Augmented Reality System to Aid the Approach to Extended Endoscopic Anterior Skull Base Surgery.

**Joseph Sinnott**<sup>1</sup>, Kumar Abhinav<sup>2</sup>, Warren Bennett<sup>1</sup>

<sup>1</sup>University Hospital Bristol and Weston, Bristol, United Kingdom, <sup>2</sup>Southmead Hospital, Bristol, United Kingdom

Poster Session, 26 Sept – 30 Sept, 2021, All day

**Background:** Novel technologies such as endoscopes, cross sectional imaging and image guidance have all led to an advances in the safety and application of skull base surgery. Virtual reality (VR) and augmented reality (AR) likely represents the next frontier. Most people are familiar with VR which is useful in simulations and visualisation. AR involves superimposing imaged onto structures in the real environment. This potentially means the ability to locate important landmarks such as the internal carotid behind bone. Other potential benefits of AR used during surgery include not having to look away from the operative field to gain accurate localisation and not having to change instruments.

**Methodology/Principal:** MagicLeap (Magic leap Inc, Plantation, Florida, USA) was assessed as a potential for augmented reality application in skull base surgery. Other technologies are available including ((2), Google Glass (Google LLC, Mountain View, California, USA) and HoloLens (Microsoft Inc., Redmond, Washington, USA) and others. We have included photographs and videos of Magic Leap's application as an example

**Results:** Brilliant and wide-reaching potential. Some learning curve required. Likely some benefits to safety but not statistical data in small case series.

**Conclusions:** This small series with photographs and videos shows the potential of this technology. There are still some limitations but it is a very exciting trend which we are likely to see much more of in the future.

**Key words:** Augmented, Virtual, technology, reality, skull-base



# Measurement of Nasal Septal Cartilage in Adult Filipinos using Computed Tomography

**Miguel Limbert Q. Ramos<sup>1</sup>**, Joseph Amado C. Galvez<sup>2</sup>

<sup>1</sup>Department of Otorhinolaryngology –Head and Neck Surgery, Ospital ng Maynila Medical Center, Manila, Philippines, <sup>2</sup>Department of Otorhinolaryngology –Head and Neck Surgery, Ospital ng Maynila Medical Center, Manila, Philippines

Poster Session, 26 Sept – 30 Sept, 2021, All day

**Background:** The nasal septal cartilage is widely used graft in different otolaryngologic procedures such as rhinoplasty. Baseline measurement was done using harvested cartilages from Filipino Malay cadavers with a small sampling size. To reinforce this measurement, can the total and harvestable cartilage area be measured using Computed Tomography (CT) scans of adult Filipinos?

**Methodology/Principal:** The unit of observation were CT scans of subjects  $\geq 18$  years old. The measurements were obtained in a generated best midsagittal image ( $n = 155$  subjects) using a DICOM image viewing software (RadiAnt). The anatomic landmarks were plotted using the image and the area was measured and compared by age and gender.

**Results:** The total and harvestable area of the nasal septal cartilage is larger in males with a mean value of  $6.52 \text{ cm}^2$  and  $3.57 \text{ cm}^2$  respectively, compared to the female mean value of  $5.71 \text{ cm}^2$  and  $3.13 \text{ cm}^2$ . The 18-30 year-old group has the largest total and harvestable area with a mean value of  $6.47 \text{ cm}^2$  and  $3.60 \text{ cm}^2$ .

**Conclusions:** The best time to perform rhinoplasty and procedures which utilize the nasal septal cartilage is during post-pubertal age to allow maturation. CT scan is a non-invasive tool that can provide information prior to these procedures.

Key words: Computed Tomography, Nasal Septal Cartilage, Rhinoplasty

## Literature

1. Kania, K., Nguyen, A., & Kim, Y. (2015). Rhinoplasty with Cartilage and Alloplastic Materials, Nasal SMAS Management in Asian Rhinoplasty, Contracture Classification, and Secondary Rhinoplasty with Contracture. *Seminars in Plastic Surgery*, 29(04), 255–261. <https://doi.org/10.1055/s-0035-1564819>
2. Lin, G., & Lawson, W. (2007). Complications using grafts and implants in rhinoplasty. *Operative Techniques in Otolaryngology-Head and Neck Surgery*, 18(4), 315–323. <https://doi.org/10.1016/j.otot.2007.09.004>
3. Sajjadian, A., Rubinstein, R., & Naghshineh, N. (2010). Current Status of Grafts and Implants in Rhinoplasty: Part I. Autologous Grafts. *Plastic and Reconstructive Surgery*, 125(2), 40e–49e. <https://doi.org/10.1097/prs.0b013e3181c82f12>
4. Yung, M. (2008). Cartilage tympanoplasty: literature review. *The Journal of Laryngology & Otology*, 122(7), 663–672. <https://doi.org/10.1017/s0022215108001813>
5. Hwang, S. M., Lim, O., Hwang, M. K., Kim, M. W., & Lee, J. S. (2016). The Clinical Analysis of the Nasal Septal Cartilage by Measurement Using Computed Tomography. *Archives of Craniofacial Surgery*, 17(3), 140–145. <https://doi.org/10.7181/acfs.2016.17.3.140>

6. Kim, J., Cho, J. H., Kim, S. W., Kim, B. G., Lee, D. C., & Kim, S. W. (2010). Anatomical variation of the nasal septum: Correlation among septal components. *Clinical Anatomy*, 23(8), 945–949. <https://doi.org/10.1002/ca.21045>
7. Kim, J. H., Jung, D. J., Kim, H. S., Kim, C. H., & Kim, T. Y. (2014). Analysis of the Development of the Nasal Septum and Measurement of the Harvestable Septal Cartilage in Koreans Using Three-Dimensional Facial Bone Computed Tomography Scanning. *Archives of Plastic Surgery*, 41(2), 163. <https://doi.org/10.5999/aps.2014.41.2.163>
8. Kim, I.-S., Lee, M.-Y., Lee, K.-I., Kim, H.-Y., & Chung, Y.-J. (2008). Analysis of the Development of the Nasal Septum according to Age and Gender Using MRI. *Clinical and Experimental Otorhinolaryngology*, 1(1), 29. <https://doi.org/10.3342/ceo.2008.1.1.29>
9. Miles, B. A., Petrisor, D., Kao, H., Finn, R. A., & Throckmorton, G. S. (2007). Anatomical variation of the nasal septum: Analysis of 57 cadaver specimens. *Otolaryngology–Head and Neck Surgery*, 136(3), 362–368. <https://doi.org/10.1016/j.otohns.2006.11.047>
10. Hu, K. (2019). Anatomical Study of Nasal Septal Cartilage in Eastern Chinese. *Journal of Surgery*, 7(2), 46. <https://doi.org/10.11648/j.js.20190702.15>
11. Pernia, N. E., J. A., G., & F., V. (2011). The Dimensions of the Nasal Septal Cartilage: A Preliminary Study in Adult Filipino Malay Cadavers. *Philippine Journal Of Otolaryngology-Head And Neck Surgery*, 26(2), 10-12.
12. Kim, J.-S., Khan, N. A., Min Song, H., & Jang, Y. J. (2010). Intraoperative Measurements of Harvestable Septal Cartilage in Rhinoplasty. *Annals of Plastic Surgery*, 65(6), 519–523. <https://doi.org/10.1097/sap.0b013e3181d59f95>

**Carmen Ruiz-García<sup>1</sup>**, Blanca Mateos-Serrano<sup>1</sup>, Claudia García-Vaz<sup>2</sup>, María González<sup>1</sup>, Javier Gavilán<sup>1</sup>

<sup>1</sup>Otolaryngology Department, Hospital Universitario La Paz, Madrid, Spain., <sup>2</sup>Public Health Department, Hospital Universitario La Paz, Madrid, Spain

Poster Session, 26 Sept – 30 Sept, 2021, All day

**Background:** Nasal myiasis is extremely uncommon in developed countries. There are some predisposing conditions such as atrophic rhinitis or immunosuppression.

**Results:** A case of a 78 year-old patient with nasal myiasis caused by *Wohlfahrtia magnifica* that started one week after he was admitted to the Intensive Care Unit is here described. Through our literature search, we found no consensus on the most effective treatment for this kind of infestation. In this case, we opted to extract the maggots and subsequently administrate ivermectin and saline solution irrigations with good results.

**Conclusions:** Nasal myiasis is a rare infectious disease in our setting. Endoscopic assisted extraction, treatment with ivermectin and saline rinses are successful treatments. To our knowledge, this is the first case of nasal myiasis in mainland Spain.

Key words: Nose Diseases; Myiasis; Ivermectin; *Wohlfahrtia Magnifica*

#### Literature

- [1] Duque CS, Marrugo G, Valderrama R. Otolaryngic manifestations of myiasis. *Ear, nose, & throat journal*. 1990;69(9):619-22.
- [2] Sayeed A, Ahmed A, Sharma SC, Hasan SA. Ivermectin: A Novel Method of Treatment of Nasal and Nasopharyngeal Myiasis. *Indian journal of otolaryngology and head and neck surgery : official publication of the Association of Otolaryngologists of India*. 2019;71(Suppl 3):2019-24.
- [3] Sante Fernández L, Hernández-Porto M, Tinguaro V, Lecuona Fernández M. Ophthalmomyiasis and nasal myiasis by *Oestrus ovis* in a patient from the Canary Islands with uncommon epidemiological characteristics. *Enfermedades infecciosas y microbiología clínica*. 2017;35(7):461-2.
- [4] Diaz JH. Myiasis and Tungiasis. In: Bennett JEMD, Dolin RMD, Blaser MJMD, editors. *Mandell, Douglas, and Bennett's Principles and Practice of Infectious Diseases* 2020. p. 3492-6.e1.
- [5] Lee YT, Chen TL, Lin YC, Fung CP, Cho WL. Nosocomial nasal myiasis in an intubated patient. *Journal of the Chinese Medical Association : JCMA*. 2011;74(8):369-71.
- [6] Singh A, Singh Z. Incidence of myiasis among humans—a review. *Parasitology Research*. 2015;114(9):3183-99.
- [7] Sharma H, Dayal D, Agrawal SP. Nasal myiasis: review of 10 years experience. *The Journal of laryngology and otology*. 1989;103(5):489-91.
- [8] Pirali Kheirabadi K, Dehghani Samani A, Rajabi Vardanjani H. A report on the genital myiasis by *Wohlfahrtia magnifica* in camel herds in southwest of Iran. *Veterinary research forum : an international quarterly journal*. 2014;5(4):329-32.
- [9] Soni NK. Endoscopy in nasal myiasis. *Tropical doctor*. 2000;30(4):225-7.

## Three Dimensional printed instruments used in a Septoplasty: a new paradigm in Surgery.

**Syed M.I. Zaidi<sup>1</sup>**, Paresh Naik<sup>1</sup>, Shahzada K. Ahmed<sup>1</sup>

<sup>1</sup>*Department of Otolaryngology, Queen Elizabeth Hospital Birmingham, Birmingham, UK*

Poster Session, 26 Sept – 30 Sept, 2021, All day

**Background:** Three-dimensional (3D) printing has been rapidly adopted by different surgical disciplines. The authors present a study in which it is hypothesized that 3D printing surgical instruments can be utilized successfully within ENT surgery.

**Methodology:** As one of the most common ENT operations worldwide, a septoplasty was chosen as the procedure to provide proof of concept. For the septoplasty, five instruments were printed: a scalpel handle, needle holders, toothed forceps, a Cottle/Freer elevator and a Killian's speculum. The entire set took 224 minutes on average to print and used approximately \$1.20 USD worth of polylactic acid plastic to create.

**Results:** All steps in performing a septoplasty on a human cadaver with the 3D printed tools were possible and were undertaken successfully. This yielded a similar outcome to using stainless steel with the added benefit of a large reduction in cost and the ability for rapid customization according to the surgeon's preferences.

**Conclusions:** As technology and mainstream interest in 3D printing develops, precise computer-aided design software will allow for more complex design creation. Currently, 3D printing has been shown to be a promising method from which future surgical tools can be fashioned to meet the growing, dynamic demands of surgery.

**Keywords:**

1. Three-Dimensional printing
2. Otolaryngology
3. Surgical Instruments
4. Global Health
5. Technology

## Novel approach to sedation for sinonasal tumour excision in a high-risk patient

Saxena S<sup>1</sup>, Luthra K<sup>2</sup>, Giannitopoulos G<sup>2</sup>, **Lakhani R**<sup>1</sup>

<sup>1</sup>ENT Department, St. George's Hospital, London, UK, <sup>2</sup>Department of Anaesthetics, St. George's Hospital, London, UK

Poster Session, 26 Sept – 30 Sept, 2021, All day

Undertaking FESS procedures under local anaesthetic for tumour surgery can be challenging and is reserved for select patients.

Our patient was an 89-year gentleman who was referred with a two-month history of right-sided nasal obstruction. Examination revealed a lesion in the right sphenoid sinus extending to the right sphenoethmoidal recess, whilst the pre-operative assessment revealed early dementia and very poor cardiac function despite no documented cardiac history. A joint anaesthetic/surgical decision was made to proceed with an excisional biopsy under local anaesthetic given that further cardiac investigations were pending and could take some time.

As an alternative to the commonly used midazolam, dexmedetomidine is a selective  $\alpha_2$ -receptor agonist that provides anxiolysis, sedation and analgesia without causing or exacerbating post-operative delirium. To our knowledge, its use as the primary sedative agent during FESS has not been described in the literature.

A maximum infusion of 0.7mcg/kg/hr was achieved for optimal sedation with topical anaesthetic. The patient was fully communicative and comfortable throughout the procedure and post-operative recovery was uneventful. He was discharged the following day and histology later confirmed an adamantinoma-like Ewing sarcoma.

In conclusion, our case demonstrates that dexmedetomidine can produce excellent results in awake rhinology procedures in high-risk elderly patients.

*Key words: biopsy, anaesthetic, sedative, dexmedetomidine, delirium*

## Prevalence, demographics and clinical characteristics of patients with nasal polyposis: A population-based study using the French national claims database

Gilles Devousassoux<sup>1</sup>, Frederic de Blay<sup>2</sup>, Christian Debry<sup>3</sup>, **Petter Olsson**<sup>4</sup>, Eric Peress<sup>5</sup>, Harneet Kaur<sup>6</sup>, Celine Thonnellier<sup>7</sup>, Francois Morand<sup>8</sup>, Idir Ghout<sup>8</sup>, Claire Hutin Mierzwinski<sup>5</sup>

<sup>1</sup>Pneumology Department, Hospital of La Croix Rousse, HCL, and University Claude Bernard, Lyon, France;;

<sup>2</sup>Pneumology Department, Strasbourg University Hospital and University of Strasbourg, Strasbourg, France ;

<sup>3</sup>ENT Department, Strasbourg University Hospital, Strasbourg, France; <sup>4</sup>Novartis Sverige AB, Kista, Sweden;

<sup>5</sup>Novartis Pharma AG, Basel, Switzerland; <sup>6</sup>Novartis Healthcare Private Limited, Hyderabad, India; <sup>7</sup>Novartis Pharma, Rueil Malmaison, France; <sup>8</sup>IQVIA, Real World Solutions, La Défense, France

Poster Session, 26 Sept – 30 Sept, 2021, All day

**Background:** Published evidence on prevalence and characterization of chronic rhinosinusitis patients with nasal polyps (CRSwNP) is lacking. This study describes the epidemiology, demographics and clinical characteristics of CRSwNP patients.

**Methods:** Anonymized French national claims database (Système National des Données de Santé, SNDS) was used to identify CRSwNP patients by ICD-10-CM codes (J33 representing primary diagnosis of CRSwNP) from July 1<sup>st</sup> 2008 to December 31<sup>st</sup>, 2017. Severe CRSwNP patients were defined as those with a J33 diagnosis and who underwent a sinonasal surgery or intranasal polypectomy within the same hospital stay.

**Results:** Of approximately 48 million adult patients (≥18 years) recorded in SNDS database in 2017, the prevalence of CRSwNP was 0.19% (N=93,070) and the incidence between 2013 and 2017 was 0.020%. Among CRSwNP patients, proportion of men was higher (60%) and nearly 66% were >50 years old (mean age [SD]: 56 [15] years). A total of 42,257 (45.4%) patients had severe disease (1 surgery: >93%; ≥2 surgeries: <7%). Major comorbidities: depression, asthma and anxiety as reported in approximately 27%, 25% and 19% patients, respectively.

**Conclusions:** Prevalence of CRSwNP is significant in France and is associated with significant co-morbidities suggesting a high disease burden and need for effective and well-tolerated treatments.

**Keywords:** Prevalence, Chronic rhinosinusitis with nasal polyps, France, comorbidities, Observational

# Allergen-specific immunotherapy for local allergic rhinitis: a systematic review and meta-analysis

**Minh P. Hoang**<sup>1,2,3</sup>, Jompol Samuthpongton<sup>4</sup>, Wirach Chitsuthipakorn<sup>5,6</sup>, Kachorn Seresirikachorn<sup>1,2</sup>, Kornkiat Snidvongs<sup>1,2</sup>

<sup>1</sup>Department of Otolaryngology, Faculty of Medicine, Chulalongkorn University, Bangkok, Thailand, <sup>2</sup>Endoscopic Nasal and Sinus Surgery Excellent Center, King Chulalongkorn Memorial Hospital, Bangkok, Thailand, <sup>3</sup>Department of Otolaryngology, Hue University of Medicine and Pharmacy, Hue University, Vietnam, <sup>4</sup>Department of Anatomy, Faculty of Medicine, Chulalongkorn University, Bangkok, Thailand, <sup>5</sup>Center of Excellence in Otolaryngology-Head & Neck Surgery, Rajavithi Hospital, Bangkok, Thailand, <sup>6</sup>Department of Otolaryngology, College of Medicine, Rangsit University, Bangkok, Thailand

Poster Session, 26 Sept – 30 Sept, 2021, All day

**Background:** Local allergic rhinitis (LAR) is a phenotype of chronic rhinitis exhibiting a local Th2-driven inflammation without positive clinical markers of atopy. Immunomodulatory effects of allergen-specific immunotherapy (AIT) induce allergen-specific tolerance. However, AIT is not well-recognized as a treatment for LAR.

**Methodology/Principal:** A systematic review with meta-analysis of AIT in LAR patients was conducted. The primary outcomes were symptom score, medication score, combined symptom medication score, and disease-specific quality of life. Secondary outcomes were serum specific(s) IgG4, sIgE, and adverse events.

**Results:** Four double-blind randomised controlled trials (156 patients) assessed the effects of subcutaneous immunotherapy (SCIT). Compared with placebo, SCIT showed significant reductions in symptom score, medication score, combined symptom medication score, disease-specific quality of life, and an increase in serum sIgG4. There was no significant change in serum sIgE. Likewise, two observational studies (one using SCIT and one using sublingual immunotherapy) improved post-therapeutic symptom score. No studies assessed the effects after discontinuation of treatment. AIT was safe without serious adverse events.

**Conclusions:** AIT had beneficial effects and safe for LAR. AIT may be considered in LAR patients. Data on the long-term benefit of ILIT remain unavailable and require longer term follow-up studies.

Key words: allergen, local allergic rhinitis, immunotherapy, subcutaneous, sublingual

## Literature

1. Rondon C, Blanca-Lopez N, Aranda A, et al. Local allergic rhinitis: allergen tolerance and immunologic changes after preseasonal immunotherapy with grass pollen. *J Allergy Clin Immunol.* 2011; 127(4): 1069-1071.
2. Rondon C, Campo P, Salas M, et al. Efficacy and safety of D. pteronyssinus immunotherapy in local allergic rhinitis: a double-blind placebo-controlled clinical trial. *Allergy.* 2016; 71(7): 1057-1061.
3. Bozek A, Kolodziejczyk K, Jarzab J. Efficacy and safety of birch pollen immunotherapy for local allergic rhinitis. *Ann Allergy Asthma Immunol.* 2018; 120(1): 53-58.
4. Rondon C, Blanca-Lopez N, Campo P, et al. Specific immunotherapy in local allergic rhinitis: A randomized, double-blind placebo-controlled trial with Phleum pratense subcutaneous allergen immunotherapy. *Allergy.* 2018; 73(4): 905-915.
5. Bozek A, Winterstein J, Galuszka B, Jarzab J. Different Development Forms of Local Allergic Rhinitis towards Birch. *Biomed Res Int.* 2020; 2020: 3408561.

## Features of diagnosis and treatment of patients with inverted papilloma

D. Zabolotnyi<sup>1</sup>, D. Zabolotna<sup>1</sup>, D. Zinchenko<sup>1</sup>, I. Tsvirinko<sup>1</sup>, **Y. Kizim**<sup>1</sup><sup>1</sup>*Department of Inflammatory Diseases, “Kolomiychenko Institute of Otolaryngology of National Academy of Medical Sciences of Ukraine”, Kyiv, Ukraine*

Poster Session, 26 Sept – 30 Sept, 2021, All day

**Background:** Inverted papilloma is a benign epithelial tumor and refers to Schneider's sinonasal papilloma. Purpose of our study: To present our experience of the treatment patients with inverted sinus papilloma based on clinical and radiological features.

**Methodology:** The analysis of clinical and radiological data, the evaluation of results of the treatment of 47 patients with inverted sinus papilloma in recent years was performed.

**Results:** According to our data, inverted papilloma was found in the maxillary sinus – in 20 (42.6%), in ethmoid – in 19 (40.4%), in frontal sinus – in 6 (12.8%), in sphenoid – in 1 (2.1%) patients. Using CT, local hyperostosis, which indicated the zone of origin of the inverted papilloma, was visualized in 34 (72.3%) patients. According to MRI in T2 mode, the striped “pattern” of the tumor was determined in 39 (82.9%) cases. Recurrence of the inverted papilloma was diagnosed in 7 (18.9%) patients.

**Conclusions:** A comprehensive definition of pathognomonic radiological signs and the choice of the most optimal tactics of surgical treatment can achieve positive postoperative results and reduce the incidence of recurrence.

**Key words:** Inverted papilloma, paranasal sinuses, endoscopic sinus surgery.

**Literature:**

1. Mak W, Webb D, Al-Salihi S, Dadgostar A, Javer A. Sinonasal inverted papilloma recurrence rates and evaluation of current staging systems. *Rhinology*. 2018;56(4):407-414. doi:10.4193/rhin18.039.
2. Adriaensen G, Lim K-H, Georgalas C, Reinartz SM, Fokkens WJ. Challenges in the Management of Inverted Papilloma: A Review of 72 Revision Cases. *Laryngoscope* 2016; 126: 322–328.



## Our experience of using fat tissue for repairment of small defects of the skull base in patients with spontaneous CSF leak

D. Zabolotnyi<sup>1</sup>, D. Zabolotna<sup>1</sup>, **E. Ismagilov<sup>1</sup>**

<sup>1</sup>*Department of Inflammatory Diseases, “Kolomyichenko Institute of Otolaryngology of National Academy of Medical Sciences of Ukraine”, Kyiv, Ukraine*

Poster Session, 26 Sept – 30 Sept, 2021, All day

**Background:** Spontaneous nasal CSF leak is a life-threatening condition and characterized by the absence of a history of brain trauma or surgery in patients. Purpose of the study: to evaluate the effectiveness of the method for reconstruction of a skull base defect of the anterior cranial fossa in patients with spontaneous CSF leak using fat tissue.

**Methodology:** We have observed 35 patients with spontaneous nasal CSF leak. The size of the bone defect varied from 0.3 to 0.5 cm. A piece of fat tissue was fixed in the area of the skull base defect as an "hourglass", a layer of fibrin glue was applied on top. The second piece of fat tissue was applied on top of the first layer and was located in the nasal cavity, as a strengthening layer for the first one.

**Results:** We haven't observed a recurrence of CSF leak. All intranasal structures in the patients were preserved, since we didn't use the technique of taking mucosal flap.

**Conclusions:** The proposed technique for repairment of the CSF fistula with fat tissue in two layers ensures tight closure of the bone defect, and the dura mater defect, while preserving all intranasal structures.

**Key words:** CSF leak, repairment of CSF fistula.

## Frequency and localization of attacks in HAE patients during 2018-2019

D. Zabolotnyi<sup>1</sup>, **L. Zabrodska**<sup>1</sup>, D. Zabolotna<sup>1</sup>, I. Tsvirinko<sup>1</sup>, Y. Kizim<sup>1</sup>

<sup>1</sup>*Centre of allergic diseases of upper airways, "Kolomiychenko Institute of Otolaryngology of National Academy of Medical Sciences of Ukraine", Kyiv, Ukraine*

Poster Session, 26 Sept – 30 Sept, 2021, All day

**Background:** There are 43 HAE patients in Ukraine: 5 children, 16 men and 22 women. The aim of the study: to focus on the anamnesis, localization, severity and frequency of HAE attacks.

**Methodology:** The analysis of the patients' answers to the questionnaire from time of the first attack, date established diagnosis, frequency, severity, most frequent localization of the attacks, triggers and family anamnesis was observed.

**Results:** 30 patients indicated that they had attacks between 0-5 years old, 9 patients developed attacks in the puberty, 4 patients started suffering after 30 years old.

24 patients consider psychological and physical stress, respiratory viral infections, physical traumas, hypothermia, overheat as triggers to develop an HAE attack.

5 adults (3 men and 2 women) had upper airway attacks during 2018-2019. They were hospitalized and transfused FFP [fresh frozen plasma]. FFP was effective in all cases, the edema and pain decreased within one hour. 2 patients had rash and scleral icterus after the FFP that went back to normal in 3-5 days of antiallergic and detoxication therapy. The attacks of the peripherals were not treated because they were not life threatening.

**Conclusion:** About 10% HAE patients had signs of allergic rhinitis and facial edema.

## A novel and cost-effective technique for securing the nasal septum to the anterior nasal spine in septoplasty and/rhinoplasty surgery

**Bhamra N<sup>1</sup>**, Neamonitou F<sup>1</sup>, Darr A<sup>1</sup>, Barraclough J<sup>1</sup>

<sup>1</sup>*Department of Otolaryngology, The Royal Wolverhampton NHS Trust.*

Poster Session, 26 Sept – 30 Sept, 2021, All day

**Background:** Septoplasties and septorhinoplasties are common procedures in otolaryngology, aimed at addressing septal and/ or bony pyramidal deflections to improve functional and cosmetic outcomes. The nasal septum (NS) as well as regulating air flow provides structural support to the nasal tip. The attachment of the NS to the anterior nasal spine (ANS) must be structurally resilient to prevent saddling or tip ptosis.

**Methodology/Principal:** We describe a novel, and cost-effective alternative utilising a blunt fill needle and simple absorbable suture. A blunt fill needle (Sol-Millennium®, cost £0.03 per unit) is passed through to form a securing channel. The neoseptum is then secured using a figure-of-eight suture.

**Results:** This can be achieved by direct attachment with absorbable suture material to the periosteum of the ANS or a drill fitted with 0.6mm diamond tip burr (Ultrabur, Invotec International), to create channel through which the NS can be secured to the ANS.

**Conclusions:** Our novel technique enables the nasal septum to be secured to the anterior nasal spine in a cost effective and efficient manner.

Key words: Septoplasty, septorhinoplasty, nasal septum, anterior nasal spine (ANS), saddling

Has been presented as a poster presentation at ASIT 2018, AOT 2019, BACO 2021.

## Economic burden of patients with severe nasal polyposis in France: A population-based study using the national claims database

Frederic de Blay<sup>1</sup>, Gilles Devouassoux<sup>2</sup>, Christian Debry<sup>3</sup>, **Petter Olsson<sup>4</sup>**, Eric Peress<sup>5</sup>, Harneet Kaur<sup>6</sup>, Celine Thonnellier<sup>7</sup>, Francois Morand<sup>8</sup>, Idir Ghout<sup>8</sup>, Claire Hutin Mierzwinski C<sup>5</sup>

<sup>1</sup>Pneumology Department, Strasbourg University Hospital and University of Strasbourg, Strasbourg, France;.

<sup>2</sup>Pneumology Department, Hospital of La Croix Rousse, HCL, and University Claude Bernard, Lyon, France;.

<sup>3</sup>ENT Department, Strasbourg University Hospital, Strasbourg, France; <sup>4</sup>Novartis Sverige AB, Kista, Sweden;

<sup>5</sup>Novartis Pharma AG, Basel, Switzerland; <sup>6</sup>Novartis Healthcare Private Limited, Hyderabad, India; <sup>7</sup>Novartis Pharma, Rueil Malmaison, France; <sup>8</sup>IQVIA, Real World Solutions, La Défense, France

Poster Session, 26 Sept – 30 Sept, 2021, All day

**Background:** To quantify the economic burden of severe chronic rhinosinusitis patients with nasal polyps (CRSwNP) in France and impact of comorbid asthma.

**Methods:** Anonymized French national claims database (Système National des Données de Santé, SNDS) was used to identify CRSwNP patients by ICD-10-CM codes from July 1<sup>st</sup> 2008 to December 31<sup>st</sup>, 2017. Severe CRSwNP was defined as patients who underwent a sinonasal surgery or intranasal polypectomy. Healthcare utilization and total costs were reported and a subgroup analysis was conducted for patients with and without comorbid asthma (ICD-10 diagnosis).

**Results:** A total of 42,257 severe CRSwNP patients were included (with asthma, n=10,388; without asthma, n=31,869) with a mean (SD) age of 51.8 (14.4) years; 64.8% were male. During the 12-month follow-up, average annual total costs per patient was estimated at €3,037. Key cost drivers were: hospitalization cost (45%), treatment cost (27%) and productivity loss (12%). Use of nasal corticosteroids and oral corticosteroids was reported in approximately 74% and 60% patients, respectively. Patients with comorbid asthma incurred approximately 30% higher annual total costs compared to patients without asthma.

**Conclusion:** In France, burden of severe CRSwNP is high which increases with comorbid asthma suggesting room for improvement and new treatments with higher effectiveness.

**Keywords:** Economic burden, Healthcare resource utilization, France, Chronic rhinosinusitis with nasal polyps, Observational

## Pleomorphic adenoma of nasal septum: – Case management and literature review

**Dr Prabhsimran Kaur**<sup>1</sup>, Mr Rakesh Mistry, Dr Andrew Gallimore<sup>2</sup>, Mr Hamid Daya, Mr Raj Lakhani

<sup>1</sup>*St George's University Hospital NHS Foundation Trust, London, United Kingdom.*, <sup>2</sup>*University College London*

Poster Session, 26 Sept – 30 Sept, 2021, All day

Pleomorphic adenomas are the most common benign tumours of the salivary glands. Pleomorphic adenomas in nasal cavity are extremely rare and are often misdiagnosed, as they have higher myoepithelial cellularity in comparison to myxoid stroma. We present a case of a 45-year-old Nigerian patient with a history of left sided septal swelling slowly growing over 2 years.

The patient had a biopsy in Nigeria. Pathology there suggested a squamous cell carcinoma of the nasal septum and he was referred for wide local excision and radiotherapy. The patient presented in London for a second opinion where he had a thorough clinical, endoscopic and radiological assessment. He later went on to have full macroscopic resection of the septal lesion and subsequent histopathological examination was consistent with pleomorphic adenoma with clear margins.

Pleomorphic adenomas are rare benign tumours of the nasal septum but should be kept in the differential diagnosis. Review of the literature reveals that optimum treatment for pleomorphic adenoma consists of surgical excision with wide margins to prevent recurrence; the surgical approach used in this patient was end nasal endoscopic resection. We present a further literature review and discussion regarding management.

**Key words:** Benign tumour; case report; nasal septum; pleomorphic adenoma; salivary gland

## Use Of 3D Infrared Laser In Rhinoplasty Evaluation And Follow-Up.

**Tali Teitelbaum**<sup>1</sup>, Isaac Shochat<sup>1</sup>, Mohamad Taha<sup>1</sup>, Izhak Braverman<sup>1</sup>.

*Otolaryngology, Head & Neck Surgery Department, Hillel Yaffe Medical Center, Hadera, Israel.*

Poster Session, 26 Sept – 30 Sept, 2021, All day

**Background:** While rhinoplasty techniques has flourished with innovation and new surgical methods, the common practice for documenting the patient's nose in rhinoplasty has not change. The common practice is to take five views pictures with professional Camera.

Meanwhile almost each one of us carry a smart phone which is capable of taking portrait pictures as well as inclusion of an infrared-(IR) laser for facial recognition. We set to assess the feasibility of device such as this in evaluation and follow-up of rhinoplasty surgery

**Methodology:** During 2021 we've integrated the use of a 3D-IR photoshoots using iPhone® 11/12 and the app "Capture: 3D scan Anything" by Standard Cyborg (2019) before, and one month following the rhinoplasty. We have discussed with the patients and surgeons regarding their expectation, the outcome and the possibility of improvements using the 3D-model.

**Results:** Six patients were documented before the operation using the 3D-IR laser. Using the 3D-model, the nose shape and its deformities was discussed, and the ability for the best approach to attain tangible results.

**Conclusions:** The 3D-modeling app enables a multi-dimensional evaluation of the surgical problem, suggesting best approach for the surgical problem and allows an open discussion regarding the surgery and its result.

Key words: Rhinoplasty, infrared, 3D, iPhone

## Mepolizumab reduces the need for surgery in patients with chronic rhinosinusitis with nasal polyps

**Wytske J. Fokkens**<sup>1</sup>, Joaquim Mullol<sup>2</sup>, David Kennedy<sup>3</sup>, Carl Philpott<sup>4,5</sup>, Veronica Seccia<sup>6</sup>, Robert C. Kern<sup>7</sup>, André Coste<sup>8</sup>, Ana R. Sousa<sup>9</sup>, Peter H. Howarth<sup>10,11</sup>, Victoria S. Benson<sup>12</sup>, Bhabita Mayer<sup>13</sup>, Steve W. Yancey<sup>14</sup>, Robert Chan<sup>9</sup>, Simon B. Gane<sup>15,16</sup>

<sup>1</sup>Department of Otolaryngology, University of Amsterdam, Amsterdam, Netherlands; <sup>2</sup>Department of Otorhinolaryngology, Hospital Clinic, IDIBAPS, Universitat de Barcelona, CIBERES, Barcelona, Catalonia, Spain; <sup>3</sup>Department of Otorhinolaryngology: Head and Neck Surgery, Perelman School of Medicine, University of Pennsylvania, Philadelphia, PA, USA; <sup>4</sup>Norwich Medical School, University of East Anglia, Norwich, UK; <sup>5</sup>Norfolk & Waveney Ear Nose & Throat Service, James Paget University Hospitals NHS Foundation Trust, Great Yarmouth, UK; <sup>6</sup>ENT Unit, Department of Neuroscience, Azienda Ospedaliero-Universitaria Pisana, Pisa, Italy; <sup>7</sup>Department of Medicine and Department of Otolaryngology, Northwestern University Feinberg School of Medicine, Chicago, IL, USA; <sup>8</sup>Service d'ORL et de Chirurgie Cervico-faciale Centre, Hospitalier Intercommunal de Creteil, et APHP, Groupe Hospitalier Henri Mondor-Albert Chenevier, Université Paris-Est Creteil, Creteil, France; <sup>9</sup>Clinical Sciences, Respiratory, GSK, GSK House, Brentford, UK; <sup>10</sup>Clinical and Experimental Sciences, Faculty of Medicine, University of Southampton and NIHR Respiratory Biomedical Research Unit, Southampton General Hospital, Southampton, UK; <sup>11</sup>Global Respiratory Franchise, GSK House, Brentford, Middlesex, UK; <sup>12</sup>Epidemiology, Value Evidence and Outcomes, GSK House, Brentford, UK; <sup>13</sup>Clinical Statistics, GSK Stockley Park West, Uxbridge, Middlesex, UK; <sup>14</sup>Respiratory Medical Franchise, GSK, Research Triangle Park, NC, USA; <sup>15</sup>Department of Rhinology, Royal National ENT Hospital, University College London Hospitals NHS Foundation Trust, London, UK; <sup>16</sup>UCL Ear Institute, University College London, London, UK.

Poster Session, 26 Sept – 30 Sept, 2021, All day

**Background:** The impact of mepolizumab on the need for repeat endoscopic sinus surgery (ESS) in CRSwNP was assessed.

**Methodology/Principal:** SYNAPSE (NCT03085797) methodology has been reported. Patients had  $\geq 1$  ESS in the past 10 years and qualified for repeat ESS. Patients received 4-weekly subcutaneous mepolizumab 100 mg or placebo, plus standard of care (SoC), for 52 weeks. We assessed the proportion of patients requiring ESS (visual analog scale overall symptom score  $> 7$ ; endoscopic bilateral NP score  $\geq 5$ ), time to inclusion on a waiting list for ESS (Kaplan–Meier estimate), and patients included on a waiting list by Week 52.

**Results:** Data from 407 patients (placebo  $n=201$ ; mepolizumab  $n=206$ ) were analyzed. After 52 weeks, more patients using mepolizumab (72%) vs placebo (51%) were identified as not needing ESS (odds ratio [95% confidence interval] 2.46 [1.59, 3.79];  $P < 0.001$ ). Kaplan–Meier estimates indicated a  $\sim 50\%$  lower risk of inclusion on a waiting list for ESS with mepolizumab than placebo. Up to Week 52, 16% versus 30% of patients using mepolizumab versus placebo were on a waiting list for ESS.

**Conclusions:** Subcutaneous Mepolizumab 100 mg reduces the need for repeat surgery versus placebo for recurrent CRSwNP despite SoC therapy.

Funding: GSK [205687/NCT03085797]. Previously presented at ARS/COSM 2021.

**Key words:** Mepolizumab, Surgery, Nasal Polyps, Rhinosinusitis

## Postoperative intranasal packing and splinting – effectiveness, patient's comfort, clinical outcomes

**P. Ivanova<sup>1,3</sup>**, G. Iliev<sup>2,3</sup>

<sup>1</sup>ENT Department, Saint Anna Hospital, Varna, Bulgaria, <sup>2</sup>ENT Department, Saint Marina Hospital, Varna, Bulgaria, <sup>3</sup>Medical University of Varna, Bulgaria

Poster Session, 26 Sept – 30 Sept, 2021, All day

**Background:** Nasal packing and splinting after Septoplasty are used as standard procedure. The aim of this study was to compare patient satisfaction and clinical outcome associated with gauze nasal packing and silicone intranasal splints following septoplasty.

**Methodology/Principal:** In total, 25 patients were included in a prospective study. All patients underwent septoplasty and were divided into two groups – group one had only silicone splints and group two had both nasal packing and splints. On the first, 7<sup>th</sup> and 30<sup>th</sup> postoperative day, the patients were questioned with the aid of visual analog scale, as three variables were investigated: 1 – pain, 2 – nasal fullness, 3 – bleeding after removal. The patients were also examined for postoperative complications, such as bleeding, formation of synechia or septal hematoma. Before and after the surgical intervention a saccharin transit time test was performed for evaluation of the mucociliary function.

**Results:** The mean visual analog scale was lower in the group having only silicone splints than in the group with both nasal packing and splints.

**Conclusions:** Regarding surgical outcome septoplasty can be safely performed without postoperative intranasal packing. Placement of silicone splints only is enough for prevention of postoperative complications and is more patient friendly than having both intranasal packing and silicone splints. Still in few cases intranasal packing is necessary due to intraoperative bleeding.

Key words: Septoplasty; Nasal packing; Silicone splints



## Atmospheric Particulate Matter: pro-inflammatory response on in vitro 3D nasal epithelium

Marisa Meloni<sup>1</sup>, Barbara De Servi<sup>1</sup>, Laura Ceriotti<sup>1</sup>, **Noemie Durand<sup>2</sup>**, Amina Saaid<sup>2</sup>

<sup>1</sup>*VitroScreen In Vitro Innovation Center, Milan, Italy*, <sup>2</sup>*Laboratoire Fumouze, 110-114 rue Victor Hugo, 92686, Levallois-Perret, France*

Poster Session, 26 Sept – 30 Sept, 2021, All day

**Background:** Fine particulate matter is among the outdoor air pollutants that causes adverse effects in humans at respiratory level; the cascade of multiple side effects starts from the impairment of the upper respiratory airways. The aim of this study was to demonstrate the induction of an inflammatory reaction on an in vitro 3D model (three batches of MucilAir™ tissues) following exposure to particulate matter (particle size <4 µm).

**Methodology/Principal:** Inflammation has been investigated by quantifying changes in IL-8 levels as pro-inflammatory cytokine, CCL-20 levels as pro-inflammatory cytokine driving Th-2 activation, and human beta-defensin-2 (hBD-2) levels as an indicator of innate immunity and inflammation activation.

**Results:** After 48h exposure to particulate matter (300µg/mL), significantly increased levels of IL-8 (>73% for all three batches tested), CCL-20 (>119% for 2 batches tested) and hBD-2 release (>60% for all three batches tested) have been observed.

**Conclusions:** These results suggest that particulate matter exposure causes inflammation in nasal epithelium tissues, thus modifying its physiological status. The experimental setting could provide a promising tool to explore preventive strategies to counteract nasal epithelium weakness, damage and impaired physiology due to exposure to environmental stressors such as particulate matter.

Key words: Particulate matter; nasal epithelium; pollution; inflammation.

# Sinonasal malignancy in a patient with history of oncocytic papilloma of the nose: a case report

**Athanasia Tourgeli<sup>1</sup>**, Panagiotis Pyrgakis<sup>1</sup>, **Alexandra Kovacs<sup>1</sup>**, Nikolaos Drimalas<sup>1</sup>, Sotirios Botsakis<sup>1</sup>

<sup>1</sup>General Hospital “Evangelismos”

Poster Session, 26 Sept – 30 Sept, 2021, All day

**Background:** Nasal papillomas are benign nasal tumors. They account for 0.5-4% of primary nasal tumor, they are rare among children and young adults and they can be distinguished from nasal polyps only through biopsy. There are three types of papillomas: inverse, fungiform and oncocytic.

**Methodology/Principal:** An 82 year old patient underwent endoscopic nasal surgery for nasal polyposis. Histology showed oncocytic papilloma of nasal epithelium. After 18 months being negative for recurrence, the patient dropped out of the follow-up. 4 years postoperatively the patient presented unilateral nasal congestion, rhinoscopy revealed a large smooth lesion of the right nasal cavity, but biopsy was indeterminate among salivary gland, undifferentiated and non-enteric type carcinoma. MRI revealed a tumor of the right nasal cavity eroding the medial orbital wall, in contact with the right optical nerve and medial rectus muscle, eroding the frontal sinus floor and extending at the anterolateral wall of the nasopharynx. The patient underwent endoscopic sinus surgery with complete excision of the mass and histology was positive for low differentiated malignant salivary gland tumor.

**Results:** Oncocytic papillomas are rare benign nasal tumors with a high rate of recurrence and a tendency of malignant transformation. These reasons dictate total excision of the mass and a prolonged follow-up.

## Conclusions:

Key words: oncocytic papilloma, carcinoma, endoscopic surgery, nasal tumor

## Literature

1. Lilja M, Viitasalo S, Hytönen M, Haapaniemi A, Hagström J, Mäkitie A. [SinonasalOncocytic Papilloma-A Series of 20 Cases With Special Emphasis on Recurrences](#). Laryngoscope Investig Otolaryngol. 2019 Dec;4(6):567-572.
2. Zhang L, Hu C, Zheng X, Wu D, Sun H, Yu W, Wu Y, Chen D, Lv Q, Zhang P, Li X, Liu H, Wei Y. [OncocyticSchneiderian papilloma-associated adenocarcinoma and KRAS mutation: A case report](#). Medicine (Baltimore). 2018 Jun;97(23):e11025
3. Jeong HJ, Roh J, Lee BJ, Cho KJ. [Low-Grade Papillary Schneiderian Carcinoma: A Case Report](#). Head Neck Pathol. 2018 Mar;12(1):131-135.
4. Leoncini G, Zanetti L. [Thepapillomas of the sinonasal tract. A comprehensive review](#). Pathologica. 2017 Mar;109(1):31-34
5. Bullock MJ. [Low-Grade Epithelial Proliferations of the Sinonasal Tract](#). Head Neck Pathol. 2016 Mar;10(1):47-59
6. Karligkiotis A, Bignami M, Terranova P, Gallo S, Meloni F, Padoan G, Lombardi D, Nicolai P, Castelnovo P. [OncocyticSchneiderianpapillomas: Clinical behavior and outcomes of the endoscopic endonasal approach in 33 cases](#). Head Neck. 2014 May;36(5):624-30
7. Darwish A, Al-Abdulla A. [Cylindrical Cell Papilloma \(OncocyticSchneiderian Papilloma\): Clinicopathological Study of Five Cases](#). Oman Med J. 2012 Sep;27(5):e039
8. Bignami M, Pistochini A, Meloni F, Delehay E, Castelnovo P. [A rare case of oncocyticSchneiderian papilloma with intradural and intraorbital extension with notes](#)

- of operative techniques. *Rhinology*. 2009 Sep;47(3):306-320
9. Saliba MC, Freitas VA, Moraes EC, Barros FL, Guimarães RE. [Oncocytic papilloma](#). *Braz J Otorhinolaryngol*. 2009 Mar-Apr;75(2):317.
  10. Olusina D, Nzegwu MA, Okoroafor IJ. [OncocyticSchneiderian papilloma occurring in a young Nigerian male: a case report](#). *Ann Afr Med*. 2008 Jun;7(2):91-3
  11. Cheng TY, Ueng SH, Chen YL, Chang KP, Chen TM. [Oncocytischneiderian papilloma found in a recurrent chronic paranasal sinusitis](#). *Chang Gung Med J*. 2006 May-Jun;29(3):336-41
  12. Liu CY, Tsai TL, Hsu CY, Lin CZ. [OncocyticSchneiderian papilloma](#). *J Chin Med Assoc*. 2004 May;67
  13. Maitra A, Baskin LB, Lee EL. [Malignancies arising in oncocytischneiderianpapillomas: a report of 2 cases and review of the literature](#). *Arch Pathol Lab Med*. 2001 Oct;125(10):1365-7

## The problem of restenosis in the surgical treatment of congenital atresia of the choan in children.

M. R. Bogomilsky<sup>1</sup>, E. Yu. Radtsig<sup>1</sup>, E. N. Kotova<sup>1</sup>, E.O.Vyaz'menov<sup>1</sup>

<sup>1</sup>ENT pediatric department, Pirogov Russia National research medical University? Moscow, Russia

Poster Session, 26 Sept – 30 Sept, 2021, All day

**Background:** The frequency of restenosis after congenital choanal atresia (CCA) surgery is quite high (up to 52%). Our aim was to prevent restenosis in CCA surgery patients.

**Methodology/Principal:** 94 CCA children aged from 1 month to 17 years were examined: 59 (62.8%) girls and 35 (37.2%) boys, primary patients - 77 (82%) and with restenosis - 17 (18%). All patients underwent transnasal endoscopic choanotomy after which stents with an enlarged distal zone (SEDZ) were used in 61 children (64.9%), stents from modified endotracheal tubes (SMET) in 13 children (13.8%) and no stents in 20 children (21.3%) over 4 years old. To avoid restenosis, we used carboxymethyl cellulose sodium salt gel (CCSSG) (made in Russia) in 51 (54, 3%) patients for nasal mucosa application: in 19 (20.2%) initially operated patients after stent removal; in 20 (21.3%) initially operated by stents during surgery and during the early postoperative period and in 12 restenosis patients as well as in the intraoperative and early postoperative period. All patients underwent nasal endoscopy after 24 hours, 7 days and 1 year.

**Results:** According to the endoscopic data in the follow-up (1-9 years) restenosis was revealed in 3 (3.2%) patients where only SMET were used. There was no restenosis in cases where both SEDZ and CCSSG were used.

**Conclusion:** The use of endoscopic techniques, SEDZ and CCSSG during the intra- and postoperative period help us to prevent restenosis after CCA surgery.

Key words: congenital choanal atresia, restenosis after congenital choanal atresia, endoscopic surgery, transnasal endoscopic choanotomy, children and infants

# Association between burden of illness, asthma and surgery in chronic rhinosinusitis with nasal polyps: results from a real-world survey in Europe

Victoria S Benson<sup>1</sup>, Shibing Yang<sup>2</sup>, Robert H Chan<sup>3</sup>, Ana R Sousa<sup>3</sup>, Gary Milligan<sup>4</sup>, Alex Bennett<sup>4</sup>, Mark Small<sup>4</sup>

<sup>1</sup>*Epidemiology, Value Evidence and Outcomes, GSK, Brentford, UK;* <sup>2</sup>*Value Evidence and Outcomes, GSK, Collegeville, PA, USA;* <sup>3</sup>*Clinical Sciences, Respiratory, GSK, Brentford, UK;* <sup>4</sup>*Adelphi Real World, Bollington, UK.*

**Background:** Real-world burden of illness research in chronic rhinosinusitis with nasal polyps (CRSwNP) in Europe is limited.

**Methodology:** The point-in-time Adelphi CRSwNP Disease Specific Programme (March–July 2019) surveyed physicians and adult patients with moderate-to-severe CRSwNP across 5 European countries. Physician- and patient-reported demographics, clinical characteristics, surgical history, Sino-Nasal Outcome Test (SNOT-22) scores and NP-related healthcare professional (HCP) visits (prior 12 months) were assessed, stratified by prior NP surgery and asthma comorbidity.

**Results:** Patients with moderate-to-severe CRSwNP were surveyed (n=1127). As number of prior surgeries increased (0/≥1/≥2), mean (standard deviation [SD]) age (43.3[14.5]/48.0[14.5]/52.1[14.5] years), proportions of patients with asthma comorbidity (32%[n=196/607]/46%[n=234/508]/53%[n=77/146]) or aspirin-exacerbated respiratory disease (3%[n=17/554]/16%[n=72/460]/28%[n=38/136]) and geometric-mean (SD) blood eosinophil counts (BEC; 202.1[4.3]/292.4[4.4]/353.0[3.5] cells/μL) were higher. Patients with asthma had higher geometric-mean (SD) BEC (265.6[5.0] cells/μL) and number of prior surgeries (38%[n=118/314]) than those without (211.2[3.5] cells/μL, 17%[n=77/468], respectively). Higher mean (SD) SNOT-22 scores were associated with higher prior surgery number (0/≥1/≥2:37.2[21.4]/44.0[21.4]/51.3[20.0]) and asthma comorbidity (with/without:48.3[19.7]/33.7[20.7]); this trend was similar for mean (SD) number of HCP visits (0/≥1/≥2:3.7[2.6]/4.8[4.0]/4.8[3.9]; with/without:4.5[3.8]/3.8[2.6], respectively).

**Conclusions:** European patients recalcitrant to surgery or with comorbid asthma were associated with higher BEC and healthcare resource utilisation, and worse health-related quality of life than those without surgery or comorbid asthma.

**Funding:** GSK[ID:213369]

**Key words:** Comorbidity, Europe, nasal polyps, quality of life, sinusitis.

# Baseline medical histories and cough characteristics of patients enrolled in phase 3 trials of gefapixant for refractory or unexplained chronic cough

**K.W. Altman<sup>1</sup>**, L. McGarvey<sup>2</sup>, S.S. Birring<sup>3</sup>, P. Dicpinigaitis<sup>4</sup>, A. Morice<sup>5</sup>, I. Pavord<sup>6</sup>, J.A. Smith<sup>7</sup>, B. Iskold<sup>8</sup>, Q. Li<sup>8</sup>, A. Martin Nguyen<sup>8</sup>, J. Schelfhout<sup>8</sup>, A. Tzontcheva<sup>8</sup>, C. La Rosa<sup>8</sup>, D. Muccino<sup>8</sup>

<sup>1</sup>Department of Otolaryngology - Head & Neck Surgery, Geisinger Health System, Danville, PA, USA;

<sup>2</sup>Wellcome-Wolfson Institute for Experimental Medicine, Queen's University Belfast, Belfast, Northern Ireland;

<sup>3</sup>Centre for Human & Applied Physiological Sciences, School of Basic & Medical Biosciences, Faculty of Life Sciences & Medicine, King's College London, London, UK; <sup>4</sup>Albert Einstein College of Medicine & Montefiore Medical Center, Bronx, NY, USA; <sup>5</sup>Hull York Medical School, Cottingham, UK; <sup>6</sup>Oxford NIHR Respiratory BRC, Nuffield Department of Medicine, University of Oxford, Oxford, UK; <sup>7</sup>Division of Infection, Immunity & Respiratory Medicine, University of Manchester & Manchester University NHS Trust, Manchester, UK; <sup>8</sup>Merck & Co., Inc., Kenilworth, NJ, USA

Poster Session, 26 Sept – 30 Sept, 2021, All day

**Background:** This analysis reports baseline medical history, cough severity, and cough-related quality of life (QOL) from a pooled data set of participants with refractory or unexplained chronic cough (RCC and UCC, respectively) enrolled in one of two phase 3 trials of gefapixant (COUGH-1, COUGH-2).

**Methodology/Principal:** Participants were adults experiencing cough for  $\geq 1$  year with diagnosis of RCC or UCC and baseline cough severity score  $\geq 40$  mm on 100-mm visual analog scale (VAS). Medical records were used to assess medical history. Cough was characterised using the Leicester Cough Questionnaire (LCQ) and Cough Severity Diary (CSD).

**Results:** Of 2044 participants, 41%, 41%, and 29% had diagnoses of asthma, gastroesophageal reflux disease, and rhinitis/upper-airway cough syndrome, respectively; 8% had all 3. Median baseline 24-hour cough frequency was 21 coughs/hour; mean cough severity VAS score was 68 mm. Prior medications included drugs for obstructive airway diseases (70%), acid-related disorders (55%), rhinitis (nasal preparations, 53%; systemic antihistamines, 35%), and cough/cold preparations (34%). Of participants with baseline CSD (n=2038) and LCQ (n=1949) scores, mean scores were 6.0/10.0 and 10.4/21.0, respectively.

**Conclusions:** Medical histories were consistent with RCC or UCC diagnoses. Cough was severe and significantly affected QOL. These data characterise patients with RCC or UCC who would benefit from treatment.

**Key words:** quality of life; patient reported outcome measures; cough; gefapixant; clinical trial, phase 3

**Encore:** This abstract is an encore from the 2021 Winter Meeting of the British Thoracic Society.

## Patient-reported outcomes following treatment with gefapixant, a P2X3-receptor antagonist, for refractory or unexplained chronic cough

**J. Mullol**<sup>1</sup>, S.S. Birring<sup>2</sup>, P. Dicpinigaitis<sup>3</sup>, A. Morice<sup>4</sup>, J.A. Smith<sup>5</sup>, L. McGarvey<sup>6</sup>, I. Pavord<sup>7</sup>, B. Iskold<sup>8</sup>, A. Martin Nguyen<sup>8</sup>, J. Schelfhout<sup>8</sup>, A. Tzontcheva<sup>8</sup>, Q. Li<sup>8</sup>, C. La Rosa<sup>8</sup>, D. Muccino<sup>8</sup>

<sup>1</sup>Rhinology Unit & Smell Clinic, ENT Department, Hospital Clinic-Clinical & Experimental Respiratory Immunology IDIBAPS, CIBERES, Universitat de Barcelona, Barcelona, Spain; <sup>2</sup>Centre for Human & Applied Physiological Sciences, School of Basic & Medical Biosciences, Faculty of Life Sciences & Medicine, King's College London, London, UK; <sup>3</sup>Albert Einstein College of Medicine & Montefiore Medical Center, Bronx, NY, USA; <sup>4</sup>Hull York Medical School, Cottingham, UK; <sup>5</sup>Division of Infection, Immunity & Respiratory Medicine, University of Manchester & Manchester University NHS Trust, Manchester, UK; <sup>6</sup>Wellcome-Wolfson Institute for Experimental Medicine, Queen's University Belfast, Belfast, Northern Ireland; <sup>7</sup>Oxford NIHR Respiratory BRC, Nuffield Department of Medicine, University of Oxford, Oxford, UK; <sup>8</sup>Merck & Co., Inc., Kenilworth, NJ, USA

Poster Session, 26 Sept – 30 Sept, 2021, All day

**Background:** In two phase 3 randomized trials (COUGH-1, COUGH-2), gefapixant 45 mg twice daily (BID) significantly reduced 24-hour cough frequency in participants with refractory or unexplained chronic cough (RCC and UCC, respectively). This analysis reports pooled patient-reported outcome (PRO) data from these studies.

**Methodology/Principal:** Adults with cough lasting  $\geq 1$  year and diagnosis of RCC or UCC were enrolled. Predefined responder criteria for each PRO included  $\geq 1.3$ -point increase on Leicester Cough Questionnaire (LCQ) total score,  $\geq 30$ -mm reduction on cough severity visual analog scale (VAS), and  $\geq 1.3$ -point and  $\geq 2.7$ -point reduction on mean weekly Cough Severity Diary (CSD) total score. Logistic regression models evaluated response rates at Weeks 12 and 24.

**Results:** 2044 participants were included. Odds ratios (95% CI) for each responder endpoint favoured gefapixant 45 mg BID at both timepoints: LCQ (Week 12: 1.42 [1.11, 1.83]; Week 24: 1.37 [1.06, 1.77]), VAS (Week 12: 1.53 [1.21, 1.93]; Week 24: 1.70 [1.34, 2.16]), CSD<sub>1.3</sub> (Week 12: 1.33 [1.05, 1.67]; Week 24: 1.47 [1.14, 1.90]), and CSD<sub>2.7</sub> (Week 12: 1.49 [1.18, 1.89]; Week 24: 1.70 [1.33, 2.16]).

**Conclusions:** Reduction of 24-hour cough frequency with gefapixant 45 mg BID is further supported by improvements in cough-specific quality of life and patient-reported cough severity in RCC and UCC.

**Key words:** purinergic P2X receptor antagonists; antitussive agents; cough; gefapixant; clinical trial, phase 3

**Encore:** Data in this abstract were previously presented at the 2021 American Thoracic Society Annual Meeting (Birring et al. Am J Respir Crit Care Med. 2021;203:A2354).

## Objective cough frequency in two phase 3 clinical trials of gefapixant for chronic cough

**I. Satia**<sup>1,4</sup>, J.A. Smith<sup>4</sup>, A. Morice<sup>5</sup>, L. McGarvey<sup>6</sup>, I. Pavord<sup>7</sup>, S.S. Birring<sup>8</sup>, P. Dicpinigaitis<sup>9</sup>, B. Iskold<sup>10</sup>, Q. Li<sup>10</sup>, A. Tzontcheva<sup>10</sup>, C. La Rosa<sup>10</sup>, D. Muccino<sup>10</sup>

<sup>1</sup>Department of Medicine, McMaster University, Hamilton, ON, CA; <sup>2</sup>Firestone Institute for Respiratory Health, St Joseph's Healthcare, Hamilton, ON, CA; <sup>3</sup>Centre for Respiratory Medicine & Allergy, University of Manchester & Manchester Academic Health Science Centre, Manchester, UK; <sup>4</sup>Division of Infection, Immunity & Respiratory Medicine, University of Manchester & Manchester University NHS Trust, Manchester, UK; <sup>5</sup>Hull York Medical School, Cottingham, UK; <sup>6</sup>Wellcome-Wolfson Institute for Experimental Medicine, Queen's University Belfast, Belfast, Northern Ireland; <sup>7</sup>Oxford NIHR Respiratory BRC, Nuffield Department of Medicine, University of Oxford, Oxford, UK; <sup>8</sup>Centre for Human & Applied Physiological Sciences, School of Basic & Medical Biosciences, Faculty of Life Sciences & Medicine, King's College London, London, UK; <sup>9</sup>Albert Einstein College of Medicine & Montefiore Medical Center, Bronx, NY, USA; <sup>10</sup>Merck & Co., Inc., Kenilworth, NJ, USA

Poster Session, 26 Sept – 30 Sept, 2021, All day

**Background:** In two separate phase 3 clinical trials (COUGH-1, COUGH-2), the P2X3-receptor antagonist gefapixant reduced 24-hour cough frequency in participants with refractory or unexplained chronic cough (RCC and UCC, respectively). This analysis assessed objective cough frequency in the pooled population from both trials.

**Methodology/Principal:** Both trials included adults with chronic cough lasting  $\geq 1$  year and diagnoses of RCC or UCC randomised to placebo, gefapixant 15 mg twice daily (BID), or gefapixant 45 mg BID. A VitaloJAK<sup>TM</sup> recording device measured objective 24-hour and awake cough frequency through Week 12 (COUGH-1) and Week 24 (COUGH-2). Pooled data across both trials were analysed at Week 12 using longitudinal analysis of covariance on log-transformed data.

**Results:** Of 2044 randomised and treated participants, baseline cough frequency was similar between treatment groups. Gefapixant 45 mg BID resulted in placebo-adjusted estimated relative reductions in 24-hour and awake cough frequency of -18.6% (95% CI: -27.1, -9.2) and -17.4% (95% CI: -26.2, -7.5), respectively. The most common gefapixant-associated adverse events (AEs) were taste related, with no differences in serious AEs between treatment groups.

**Conclusions:** Gefapixant 45 mg BID demonstrated clinically important reductions in cough frequency compared with placebo in the largest analysis of chronic cough to date, without an increase in serious AEs.

Key words: cough; gefapixant, antitussive agents; purinergic P2X receptor antagonists; clinical trial, phase 3

**Encore:** This abstract is an encore of the 2021 American Thoracic Society International Conference ("Objective Cough Frequency with Gefapixant in Chronic Cough: A Pooled Analysis of Two Phase 3 Randomized, Controlled Clinical Trials [COUGH-1 and COUGH-2]"; abstract ID, A2353).



## Giant Cell Tumor of the Maxillary Sinus : an unusual location

**Dr A.Trimoska-Radevska**, Dr M.Jurlina, Dr R.Filipovski,

*Department of ENT, City Hospital 8<sup>th</sup> of September, Skopje, Rep. of Macedonia  
Department of Maxillofacial Surgery, Clinical Hospital "Dubrava", Rep. of Croatia*

*Poster Session, 26 Sept – 30 Sept, 2021, All  
day*

A **giant cell tumor** is a rare aggressive benign tumor. It mostly affects the long bones of the extremities, mainly at their epiphyses. Craniofacial location is very uncommon, especially in the maxilla. Giant cell tumors most commonly occur in young adults after the cessation of skeletal bone growth. The exact etiopathogenesis of giant cell tumors remains unknown. Although giant cell tumors are not malignant tumors, they may act in a destructive manner to neighbouring tissue and they are prone to recur.

In this presentation we are presenting a patient with the swelling in the region of the maxilla, accompanied with pain in the cheek and the eye. On CT and MRI scans, an expanding soft tissue in the maxillary sinus is detected with the destruction of the orbital floor and medial wall of the maxillary sinus. The biopsy was performed and, after the histopathological analysis, Giant Cell Tumor was diagnosed.

The decision of the tumor board was that the tumor should be surgically treated. Surgical treatment was at the beginning performed in an endoscopic manner but, because of the tumor adherence to the periorbit, it had to be combined with a Caldwell – Luc procedure. After the completion of the surgical procedure, histological analysis of the resected tumor tissue confirmed the preliminary diagnosis. Two-years clinical and radiological follow up has been uneventful, without the signs of recurrence.

An underdiagnosed condition? Prevalence estimates of self-reported chronic cough among Spanish adults and frequency of those diagnosed

Domínguez-Ortega J.<sup>1</sup>, Plaza V.<sup>2</sup>, Li V.W.<sup>3</sup>, Fonseca E.<sup>4</sup>, Martin A.<sup>3</sup>, Brady J.E.<sup>4</sup>, Schelfhout J.<sup>4</sup>, Arteaga M.J.<sup>5</sup>, **Julia De Páramo B.**<sup>5</sup>, Cea-Calvo L.<sup>5</sup>

<sup>1</sup>Allergy Department, University Hospital La Paz, Madrid, Spain, <sup>2</sup>Pulmonology Department, University Hospital de la Santa Creu i Sant Pau, Barcelona, Spain, <sup>3</sup>Kantar LLC, London, United Kingdom, <sup>4</sup>Center for Observational and Real-world Evidence, Merck & Co., Inc, Kenilworth, NJ, United States, <sup>5</sup>Medical Affairs, MSD, Madrid, Spain

Poster Session, 26 Sept – 30 Sept, 2021, All day

**Background:** We estimated prevalence of chronic cough (CC) in Spanish adults and the proportion diagnosed with CC by a physician.

**Method:** A web-based survey (National Health and Wellness Survey) was administered in 2020 to a Spanish general population with strata by sex and age representative of Spanish adults. CC was defined as daily cough  $\geq 8$  weeks. Weighted prevalence of CC, anytime during one's life and CC in the past 12-months, were estimated using Horvitz-Thompson method.

**Results:** Of 7,074 respondents (mean age 46.6 years, 51% female), 579 self-reported CC in their lifetime. Weighted lifetime CC prevalence was 8.2% (~3.3 million adults); prevalence did not vary significantly by sex. In the past year, 389 respondents (mean age 45.1 years, 57% female) reported CC. Weighted annual CC prevalence was 5.5% (~2.2 million adults); prevalence was slightly higher among women than men (6.0% vs 4.9%,  $p=0.049$ ). Only 39% and 44% of respondents with CC in their lifetime and in the past year, respectively, had been diagnosed by a physician.

**Conclusion:** Lifetime and annual prevalence estimates of self-reported CC were 8.2% and 5.5%, respectively, but less than half had received a diagnosis of CC by a physician, suggesting that CC is underdiagnosed in Spain.

*Funding Source: This study was funded by Merck Sharp & Dohme Corp., a subsidiary of Merck & Co., Inc., Kenilworth, NJ, USA.*

**Key words:**

*Cough; Chronic Cough; prevalence; diagnosis*

## Carcinosarcoma, a rare sinonasal malignancy: a case report

Vera Miranda<sup>1</sup>, **Tiago S. Santos<sup>1,2</sup>**, Paulo Gonçalves<sup>1</sup>, Débora Gonçalves<sup>1</sup>, Carlos Carvalho<sup>1</sup>

<sup>1</sup>ENT Department, Centro Hospitalar de Entre o Douro e Vouga, Santa Maria da Feira, Portugal, <sup>2</sup>Unit for Multidisciplinary Research in Biomedicine, Institute of Biomedical Sciences Abel Salazar, University of Porto, Porto, Portugal

Poster Session, 26 Sept – 30 Sept, 2021, All day

**Background:** Carcinosarcoma, also known as spindle cell carcinoma, is a malignant neoplasm, with rapid growth and extensive local destruction, comprising mesenchymal and epithelial components. This is an extremely rare neoplasm in the sinonasal region.

**Case Report:** We report a case of a 61-year-old man with progressive left-side nasal obstruction and epiphora for six months. Computed tomography (CT) and magnetic resonance imaging (MRI) showed a massive mass lesion, mainly localized in the left nasal cavity and ethmoid sinus, with no intracranial or orbital extension. Biopsy of the nasal mass revealed a poorly-differentiated squamous cell carcinoma associated with sarcomatous elements. No metastasis lesions were detected. The neoplasm was completely resected by sinonasal endoscopic surgery and negative margins were achieved through frozen section analysis. Postoperative histopathologic examination revealed a carcinosarcoma, a biphasic tumour with sarcomatous and epithelial components. Adjuvant radiotherapy (Volumetric Modulated Arc Therapy – VMAT) was performed with a total of 60 Gy. After 43 months of follow-up, there is no evidence of tumoral recurrence.

**Conclusions:** Carcinosarcoma is rare malignancy in nasal cavity and paranasal sinus. Even though despite the lack of optimal treatment protocol, long term disease control can be achieved through endoscopic surgical resection complemented with radiotherapy.

**Key words:** Carcinosarcoma, Nasal cavity, Paranasal sinuses

#### Literature

1. Patel TD, Vázquez A, Plitt MA, Baredes S, Eloy JA. A case-control analysis of survival outcomes in sinonasal carcinosarcoma. *Am J Otolaryngol - Head Neck Med Surg.* 2015;36(2):200–4.
2. Yuen J, Varadarajan V, Stavrakas M, Muquit S, Khalil H. A Case of Invasive Sinonasal Carcinosarcoma: The Importance of Early Detection. *Case Rep Otolaryngol.* 2018;2018:1–5.
3. Hasnaoui J, Anajar S, Tatari M, Abada R, Rouadi S, Roubal M, et al. Carcinosarcoma of the maxillary sinus: A rare case report. *Ann Med Surg.* 2017;19:41–4.
4. Guan M, Li Y, Shi ZG, Xie LS, Cao XL. Sarcomatoid carcinoma involving the nasal cavity and paranasal sinus: A rare and highly progressive tumor. *Int J Clin Exp Pathol.* 2014;7(7):4489–92.
5. Altınay S, Altınok A, Altınok Sut P, Taskın U, Bilici A. Spindle cell carcinoma (sarcomatoid carcinoma) of maxillary sinus and nasal cavity with orbital involvement: A rare case report and brief review of literature. *Dent Oral Craniofacial Res.* 2018;4(5):1–4.

Vera Miranda<sup>1</sup>, **Tiago S. Santos<sup>1,2</sup>**, Paulo Gonçalves<sup>1</sup>, Débora Gonçalves<sup>1</sup>, Carlos Carvalho<sup>1</sup>

<sup>1</sup>ENT Department, Centro Hospitalar de Entre o Douro e Vouga, Santa Maria da Feira, Portugal, <sup>2</sup> Unit for Multidisciplinary Research in Biomedicine, Institute of Biomedical Sciences Abel Salazar, University of Porto, Porto, Portugal

Poster Session, 26 Sept – 30 Sept, 2021, All day

**Background:** Cholesteatomas, commonly found in middle ear and mastoid, can infrequently be found in the paranasal sinuses. The frontal sinus is the most common location for paranasal cholesteatomas. Although described as slow-growing benign tumours, the ability to involve the underlying structures could lead to several complications, including infections that can be life-threatening.

**Case Report:** We report a case of 60-year-old woman who presented, in 2014, with acute right frontal sinusitis complicated with subdural empyema. The patient was treated, in a different institution, with endoscopic sinus surgery combined with subdural empyema drainage and 6-weeks of intravenous broad-spectrum antibiotic. In 2020 the patient had a second episode of acute right frontal sinusitis complicated with meningitis. Urgent endoscopic sinus surgery was successfully performed and keratin-like aspect of the mucosa was found inside the right frontal sinus. The histopathological examination was consistent with cholesteatoma. A follow-up MRI of the paranasal sinus showed expansion of the frontal sinus filled with heterogenous soft tissue, without signs of dural involvement. The patient underwent a new surgery, a combined endoscopic Lothrop procedure and an external bicoronal frontal osteoplastic flap, to ensure complete cholesteatoma resection.

**Conclusions:** Frontal sinus cholesteatomas are rare and preoperative diagnosis is often unusual. A complete surgical resection is the only effective treatment in order to avoid recurrence.

Key words: Cholesteatoma, Frontal sinus, Paranasal sinuses

#### Literature

1. Kurien R, Thomas L, Varghese L, Nair BR. Frontal sinus cholesteatoma: a masquerading diagnosis. *BMJ Case Rep.* 2019;12(11):10–3.
2. Hansen S, Sørensen CH, Stage J, Mouritzen A, Cayé-Thomasen P. Massive cholesteatoma of the frontal sinus: Case report and review of the literature. *Auris Nasus Larynx.* 2007;34(3):387–92.
3. Hammami B, Mnejja M, Chakroun A, Achour I, Chakroun A, Charfeddine I, et al. Cholesteatoma of the frontal sinus. *Eur Ann Otorhinolaryngol Head Neck Dis.* 2010;127(6):213–6.
4. Tejani N, Kshirsagar R, Song B, Liang J. Evolving Treatment of Frontal Sinus Cholesteatoma: A Case Report. *Perm J.* 2020;1–4.

## Management of anterior skull base cerebrospinal fluid leaks, our experience at Hospital Universitario La Paz.

**Teresa Langeber Gavilán**<sup>1</sup>, Blanca Mateos Serrano<sup>1</sup>, Jose Suazo Díaz-Recio<sup>1</sup>, Carolina Alfonso Carrillo<sup>1</sup>, Álvaro de Arriba Sánchez<sup>1</sup>, Carlos Pérez López<sup>2</sup>, Javier Gavilán Bouzas<sup>1</sup>.

<sup>1</sup>Department of Otorhinolaryngology, Hospital Universitario La Paz, Madrid, Spain, <sup>2</sup>Department of Neurosurgery, Hospital Universitario La Paz, Madrid, Spain

Poster Session, 26 Sept – 30 Sept, 2021, All day

**Background:** Cerebrospinal fluid (CSF) leaks appear due to a cranial base structure disruption. Without treatment there's a high risk of meningitis. Advancements in endonasal endoscopic reconstructive techniques have helped success rate of treatment.

**Methodology/Principal:** A retrospective review of patients with surgical repair of iatrogenic, traumatic or spontaneous anterior skull base CSF leaks operated between 2015-2021 was performed. Etiology, location, symptomatology, anthropometric evaluation and surgical technique were analyzed.

**Results:** Out of fourteen patients with CSF leaks, 64,3% were females, mean age was  $47,79 \pm 17,49$  years with a mean body mass index of  $29,8 \pm 9,9$  kg/m<sup>2</sup>. Seven were postsurgical, six spontaneous and one traumatic.

Flouresceine was used in seven patients with unlocalized CSF leaks, four of them were diagnosed. Most common location was sphenoid sinus followed by olfactory recess.

Surgical reconstruction was mainly performed using a nasoseptal flap (NSP) and middle turbinate flap (MTF). Immediate postsurgical relapsed occurred in one patient after transsphenoidal approach revision. We found three relapses on the first year, two associated to meningocele.

**Conclusions:** Majority of CSF leaks remained solved one year after surgery. Two most common reconstruction techniques were NSF and MTF. Fluoresceine use was useful to localized leakages improving the success of surgery.

Key words: Cerebrospinal fluid leak, CSF leak, endoscopic repair, anterior skull base, management

Ioannis Skoumpas<sup>1</sup>, Christos Diloglou<sup>2</sup>, Alexandros Poutoglidis<sup>1</sup>, Leonidas Demourtzidis<sup>2</sup>,  
Spyridon D. Gougousis<sup>1</sup>

<sup>1</sup>ENT Department of G.H."G.Papanikolaou", Thessaloniki, Greece, <sup>2</sup>Neurosurgery Department of G.H."G.Papanikolaou", Thessaloniki, Greece

Poster Session, 26 Sept – 30 Sept, 2021, All day

**Introduction:** Contemporary laboratory tests for confirmation of cerebrospinal fluid (CSF) leak, like beta-2 transferrin and beta-trace protein, have limited availability in various regions including our country. The purpose of our study was to evaluate whether diagnosis is possible without biochemical exams.

**Methods:** Eight consecutive patients with clinical suspicion of CSF rhinorrhea were treated in our hospital. High resolution computed tomography (HRCT) was performed for detection of bony defects in the skull base. Six patients also underwent magnetic resonance cisternography (MRC).

**Results:** The cause of CSF rhinorrhea varied (4 traumatic, 4 spontaneous). MRC identified the presence of CSF leak in all 6 cases. The remaining two were confirmed with HRCT. HRCT depicted the bony dehiscence in 7 out of 8 cases. The site of origin was the lateral lamella of the ethmoid bone in all 8 patients. In four of them the fistula was confirmed and repaired surgically, while lumboperitoneal shunt was performed in the remaining.

**Conclusions:** Combination of clinical suspicion, endoscopic findings, imaging methods and surgical confirmation can lead to safe diagnosis of CSF rhinorrhea. Although our results are encouraging, further studies are necessary to support this hypothesis.

**Keywords:** cerebrospinal fluid, CSF leak, CSF rhinorrhea, diagnostic algorithm, MRI cisternography, diagnosis

#### Literature:

1. Ecin G, Oner AY, Tokgoz N, Ucar M, Aykol S, Tali T. T2-weighted vs. intrathecal contrast-enhanced MR cisternography in the evaluation of CSF rhinorrhea. *Acta Radiol.* 2013 Jul;54(6):698-701.
2. Oakley GM, Alt JA, Schlosser RJ, Harvey RJ, Orlandi RR. Diagnosis of cerebrospinal fluid rhinorrhea: an evidence-based review with recommendations. *Int Forum Allergy Rhinol.* 2016 Jan;6(1):8-16. doi: 10.1002/alr.21637. Epub 2015 Sep 15.
3. Mantur M, Łukaszewicz-Zajac M, Mroczko B, Kułakowska A, Ganslandt O, Kemona H, Szmitkowski M, Drozdowski W, Zimmermann R, Kornhuber J, Lewczuk P. Cerebrospinal fluid leakage--reliable diagnostic methods. *Clin Chim Acta.* 2011 May 12;412(11-12):837-40. doi: 10.1016/j.cca.2011.02.017. Epub 2011 Feb 17.
4. Eljazzar R, Loewenstern J, Dai JB, Shrivastava RK, Iloreta AM Jr. Detection of Cerebrospinal Fluid Leaks: Is There a Radiologic Standard of Care? A Systematic Review. *World Neurosurg.* 2019 Jul;127:307-315. doi: 10.1016/j.wneu.2019.01.299. Epub 2019 Feb 22.
5. Shetty PG, Shroff MM, Fatterpekar GM, Sahani DV, Kirtane MV. A retrospective analysis of spontaneous sphenoid sinus fistula: MR and CT findings. *AJNR Am J Neuroradiol.* 2000 Feb;21(2):337-42.
6. Shetty PG, Shroff MM, Sahani DV, Kirtane MV. Evaluation of high-resolution CT and MR cisternography in the diagnosis of cerebrospinal fluid fistula. *AJNR Am J Neuroradiol.* 1998 Apr;19(4):633-9.
7. Algin O, Hakyemez B, Gokalp G, Ozcan T, Korfali E, Parlak M. The contribution of 3D-CISS and contrast-enhanced MR cisternography in detecting cerebrospinal fluid leak in patients with rhinorrhoea. *Br J Radiol.* 2010 Mar;83(987):225-32. doi:

10.1259/bjr/56838652. Epub 2009 Sep 1.

8. Goel G, Ravishankar S, Jayakumar PN, Vasudev MK, Shivshankar JJ, Rose D, Anandh B. Intrathecal gadolinium-enhanced magnetic resonance cisternography in cerebrospinal fluid rhinorrhea: road ahead? J Neurotrauma. 2007 Oct;24(10):1570-5.

## Dupilumab Improved All Smell Outcomes in Patients With Severe Chronic Rhinosinusitis With Nasal Polyps Regardless of Asthma or NSAID-Exacerbated Respiratory Disease Status: Results From the SINUS-24 and SINUS-52 Phase 3 Trials

**Joaquim Mullol**<sup>1</sup>, Claus Bachert<sup>2,3</sup>, Peter W. Hellings<sup>4</sup>, Nadia Daizadeh<sup>5</sup>, Benjamin Ortiz<sup>6</sup>, Michel Djandji<sup>5</sup>, Yamo Deniz<sup>6</sup>, Paul J. Rowe<sup>7</sup>, Nikhil Amin<sup>6</sup>, Leda P. Mannent<sup>8</sup>

<sup>1</sup>Hospital Clínic, IDIBAPS, Universitat de Barcelona, CIBERES, Barcelona, Catalonia, Spain; <sup>2</sup>Ghent University, Ghent, Belgium; <sup>3</sup>Karolinska Institutet, Stockholm, Sweden; <sup>4</sup>University Hospitals Leuven, Leuven, Belgium; <sup>5</sup>Sanofi, Cambridge, MA, USA; <sup>6</sup>Regeneron Pharmaceuticals, Inc., Tarrytown, NY, USA; <sup>7</sup>Sanofi, Bridgewater, NJ, USA; <sup>8</sup>Sanofi, Chilly-Mazarin, France

Poster Session, 26 Sept – 30 Sept, 2021, All day

**Background:** We report the effect of dupilumab 300 mg every 2 weeks vs placebo on smell outcomes in patients with chronic rhinosinusitis with nasal polyps (CRSwNP) and comorbid asthma or NSAID-exacerbated respiratory disease (N-ERD) in the pooled SINUS-24 (NCT02912468) and SINUS-52 (NCT02898454) phase 3 studies.

**Methodology:** Dupilumab vs placebo was assessed on smell outcomes: daily loss of smell (LoS; 0–4), University of Pennsylvania Smell Test (UPSIT; 0–40), 22-item Sino-Nasal Outcome Test (SNOT-22) smell/taste item (0–5), and % anosmia (UPSIT ≤18).

**Results:** 59.1% of patients had comorbid asthma and 28.2% N-ERD. Week 24 least squares (LS) mean changes from baseline vs placebo in patients with/without asthma: UPSIT: +11.1/+9.8; SNOT-22 smell/taste item: –2.1/–1.8; LoS: –1.1/–0.9. Week 24 LS mean changes from baseline vs placebo in patients with/without N-ERD: UPSIT: +10.2/+10.7; SNOT-22 smell/taste item: –2.1/–0.9; LoS: –1.0/–1.1. All P vs placebo <0.0001. In dupilumab-treated patients with/without asthma and with/without N-ERD anosmia was 86.5%/65.1% and 87.4%/74.0% at baseline and 33.7%/19.8% and 39.8%/23.3% at Week 24. Dupilumab was well tolerated.

**Conclusions:** Dupilumab led to improvements in all smell outcomes vs placebo in patients with severe CRSwNP, regardless of comorbid asthma or N-ERD.

**Key words:** Comorbidity; Inflammation; Nasal polyps; Sinusitis; Smell

**Acknowledgements:** Research sponsored by Sanofi and Regeneron Pharmaceuticals, Inc. ClinicalTrials.gov Identifiers: NCT02912468 (SINUS-24) and NCT02898454 (SINUS-52). Medical writing/editorial assistance provided by Nick Patterson, PhD, of Excerpta Medica, funded by Sanofi Genzyme and Regeneron Pharmaceuticals, Inc., according to the Good Publication Practice guideline.

### Disclosures:

**Mullol J:** Regeneron Pharmaceuticals Inc., Sanofi – clinical trial funding, advisory board member.

**Bachert C:** ALK, ASIT Biotech, AstraZeneca, Intrexon Actobiotics, Novartis, Sanofi, Stallergenes Greer – advisory board member.

**Hellings PW:** Regeneron Pharmaceuticals, Inc., Sanofi – advisory board member.

**Daizadeh N, Djandji M, Rowe PJ, Mannent LP:** Sanofi – employees, may hold stock and/or stock options in the company.

**Ortiz B, Deniz Y, Amin N:** Regeneron Pharmaceuticals, Inc. – employees and shareholders.



# Rapid and Sustained Improvement in Sense of Smell With Dupilumab in Patients With Severe Chronic Rhinosinusitis With Nasal Polyps and 0, 1, 2, or $\geq 3$ Prior Sinonasal Surgeries (SNS): Pooled Results From the SINUS-24 and SINUS-52 Phase 3 Studies

**Joaquim Mullol**<sup>1</sup>, Claus Bachert<sup>2,3,4</sup>, Martin Desrosiers<sup>5</sup>, Joseph K. Han<sup>6</sup>, Roger Jankowski<sup>7</sup>, Nadia Daizadeh<sup>8</sup>, Benjamin Ortiz<sup>9</sup>, Shahid Siddiqui<sup>9</sup>, Michel Djandji<sup>8</sup>, Juby A. Jacob-Nara<sup>10</sup>, Paul J. Rowe<sup>10</sup>, Yamo Deniz<sup>9</sup>, Nikhil Amin<sup>9</sup>, Leda P. Mannent<sup>11</sup>, Asif H. Khan<sup>11</sup>, Siddhesh Kamat<sup>9</sup>

<sup>1</sup>Hospital Clínic, IDIBAPS, Universitat de Barcelona, CIBERES, Barcelona, Catalonia, Spain; <sup>2</sup>Ghent University, Ghent, Belgium; <sup>3</sup>Karolinska Institutet, Stockholm, Sweden; <sup>4</sup>Sun Yat-sen University, The First Affiliated Hospital, Guangzhou, China; <sup>5</sup>Centre de recherche du Centre hospitalier de l'Université de Montréal (CRCHUM), Montreal, QC, Canada; <sup>6</sup>Eastern Virginia Medical School, Norfolk, VA, USA; <sup>7</sup>University Hospital of Nancy, Nancy, France; <sup>8</sup>Sanofi, Cambridge, MA, USA; <sup>9</sup>Regeneron Pharmaceuticals, Inc., Tarrytown, NY, USA; <sup>10</sup>Sanofi, Bridgewater, NJ, USA; <sup>11</sup>Sanofi Chilly-Mazarin, France.

Poster Session, 26 Sept – 30 Sept, 2021, All day

**Background:** Loss of smell (LoS) is a difficult-to-treat symptom in patients with chronic rhinosinusitis with nasal polyps (CRSwNP).

**Methodology:** University of Pennsylvania Smell Identification Test (UPSIT; 0-40), daily-assessed LoS score (0-3), and percentage with anosmia (UPSIT  $\leq 18$ ) were assessed according to number of prior sinonasal surgeries (SNS) in patients treated with dupilumab 300 mg every 2 weeks or placebo in the pooled phase 3 studies SINUS-24 and SINUS-52 (NCT02912468, NCT02898454).

**Results:** At baseline, patients with 0/1/2/ $\geq 3$  prior SNS (n=265/254/94/111) had mean UPSIT 16.02/12.87/12.97/12.49, mean LoS score 2.65/2.76/2.81/2.83, and percentage with anosmia was 64.9/83.1/78.7/84.7, respectively. Dupilumab significantly improved UPSIT from the first post-baseline assessment (Week 2 LS mean differences vs placebo: +6.70/+5.38/+5.57/+3.45; all P<0.01), through Week 24 (+10.45/+11.04/+12.13/+8.71; all P<0.0001). Dupilumab also significantly improved LoS (LS mean differences vs placebo: -0.28/-0.27/-0.38/-0.32 at Week 2, all P<0.05; and -0.96/-1.14/-0.98/-0.98 at Week 24; all P<0.0001). Percentage of patients with anosmia was reduced with dupilumab to 31.3/47.1/43.6/60.9 at Week 2 and 18.7/30.1/25.5/40.6 at Week 24 vs 57.6/74.3/69.2/83.0 and 64.6/78.2/71.8/87.2, respectively, with placebo.

**Conclusions:** Patients with prior SNS had worse sense of smell at baseline. Dupilumab produced rapid and sustained improvement in sense of smell in patients with CRSwNP regardless of number of prior surgeries.

**Key words:** Inflammation; Nasal polyps; Sinusitis; Smell; Surgery

## Acknowledgements

Research sponsored by Sanofi and Regeneron Pharmaceuticals, Inc. ClinicalTrials.gov Identifiers: NCT02912468 (SINUS-24) and NCT02898454 (SINUS-52). Medical writing/editorial assistance provided by Matt Lewis, PhD, of Adelphi Group, funded by Sanofi Genzyme and Regeneron Pharmaceuticals, Inc., according to the Good Publication Practice guideline.

## Disclosures:

**Mullol J:** AstraZeneca, Genentech, GlaxoSmithKline, Menarini, Mitsubishi Tanabe Pharma Corporation, MSD, Mylan-MEDA Pharma, Novartis, Sanofi Genzyme, Regeneron Pharmaceuticals, Inc., UCB, Uriach Group – advisory board member and/or speaker fees; Mylan-MEDA Pharma, Uriach Group – research grants.

**Bachert C:** ALK, AstraZeneca, GlaxoSmithKline, Mylan, Novartis, Sanofi, Stallergenes

Greer – advisory board member, speakers' fees.

**Desrosiers M:** AstraZeneca, GlaxoSmithKline, Probionase Therapies, Sanofi – clinical trial funding; Regeneron Pharmaceuticals, Inc., Sanofi – advisory board member; Probionase Therapies – equity holder.

**Han JK:** Sanofi – advisory board member.

**Jankowski R:** ALK, Laboratoire de la Mer, Regeneron Pharmaceuticals, Inc., Sanofi – advisory board member.

**Daizadeh N, Djandji M, Jacob-Nara JA, Rowe PJ, Mannent LP, Khan AH:** Sanofi – employees, may hold stock and/or stock options in the company.

**Ortiz B, Siddiqui S, Deniz Y, Amin N, Kamat S:** Regeneron Pharmaceuticals, Inc. – employees and shareholders.

## Nasal septum hemangioma: a rare cause of nasal epistaxis in a child

Konstantinos Garefis<sup>1</sup>, Maria Garefi<sup>2</sup>, Vasileios Nikolaidis<sup>1</sup>, Angelos Chatziavramidis<sup>1</sup>, Iordanis Konstantinidis<sup>1</sup>, Konstantinos Markou<sup>1</sup>

<sup>1</sup> 2<sup>nd</sup> Academic ORL, Head and Neck Surgery Department Aristotle University of Thessaloniki, Papageorgiou Hospital, Thessaloniki, Greece; <sup>2</sup> Department of Pediatric, General Hospital of Veroia, Veroia, Greece

Poster Session, 26 Sept – 30 Sept, 2021, All day

**Background:** Hemangiomas of the head and neck account for about 7% of all benign tumors in children. Only 6 cases of nasal septum hemangiomas in childhood have been previously described. We present a rare case of unilateral nasal epistaxis in a 9-year-old boy that was treated with transnasal endoscopic resection of nasal septum hemangioma.

**Methodology/Principal:** A 9-year-old boy was referred to our department from a district hospital with active nose bleeding and a 6-month history of recurrent left-sided nasal epistaxis and obstruction. Anterior rhinoscopy and nasal endoscopy revealed a hemorrhagic pedicled mass, 0,8X0,7X0,5 cm in size, arising from the left side of the anterior septum. An endoscopic resection of the bleeding lesion, using bipolar diathermy, under general anesthesia was performed. Packing of left nasal cavity was done and was removed on the second day of hospitalization.

**Results:** The patient was discharged on the second post-operative day. Histopathological and immunohistochemical examination revealed a capillary hemangioma of the nasal septum. The child remains symptom-free on 6 months follow-up with no evidence of hemangioma recurrence.

**Conclusions:** Intranasal hemangiomas should be considered in the differential diagnosis of all pediatric endonasal masses associated with unilateral epistaxis and nasal obstruction.

**Key words:** hemangioma, epistaxis, nasal obstruction, septum, pediatric

#### Literature

1. Zaytoun GM, Mufarrrij AA, Hadi UM, Shikhani AH, Salman SD. Hemangioma of the Nasal Septum: A Clinicopathological Profile. *Ann Saudi Med.* 1991 Jan;11(1):67-72.
2. Mariño-Sánchez F, Lopez-ChaconM, Jou C, Haag O. Pediatric intranasal lobular capillary hemangioma: Report of two new cases and review of the literature. *Respir Med Case Rep.* 2016; 18: 31–34.
3. Salman N, Baysal N, Adabag, A, Yildiz U, İstemihan A. Capillary hemangioma of the nasal septum in children. *J Pediatr Sciences.* 2012;4(2): 1-4.
4. Baki A. Nasal Cavity Hemangiomas. In *Maxillofacial Surgery and Craniofacial Deformity-Practices and Updates.* IntechOpen. 2020

## Torus tubarius pleomorphic adenoma: a rare cause of nasal obstruction

**Konstantinos Garefis**, Konstantinos Gkiouzelis, Stella Fotiadou, Iordanis Konstantinidis, Konstantinos Markou, Angelos Chatziavramidis

*2<sup>nd</sup> Academic ORL, Head and Neck Surgery Department Aristotle University of Thessaloniki, Papageorgiou Hospital, Thessaloniki, Greece*

Poster Session, 26 Sept – 30 Sept, 2021, All day

**Background:** Pleomorphic adenoma (PA) is the most common salivary gland benign tumor. Only 16 cases of nasopharyngeal PAs have been previously described. We present the first clinical report of torus tubarius PA treated with transnasal endoscopic resection.

**Methodology/Principal:** A 68-year-old male patient referred to our department with a 5-year history of progressive left nasal obstruction. Endoscopic examination of nasal cavities and nasopharynx demonstrated a smooth, oval mass arising from the left torus tubarius, obstructing the left nasal choanae and a part of the right choanae. Otoscopy and neck palpation were normal. Computed tomography scan showed a 4.7 cm x 4.2 cm x 3.9 cm well defined mass in the left site of the nasopharynx. Under general anesthesia, the tumor was meticulously detached from the torus tubarius endoscopically, using bipolar diathermy. It was excised en block with its pedicle, to prevent recurrence.

**Results:** The patient was discharged on the second postoperative day. The histopathological diagnosis was PA. No complications were reported during the immediate postoperative period. At 6-month follow-up period assessment there was no evidence of tumor recurrence.

**Conclusions:** Nasopharyngeal PAs should be kept in mind in the differential diagnosis of nasal obstruction. The treatment of choice is transnasal endoscopic total excision of the mass.

Key words: pleomorphic adenoma, nasal obstruction, endoscopic, torus tubarius, nasopharynx

#### Literature

1. Berrettini S, Fortunato S, De Vito A, Bruschini L. A rare case of nasopharyngeal pleomorphic adenoma. *Case Rep Otolaryngol.* 2013; 2013:3.
2. Li W, Lu H, Zhang H, Lai Y, Zhang J, Ni Y, Wang D. Sinonasal/nasopharyngeal pleomorphic adenoma and carcinoma ex pleomorphic adenoma: a report of 17 surgical cases combined with a literature review. *Cancer Manag Res.* 2019; 11:5545-5555.
3. Roh JL, Jung BJ, Rha KS, Park CI. Endoscopic resection of pleomorphic adenoma arising in the nasopharynx. *Acta Otolaryngol.* 2005; 125(8):910–912.
4. Bowman J, Daudia A, Sahasrabudhe N, Belloso A. Coblator-Assisted Endoscopic Transnasal Resection of a Large Nasopharyngeal Pleomorphic Adenoma. *Case Rep Otolaryngol.* 2019; 2019:4654357.
5. Celik S, Kilic O, Zenginkinet T, Kalcioglu MT. Nasopharyngeal Pleomorphic Adenoma: A Rare Case Report and Review of the Literature. *Case Rep Otolaryngol.* 2018 Dec 31;2018:2481370.

# Self-Isolated COVID-19 Patients with smell and taste dysfunction present two phenotypes of recovery: a short-term follow-up study in Greece

**Konstantinos Garefis<sup>1</sup>**, Alexander Delides<sup>2</sup>, Evangelia Tsakiropoulou<sup>1</sup>, Pavlos Maragoudakis<sup>2</sup>, Iordanis Konstantinidis<sup>1</sup>

<sup>1</sup>2nd Academic ORL Department, Papageorgiou Hospital, Aristotle University, Thessaloniki, Greece, , <sup>2</sup>2nd Academic ORL Department, Attikon University Hospital, School of Medicine, National and Kapodistrian University of Athens, Athens, Greece

Poster Session, 26 Sept – 30 Sept, 2021, All day

**Background:** The course of anosmia and ageusia in COVID-19 patients is not yet extensively studied. We present short-term follow-up data concerning mild to moderate disease in home-quarantined COVID-19 patients in Greece.

**Methodology/principal:** A symptom questionnaire and instructions for a self-administered home smell-and-taste test was provided to 79 positive COVID-19 patients from two tertiary hospitals in Greece. Patients had to record their subjective symptoms before, during infection and 4 weeks after diagnosis. They also underwent the home test during infection and 4 weeks later.

**Results:** Twenty-nine patients (36.7%) reported smell impairment, and 21 (27.8%) reported a loss of taste. Two types of recovery were observed: 1.a rapid, almost complete recovery, and 2. a second slower and partial recovery. The type of recovery was not age related. A rapid recovery was observed in two thirds of the patients. A slow recovery in olfaction was correlated with low intensity ratings in odors with a trigeminal compound. The loss of taste was more pronounced in sweet and salty intensity ratings.

**Conclusion:** Smell and taste deficits associated with COVID-19 infection in most cases, returned to normal within 4 weeks. However in one third of patients presented with persistent chemosensory dysfunction in the short term.

**Keywords:** COVID-19; ageusia; anosmia; Smell; Taste.

## Literature

1. Lechien JR, Chiesa-Estomba CM, De Siati DR, Horoi M, Le Bon SD, Rodriguez A, et al. Olfactory and gustatory dysfunctions as a clinical presentation of mild-to-moderate forms of the coronavirus disease (COVID-19): a multicenter European study. *Eur Arch Otorhinolaryngol*. 2020 Aug;277((8)):2251–61.
2. Beltrán-Corbellini Á, Chico-García JL, Martínez-Poles J, Rodríguez-Jorge F, Natera-Villalba E, Gómez-Corral J, et al. Acute-onset smell and taste disorders in the context of COVID-19: a pilot multicentre polymerase chain reaction based case-control study. *Eur J Neurol*. 2020 Apr;22((9)):1738–41.
3. Vaira LA, Salzano G, Deiana G, De Riu G. Anosmia and Ageusia: Common Findings in COVID-19 Patients. *Laryngoscope*. 2020 Jul;130((7)):1787.
4. Oleszkiewicz A, Schriever VA, Croy I, Hähner A, Hummel T. Updated Sniffin' Sticks normative data based on an extended sample of 9139 subjects. *Eur Arch Otorhinolaryngol*. 2019 Mar;276((3)):719–28.
5. Landis BN, Welge-Luessen A, Brämerson A, Bende M, Mueller CA, Nordin S, et al. "Taste Strips" - a rapid, lateralized, gustatory bedside identification test based on impregnated filter papers. *J Neurol*. 2009 Feb;256((2)):242–8.

# Local-nasal immunotherapy for Allergic rhinitis: A systematic review and meta-analysis.

**Navarat Kasemsuk**<sup>1</sup>, Premyot Ngaoteprutaram<sup>1</sup>, Dichapong Kanjanawasee<sup>1</sup>, Triphoom Suwanwech<sup>1</sup>, Stephen R Durham<sup>2</sup>, Giorgio Walter Canonica<sup>3</sup>, Pongsakorn Tantilipikorn<sup>1</sup>

<sup>1</sup>Division of Rhinology and Allergy, Department of Otorhinolaryngology, Faculty of Medicine Siriraj Hospital, Mahidol University, Bangkok, Thailand, <sup>2</sup>Department of Allergy and Clinical Immunology, Imperial College London, London, United Kingdom, <sup>3</sup>Department of Internal Medicine, Respiratory Disease Clinic, IRCCS Humanitas Clinical and Research Center, Humanitas University, Milan, Italy

Poster Session, 26 Sept – 30 Sept, 2021, All day

**Background:** Local-nasal immunotherapy (LNIT) is an option for non-injection immunotherapy administration. LNIT is theoretically efficient method to induce immunotolerance directly at the shock organ. It is considered more convenient, less invasive and with less systemic reaction compared to injection immunotherapy. This article aims to evaluate clinical, immunologic efficacy and safety of LNIT in allergic rhinitis patients.

**Methodology:** A systematic search for randomized controlled trials comparing LNIT and placebo was performed using OVID Medline and EMBASE. Data were pooled for meta-analysis.

**Results:** 20 studies with 698 participants were included. The LNIT group had greater post-treatment improvement of TNSS, SMS and medication score than control group (TNSS: SMD -1.37; 95% CI: [-2.04, -0.69], SMS: -1.55; 95% CI: [-2.83, -0.28], medication score: -1.09; 95% CI: [-1.35, -0.83]). Immunologic assessment demonstrated no significant difference for serum specific IgE, nasal IgE and nasal ECP. Only serum IgG was significantly increased (MD 0.45; 95% CI: [0.20, 0.70]) in LNIT group. The nasal provocation threshold post-treatment was higher in LNIT (MD 27.30; 95% CI: [10.13, 44.46]). No significant adverse event was reported.

**Conclusions:** LNIT is promising alternative route of allergen immunotherapy. LNIT can improve clinical symptoms, lessen medication usage, increase nasal provocation threshold in allergic rhinitis patients.

**Key words:** local nasal immunotherapy, nasal administration, allergy vaccine, allergic rhinitis, meta-analysis

## Literature

1. Brożek JL, Bousquet J, Agache I, Agarwal A, Bachert C, Bosnic-Anticevich S, et al. Allergic Rhinitis and its Impact on Asthma (ARIA) guidelines-2016 revision. The Journal of allergy and clinical immunology. 2017;140(4):950-8.
2. Alsowaidi S, Abdulle A, Shehab A, Zuberbier T, Bernsen R. Allergic rhinitis: prevalence and possible risk factors in a Gulf Arab population. Allergy. 2010;65(2):208-12.
3. Ha J, Lee SW, Yon DK. Ten-Year trends and prevalence of asthma, allergic rhinitis, and atopic dermatitis among the Korean population, 2008-2017. Clinical and experimental pediatrics. 2020;63(7):278-83.
4. Tantilipikorn P, Pinkaew B, Talek K, Assanasen P, Triphoom Suwanwech TS, Bunnag C. Pattern of allergic sensitization in chronic rhinitis: A 19-year retrospective study. Asian Pacific journal of allergy and immunology. 2020.
5. Lin SY, Nnacheta LC. American Academy of Otolaryngology-Head and Neck Surgery Foundation (AAO-HNSF) will publish its latest “Clinical practice guideline: allergic rhinitis (AR) in February, 2015”. American journal of rhinology & allergy. 2015;29(1):82.
6. Muraro A, Roberts G, Halken S, Agache I, Angier E, Fernandez-Rivas M, et al. EAACI guidelines on allergen immunotherapy: Executive statement. Allergy. 2018;73(4):739-

43.

7. Li Y, Yu SY, Tang R, Zhao ZT, Sun JL. Sublingual Immunotherapy Tablets Relieve Symptoms in Adults with Allergic Rhinitis: A Meta-analysis of Randomized Clinical Trials. *Chinese medical journal*. 2018;131(21):2583-8.
8. Huang Y, Wang C, Wang X, Zhang L, Lou H. Efficacy and safety of subcutaneous immunotherapy with house dust mite for allergic rhinitis: A Meta-analysis of Randomized Controlled Trials. *Allergy*. 2019;74(1):189-92.
9. Casale TB, Stokes JR. Future forms of immunotherapy. *The Journal of allergy and clinical immunology*. 2011;127(1):8-15; quiz 6-7.
10. Lee H, Ruane D, Law K, Ho Y, Garg A, Rahman A, et al. Phenotype and function of nasal dendritic cells. *Mucosal immunology*. 2015;8(5):1083-98.
11. Liu Z, Guo H, Wu Y, Yu H, Yang H, Li J. Local nasal immunotherapy: efficacy of *Dermatophagoides farinae*-chitosan vaccine in murine asthma. *International archives of allergy and immunology*. 2009;150(3):221-8.
12. Giannarini L, Maggi E. Decrease of allergen-specific T-cell response induced by local nasal immunotherapy. *Clinical and experimental allergy : journal of the British Society for Allergy and Clinical Immunology*. 1998;28(4):404-12.
13. Tsai JJ, Liao EC, Tsai FH, Hsieh CC, Lee MF. The effect of local nasal immunotherapy in allergic rhinitis: using strips of the allergen *dermatophagoides pteronyssinus*. *The Journal of asthma : official journal of the Association for the Care of Asthma*. 2009;46(2):165-70.
14. Passalacqua G, Canonica GW. Local nasal specific immunotherapy for allergic rhinitis. *Allergy, asthma, and clinical immunology : official journal of the Canadian Society of Allergy and Clinical Immunology*. 2006;2(3):117-23.
15. M. Ramvikas MA, S.R. Chakrabarti, and K.S. Jaganathan. Nasal Vaccine Delivery. 2017. In: *Micro and Nanotechnology in Vaccine Development* [Internet]. [279-301].
16. Cumpston M, Li T, Page MJ, Chandler J, Welch VA, Higgins JP, et al. Updated guidance for trusted systematic reviews: a new edition of the Cochrane Handbook for Systematic Reviews of Interventions. *The Cochrane database of systematic reviews*. 2019;10:Ed000142.
17. RevMan 5.3 User Guide. The Cochrane Collaboration [Internet]. 2014; 5.3.3:[46 p.].
18. Andri L, Senna GE, Betteli C, Givanni S, Andri G, Falagiani P, et al. Local nasal immunotherapy in allergic rhinitis to *Parietaria*. A double-blind controlled study. *Allergy*. 1992;47(4 Pt 1):318-23.
19. Andri L, Senna G, Betteli C, Givanni S, Andri G, Falagiani P. Local nasal immunotherapy for *Dermatophagoides*-induced rhinitis: efficacy of a powder extract. *The Journal of allergy and clinical immunology*. 1993;91(5):987-96.
20. Bertoni M, Cosmi F, Bianchi I, Di Berardino L. Clinical efficacy and tolerability of a steady dosage schedule of local nasal immunotherapy. Results of preseasonal treatment in grass pollen rhinitis. *Annals of allergy, asthma & immunology : official publication of the American College of Allergy, Asthma, & Immunology*. 1999;82(1):47-51.
21. Pocobelli D, Del Bono A, Venuti L, Falagiani P, Venuti A. Nasal immunotherapy at constant dosage: a double-blind, placebo-controlled study in grass-allergic rhinoconjunctivitis. *Journal of investigational allergology & clinical immunology*. 2001;11(2):79-88.
22. Bardare M, Zani G, Novembre E, Vierucci A. Local nasal immunotherapy with a powder extract for grass pollen induced rhinitis in pediatric ages: a controlled study. *Journal of investigational allergology & clinical immunology*. 1996;6(6):359-63.
23. Ariano R, Panzani RC, Chiapella M, Augeri G, Falagiani P. Local intranasal immunotherapy with allergen in powder in atopic patients sensitive to *Parietaria officinalis* pollen. *Journal of investigational allergology & clinical immunology*. 1995;5(3):126-32.
24. Schumacher MJ, Pain MC. Intranasal immunotherapy and polymerized grass pollen allergens. *Allergy*. 1982;37(4):241-8.
25. Welsh PW, Butterfield JH, Yunginger JW, Agarwal MK, Gleich GJ. Allergen-

- controlled study of intranasal immunotherapy for ragweed hay fever. *The Journal of allergy and clinical immunology*. 1983;71(5):454-60.
26. Ascione E, De Lucia A, Imperiali M, Varricchio A, Motta G. Nasal application of immunotherapy. *Chemical immunology and allergy*. 2003;82:89-98.
  27. Passalacqua G, Albano M, Pronzato C, Riccio AM, Scordamaglia A, Falagiani P, et al. Long-term follow-up of nasal immunotherapy to *Parietaria*: clinical and local immunological effects. *Clinical and experimental allergy : journal of the British Society for Allergy and Clinical Immunology*. 1997;27(8):904-8.
  28. Nickelsen JA, Goldstein S, Mueller U, Wypych J, Reisman RE, Arbesman CE. Local intranasal immunotherapy for ragweed allergic rhinitis. I. Clinical response. *The Journal of allergy and clinical immunology*. 1981;68(1):33-40.
  29. Nickelsen JA, Goldstein S, Mueller U, Wypych J, Reisman RE, Arbesman CE. Local intranasal immunotherapy for ragweed allergic rhinitis. II. Immunologic response. *The Journal of allergy and clinical immunology*. 1981;68(1):41-5.
  30. D'Amato G, Lobefalo G, Liccardi G, Cazzola M. A double-blind, placebo-controlled trial of local nasal immunotherapy in allergic rhinitis to *Parietaria* pollen. *Clinical and experimental allergy : journal of the British Society for Allergy and Clinical Immunology*. 1995;25(2):141-8.
  31. Andri L, Senna G, Andri G, Dama A, Givanni S, Betteli C, et al. Local nasal immunotherapy for birch allergic rhinitis with extract in powder form. *Clinical and experimental allergy : journal of the British Society for Allergy and Clinical Immunology*. 1995;25(11):1092-9.
  32. Andri L, Senna G, Betteli C, Givanni S, Andri G, Dimitri G, et al. Local nasal immunotherapy with extract in powder form is effective and safe in grass pollen rhinitis: a double-blind study. *The Journal of allergy and clinical immunology*. 1996;97(1 Pt 1):34-41.
  33. Cirila AM, Sforza N, Roffi GP, Alessandrini A, Stanizzi R, Dorigo N, et al. Preseasonal intranasal immunotherapy in birch-alder allergic rhinitis. A double-blind study. *Allergy*. 1996;51(5):299-305.
  34. Fanales-Belasio E, Ciofalo A, Zambetti G, Ansotegui IJ, Scala E, Paganelli R, et al. Intranasal immunotherapy with *Dermatophagoides* extract: in vivo and in vitro results of a double-blind placebo-controlled trial. *Rhinology*. 1995;33(3):126-31.
  35. Gaglani B, Borish L, Bartelson BL, Buchmeier A, Keller L, Nelson HS. Nasal immunotherapy in weed-induced allergic rhinitis. *Annals of allergy, asthma & immunology : official publication of the American College of Allergy, Asthma, & Immunology*. 1997;79(3):259-65.
  36. Georgitis JW, Reisman RE, Clayton WF, Mueller UR, Wypych JI, Arbesman CE. Local intranasal immunotherapy for grass-allergic rhinitis. *The Journal of allergy and clinical immunology*. 1983;71(1 Pt 1):71-6.
  37. Georgitis JW, Clayton WF, Wypych JI, Barde SH, Reisman RE. Further evaluation of local intranasal immunotherapy with aqueous and allergoid grass extracts. *The Journal of allergy and clinical immunology*. 1984;74(5):694-700.
  38. Marcucci F, Sensi LG, Caffarelli C, Cavagni G, Bernardini R, Tiri A, et al. Low-dose local nasal immunotherapy in children with perennial allergic rhinitis due to *Dermatophagoides*. *Allergy*. 2002;57(1):23-8.
  39. Motta G, Passali D, De Vincentiis I, Ottaviani A, Maurizi M, Sartoris A, et al. A multicenter trial of specific local nasal immunotherapy. *The Laryngoscope*. 2000;110(1):132-9.
  40. Passalacqua G, Albano M, Ruffoni S, Pronzato C, Riccio AM, Di Berardino L, et al. Nasal immunotherapy to *Parietaria*: evidence of reduction of local allergic inflammation. *American journal of respiratory and critical care medicine*. 1995;152(2):461-6.
  41. Passali D, Bellussi L, Passali GC, Passali FM. Nasal immunotherapy is effective in the treatment of rhinitis due to mite allergy. A double-blind, placebo-controlled study with rhinological evaluation. *International journal of immunopathology and pharmacology*.



2002;15(2):141-7.

42. Welsh PW, Zimmermann EM, Yunginger JW, Kern EB, Gleich GJ. Preseasonal intranasal immunotherapy with nebulized short ragweed extract. *The Journal of allergy and clinical immunology*. 1981;67(3):237-42.
43. Faraone SV. Interpreting estimates of treatment effects: implications for managed care. *P & T : a peer-reviewed journal for formulary management*. 2008;33(12):700-11.
44. Walker SM, Durham SR, Till SJ, Roberts G, Corrigan CJ, Leech SC, et al. Immunotherapy for allergic rhinitis. *Clinical and experimental allergy : journal of the British Society for Allergy and Clinical Immunology*. 2011;41(9):1177-200.
45. Huang Y, Wang C, Cao F, Zhao Y, Lou H, Zhang L. Comparison of Long-term Efficacy of Subcutaneous Immunotherapy in Pediatric and Adult Patients With Allergic Rhinitis. *Allergy, asthma & immunology research*. 2019;11(1):68-78.
46. Lim CE, Sison CP, Ponda P. Comparison of Pediatric and Adult Systemic Reactions to Subcutaneous Immunotherapy. *The journal of allergy and clinical immunology In practice*. 2017;5(5):1241-7.e2.
47. Canonica GW, Baena-Cagnani CE, Bousquet J, Bousquet PJ, Lockey RF, Malling HJ, et al. Recommendations for standardization of clinical trials with Allergen Specific Immunotherapy for respiratory allergy. A statement of a World Allergy Organization (WAO) taskforce. *Allergy*. 2007;62(3):317-24.
48. Akdis M, Akdis CA. Mechanisms of allergen-specific immunotherapy: multiple suppressor factors at work in immune tolerance to allergens. *The Journal of allergy and clinical immunology*. 2014;133(3):621-31.
49. Krzych-Fałta E, Samoliński BK. Objectification of the nasal patency assessment techniques used in nasal allergen provocation testing. *Postepy dermatologii i alergologii*. 2020;37(5):635-40.
50. Biedermann T, Couroux P, Greve TM, Mäkelä M. Safety of the SQ Tree Sublingual Immunotherapy Tablet: Pooled safety analysis of clinical trials. *Allergy*. 2021.
51. Gidaro GB, Marcucci F, Sensi L, Incorvaia C, Frati F, Ciprandi G. The safety of sublingual-swallow immunotherapy: an analysis of published studies. *Clinical and experimental allergy : journal of the British Society for Allergy and Clinical Immunology*. 2005;35(5):565-71.

# Clinical characteristics and cytokine profiles of central-compartment-type chronic rhinosinusitis

**Chun-Kang Liao**<sup>1</sup>, Yi-Tsen Lin<sup>1,2</sup>, Chih-Feng Lin<sup>1</sup>, Bor-Luen Chiang<sup>2</sup>, Te-Huei Yeh<sup>1,3</sup>

<sup>1</sup>Department of Otolaryngology, National Taiwan University Hospital, Taipei, Taiwan., <sup>2</sup>Graduate Institute of Clinical Medicine, College of Medicine, National Taiwan University, Taipei, Taiwan. <sup>3</sup>College of Medicine, National Taiwan University, Taipei, Taiwan.

Poster Session, 26 Sept – 30 Sept, 2021, All day

**Background:** The clinical characteristics of central-compartment-type chronic rhinosinusitis (CRS) in East Asian individuals are not clear. Herein, we investigate the clinical features and the cytokine profiles of central-compartment-type CRS in Taiwanese patients.

**Methods:** Adult patients with bilateral CRS were recruited. Revised or pansinusitis (Lund-Mackay scores >23) cases were excluded. Central-compartment-type CRS was defined by endoscopic and radiological features. Clinical symptoms, inhalant allergen sensitization status, endoscopic findings, and radiological assessments were recorded and compared between patients with central-compartment-type CRS and others. We also examined tissue eosinophilia and specific cytokine protein levels in the sinonasal tissues.

**Results:** Central-compartment-type CRS was found in 16 (23.9%) patients, and non-central-compartment-type CRS was found in 51 (76.1%) patients. Hyposmia/anosmia as the major symptom was more common in the central-compartment-type CRS group. The numbers of eosinophils in tissue and serum were significantly higher in the central-compartment-type CRS patients. The presence of allergen sensitization was not significantly different between groups. The levels of IL-5 and IL-13 were increased in middle turbinate tissues of patients with central-compartment-type CRS.

**Conclusion:** Central-compartment-type CRS was associated with hyposmia/anosmia, eosinophilic subtypes, and elevated levels of IL-5 and IL-13 in middle turbinate tissues but not necessarily correlated with allergen sensitized status in our patients.

*Key words: aeroallergens, allergic rhinitis, chronic rhinosinusitis, computed tomography, central compartment atopic disease*

Literature

Published in Int Forum Allergy Rhinol . 2021 Feb 2. doi: 10.1002/alr.22759

Encore presentation

## Psychometric evaluation of child-based patient-reported outcome measures (pSN-5) for sinonasal disease.

**Mohd Afiq Mohd Slim<sup>1</sup>**, Rhona Hurley<sup>1</sup>, Kate Hulse<sup>1</sup>, Max Allan<sup>2</sup>, David Young<sup>3</sup>, David McGregor Wynne<sup>1</sup>

<sup>1</sup>Paediatric Ear, Nose and Throat Department, Royal Hospital for Children, Glasgow. 1345 Govan Rd, Glasgow G51 4TF., <sup>2</sup>University of Glasgow, Glasgow, G12 8QQ., <sup>3</sup>Department of Mathematic and Statistics, University of Strathclyde, 16 Richmond St, Glasgow G1 1XQ.

Poster Session, 26 Sept – 30 Sept, 2021, All day

**Background:** Child-based patient-reported outcome measure for sinonasal disease in children are limited. Our objective is to evaluate the pSN-5 internal validity, test-retest reliability, and construct validity against SN-5.

**Methodology/Principal:** Prospective study with convenience sampling for children aged 7-15-year-old. Cronbach's  $\alpha$  determined the internal consistency. Test-retest reliability at 4-weeks and construct validity with SN-5 were evaluated with the Bland-Altman analysis (Level of agreement at  $\pm 1$ ). Sensitivity analysis was performed with the 'overall items means' and based on age category.

**Results:** Overall internal consistency was at  $\alpha$ :0.69 (95% CI: 0.58;0.79),  $\alpha$ :0.70 (95% CI: 0.57;0.84) aged 7-11 and  $\alpha$ :0.65 (95% CI: 0.48;0.82) aged 12-15. The pSN-5 is reliable within the test-retest period. Statistically significant and clinically important degree of bias towards the child's response (pSN-5) can be appreciated in the physical domain; Item 1 (Bias: 2 [1;3],  $p < 0.01$ ), Item 2 (Bias: 2 [0;3],  $p < 0.01$ ) and Item 3 (Bias: 2 [1;4],  $p < 0.01$ ). Meanwhile, Item 6 bias towards SN-5 (Bias: -4 [-5;2],  $p < 0.01$ ). No clinically relevant degree of bias seen with the overall item means (Bias:  $0.43 \pm 0.97$ ,  $p < 0.01$ ).

**Conclusions:** The pSN-5 have acceptable internal consistency and test-retest reliability. It should be used with the SN-5 to guide management of paediatric rhinosinusitis.

Key words: Child, reported, measures, rhinitis, chronic rhinosinusitis, allergic rhinitis, PROM, Quality of life

## QoL and rehabilitation of olfaction and taste after total laryngectomy - our experience

**Paula L. Bejenaru<sup>1</sup>**, Grigore Raluca <sup>1,2</sup>, Bogdan Popescu <sup>1,2</sup>, Liliana Nițu <sup>1,2</sup>, Catrinel B. Simion-Antonie<sup>1</sup>, Gloria S. Munteanu <sup>1,3</sup>, Mihnea Condeescu-Cojocăriță <sup>1,2</sup>, Alexandru Nicolaescu <sup>1,4</sup>, Anca I. Cîrstea <sup>2</sup>, Irina Oașă <sup>2</sup>, Simona A. Rujan<sup>2</sup>, Bianca P. Taher<sup>2</sup>, Teodora E. Diaconu<sup>2</sup>, Ruxandra Nedelcu <sup>2</sup>, Amer Othman<sup>2</sup>, Iulia Vetricean<sup>2</sup>, Alexandru G. Enea<sup>2</sup>, Mihai Tudose <sup>2</sup>, Șerban V. G. Berteșteanu <sup>1,2</sup>

<sup>1</sup>“Carol Davila” University of Medicine and Pharmacy, Bucharest (ROMANIA) , <sup>2</sup>“Coltea” Clinical Hospital, Bucharest (ROMANIA), <sup>3</sup>“Carol Davila” Central Military Emergency University Hospital, Bucharest (ROMANIA), <sup>4</sup>“Prof. Dr. Dimitrie Gerota” Ministry of Internal Affairs Hospital, Bucharest (ROMANIA)

Poster Session, 26 Sept – 30 Sept, 2021, All day

**Background:** Assessing the results of Nasal Airflow – Inducing Maneuver (NAIM) odor – rehabilitation technique, olfactory function in patients who undergo a total laryngectomy (TL) and the way that their QoL was influenced.

**Methodology/Principal:** Prospective study with 20 patients, assessing QoL – using EORTC QLQ-C30 and EORTC H&N35 questioners and score scales, olfactory testing - odor identification tests of University of Pennsylvania Smell Identification Test (UPSIT) - and taste testing, before and after intervention. All patients were trained by speech therapists with NAIM technique – 3 interventions within 6 weeks.

**Results:** Before TL, patients presented normal smell sense, with a mean of 32 score on UPSIT scales and had a good QoL. QoL decreases after total laryngectomy but adjuvant techniques as vocal, olfaction and taste rehabilitation can improve total scores. 2 weeks after TL, 15 patients (75%) had impaired olfaction – with a mean of 20 score on UPSIT scale, only 3 of them had severe anosmia; these group had a subsequent overall QoL score of 66/100. After using NAIM technique, 10 patients (50%) showed olfaction improvement. Overall QoL score in these group of patients was 80/100.

**Conclusions:** Olfaction, taste and respiratory rehabilitation often comes in second in oncological treatment, but they highly influence quality of life, with associated physical and psychosocial problems. Thus they need to be applied in proper time after surgery.

Key words: quality of life, smell, head and neck cancer

## A severe case of craniofacial fibrous dysplasia in a young female.

**Kyriaki Vallianou**<sup>1</sup>, Eyfrosyni Palla<sup>1</sup>, Charikleia Maiou<sup>1</sup>, Eythymios Solomi<sup>1</sup>, Aggeliki Alagianni<sup>1</sup>, Charalampos Skoulakis<sup>1</sup>

<sup>1</sup>*Department of Otolaryngology-Head and Neck Surgery, University Hospital of Larisa, Prof. Charalampos Skoulakis, Larisa, Greece*

Poster Session, 26 Sept – 30 Sept, 2021, All day

**Background:** Fibrous dysplasia is a non-malignant condition caused by activating mutations of the GNAS gene, that leads to the replacement of normal bone and marrow by fibrous tissue and woven bone. Patients may exhibit involvement of one or multiple bones (monostotic/polyostotic) or they may have McCune-Albright syndrome. The maxilla is found to be the most commonly involved bone in both CFD (30%). We report the case of a 24-year-old woman, that was referred to the outpatient clinic because of chronic swelling of the left side of the face, which showed progressive growth. Besides facial deformity, symptoms included nasal breathing difficulty and impairment of ocular mobility.

**Methodology/Principal:** The diagnostic approach included physical examination, CT scan of the visceral skull and biopsy under local anesthesia.

**Results:** The mass on palpation was solid, smooth and immovable. The CT scan revealed an expansive lesion (7.2x6.9x6.2cm) in the base of skull and left maxilla with extension to the left maxillary sinus, suggestive of craniofacial fibrous dysplasia. Histopathology confirmed the diagnosis of fibrous dysplasia. A surgical resection of the lesion was recommended but the patient refused. Currently, there is no follow-up in our department.

**Conclusions:** Any growing mass requires investigation. In Fibrous Dysplasia surgical management and regular follow-ups are recommended.

Key words: craniofacial fibrous dysplasia, maxilla, facial deformity

#### Literature

- 1) Lee, J., FitzGibbon, E., Chen, Y., Kim, H., Lustig, L., Akintoye, S., Collins, M., Kaban, L. (2012). Clinical guidelines for the management of craniofacial fibrous dysplasia. *Orphanet Journal of Rare Diseases*, 7(Suppl 1), S2. doi:10.1186/1750-1172-7-s1-s2
- 2) Yang, L., Wu, H., Lu, J., & Teng, L. (2017). Prevalence of Different Forms and Involved Bones of Craniofacial Fibrous Dysplasia. *Journal of Craniofacial Surgery*, 28(1), 21–25. doi:10.1097/scs.0000000000002830
- 3) Li, Z., Raynald, Wang, Z., & Qian, H. (2019). Malignant transformation of craniofacial fibrous dysplasia: a systematic review of overall survival. *Neurosurgical Review*. doi:10.1007/s10143-019-01089-1

# Is Surgery for Severe Type 2 Nasal Polyps safe under the Treatment with Biologics?

**Zhaofeng Xu<sup>a,b</sup>**, Nan Zhang<sup>b</sup>, Yanran Huang<sup>b,d</sup>, Sharon Van Nevel<sup>b</sup>, Gabriele Holtappels<sup>b</sup>, Weiping Wen MD<sup>a</sup>, and Claus Bachert<sup>a,b,c</sup>

<sup>1</sup>Upper Airway Research Laboratory, Ghent University, Ghent, Belgium, <sup>2</sup>The First Affiliated Hospital, Sun Yat-sen University, International Airway Research Center, Guangzhou, China, <sup>3</sup>Division of ENT diseases, CLINTEC, Karolinska Institute, Stockholm, Sweden, <sup>4</sup>Department of Otolaryngology Head and Neck Surgery, Beijing TongRen Hospital, Capital Medical University, Beijing 100730, China

Poster Session, 26 Sept – 30 Sept, 2021, All day

**Background:** Severe type 2 chronic rhinosinusitis with nasal polyps (CRSwNP) often remains uncontrolled by current standard of care treatment. Biologics targeting the key cytokines interleukin-4 and -13 or IgE have been proven efficacious in Phase 3 trials and await introduction into clinical care pathways of CRSwNP. However, efficacy and safety of sinus surgery under biologic treatment remain unknown.

**Methods:** This retrospective study included 11 patients with sinus surgery for uncontrolled severe CRSwNP under biologics treatment and a group of 9 patients with comparable disease who underwent sinus surgery without biologic therapy during this time. Baseline information, intra-operative observations and the wound healing process were monitored.

**Results:** Biologics treatment significantly improved the smell and lung function pre-operatively. There was no increase in adverse events or surgical complications under the biologic, and the duration and completeness of the wound healing process was comparable in the two groups.

**Conclusion:** Sinus surgery under biologic treatment was safe and did not impair wound healing. A combination of sinus surgery and biologics might be the optimal treatment strategy for patients with uncontrolled severe type 2 CRSwNP not fully responding to biologic treatment.

Key words: Chronic rhinosinusitis, Nasal polyps, Biologics, Sinus surgery

## A prospective study of aromatherapy treatment on patients with olfactory disorders after Covid-19 infection.

**Anna Mpouronikou**<sup>1</sup>, Nikolaos Kalogritsas<sup>1</sup>, Fani Saini<sup>1</sup>, Nikolaos Gkolias<sup>1</sup>, Eleni Karoni<sup>1</sup>, Vasileios Lachanas<sup>1</sup>

<sup>1</sup>*Department of Otolaryngology-Head and Neck Surgery, University Hospital of Larisa, Prof. Charalampos Skoulakis, Larisa, Greece*

Poster Session, 26 Sept – 30 Sept, 2021, All day

**Background:** As COVID-19 pandemic spread around the world, anosmia was recognized as a key presenting symptom. This is a prospective study regarding aromatherapy treatment of patients with post-covid-19 olfactory disorders.

**Methodology/Principal:** Patients with persistent olfactory disorders two months after their COVID-19 infection were included. All patients underwent ENT examination, olfactory measurements with sniffin'sticks and subjective measurements with SF-12 general quality of life questionnaire. Participants received a kit with four essential oils (rose, eucalyptol, lemon, cloves) which were used twice daily. Measurements were performed prior to treatment, as well as the 1<sup>st</sup>, 2<sup>nd</sup> and 3<sup>rd</sup> month afterword's.

**Results:** 17 patients 15 to 58 years old were included. The vast majority of patients experienced a mild clinical form of the COVID-19 infection. Aromatherapy in those patients improved their quality of life and the TDI scores (comprehensive score of Threshold, Discrimination, and Identification abilities), even within the 1<sup>st</sup> month of treatment. Many patients with hyposmia and parosmia also reported parosmia reduction within the 1<sup>st</sup> month of aromatherapy.

**Conclusions:** Odorant training may be considered in subjects who experience post-covid olfactory disorders. Aromatherapy may probably be applied in the very early phases of the infection in order to favor a constant stimulation of the olfactory function.

Key words: olfactory disorders, aromatherapy, sniff sticks, COVID-19, parosmia.

### Literature

1. Long-term recovery from COVID-19 anosmia: Promising findings and unanswered questions

2. Pathophysiology of Olfactory Disorders and Potential Treatment Strategies

Stefania Goncalves, M.D. and Bradley J. Goldstein, M.D., Ph.D.

Department of Otolaryngology and Interdisciplinary Stem Cell Institute, University of Miami Miller School of Medicine, Miami, FL

Stefania Goncalves: [sxg402@med.miami.edu](mailto:sxg402@med.miami.edu)

3. Olfactory Disorders and Quality of Life—An Updated Review

Ilona Croy<sup>1,3</sup>, Steven Nordin<sup>2</sup> and Thomas Hummel<sup>3</sup>

<sup>1</sup>Department of Occupational and Environmental Medicine, Gothenburg University, Medicinaregatan 16, 40530 Göteborg, Sweden, <sup>2</sup>Department of Psychology Umeå University SE-90187 Umeå Sweden and <sup>3</sup>Smell & Taste Clinic, Department of Otorhinolaryngology, University of Dresden Medical School, Fetscherstrasse 74, 01307 Dresden, Germany

Correspondence to be sent to: Ilona Croy, Occupational and Environmental Medicine, Medicinaregatan 16, University of Gothenburg, Box 414, 40530 Göteborg, Sweden. e-mail: [ilona.croy@tu-dresden.de](mailto:ilona.croy@tu-dresden.de)

# The development of the mucosal concept in chronic rhinosinusitis and its clinical implications

**Yanran Huang**<sup>1,2</sup>, Nan Zhang MD<sup>1</sup>, Zhaofeng Xu<sup>1,5</sup>, Luo Zhang<sup>2,3</sup>, Claus Bachert<sup>1,4,5</sup>

<sup>1</sup>Upper Airway Research Laboratory, Ghent University, Ghent, Belgium; <sup>2</sup>Department of Allergy, Department of Otolaryngology Head and Neck Surgery, Beijing TongRen Hospital, Capital Medical University, Beijing, P.R. China; <sup>3</sup>Beijing key laboratory of nasal diseases, Beijing Institute of Otolaryngology, Beijing, P.R. China; <sup>4</sup>Division of ENT diseases, CLINTEC, Karolinska Institute, Stockholm, Sweden; <sup>5</sup>The First Affiliated Hospital of Sun Yat-sen University, Sun Yat-sen University, Department of Otorhinolaryngology, International Airway Research Center, Guangzhou, China

Poster Session, 26 Sept – 30 Sept, 2021, All day

**Background:** In the last 2 decades, an increasing understanding of pathophysiological mechanisms in chronic rhinosinusitis opened an avenue from phenotyping to endotyping, from eosinophilic inflammation to type 2 immunity, and from the “ventilation and drainage” paradigm to the mucosal concept for therapeutic considerations.

**Methodology/Principal:** We here aim to focus on the complexity and heterogeneity of the features of CRS endotypes, including its history, latest developments, clinical associations and endotype-driven solutions.

**Results:** Today is clear that the recent achievements undoubtedly shift our understanding from a physical “ventilation and drainage” paradigm to the mucosal concept, as it has been clearly demonstrated that chronic sinusitis is a mucosal disease.

**Conclusions:** Type 2 immune reactions are the key to understand clinical prognosis and severity of disease. The concept of adapted surgical approaches and targeted type 2 biologics as innovative treatment options, often in combination, will change our care pathways profoundly and offer the currently uncontrolled severe CRSwNP patients so far unexperienced progress.

Key words: Chronic rhinosinusitis; Nasal polyps; Endotype; Type 2 inflammation



A clinical case presentation of an angiomatous antrochoanal polyp that simulates sinonasal malignancy.

**Konstantinos Chantzis<sup>1</sup>**, Stavros Ioakeimidis<sup>1</sup>, Eustratios Moschovakis<sup>1</sup>

<sup>1</sup>Otorhinolaryngology Department, General Hospital of Nikaia Agios Panteleimon, Athens, Greece.

Poster Session, 26 Sept – 30 Sept, 2021, All day

**Background:** Angiomatous nasal polyps are rare subtypes of inflammatory sinonasal polyps (5%) which are characterized by extensive vascular proliferation and ectasia.

**Principal:** A 29 years-old female patient came to our department complaining about recurrent epistaxis of the right nostril. During an endoscopic examination, a reddish-dark polypoid tumour, originating from the middle meatus, was observed. CT scan demonstrated a mass, completely filling the maxillary sinus, extending through the nasal cavity, widening the maxillary ostium and deviating the nasal septum. The histopathological examination of endoscopic incision biopsy showed blood clots and fibrous exudate. Following that, an endoscopic sinus surgery under general anesthesia was performed, resecting the whole tumour in parts due to its fragility.

**Results:** Immunohistochemical examination of the sample resulted to the identification of a nasal polyp, with abundant plasma cell infiltration and dilated clotted vascular profusion, giving the diagnosis of an angiomatous antrochoanal polyp.

**Conclusions:** The angiomatous antrochoanal polyp, as a histopathological examination aftermath of a single antrochoanal polyp, is probably due to venal congestion at the site of the ostium, or tissue damaging. This case should be considered during a differential diagnosis of unilateral bleeding mass in order to avoid amputating procedures that are necessary to other malignancies.

*Key words:* angiomatous polyp, antrochoanal polyp, epistaxis, sinonasal malignancy, nasal mass

#### Literature

1. Yfantis HG, Drachenberg CB, Gray W, Papadimitriou JC. Angiectatic nasal polyps that clinically simulate a malignant process: report of 2 cases and review of the literature. Arch Pathol Lab Med 2000;124:406-10
2. Batsakis JG, Sneige N. Choanal and angiomatous polyps of the sinonasal tract. Ann Otol Rhinol Laryngol 1992;101:623-5
3. Sheahan P, Crotty PL, Hamilton S, Colreavy M, McShane D. Infarcted angiomatous nasal polyps. Eur Arch Otorhinolaryngol 2005;262:225-30
4. Som PM, Cohen BA, Sacher M, Choi IS, Bryan NR. The angiomatous polyp and the angiofibroma: two different lesions. Radiology. 1982;144: 329-334.
5. Sheahan P, Crotty PL, Hamilton S, Colreavy M, McShane D. Infarcted angiomatous nasal polyps. Eur Arch Otorhinolaryngol. 2005;262:225-230.

## Bitter taste in patients with CRS and Cystic fibrosis

**Konstantinos Garefis<sup>1</sup>**, Angelos Chatziavramidis<sup>1</sup>, Konstantinos Tarazis<sup>1</sup>, Evangelia Tsakiropoulou<sup>1</sup>, Konstantinos Markou<sup>1</sup>, Iordanis Konstantinidis<sup>1</sup>

<sup>1</sup>2<sup>nd</sup> Academic ORL, Head and Neck Surgery Department Aristotle University of Thessaloniki, Papageorgiou Hospital, Thessaloniki, Greece

Poster Session, 26 Sept – 30 Sept, 2021, All day

**Background:** Bitter taste receptors are expressed from the ciliated cells and solitary chemosensory cells in the upper airway. Stimulation of these receptors result in fighting bacteria through release of NO and antimicrobial peptides.

**Methodology/Principal:** We assessed the bitter taste ability, by using taste strips of phenylthiocarbamide, in CRSsNP (n=19), CRSwNP (n=33), Cystic fibrosis (n=14) patients, planned for FESS and controls (n=26), within a period of 2 years. All participants were >18 years old and distributed as non-tasters, tasters and supertasters. Lund-Mackey score and SNOT-22 were also assessed.

**Results:** Controls have a distribution as follows: 26% non-tasters, 44% tasters and 30% supertasters. Comparison of controls with CRSsNP patients showed that the percentage of non-tasters is significantly higher in CRSsNP subgroup ( $p<0,05$ ). Additionally, the percentage of non-tasters in CRSwNP group is higher than control group. However, in Cystic Fibrosis subgroup the tasters are significantly higher than in controls ( $p<0,05$ ). No correlation was found between bitter taste, Land – Mackey score and SNOT-22 in patients' subgroups.

**Conclusions:** CRSsNP patients are more likely to be less sensitive to bitter taste. However, Cystic Fibrosis patients presented a different phenotype distribution being more sensitive to bitter taste.

**Key words:** CRS; Cystic Fibrosis; bitter taste; phenylthiocarbamide

#### Literature

1. Rowan NR, Soler ZM, Othieno F, Storck KA, Smith TL, Schlosser RJ. Impact of bitter taste receptor phenotype upon clinical presentation in chronic rhinosinusitis. *IntForumAllergyRhinol*. 2018 Sep;8(9):1013-1020.
2. Jeruzal-Świątecka J, Fendler W, Pietruszewska W. Clinical Role of Extraoral Bitter Taste Receptors. *Int J MolSci*. 2020;21(14):5156.
3. Workman AD, Brooks SG, Kohanski MA, Blasetti MT, Cowart BJ, Mansfield C et al. Bitter and sweet taste tests are reflective of disease status in chronic rhinosinusitis. *J Allergy Clin Immunol Pract*. 2018 May-Jun;6(3):1078-1080.
4. Lee RJ, Cohen NA. The emerging role of the bitter taste receptor T2R38 in upper respiratory infection and chronic rhinosinusitis. *Am J RhinolAllergy*. 2013 Jul-Aug;27(4):283-6. doi: 10.2500/ajra.2013.27.3911. PMID: 23883809.
5. Civantos AM, Maina IW, Arnold M, Lin C, Stevens EM, Tan LH et al. Denatonium benzoate bitter taste perception in chronic rhinosinusitis subgroups. *Int Forum Allergy Rhinol*. 2021 Jun;11(6):967-975.

## Age of presentation as a distinguishing feature between persistent rhinitis and chronic rhinosinusitis.

**Adam Perkovic<sup>1</sup>**, Jacqueline Ho<sup>1</sup>, Dichapong Kanjanawasee<sup>1</sup>, Raquel Alvarado<sup>1</sup>, Janet Rimmer<sup>1,2,3</sup>, Larry Kalish<sup>1,4,5</sup>, Raewyn G Campbell<sup>1,6,7</sup>, Raymond Sacks<sup>4,5,7</sup>, Richard J. Harvey<sup>1,7</sup>

<sup>1</sup>Rhinology and Skull Base Research Group, Applied Medical Research Centre, University of New South Wales, Sydney, Australia, <sup>2</sup>Woolcock Institute, University of Sydney, Australia, <sup>3</sup>Faculty of Medicine, Notre Dame University, Sydney, Australia, <sup>4</sup>Faculty of Medicine, University of Sydney, Australia, <sup>5</sup>Department of Otolaryngology, Head and Neck Surgery, Concord General Hospital, University of Sydney, <sup>6</sup>Department of Otolaryngology Head and Neck Surgery, Royal Prince Alfred Hospital, Sydney, Australia, <sup>7</sup>Faculty of Medicine, Health and Human Sciences, Macquarie University, Sydney, Australia

Poster Session, 26 Sept – 30 Sept, 2021, All day

**Background:** Individuals with persistent rhinitis (PR) and chronic rhinosinusitis (CRS) often present similar clinical characteristics. This study aims to differentiate the demographics between these patient populations.

**Methodology/Principal:** A cross-sectional analysis was performed of adult patients ultimately diagnosed with PR or CRS who presented with sinonasal symptoms to a tertiary rhinologic clinic. Variables assessed include age, gender, smoking status, alcohol consumption, gastro-oesophageal reflux disease and active asthma. Patient atopic status was also defined.

**Results:** 651 participants were included (46.8±14.9 years, 43.8% female). Patients with rhinitis were younger than those with CRS (40.3±14.2 vs 49.1±14.5 years,  $p<0.001$ ) and had a lower prevalence of gastro-oesophageal reflux (9.8% vs 16.3%,  $p=0.04$ ) and active asthma (25.8% vs 45.5%,  $p<0.001$ ). Those with allergic rhinitis were even younger than non-atopic CRS (36.1±13.0 vs 52.1±14.8 years,  $p<0.001$ ). In those patients <30 years old, the diagnostic odds ratio of having allergic rhinitis as the cause of ‘sinonasal’ symptoms was 8.86 and positive likelihood ratio was 5.71.

**Conclusions:** Younger patients, especially those <35, are more likely to have a rhinitis condition producing their sinonasal symptoms than CRS.

*Key words: age, allergic rhinitis, chronic rhinosinusitis, demographics, persistent rhinitis*

## Comparison of Septal Extension Grafts to Columella Strut Grafts in Airway Function, Patient Satisfaction and Tip Support.

**Adil Lathif<sup>1</sup>**, Raquel Alvarado,<sup>1</sup> Mickey Kondo<sup>1</sup>, João Mangussi-Gomes<sup>1</sup>, George N. Marcells<sup>2</sup>, Richard J. Harvey<sup>1,3</sup>.

<sup>1</sup>Rhinology and Skull Base Research Group, Applied Medical Research Centre, University of New South Wales, Sydney, Australia, <sup>2</sup>Bondi Junction Private Hospital, Bondi Junction, New South Wales, Australia, <sup>3</sup>Faculty of Medicine and Health Sciences, Macquarie University, Sydney, Australia

Poster Session, 26 Sept – 30 Sept, 2021, All day

**Background:** Different techniques exist to provide tip support in rhinoplasty. Those with Septal Extension Graft (SEG) were compared to those with Columella Strut Graft (CSG).

**Methodology/Principal:** Patients with SEG or CSG at a tertiary rhinoplasty centre were retrospectively compared. Nasal peak inspiratory flow (NPIF) and nasal airway resistance (NAR) were the primary airway outcomes. The primary PROMs analysed were a visual analogue scale for nasal obstruction and 13-point Likert scale for global cosmesis, the Nose Outcome Symptom Evaluation. Tip support was determined by the Nasolabial Angle (NLA) and Simon's Ratio as assessed by Rhinobase software on lateral Frankfort plane photographs.

**Results:** 165 patients were assessed (72% female), 100 (61%) of which received SEG. There were similar nasal airway assessments between CSG and SEG (NPIF and NAR). Amongst PROMs, a greater cosmetic outcome was seen in the SEG group ( $7.20 \pm 2.97$  v  $5.69 \pm 3.45$ ,  $p < 0.01$ ) with all other assessments similar between techniques. Photographic analysis of tip projection showed reduced NLA distortion in the SEG.

**Conclusions:** Greater patient perceived cosmesis was reported in SEG patients. There were similar airflow and patient reported nasal function between groups. Photographic analysis showed SEG patients benefited from less NLA distortion and greater tip maintenance.

Key words:

Rhinoplasty, Facial Plastics, Septal Extension Graft, Columella Strut, Nasal Tip

## The changing face of rhinology in the NHS: a study of septoplasty, septorhinoplasty and rhinoplasty hospital episode statistics

Edward Balai<sup>1</sup>, Karan Jolly<sup>1</sup>, Navdeep Bhamra<sup>1</sup>, Max Osborne<sup>1</sup>, James Barraclough<sup>1</sup>.

<sup>1</sup>*Department of ENT, New Cross Hospital, The Royal Wolverhampton NHS Trust*

Poster Session, 26 Sept – 30 Sept, 2021, All day

**Background:** In 2011, septorhinoplasty and rhinoplasty were reclassified as procedures of limited clinical value in the NHS. The criteria for funding these operations varies across England. We aimed to use Hospital Episode Statistics (HES) and Freedom of Information (FOI) requests to review the total number of rhinology procedures performed across the previous decade, looking at trends in practice related to time, demographic, and commissioning policy.

**Methodology/Principal:** HES for 2012-2019 were used to calculate the number of septoplasty, septorhinoplasty, rhinoplasty and reduction rhinoplasty procedures performed in children and adults. FOI requests were also made to all Clinical Commissioning Groups (CCGs) in England asking for number of procedures performed and number of Individual Funding Requests (IFRs) made.

**Results:** 158,031 procedures were performed over this period; the majority were in adult (99.0%) males (65.7%). Septoplasty was the most frequently performed operation; however, the total numbers declined by 5.4% over this period. There was a yearly reduction in the overall number of septorhinoplasty, rhinoplasty and reduction rhinoplasty operations. Four CCGs provided a detailed breakdown of data by year and procedure. Those that required IFRs for all cases saw septorhinoplasty numbers fall by 81% and 75% over the period. Those that did not, saw numbers increase or remain the same.

**Conclusions:** We found an overall year-on-year reduction in the number of rhinology operations being performed in the NHS, but variation in trends between different CCGs. A reduction in operative activity likely represents the effect of underlying restrictions on commissioning rather than reduced clinical need.

**Key words:** Rhinoplasty, Septoplasty, Septorhinoplasty

## Intranasal steroids for non-allergic rhinitis

**Christine L. Segboer**<sup>1</sup>, A. Gevorgyan<sup>2</sup>, K. Avdeeva<sup>3</sup>, Wytske J. Fokkens<sup>3</sup>

<sup>1</sup>*Dijklander Hospital, Hoorn and Purmerend, The Netherlands*, <sup>2</sup>*Lakeridge Health Oshawa, Oshawa, Canada*, <sup>3</sup>*University Medical Center (UMC) Amsterdam, The Netherlands*

Poster Session, 26 Sept – 30 Sept, 2021, All day

**Background:** Intranasal corticosteroids (INCS) are often prescribed in patients with rhinitis or rhinosinusitis symptoms, including those with non-allergic rhinitis (NAR). INCS are considered to be most effective in rhinitis or rhinosinusitis with Th2-inflammation. It is unclear whether INCS are effective in NAR or specific phenotypes of NAR.

**Methodology/Principal:** Cochrane Systematic Review

**Results:** Intranasal corticosteroids versus placebo:

Intranasal corticosteroid treatment may improve patient-reported disease severity as measured by total nasal symptom score compared with placebo at up to four weeks (SMD -0.74, 95% confidence interval (CI) -1.15 to -0.33; 131 participants; 4 studies;  $I^2 = 22\%$ ) (low-certainty evidence). Between four weeks and three months the evidence is very uncertain (SMD -0.24, 95% CI -0.67 to 0.20; 85 participants; 3 studies;  $I^2 = 0\%$ ) (very low-certainty evidence).

Intranasal corticosteroids versus other treatments:

Only one or a few studies assessed intranasal corticosteroids versus other possible treatments and therefore it is uncertain whether there are differences between intranasal corticosteroids and other active treatments.

**Conclusions:** The quality of the evidence for most outcomes in the Cochrane Review was low or very low. It is unclear whether intranasal corticosteroids reduce patient-reported disease severity in NAR patients compared with placebo when measured at up to three months.

Key words: intranasal steroids, INCS, non-allergic rhinitis, idiopathic rhinitis, inflammation

## Treatment of loco-regional recurrences of nasopharyngeal carcinoma: oncological outcomes, morbidity, and predictive nomograms

Vittorio Rampinelli <sup>1</sup>, Alberto Schreiber <sup>1</sup>, Marco Ferrari <sup>2</sup>, Davide Mattavelli <sup>1</sup>, Roberta Rosati <sup>1</sup>, Daniela Alterio <sup>3</sup>, Pierluigi Bonomo <sup>4</sup>, Barbara Vischioni <sup>5</sup>, Marta Maddalo <sup>6</sup>, Davide Tomasini <sup>6</sup>, Alessia Lambertoni <sup>7</sup>, Tommaso Gualtieri <sup>1</sup>, Michele Tomasoni <sup>1</sup>, Mario Turri-Zanoni <sup>7</sup>, Stefano Maria Magrini <sup>6</sup>, Paolo Castelnuovo <sup>7</sup>, Paolo Bossi <sup>8</sup>, Alberto Deganello <sup>1</sup>, Cesare Piazza <sup>1</sup>, Piero Nicolai <sup>2</sup>, Ester Orlandi <sup>5</sup>.

<sup>1</sup>Unit of Otorhinolaryngology - Head and Neck Surgery, University of Brescia, Brescia, Italy, <sup>2</sup>Section of Otorhinolaryngology – Head and Neck Surgery, Department of Neurosciences, University of Padua, Padua, Italy, <sup>3</sup>Unit of Radiotherapy, Istituto Europeo di Oncologia, Milan, Italy, <sup>4</sup>Unit of Radiotherapy, Azienda Ospedaliero-Universitaria Careggi, Florence, Italy, <sup>5</sup>Centro Nazionale di Adroterapia Oncologica di Pavia, Pavia, Italy, <sup>6</sup>Istituto del Radio Alberti, University of Brescia, Brescia, Italy, <sup>7</sup>Unit of Otorhinolaryngology - Head and Neck Surgery, ASST Sette Laghi di Varese, Varese, Italy, <sup>8</sup>Unit of Oncology, University of Brescia, Brescia, Italy

Poster Session, 26 Sept – 30 Sept, 2021, All day

**Background:** Recurrent nasopharyngeal carcinoma (NPC) is a rare disease with controversial therapeutic strategies.

**Materials and methods:** Italian Multicenter collaboration with retrospective recruitment of patients affected by local/regional relapse of NPC, treated with endoscopic and open surgery, radiotherapy, and chemotherapy (exclusive or in multimodal setting) with radical intent. Prognostic factors, survival, and treatment-related morbidity were analyzed, and a predictive survival nomogram was developed.

**Results:** A total of 140 patients were included in the study, of which 48.1 % treated with surgery and 51.8% with re-irradiation (43.0% proton based and 57.0% photon based). Neoadjuvant chemotherapy was performed in 27 patients. Thirty-five patients experienced toxicity  $\geq$  G3, 16.9% and 37.6% in the cohort treated with surgery and re-irradiation, respectively. At multivariable analysis, age and DFI were independent factors influencing OS and DSS, as opposed to stage and treatment modality. Treatment modality was not associated with increased complication rate. Predicting nomograms were developed for OS, DSS, and RFS.

**Conclusions:** Treatment modality does not seem to affect OS of patients with recurrent NPC, unlike age and DFI. Although without significant difference at multivariate analysis, the rate of severe complications is not negligible in both surgery and re-irradiation cohorts.

Key words: Nasopharyngeal carcinoma, nomogram, oncology

## Influence of local anaesthesia for respiratory epithelial samples on ciliary functional analysis

**L. Benchimol<sup>1</sup>**, N. Bricmont<sup>2</sup>, S. Dubois<sup>1</sup>, R. Bonhiver<sup>2</sup>, H. Boboli<sup>3</sup>, M.C. Seghaye<sup>4</sup>, R. Louis<sup>2,5</sup>, P.P. Lefebvre<sup>1</sup>, J.F. Papon<sup>6,7,8</sup>, B. Louis<sup>8</sup>, C. Kempeneers<sup>2,3</sup>, A.L. Poirrier<sup>1</sup>

<sup>1</sup>ENT Department, University Hospital of Liege, Belgium, <sup>2</sup>I3 Group, GIGA Research Centre, University of Liege, Belgium, <sup>3</sup>Division of Respiriology, Department of Pediatrics, University Hospital of Liege, Belgium, <sup>4</sup>Division of Cardiology, Department of Pediatrics, University Hospital of Liege, Belgium, <sup>5</sup>Department of Pneumology, University Hospital of Liege, Belgium, <sup>6</sup>Assistance Publique-Hôpitaux de Paris (AP-HP), ENT Department, Hôpital Bicêtre, Le Kremlin-Bicêtre 94275, France, <sup>7</sup>Université Paris-Saclay, Faculté de Médecine, Le Kremlin-Bicêtre 94275, France, <sup>8</sup>Université Paris-Est, Faculté de Médecine, Institut National de la Santé et de la Recherche Médicale (INSERM U955), CNRS ERL7240, Hôpital Henri Mondor, Créteil 94010, France

Poster Session, 26 Sept – 30 Sept, 2021, All day

**Background:** Digital high-speed videomicroscopy (DHSV) is highly sensitive and specific for primary ciliary dyskinesia diagnosis. However, the effect of local anaesthesia for sample collection on ciliary beating has never been studied in humans. Our goal was to compare ciliary function after local anaesthetic or saline application, and secondarily to evaluate ciliary function over time after local anaesthesia.

**Methodology:** Ciliated epithelial samples were obtained by lower turbinate brushing from 5 healthy subjects after saline or local anaesthetic application. DHSV assessed ciliary beat frequency (CBF) and percentage of normal ciliary beat pattern (CBP) at 0, 1 and 3 hours after samples collection.

**Results:** Ciliary function evaluated immediately after nasal brushing was not significantly impacted by local anaesthesia. CBF was 14.00[11,14-17,47] Hz and 14.13 [10.78-16.75] Hz with or without local anaesthesia, respectively (Wilcoxon  $p > 0.9999$ ). Normal CBP was 74.40[68.25-89.85] % and 51.50 [27.05-94.10] % with and without local anaesthesia, respectively (Wilcoxon  $p = 0.4375$ ). There was no ciliary function variation over time after local anaesthesia. Kruskal Wallis H at 0, 1 and 3 hours after brushing was 0.74 for CBF( $p = 0.69073$ ) and 1.295 for normal CBP( $p = 0.52335$ ).

**Conclusion:** This pilot study suggested that local anaesthesia had no effect on ciliary function in humans. Larger studies are needed to confirm these preliminary results, notably in pathological conditions.

**Keywords:** Primary ciliary dyskinesia, Ciliary motility disorder, Diagnosis, Microscopy.

This study was approved by the ethic committee of the CHU Liege.



# Severity, duration and predisposing factors of olfactory and taste disorders in a hospitalized Greek population with COVID-19 infection: study protocol and preliminary results.

Athanasia Milioni<sup>1</sup>, Angelos Saratsiotis<sup>1</sup>, George Karampelias<sup>1</sup>, Gerasimos Karageorgos<sup>1</sup>, Pinelopi Grigoropoulou<sup>2</sup>, Dimitrios Davilis<sup>1</sup>

<sup>1</sup>ENT Department, Elpis General Hospital, Athens, Greece, <sup>2</sup>Internal Medicine Department, Elpis General Hospital, Athens, Greece

Poster Session, 26 Sept – 30 Sept, 2021, All day

**Background:** The aim of our study is to determine the prevalence and duration of olfactory and taste changes associated with COVID-19 infection in hospitalized patients, as well as detecting any predisposing factors, using standardized methods.

**Methodology/Principal:** A prospective, cohort study in a secondary hospital was conducted from December 2020. 63 hospitalized patients with COVID-19 infection, confirmed by molecular testing, were voluntarily included. The subjects were asked to complete specially designed self-reported questionnaires about their symptoms due to COVID-19 infection. Subsequently, they underwent an olfactory test (UPSIT) and a subjective taste test on the same day. At monthly follow-up, the subjects were assessed with the same methods.

**Results:** Almost 45% of patients self-reported loss of smell, which was confirmed by the UPSIT,

and 6 of them were found to have complete anosmia. 80% had lower severity scores. The majority reported improvement or complete resolution by the time of initial follow-up. Only 2 patients reported independent taste disturbances. The Bitter taste was the most commonly found to be affected. Younger age and BMI were found to have a correlation with smell loss.

**Conclusions:** Objective methods revealed almost double prevalence of smell and taste disorders compared to subjective ones. Early recovery rates were observed in the majority, a finding consistent with other studies.

Key words: Smell and taste disorders, Anosmia, COVID-19

## Giant aneurysmal bone cyst of maxillary sinus: A rare entity case report

**M.Givannakis<sup>1</sup>**, I.Koskinas<sup>1</sup>, S-E.Tzorakoleftheraki<sup>2</sup>, C.Fotiadou<sup>3</sup>, P.Karkos<sup>1</sup>, G.Tsiropoulos<sup>1</sup>, D.Anestakis<sup>2</sup>, V.Rafailidis<sup>3</sup>, J.Constantinidis<sup>1</sup>

<sup>1</sup>*1<sup>st</sup> Department of ENT, AHEPA University hospital, Thessaloniki, Greece,* <sup>2</sup> *Department of Autopsy Histopathology, Laboratory of Forensic Medicine and Toxicology, Aristotle University, Thessaloniki, Greece* , <sup>3</sup>*Radiology Department, AHEPA University Hospital, Thessaloniki, Greece*

Poster Session, 26 Sept – 30 Sept, 2021, All day

**Introduction:** Primary aneurysmal bone cyst (ABC) is a benign, clonal neoplasm, usually affecting the long bones of pediatric patients. Only 2% of ABCs are located in the head and neck region, while the location of the sinonasal cavity is extremely rare.

**Case presentation:** We report the case of a 27 years old male patient, who presented with nasal obstruction, catarrh, foreign body sensation, combined with mild dysphagia. Clinical investigation revealed obstruction of left nasal cavity, with bulging of the lateral nasal wall and the presence of a hard palate solid mass. A CT and MRI was conducted, with findings indicative of ABC. A transnasal endoscopic excision of the mass was performed, within safe boundaries, through a medial maxillectomy approach. Histopathological examination confirmed the diagnosis of ABC. Two year follow up showed no signs of recurrence.

**Conclusions:** Although a benign neoplasm, ABC may behave aggressively, invading adjacent structures. Atypical sites, as craniofacial bones should not rule out ABC from differential diagnosis. Associated primary bone pathology should be investigated. Endoscopic sinus surgery should be a first line surgical treatment, whenever applicable. Long term follow up, is vital due to recurrence risk.

Key words: Aneurysmal cyst, maxillary sinus, craniofacial bones.

#### Literature

Fyrmpas G, Constantinidis J, Televantou D, Konstantinidis I, Daniilidis J. Primary aneurysmal bone cyst of the maxillary sinus in a child: case report and review of the literature. *Eur Arch Otorhinolaryngol.* 2006 Jul;263(7):695-8

Martinez V, Sissons HA (1988) Aneurysmal bone cyst: a review of 123 cases including primary lesions and those secondary to other bone pathology. *Cancer* 61:2291–2304

McMullen, P. D., Bridge, J. A., Blair, E. A., Yang, C. W., Collins, J., & Cipriani, N. A. Aneurysmal Bone Cyst of the Maxillary Sinus with USP6 Rearrangement: Case Report of a Rare Entity and Review of the Literature. *Head Neck Pathol.* 2019 Sep;13(3):281-285

Suzuki F, Fukuda S, Yagi K, Chida E, Inuyama Y. A rare aneurysmal bone cyst of the maxillary sinus: a case report. *Auris Nasus Larynx.* 2001;28:S131–7.

Seyyed MH, Heidarpour M, Eshaghian A, Ansari P, Hashemi MH, Yaghoobi M, Barati S. A rare case of aneurysmal bone cyst in the paranasal sinus. *Iran J Otorhinolaryngol.* 2015;27(82):395–9.

- Bataineh AB. Aneurysmal bone cyst of the maxilla: a clinico-pathologic review. *J Oral Maxillofac Surg.* 1997;55:1212–16.
- Segall L, Cohen-Kerem R, Ngan BY, Forte V. Aneurysmal bone cysts of the head and neck in pediatric patients: a case series. *Int J Ped Otorhinolaryngol.* 2008;72:977–83.
- Fennessy BG, Vargas SO, Silvera MV, Ohlms LA, McGill TJ, Healy GB, Rahbar R. Paediatric aneurysmal bone cysts of the head and neck. *J Laryngol Otol.* 2009;123:635–41.
- Boyd RC. Aneurysmal bone cysts of the jaws. *Br J Oral Surg.* 1979;16:248.
- Robinson PD. Aneurysmal bone cyst: a hybrid lesion? *Br J Oral Maxillofac Surg.* 1985;23:220.
- Ellis DL, Walters PJ. Aneurysmal bone cyst of the maxilla. *Oral Surg.* 1972;34:26.
- Takimoto T, Kamide M, Umeda R. Aneurysmal bone cyst of the maxilla: a case report. *Rhinology.* 1990;28:205.
- Yarington CT, Abbot J, Raines D. Aneurysmal bone cyst of the maxilla: association with giant cell reparative granuloma. *Arch Otolaryngol.* 1964;80:313.

Design of a software aiming to assist the decision on how to administer analgosedation during drug-induced sleep endoscopy.

**Nicoleta Dumitrescu<sup>1</sup>**

<sup>1</sup>ENT Department, "Saint Spiridon" Clinic, Bucharest, Roumania

Poster Session, 26 Sept – 30 Sept, 2021, All day

**Background:** Drug-induced sleep endoscopy can be performed either in the operating room or in the outpatient office depending on certain conditions. Starting from the European and American guidelines regarding sedation during gastrointestinal investigations, we have developed a software that aims to help the ENT specialist to decide where is best to undergo this diagnostic procedure.

**Methodology/Principal:** The application is written in C#, using the .NET Framework, and is available for the Windows operating system. It also has a very simple and user-friendly interface with a bare-bones implementation focusing strictly on the decision-making process. The project was designed in collaboration with a software engineer.

**Results:** The application uses the information obtained from patient history, clinical examination and polysomnography. After filling the patient's data, it shows one of the following results: "treatment can be ambulatory", "treatment should be done in the hospital" or "treatment is not recommended".

**Conclusions:** The software designed for the decision-making process may substitute the evaluation of the anaesthesiologist during drug-induced sleep endoscopy in certain conditions.

Key words: drug-induced sleep endoscopy, analgosedation, software application.

#### Literature

1. Shamsuzzaman ASM, Gersh BJ, Somers VK. Obstructive sleep apnea, implications for cardiac and vascular disease. *JAMA*. 2003;290(14):1906–14. DOI:10.1001/jama.290.14.1906.
2. George CF, Smiley A. Sleep apnea & automobile crashes. *Sleep*. 1999;22(6):790–5.
3. Passali FM, Marzetti A, Bellussi L, Passali D. The diagnosis of obstructive sleep apnea syndrome. *Romanian Journal of Rhinology*. 2013;3(12):195-202.
4. Lo YL, Ni YL, Wang TY, Lin TY, Li HY, White DP, et al. Bispectral index in evaluating effects of sedation depth on drug-induced sleep endoscopy. *Clin Sleep Med*. 2015;11(9):1011-20.
5. De Corso E, Fiorita A, Rizzotto G, Mennuni GF, Meucci D, Giuliani M, et al. The role of drug-induced sleep endoscopy in the diagnosis and management of obstructive sleep apnoea syndrome: our personal experience. *Acta Otorhinolaryngol Ital*. 2013;33(6):405-13.
6. Civelek S, Emre IE, Dizdar D, Cuhadaroglu C, Eksioglu BK, Eraslan AK, et al. Comparison of conventional continuous positive airway pressure to continuous positive airway pressure titration performed with sleep endoscopy. *Laryngoscope*. 2012;122(3):691-5. DOI: 10.1002/lary.22494.
7. An Updated Report by the American Society of Anesthesiologists Task Force on Sedation and Analgesia by Non-Anesthesiologists. Practice Guidelines for Sedation and Analgesia by Non-Anesthesiologists. *Anesthesiology*. 2002;96:1004-17. DOI: 10.1097/00000542-200204000-00031.
8. Early DS, Lightdale JR, Vargo JJ, Acosta RD, Chandrasekhara V, Chathadi KV, et al. Guidelines for sedation and anesthesia in GI endoscopy. *Giejournal*. 2018;87(2):327-37.
9. Hassan C, Rex DK, Cooper GS, Benamouzig R. Endoscopist-directed propofol administration versus anesthesiologist assistance for colorectal cancer screening: a cost-

- effectiveness analysis. *Endoscopy*. 2012;44(5):456-64. DOI: 10.1055/s-0032-1308936.
10. Dumonceau JM, Riphaus A, Schreiber F, Vilmann P, Beilenhoff U, Aparicio JR, et al. Non-anesthesiologist administration of propofol for gastrointestinal endoscopy: European Society of Gastrointestinal Endoscopy, European Society of Gastroenterology and Endoscopy Nurses and Associates Guideline—Update June 2015. *Endoscopy*. 2015;47(12):1175-89. DOI: 10.1055/s-0034-1393414.
  11. Calderwood AH, Chapman FJ, Cohen J, Cohen LB, Collins J, Day LW, et al. Guidelines for safety in the gastrointestinal endoscopy unit. *Gastrointest Endosc*. 2014;79(3):363-72. DOI: 10.1016/j.gie.2013.12.015.
  12. American Society of Anesthesiologists Committee. Practice guidelines for preoperative fasting and the use of pharmacologic agents to reduce the risk of pulmonary aspiration: application to healthy patients undergoing elective procedures: an updated report by the American Society of Anesthesiologists Committee on Standards and Practice Parameters. *Anesthesiology*. 2011;114(3):495-511. DOI: 10.1097/ALN.0b013e3181fcbfd9.
  13. Vargo JJ, DeLegge MH, Feld AD, Gerstenberger PD, Kwo PY, Lightdale JR, et al. Multisociety sedation curriculum for gastrointestinal endoscopy. *Gastrointest Endosc*. 2012;76(1):e1-25.
  14. Willey J, Vargo JJ, Connor JT, Dumot JA, Conwell DL, Zuccaro G. Quantitative assessment of psychomotor recovery after sedation and analgesia for outpatient EGD. *Gastrointest Endosc*. 2002;56(6):810-6. DOI: 10.1067/mge.2002.129609.
  15. Horiuchi A, Nakayama Y, Hidaka N, Ichise Y, Kajiyama M, Tanaka N. Low-dose propofol sedation for diagnostic esophagogastroduodenoscopy: results in 10,662 adults. *Am J Gastroenterol*. 2009;104(7):1650-5. DOI: 10.1038/ajg.2009.250.
  16. Kiaer EK, Tønnesen P, Sørensen HB, Rubek N, Hammering A, Møller C, Hildebrandt AM, et al. Propofol sedation in Drug Induced Sedation Endoscopy without an anaesthesiologist - a study of safety and feasibility. *Rhinology*. 2019;57(2):125-131. DOI: 10.4193/Rhin18.066.
  17. Goudra BG, Singh PM, Gouda G, Borle A, Gouda D, Dravida A, et al. Safety of non-anesthesia provider administered propofol (NAAP) sedation in advanced gastrointestinal endoscopic procedures: comparative meta-analysis of pooled results. *Dig Dis Sci*. 2015;60(9):2612-27. DOI: 10.1007/s10620-015-3608-x.
  18. Sethi S, Wadhwa V, Thaker A, Chuttani R, Pleskow DK, Barnett SR, et al. Propofol versus traditional sedative agents for advanced endoscopic procedures: a meta-analysis. *Dig Endosc*. 2014;26(4):515-24. DOI: 10.1111/den.12219.
  19. Sieg A, bng-Study-Group; Beck S, Scholl SG, Heil FZ, Gotthardt DN, et al. Safety analysis of endoscopist-directed propofol sedation: a prospective, national multicenter study of 24 441 patients in German outpatient practices. *J Gastroenterol Hepatol*. 2014;29(3):517-23. DOI: 10.1111/jgh.12458.
  20. Gupta A. Preoperative screening and risk assessment in the ambulatory surgery patient. *Curr Opin Anaesthesiol*. 2009;22(6):705-11. DOI: 10.1097/ACO.0b013e3283301fb3.

## Ultra-Low Dose CBCT: good image quality - minimal radiation dose

Pekka Tamminen<sup>1</sup>, Jorma Järnstedt<sup>2</sup>, Antti Lehtinen<sup>2</sup>, Ilkka Kivekäs<sup>1</sup>, Jura Numminen<sup>1</sup>, Lauri Lehtimäki<sup>3</sup> and Markus Rautiainen<sup>1</sup>

<sup>1</sup>Department of Otorhinolaryngology – Head and Neck Surgery, Tampere University Hospital, Finland,

<sup>2</sup>Department of Radiology, Medical Imaging Centre, Tampere University Hospital, Finland, <sup>3</sup>Department of Respiratory Medicine, Tampere University Hospital, Finland

**Background:** Image quality evaluation of ultra-low dose (ULD) cone beam computed tomography (CBCT) and its feasibility in imaging of chronic rhinosinusitis (CRS).

**Methodology/Principal:** Thirty-three patients with CRS were scanned with our standard protocol (NAV) and ULD with 4-6 weeks intervals. Four authors assessed the image quality (IQ) with 6-point Likert scale 0-5. Zinreich modified Lund-Mackay score was used to assess radiological disease severity.

**Results:** IQ with both protocols was clinically high-class. NAV imaging offered unanimously excellent (median 5; min 0) IQ from all assessed nasal structures compared to median of good (median 4; min 0) with ULD. Median IQ was significantly better with NAV compared to ULD ( $p < 0.05$ ).

The percentages of insufficient IQ (0-2) were low (median: NAV 0.0; ULD 2.2); Significantly higher with ULD than NAV at lateral lamella and posterior ethmoidal artery, but higher with NAV at planum sphenoidale. In both modalities, greater degree of opacification was associated to poorer image quality.

ULD scans were also successfully used for navigation.

**Conclusions:** The image quality of ULD CBCT is good for imaging CRS patients with 85 % less radiation compared to NAV: Dose area product equals to 7-9 days of background radiation or 2-3 projections of conventional sinus x-rays.

Key words:

Diagnostic Imaging

Sinusitis

Cone-Beam Computed Tomography

## Transnasal endoscopic medial maxillectomy as first choice in recurrent inverted papilloma of the maxillary sinus: a case report

**Panagiotis Pyrgakis**<sup>1</sup>, Nikolaos Drimalas<sup>1</sup>, Athanasia Tourgeli<sup>1</sup>, Alexandra Kovac<sup>1</sup>, Sotirios Botsakis<sup>1</sup>, Christos Georgalas<sup>2</sup>

<sup>1</sup>General Hospital "Evangelismos", Athens, Greece, <sup>2</sup>Ygeia Hospital, Athens, Greece

Poster Session, 26 Sept – 30 Sept, 2021, All day

**Background:** Inverted papilloma is the most common benign sinonasal tumor. It has a high rate of recurrence (11.5%) and a potential of malignant transformation (7%) or coexistence with SCC (9.3%). This case report describes the management of a patient with recurrent inverted papilloma of the maxillary sinus. Caldwell-Luc, midface degloving and endoscopic approaches are used in such cases, depending on patient anatomy and the tumor's attachment point.

**Case report:** A 73 year old patient presented with left unilateral nasal congestion due to nasal mass. CT scan and tumor biopsy revealed a Krouse T3 inverted papilloma of the left maxillary sinus. A transnasal endoscopic medial maxillectomy type 2b was performed, with total excision of the tumor. 5 months postoperatively, during clinical examination, recurrence of the papilloma was suspected and a second CT scan and biopsy confirmed it. A medial maxillectomy type 4 was performed to optimize drilling of the tumor's attachment point. The patient was discharged 2 days postoperatively with no complications and his follow-up was negative for recurrent disease.

**Conclusion:** The transnasal endoscopic approach seems to be the golden standard in the management of inverted papilloma. Other techniques, like midface degloving, present similar results, however greater postoperative complications and pain.

Key words: Transnasal endoscopic maxillectomy, inverted papilloma

## Inverted Papilloma of the frontal sinus in a 58 year-old patient, treated with Draf 3 operation: a case report

**Panagiotis Pyrgakis**<sup>1</sup>, Drimalas Nikolaos<sup>1</sup>, Konstantinos Chras<sup>1</sup>, Sotirios Botsakis<sup>1</sup>, Christos Georgalas<sup>2</sup>

<sup>1</sup>General Hospital “Evangelismos”, Athens, Greece, <sup>2</sup>Ygeia Hospital, Athens, Greece

Poster Session, 26 Sept – 30 Sept, 2021, All day

**Background:** Inverted papilloma rarely originates from the frontal sinus (1-16%). The surgical management comprises in the complete resection of the tumor and drilling of the underlying and surrounding subperiosteum of the attachment point. The most common surgical approaches used are draf 3 and the classic osteoplastic flap. The optimal approach is chosen according to the tumor's extension, patient comorbidities and surgeon's experience.

**Case report:** A 58 year old female patient presented with headache and nasal congestion. Rhinoscopy showed a tumor in the right middle meatus and its biopsy showed inverted papilloma. The CT scan revealed a bilateral tumor of the frontal sinus, extending into the frontal ethmoidal cells and into the right maxillary sinus. The attachment point was at the anterolateral wall of the right frontal sinus. A Draf 3 procedure was performed with total excision of the tumor. The patient was discharged 2 days postoperatively and her follow-up was negative for recurrent disease.

**Conclusion:** According to literature there is no significant statistical difference between the different techniques, concerning recurrence of disease. However, endoscopic surgery is considered to be the surgeon's first choice due to less complications, shorter hospitalization and better patient quality of life.

Key words: Draf 3, inverted papilloma, frontal sinus, frontal endoscopic sinusostomy



## Cross-cultural adaptation and applicability of Pennsylvania Smell Identification Test for a Greek population

Angelos Saratsiotis<sup>1</sup>, Athanasia Milioni<sup>1</sup>, Maria Andrianaki<sup>1</sup>, Paris Moumoulidis<sup>1</sup>, Jacob Economides<sup>1</sup>, Georgios X Papacharalampous<sup>1</sup>

<sup>1</sup>ENT Department, Elpis General Hospital, Athens, Greece

Poster Session, 26 Sept – 30 Sept, 2021, All day

**Background:** The University of Pennsylvania Smell Identification Test (UPSIT) is a well-developed olfactory test, which has been validated in various population. The aim of this study was the cross-cultural adaptation of the UPSIT (revised) and the evaluation of its applicability in a Greek population.

**Methodology/Principal:** The methodology consisted of 3 stages. In the first stage, two native Greek speakers translated independently the original test. The second stage included field testing with recognition of problematic items and a re-test with a 2-week interval to assess its reliability. In the third stage, volunteers with no subjective smell loss were recruited. Their results were correlated with a corresponding sample of patients from the normative data of the original UPSIT.

**Results:** In total 60 subjectively normosmic subjects were included to the study. Most subjects reported that the UPSIT was easy and interesting. Results in our study population were not significantly different from the findings of the original tool. Differences were found as age progresses, in accordance with previous reports. Overall, the females outperformed the male subjects.

**Conclusions:** The UPSIT (revised) is an adequate test for clinical use to assess olfactory function in a Greek population.

Key words: UPSIT, Olfactory test, Smell, Cultural adaptation

## Management of ICU patients with fever of unknown origin and signs of rhinosinusitis with functional endoscopic sinus surgery. A prospective study

Athanasia Tourgeli<sup>1</sup>, **Panagiotis Pyrgakis<sup>1</sup>**, Chras Konstantinos<sup>1</sup>, Nikolaos Drimalas<sup>1</sup>, Sotirios Botsakis<sup>1</sup>

<sup>1</sup>General Hospital "Evangelismos"

Poster Session, 26 Sept – 30 Sept, 2021, All day

**Background:** Fever is common in the ICU patients and its source can either be infectious or not. The most common sources of fever in ICU patients include ventilator associated pneumonia, intravenous catheter infections and sinusitis. The aim of this study is to evaluate the clinical impact of functional endoscopic sinus surgery in ICU patients with sinusitis.

**Methodology/Principal:** The patients included in this prospective study met the following criteria: prolonged intubation, fever of unknown origin, null other sites of infection, CT scan with signs of opacification of the paranasal sinuses, endoscopical assessment of nose and ostium positive for purulent discharge and poor clinical response to conservative treatment.

**Results:** In the course of 5 years 98 patients in the ICU met the inclusion criteria and underwent functional endoscopic sinus surgery according to CT findings. 92% had opacification of the maxillary sinus, 86% of the ethmoidal cells and 53% of the sphenoidal sinus. 63 patients (64%, n=98) showed improvement of fever and clinical status within 5 postoperative days.

**Conclusions:** Functional endoscopic sinus surgery in ICU patients with fever of unknown origin and signs of rhinosinusitis can be beneficial. However, more prospective control trials are needed, with standardized antibiotic therapy, to get more evidence.

Key words: ICU, functional endoscopic sinus surgery, FESS, fever, rhinosinusitis

### Literature

1. Riga M, Danielidis V, Pneumatikos I. Rhinosinusitis in the intensive care unit patients: a review of the possible underlying mechanisms and proposals for the investigation of their potential role in functional treatment interventions. J Crit Care. 2010 Mar;25(1):171.e9-14.
2. van Zanten AR, Dixon JM, Nipshagen MD, de Bree R, Girbes AR, Polderman KH. Hospital-acquired sinusitis is a common cause of fever of unknown origin in orotracheally intubated critically ill patients. Crit Care. 2005 Oct 5;9(5):R583-90.
3. Pádua FG, Bezerra TF, Voegels RL, Bento RF. The efficacy of functional endoscopic sinus surgery in the evolution of fever of unknown origin in ICU patients. Acta Otolaryngol. 2011 Feb;131(2):166-72.

**Surgical and Cosmetic Outcomes in Paediatric Nasal Dermoids: A case series over 5 years including 15 patients. Outcomes of varying investigations and a multidisciplinary approach.**

Rosie Fenton<sup>1</sup>, Joseph Sinnott<sup>2</sup>, Michael Saunders<sup>2</sup>

<sup>1</sup>University of Bristol Medical School, Bristol, United Kingdom, <sup>2</sup>University Hospital Bristol and Weston, Bristol, United Kingdom

Poster Session, 26 Sept – 30 Sept, 2021, All day

**Background:** Nasal dermoids represent the most common midline nasal lesion in children. They are congenital anomalies derived from ectoderm and mesoderm. They mainly contain a variety of structures. The classical sign is hair emerging from the lesion. Management is surgical excision but there is no gold standard for the technique nor for preoperative investigations. Nasal dermoids can be superficial, extend through the nasal bones or intracranially.

**Methodology/Principal:** Data was collected on nasal dermoids treated at a tertiary UK Paediatric ENT centre over a 5-year period. 15 cases were identified after searching electronic patient and operating theatre records.

**Results:** Six patients were managed by ENT, four by plastics and 5 had a combination of plastics and ENT. Thirteen had a MRI, four a CT and two ultrasounds. There was one recurrence and this required neurosurgical input and management at a second operation. Outcomes from an external approach with vertical incision were extremely good. In cases where there was extension through the nasal bones, ENT were required to perform drilling to allow the tract to be followed (6 patients).

**Conclusions:** All patients should have an MRI preoperatively to identify the small number of cases which extend intracranially. CT may be considered in selected cases such as those where there is evidence of intracranial extension. Ultrasound was not useful. Neurosurgery was rarely required and in this case series, where there was only evidence on MRI of extension towards skull base (not into or through the skull base), having neurosurgery cover available at the time of the operation was adequate. Joint ENT / Paediatric Plastic Surgery operations with vertical incision cases show very good early outcomes.

**Key words:** Dermoid, nasal, plastics, rhinotomy

## Subdural empyema as a complication of frontal sinusitis: a case report

A. Tourgeli<sup>1</sup>, **A Kovacs**<sup>1</sup>, K. Hapsi<sup>1</sup>, N. Drimalas<sup>1</sup>, S. Botsakis<sup>1</sup><sup>1</sup>*Evangelismos Hospital, Athens, Greece*

Poster Session, 26 Sept – 30 Sept, 2021, All day

**Introduction:** Intracranial complications of sinusitis are uncommon but when occur they are life threatening diseases.

**Principal:** We present a case of a 15 years old male with fever, headache, vomiting and progressive loss of consciousness which was perceived late because of the Asperger syndrome (GCS 9/15) The patient was assessed by the physician and neurology team .Blood results showed increased inflammatory markers.(WBC 23980,CRP 18,8)The CT scan showed opacification of the left paranasal sinuses and erosion of the left frontal sinus wall with the suspicion of meningitis. Neurosurgical report was negative for surgical treatment. The patient was admitted and 12 hours later the ENT team was called to assess the case, meanwhile GCS has been deteriorated (6/15) and the patient was intubated. A second CT was performed and showed the known opacification of the paranasal sinuses and subdural enhancement at the left hemisphere with the suspicion of subdural empyema. ENT liaised with neurosurgery and radiology team performed the emergency procedure with left FESS and extended craniotomy due to osteomyelitis. The patient was discharged 2 months later in a good clinical condition.

**Conclusion:** The case showed the rapid progression of subdural empyema which represents a true emergency requiring prompt diagnosis and management.

**Keywords:** frontal sinusitis, asperger syndrome, subdural empyema, FESS, craniotomy

Literature:

1. Osborn MK<sup>1</sup>, Steinberg JP. Subdural empyema and other suppurative complications of paranasal sinusitis. *Lancet Infect Dis.* 2007 Jan;7(1):62-7.
2. Gallagher RM<sup>1</sup>, Gross CW, Phillips CD. Suppurative intracranial complications of sinusitis. *Laryngoscope.* 1998 Nov;108(11 Pt 1):1635-42.
3. Dolan RW<sup>1</sup>, Chowdhury K. Diagnosis and treatment of intracranial complications of paranasal sinus infections. *J Oral Maxillofac Surg.* 1995 Sep;53(9):1080-7.
4. Osborn MK<sup>1</sup>, Steinberg JP. Subdural empyema and other suppurative complications of paranasal sinusitis. *Lancet Infect Dis.* 2007 Jan;7(1):62-7.
5. Giannoni CM<sup>1</sup>, Stewart MG, Alford EL. Intracranial complications of sinusitis. *Laryngoscope.* 1997 Jul;107(7):863-7.

## A prospective study of complications to acute bacterial rhinosinusitis in children - bacterial cultures, virus detection, allergy sensitization and immunoglobulins.

**Sofia Hultman Dennison**<sup>1,2</sup>, Anna Granath<sup>1,2</sup>, Mats Holmström<sup>2</sup>, Pär Stjärne<sup>1,2</sup>, Olof Hertting<sup>3,4</sup>

<sup>1</sup>Department of Otorhinolaryngology, Karolinska University Hospital, Stockholm, Sweden, <sup>2</sup>Department of Clinical Science, Intervention and Technology (CLINTEC), Division of Ear, Nose and Throat Diseases, Karolinska Institutet, Stockholm, Sweden, <sup>3</sup>Pediatric Infectious Diseases, Astrid Lindgren Children's Hospital, Karolinska University Hospital, Stockholm, Sweden, <sup>4</sup>Department of Women's and Children's Health, Karolinska Institutet, Stockholm, Sweden

Poster Session, 26 Sept – 30 Sept, 2021, All day

**Background:** Prospective studies of complications to acute rhinosinusitis in children are lacking; the bacterial aetiology is difficult to establish; viral infection, allergic rhinitis and immunoglobulin deficiency have been implicated in the pathogenesis.

**Methodology:** Prospective cohort study in Sweden of hospitalized children 0-18 years with acute rhinosinusitis, 2017 to 2020. Bacterial cultures from: nasopharynx (NPH); nasal middle meatus (MM); blood; and cultures and broad-range 16S rDNA PCR from surgical cases were obtained.

**Results:** 55 children included (median age 7.6). MM cultures were positive for bacterial growth to a larger extent than NPH cultures, displaying different bacteria in most cases. *S. milleri* dominated in the surgical cultures. 50% of surgical cases had negative nasal cultures. *S. pyogenes* was associated with higher CRP (57.5,  $p=0.007$ ); *H. influenzae* and *S. pneumoniae* with lower CRP (-38.9,  $p=0.028$ ; -45.5,  $p=0.023$ ). Viral nasopharyngeal PCR was positive in 51%, associated with a lower grade of complication (-1.3,  $p=0.028$ ) and CRP (-36.2,  $p=0.05$ ). Influenza A/B was associated with *S. pyogenes* (1.5,  $p=0.040$ ). Allergy sensitization was possibly associated with more days with intravenous antibiotics (1.2,  $p=0.052$ ).

**Conclusions:** We found differences in the patterns of bacterial growth in nasopharyngeal, middle meatus and surgical cultures in children with complications. Certain viruses and sensitization to airborne allergies seem to play a role in complications to ABRS in children.

Key words: acute sinusitis, bacteria, children, complications, allergic rhinitis

## Orbital reconstruction in maxillary sinus fibrous dysplasia

**Patrícia Silva Sousa<sup>1</sup>**, José Alberto Fernandes<sup>1</sup>, Clara Magalhães<sup>1</sup>, António Castanheira<sup>1</sup><sup>1</sup>*Centro Hospitalar de Trás-os-Montes e Alto Douro, Portugal*

Poster Session, 26 Sept – 30 Sept, 2021, All day

**Background:** Fibrous dysplasia (FD) is a rare hamartomatous bone disorder in which normal bone is replaced by fibrous-osseous connective tissue. FD can affect one or multiple bones assuming the monostotic or polyostotic form, respectively. Monostotic form is more frequent and malignant degeneration is rare.

**Methodology:** A 45-year-old woman presented with a 5-month history of right cheek and medial canthus swelling. A hard painless right suborbital mass was evidenced as well as mild proptosis. The CT scan showed a well-delimited, heterogeneous ground-glass appearance mass in the right maxillary sinus, anterior and medial walls. Orbital floor was also compromised. A biopsy was performed and pointed to FD.

**Results:** The patient underwent external approach for a radical mass excision preserving infraorbital nerve and lacrimal system. Orbit was reconstructed with autologous calvary bone fixed with titanium plates and screws. An outstanding functional and aesthetic outcome was achieved otherwise minor and transitory hyposthesia. Preoperative epiphora was solved in a 2-year follow-up after a dacryocystorhinostomy.

**Conclusions:** Although benign and a slow growing disorder, FD can disrupt craniofacial aesthetics and function and surgery continues to be the mainstay treatment. ENT surgeons must have appropriate knowledge once better outcomes for FD management are achieved at early stages.

Key words: Fibrous dysplasia; Maxillary sinus; Orbital reconstruction.

## Literature

Couturier A, Aumaître O, Gilain L, Jean B, Mom T, André M. Craniofacial fibrous dysplasia: A 10-case series. *Eur Ann Otorhinolaryngol Head Neck Dis.* 2017;134(4):229-235. doi:10.1016/j.anorl.2017.02.004

Ricalde P, Magliocca KR, Lee JS. Craniofacial fibrous dysplasia. *Oral Maxillofac Surg Clin North Am.* 2012;24(3):427-441. doi:10.1016/j.coms.2012.05.004

Eachempati P, Aggarwal H, Shenoy V, Baliga M. Multidisciplinary approach for management of a patient with fibrous dysplasia of maxilla. *BMJ Case Rep.* 2015;2015:bcr2015210330. Published 2015 Aug 5. doi:10.1136/bcr-2015-210330

**R. Sekine<sup>1</sup>**, E. Mori, Y. Tsurumoto<sup>1</sup>, R. Sakurai, M. Tei<sup>1</sup>, H. Kojima, N. Otori<sup>1</sup>

<sup>1</sup>The Jikei University School of Medicine, Department of Otorhinolaryngology, Minato-ku, Tokyo, Japan

Poster Session, 26 Sept – 30 Sept, 2021, All day

**Background:** Olfaction plays an important role in our daily and social lives for both adults and children. We conducted a survey to assess whether the ability to identify odours increases with age as well as ability in various age groups and the factors involved.

**Methodology/Principal:** The survey was performed 2017 on 697 Japanese children (366 girls, 311 boys) aged 6 to 18 years living in Tsunan, Nigata, Japan. The 'Open Essence', a card-type odour identification test and a questionnaire of six factors, was used. The 10<sup>th</sup> percentile score according to age was analyzed, and the six different factors were assessed to determine whether they were correlated.

**Results:** The result shows that the odour identification abilities of children increase with age, and children who have daily conversations about odours at home have better odour identification abilities.

**Conclusions:** Odour identification ability increases with age. In addition, we detected that conversation may possibly affect odour identification. Hence, it is important for children to be exposed to an environment where they develop an interest in smells for better growth of their odour identification ability.

Key words: conversation, identification, odorant, olfaction

#### Literature:

1. Doty RL, Shaman P, Applebaum SL, Giberson R, Siksorski L, Rosenberg L. Smell identification ability: changes with age. *Science*, 1984; 226(4681):1441-1443.
2. Doty RL, Cameron EL. Sex differences and reproductive hormone influences on human odor perception. *Physiology & Behavior*, 2009; 97:213-228.
3. Novakova LM, Fialova J, Havlic J. Effects of diversity in olfactory environment on children's sense of smell. *Scientific Reports*, 2018; 8:2937. <https://doi.org/10.1038/s41598-018-20236-0>
4. Van, Spronsen E, Ebbens FA, Fokkens WJ. Olfactory function in healthy children: Normative data for odor identification. *American Journal of Rhinology & Allergy*. 2013; 17:197-201.
5. Sorokowska A, Schriever VA, Gudziol V, et al. Changes of olfactory abilities in relation to age: odor identification in more than 1400 people aged 4 to 80 years. *European Archives of Oto-Rhino-Laryngology*, 2015; 272:1937-1944.
6. Obrebowski A, Obrebowska-Karsznia Z, Gawlinski M. Smell and taste in children with simple obesity. *International Journal of Pediatric Otorhinolaryngology*, 2000; 55:191-196.
7. Schriever VA, Agosin E, Altundag A, et al. Development of an international odor identification test for children – the “U-Sniff” test. *Journal of Pediatrics*, 2018; Jul;198:265-272.E3
8. Laing DG, Segovia C, Fark T, et al. Tests for screening olfactory and gustatory function in school-age children. *Otolaryngology-Head and Neck Surgery*, 2008; 139:74-82.
9. Frye RE, Schwartz BS, Doty RL. Dose-Related Effects of Cigarette Smoking on Olfactory Function. *JAMA*. 1990; 263(9):1233-1236.
10. Katotomichelakis M, Balatsouras D, Tripsianis G, et al. The effect of smoking on the olfactory function. *Rhinology*, 2007; 45: 273-280.
11. Mori E, Petters W, Schriever VA, Valder C, Hummel T. Exposure to odors improves olfactory function in healthy children. *Rhinology*, 2015; 53:221-22

## Posttraumatic septorhinoplasty for teen athletes

Grachev N.S.<sup>1</sup>, Zyabkin I.V.<sup>2</sup>, Frolov S.V.<sup>2</sup>, Magomedova A. M.<sup>2</sup>, Ataeva D.M.<sup>2</sup>, Polev G.A.<sup>1</sup>

<sup>1</sup>Dmitry Rogachev National Medical Research Center of Pediatric Hematology, Oncology and Immunology of the Ministry of Health of Russia, Moscow, Russia, <sup>2</sup>Federal State Budgetary Unit Federal Scientific and Clinical Center of kids and adolescents of the Federal Medical Biological Agency, Moscow, Russia

Poster Session, 26 Sept – 30 Sept, 2021, All day

**Background:** Injuries of nasal structures are common for athletes who engaged close-contact sports. Such deformities like crooked nose and caudal septum deviation are typical for this type of patients and can cause different abnormalities of facial, especially nasal growth and mouth-breathing pattern. Because adequate nasal breathing and facial esthetics is essential for athletes, importance of surgical treatment is high, in addition to problems caused by chronic severe nasal obstruction and social adaptation is incredibly important for kids and adolescents.

**Methodology/Principal:** We include 15 athletes with posttraumatic nasal deformities from age 14 before 18. 11 of them undergoing open structural septorhinoplasty, 4 of them - only septoplasty. Turbinate surgery performed for all the patients. Efficiency of nasal symptoms after surgery rated by the Nasal Obstruction Symptom Evaluation (NOSE) questionnaire.

**Results:** All the patients underwent surgery successfully. There were only 2 cases of surgical complications (13,3%) – case of septal hematoma in early postoperative period and case of slight middle vault deviation after two months of surgery.

**Conclusions:** Open structural rhinoseptoplasty is preferred mode of treatment for adolescents, especially for athletes with posttraumatic nasal deformities, cause it provides clearly nasal breathing. Positive impact of surgical treatment prevails over potential risks.

Key words: Nasal surgery; Pediatric rhinoplasty; Pediatric septoplasty; Nose Deformities,

## Literature

1. Johnson, M. D. (2017). Management of Pediatric Nasal Surgery (Rhinoplasty). Facial Plastic Surgery Clinics of North America, 25(2), 211–221.
2. Tasca I, Compadretti GC. Nasal growth after pediatric septoplasty at long-term follow-up. Am J Rhinol Allergy 2011;25(1):e7–12.
3. Principato JJ. Upper airway obstruction and craniofacial morphology. Otolaryngol Head Neck Surg 1991;104(6):881–90.



A rare cause of nasal obstruction in the elderly: respiratory epithelial adenomatoid hamartoma

Haseem Raja<sup>1</sup>, **Rishi Talwar**<sup>1</sup>

<sup>1</sup>ENT Department, Luton and Dunstable University Hospital, Luton, England.

Poster Session, 26 Sept – 30 Sept, 2021, All day

**Background:** Respiratory epithelial adenomatoid hamartomas (REAHs) are rare tumours that are typically found in the nasal cavity of middle-aged men. These benign lesions can often be difficult to distinguish, both grossly and microscopically, from aggressive tumours such as inverted papilloma and sinonasal carcinoma.

**Methodology/Principal:** We report a case of a 78-year-old Caucasian female who presented with significant nasal obstruction, congestion, and rhinorrhea of 5 months duration.

**Results:** Flexible nasendoscopy revealed a large mass medial to the right middle turbinate. Head and neck examination findings were otherwise unremarkable. CT of the sinuses demonstrated a solitary right nasal mass of 20 x 10mm that was closely related to the anterior skull base. Subsequent MRI showed the lesion arising at the level of the crista galli and anterior to it with no involvement of the cribriform plate. Sub-total excision biopsy findings revealed a REAH with no evidence of dysplasia or malignancy. This treatment provided significant improvement in her nasal symptoms and quality of life.

**Conclusions:** REAHs are benign pathological entities that should be included in the differential diagnosis for unilateral sinonasal masses, even in the elderly female population. Awareness of REAHs and correct diagnosis is important to reduce the risk of aggressive surgical management that is inappropriate.

Key words: REAH, benign, tumour

**Konstantinos Chantzis**<sup>1</sup>, Stavros Ioakeimidis<sup>1</sup><sup>1</sup>*Otorhinolaryngology Department, General Hospital of Nikaia Agios Panteleimon, Athens, Greece.*

Poster Session, 26 Sept – 30 Sept, 2021, All day

**Background:** Fibroepithelial polyp is a benign tumour originating from the mesodermal tissue presented mostly of the times in the skin. The respiratory system, especially the nasal passage, are extremely rare locations of fibroepithelial polyps.

**Principal:** We present a case in which, a 20-year-old male patient visited our department complaining about nasal obstruction of the right nostril since 2 years. An anterior rhinoscopy of the right side revealed a pink polypoid soft tissue tumour adhering to the septal cartilage at the level of the interior nasal valve. We performed a procedure using local anesthesia, during which, a right mucoperichondrial flap of the quadrangular cartilage was created and resected including the whole polypoid lesion.

**Results:** The immunohistochemical examination of the sample resulted in a presence of a fibroepithelial polyp in the nasal cavity. During the 2 years follow up of the patient after the excision, no recurrence or septal deformity has been observed.

**Conclusions:** In literature there are cases of malignant fibroepithelial polyp transformations, making the resection and the careful histopathologic examination of the polyps necessary for the patient's safety.

**Key words:** fibroepithelial polyp, nasal polyp, nasal septum, mesoderm

#### Literature

- 1.Peric A, Matkovic-Jozin S, Vukomanovic-Durdevic B. Fibroepithelial polyp arising from the inferior nasal turbinate. J Postgrad Med. 2009;55(4):288-289.
- 2.Nishijima H, Yagi M. Multiple fibroepithelial polyps arising from the inferior turbinate. Otolaryngol Head Neck Surg. 2012;146(6): 1031-1032.
- 3.Agir H, Sen C, Cek D. Squamous cell carcinoma arising from a fibroepithelial polyp. Ann Plast Surg. 2005;55(6):687-688.
- 4.Stoiljkov M, Perić A. Fibroepithelial Polyp Originating from the Nasal Septum. Turk Arch Otorhinolaryngol 2019; 57(4): 206-8.
5. Jae-Hoon Lee. Fibroepithelial Polyp Arising From the Nasal Vestibule. Ear, Nose & Throat J 2019 Dec 23. doi:10.1177/0145561319892456.

Peric A, Matkovic-Jozin S, Vukomanovic-Durdevic B. Fibroepithelial polyp arising from the inferior nasal turbinate. J Postgrad Med. 2009;55(4):288-289.

## Long term olfactory and taste disorders in post-COVID syndrome. Olfactory treatment and subjective evaluation.

**Blanca Mateos Serrano<sup>1</sup>**, Carmen Alegre Segura<sup>2</sup>, Alejandra Martínez Gómez<sup>2</sup>, Andrea Sanz Jiménez<sup>2</sup>, Cristina Rey Iborra<sup>2</sup>, Tania Cuesta Luzzy<sup>2</sup>

<sup>1</sup>Otolaryngology Department. La Paz University Hospital. Madrid. Spain. , <sup>2</sup>Post-COVID Nursing Department. Carlos III Hospital / La Paz University Hospital. Madrid. Spain.

Poster Session, 26 Sept – 30 Sept, 2021, All day

Olfactory and taste disorders are high prevalent symptoms in post-COVID patients. On the other hand, olfactory training has been a helpful tool in post-viral anosmia.

A longitudinal prospective study was performed with 69 patients. Smell and taste alterations were recorded and subjective questionnaires were fulfilled by the patients at the time of the first visit and three months after. Patients fulfilled Questionnaire of Olfactory Disorders–Negative Statements (QOD-NS), four specific questions for qualitative disorders and several visual analogue scales (VAS).

The most prevalent alterations were parosmia, phantosmia and dysgeusia. Forty-six patients performed olfactory training satisfactorily meanwhile 23 did not.

Even all disorders improved over time, there were no statistical differences between patients who completed therapy and patients who did not in the QOD-NS and in the specific questions for qualitative disorders, nor in the VAS for olfactory lost and for taste lost. However, we found statistical differences in VAS scales “How annoying the difficulties with smelling/tasting are to you” and “How much it affects your enjoyment of food”.

Only a slightly benefit of olfactory training was determined in this study. Nevertheless, objective evaluation would be necessary to determine more accurately the evolution of these disorders in post-COVID patients.

**Key words:** Anosmia, Olfactory training, Post-COVID anosmia, Subjective evaluation

### Literature

- Denis F, Septans AL, Periers L, Maillard JM, Legoff F, Gurden H, Moriniere S. Olfactory Training and Visual Stimulation Assisted by a Web Application for Patients with Persistent Olfactory Dysfunction After SARS-CoV-2 Infection: Observational Study. *J Med Internet Res*. 2021 May 27;23(5): e29583
- Jafari A, Lehmann AE, Metson R. Is Olfactory Training Effective Treatment for Postinfectious Smell Loss? *Laryngoscope*. 2021;131(6):1198-1199
- Langstaff L, Pradhan N, Clark A, Boak D, Salam M, Hummel T, Philpott CM. Validation of the olfactory disorders questionnaire for English-speaking patients with olfactory disorders. *Clin Otolaryngol*. 2019 Sep;44(5):715-728. doi: 10.1111/coa.13351. Epub 2019 Jun 17. PMID: 31038840.
- Chiesa-Estomba CM, Lechien JR, Calvo-Henríquez C, Mayo M, Maldonado B, Maza J, Tucciarone M, Villareal I, Vaira LA, Izquierdo-Dominguez A, Alobid I. Translation and validation of the short version of the Questionnaire of Olfactory Disorders–Negative Statements to Spanish. *Am J Otolaryngol*. 2021 Jan-Feb;42(1):102775. doi: 10.1016/j.amjoto.2020.102775. Epub 2020 Oct 23. PMID: 33125905.

## Proboscis lateralis: A case report with literature review

Asiya K Zaidi<sup>1-2</sup>, Ishita Ray<sup>2</sup>, Sunny Dawoodi<sup>3</sup>, Puya Dehgani-Mobaraki<sup>1</sup>,

<sup>1</sup>Association "Naso Sano", Umbria Regional Registry of Volunteer Activities, Corciano, Italy, <sup>2</sup>MGM Medical College Indore (MP), India, <sup>3</sup>RIPAS Hospital, Bandar Seri Begawan, Brunei

Poster Session, 26 Sept – 30 Sept, 2021, All day

**Background:** Proboscis Lateralis is an extremely rare congenital anomaly of the nose. It is caused by incomplete nasal development in utero. There are only limited articles available on PL, making it a highly underrepresented topic in otorhinolaryngology.

**Methods:** This study describes a five-day-old baby born with PL in a tertiary level hospital in India. We also provide a literature review of fifty-six case reports on PL published between 1958 and 2021. We have also outlined the significant study findings from each case report.

**Results:** Our patient was delivered by cesarean section and diagnosed at birth with PL. Many severe congenital heart defects were additionally present, including one ventricular septal defect and two atrial septal defects. Colpocephaly and minor facial bone defects were also noted. The patient's family chose to defer treatment until the child grows older. Hence, we tried to explore the challenges faced in starting early management for PL in developing countries. Our literature review revealed that there still exists no defined treatment protocol for PL and management varies from case to case.

**Conclusions:** Proboscis Lateralis being a structural abnormality of the face, involves significant stigma among patients. A large proportion of patients diagnosed with PL report psychological trauma due to the same. A multidisciplinary approach is required that involves pediatric, otorhinolaryngology, plastic surgery, anesthesiology, ophthalmology, radiology, and psychiatry departments to manage PL successfully. There is a pressing need to spread awareness about treatment options for PL especially in developing countries.

### Key words

Proboscis Lateralis, Congenital facial anomalies, Frontonasal reconstruction, medial canthus, Lateral nasal proboscis, Heminasal proboscis

## Management of tension pneumo-orbit secondary to medial orbital wall fracture.

**Konstantinos Chaidas<sup>1</sup>**, Jonathan H. Norris<sup>2</sup>, Alexander Ashman<sup>1</sup>.

<sup>1</sup>ENT Department, John Radcliffe Hospital, Oxford University Hospitals NHS Foundation Trust, Oxford, UK.,

<sup>2</sup>Oxford Eye Hospital, John Radcliffe Hospital, Oxford University Hospitals NHS Foundation Trust, Oxford, UK.

Poster Session, 26 Sept – 30 Sept, 2021, All day

**Background:** Tension pneumo-orbit is a rare, but eye-threatening sequelae of orbital trauma. Minimal trauma to the lamina papyracea can result in a valve effect leading to rapid onset proptosis and optic nerve compression in the absence of a haematoma.

**Results/Case report:** We describe a case of medial orbital wall fracture in a 35-year-old lady following a minor fall at home. She presented with severe proptosis of the left eye. Imaging showed marked pneumo-orbit, which was managed definitively by endoscopic orbital decompression.

**Conclusions:** Tension pneumo-orbit requires prompt recognition and surgical decompression. An endonasal approach may be used to decompress the orbit via the medial wall.

**Key words:** Ophthalmology, Orbital Fractures, Exophthalmos

### Literature:

1. Al-Shammari L, Majithia A, Adams A, Chatrath P. Tension pneumo-orbit treated by endoscopic, endonasal decompression: case report and literature review. *J Laryngol Otol.* 2008;E8.
2. Key SJ, Ryba F, Holmes S, Manisali M. Orbital emphysema - the need for surgical intervention. *J Craniomaxillofac Surg.* 2008 Dec;36(8):473-6.
3. Burt B, Jamieson M, Sloan B. Medial wall fracture- induced pneumo-orbita mimicking inferior rectus entrapment. *Am J Emerg Med.* 2010 Jan;28(1):119.e1-3.
4. Tomasetti P, Jacobsen C, Gander T, Zemmann W. Emergency decompression of tension retrobulbar emphysema secondary to orbital floor fracture. *J Surg Case Rep.* 2013 Mar 21;2013(3).
5. O'Brien BJ, Rosenfeld JV, Elder JE. Tension pneumo-orbitus and pneumocephalus induced by a nasal oxygen cannula: report on two paediatric cases. *J Paediatr Child Health.* 2000 Oct;36(5):511-4.
6. García-Medina JJ, García-Medina M, Pinazo-Durán MD. Severe orbitopalpebral emphysema after nose blowing requiring emergency decompression. *Eur J Ophthalmol.* 2006 Mar-Apr;16(2):339-42.

## Association between nasal function and continuous positive airway pressure use in patients with obstructive sleep apnoea: a systematic review.

**Konstantinos Chaidas**<sup>1</sup>, Marina Brimioulle<sup>1</sup>

<sup>1</sup>*Ear, Nose, and Throat (ENT) Department; John Radcliffe Hospital, Oxford University Hospitals NHS Foundation Trust; Oxford; United Kingdom.*

Poster Session, 26 Sept – 30 Sept, 2021, All day

**Background:** This review aims to answer the following questions: “Does nasal pathology affect CPAP use?”, “What is the effect of CPAP on the nose?”, “Does treatment of nasal pathology affect CPAP use?”.

**Methodology:** Pubmed and Scopus databases were searched up to October 2020.

**Results:** Sixty-three articles were selected. Most studies identified a correlation between larger nasal cross-sectional area or lower nasal resistance and higher CPAP compliance or lower CPAP pressures; however, baseline nasal symptoms did not appear to affect CPAP use. The effect of CPAP on the nose remains uncertain: while most studies suggested increased mucosal inflammation with CPAP, those investigating symptoms presented contradictory results. Nasal surgery leads to improved CPAP compliance and decreased CPAP pressures, whereas there is little evidence available for the use of topical nasal steroids.

**Conclusions:** There appears to be a link between smaller nasal volumes or higher nasal resistance and lower CPAP compliance, an increase in nasal inflammation caused by CPAP, and a beneficial effect of nasal surgery on CPAP usage, but no significant effect of CPAP on nasal patency or effect of topical steroids on CPAP compliance. Results are more mitigated with regards to the effect of nasal symptoms on CPAP use and vice-versa.

**Key words:** Obstructive sleep apnoea; continuous positive airway pressure; nasal pathology; nasal symptoms; compliance

## Endoscopic Posterior Nasal Neurectomy for Intractable Rhinitis: a Systematic Review of the Literature

**Patrick Daragh Chakravarty**<sup>1</sup>, Crystal Lee Mun Leng<sup>1</sup>, David Ellul.<sup>1</sup>

<sup>1</sup>*Department of Otolaryngology, Queen Elizabeth University Hospital, Glasgow, Scotland*

Poster Session, 26 Sept – 30 Sept, 2021, All day

**Introduction:** Rhinitis affects up to 40% of the population worldwide and can significantly reduce quality of life. Some patients remain symptomatic despite maximal medical therapy, septal and turbinate surgery. In refractory cases posterior nasal neurectomy (PNN); the selective resection of branches of the sphenopalatine ganglion at the sphenopalatine foramen has been postulated to reduce symptom burden.

**Methodology:** A systematic review of Pubmed, EMBASE and MEDLINE was undertaken. Studies were excluded if not available in English or undertaken in non-human subjects.

**Results:** 17 articles were included studying in total 1818 patients who underwent PNN. Sample size ranged from 8-1056. There were two randomised controlled trials, two case control studies and the remaining thirteen were case series. A mixture of objective and subjective outcomes were used. All but one study found improved patient reported outcomes. Complications were reported in 15 studies- overall complication rate was 3%. The most common complication was haemorrhage in 30 patients (1.3% of subjects).

**Conclusions:** Endoscopic posterior neurectomy appears to be safe and efficacious in the treatment of intractable rhinitis as an alternative to vidian neurectomy. The quality of literature studied was generally poor however. Larger studies are needed to fully elucidate its role in the management of hard to treat rhinitis.

MeSH: rhinitis, allergic, nerve

## Congenital Nasal Pyriform Aperture Stenosis; Our Experience of 34 cases

**Patrick Daragh Chakravarty**<sup>1</sup>, Fiona Sim<sup>1</sup>, Mohd Afiq Mohd Slim<sup>1</sup>, Neil Patel<sup>2</sup>, Andrew Clement<sup>1</sup>.

<sup>1</sup>Department of Otolaryngology, Royal Hospital for Children, Glasgow, Scotland, <sup>2</sup>Department of Neonatology, Intensive Care, Royal Hospital for Children, Glasgow, Scotland

Poster Session, 26 Sept – 30 Sept, 2021, All day

**Background:** Congenital nasal pyriform aperture stenosis (CNPAS) is a rare cause of neonatal upper airway obstruction. CNPAS is estimated to occur in 1 in 25,000 live births; associated birth anomalies are common. Neonates with severe airway obstruction or feeding difficulties require surgical intervention however it remains a challenge to predict this.

**Methodology:** Retrospective case note review of all patients treated for CNPAS at a single tertiary paediatric referral site was undertaken. Diagnosis was made on the basis of a pyriform aperture of <11mm on CT scanning.

**Results:** 34 patients were included in the series, 28 (84%) of whom required surgery. 53% of subjects had associated mega central incisor. All infants with a pyriform aperture of under 6mm required surgery. There was no association with being preterm or having a low birth weight and requiring surgery. One third of patients with the condition arose from the most deprived quintile of the Scottish population.

**Conclusion:** These results support the literature that a pyriform aperture of less than 6mm will require surgery. Associated birth anomalies confound matters but in this cohort that was not associated with an increased likelihood of surgery. An association between CNPAS and deprivation is a novel finding and is hard to explain.

MeSH: Congenital, Nasal, Stenosis, Neonate



## COVID-19 Anosmia: a prospective observational study on the impact of anosmia on patient's quality of life

**Y. Devabalan<sup>1</sup>**, N. Quah Qin Xian<sup>1</sup>, E. Bullock<sup>1</sup>, E. Irune<sup>2</sup>, C. Rennie<sup>1</sup>

<sup>1</sup>Department of Otolaryngology, Charing Cross Hospital, Imperial College Healthcare NHS Trust, London, UK.,

<sup>2</sup>Department of Otolaryngology, Addenbrooke's Hospital, Cambridge.

Poster Session, 26 Sept – 30 Sept, 2021, All day

**Background:** Anosmia was one of the most common documented symptoms of COVID-19 infection. However, the long-term impact on patient's quality of life both subjectively and objectively have yet to be explored. A single-centre prospective observational study was established to investigate both objective and subjective measures of anosmia on patients' quality of life.

**Methodology/Principal:** Our cohort of post-COVID-19 anosmia patients were identified during outpatient rhinology clinics and selected to enrol in this study. Each patient was given an objective University of Pennsylvania Smell Inventory Test (UPSIT), and subjective eQOD (olfactory disorders questionnaire) and SNOT-22 (Sino-Nasal Outcome Test) questionnaires. These 3 assessments were given at participation and then repeated at regular intervals of 1, 3, 6, 9 and 12 months after.

Clinicodemographical factors and factors related to severity of COVID-19 for this cohort were collected.

**Results:** 30 patients were enrolled onto the study. No patients in the study had a hospital or ITU admission related to COVID-19, or any long-term related complications for which they are currently under investigation. Currently 7 patients have completed up to 3 months follow-up, 3 patients up to 6 months follow-up, and 1 patient up to 12 months follow-up.

Of the 7 patients to have completed up to 3 months of follow-up, all were female with a mean age of 43. Interestingly, UPSIT scores for the cohort decreased over the study period, but this was not statistically significant with such low numbers. Subjectively, their SNOT22 and eQOD scores revealed an improvement in quality of life.

**Conclusions:** COVID-19 related anosmia can be functionally debilitating for patients, and further research is needed to establish the impact it can have on patients and their quality of life.

Key words:

COVID-19; Anosmia; Sino-Nasal Outcome Test-22; Smell; observational study

**Alicia Maria. Perez Orribo**<sup>1</sup>, Silvia. Martin Martin<sup>1</sup>, Rida M. Nahli<sup>1</sup>, Alba. Aparicio-Parrado<sup>1</sup>, Gabriela. Muñoz Cordero<sup>1</sup>, Mario. De Bonis Redondo<sup>1</sup>.

<sup>1</sup>ENT Department of University hospital of the Canary Islands, La Laguna, Tenerife Canary Islands, Spain.

Poster Session, 26 Sept – 30 Sept, 2021, All day

**Background:** Definition: Absence of permeability of the posterior portion of the nostrils.

Incidence: 1/5,000 to 1/8,000 births and affects with higher prevalence in girls 2:1.

Experience. 3 interventions of patients aged between 5-8 years with a diagnosis of unilateral choana atresia (2 left cases, 1 right case) of mixed structure (fibrous and bone).

**Methodology/Principal:** The OBJECTIVE of this work is to show the surgical technique performed in the University Hospital of the Canary Islands (HUC) endoscopically, general anesthesia and with a 0° lens: Posterior septectomy with pit flour milling with choana opening.

**Results:** No intraoperative or post-operative complications were recorded within five, four and one year of follow-up in each case. No nasal tamponade or silicone tube was placed in any case.

**Conclusions:** Performing the posterior septectomy and opening of choana by endoscopic milling is a safe, effective and reproducible technique that allows the unification of the choana through permeabilization by atresia nostril. Currently there are multiple variants in the technique that make it difficult to single coding.

Key words: Choanal atresia, Rhinology, nasal surgery.

Literature

201052

## Dealing with middle turbinate, one of big dilemmas in FESS

Khaled Mohamed bofares, professor of otorhinolaryngology

Omar Almoukhtar University, Elbyda, Libya

Poster Session, 26 Sept – 30 Sept, 2021, All day

FESS is considered as one important surgical procedures in rhinology, which performed on basis of the preservation of the rhino-sinus function. However, the middle turbinates have a very significant role in the maintenance of this function. Thus, the preservation of middle turbinates should be one of major aims of FESS.

In accordance, as another major aim of FESS is providing a sufficient drainage, ventilation, and accessibility of different paranasal sinuses groups. However, this aim cannot be achieved completely unless the most of lower part of ipsilateral middle turbinate is resected. In contrary, this will oppose the cornerstone of FESS aim that is the preservation of paranasal sinus function. Therefore, this issue creates a big dilemma for most of surgeons.

As a clinical trial to clarify this dilemma, this study was conducted to evaluate the pathological effect of the resection of middle turbinate on outcomes of FESS, and confirm whether there is any significant difference if this turbinate is preserved regarding the effect on post FESS rhino-sinus function.

**Key words:** Middle turbinate interference, middle turbinate surgery dilemma, middle turbinate resection, middle turbinate preservation.

## Fibrous Dysplasia of the right maxilla on a pediatric patient: A rare case

Patrick John I. Batol<sup>1</sup>, M.D., Alexander Edward S. Dy, M.D.<sup>1</sup>

<sup>1</sup>*Jose R. Reyes Memorial Medical Center, Sta Cruz Manila, Philippines*

Poster Session, 26 Sept – 30 Sept, 2021, All day

**Background:** •To present a case of an 8-year-old female who had a fibrous dysplasia of the maxillary area, right

**Methodology/Principal:** Case Report

**Conclusions:** In summary, this paper describes a rare case of polyostotic fibrous dysplasia on a pediatric patient. She presented with right maxillary bulge, proptosis of the right eye, and nasal mass and deviation of the septum to the left. Nasal endoscopy with punch biopsy was done, revealing fibrous dysplasia.

Key words: Craniofacial Fibrous Dysplasia; Fibrous dysplasia, monostotic; maxilla; ethmoid; sphenoid

Literature

## Patient, payer and physician preferences for treatment of nasal polyposis: A multi-country qualitative interview study

Petter Olsson,<sup>1</sup> Harneet Kaur,<sup>2</sup> Briana Ndife,<sup>3</sup> Eric Peress,<sup>4</sup> Sabina Heinz,<sup>5</sup> Joern Kleebach,<sup>6</sup> Claire Hutin Mierzwinski<sup>4</sup>

<sup>1</sup>Novartis Sverige AB, Kista Sweden; <sup>2</sup>Novartis Healthcare Private Limited, Hyderabad, India; <sup>3</sup>Novartis Pharmaceuticals Corp, East Hanover, NJ, USA; <sup>4</sup>Novartis Pharma AG, Basel, Switzerland; <sup>5</sup>Ipsos GmbH, Munich, Germany, Ipsos Healthcare, S.A., Basel, Switzerland

Poster Session, 26 Sept – 30 Sept, 2021, All day

**Background:** Understanding the perspective of the patient, payer and physician regarding treatments available for chronic rhinosinusitis with nasal polyps (CRSwNP) is important as evidence regarding the most effective treatment strategy is limited.

**Methods:** 60-minute in-depth telephone interviews were conducted with patients (n=30), Ear, nose and throat (ENTs) physicians (n=30) and payers (n=16) in United States, Canada and Germany to explore relative importance of treatment safety, efficacy and mode of administration (subcutaneous syringe vs. surgery) in CRSwNP.

**Results:** Overall, patients prefer a treatment that can improve quality of life (QoL) as they feel congested, hard to breathe, poor sense of smell/taste, impact on sleep quality leading to daytime fatigue, and distressed by recurrence of polyps; while oral administration would be preferable, subcutaneous injection would be considered acceptable to most patients (83%); ENTs prefer a treatment that achieve patient satisfaction by improving their QoL through complete removal of polyps with no recurrence; Payers consider clinical and economic domains as more important than humanistic domains when deciding on a new treatment.

**Conclusions:** ENTs are facing limited solutions to achieve patient satisfaction through surgical removal of polyps with no recurrence. Subcutaneous injection would be considered acceptable to most patients.

**Keywords:** chronic rhinosinusitis with nasal polyps, patient preference, physician preference, payer preference, surgery vs. syringe

## **Authors List**

**A**

A. Bouladaki . . . . .	202459, 202458	Alterio Daniela . . . . .	203777-258
Aanæs Kasper. . . . .	202276, 202277	Altman K.W. . . . .	203650-138
Aarstad Hans Jørgen . . . . .	202850	Altuna-Mariezcurrena Xabier. . . . .	203202
Abbas Syed Akbar . . . . .	203521-36, 203522-37	Alvarado Raquel. . . . .	203757-238, 203759-241
Abbasi M. . . . .	203842-320	Alves Sílvia Fidalgo. . . . .	203221, 203856-333
Abdu Semah. . . . .	202393	Alyousuf Awatif . . . . .	202468
Abergerl Avraham . . . . .	203015	Amarante José . . . . .	203674-162
Abhinav Kumar. . . . .	203547-61	Amin Nikhil . . . . .	202279, 203682-167, 203681-166
Abičić Ivan. . . . .	203260, 203513-20	Amina Saaid . . . . .	203631-119, 203632-120
Acke Frederic . . . . .	201474	Amiti Nimrod . . . . .	202541
Adónis Cristina . . . . .	201499	Amjadimanesh H.. . . . .	203842-320
Aga Alfred. . . . .	202727	Amos Itai . . . . .	201040, 201860
Agarwal M. . . . .	202123	Ana Isabel Santos. . . . .	203856-333
Agius AM. . . . .	203804-288	Anastasiadou Sofia . . . . .	201367
Agosti E. . . . .	201794	Anda Stefan . . . . .	203191
Ahmed Shahzada . . . . .	203386, 203436, 203481, 203519-34, 203520-35, 203521-36, 203522-37, 203539-53, 203540-54, 203541-55, 203542-56, 203575-93	Anders Broström . . . . .	201107
Ahmed Sk . . . . .	203619-107	Andersen JH . . . . .	201103
Akdis Cezmi A. . . . .	201563	Andorfer Kornelia E.C. . . . .	203513-9, 201161
Alagianni Aggeliki. . . . .	203729-213	Andre M. . . . .	203124
Alanin Mikkel . . . . .	201560, 202273, 202276	Andrea Sanz Jimenez. . . . .	203855-332
Alawami Zainab . . . . .	201004	Andrews Peter J. . . . .	201155
Albati Fatma . . . . .	201004	Andrianaki Maria . . . . .	203807-286
Albers Frank C. . . . .	202687	Anestakis D. . . . .	203417, 203793-273
Albu Silviu . . . . .	203575-89	Anesteva R. . . . .	203513-17
Alejandra Martinez Gomez . . . . .	203855-332	Angely Christelle . . . . .	202881, 202358
Aleksić Alexandra. . . . .	201913	Anghel I. . . . .	203430
Alessandro Nonis. . . . .	201322, 201323	Ansuetz Lukas. . . . .	202060, 202427
Alessandro Vinciguerra MD . . . . .	201322, 201323	Anterriotis Dimitrios . . . . .	203220
Alex C Tham . . . . .	202594	Antonio Giordano Resti MD. . . . .	201322, 201323
Alexander Lydia . . . . .	203513-11	Antonio Marcelo . . . . .	202136
Alexandros Poutoglidis . . . . .	202982, 203675-161	Antunes J. . . . .	201499
Alexandru G. Enea . . . . .	203709-194, 203721-206, 203719-204	Antunes Luís. . . . .	203221, 203856-333
Alfonso C. . . . .	201892, 201893	Aparicio-Parrado Alba. . . . .	203880-357
Alghmadi Faris . . . . .	203859-338	Apšeniece K. . . . .	203630 – 118
Alharbi Ahmed . . . . .	203330	Aragon Davi Casale . . . . .	202323
Aliuş Ruxandra Oana . . . . .	203826-309	Arantes do Amaral Maria Stella . . . . .	202322
Allan Max . . . . .	203713-198	Araújo Bernardo Carvalho . . . . .	202110
Almeida e Sousa Cecília . . . . .	201105, 203674-162, 203374	Argsus Amr . . . . .	203859-338
Almoukhtar Omar . . . . .	201052	Ariadna Valldeperes Vilanova . . . . .	202690
Alobid Isam. . . . .	203228	ARJOCA Elena. . . . .	202126, 202376, 202485
Alogdianakis Evangelos. . . . .	202713	Armida Kaba. . . . .	202727
Alokby Ghassan . . . . .	203167	Arndal Elisabeth . . . . .	202276, 202277
ALREDHA DONIA. . . . .	201004	Arosio Alberto Daniele . . . . .	201794
Alshaikh Nada A. . . . .	201004	Arruda Eurico . . . . .	202323
		Arteaga M.J. . . . .	203657-144
		Artemyeva Elena . . . . .	202111
		Artur Xhumari . . . . .	202727
		Arutunyan S . . . . .	201070
		Arvaniti Antonia. . . . .	202488
		Ashman Alexander . . . . .	203864-340
		Ashraf Nadia . . . . .	203288, 203289
		Aslanidou Anastasia . . . . .	203539-53, 203619-107

Asmar Marc-Henri . . . . . 201588  
 Astreinidou Anna . . . . . 202768, 202769  
 Ataeva D.M. . . . . 203849-326  
 Athanasiadi A. . . . . 203030  
 Aumaitre O. . . . . 203124  
 Auxiliadora Guerrero María . . . . . 201014  
 Avdeeva Klementina . . . . . 201098, 203768-254  
 Avgeri Theodora K. . . . . 203513 – 18  
 Awan Mohammad Ozair . . . . . 203519-34  
 Awan Mohammad Sohail . . . . . 203519-34  
 Ayoub BEY . . . . . 203281  
 Azevedo Catia . . . . . 203833-313

## B

Babar-Craig Humera . . . . . 203204  
 Bachert Claus . . . . . 201474, 202216, 202279,  
 . . . . . 202687, 203736-219, 203732-218,  
 . . . . . 203682-167, 203681-166  
 Bachmann Lucas M . . . . . 201565  
 Backaert Wout . . . . . 203513-16  
 Backer Vibeke . . . . . 202276, 202277  
 Badea Carmen . . . . . 202529  
 Badea Theodor . . . . . 202342  
 Badir Samih . . . . . 202541  
 Badolato Raffaele . . . . . 202271  
 Bakirtzis Christos . . . . . 202127  
 Balai Edward . . . . . 203764-246, 203538-52  
 Balatkova Zuzana . . . . . 202256, 202354  
 Baldry M. . . . . 202016, 202017  
 Baletić Nenad . . . . . 201096  
 Balica N.C. . . . . 202697, 202860, 202861  
 Ball Jessica . . . . . 201038  
 Ballas Konstantinos . . . . . 201538  
 Bamichas Gerasimos . . . . . 202980  
 Bamidis P. . . . . 203192  
 Bandi Francesco . . . . . 201794, 203176  
 Bandino Fabrizio . . . . . 203879-355  
 Banica Bogdan . . . . . 201713, 201791  
 Baptista Peter . . . . . 201859, 201861  
 Barać Aleksandra . . . . . 201296  
 Barbosa Leonel . . . . . 203404  
 Barraclough J. . . . . 203621-109, 203618-106,  
 . . . . . 203764-246, 203617-105  
 Barreto Iceia S. . . . . 202136  
 Barros Ezequiel . . . . . 203234, 203238, 202110  
 Barroso Mafalda . . . . . 202110  
 Bartosik Tina J . . . . . 20385-322  
 Basak H. . . . . 203271  
 Bates James . . . . . 203435  
 Batol Patrick John I. . . . . 203513-7  
 Batra Ruchika . . . . . 203539-53  
 Battaglia Paolo . . . . . 203114, 203176

Bavnik Yosef . . . . . 201040, 201860  
 Bawazeer Naif . . . . . 201883  
 Bayer Karina . . . . . 203845-322  
 Bebchuk Herman . . . . . 201076  
 Bécaud Justine . . . . . 202881, 202358  
 Becker Minerva . . . . . 202833  
 Becker S. . . . . 202305  
 Bejenariu Andreea Elena . . . . . 202529  
 BEJENARU Paula . . . . . 202126, 202376, 202485,  
 . . . . . 202512, 203719-204  
 Belleudy Severin . . . . . 203330  
 Ben Ner Daniel . . . . . 203747-229  
 Bénard Antoine . . . . . 203331  
 BENCHIMOL LIONEL . . . . . 202572, 203779-259  
 Benkhatar H. . . . . 203584-98  
 Bennett Alex . . . . . 203648-137  
 Bennett Warren . . . . . 203547-61  
 Benson Victoria S. . . . . 203626-114, 203648-137  
 BEQUIGNON EMILIE . . . . . 202644, 202881, 202358  
 Berget Kristine Thomassen . . . . . 202850  
 Berghi Ovidiu . . . . . 201984  
 Berlucchi Marco . . . . . 202271  
 Bertlich M. . . . . 201980  
 Besli Ioanna . . . . . 202979, 202980, 202982  
 Besser Gerold . . . . . 203513-15, 203513-6,  
 . . . . . 203844-321, 203845 -322  
 Beton S. . . . . 203271  
 Beyersdorf N. . . . . 201061  
 Bhamra Navdeep . . . . . 203539-53, 203540-54,  
 . . . . . 203619-107, 203621-109, 203618-106,  
 . . . . . 203764-246, 203617-105  
 Binz Gregori . . . . . 201267  
 Birring S.S. . . . . 203652-140, 203651-139,  
 . . . . . 203650-138  
 Bischoff Sabrina . . . . . 201563, 201565  
 Biserka Vukomanović Đurđević . . . . . 201096  
 Blackabey V. . . . . 202116  
 Bleys Ronald L.A.W. . . . . 201148, 203513-10  
 Bo Söderquist . . . . . 201075  
 Bobecka-Wesołowska K. . . . . 203726-211  
 Boboli H. . . . . 202572, 203779-259  
 Boeckermann Lauren M. . . . . 203848-325  
 bofares khaled mohamed . . . . . 201052  
 Bogomilsky M.R. . . . . 203646-134  
 Bogović Vjeran . . . . . 203260, 203513-20  
 Boia E.R. . . . . 202697  
 Boisvert Pierre . . . . . 202830  
 Bonhiver R. . . . . 203779-259  
 Bonomo Pierluigi . . . . . 203777-258  
 Bonù Marco Lorenzo . . . . . 202071  
 Bossi Paolo . . . . . 203777-258  
 Botsakis Sotirios . . . . . 203637-125, 203817-296,



..... 203808-287, 203805-284,  
 ..... 203803-283  
 Bottier Mathieu ..... 202881  
 Boubard Philippe ..... 203329  
 Boulet Louis-Philippe ..... 202830  
 Bouzas Javier Gavilán ..... 203674-160  
 Boyer Laurent ..... 202644  
 Boziki Marina ..... 202127  
 Bradford Eric S. .... 202687  
 Brady J.E ..... 203657-144  
 Brahmabhatt P ..... 203195  
 Branco Mariana ..... 203856-333  
 Bratton Daniel J. .... 202687  
 Braverman Itzhak ..... 201062, 202520, 201165,  
 ..... 203625-113  
 Bregenzer M. .... 201061  
 Bricmont N. .... 202572, 203779-259  
 BRIMILO M ..... 203435  
 Brimiouille Marina ..... 203865-341  
 Broglie Martina A. .... 203184  
 Brothánková Pavlína ..... 203441  
 Brozek Madry Eliza ..... 203723-207, 203721-210  
 Brusselle Guy ..... 202687  
 Bryan W W Lee ..... 202594  
 Bubshait Huda ..... 201004  
 Bucher Sarina ..... 201073, 201565  
 Budkovaia Marina ..... 202111  
 Budu Vlad ..... 203201  
 Bujoreanu Iulia ..... 201068  
 Bula Daniel ..... 203513-22  
 Bulent Ocal ..... 203215  
 Bulfamante A. .... 203298  
 Bumber Boris ..... 202319  
 Burgess Christopher ..... 201038  
 Burghard Marcin ..... 203723-207, 203724-210  
 Burska Zofia ..... 203723-207, 203724-210  
 Bwyer D. .... 203619-107

## C

Cabrera López C. .... 202361  
 Cabrera Ramírez M.S. .... 202361  
 Caciandone M. .... 203430  
 Champion Nick ..... 203845-322  
 Campos A. .... 203107  
 Canis M. .... 202305, 201980  
 Canonica Giorgio Walter ..... 203691-176  
 Canoui-Poitaine Florence ..... 202644  
 Cao Yang ..... 201075  
 Cardoso Luís ..... 201105  
 Cardoso Marta ..... 203285  
 Carenzi Lucas R. .... 202323  
 Carlos M. Chiesa Estomba ..... 202690, 202781

Carmel Neiderman Narin N ..... 203179, 203015  
 Carmen Alegre Segura ..... 203855-332  
 Carmona Susana ..... 203856-333  
 Carrillo Carolina Alfonso ..... 203674-160  
 Carrillo Díaz T. .... 202361  
 Carvalho Carlos ..... 203670-156, 203668-155  
 Carvalho Isabel ..... 203374  
 Carvalho Liliana ..... 203404  
 Carvalho T. .... 203236  
 Casale M ..... 201859, 201861  
 Caspi Inbar ..... 203179  
 Cassano M. .... 201859, 201861  
 CASSE Jean Matthieu ..... 203281  
 Castain Claire ..... 203331  
 Castanheira António ..... 203835-314  
 Castelhana I. .... 203107, 202886  
 Castellani L. .... 203298  
 Castelnuovo Paolo ..... 201794, 203114, 203176,  
 ..... 203777-258  
 Catană Mihai Eugen ..... 203826-309  
 Catrinel ANTONIE ..... 202126, 202376, 202485,  
 ..... 202512, 203719-204  
 Caversaccio Marco ..... 202060, 202427  
 Cea-Calvo L. .... 203657-144  
 Ceriotti Laura ..... 203632-120  
 Chaidas Konstantinos ..... 203865-341, 203864-340  
 Chaiyasate Saisawat ..... 201060  
 Chakravarty Patrick Daragh ..... 203869-345,  
 ..... 203868-344  
 Chalkiadaki Eleni ..... 203061, 203188  
 Chalkiadakis Vasileios ..... 202488  
 Chambers Alistair ..... 203227  
 Chan Robert ..... 203626-114, 203648-137  
 Chantre Tiago ..... 202110  
 Chantzis Konstantinos ..... 203854-331,  
 ..... 203741-225  
 Chapple K ..... 202484  
 Chatziavramidis Angelos ..... 203753-234,  
 ..... 203684-169, 203683-168  
 Chatzinakis V. .... 203007  
 Cherkes Maryana B. .... 203142  
 Chernikova Nadezhda ..... 203664-151  
 Cheva Angeliki ..... 202980  
 Chiang Bor-Luen ..... 203705-190  
 Chimona Theognosia ..... 202097, 202098  
 Chisholm Edward ..... 201037  
 Chitsuthipakorn Wirach ..... 203594-101  
 Chou M.Y.L. .... 203257  
 Choudhury Natasha ..... 203204  
 Choussy Olivier ..... 203340  
 Chovanec Martin ..... 202324  
 Chras Konstantinos ..... 203808-287, 203805-284

Chrisanda S Lee ..... 202594  
 Chrissi Kelly ..... 203097  
 Christensen Karl Bang ..... 202276, 202277  
 Christina Ray Iborra ..... 203855-332  
 Chroni M. .... 203356  
 Chrysouli Konstatina ..... 203248, 203326  
 Chrysovergis Aristeidis ..... 201828, 203248  
 Chrysovitsiotis Georgios ..... 201828, 202187  
 Chuang Chien-Chia ..... 202279  
 Chun-Kang Liao ..... 203705-190  
 Chupp Geoffrey ..... 202687  
 Ciftci Saït ..... 201883  
 CÎRSTEA Anca ..... 202126, 202376, 202485,  
 ..... 202512, 203719-204  
 Claravall Henry J.F. .... 201287  
 Clark Allan ..... 203386  
 Clement Andrew ..... 203869-345  
 Coden Elisa ..... 203114, 203176  
 Cohen Oded ..... 201040, 201041, 201860  
 Collins L3 ..... 202273  
 Compagnoni Inaê Mattoso ..... 202322  
 CONDEESCU Mihnea ..... 202126, 202376, 202512,  
 ..... 202485, 203719-204  
 Constantinidis J ..... 203172, 203424, 203143,  
 ..... 203145, 203170, 202127, 202980, 203417,  
 ..... 202496, 202300, 203793-273  
 Cordero Gabriela Munoz ..... 203880-357  
 Correia F. .... 203107  
 Corren Jonathan ..... 202216  
 Corriols P. .... 201206, 202827  
 Costa Isabel E. .... 203833-313  
 Costales María ..... 202826  
 Costantino A. .... 201859, 201861  
 Coste André ..... 202644, 202881, 203340,  
 ..... 203626-114, 202358  
 Covali Ala ..... 202644  
 Cozma Marina ..... 202342  
 Crăc Silviu ..... 203201  
 Crampette Louis ..... 203340  
 Crystal Lee Mun Leng ..... 203868-344  
 Cua-Lim Jacqueline ..... 201287  
 CURCĂ Claudiu ..... 202126, 202376  
 Cyran Anna ..... 203486, 202805  
 Czerwaty Katarzyna ..... 203486, 202805

## D

D. M. M. Jorge ..... 202323  
 da Silva Victor Correia ..... 201727  
 Dąbkowska Aleksandra ..... 202494  
 Daizadeh Nadia ..... 203682-167, 203681-166  
 Darr A. .... 203619-107, 203621-109,  
 ..... 203618-106, 203538-52, 203617-105

Das Jai K ..... 203519-34, 203521-36, 203522-37  
 Daskalou Dimitrios ..... 202864  
 Daveau C. .... 202545  
 Davilis Dimitrios ..... 202724, 203792-285  
 Dawoodi Sunny ..... 203859-337  
 Daya Hamid ..... 203624-112  
 De Bernardi Francesca ..... 203176, 201828  
 de Blay Frederic ..... 203586-100, 203622-110  
 De Bonis Redondo Mario ..... 203880-357  
 De Bonnecaze C. .... 202545, 203329  
 de Gabory Ludovic ..... 203340, 203328, 203329,  
 ..... 203330  
 de Kermadec Héloïse ..... 203340  
 De Lima Clara Monica ..... 203513-27, 202721  
 De Páramo Juliá ..... 203657-144  
 de Paula Flavia E. .... 202323  
 De Servi Barbara ..... 203632-120  
 De Zinis Luca Redaelli ..... 202271  
 Debry Christian ..... 203586-100, 201883,  
 ..... 203329, 203622-110  
 Deekonda P. .... 202016, 202017  
 Deganello Alberto ..... 203777-258  
 Dehgani-Mobaraki Puya ..... 203859-337  
 Delchev I. .... 202896  
 Delides Alexander ..... 203712-197, 203687-172  
 Delidis Alexandros ..... 203513 – 18  
 Dellian Marc ..... 203863-339  
 Demagkou Aikaterini ..... 203012, 203513 – 18  
 Demir Uygar ..... 201333  
 Demiri E. .... 203424  
 Demourtzidis Leonidas ..... 203675-161  
 Deniz Yamo ..... 203682-167, 203681-166  
 Dennis Poe ..... 201476  
 Dentinho Jorge ..... 203221, 203856-333  
 Denysenko R. .... 202955  
 Dertkigil Sérgio S. J. .... 202136  
 Desrosiers Martin ..... 202279, 201184, 202830,  
 ..... 203682-167  
 Devabalan Y. .... 203878-354  
 Devouassoux Gilles ..... 203622-110, 203586-100  
 Devousassoux Gilles ..... 203586-100  
 Diaconu Elena-Teodora ..... 202126, 202376,  
 ..... 202485, 202512, 203719-204  
 Dias Luis ..... 203833-313  
 Díaz-Recio Jose Suazo ..... 203674-160  
 Dicipinigaitis P. .... 203652-140, 203651-139,  
 ..... 203650-138  
 Dietmar Rafolt ..... 202600  
 Dikhtiaruk O. .... 202955  
 Diloglou Christos ..... 203675-161  
 DIMCEA Alisa ..... 202126, 202376, 202485,  
 ..... 202512

Dimitris Boubas .....	203513 – 18
Dimitrov Stoyan .....	202480
Dirla Octavian .....	202530
Ditza de Vilhena .....	203833-318
Djandji Michel .....	202279, 203682-167, .....203681-166
Djennaoui Idir .....	201883
Dobele Ilze .....	203218
Dobrut Mirosław .....	203513-22
Doglietto Francesco .....	202071
Domínguez Sosa M.S. ....	202361
Domínguez-Ortega J. ....	203657-144
Dominsky Omri .....	203015
Doros C.I. ....	202860, 202861, 203202
Doulaptsi Maria .....	202856, 202892
Dourado Nuno .....	203674-162
Dragisic Milan .....	201916
Dragomir Mihai .....	202946
DRAPER M .....	203435
Dreher Anita .....	201563
Drimalas Nikolaos .....	203637-125, 203817-296, ..... 203808-287, 203805-284, ..... 203803-283
Drozdowski Piotr .....	203513-22
Duarte Delfim .....	203833-318
Dubois S. ....	203779-259
Duhlenki Boris Ivov .....	203106, 201986
Dumitrescu Nicoleta .....	203797-276
Dumitru C.S. ....	202860, 202861
Dumitru Mihai .....	201713, 201791, 201984, ..... 202342
Durand Noemie .....	203632-120
Durham Stephen R .....	203691-176
Duverger Nicolas .....	202279
Dzhafarova Maryam .....	201077
DZHAMBAZOV KAREN .....	203513-17

## E

Eça T. ....	202592
Eckl-Dorna Julia .....	203845-322
Economides Jacob .....	203807-286
Edward S. ....	203513-7
Egbuji Ofuchi .....	203542-56
Eguiluz Ibon .....	201014
Ehricht Ralf .....	201075
Eichler U. ....	202305
Eisenberg Netanela .....	203179
El Achi Zouhir .....	203191
El Mograbi Aiman .....	203747-229
Elbosraty Hussam .....	202532, 202538, 202540, ..... 203696-181, 203698-183
Elicin Olgun .....	202060

Elisabeth R. Ninchritz-Becerra .....	203202
Ellul David .....	203868-344
Elmograbi Aiman .....	202541
Emirjona Vajushi .....	202727
Endam Leandra Mfuna .....	202830
Ermolao Andrea .....	202411
Escabasse Virginie .....	203329
Escada P. ....	202886
Escudier Estelle .....	202881, 202358
Eugene Lim .....	202594
Evans Victoria .....	203195
Exarchou E. ....	203030

## F

Fan Chunpeng .....	202279
Fanaras P. ....	203214
Fang Sean .....	203204, 203457
Fantucci Marina Zilio .....	202322
Faramarzi M. ....	203842-320
Farina Davide .....	202071
Farmer SE .....	203195
Fath Léa. ....	201883
Felisati G. ....	203298
Fent Zoltán .....	203174
Fenton Rosie .....	203808-298
Ferfeli Maria .....	201017, 201801, 201803
Fernandes A. ....	202593
Fernandes José Alberto .....	203835-314
Ferrari Marco .....	202071, 202271, 203777-258
Ferraria Lília .....	203221
Ferreira Filipa .....	203221
Ferreira L. ....	203107
Ferreira Miguel Gonçalves .....	201105, 203674-162
Ferreira Rita .....	203856-333
Fierens Sylvestre .....	203331
Filipovski R. ....	203653-141
Filoché Marcel .....	202644, 202881, 202358
Fischer René .....	203383, 203513-9
Fliss Dan M. ....	203015
Floridi Alessandro .....	203858-335
Floridi Emanuela .....	203858-335
Florou Vasiliki .....	202768, 202769
Fokkens Wytske J. ....	201098, 202279, ..... 203658-145, 203626-114, ..... 203768-254, 203203
Foletto Mirto .....	202416
Folic Miljan .....	201916
Fonseca E. ....	203657-144
Forgács Gábor .....	203174
Fotiadou C. ....	203793-273
Fotiadou Stella .....	203684-169
Fouka Evangelia .....	203518-33

Fountakis E . . . . . 201896  
 Fountoulakis Emmanuel . . . . . 201538  
 Fragola Claudio . . . . . 202525  
 Franco Joel . . . . . 201393  
 Fredlund Hans . . . . . 201075  
 Freire Filipe . . . . . 202077, 201499, 203285,  
 . . . . . 201500, 203404  
 Frolov Sergey . . . . . 203849-326  
 Fu Bertram . . . . . 201990, 201991, 202642,  
 . . . . . 203165, 203229, 203517-32  
 Fuentes-Prado M. . . . . 203228  
 Fujieda Shigeharu. . . . . 203102  
 Fyrmpas G. . . . . 203846-323, 203402

## G

Gaćeša Dejan . . . . . 201296  
 Gadea Alfonso Santamaria . . . . . 203659-146, 202582  
 Gallard Romain. . . . . 203331  
 GALLET Patrice . . . . . 203281  
 Gallimore Andrew . . . . . 203624-112  
 Gallo Stefania . . . . . 203176  
 Galvez Joseph Amado C. . . . . 203570-84  
 Gama Ilídio . . . . . 202110  
 Gane Simon . . . . . 203097, 203626-114  
 Gangl Katharina . . . . . 203845-322  
 García-Vaz Claudia . . . . . 203573-87  
 Gardner Paul A. . . . . 201393, 201394  
 Garefi Maria . . . . . 203683-168  
 Garefis Konstantinos . . . . . 203753-234, 203687-172,  
 . . . . . 203684-169, 203683-168  
 Gâta Anda . . . . . 203575-89  
 GAUCHOTTE Guillaume . . . . . 203281  
 Gavilán J. . . . . 201892, 201893  
 Gavilán Javier . . . . . 203573-87  
 Georgalas Christos . . . . . 203513, 203805-284,  
 . . . . . 203803-283  
 Georgieva Nadya . . . . . 202035  
 Gerasimos Danielidis . . . . . 201351  
 Gerber Philipp A. . . . . 203184  
 Gerhard Ranner . . . . . 202600  
 Gevaert Philippe . . . . . 201474, 202216  
 Gevorgyan A. . . . . 203768-254  
 Gheorghe Alexandra Catalina . . . . . 203201  
 Ghout Idir . . . . . 203622-110, 203586-100  
 Giannitopoulos G. . . . . 203580-96  
 Giger Roland . . . . . 202060  
 Gigov K. . . . . 203513-17  
 Gilain T. . . . . 202545, 203124  
 Gionea C.S. . . . . 202697  
 Giorgianni A . . . . . 201794  
 Giotakis Evangelos . . . . . 203012, 202187, 203326  
 Giuntoli Diletta Giulia . . . . . 201884, 202411, 202416

Givannakis Marios . . . . . 203424, 203417, 203793-273  
 Gkamari Fotini . . . . . 202724  
 GKAMPRANAS Dim . . . . . 203384  
 Gkeka Ioanna . . . . . 202496  
 Gkiouzelis Konstantinos . . . . . 203684-169  
 Gkolias Nikolaos . . . . . 203733-216  
 Gkotsis Antonios . . . . . 203319, 203384  
 Gkrinia Eleni . . . . . 203738-221, 202324  
 Gnjatić Mirjana . . . . . 201913  
 Gomes Pedro Miguel. . . . . 203833-318  
 Gómez Francisca . . . . . 201014  
 Gonçalves Débora . . . . . 203670-156, 203668-155  
 Goncalves Ana Isabel C. . . . . 203833-318  
 Goncalves Miguel . . . . . 202340  
 Gonçalves Paulo . . . . . 203670-156, 203668-155  
 GONDIM TEIXEIRA Pedro Augusto . . . . . 203281  
 Gonzalez Emmanuel . . . . . 201183  
 González García Jose A. . . . . 202781  
 González María . . . . . 203573-87  
 Górski S. F. . . . . 201158  
 Gos E. . . . . 201158  
 Gotlib Tomasz . . . . . 203726-211  
 Gougousis Spyridon D. . . . . 202979, 202980, 202982,  
 . . . . . 203675-161  
 Gouveris Haralampos . . . . . 201017, 201801, 201803,  
 . . . . . 203518-33, 203549-63  
 Graca Mariana L. . . . . 203833-313  
 Grachev N.S . . . . . 203849-326  
 Grajek Maciej . . . . . 203513-22  
 Grammatopoulou Victoria . . . . . 201211  
 Granath Anna . . . . . 203823-302  
 GRIGORE Raluca . . . . . 202126, 202376, 202485,  
 . . . . . 202512, 203719-204  
 Grigoriadis Nikolaos . . . . . 202127  
 Grigoropoulou Pinelopi . . . . . 203792-285  
 Guadagnini Dioze . . . . . 202136  
 Gualtieri Tommaso . . . . . 203777-258  
 Guha Anasuya . . . . . 202336, 202337  
 Guillemain Isabelle . . . . . 202279  
 Guimarães Alessandro Fernandes . . . . . 202322  
 Guimarães Ana . . . . . 201499, 201500  
 Guimarães Roberto Eustaquio . . . . . 202322  
 Gupta A. . . . . 202123  
 Gupta Keshav Kumar . . . . . 203539-53, 203540-54,  
 . . . . . 203541-55, 203542-56, 203538-52  
 Guzina Golac Nataša . . . . . 201913  
 Gwizdalska Iwonna . . . . . 202494  
 Gyulev At. . . . . 202896

## H

H. Skarżyński . . . . . 201110, 201111, 201158, 202494  
 Haack M. . . . . 202305

Hackenberg S. ....	201061	Huang Yanran . . . . .	203736-219, 203732-218
Hackenberg Stephan . . . . .	201262	Huellner Martin W. . . . .	203184
Hagen R. . . . .	201061	Hugentobler Marianne . . . . .	202833
Hainăroșie Răzvan . . . . .	203826-309	Hugosson Svante . . . . .	201075, 202232
Hainoglou Georgia . . . . .	201085	Huizing Egbert H . . . . .	201148, 203513-10
Hajjioannou Jiannis . . . . .	203738-221, 202324	Hüllner Martin W. . . . .	201269
Halperin Doron. . . . .	201040, 201041, 201860	Hulse Kate . . . . .	203713-198
Hamilton Leanne O W. . . . .	202539, 202543	Hultman Dennison Sofia . . . . .	203823-302
Han Ba-Da. . . . .	202365	Hummel Thomas . . . . .	202277, 203513-15
Hannan SA . . . . .	202484	Huppertz T. . . . .	202305
Hapsi Kalliopi . . . . .	203817-296	Hurley Rhona . . . . .	203713-198
Harari Ayelet. . . . .	201041	Hut Alexandru-Romulus . . . . .	202697
Harun N2. . . . .	202273	Hutson Kristian. . . . .	203386
Harvey Richard J. . . . .	203757-238, 203759-241		
Haseem Raja. . . . .	203852-329	<b>I</b>	
Hashimoto Hideki . . . . .	202742	Ickrath Pascal . . . . .	201061
Hasselbacher Katrin. . . . .	203863-339	Iereidou F. . . . .	203417
Hatano Akihiro . . . . .	201053	Iftikhar Haissan. . . . .	203520-35, 203521-36, 203522-37
Haubner Frank . . . . .	203514-29, 201980	Ikram Mubasher . . . . .	203522-37
Hebestreit Helge . . . . .	201262	Iliev G. . . . .	203629-117
Heinz Sabina . . . . .	203513-25	Ioakeimidis Stavros . . . . .	203854-331, 203741-225
Hellings Peter W. . . . .	201474, 202216, 202279, 202892, 203513-16, 203681-166	Ioniță Irina Gabriela. . . . .	203826-309
Henriques P. . . . .	202077	Irimia Larisa . . . . .	203191
Heristanidou E. . . . .	201896	Irina Oasa . . . . .	202376, 203719-204
Herman Philippe . . . . .	203340	Iro Heinrich . . . . .	202340
Hertting Olof . . . . .	203823-302	Irune E. . . . .	203878-354
Hideaki Shiga . . . . .	201146	Isaac Shochat . . . . .	201165, 203625-113
Hinder Dominik . . . . .	201563	Isabey Daniel . . . . .	202881
Hintschich Constantin . . . . .	203306	Isankova O. . . . .	203630 – 118
Hirani S. . . . .	203169a	Iskold B. . . . .	203652-140, 203651-139, 203650-138
Hiromasa Tomo . . . . .	201146	Islam Lutaf . . . . .	202216
Ho Jacqueline . . . . .	203757-238	Ismagilov E. . . . .	203615-103
Hoang Minh . . . . .	203594-101	Ivanova P. . . . .	203629-117
Hocevar-Boltezar Irena . . . . .	202661	Ivasivka Khrystyna . . . . .	203142
Hohenberger Ralph . . . . .	202060	Iza Leire Garcia . . . . .	202781, 203202
Hokkinen Lauri . . . . .	201193		
Holmström Mats . . . . .	203823-302	<b>J</b>	
Holtappels Gabriele. . . . .	203732-218	J. Dąbrowska-Bień . . . . .	201110, 201111, 201158
Holweg Cecile T.J. . . . .	203534-49, 203536-50	J. Grinholtz-Haddad . . . . .	203584- 98
Holzmann David . . . . .	201267, 201269, 203184, 203853-330	Jaafar Mustafa . . . . .	201155
Homma A. . . . .	201935, 202013	Jaakko Ormiskangas . . . . .	201476
Hong Anna . . . . .	203289	Jabarin Basel. . . . .	203294
Honma A. . . . .	201935	Jablonska-Pawlak Anna. . . . .	203486, 202805
Hopkins Claire. . . . .	201560, 202273, 202393	Jacinto João . . . . .	202110
Hosemann Werner . . . . .	203383	Jackowska Joanna . . . . .	202989
Houssein Firas A. . . . .	203848-325	Jacob-Nara Juby A. . . . .	203682-167
Howarth Peter . . . . .	202687, 203626-114	Jakovčević Antonija . . . . .	202319
Hox Valerie . . . . .	202892	Jakovljevic Sasa . . . . .	201916
Hrvoje Mihalj . . . . .	203260, 203513-20	James Arwyn-Jones . . . . .	201572
Hsieh Julien Wen . . . . .	202833, 202834, 202864	Jankowski Roger. . . . .	203281, 203329, 203682-167
		Jaumont Xavier. . . . .	202216



Jennifer Magil.....	201572	Katsilidou M.....	203846-323
Jennum P.J. ....	202257	Katsilis Georgios.....	201804, 203518-33, 203402
Jiang Rong-San .....	202834	Katsouli Georgia.....	203319
Jimenez-Chobillon Marcos Alejandro .....	203631-119	KAUR HARNEET .....	203586-100, 203622-110, ..... 203513-25
Jochen Schachenreiter .....	202600	Kaur Prabhsimran .....	203624-112
Johannes Van Ioon.....	203847-324	Kawauchi Hideyuki .....	201474
Jolly K. ....	203618-106	Kefalogianni Thiresia .....	203061, 203188
Jolly Karan.....	203539-53, 203540-54, ..... 203541-55, 203542-56, 203619-107, ..... 203764-246, 203538-52	Kekes Georgios.....	201017, 201801, 201803
Jones H.....	202016, 202017	Keller Andreas .....	202834
Jorissen Mark .....	201474, 203513-16	Kempeneers Céline .....	202572, 203779-259
Jorma Järnstedt .....	201476, 203802-282	Kennedy David .....	203626-114
Joseph Jonathan.....	202516, 202988	Kenyon O. ....	202116
Joshi Anil .....	202530	Kérimian Mélodie .....	203340, 203330
Jovancevic Ljiljana.....	201748	Kern Izidor.....	202661
Jukka Leikkala .....	201476	Kern Robert C. ....	203626-114
Julkunen Anna .....	202810	Kesner Adam .....	202256, 203354
Junqueira Leite Marcelo Gonçalves.....	202323	Khali Yasmin .....	201004
Jurlina Martin.....	203653-141	Khalil H.S. ....	202436
<b>K</b>		Khalil Hisham .....	203733-217
K. Han Joseph .....	203682-167	Khan Asif H. ....	202279, 203682-167
Kaecker Christoph .....	202060	Kiaer Eva .....	202257
Kahilogullari G. ....	203271	Kiakou Maria .....	202713, 203513-4
Kalentakis Zacharias .....	202488	Kidoguchi Masanori .....	203102
Kalish Larry .....	203757-238	Kiessling Si-Young.....	201563
Kalogritsas Nikolaos.....	203733-216	Kimura S.....	201935
Kamargiannis Nikolaos .....	202768, 202769	Kinuya Seigo .....	201146
Kamat Siddhesh .....	202279, 203682-167	Kirichenko Irina .....	203689-174
Kanjanawasee Dichapong.....	203757-238, ..... 203691-176	Kirov V. ....	201986
Kantor Ireneusz .....	203486, 202805	Kivekäs Ilkka ...	201192, 201193, 201476, 203802-282
Karageorgos Gerasimos .....	203792-285	Kizim Y. ....	203614-102, 203616-104
Karagiorgas Fanis .....	203513 – 18	Kjeldsen Anette D.....	201103
Karagkouni E. ....	201896	Kleebach Joern.....	203513-25
Karakasi Alexandra .....	203012	Ko Jinnie .....	203534-49, 203536-50
Karakostas Efthimios.....	203061	Koch Walter .....	202440, 202600
Karamagkiolas Sotirios .....	203712-197	Kojima H.....	203842-319
Karampelias George .....	203792-285	Kokkinaki Maria .....	203188
Karatzanis Alexander... ..	202856, 202892, 203764-245	Kokolakis G. ....	202459, 202458, 203197, 203268
Karavitaki Niki.....	203436	Kolia Nadeem R. ....	201394
Karelis A.....	203007	Kondo Mickey.....	203759-241
Karjalainen Markus .....	201193	Konstantinidis Iordanis .....	203402, 203753-234, ..... 203687-172, 203684-169, 203683-168
Karkanis Georgios F. ....	202713	Kontopoulos Panayiotis .....	201538
Karkos P.D. ....	203192, 203793-273	Kontunen Anton .....	201193
Karoni Eleni.....	203733-216	Korais Christos .....	202324
Kasaboglu Julide.....	202480	Korakovouni Kalliopi .....	202097, 202098
Kasemsuk Navarat.....	203691-176	Korányi Katalin .....	203174
Kashani F. ....	201980	Koren Ana .....	202661
Katotomichelakis Michael.....	202724	Korkova Anastasiya K. ....	202035
Katsantonis Christos .....	203319	Korosec Peter.....	202661
Katsikari Joulia .....	203549-63	Kosak Soklic Tanja .....	202661, 202664, 202686
		Koskinas I.....	203417, 203793-273

Koskinen Anni. . . . . 202810  
 Kotova E. N. . . . . 203646-134  
 Kotsis G.P. . . . . 202459, 203513-8, 202458,  
 . . . . . 203197, 203268  
 Kovacs Alexandra. . . . . 203637-125, 203817-296,  
 . . . . . 203803-283  
 Kowalik Katarzyna . . . . . 201063  
 Kozana Androniki . . . . . 203188  
 Kozlova N.S. . . . . 203689-174  
 Krakowczyk Łukasz . . . . . 203513-22  
 Krivorov N. . . . . 202896  
 Krzeski Antoni. . . . . 203723-207, 203724-210  
 Ktisti Antigoni. . . . . 203738-221  
 Kühnel Thomas S. . . . . 203306, 203383,  
 . . . . . 203513-9, 201161  
 Kumai Masami . . . . . 201146  
 Kumar B. Nirmal. . . . . 203386  
 Kumar R. . . . . 203621-109  
 Kumpitsch Christina S. . . . . 201190  
 Kunz Seraina . . . . . 201563, 203185, 203184  
 Kuźmińska M. . . . . 203726-211  
 Kvasha Olena . . . . . 202297  
 Kwame I . . . . . 202484  
 Kyrodimos Efthymios. . . . . 203012, 202187, 203248  
 KORODIMA Maria . . . . . 203384

## L

La Rosa C. . . . . 203652-140, 203651-139, 203650-138  
 Lachanas Vasileios . . . . . 203733-216  
 Lacheta Dominika . . . . . 203486, 202805  
 Ladas Alexandros . . . . . 202097, 202098  
 Lagoudianakis George. . . . . 203061  
 Laidlaw T. . . . . 201560  
 Lakhan Raj. . . . . 201763  
 Lakhani Raj . . . . . 203624-112, 203580-96  
 LAMBERTONI ALESSIA . . . . . 203176, 203777-258  
 Lança B . . . . . 202592, 203236  
 Lancini Davide . . . . . 202271  
 Lancner Françoise Zerah. . . . . 202644  
 Land David . . . . . 202440  
 Landis Basile N. . . . . 202833, 202864  
 Langeber Gavilán Teresa. . . . . 203674-160  
 Lapousis Ilias. . . . . 201538  
 Lapperre Therese Sophie . . . . . 202276  
 Lasithiotakis Dimitrios. . . . . 203332  
 Lassi Zohra S . . . . . 203521-36  
 Lathif Adil . . . . . 203759-241  
 Lazaridis Nikolaos. . . . . 203143, 203145  
 Le Lam. . . . . 201462  
 Lebit Daniela. . . . . 201984  
 Ledermueller R. . . . . 202305  
 Lee Chang Woo . . . . . 201211

Lee Dong-Won Lee . . . . . 202365  
 Lee Stella. . . . . 202279  
 Lefantzis D. . . . . 203030  
 Lefebvre P. P. . . . . 202572, 203779-259  
 Lehtimäki Lauri. . . . . 203802-282  
 Lehtinen Antti. . . . . 203802-282  
 Leiba Hana . . . . . 201040, 201860  
 Lenoir Vincent . . . . . 202833  
 Lenos M.G. . . . . 203197  
 Leventi A. . . . . 203169, 203214  
 Li Q. . . . . 203652-140, 203651-139, 203650-138  
 Li V.W. . . . . 203657-144  
 Lialiaris S . . . . . 203846-323  
 Liapi Anastasia . . . . . 203169, 203214, 203169a,  
 . . . . . 203220, 203332  
 Liaskos Meletis. . . . . 202713  
 Lilja Markus. . . . . 202810  
 Lima António F. . . . . 202611  
 Lima Wilma T. Anselmo. . . . . 202322, 202323  
 Lin Chih-Feng . . . . . 203705-190  
 Lin Yi-Tsen . . . . . 203705-190  
 Liu A. . . . . 203294  
 Liu David T. . . . . 203513-15, 203513-6, 203848-325  
 Liva Georgia A. . . . . 203764-245  
 Lizzio Roberta. . . . . 203112, 203119  
 Lobo D. . . . . 201206, 202827  
 Locatelli D. . . . . 201794  
 Lodes Nina . . . . . 201262  
 Lodhia Krishan . . . . . 202643  
 Lønnerød Anne Cathrine . . . . . 202850  
 López Carlos Pérez . . . . . 203674-160  
 Lopez MA . . . . . 201861  
 López-Chacón M . . . . . 203228  
 López-Higuera José M. . . . . 202826  
 López-Simón E. . . . . 201206, 202827  
 Loro Anna . . . . . 203859-336  
 Louis Bruno. . . . . 202572, 202644, 202881,  
 . . . . . 203779-259, 202358  
 Louis R. . . . . 202572, 203779-259  
 Lourijssen Evelijn . . . . . 203203  
 Lovisa Hermansson . . . . . 201107  
 Ludwig Nils . . . . . 203486, 202805  
 Luís L. . . . . 202592, 202593  
 Luo Yiwen . . . . . 203185  
 Lupoi Daniel . . . . . 202946  
 Luthra K. . . . . 203580-96

## M

M. Alomani. . . . . 203584- 98  
 M. Buksińska . . . . . 201110, 201111  
 M. Crepy-Ameli . . . . . 203584-98  
 Maayan Dor . . . . . 201062, 201165

Machado André	203374	203753-234, 203684-169, 203683-168
Maciejewski Adam	203513-22	202071
Mackaaij Claire	201148, 203513-10	202110
Mădălan Elena	202298	202110
Madatali Nurdin Aliya Nurula	202592, 202593	202361
Maddalo Marta	203777-258	202136
Madeiros Nuno	203711-196	202805
Magalhães Clara	203835-314	203657-144
Magalhães M.	203107	203879-355
Magdan Madalin	203709-174	202592, 202593, 202326
Magill JC	203426	202323
Magomedova A. M.	203849-326	202323
Magrini Stefano Maria	203777-258	Mateos-Serrano Blanca
Mahamud Ishtiak	203288, 203289	203573-87, 201892, 201893, 203855-332, 203674-160
Mahaudeau Pierre	201883	201041
Maiorano Eugenia	203112, 203119	202324
Maiou Charikleia	202324, 203729-213	202713
Mak Mandy	202988	202742
Mäkelä Mika J.	202810	Mattavelli Davide
Mäkitie Antti	202810	202071, 203777-258
Malard Olivier	201392, 203329	Matteo Trimarchi MD
Malaxianaki Georgia	203188	201322, 201323
Maleš Josip	203260, 203513-20	Matti Elina
Malheiro Emeline	202644	203112, 203119
Malyavina U	201067, 201069, 201070	Mayer Bhabita
Mangin David	202881	203626-114
Mangussi-Gomes João	203759-241	Mazza Valerio
Maniakas Anastasios	201183, 202830, 201588	202071
Maniatakos Vasilios	203332	McFaul Susan
Manika Ioanna	203061	202872
Mannent Leda P.	202279, 203682-167, 203681-166	McGarvey L.
Mantelakis Angelos	202303	203652-140, 203651-139, 203650-138
Mantsopoulos Konstantinos	202340	Mckenzie Andrew
Maragkoudakis Pavlos	203513 – 18	202393
Maragoudakis Pavlos	203012, 203712-197, 203687-172	Meco C.
Marc Dean	201476	203271
Marcells George N.	203759-241	Meerwein Christian
Margaritis Eleftherios	201538	201267, 201269, 203853-330
Marglani Osamah	203859-338	Megía R.
Maria M. Soriano Reixach	202690, 202781, 203202	201206, 202827
Mariano M.	203107	Meier Eva Catharina
Marien Gert	202892	201564
Marini Katerina	202768, 202769	Melinte Gabriela-Violeta
Mariño-Santiago Franklin	202525	202950
Marinou A.	203169, 203214, 203220, 203332	Melo Marta
Marinov Tsvetomir	202480	202077, 203285, 203107
Mario Bussi MD	201322, 201323	Melo Patrícia
Marjanovic Kavanagh Marcel	202319	203238
Markkola Antti	202810	Meloni Marisa
Markou Konstantinos	202496, 203402,	203632-120
		Meltzer Eli O.
		203534-49
		Mendes Gonçalo
		203374
		Mendes Nuno
		202077, 201500, 201499
		Mendeš Tihana
		203260
		Menexes G.
		203192
		Menger Dirk J.
		203513-10, 201148
		Mentzel H.
		202305
		Merkulov Oleksandr
		202733
		Meytel I.
		201067, 201069, 201070
		Mfuna Leandra Endam
		201183
		Micaela Acosta
		201572
		Michel Justin
		203340
		Mickielewicz Aleksandra
		202494
		Mierzwinski Claire Hutin
		203622-110, 203513-25
		Mihalcea Catalin C.
		203709-194
		Mihali Maria
		202342
		Miksa L.
		202697
		Milanković Stjepan Grga
		203260, 203513-20
		Milea Alex I.
		202529, 202950



Miliadou A.C. ....	202459	.....	203650-138
Milioni Athanasia .....	203807-286, 203792-285	Mueller Christian A. ....	203513-15, 203513-6,
Millette Lauren A. ....	203534-49, 203536-50	.....	203844-321, 203845-322
Milligan Gary .....	203648-137	Muhammad Hammad Deewani, .....	203521-36
Milstein Asher .....	201040, 201860	Mulholland Carl .....	202872
Min Keh Siew .....	202539, 202543, 202872	Müller Elke .....	201075
Mirabella Rosolino .....	203112, 203119	Müller Sarina .....	202340
Miranda Daniel A. ....	202611	Mullol Joaquim .....	202216, 202892, 203626-114,
Miranda Vera .....	203670-156, 203668-155	.....	203228, 203682-167, 203681-166,
Mireas George .....	203319	.....	203651-139, 203536 -50
Miri Sarid. ....	201165	MUNTEANU Gloria .....	202126, 202376,
Miskiewicz Piotr .....	203486, 202805	.....	202485, 202512, 203719-204
Mistry N. ....	203621-109	Muradov Fazliddin .....	202530
Mistry Rakesh. ....	203624-112	Murono Shigeyuki .....	202742
Mitikami Fenólio Guilherme Henrique .....	202322	Muscat R. ....	203804-288
MITRAN Denisa .....	202126, 202376, 202485	Mustafa Khawaja .....	203519-34, 203521-36,
Miwa Takaki .....	201146	.....	203522-37
Miyazono Sadaharu. ....	201146	Muzzafar Jameel .....	203541-55
Mladenov Tsv. ....	201986	Myller Jyri .....	202810
Mladenov Tsvetan .....	203106		
Mladina Ranko .....	202319	<b>N</b>	
Moffa A. ....	210859, 201861	Nahil Rida M. ....	203880-357
Mohan S. ....	202123	NAIK PARESH .....	203436, 203481, 203493,
MOHD SLIM MOHD AFIQ .....	203713-198,	.....	203542-56, 203575-93
.....	203869-345	Nakache Gabriel. ....	202541
Moissl-Eichinger Christine .....	201190	Nakamaru Y. ....	201935, 202013
Mokoyan Zh .....	201069	Nakazono A. ....	201935
Molinari Giulia .....	202427	Nakhleh Laura .....	201883
Molinier-Blossier Sandrine .....	203331	Nanfitò Ludovica .....	203112
Mom T. ....	202545, 203124	Nascimento Joana .....	203238
Monecke Stefan. ....	201075	Nasta M. ....	203007
Montalto Kelly .....	203534-49, 203536-50	Nasuno Tomomitsu .....	201053
Montalvão P. ....	203107	Natsis Konstantinos .....	203143, 203145
Montrieul L. ....	202545, 203124	Naumenko O. ....	202955
Morand Francois .....	203586-100, 203622-110	Navaratnam Annakan .....	202988
Morand Grégoire. ....	203184	Ndife Briana .....	203513-25
Moreira Carla .....	203238	Ndomahina Jane .....	203227
Moreira Filipa C. ....	202611	Neagos Adriana .....	203191
Mori Eri .....	203842-319	Neagos Cristian .....	203191
Morice A. ....	203652-140, 203651-139, 203650-138	Neamonitou F. ....	203617-105
Morinière Sylvain .....	203329	Neculcea Tiberiu .....	203191
Mortuaire Geoffrey .....	202545, 203340,	NEDELCEU Ruxandra Ioana. ....	202126, 202376,
.....	203329, 203331	.....	202485, 202512, 203719-204
Moschovakis Eustratios .....	203741-225	Neumaier Patricia .....	203295
Mosito Sylvia .....	202604	Neumann Aline S. ....	203853-330
Moumoulidis Paris. ....	203807-286	Ngaotepprutaram Premyot .....	203691-176
Moya-Plana Antonie .....	203331	Nguyen Duc Trung .....	203281
MPAKAS Vas. ....	203384	Nguyen Martin A. ....	203651-139, 203650-138
Mpakas Vasilios .....	203319	Nica Adriana Elena. ....	201713, 201791
Mpouronikou Anna .....	203733-216	NICOLAESCU Alexandru .....	202126, 202376,
Mpoutou Afroditi. ....	203549-63	.....	202512, 203719-204
Muccino D. ....	203652-140, 203651-139,		

Nicolai Piero ..... 201884, 202071, 203777-258,  
 ..... 202411, 202416  
 Nicolau A. .... 202592  
 Nikolaidis V. .... 203683-168  
 Nikolaos Mastronikolis ..... 201351  
 Nikolaou Angellos ..... 201804, 202979  
 Nikolaou Georgios ..... 201267  
 Nikolov G. .... 203106, 201986  
 Nimrod Amitai ..... 203747-229  
 Ninos Alexandros ..... 202713  
 NIȚU Liliana ..... 202126, 202376, 202485,  
 ..... 202512, 203719-204  
 Nizamova Nezi ..... 202480  
 Noguchi Emiko ..... 203102  
 Noguchi Tomohiro ..... 201146  
 Norris Jonathan H. .... 203864-340  
 Novaković Zorica ..... 201913  
 Novicka R. .... 203630 – 118  
 Numminen Jura ..... 201192, 201193, 202810,  
 ..... 203802-282  
 Nurdin A. .... 203236

## O

Odell E3. .... 202273  
 Ogawa Kazuma. .... 201146  
 Ohashi Kentaro. .... 201053  
 Ohki Motofumi. .... 201053  
 Oikonomopoulos P. .... 203513-8  
 Oksala Niku. .... 201192, 201193  
 Ola Sunnergren ..... 201107  
 Oliveira Oliveira ..... 202592, 202593  
 Oliveira V. .... 203236  
 Olivieri Carla ..... 203119  
 Olli Valtonen ..... 201476  
 Olsson Petter ..... 203586-100, 203622-110,  
 ..... 203513-25, 203534-49, 203536-50  
 Omachi Theodore ..... 202216  
 Omar Ahmed ..... 203229, 203517-32  
 Onutchak Adrian ..... 203142  
 Opyrchal Jakub. .... 203513-22  
 Órfão João ..... 203285, 203404  
 Orlandi Ester. .... 203777-258  
 Orsel Stephane. .... 203331  
 Ortiz Benjamin ..... 202279, 203682-167,  
 ..... 203681-166  
 Osborne Max Sallis ..... 203540-54, 203764-246  
 Osborne MS. .... 203618-106  
 Oscar Luca ..... 203776-257  
 Osen Elana R. .... 201763  
 Ospina Javier. .... 202826  
 OTHMAN Amer ..... 202126, 202376, 202485,  
 ..... 203719-204

Otori Nobuyoshi. .... 203842-319  
 Ottaviano Giancarlo. .... 201884, 202411, 202416  
 Outh R. .... 203124  
 Ozoliņa L. .... 203630-118

## P

P.H. Skarżyński ..... 201110, 201111, 201158, 202494  
 Padoan Rita ..... 202271  
 Pagella Fabio. .... 203112, 203119  
 Palla Eyfrosyni ..... 203729-213  
 Pallis Georgios ..... 203012  
 Pantazidou G. .... 201896  
 Pantazopoulos Theodoros ..... 202488  
 Papacharalampous George ..... 202724, 203807-286  
 Papadakis Chariton ..... 202097, 202098  
 Papadakis Ioannis ..... 201538  
 Papadimitriou Nikolaos. .... 203712-197  
 Papadopoulos K. .... 203417  
 Papadopoulos Panayiotis ..... 203145  
 Papadopoulou Dionyssia ..... 202496  
 Papakosta Despoina ..... 203518-33  
 Papanikolaou Vasileios S. ... 201828, 203248, 203326  
 Papapetropoulos Nektarios ..... 202488  
 Papon Jean-François ..... 202572, 202881, 202358,  
 ..... 203779-259  
 Papouliakos S. .... 203169, 203214, 203220, 203332  
 Pär Stjärne ..... 201107, 203823-302  
 Parker Jane K. .... 203097  
 Pasquier Jennifer ..... 202881  
 Patel Neil. .... 203869-345  
 Patiar Shalini. .... 202516  
 Patron V. .... 202545  
 Pauline Paris ..... 201883  
 Paval Cristian C. .... 203709-194  
 Pavlidis Pavlos .... 201017, 201801, 201803, 201804,  
 ..... 203518-33, 203549-63  
 Pavlou A. .... 203169  
 Pavlović Oliver ..... 203513-20  
 Pavord I. .... 203652-140, 203651-139,  
 ..... 203650-138  
 Pazahr Shila. .... 201269  
 Pedrero-Escalas F. .... 201892  
 Pedrosa G. .... 201500  
 Peev Kiril ..... 202480  
 Peixoto Conceição ..... 201727  
 Pekkanen Juha ..... 202810  
 Peksis K. .... 203630 – 118  
 Peksis Kaspars ..... 203752-233  
 PENDOLINO ALFONSO LUCA ..... 201155, 201884  
 Pentti Saarenrinne. .... 201476  
 Pereira Susana ..... 203234, 203238, 203107  
 Pereira Valera Fabiana Cardoso. .... 202322, 202323

Peress Eric. ....203586-100, 203622-110,  
 .....203513-25  
 Perez Orribo Alicia Maria ..... 203880-357  
 Pérez-Lázaro A. .... 201892  
 Peric Aleksandar .....201296, 201096  
 Perić Aneta ..... 201296  
 Perkovic Adam .....203757-238  
 Pettorelli Andrea .....201884, 202411, 202416  
 Phillips Katie M. .... 203844-321  
 Philp Nichola..... 202539, 202543  
 Philpott Carl ..... 203386, 203626-114  
 Piagkou Maria. .... 203143, 203145  
 Piazza Cesare ..... 203777-258  
 Picolo S..... 203298  
 Pietroşanu Cătălina ..... 203826-309  
 Pimentel João Cabral. .... 203234, 203238, 202886  
 Piotrowska-Seweryn Agnieszka.....203513-22  
 Pizzoglio Valeria ..... 203119  
 Plaza V .....203657-144  
 Plzak Jan .....202256, 202354  
 Pochuieva Tetiana ..... 202733  
 Poenaru M. .... 202697  
 Poikane Eliza ..... 203295  
 Poirrier Anne-Lise ..... 202572, 203779-259  
 Polainas Sofia ..... 203856-333  
 Poletti Sophia C..... 201563  
 Polev G.A..... 203849-326  
 Poli Piercarlo..... 202271  
 Polymerou I..... 202436  
 POPA Teodora ..... 202126, 202376, 202485, 202512  
 Popaduk V.I. ....203689-174  
 Popescu Alin..... 202642, 203165, 203229  
 POPESCU Bogdan..... 202126, 202376, 202485,  
 ..... 202512, 203719-204  
 Popko-Zagor Mariola. ....201063, 201148, 203513-10  
 Popov Todor ..... 202480  
 Poslednik Krzysztof B. ....203486, 202805  
 Potamianos Spyridon ..... 202187, 203326  
 Pozzi F..... 201794  
 Prates Mirela Cristina M. .... 202323  
 Prieto del Prado Ana ..... 201014  
 Printza Athanasia ..... 202127, 202300  
 Proença-Modena José Luiz..... 202323  
 Proimos Efklidis ..... 202097, 202098  
 Prokopakis Emmanuel..... 201474, 202856, 202892,  
 ..... 203764-245  
 Protonotariou Efthymia ..... 202496  
 Provatas I..... 203356  
 Prpić Tin ..... 203260, 203513-20  
 Prstacić Ratko..... 202319  
 Pujols L .....  
 Pulpă Raluca Oana..... 203826-309

Pusateri Alessandro..... 203112, 203119  
 Puvanendaran M. .... 203513-4  
 Pyrgakis Panagiotis ..... 203637-125, 203808-287,  
 ..... 203805-284, 203803-283

## Q

Quadrio M..... 203298  
 Quah Qin Xian N..... 203878-354  
 Quero-Campos Iris ..... 202525  
 Quitter Christian ..... 201684  
 Qureishi Ali ..... 203879-355

## R

Rachmanidou Anastasia ....202303, 202530, 202643,  
 ..... 203227, 203457, 202123  
 Rachovitsas Dimitrios ..... 202496  
 Radtsig E. Yu. .... 203646-134  
 Rafailidis V. .... 203793-273  
 Ragoni Ana C..... 202525  
 Rajiah Liz ..... 202484  
 Ram Zvi ..... 203015  
 Ramakrisnan Vijay ..... 203534-49  
 Ramezanpour Mahnaz ..... 202013  
 Ramos Miguel Limbert ..... 203570-84  
 Rampinelli Vittorio. ....202071, 202271, 203777-258  
 Randhawa Premjit ..... 201155  
 Ranford David..... 203567-81, 203568-82  
 Raposo Diogo ..... 203285, 203107, 201500  
 Raposo F..... 202886  
 Rata P.I. ....202860, 202861  
 Rau Ileana ..... 202342  
 Raumane D. .... 203218  
 Rautiainen Markus ..... 201192, 201193, 202810,  
 ..... 201476, 203802-282  
 Ravanelli Marco ..... 202071  
 Ray Ishita..... 203859-337  
 Raychowdhury R..... 201057, 201056  
 Razou Andriana ..... 203012, 203513-8  
 Real Luciana E. .... 202525  
 Reichelt Andreas ..... 202340  
 Reis L..... 202886  
 Reitsma Sietze ..... 201098, 203658-145, 203203  
 Renaud Marion ..... 202358  
 Renkonen Risto ..... 202810  
 Renner Bertold..... 203513-15, 203513-6  
 Rennie Catherine..... 201068, 201367, 201572,  
 ..... 202468, 203878-354, 203426  
 Renteria Axel E. ....202830, 201183  
 Reuven Yonatan..... 202541  
 Rey Emile..... 203340  
 Rezo Matej ..... 203260, 203513-20  
 Richards Emma ..... 203481

Righini Christian .....202545, 203340  
 Rijavec Matija ..... 202661  
 Rimmer Joanne .....203757-238  
 Rinaldi V. ....201859, 201861  
 Ringel Barak ..... 203179  
 Rito João ..... 202077  
 Rodrigues Berta M. .... 203833-313  
 Rodrigues Dias David.....201105, 203674-162  
 Rodrigues P. ....202592, 202593  
 Roh Daeyoung ..... 202940  
 Roine Antti.....201192, 201193  
 Rondón Carmen..... 201014  
 Roongrotwattanasiri Kannika. .... 201060  
 Rosati Roberta ..... 203777-258  
 Rowe Paul.....203682-167, 203681-166  
 Rubin J. .... 203169a  
 Ruiz-Bravo E..... 201893  
 Ruiz-García Carmen..... 203573-87  
 RUJAN Simona Andreea ....202126, 202376, 202485,  
 ..... 202512, 203719-204  
 Rumeau Cécile ....202545, 203281, 203340, 203329  
 Runggaldier Daniel..... 203185  
 Rupp Niels J. .... 203184  
 Rusescu andreea ..... 203826-309  
 Rusetska Natalia..... 201063  
 Rusetsky Yuri .....201067, 201069, 201070  
 Russo Federico..... 203114  
 Russo Massimiliano ..... 202411  
 Rylska O. .... 202297

## S

S. Zaer ..... 203584-98  
 Sabatino L. ....201859, 201861  
 Saber Amanj..... 202232  
 Sacks Raymond .....203757-238  
 Sadrizadeh S. .... 203842-320  
 Saenz Rebecca ..... 202216, 203534-49,  
 ..... 303536-50  
 Saga Gutierrez Carlos ..... 202781  
 Sagoo Karanjeet..... 202643  
 Saibene A.M. .... 203298  
 Said Nihaya..... 202276  
 Saini Fani. .... 203738-221, 203733-216  
 Sakano Eulalia.....202136, 202322  
 Sakellaridis A.C. .... 202459, 203513-8, 202458,  
 ..... 203197, 203268  
 Sakuma Emerson T. I. .... 202136  
 Sakurai Rinko ..... 203842-319  
 Salas María ..... 201014  
 Salee Parichat..... 201060  
 Saleh Hesham ..... 201068, 201367, 201572,  
 ..... 202468, 203426

Salomváry Bernadett.....203174  
 Sami Amtul ..... 202643  
 Sampaio Marcelo H. .... 202136  
 Samuel Constant .....203631-119  
 Samuthpongton Jompol ..... 203594-101  
 Sánchez Álvaro de Arriba .....203674-160  
 Sanchez Franklin Marino..... 203659-146, 202582  
 Santamaria-Gadea Alfonso ..... 202525  
 Santos Jorge ..... 203674-162  
 Santos Mariline .....201105, 203674-162  
 Santos Pedro ..... 203374  
 Santos Tiago S..... 203670-156, 203668-155  
 Santos-Granados Gonzalo ..... 202525  
 Sanyal Shaoni ..... 201057, 201056  
 Sarafidou Anastasia.....203172, 203170, 203417  
 Sarafoleanu Codrut .....202529, 202950  
 Sarasola Ekhiñe Larruscain ..... 202781  
 Saratsiotis Angelos.....202724, 203807-286,  
 .....203792-285  
 Saratziotis Athanasios ..... 201017, 201801, 201803,  
 ..... 203738-221, 202324  
 Sarnowska Elzbieta ..... 201063  
 Saroul nicolas .....202545, 203124  
 Sarris B ..... 201896  
 Sartori Daniele ..... 201884  
 Satia I. ....203652-140  
 Saturno Tamara H..... 202323  
 Saunders Michael .....203546-60, 203808-298  
 Sauter Alexander ..... 203863-339  
 Savchenko T..... 202297  
 Saviotto Enrico .....201884, 202411, 202416  
 Saxena S..... 203580-96  
 Scarpa Bruno .....201884, 202416  
 Schalek Petr .....202336, 202337  
 Schebesch K. H. ....203306, 201161  
 Schelfhout J..... 203657-144, 203651-139,  
 ..... 203650-138  
 Scherzad Agmal ..... 201262  
 Schindler Valeria ..... 203185  
 Schinke H..... 201980  
 Schitteck Gregor .....201017, 201801, 203549-63  
 Schmid-Grendelmeier Pete .....201073, 201564  
 Schneider A..... 201980  
 Schneider Sven..... 203845-322  
 Schreiber Alberto..... 202071, 203777-258  
 Sckell Maximilian ..... 202440  
 Seccia Veronica .....203626-114  
 Sedaghat Ahmad R. .... 203844-321  
 Seebauer Caroline ..... 203513-9, 201161  
 Segboer Christine ..... 203768-254  
 Seghayeh M. C.....202572, 203779-259  
 Sekine Rumi ..... 203842-319

Selwyn Anya C.E. ....	201990, 201991, 202642, ..... 203165, 203229	Solomos Panagiotis .....	203712 -197
Şerban Berteşteanu. ....	202376, 202485, 202512, ..... 203719-204, 202126, 202470	Sook Han Y. ....	203288
Seresirikachorn Kachorn. ....	203594-101	Sørensen Anne Lyngholm. ....	202276, 202277
Sergeeva N .....	201067, 201070	Soudry Ethan .....	203747-229, 202541
Serrano Elie. ....	203340	Sousa Ana R. ....	203626-114, 203648-137
Serras D. ....	202593	Sousa José Pinto. ....	203234, 203238
Šestak Anamarija .....	203260, 203513-20	Sousa Patricia Silva .....	203835-314
Seys Sven .....	201474, 202892	Soyka Michael B. ....	201073, 201267, 201269, ..... 201563, 201564, 201565, ..... 203185, 203184, 203853-330
Shaladi Ali .....	203517-32	Speth Marlene .....	203844-321, 203848-325
Sharma Gunjan. ....	203513-6	Spiegel J. L. ....	202305
Sharma Srijan .....	203513-11	Spinos Dimitrios .....	201068, 203513
Shelesko E.V .....	203664-151	Spinozzi Giuseppe .....	203112, 203119
Shin Ji-Hyeon .....	202940	Spiranskaya O. ....	201067, 201069, 201070
Shin Seung-Heon .....	202365	Spirito Luca .....	203176
Shochat Isaac .....	201062, 202520	Sprügel L. ....	201061
Shoshani Yohai .....	201040, 201860	Spyridon Lygeros .....	201351
Siddiqui Shahid .....	203682-167	Spyridonidis Efstathios .....	203549-63
Sierdzinski Janusz .....	203486, 203723-207	Spyropoulou G.A. ....	203424
Signorini Liana .....	202071	Stagas Marios. ....	201538
Silar Mira. ....	202661	Stamataki Sofia .....	202488
Sileo Giorgio .....	201794	Stamkopoulou P. ....	203846-323
Silva C. ....	202592, 202593, 203236	Stanek V .....	203845-322
Silva D. ....	202886	Stansfield Joe .....	203513-11 , 202914
Silva Diana P. ....	203833-313	Starzyk Joanna .....	201565
Silvia Martin .....	203880-357	Stavrakas Marios .....	203192, 203733-217
Sim Fiona. ....	203869-345	Stavrianaki Anna .....	203061
Simantirakis Christos. ....	203061	Stec Zuzanna. ....	203724-210
Singerman Kyle W. ....	203848-325	Steelant Brecht. ....	203513-16
Sinnott Joseph .....	201037, 201038, 203546-60, ..... 203547-61, 203548-62, 203808-298	Stefanos Papaioannou .....	201351
Sioni A. ....	203513-8	Stefko S. Tonya .....	201393
SIREȚEANU Luiza Maria .....	202126, 202485, ..... 202512, 202376	Steiner Urs .....	201564, 201565
Sistiaga Suarez Jon A. ....	202781	Steinke Maria .....	201262
Skoulakis Charalampos .....	202324, 203729-213	Steinsvåg Sverre K .....	202850
Skoumpas Ioannis .....	201804, 202979, 202982, ..... 203675-161	Stoyanov Tsv. ....	203106, 201986
Skoupa Jana .....	203328	Stracenski-Perge Mirjana .....	202101
Skoura Lemonia .....	202496	Strunina Yu.V. ....	203664-151
Škrlec Martin .....	202688	Sukapan Kornkanok. ....	201060
Small Mark .....	203648-137	Suliman Omar Abu. ....	203859-338
Smiljanić Ranko .....	202319	Sunkaraneni San .....	203386
Smith J.A. ....	203652-140, 203651-139, 203650-138	Sunkaraneni Vishnu S. ....	201211
Smith Steven G. ....	202687	Susanne Engelmann .....	201075
Snidvongs Kornkiat .....	203594-101	Sutherland Josh .....	202872
Snyderman Carl H. ....	201393, 201394	Suvinen Mikko .....	202810
Söderquist Bo. ....	202232	Suwanwech Triphoom .....	203691-176
Sofokleous Valentinos .....	203012, 201828, 202187	Suzuki M. ....	201935, 202013
Sokolova Anna .....	203404	Suzuki Takayoshi. ....	202013
Solomi Eythymios .....	203729-213	Syed Irfan .....	202303, 202530, 202643, ..... 203227, 203457
		Szalóki Tibor .....	203174
		Szczepanski Mirosław J. ....	203486, 202805



Szumniak Ryszard .....203513-22  
 Szymczyk Cezary .....203513-22

## T

Taha Mohamad ..... 203625-113  
 TAHER Bianca Petra ..... 202126, 202376, 202485,  
 ..... 202512, 203719-204  
 Tailor Hiteshkumar ..... 202872  
 Taki Junichi ..... 201146  
 Talavera Karel .....203513-16  
 Talwar Rishi ..... 202116, 203852-329  
 Tamás László .....203174  
 Tamashiro Edwin ..... 202322, 202323  
 Tamminem Pekka ..... 203802-282  
 Tanase Ionut ..... 202946  
 Tancer Ivana ..... 202688  
 Tania Cuesta Luzzy ..... 203855-332  
 Tantilipikorn Pongsakorn .....203691-176  
 Tarazis Konstantinos ..... 203753-234  
 Tatiou Zoi ..... 201085  
 Tavernaraki A. .... 203356  
 Teeranoraseth Tanyathorn ..... 201060  
 Tei Masayoshi ..... 203842-319  
 Teitelbaum Tali ..... 203625-113  
 Terzakis Dimitrios ..... 203513  
 Terzoudis Christos ..... 203738-221  
 Tessler Idit ..... 201860  
 Testera Almudena ..... 201014  
 Thamboo A. .... 203294  
 Theys Tom. .... 203847-324  
 Thomas Lucie ..... 202358  
 Thonnellier Celine ..... 203586-100, 203622-110  
 Thunberg Ulrica ..... 202232, 201075  
 Till Stephen J. .... 202393  
 Timpano Silviana ..... 202271  
 Tinelli Carmine ..... 203119  
 Titelis Konstantinos ..... 202768, 202769  
 Tokić Tomislav. .... 202319  
 Tomasini Davide ..... 203777-258  
 Tomasoni Michele ..... 203777-258  
 Tomazic Peter V ..... 201190  
 Tomazini Gabriela Canina ..... 202322  
 Topalova A. ....203513-17  
 Toppila-Salmi Sanna ..... 202810  
 Toro Mariana D. C. .... 202136  
 Torgeli Athanasia ..... 203637-125, 203817-296,  
 ..... 203808-287, 203803-283  
 Trampedach Charlotte Riis ..... 202276  
 Tran Luan ..... 201462  
 Trau Guillaume ..... 201883  
 Traykova N .....203513-17  
 Trévillot Vincent ..... 203340

Triantos S. .... 203007, 203030  
 Triaridis S. .... 203192, 203424, 202300, 203417  
 Trimoska-Radevsk A. ....203653-141  
 Trivic Aleksandar ..... 201916  
 Tsagkovits Aikaterini ..... 202516  
 Tsakiraki Helen ..... 202097, 202098  
 Tsakiropoulou Evangelia .... 203753-234, 203687-172  
 TSAPRANTZI AGGELIKI ..... 201085  
 Tsinaslanidou Z. .... 203172, 203170  
 Tsiropoulos G. .... 203424, 203793-273  
 Tsiiridis Ioannis ..... 203738-221  
 Tsoumaridou Aikaterini. .... 202459, 203007, 203030,  
 ..... 203513-8, 202458, 203197, 203268  
 Tsurumoto Yuka ..... 203842-319  
 Tsvirinko I. .... 203614-102, 203616-104  
 Tu Aldine ..... 203845-322  
 Tudosie Mihai D. .... 203709-194, 203719-204  
 Turri-Zanoni Mario. .... 201794, 203114, 203176,  
 203777-258  
 Tzontcheva A. .... 203652-140, 203651-139,  
 ..... 203650-138  
 Tzorakoleftheraki S-E. .... 203793-273

## U

Ugolini Sara ..... 203112, 203119  
 Ugrinovic Aleksandar ..... 201916  
 Uluc D. .... 203271  
 Unadkat Samit ..... 201155  
 Ungureanu Ramona ..... 202298  
 Urbancic Jure ..... 202664, 202686, 202688

## V

Vaca Miguel ..... 203659-146, 202582  
 Vakis Antonis F. .... 203764-245  
 Valaperti Alan. .... 201565  
 Valdiande José J. .... 202826  
 Valkov Al. .... 203106, 201986  
 Vallianou Kyriaki ..... 203729-213  
 Valsamidis Constantinos ..... 202127, 202300  
 Valsamidis Nikolaos ..... 202300  
 van Boemmel Lucas. .... 202440  
 van Cutsem Jean-Christophe ..... 201474  
 Van der Lans Rik. .... 203658-145  
 Van Gerven Laura ..... 203513-16, 203847-324  
 Van Nevel Sharon .....203732-218  
 Van Zele Thibaut ..... 201474  
 Vardouniotis Alexios S. .... 201538, 202856  
 Vargas-Alvarez Aitor ..... 203202  
 Vasileios Danielidis. .... 201351  
 Včeva Andrijana ..... 203260, 203513-20  
 Velegarakis Stylianos ..... 202856  
 Venelin Marinov .....203581-95

Vergez Sebastien ..... 203340, 203331  
 Verillaud Benjamin. .... 202545, 203340, 203331  
 Verlinde-Schellekens Suzanne A.M.W. .... 201148,  
 ..... 203513-10  
 Vetrician Iulia. .... 203709-194, 203721-206,  
 ..... 203719-204  
 Vicheva Dilyana ..... 202502  
 Vielsmeier Veronika. .... 203513-9  
 Viera Artilles J. .... 201206, 202826, 202827  
 Viksne Rudolf ..... 202978  
 Ville Rantanen ..... 201476  
 Virtanen Jussi ..... 201192, 201193  
 Vischioni Barbara ..... 203777-258  
 Vlamincq Stephan ..... 201474  
 Vlastos Ioannis ..... 202892  
 Vodicka Jan ..... 203441  
 Vogt Klaus ..... 202422, 202440, 202978, 203295  
 von Buchwald C. .... 202257, 202276, 202277  
 Vosshall Leslie Birgit. .... 202834  
 Vreugde Sarah ..... 202013  
 VRINCEANU DANIELA ..... 201713, 201791,  
 ..... 201984, 202342  
 Vrochidis Paraskevas ..... 203143, 203145  
 Vuento Risto ..... 201193  
 Vural Alperen ..... 202071  
 Vyaz'menov E.O. .... 203646-134

## W

Wahba Basim ..... 202642, 203165, 203229  
 Wakabayashi Hiroshi ..... 201146  
 Walczak Dominik ..... 203513-22  
 Walker Abigail ..... 202303, 203227  
 Wang C.H.Wang ..... 203257  
 Wang Eric ..... 201393, 201394  
 Waniewska-Łęczycka Martyna ..... 201063  
 Warman Meir. .... 201040, 201041, 201860  
 Washiyama Kohshin ..... 201146  
 Wawarczyk-Fröhlich Sandra ..... 202494  
 Weber Rainer ..... 203383  
 Weiss Bernhard G. .... 202305  
 Wen Weiping ..... 203732-218  
 Wengier Anat ..... 203015  
 Wernecke Klaus-Dieter ..... 202978, 203295  
 Wierzgoń Janusz ..... 203513-22  
 Wolf Axel. .... 201190  
 Wong BLK ..... 203513-4  
 Wong Michele ..... 202834  
 Wormald Peter-John ..... 202013  
 Woszczek Grzegorz ..... 202393  
 Wynne David McGregor ..... 203713-198

## X

Xanthopoulou Kuriaki ..... 201804  
 Xanthou I. .... 203172, 203170  
 Xekouki Paraskevi K. .... 203764-245  
 Xia Jiao. .... 202393  
 Xie Shifan ..... 202643  
 Xu Zhaofeng ..... 203736-219, 203732-218

## Y

Yacoub Abraam ..... 202427  
 Yadav Nidhi. .... 203858-335  
 Yampolska Kateryna ..... 202733  
 Yancey Steve W. .... 203626-114  
 Yang Shibing ..... 203648-137  
 YAPP D. .... 203435  
 Ye Mi-Kyung ..... 202365  
 Yeh Te-Huei. .... 203705-190  
 Yildiz M. .... 203106  
 Yosepovich Ady ..... 201041  
 Young David ..... 203713-198

## Z

Zabolotna D. .... 203614-102, 203615-103,  
 ..... 203616-104  
 Zabolotnyi Dmytro. .... 202297, 203614-102,  
 ..... 203615-103, 203616-104  
 Zabrodskaya L. .... 203616-104  
 Zacharioudaki Evangelia .... 203214, 203220, 203332  
 Zaharioudaki E. .... 203169  
 Zaidi Asiya K. .... 203858-335, 203859-337  
 Zaidi Syed ..... 203575-93  
 Zainea Viorel. .... 203826-309  
 Zarytska I. .... 202297  
 Zavras Panagiotis ..... 203220  
 Zhang Henry. .... 201155  
 Zhang Luo ..... 203736-219  
 Zhang Nan. .... 203736-219, 203732-218  
 Zhao Rui ..... 202216  
 Zhelqzkov Ch. .... 203513-17  
 Zhulai Tetiana ..... 202670, 202733  
 Zinchenko D. .... 203614-102  
 Zinkevich D.N. .... 203664-151  
 Zisoglou M. .... 203846-323  
 Zlatanov Hristo K. .... 202035  
 Zorza Ivan ..... 202071  
 Zubčić Željko ..... 203260, 203513-20  
 Zupanets Igor ..... 202670  
 Zwagerman Nathan. .... 201393  
 Zhabkin I.V. .... 203849-326

## **CONTENT**

**ERS 2021 abstract book**

**29th congress of the European Rhinologic Society**

**Thessaloniki, Greece**

**September 26-30, 2021**